Pattern 1c: T1 Hyperintensity

Chronic hepatic encephalopathy

- bilateral and symmetric T1 hyperintensity involving the globi pallidi and substantiae nigrae — most likely due to **manganese** accumulation

- corticospinal and perirolandic signal

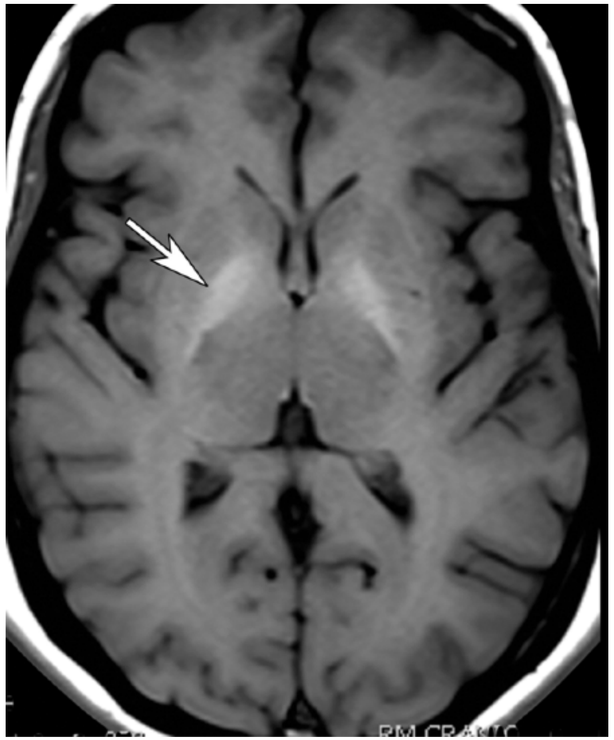

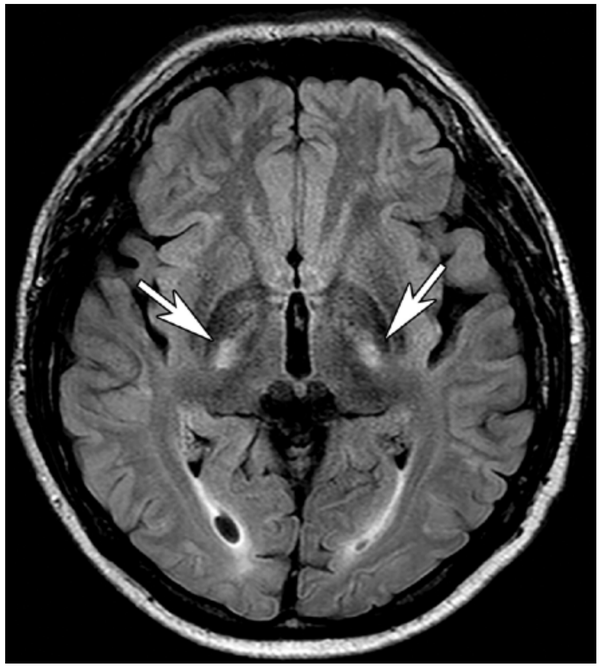

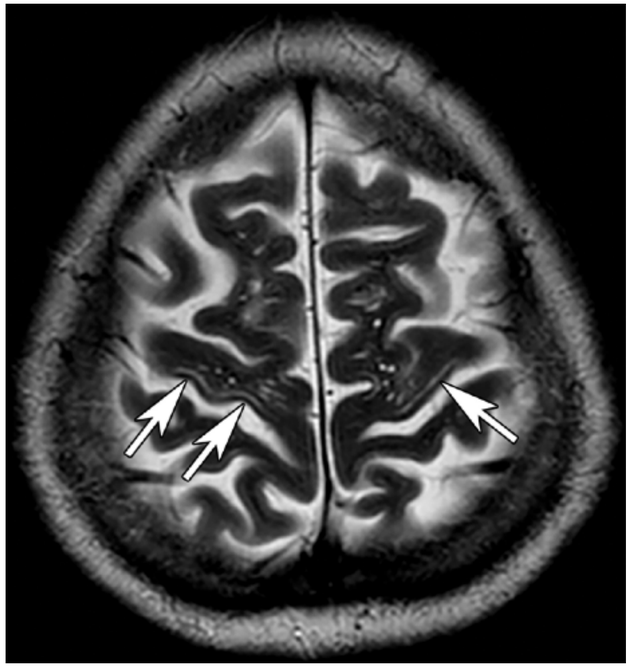
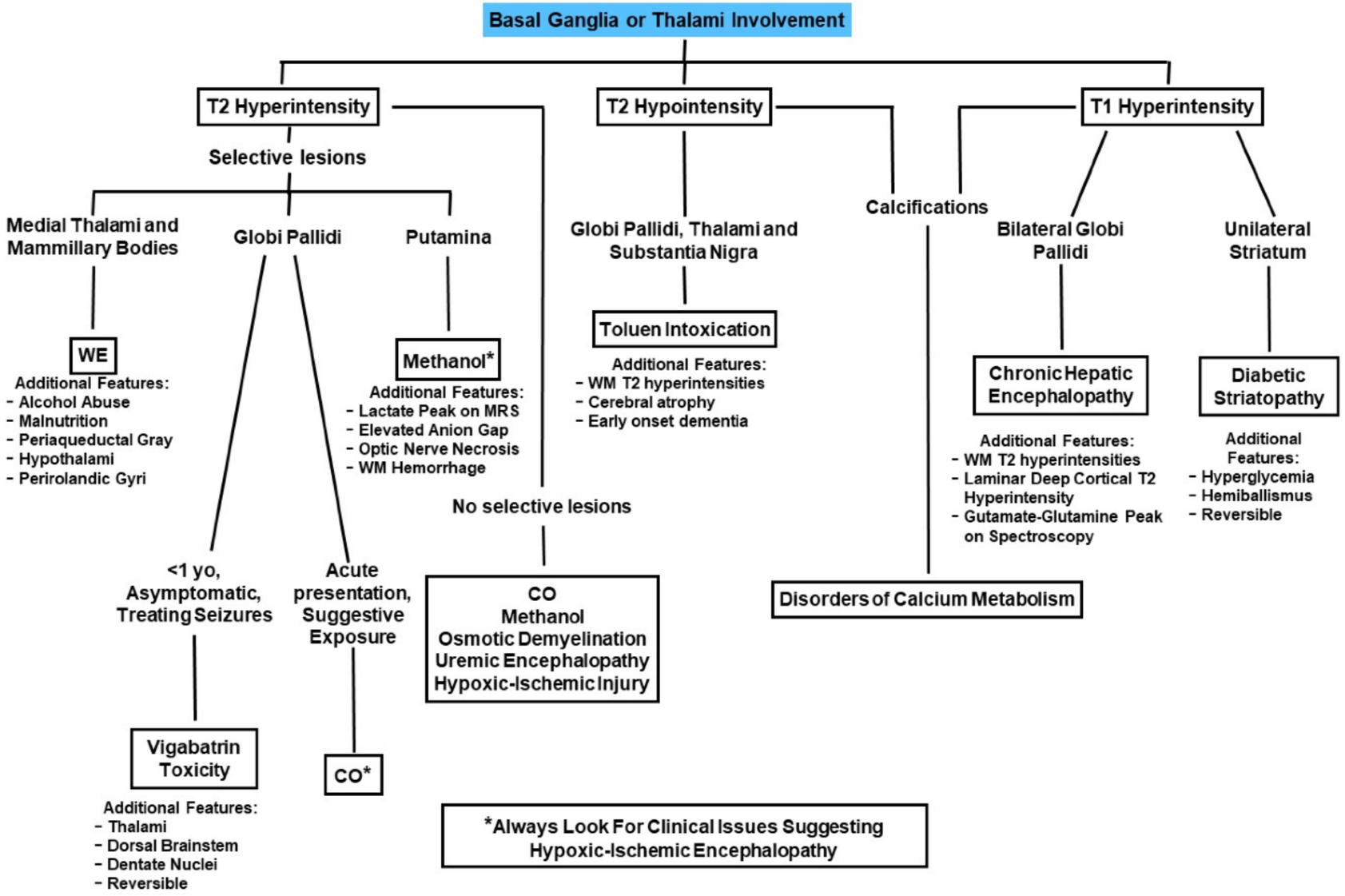
Review of Pattern 1