Imaging approach

- Toxic-metabolic disorders often produce **excitotoxic** brain injury due to excessive glutamate release
  - Symmetric
  - Mostly white matter
  - Often involves cortical gray matter, deep gray nuclei, thalami, periventricular white matter, and *corpus callosum*
    - *Corpus callosum:* derived from *corpus* "body" and *callosum* “hard”, largest white matter structure in the human brain
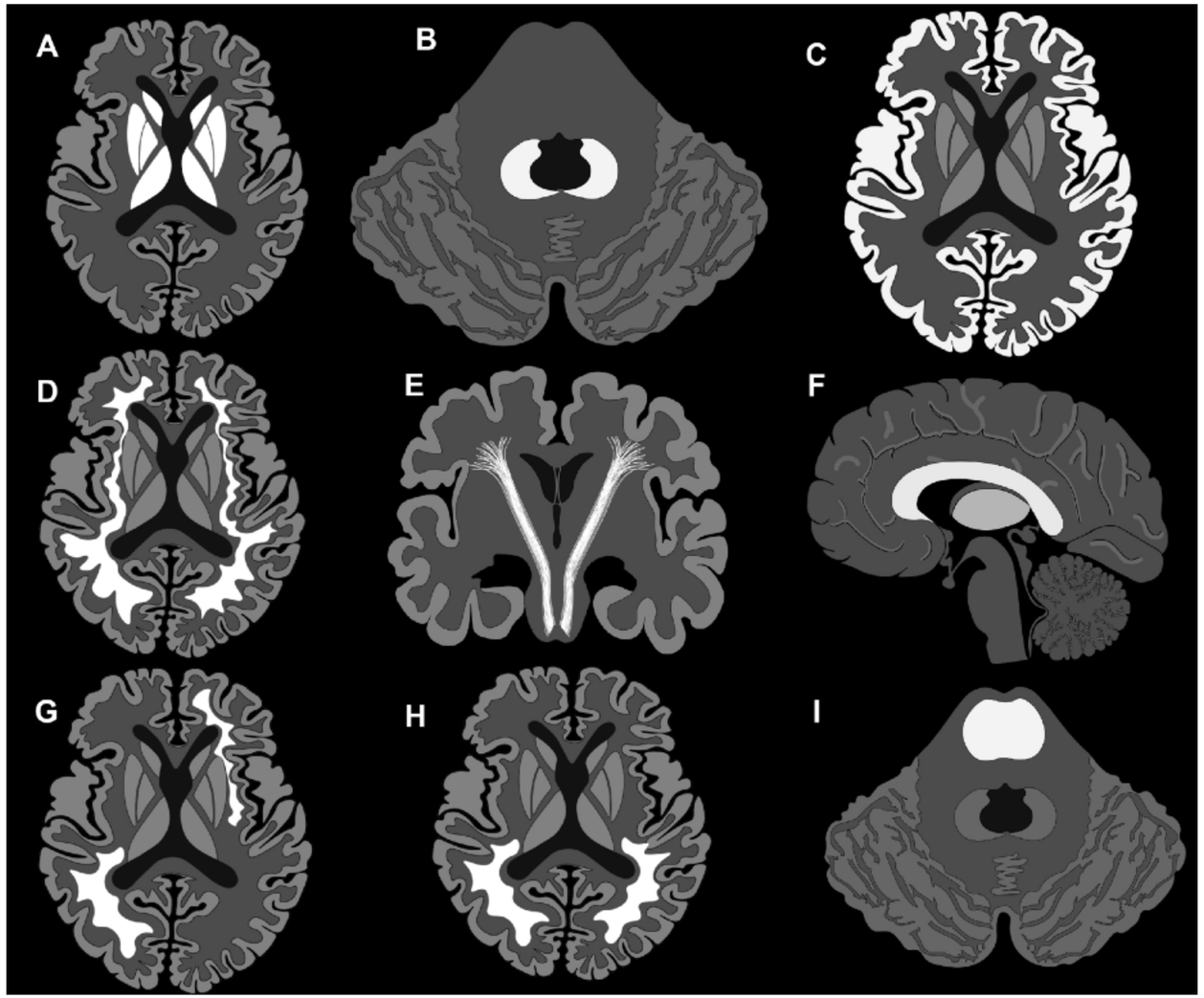
Imaging patterns in toxic and metabolic brain disorders