Pattern 3

Prominent and Symmetric Cortical Involvement with Restricted Diffusion

Parieto-Occipital Predominance; White Matter, Thalami, Cerebellar Sparing

Adult Hypoglycemic Encephalopathy

Additional Features:
- Posterior Limb of the Internal Capsule Involvement
- Thalami Sparing
- Cerebellar Sparing
- Hypoglycemia

Major Differential Diagnosis

Hypoxic-Ischemic Encephalopathy

Additional Features:
- Diffuse Cortical Involvement
- Cerebellar Involvement
- Bilateral Thalamic and Basal Ganglia Involvement
- Cardiac Arrest History

Occipital Sparing; Insula and Cingulate Gyri Involvement

Hyperammonemic Encephalopathy/ Acute Hepatic Encephalopathy

Additional Features:
- Acute Liver Failure
- Hyperammonemia
- Perirolandic Cortex Sparing
- Gutamate-Glutamine Peak at MR Spectroscopy

Pattern 4

Symmetric Periventricular White Matter Involvement
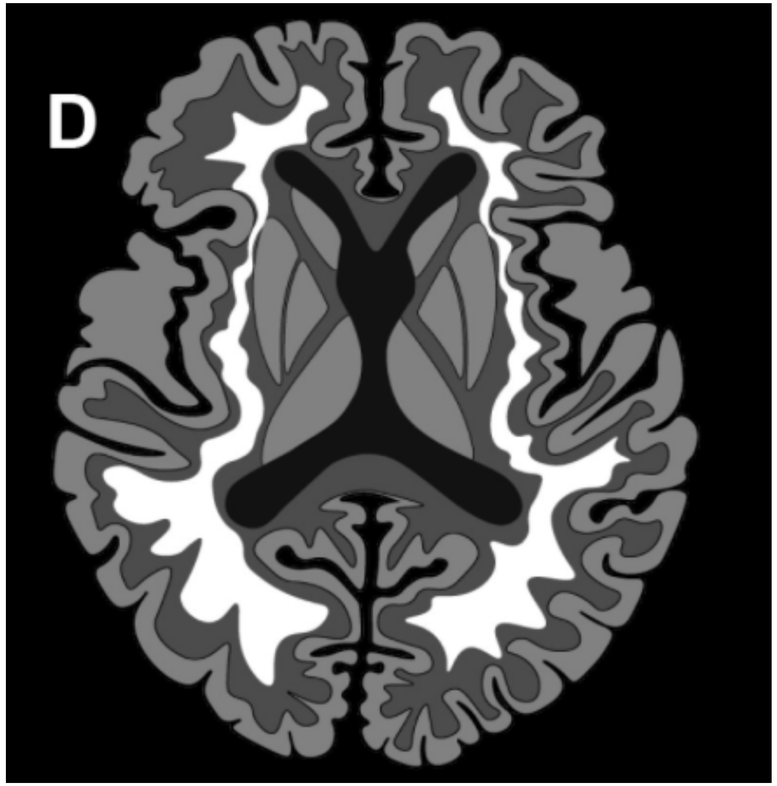
- Heroin Toxic Leukoencephalopathy
- Methotrexate and Other Chemotherapeutic Agents
- Carbon Monoxide Poisoning
- Uremic Encephalopathy
- Acute Hepatic Encephalopathy
- Other etiologies of acute toxic leukoencephalopathy…