Pattern 4

Heroin Toxic Leukoencephalopathy

- Chasing the dragon
- confluent, widespread, bilateral, symmetric white matter T2-weighted and FLAIR hyperintensities involving both the supra- and infratentorial compartments
- The basal ganglia are rarely involved

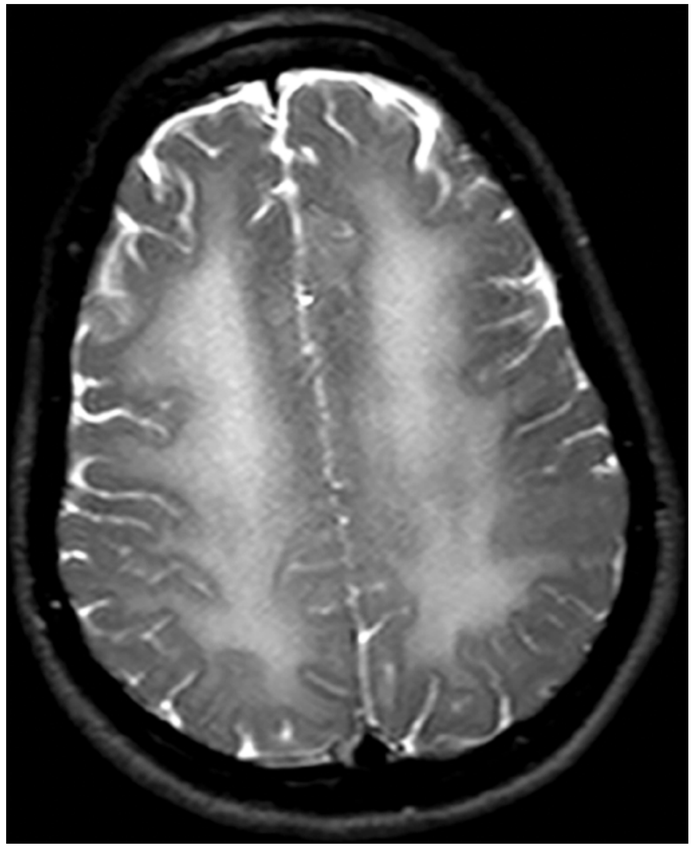

Pattern 4

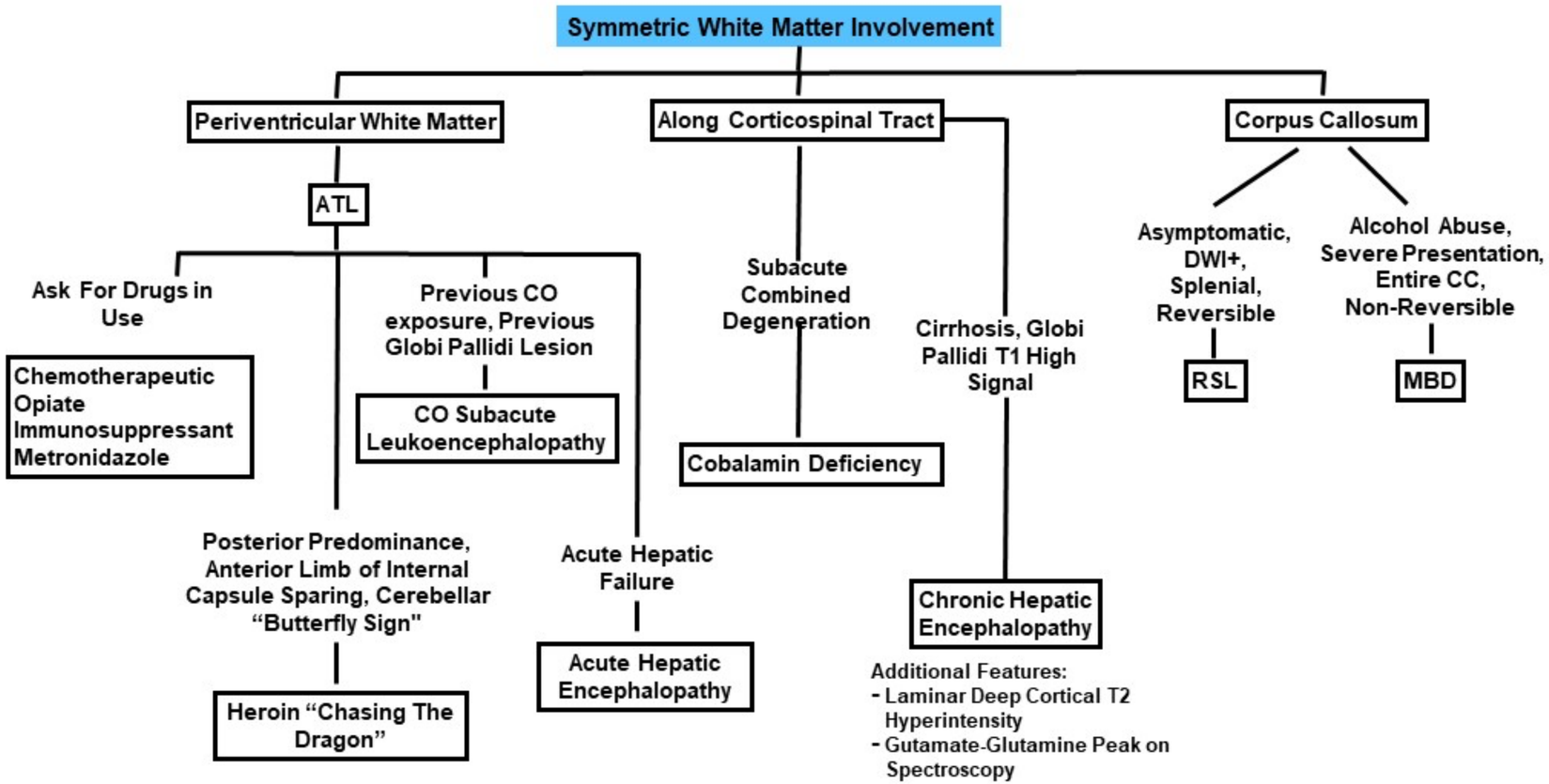
Symmetric White Matter Involvement
Periventricular White Matter
Along Corticospinal Tract
Corpus Callosum
ATL
Ask For Drugs in Use
Chemotherapeutic
Opiate
Immunosuppressant
Metronidazole
Previous CO exposure, Previous Globi Pallidi Lesion
CO Subacute Leukoencephalopathy
Posterior Predominance, Anterior Limb of Internal Capsule Sparing, Cerebellar "Butterfly Sign"
Heroin "Chasing The Dragon"
Acute Hepatic Failure
Acute Hepatic Encephalopathy
Subacute Combined Degeneration
Cobalamin Deficiency
Cirrhosis, Globi Pallidi T1 High Signal
Chronic Hepatic Encephalopathy
Additional Features:
- Laminar Deep Cortical T2 Hyperintensity
- Gutamate-Glutamine Peak on Spectroscopy
Asymptomatic, DWI+, Splenial, Reversible
RSL
Alcohol Abuse, Severe Presentation, Entire CC, Non-Reversible
MBD