Imaging patterns in toxic and metabolic brain disorders

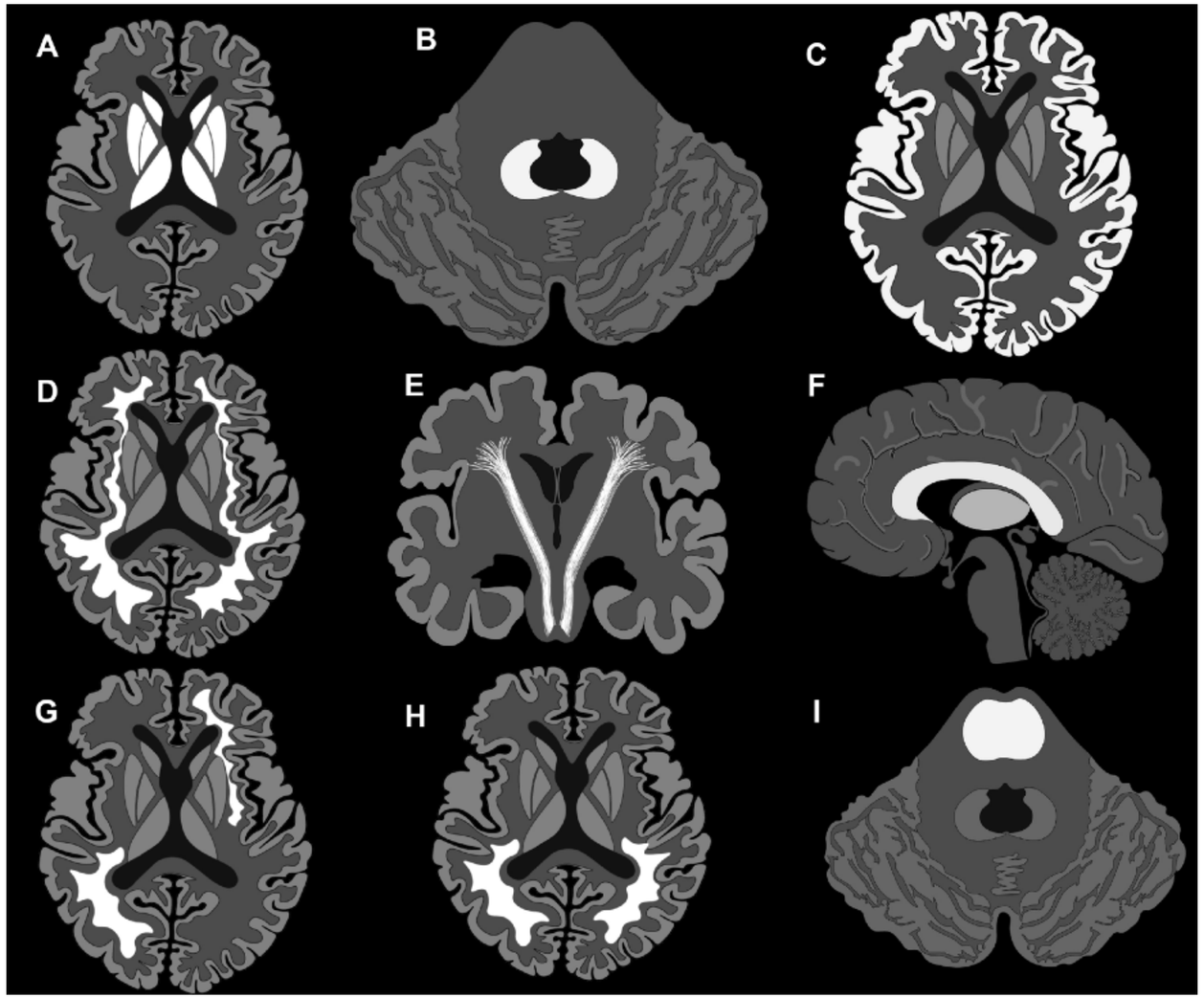

Pattern 1

Basal Ganglia and/or Thalami Involvement
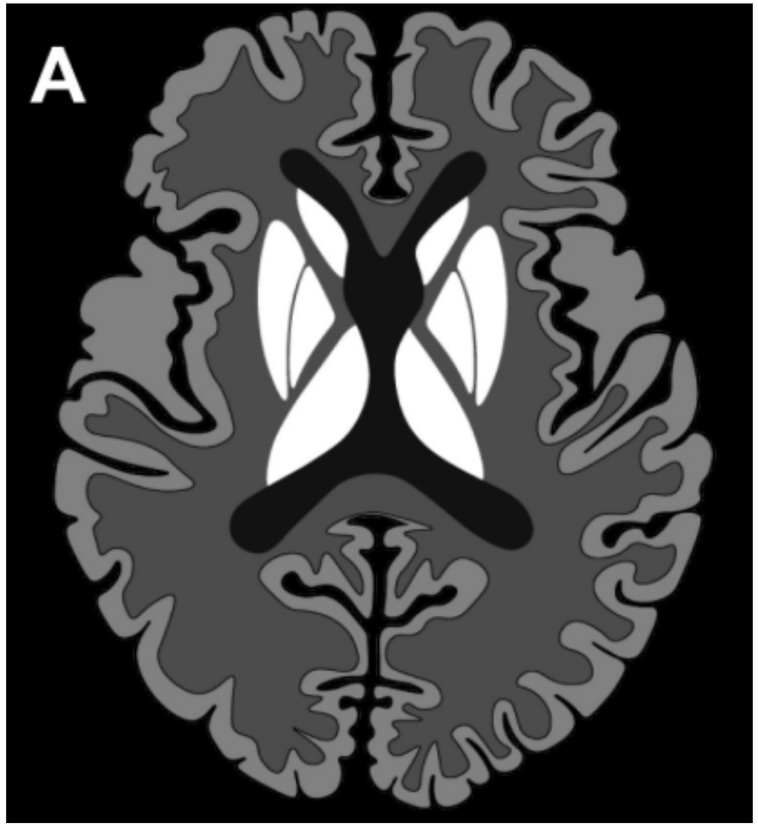
- Wernicke Encephalopathy
- Methanol Poisoning
- Carbon Monoxide Poisoning
- Vigabatrin-associated Toxicity
- Uremic Encephalopathy
- Toluene Use
- Parathyroid-Hypofunction Disorders and Hyperparathyroidism-related Disorders
- Diabetic Striatopathy
- Chronic Hepatic Encephalopathy