Pattern 4

Symmetric Periventricular White Matter Involvement

- Heroin Toxic Leukoencephalopathy
- Methotrexate and Other Chemotherapeutic Agents
- Carbon Monoxide Poisoning
- Uremic Encephalopathy
- Acute Hepatic Encephalopathy
- Other etiologies of acute toxic leukoencephalopathy…

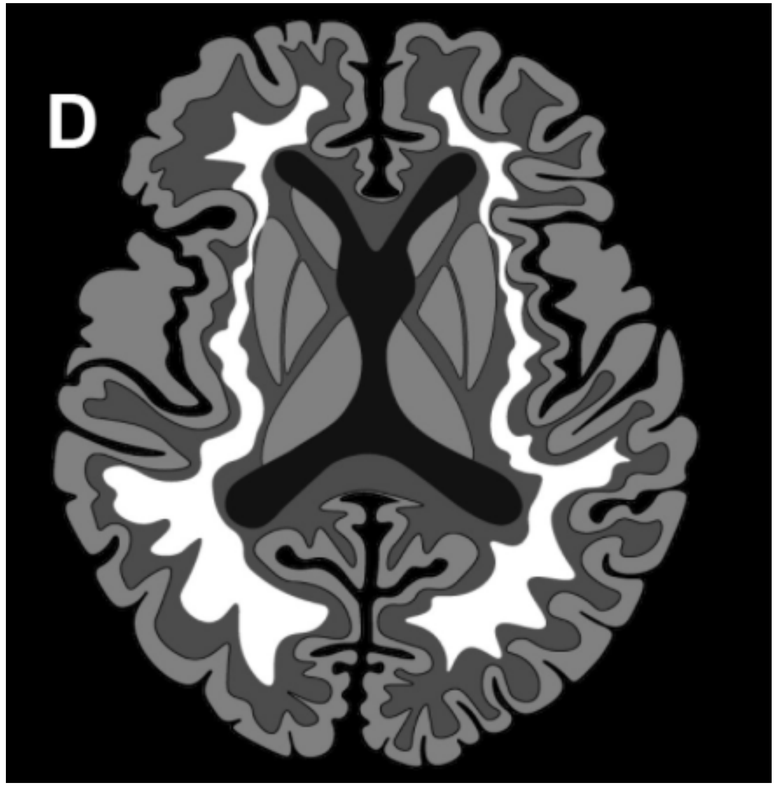

Pattern 4

Heroin Toxic Leukoencephalopathy
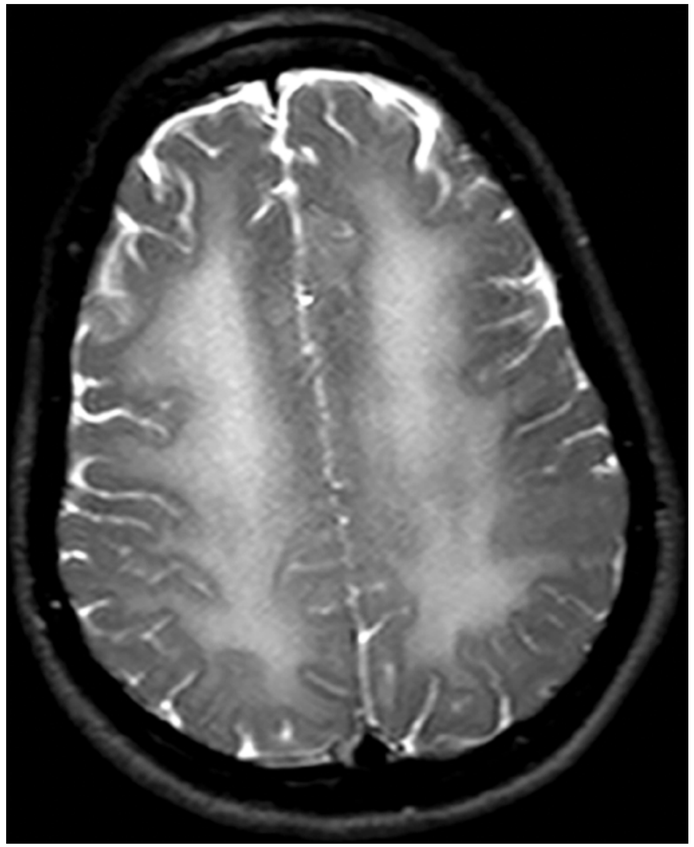
- Chasing the dragon
- confluent, widespread, bilateral, symmetric white matter T2-weighted and FLAIR hyperintensities involving both the supra- and infratentorial compartments
- The basal ganglia are rarely involved