E. S. HANDLER

THE MAST CELLS

HANS SELYE

THE MAST CELLS

WASHINGTON
BUTTERWORTHS
1965

U. S. A.: BUTTERWORTH INC.
WASHINGTON, D. C.: 7235 Wisconsin Avenue, 14

ENGLAND: BUTTERWORTH & CO. (PUBLISHERS) LTD.
LONDON: 88 Kingsway, W.C.2

AUSTRALIA: BUTTERWORTH & CO. (AUSTRALIA) LTD.
SYDNEY: 20 Loftus Street
MELBOURNE: 430 Bourke Street
BRISBANE: 240 Queen Street

CANADA: BUTTERWORTH & CO. (CANADA) LTD.
TORONTO: 1367 Danforth Avenue, 6

NEW ZEALAND: BUTTERWORTH & CO. (NEW ZEALAND) LTD.
WELLINGTON: 49/51 Ballance Street
AUCKLAND: 35 High Street

SOUTH AFRICA: BUTTERWORTH & CO. (SOUTH AFRICA) LTD.
DURBAN: 33/35 Beach Grove

LIBRARY OF CONGRESS CATALOGUE CARD NO. 65-19996

COPYRIGHT © 1965
BUTTERWORTH INC.

All rights reserved. This book is protected by copyright. No part of it may be duplicated or reproduced in any manner without written permission from the publisher.

PRINTED IN THE UNITED STATES OF AMERICA
BY WAVERLY PRESS, INC., BALTIMORE, MARYLAND

Dedicated to

GIULIO GABBIANI

Digitized by the Internet Archive
in 2023

https://archive.org/details/mastcells0000hans

Foreword

EVER since its discovery almost a century ago, the mast cell (MC) has excited the curiosity of morphologists and physiologists; more recently it has also acquired interest for pharmacologists, biochemists, and clinicians.

To the *morphologist,* the MC is an almost ubiquitous constituent of connective tissue, easily identifiable by its specific granules which stain in striking metachromatic colors with certain dyes. It occurs in all vertebrates and possibly phylogenetic precursors develop even in invertebrates. In mammals it appears during early embryonic life and persists until senility, although its aspect and distribution are modified by age. To reproduce its own kind, the MC can divide by mitosis and probably also by amitosis, but perhaps even more commonly it develops by metaplasia from other connective-tissue elements. It is probably closely related to fibroblasts and histiocytes (perhaps even to plasma cells and lymphocytes), all of which have been claimed to possess the ability of accumulating characteristic metachromatic granules in their cytoplasm, thereby giving rise to MCs.

The electron microscope is just beginning to reveal the intimate structure of this peculiar cell. It shows us, for example, the relationship between the metachromatic granules (which presumably contain specific secretions) and the mitochondria; it also visualizes the morphologic changes associated with the release of these granules into the connective tissue.

Yet, innumerable morphologic problems still remain unsolved. What are the exact structural relationships between MCs and other connective-tissue elements? To what extent can we elucidate the nature of the specific granules by the use of our new histochemical techniques? Is a phagocyte which ingested metachromatic granules an MC, merely because the latter is traditionally defined as a cell containing such inclusions?

To the *physiologist,* the MC is a "unicellular endocrine gland" which presumably regulates many vital processes such as inflammation, blood-clotting, vasomotion, hypersensitivity reactions, phagocytosis, and perhaps even metal-binding, particularly calcification. Its secretory granules act not only upon the immediate surroundings of the cell but also upon distant sites, for after entering the blood stream they are distributed throughout the entire organism.

But what are the physiologic mechanisms responsible for MC-formation and discharge? Why do different blood-borne substances cause degranulation of MCs selectively in one or the other region? How is it possible that, depending upon conditions, the liberation of the same metachromatic granule produces predominantly histamine-like, heparin-like, serotonin-like, or other physiologic actions?

To the *pharmacologist,* the MC is both a source and a target organ of various potent drugs. Its granules can be discharged by histamine liberators and certain

consequences of this discharge can be blocked by antihistaminics, antiserotonins and many other agents.

But why is it that many of these blocking agents known to nullify the pharmacologic actions of certain MC-products (e.g., those of histamine or serotonin) also affect the MC-discharge itself? To what extent will it be possible to develop specific inhibitors or potentiators of one or the other MC-product? How can certain blood-borne compounds act with an amazing degree of selectivity upon the MC-population of circumscribed regions? Through what mechanism is histamine liberated from tissues (such as hog pyloric mucosa) which are poor in MCs and yet rich in histamine?

To the *biochemist,* the MC is primarily an interesting source of several physiologically important substances. For example, pure heparin, histamine, or serotonin can be obtained from tissues rich in MCs. It is also possible to learn a great deal about the metabolism of these compounds by studies on pure MC-granule suspensions obtained by ultra-centrifugation. But the ultimate mechanisms of the synthesis and degradation of MC-products still remain challenging fields for biochemical investigation.

To the *clinician,* the most striking manifestations of MC pathology are undoubtedly furnished by urticaria pigmentosa, basophilic leukemia, and the related forms of mastocytosis. But surely this is not the only part of the MC in clinical medicine! There is good evidence that MCs participate in all forms of urticaria, in many hypersensitivity reactions, and even in nonspecific inflammatory phenomena in general. It is highly probable that this important regulator of the mesenchyma plays a part in the pathogenesis of numerous other morbid lesions as well: MCs tend to proliferate in various forms of sclerosis, and are especially abundant in the stroma of certain cancers and sometimes in keloids; they also appear to have a decisive regulating effect upon the localization of blood-borne particles. Yet, we still know virtually nothing about the clinical significance of the MC except in the case of the mastocytoses. Are there any syndromes resulting from a deficiency in MC-formation or discharge? What is the role of the MC in the genesis of collagen diseases? Does this cell play any part in the development of bone lesions other than those associated with urticaria pigmentosa?

My own interest in the MC was first aroused by the discovery of the *anaphylactoid reaction*—the peculiar Quincke edema-like, acute swelling and hyperemia of the snout, paws, and genital region—elicited by the parenteral administration of egg white in the rat. This response was subsequently shown to be provoked also by a variety of unrelated compounds (dextran, globin, certain forms of dextrin, etc.), while other agents produce essentially similar acute edematous pruriginous responses in the extremities more than in the snout (5-HT), or rather evenly over the entire skin surface (compound 48/80, polymyxin). The only obvious common feature of all these "anaphylactoidogenic" agents is that they cause acute MC-degranulation in the target areas in which they elicit edema and hyperemia. Conjointly with the discharge of the metachromatic granules, histamine and 5-HT are released from the cytoplasm and the anaphylactoid response can be prevented by

antagonists of histamine or 5-HT, as well as by a previously induced MC-discharge. All these observations suggested that the MCs and their specific products are intimately related to the pathogenesis of such anaphylactoid reactions.

More recently, it was noted that certain types of *calciphylaxis* and *calcergy* can be elicited in suitably sensitized animals by treatment with histamine liberators. When the latter cause a sudden MC-discharge under these conditions, the metachromatic granules undergo calcification as soon as they emerge from the cell body. It has long been known that certain metachromatic polysaccharides appear both in the organic bone matrix and in extraskeletal tissues undergoing calcification. Studies on the histogenesis of calciphylactic and calcergic lesions suggested that the metachromatic MC material may act as a calcium trap. Furthermore, histamine- and serotonin-blocking agents (e.g., cyproheptadine), as well as pretreatment with an MC-discharger before sensitization, actually prevent those same forms of calciphylaxis and calcergy that are normally elicited by treatment with MC-dischargers after sensitization. All these findings suggested that the MC may have yet another hitherto unsuspected function, namely, that of providing a matrix for the binding of calcium salts and the metals used for the production of calciphylaxis and calcergy.

In view of these recent developments, the time appears to be appropriate now to prepare ourselves for further work along these lines by a detailed survey of existing data on the MC.

Monographs and Reviews on Mast Cells in General

A large number of monographs and reviews deal with the morphology, physiology, and pathology of the MC in general. These are merely listed here in chronologic order, so that the reader interested in the status of knowledge at any one time may readily find surveys for general orientation. The most complete and instructive articles are marked with asterisks.

Williams D27,891/00
Bargum E20,446/03
Ducati D30,559/05
Marchand 48,306/13
Staemmler D26,807/21
Lehner D27,094/24
Brack D26,821/25
Nagayo D26,871/28
**Michels* C72,066/38
Vallone D26,432/44
Burkl D26,896/52
Sannazzari & Visioli D66,745/53
Serrão C8,615/53
Trincão D26,926/53
Asboe-Hansen D27,999/54; C77,655/57; D7,843/61
Baglioni C16,539/54
Riley B92,944/54; C9,303/55
Anonymous C20,841/56
Montagna D61,511/56
Pruniéras E61,998/56
Lacaz et al. C33,366/57
Padawer D30,194/57
Benditt C69,702/58
West C64,139/58
**Riley* C70,315/59
Braunsteiner D59,693/59
**Kelsall & Crabb* D26,076/59
Lindholm C70,944/59
Craps D27,704/60
Keller C91,531/60
Macaluso & Pasqualino D5,225/60
Niebauer C90,011/60
Riley D2,369/61
Lindner D12,409/61
Delaunay E33,429/62
Keller D39,758/62
Remy D32,662/62
Asboe-Hansen G2,134/63
Riley D61,078/63
Smith D63,031/63
Padawer G5,248/63
Benditt & Lagunoff G10,074/64
Parish E4,391/64

Acknowledgments

I would like to take this opportunity to express my heartfelt gratitude, first of all to Doctors Giulio Gabbiani and Beatriz Tuchweber, and also to Drs. D. Baic, L. Ferlini, A. Gregory, A. Kumagai, R. Lemay, R.B. Mathur, K. Paul, T. Sakai, and G. Winandy who assisted me in many of the original experiments that form the subject matter of this volume.

My special thanks are due to Mrs. E. Staub (who edited the manuscript), Mr. G. Ember (Chief of Documentation at our Institute, who helped to select the literature and prepared the Index), Mr. J. Krzyzanowski (Chief Librarian, who patiently collected even the most inaccessible publications), Mr. E. Oehnel (who was responsible for the bibliography), Mr. K. Nielsen (who prepared the histologic slides and photographic illustrations), as well as to Misses E.A. Middleton, B. Koretz, Mrs. Y. Côté and Mrs. N. Vaille (for the extraordinary care and devotion with which they prepared the typescript and read the proofs.

I would also like to thank my publishers, Butterworth Inc., Washington, especially Mr. J.K. Burgess and Mr. L.M. Vandiver for the care and attention they have given to all details of manufacture and design.

The original experimental work done at our Institute, which inspired this volume, was subsidized by: The Medical Research Council of Canada; The Ministry of Health of the Province of Quebec (Grants Nos. 604-9-277, 604-7-426); Lakeside Laboratories Inc.; Benger Laboratories Ltd.; The John A. Hartford Foundation; The U.S. Army, Medical Research and Development Command (Contract No. DA-49-193-MD-2039); U.S.P.H.S. National Heart Institute (Grant No. H-6182); The Canadian Arthritis and Rheumatism Society; The Canadian Heart Foundation, and The National Cancer Institute of Canada.

H.S.

Université de Montréal
April 1965

Prefatory Remarks on the Style of This Book

APART from its primary objective, that of coordinating the literature on the mast cell (normally abbreviated as MC in this work), I would like to use this volume to test certain ideas on the compilation of scientific monographs in general. It seems to me that through a novel style it should be possible *to facilitate fact-finding and to strictly separate the objective, concise report of previously published data from the author's evaluation of them.*

Conventionally, the preparation of a monograph progresses in two stages:

(1) The author surveys the literature and makes brief abstracts of each publication pertinent to his subject.

(2) In writing the successive chapters of his book, the author transforms these abstracts into a current narrative.

In theory, this seems to be a perfectly logical procedure and undoubtedly it can be successfully applied in some cases. However, usually the second phase of the work meets with virtually insurmountable difficulties. Whenever numerous data are accumulated by many investigators who used different techniques, the interpretations may be consonant, contradictory, or unrelated, so that a unified concise report of all relevant facts and views is hardly possible without confusing distortions or oversimplifications. But why stoop to the customary practice of verbal acrobatics designed to give the ununifiable the appearance of unity? To make sense, the incongruous monster sentences painfully synthesized by the author must later be mentally broken down into their constituent parts by the reader. What the author has coded, the reader must decode again. Statements must be very diplomatically worded to fit several papers because different authors bracketed after one remark rarely if ever have said exactly the same thing. Hence, such texts are difficult to read and in the final analysis they accomplish little more than to act as indices to the literature which still has to be procured and read in the original before it can serve as a reliable guide to further work. The essential weakness of this conventional style is that the author must formulate his remarks very vaguely whenever he wants to cite several related, but of course never identical, papers in support of a statement. This procedure is necessary for unification, but the result is uninformative or misleading, usually both.

I have learned these facts by bitter experience while writing my sixteen earlier medical texts in the conventional style. Could the usual drawbacks of monographs be avoided by a totally different approach? In compiling a scientific treatise it is undoubtedly necessary first to peruse all pertinent publications and to prepare concise abstracts of them. (Incidentally, I never minded this part of the work which was instructive and pleasant; it gave me a broad panoramic view of the observations and reflections of others, the very basis for any correlative scientific study.) But then came the deadly and uninstructive task of modifying and paraphrasing portions of my summaries so that they could be squeezed into more or

less cohesive, current prose. Why bother? All that was accomplished in this second stage was to conform with the style sanctified by common usage; but in the process, the practical value of my abstract collection was largely lost. I must admit that even after the book appeared in print, I usually still preferred to look up my original résumés. After all, the book contained only portions of these and even they were not expressed as clearly as in the abstracts, mainly for three reasons:

(1) Whenever several references are cited to document a statement, certain details have to be eliminated or put vaguely to make the text fit all the publications quoted in support of it.

(2) Transitional sentences are needed to connect one idea with another and these are only confusing ballast which does no real work.

(3) Many circumlocutions are necessary to distinguish tactfully between data which are fully, partly, or not at all, acceptable.

In other words, the first part of the work, the reading and abstracting, is pleasant, instructive, and comparatively easy while the second part, the paraphrasing into current narrative, is tedious and largely spoils the accomplishments of the first phase.

Of course, a collection of abstracts is not a monograph; it does not possess any overall structure or continuity and, even with the aid of an extensive index, it cannot act as a handy guide to a new field. Such a compendium is also necessarily uncritical and devoid of originality. It gives none of the interpretations and personal findings of the reviewer.

How could we devise a style which would combine concise, objective reporting with original interpretations without creating any confusion between the two? This is what I have tried to accomplish here, and it may be worthwhile to describe the technique in detail for those interested in the compilation of extensive monographs. We proceeded as follows:

1. Collection of literature.—A list comprising most of the literature on MCS was compiled from abstract journals, the *Index Medicus* and the bibliographies given by previous authors who wrote on this subject. The corresponding original articles were then obtained in the form of reprints or as photoreproductions. These came mostly from the journals in our two local university libraries (Université de Montréal and McGill University) and in The National Medical Library in Washington, D.C. More than 8,500 articles thus became available for study in original form and of these, 2,500 were finally selected as sufficiently relevant to warrant inclusion in the bibliography of this work. There (pp. 407-488) they are listed in alphabetic order, with the accession number they carry in our library. These same numbers, followed by a stroke and the year of publication, are also used in the text for identification. In the case of lengthy publications, the pages referred to are also given for convenience. Thus, a sentence preceded by the reference "*Lehner* D27,094/24, *p. 149*" indicates that the statement comes from the article of Lehner which bears our accession number D27,094 and was published in 1924, reference being made to a passage on page 149.

2. Abstracting.—Every abstract was dictated on magnetic tape with the original source material before me. I had to quote second hand only a few quite unavailable Doctors' theses, remarks made at congresses which published no pro-

ceedings, and "personal communications" cited by others. To avoid constant spelling out and to facilitate the task of transcription, key words, names, numbers, and complex technical terms were underlined in the original texts for the guidance of our typists.

In preparing the abstracts, we tried to incorporate all the essentials, including the species on which an observation was made, the route of administration of drugs, the techniques of determinations, etc., wherever these facts may have significantly influenced the findings. However, equal care was taken to eliminate all irrelevant data in order to make the abstracts concise and readable.

Whenever an author summarized a salient point concisely or expressed a particularly unexpected view, his own wording was quoted. Each abstract was preceded by a brief title identifying its subject matter. Articles which contained data pertaining to several chapters of this monograph were separately abstracted for each section. However, often the same summary could be used for this purpose, changing only the title. For example, in preparing an article concerned with the MC population of the guinea-pig thymus, I first dictated it with the title "Guinea-pig" (for the section on *Comparative Anatomy*) and then merely added "repeat the same abstract with the title 'Thymus' " (for the section on the *Regional Distribution of Mast Cells*).

Finally, the pages containing these abstracts were cut up into slips and taped into proper position—according to the "rail paper technique" (*Selye* E24,150/64, *p. 350*)—on a master copy provided with index tabs. At this stage, some simplification of the text became possible by citing several papers after the same remark (e.g., "Case Reports," "Reviews"), but this was done only when all references fitted the caption or statement equally well. Occasionally, when the papers cited represented interlocking stages of the same study, several abstracts were even condensed into a kind of telegraphic, current narrative.

Throughout this phase of the work, my main concern was to reflect the authors' statements objectively, whether I agreed with them or not. Only in a few instances (e.g., when the statements were contradictory or the technique faulty) was it necessary to point out possible sources of confusion, but this was done after the reference, in separate, initialed comments.

The resulting classified abstract collection corresponds to the smaller text print in this volume.

3. Critique and personal observations.—We now had a classified collection of concise abstracts which served as a convenient guide to the literature on MCs. However, precisely because of its strict objectivity and the absence of any connecting sentences between the abstracts, this text completely lacked both originality and continuity. It is useful for the experienced specialist who only wants to look up the literature on a certain point, but it gives no guidance to the beginner and contributes no unpublished new thoughts or observations.

While this bibliographic work was in progress, my associates and I were also engaged in experimental research on MCs. It was felt that the results of these investigations and the personal views formulated during the systematic study of the world literature should also be incorporated in this volume.

The published data of our group were handled in the usual manner, by preparing objective abstracts of them for the small print sections. However, my own

interpretation of the literature and our hitherto unpublished observations were reported in an entirely different, current narrative form; this text is clearly separated from the rest by being printed in a larger type. Here, there are no references, it being silently understood that the conclusions are based on a critical interpretation of the separately abstracted literature and on my personal experience. In addition, photographs and diagrams have been prepared to make the report informative.

Thus, we end up with a book within a book: the *small print* sections represent concise and impersonal abstracts of published data, formulated in telegraphic style, to be looked up but not to be read through from cover to cover; the *large print* text, on the other hand, is a critical evaluation of the literature and an illustrated description of unpublished observations. The reader who only wishes to get an overall view of the present status of knowledge on MCS can do so without getting lost in detail and confusing contradictory statements by reading only the large type sections. The investigator who wants to verify a special point quickly, will find it, without having to wade through much text, by merely consulting the classified abstracts in the corresponding section.

This new style would not lend itself to the writing of textbooks for students nor would it be suitable for monographs on entirely new subjects on which there is virtually no earlier literature; but I think it could be profitably employed in the compilation of any review, monograph, or handbook which is to combine an extensive literature survey with personal observations and critical interpretations.

In our era, in which interest and material support for research has reached unprecedented proportions, one of the greatest handicaps to the further development of science is the growing difficulty of keeping track of the ever-expanding mass of literature. Hence, a generally acceptable simplified style of reporting could be of immeasurable value. Of course, surveys written in the style used here would be most useful to laboratory men who lack the time, library facilities, or the knowledge of foreign languages necessary for a thorough personal search of the original literature on an extensive field. Yet, any competent scientist must master his own subject and, even if the scope of his investigations is limited by lack of documentation, he will eventually gain a familiarity with the publications on related subjects. This knowledge should be made available to others as well. It is hoped that the extreme simplicity of reporting in the style recommended here will encourage the writing of surveys by authors who would not have ventured to do so in the more time-consuming conventional form. Should this be the case, correlative investigations would certainly receive a welcome stimulus at a time when mass production threatens to discourage the integration of knowledge.

Contents

Dedication ..... *v*
Foreword ..... *vii*
Acknowledgments ..... *x*
Prefatory Remarks on the Style of this Book ..... *xi*

Chapter 1

HISTORY **1**

First Observations on Unstained Specimens 1
Discovery of the Mast Cell by the use of Specific Dyes 1
The Confusing Use of the Term "Plasma Cell" 2
The Mast Cells Assume Clinical Significance 2
The Anaphylactoid Inflammation 3
The Mast Cells as Carriers of Heparin 4
The Mast Cells as Carriers of Histamine 4
The Mast Cells and Hyaluronic Acid Production 4
The Mast Cells as Carriers of 5-HT 5
The Mast Cells in Calciphylaxis, Calcergy, and the Local Fixation of Blood-Borne Materials in General 5
The "Emergency Kit" Hypothesis 6
Other Possible Mast-Cell Functions 6
The Still Challenging "Riddle of the Mastocytes" 6
Original Articles 8

Chapter 2

DEFINITION AND TERMINOLOGY **11**

DEFINITION 11
TERMINOLOGY 12
Mastzellen 13
Mastocyte 13
Clasmatocyte 13
Cellules granulifères 14
Basophil Tissue Granulocytes 14
Basophil Granule Cells 14

Cellules Granuleuses . . . 14
Labrocyte . . . 14
Cellule Granulose Basofile . . . 14
Basophile mit unlöslicher Granulation . . . 14
Cellules Isoplastiques . . . 14
Cellule Tiazinofile . . . 14
Heparinocytes . . . 14
Heparinocito . . . 14
Heparinoforo . . . 14
Histaminocyte . . . 14
Hizósejt . . . 14
Trephocytes . . . 14
Sagmatocyte . . . 15
Explosive Cell . . . 15
Cellules Engrais . . . 15
Neurohormónal Cells . . . 15
Myxoblasts . . . 15
Mucinoblast . . . 15
Wanderzellen . . . 15

Chapter 3

HISTOLOGY 16

GENERALITIES . . . 16
Total Mass . . . 17
Dry Mass . . . 17
Artifacts . . . 17
Interpretation . . . 17
CLASSIFICATION . . . 17
Size and Shape . . . 19
Ortho- and Metachromatic . . . 19
Other Special Stains . . . 20
Degranulation, Lysis, Spongiosis . . . 21
Sensitivity to Histamine-Liberators . . . 21
Water Solubility of Granules . . . 21
Hyaluronidase Resistance of Granules . . . 21
Fluorescence . . . 21
Plasmamastcells . . . 21
Lymphomastcells . . . 22
Russell-Body Mastcells . . . 22
Pigment Mastcells . . . 22
Cellule Mastlipoidi . . . 22
Chromaffin Mastcells . . . 23

Stellate Mastcells 23
Histiocytoid Mastcells 24
Specific Cells of Uterus 24
Quasimastcells 24
"Kugelhaufen" 25
Blood Basophils 25
FIXATION 25
SPREAD 26
COUNTING 29
ISOLATION 30
METACHROMASIA 31
SPECIAL STAINS 36
Alcian Blue 37
Astrablue 37
Azure 37
Bismarck Brown 38
Cadmium Dye Complexes 38
Carmine, Mucicarmine 38
Celestin Blue 38
Chrysoidin 38
Dimethyl-P-Phenylenediamine 38
Elastica 38
Feulgen + Methyl Green 39
Feulgen + Bismarck Brown 39
Fite-Faraco Stain 39
Fuchsin, Aldehyde-Fuchsin 39
Gold 40
Iron, Colloidal (Hale) 40
Methylene Azure 40
Methylene Blue 40
Multipurpose Polychrome Stain 41
Neutral Red + Hematoxylin 41
Night Blue 41
Nuclear Fast Red 42
PAS 42
Pinacyanol Erythrosinate 42
Pyronin + Methyl Green 43
Rhodamin S 43
Rinehart Stain 43
Safranin 43
Tannin + Iron Hematoxylin 43
Thionin 43
Toluidine Blue 43
Vesuvin 45

HISTOCHEMISTRY 45
Heparin 46
Tryptophan 46
Arginine 46
Hyaluronic Acid 46
Ascorbic Acid 47
RNA 47
5-HT and Argyrophilia 47
Histamine 47
Adrenaline, Noradrenaline, DOPA 47
Lipids 48
Glycogen 49
Amyloid 49
Iron 49
Calcium 50
Magnesium 50
Zinc 50
Chlorides 50
Enzymes in General 50
Oxidase, Peroxidase 50
Reductase 51
Esterases in General 51
Lipase 51
Phosphatase 51
ATP-ase 52
Histidine Decarboxylase 52
5-HTP-Decarboxylase 52
Leucineaminopeptidase 52
Trypsin, Chymotrypsin, and other Proteases 53
β-Glucoronidase 53
β-Hydroxybutyric Acid Dehydrogenase 53
Succinic Dehydrogenase 53
DPN-Diaphorase 53
Various Other Compounds 53
AUTORADIOGRAPHY 54
LIGHT-MICROSCOPIC CYTOLOGY 55
Nucleus 56
Centriole 56
Golgi Apparatus 56
Mitochondria 56
Granules 57
Pigments 57
ELECTRON MICROSCOPY 57
IN-VIVO OBSERVATION 63
VITAL AND SUPRAVITAL STAINING 63

PHASE-CONTRAST MICROSCOPY 66
FLUORESCENCE MICROSCOPY 67
POLARIZED LIGHT MICROSCOPY 68
INTERFERENCE MICROSCOPY 68
CINEMATOGRAPHIC OBSERVATION 69
TISSUE CULTURE 69
HISTOPHYSIOLOGY 71
Degranulation 71
Regranulation 79
Motility 80
Phagocytosis 82
Mitosis and Amitosis 84
Formation of MCs from Other Cells 86
REGIONAL DISTRIBUTION OF MAST CELLS 90
Epithelium 93
Skin and Appendages 94
Head 95
Respiratory System 98
Digestive Tract 99
Peritoneum 103
Thymus 104
Lymph Nodes and Lymph Vessels 104
Spleen 105
Bone Marrow 106
Bone 108
Cardiovascular System 108
Joints 109
Muscles 109
Kidney 110
Urinary Passages 110
Adrenal Glands 110
Hypophysis 111
Pancreas 111
Thyroid Gland 112
Parathyroid Gland 112
Pineal Gland 112
Ovary 112
Female Accessory Sex Organs 113
Testis 117
Male Accessory Sex Organs 117
Nervous System 118
Meninges, Choroid Plexus 119
Other Tissues 120

Chapter 4

EMBRYOLOGY 121

Chapter 5

COMPARATIVE ANATOMY 123

COMPARISONS BETWEEN VARIOUS SPECIES 124
MICROBES, INVERTEBRATES 124
FISH 125
AMPHIBIA (Frogs, Toads, Newts, Salamanders) 125
REPTILES (Snakes, Lizards, Turtles) 126
BIRDS 126
MAMMALS 127
Bat 127
Cat 127
Cattle 127
Deer 127
Dog 127
Guinea-Pig 128
Hamster 128
Hedgehog 129
Horse 129
Monkey 129
Mouse 129
Opossum 130
Pig 130
Rabbit 130
Rat 131
Sheep 131
Squirrel 131

Chapter 6

AGENTS AFFECTING MAST CELLS 132

HORMONES 132
Hypophysectomy 132
ACTH 133
STH 134
Thyrotrophic Hormone (TTH) 134

Gonadotrophic Hormones (GTH) . . . 134
Adrenalectomy . . . 135
Adrenalectomy + Hormones . . . 135
Adrenalectomy + Chemical Agents . . . 136
Adrenalectomy + Physical Agents . . . 136
Adrenaline . . . 137
Glucocorticoids . . . 137
Glucocorticoids + Other Agents . . . 139
Mineralocorticoids . . . 140
Ovariectomy . . . 140
Folliculoids (Estrogens) . . . 140
Luteoids (Progestogens) . . . 142
Testoids (Androgens) . . . 142
Thyroid Hormones . . . 142
Insulin and Alloxan . . . 143
Other Hormones and Tissue Extracts . . . 143
DRUGS IN GENERAL . . . 144
Acetone . . . 148
Achromycin . . . 148
Agar-Agar . . . 148
Aleuronat . . . 148
Allicin . . . 148
Aluminum Dextran . . . 148
Amino-Caproic Acid . . . 148
Ammonium Hydroxide . . . 148
Ammonium Oxalate . . . 148
Anaphylotoxin . . . 148
Antibiotics . . . 149
Antihistamine Liberators . . . 149
Antihistaminics . . . 149
Antimitotics . . . 150
Antimony Dextran . . . 150
Arsenic . . . 150
Asbestos . . . 150
Atropine . . . 150
Aureomycin . . . 150
Bacitracin . . . 150
Bacteria, Bacterial Toxins . . . 150
Benadryl . . . 151
Benzene . . . 151
Blood Clots . . . 151
Cantharidin . . . 152
Carbon Tetrachloride . . . 152
Carboxymethylcellulose . . . 152
Carcinogens . . . 152

Carcinolytics . . . 156
Chlorpromazine . . . 156
Cholesterol . . . 156
Chondroitin Sulfate . . . 156
Chromium . . . 156
Colchicine and Podophyllin . . . 156
Colloids . . . 157
Compound 48/80 . . . 157
Compound 1935 L . . . 165
Croton . . . 165
Cyanides . . . 165
Cyclizine . . . 166
Cyproheptadine . . . 166
Decamethylene Diamine (1,10-Diaminodecane) . . . 166
Decylamine . . . 166
Dextran . . . 166
Dextrin . . . 169
Dicumarol . . . 169
Diethylaminoleate . . . 169
Dihydrotachysterol . . . 170
DOPA . . . 170
Dyes . . . 170
Egg White . . . 170
Emulsifiers . . . 170
Enzymes . . . 171
Ergot . . . 174
Ethanol . . . 174
Ethanolamine . . . 174
Ether . . . 174
Ethionine . . . 174
Ferric Dextran . . . 174
Ferric Dextrin . . . 179
Ferric Oxysaccharate . . . 181
Ferric Sorbitol . . . 181
Fluorenylacetamide . . . 181
Formaldehyde . . . 181
Gelatin . . . 183
Globulin . . . 183
Glucosamine . . . 183
Glucose . . . 183
Glycogen . . . 184
Goldthioglucose . . . 184
Hemoglobin . . . 184
Heparin . . . 184
Heptamethylene Diamine . . . 186

Hexadimethrine 186
Histamine 187
Histone 193
Hyaluronic Acid 193
Hydralazine 193
Hydrazine 193
5-Hydroxytryptamine (5-HT, Serotonin) 193
Inulin 196
Invertebrate and Plant Toxins 196
Lathyrogens 197
Lead 197
Lipids 197
Methanol 201
Monocrotaline 201
Morphine 201
Mucin 201
Sodium Salts 201
Naphthalene 201
Nitrogen Mustard 201
Octylamine 201
Ovalbumen and Ovomucoid 202
Parachloromercuribenzoate 203
Penicillin 203
Pentamidine 203
Peptone 203
*p*H 204
Phenol 204
Phenylbutazone 204
Phlogogens 204
Phospholipid-A 205
Pilocarpine 205
Plants 205
Podophyllin 205
Polymixin 205
Polyvinylpyrrolidone (PVP) 208
Propamidine 209
Protamine 209
Pyramidon 210
Pyrilamine 210
RES-Stimulators 210
Reserpine 210
Salicylates 211
Sclerosing Agents 211
Serotonin 211
Silica 211

Silver Nitrate 211
Sinomenine 211
Stilbamidine 211
Sulfanilamide 212
Tannic Acid 212
Thiourea 212
Thorium Dextrin 212
Thrombin 213
Thrombokinase 213
Thromboplastin 213
Tuberculostatics 213
d-Tubocurarine 213
Tween 20 213
Uranyl Acetate 213
Viomycin 214
Vitamin-A 214
Vitamin-B 214
Vitamin-C 214
Vitamin-D 214
Vitamin-K 215
Vitamins (Various) 215
Water (Including Osmotic Pressure) 215
STRESSORS AND PHYSICAL AGENTS 217
Mechanical Trauma, Surgical Interventions 218
Hemorrhage 219
Gravity 219
Drugs (Including Inflammatory Irritants) 219
Temperature 220
Various Other Stressors 221
Ionizing Radiation 222
Visible Light and Ultraviolet Rays 225
ALLERGY (Including Anaphylaxis, Immunity, And Other Antigen-Antibody Reactions) 225
Allergy + Various Agents 234
DIET 236
Various Complex Diets 236
Starvation 237
Calcium 237
Magnesium 237
NERVOUS STIMULI 238
SEX AND REPRODUCTION 238
Sex 238
Sexual Cycle 239
Pregnancy 239
Lactation 240

AGE . . . 240
HIBERNATION, SEASONAL VARIATIONS . . . 244
HEREDITY . . . 245
Man . . . 245
Animals . . . 245

Chapter 7

DISEASES 247

MASTOCYTOSES IN MAN . . . 247
History . . . 247
Case Reports . . . 248
Classification . . . 249
Pathologic Anatomy . . . 255
Clinical Course . . . 262
Diagnosis . . . 267
Prognosis . . . 268
Pathogenesis . . . 269
Agents Influencing the Mastocytoses of Man . . . 270
MASTOCYTOMAS IN ANIMALS . . . 275
Agents Influencing the Mastocytomas of Animals . . . 279
THE MAST CELLS IN VARIOUS DISEASES . . . 281
Dermatoses . . . 283
Keloids . . . 285
Cardiovascular Diseases . . . 285
Renal Diseases (Including Diseases of the Urinary Passages) . . . 287
Gastrointestinal Diseases . . . 288
Diseases of the Respiratory Tract . . . 289
Ocular Diseases . . . 289
Blood Dyscrasias . . . 290
Infections . . . 290
Parasitic Infestations . . . 292
Endocrine Diseases . . . 293
Various Tumors . . . 293
Carcinoids . . . 297
Rheumatoid Arthritis, Rheumatic Fever, and Other Collagenoses . . . 297
Macroglobulinemia (Waldenström) . . . 298
Nervous Diseases . . . 298
Lymphedema . . . 298
Various Other Diseases . . . 299
Diseases of Animals . . . 299

Chapter 8

BIOCHEMISTRY 301

HEPARIN AND RELATED MUCOPOLYSACCHARIDES 301
In Normal Tissues 303
In Normal Mast Cells 304
Isolated Mast-Cell Granules 304
In Human Mastocytoses 304
In Animal Mastocytomas 306
In Other Diseases 307
Following Experimental Interventions 307
Histamine and 5-HT Binding by Heparin 309
HISTAMINE AND RELATED COMPOUNDS 309
In Normal Tissues 311
In Normal Mast Cells 313
Histamine Content of Isolated MC Granules 313
In Human Mastocytoses 314
In Animal Mastocytomas 315
Following Experimental Interventions 317
Histamine in Leukocytes and Platelets 319
Histamine Synthesis by Mast Cells 319
5-HT AND RELATED COMPOUNDS 320
In Normal Tissues 320
In Normal Mast Cells 321
In Isolated Mast-Cell Granules 321
In Human Mastocytoses 321
In Animal Mastocytomas 322
Following Experimental Interventions 323
5-HT in Platelets 324
5-HT Synthesis by Mast Cells 324
Slow-Reacting Substance (SRS) 324
ENZYMES 325
Proteases in General 325
Trypsin, Chymotrypsin, MC Chymase 325
Fibrinolysin (Plasmin) 326
Hydroxylases 326
β-Glucuronidase 326
Hyaluronidase 326
Dehydrogenases 326
Esterases, TAME-ase 326
Monoamine Oxidase 327
Diaphorase 327
Phosphatidase, Lysolecithin 327
Phosphatase, ATP-ase 327

Decarboxylases . . . 327
VARIOUS OTHER COMPOUNDS . . . 328
Cerebrosides . . . 328
Lecithin . . . 328
Phosphatidyl Choline . . . 328
Nucleotides, ATP . . . 328
Neuraminic Acid . . . 328
Imidazolacetic Acid . . . 328
Cysteic Acid . . . 329
Taurine . . . 329
Chondroitin Sulfate . . . 329
DOPA . . . 329
Hyaluronic Acid . . . 329
Hexosamine . . . 329
Lipids . . . 329
Amyloid . . . 329
Calcium . . . 329
Zinc . . . 330
Iron . . . 330

Chapter 9

THE BLOOD BASOPHIL 331

MONOGRAPHS AND REVIEWS ON BLOOD BASOPHILS IN GENERAL . . . 331
HISTORY . . . 331
HISTOLOGY . . . 332
Generalities, Classification, Terminology . . . 332
Isolation, Fixation, Counting . . . 333
Histochemistry . . . 334
Electron-microscopy . . . 334
Vital and Supravital Staining . . . 335
Phase-contrast Microscopy . . . 335
Histophysiology . . . 335
EMBRYOLOGY . . . 335
COMPARATIVE ANATOMY . . . 335
AGENTS INFLUENCING THE BLOOD BASOPHILS . . . 337
Hormones . . . 338
Drugs . . . 341
Stressors, Physical Agents . . . 341
Allergy . . . 342
Diet . . . 345
Diurnal and Seasonal Variations, Hibernation . . . 345

Sex, Cycle, Pregnancy . . . 346
Age . . . 346
BASOPHILIC LEUKEMIA . . . 346
History . . . 346
Case Reports . . . 347
Classification and Terminology . . . 347
Pathologic Anatomy . . . 348
Clinical Course, Prognosis . . . 349
Diagnosis . . . 349
Etiology and Pathogenesis . . . 349
Agents Influencing Basophilic Leukemia . . . 350
The Basophils in Various Diseases . . . 351
Basophilic Leukemia in Animals . . . 355
BIOCHEMISTRY . . . 355
Heparin . . . 356
Histamine . . . 356
THEORIES . . . 357
Allergy . . . 357
Lipid Metabolism . . . 357
Other Theories . . . 357

Chapter 10

THEORIES **359**

RELATION OF BLOOD BASOPHILS TO MAST CELLS . . . 359
RELATION OF BLOOD EOSINOPHILS TO MAST CELLS . . . 364
Heparin . . . 365
Histamine . . . 366
5-HT and Related Compounds . . . 366
Slow-Reacting Substance (SRS) . . . 367
Hyaluronic Acid . . . 367
Mucin . . . 367
Catecholamines (Adrenaline, Noradrenaline) . . . 369
Pigments . . . 370
Various Other Compounds . . . 372
Connective Tissue and Nutrition . . . 372
Tumors . . . 378
Immunity, Anaphylaxis . . . 378
Anaphylactoid Inflammation . . . 379
Defense . . . 383
Stress . . . 385

Blood Vessels, Edema . . . 385
Nervous Function . . . 389
Relationship to Juxtaglomerular Apparatus . . . 390
Temperature Regulation . . . 391
Hair Growth . . . 391
Growth, Cell Proliferation . . . 392
Calcium Metabolism and Osteogenesis . . . 393
Lipid Metabolism . . . 398
Endocrine Function . . . 399
Reticuloendothelial System (RES) . . . 399
Enzymes . . . 400
Gastric Secretion . . . 400
Sweat Secretion . . . 401
Various Other Theories . . . 401

Chapter 11

OVERVIEW **403**

BIBLIOGRAPHY **407**

INDEX **493**

1

History

THE gradual evolution of our knowledge of the MC has had a very interesting and instructive history. It vividly exemplifies the dictum that it "all depends on the way you look at it."

First observations on unstained specimens

Mast cells were recognized and perfectly illustrated in a paper published by von Recklinghausen in 1863 when he described the structural elements that can be seen in the unstained mesentery of the frog. About a dozen years later the German anatomist Waldeyer was impressed by the observation that, in addition to the fibroblasts, everywhere in connective tissue there are granular cells of "embryonal" aspect which, being rich in cytoplasm, he named "plasma cells." Indeed, these cells were probably seen even earlier, but without the use of special stains the various constituents of the large heterogeneous group of "wandering connective tissue cells" look too much alike to be distinguished and characterized. Distinct cell forms were described but their fundamentally separate identities were not recognized: the MC was seen but not discovered as a special cell type.

Discovery of the mast cell by the use of specific dyes

At about this time, during the second half of the nineteenth century, Karl Weigert began to use the novel technique of staining histologic sections. He had a cousin—a young boy named Paul Ehrlich—who liked to examine his stained slides under the microscope and became fascinated by the colors and shapes of the structures he saw. The fact that struck him most was that certain parts of a cell should take up dyes selectively while the rest of the cell body remained unstained. Could this specific affinity of certain structures be used for the analysis of cell parts by means of dyes? Might it be possible to influence certain organs—perhaps even microorganisms—selectively by specific drugs given in amounts which would not hurt the rest of the body? This was the germ of the idea that was to lead Ehrlich to what we now know as specific chemotherapy; it took most of his long lifetime to develop this thought.

However, the concept brought one immediate result. While Ehrlich was still a medical student he discovered that some of the cells which Professor Waldeyer, his chief, called "plasma cells" have granules that stain red or violet when treated with a blue basic aniline dye known as dahlia. By means of this "metachromasia," he could distinguish within the large group of Waldeyer's plasma cells certain elements which he called "Mastzellen" because their cytoplasm is stuffed full

with large metachromatic granules. These cell inclusions he believed to be products of over-feeding (in German, "Mästung"—a root which we find also in the English word "mastication", from "masticare" to chew).

Using various metachromatic dyes, Erhlich proceeded to discover a great many other things about the MCs. He recognized their tendency to become concentrated around blood vessels, nerves, and glandular ducts as well as in inflammatory and neoplastic foci. He observed the extraordinary water solubility of the MC granules in certain species and was the first to point out that this feature must be kept in mind in selecting suitable fixatives and dyes for them.

The results of all these studies were incorporated in Ehrlich's Doctor's thesis (Leipzig, 1878) and presented before the Physiologic Society of Berlin on January 17th, 1879 in a memorable report which happened to be the young man's first public address.

The special identity of the MC as a distinct type within the old "plasma cell" group was soon conceded by his teacher, Waldeyer, and further elaborated in the Doctor's thesis of Ehrlich's pupil Westphal.

The confusing use of the term "plasma cell"

A few years later, the dermatologist Unna of Hamburg described a roundish or ovoid "plasma cell" with a strongly basophilic cytoplasm, a "wheel nucleus" and a characteristic juxtanuclear clear area. This cell did not stain metachromatically and was found to be particularly plentiful in tuberculous lupus, syphilis, leprosy, and other chronic inflammations.

Actually, this cell had been described and excellently illustrated previously in a Spanish text for students, written by the great histologist Ramon y Cajal. But this treatise had a limited circulation and was never translated into any other language so we can hardly blame Unna for not having known about it. Although Cajal believed these cells to be specific for syphilis—at first he even called them "syphilitic cells"—Unna hastened to give Cajal credit for the discovery as soon as the latter told him about it. Yet the world continued to call these cells "Unna's plasma cells" to the great dismay of Cajal who persisted in defending his priority with much ardor even after Unna had so willingly conceded it.

To summarize the essence of what had been learned up to this time, Waldeyer's plasma cell turned out to be a heterogeneous group consisting of numerous distinct types. These include: (1) what we now know as MCs (characterized by metachromatic granules); (2) the "syphilitic cells" of Cajal, or plasma cells of Unna (characterized by basophilia, an eccentric wheel nucleus with a juxtanuclear light area, lack of metachromasia, and special staining with certain dyes such as pyronin); (3) histiocytes (to which also belong some of Ranvier's "clasmatocytes"); (4) adventitial cells; (5) monocytes and perhaps even other hitherto not fully identified cell types. This classification was subsequently accepted by Waldeyer who withdrew his generic use of the term "plasma cell" to avoid confusion with the Cajal-Unna type of cell, the only one now so designated.

The mast cells assume clinical significance

The next important discovery was again made by Unna. In 1894 he found that the cutaneous lesions in urticaria pigmentosa consist almost exclusively of MCs. He also found the MC population of the skin to be increased—although

to a much lesser extent—in certain other dermatoses. These findings first suggested that excessive proliferation of MCs may be of clinical importance.

Thus, just before the turn of the century, the first great period in the history of the MC—that of establishing its position in normal and pathologic histology—came to an end.

The anaphylactoid inflammation

During the subsequent years, a great many observations were made on the distribution and staining properties of the MCs in various animal species under normal and abnormal conditions. However, approximately four decades went by before the beginning of the second, or experimental, period in the history of the MC. This phase—like the preceding one—was foreshadowed by previous observations. As early as 1894, Kanthack and Hardy pointed out that the MCs of mammals resemble the "explosive cells" of Astacus in that they can suddenly discharge their granules upon contact with irritants. This fact was later confirmed by several investigators, in particular by Webb who, in 1931, showed that the peritoneal MCs of the rat undergo vacuolation and degranulation following topical irritation by the intraperitoneal injection of India ink, egg white, and other compounds. Yet, these observations aroused only limited interest because most cells disintegrate when placed in contact with strong irritants; the only special feature of MC disintegration is that it occurs so easily and that the granules tend to penetrate far away from their damaged cells of origin.

During 1937, in Canada, experiments were under way to explore the possible role of histamine liberation in the development of the then newly discovered general adaptation syndrome, or G.A.S. In the course of this work, it was noted that, unlike most nonspecific stressors, intraperitoneally-injected egg white produces a peculiar urticaria-like systemic syndrome in the rat. This reaction is characterized by an acute hyperemia and edema, especially of the "acral regions" (lips, nose, tongue, ears, paws) and of the genitalia, the swelling being accompanied by intense pruritus as judged by the fact that the animals scratch themselves violently. The syndrome exhibits certain characteristics of histamine liberation (edema, hyperemia) and anaphylaxis but, since it is produced without any previous sensitization, it was called the "anaphylactoid inflammation." The response evidently differed from the nonspecific alarm reaction to stress; indeed, it could be prevented by previous exposure to a stressor of sufficient intensity to produce adrenocortical enlargement. On the other hand, adrenalectomy aggravated the anaphylactoid inflammation to such an extent that the affected regions became deeply cyanotic. Furthermore, adrenalectomized rats died after treatment with small doses of egg white which were well tolerated by intact controls.

The relationship of the anaphylactoid inflammation to the MCs was not immediately recognized, but subsequent studies in many laboratories showed that not only egg white but numerous other agents (dextran, dextrin, 48/80, polymyxin, etc.) produce similar reactions. Using this test object, several investigators were able to show later that, although the distribution of the lesions varies depending upon the agent used, the MCs in the affected regions always undergo acute degranulation associated with a discharge of histamine and 5-HT.

Thus, these experiments first called attention to the effect of stress and adrenal hormones on the development of inflammation; at the same time they furnished

a convenient and reliable disease model for the study of the complex interactions between hormones, stress, MCs, and certain drugs that cause liberation or blockade of MC products.

The mast cells as carriers of heparin

Also during the year of 1937, Jorpes and his group in Stockholm made the important discovery that heparin, a powerful anticoagulant which had been isolated from dog liver, stains metachromatically with toluidine blue and that there is a good correlation between the MC count and the heparin content of various tissues. Since MCs are particularly abundant in the vicinity of blood vessels, it was thought that they may help to prevent intravascular clotting.

At this point, it appeared that the riddle of the MCs was finally solved: their function is to produce heparin. They were consequently named "heparinocytes."

These findings also threw a new light upon the old observation of my teacher Biedl who, working with Kraus in Vienna in 1909, observed that the blood-clotting time of dogs is greatly increased in anaphylactic and peptone shock. The changes elicited by a single injection of peptone resembled the anaphylactic shock and, hence, were described as "anaphylactoid shock." In 1939, Wilander of Stockholm observed that the extraordinarily numerous hepatic MCs of the dog discharge their granules during peptone shock. The following year Jaques and Waters of Toronto found that a similar hepatic MC-discharge occurs in the dog during anaphylactic shock and is associated with a demonstrable release of heparin from the liver, accounting for the associated coagulation defect.

The mast cells as carriers of histamine

But what about the relationship of MCs to urticaria pigmentosa and anaphylactoid inflammation, both of which appeared to depend upon the liberation of histamine or similar vaso-active and edema-producing substances? During anaphylactic or peptone shock, histamine and heparin are simultaneously released from the dog liver, a fact which suggested some interrelationship between these otherwise so dissimilar biologic compounds. The nature of this relationship remained an enigma until 1953, when it was found that after treatment with lethal doses of fluorescent histamine liberators, the fluorescent material is sharply localized in the MCs which then break up and release histamine. In a series of elegant experiments, Riley in Scotland and West in England demonstrated convincingly that in various tissues the MC density agrees as well with the histamine as with the heparin content. It was thought, therefore, that it would be just as proper to call the MCs "histaminocytes" as "heparinocytes."

At this stage, it seemed that the main function of the MCs might be to regulate blood clotting through heparin production, as well as vasoconstriction and capillary permeability through the secretion of histamine. The predominantly perivascular localization of MCs in many areas appears to support this view.

The mast cells and hyaluronic acid production

Mast cells are plentiful even in lower organisms having no blood vascular system; even in mammals many MCs are far from vessels in the connective tissue. In the course of evolution, nature usually succeeds in rearranging the constituents

of living matter "purposefully," and what could regulators of blood clotting and blood vessels do at a distance from their target organs? Many earlier investigators assumed, on purely histologic grounds, that the MCs may have a trophic influence upon connective tissue in general. In 1954, Asboe-Hansen of Copenhagen reported a striking parallelism between the MC population and the hyaluronic-acid content of many normal and pathologic tissues. Consequently, he suggested that, under the influence of various hormonal stimuli, the MCs may secrete hyaluronic acid, perhaps in the form of a heparin precursor.

The mast cells as carriers of 5–HT

The next important discovery was made during 1955 by Benditt and his colleagues in the U.S.A. They found that the MCs in the peritoneal washings of the rat contain serotonin, or 5-hydroxytryptamine (5-HT). There appears to exist a fairly close parallelism between the MC population and 5-HT content of various tissues in the rat and mouse, but the MCs of most other species contain little, if any, 5-HT. Still, it is highly probable that 5-HT can be produced at least by certain MCs and that liberation of this compound also plays a role in anaphylactoid inflammation.

The mast cells in calciphylaxis, calcergy, and the local fixation of blood-borne materials in general

In 1962 while we were trying to familiarize ourselves with the various calciphylactic syndromes, it was noted that in suitably sensitized (e.g., dihydrotachysterol or parathyroid-hormone treated) rats, the administration of an MC-discharger (e.g., polymyxin) is followed by calcium precipitation around each discharged MC granule. However, this effect was conspicuous only in animals which, in addition to the treatment just mentioned, received an iron compound intravenously. In this case, first iron and then calcium appeared to be attracted to the discharged MC granules and their surroundings. Even without calciphylactic sensitization, intravenously-injected iron is guided by concurrent treatment with MC-dischargers to regions in which the latter cause MC degranulation, but in this event ferrification is not followed by calcification.

Calcergy is a phenomenon which resembles calciphylaxis but differs from the latter in that no sensitization with a calcifying compound (e.g., dihydrotachysterol or parathyroid hormone) is needed to elicit it. For example, the subcutaneous administration of various metal salts (e.g., those of lead, lanthanum, cerium) produces topical calcification at the injection site, even in otherwise untreated rats. If such a "calcergen" as lead acetate is injected intravenously to rats simultaneously given a subcutaneous injection of an MC-discharger (e.g., polymyxin, compound 48/80) or of certain MC products (e.g., 5-HT, histamine), it produces "mastocalcergy." Here, the blood-borne calcergen (in this case lead) is first localized in and around the discharged MCs in the treated subcutaneous area and subsequently it attracts calcium. Here again, the MCs appear to play a decisive role in metal binding.

This phenomenon of fixation of either calcium or other blood-borne substances (iron, lead, or even carbon particles) is abolished in animals whose MCs have previously been caused to discharge their granules. Apparently, yet another

function of the MC is "mastopexis," the local fixation of blood-borne particles by MC products. It was thought that mastopexis might also play a role in the localization of blood-borne pathogens (microbes, toxins, pigments, malignant cells). Indeed, mastopexis might give yet another extension to the original concept of Ehrlich in that even drugs which do not possess a desired tropism may be endowed with it by combination with an appropriate organotropic MC-discharger.

The "emergency kit" hypothesis

As the matter stands today, there is good evidence in support of the view that the MCs produce heparin, histamine, and, at least in certain species, 5-HT. They also participate in the local fixation of blood-borne agents. For technical reasons, it is more difficult to prove that they are the principal, or even an important, source of hyaluronic acid but this possibility must also be considered. Clearly, the MC is a pluripotent cell, a kind of emergency kit which contains a number of compounds that tissues may need, especially in regions exposed to local stress. It may be imagined, for example, that the explosive degranulation of MCs under the influence of nonspecific local stressors may help to produce an inflammatory edema which dilutes, quarantines, and eventually inactivates the irritant. Histamine liberation may play a role here by promoting edema formation, improving the local blood supply and perhaps even by enhancing the topical fixation, phagocytosis, and subsequent detoxification of blood-borne substances. 5-HT may act in a rather similar manner; whereas heparin would help to prevent blood clotting, and hyaluronic acid may assist in the formation of the connective tissue necessary for granuloma formation and wound healing.

Other possible mast-cell functions

Many other theories have been proposed. There is at least suggestive evidence to support the view that MCs may also participate in the elaboration of *mucin* (a metachromatic material possibly related to that of the MC granule), the accumulation of *pigments* (through synthesis or mastopexis), *fat metabolism* (through the lipid-clearing effect of heparin), *nervous activity* (through the neurotropic effect of MC products), *gastric secretion* (through histamine liberation), defense against *tumorigenesis, immunologic* and particularly *anaphylactic* reactions, the production of *"slow reacting substance"* (SRS) and many other functions. All these possibilities deserve further attention.

The still challenging "riddle of the mastocytes"

In this section we have surveyed only a few of the highlights gathered from the polyglot and multidisciplinary literature of some 2,500 papers that came from so many countries during the hundred years since the MCs were first recognized under the microscope by a medical student. Some of the observations cited are less important than others and the wisdom of including them in this résumé, at the expense of neglecting possibly more significant findings, may be questioned. But what author could free himself completely of subjectivity in assessing the significance and promise of a discovery? In any event, it is clear that much has been learned and it is equally clear that the "riddle of the mastocyte" is still far from being solved.

We are just beginning to have enough well-established facts to start planned systematic work without having to rely too much upon chance observations. To do this efficiently we must build upon what is already known and create easy access to it.

It is perhaps no mere coincidence that so often important contributions to the knowledge of the MC were made by associates or pupils of scientists who themselves spent a great deal of time studying this singular cell. The MC is a shy fellow who does not easily share his secrets with people who are not personally introduced by friends who know him well. Work on MCs was largely an "academic family business" because it was so difficult to get a good introduction to the field for lack of comprehensive reviews. Today it is no longer possible for any scientist to train an apprentice merely on the basis of his personal experience. That is why the present appears to be an appropriate time for the publication of a detailed guide to the complex literature available on the "Mastzellen."

Reviews:

Neumann D29,310/1890
Kanthack & Hardy D28,369/1894–95
Hardy & Wesbrook D28,474/1895
Gulland D31,619/1895–96
Leredde & Bezançon D39,509/1898
Harris D26,716/00
Williams D27,891/00
Levaditi D63,798/02
Schwenter-Trachsler D26,846/06
Lehner D27,094/24
Webb D27,897/31
Michels C72,066/38
Trincão D26,962/53
Baglioni C16,539/54
West C64,139/58
Riley C70,315/59; D2,369/61
Benditt & Lagunoff G10,074/64

von Recklinghausen D29,297/1863: Observation of granular cells in the unstained mesentery of the frog. As judged by the description, these cells were undoubtedly MCs, but their metachromatic staining ability was not recognized.

Cohnheim D31,546/1869: Description of MCs in inflamed tissue (still not identified by staining).

Waldeyer A6,120/1875: First description of MCs under the name of "Plasmazellen" in the stroma of carcinomas in man, the omentum of the mouse, the blood vessels of the dura mater in the rat, and in the subcutaneous tissue of various species. However, no distinction is made between these "plasmacells" and many other cellular elements obviously unrelated to MCs, e.g., the interstitial cells of the testis, the epithelial cells of the coccygeal and carotid body.

Ehrlich D26,864/1877: First description of the MC as a cell which takes a particular "nuance" when stained with dahlia; unlike other structures (which stain blue), it stains red-violet, as does cartilage. Here, the cell is still referred to as a special form of Waldeyer's plasmacell and the term metachromasia is not yet employed. The granules are not fatty since their tingibility is unaltered by previous defatting of the tissue. MCs are found in various species and in almost all organs, "it is more surprising not to find them than to find them." Unlike in other species, in the dog liver not only the stroma but the hepatic parenchyme itself is rich in MCs. The "hepatic star cells (Sternzellen), recently discovered by Kupffer," likewise stain with dahlia, though much less intensely than the "plasmacells." "The staining of these cells is diffuse, however, apparently in the same characteristic color nuance. . . . I am therefore inclined to agree with Kupffer's view that the star cells of the liver belong to the plasmacells." Excellent drawings illustrate various forms of MCs in diverse organs of several species.

Korybutt-Daszkiewicz D31,544/1878: Speaks of plasmacells in Waldeyer's sense which he finds in the vicinity of nerve fibers in frogs. He quotes several still earlier investigators who noted similar cells (obviously MCs) in various tissues.

Ehrlich D40,102/1878; D27,092/1879: Detailed characterization of the MCs—now named "Mastzellen"—as metachromatic connective-tissue cells. They differ from Waldeyer's plasmacells, most of which do not show metachromasia and, hence, consist of a rather heterogeneous group in which only some elements are true MCs. Large accumulations of MCs are frequently found in chronic inflammations and around carcinomas.

Westphal A8,394/1880: In this doctor's dissertation (written under Ehrlich's supervision), the tinctorial properties of the MCs are further explored and their metachromatic staining considered to be particularly characteristic. In sections of a triton heart both the myocardium and the blood in the cavities contained cells with metachromatic granules; presumably the "blood mast cells" (basophils) are essentially related to the tissue MCs.

Ranvier D31,575/1890; D31,524/1891; D31,525/00: Description of the "clasmatocytes" which are defined as cells which cast off (clasmatose) fragments of cytoplasm. It is obvious from the description that many of these clasmatocytes were actually MCs, although this has not been demonstrated here by metachromatic staining. In the newt and salamander, the MCs are exceptionally large and frequently possess arborizing processes.

Unna D27,089/1891: On the basis of their tinctorial properties, the MC granules are thought to consist of mucin. First detailed description of what we now call plasmacells. In inflamed tissues, they are distinguished from MCs by orthochromatic staining.

Kanthack & Hardy D28,369/1894–95: Brief review of the early history of MCs. They are called "explosive cells" because—like certain similarly designated cells of Astacus—they explosively discharge their granules upon irritation.

Unna D31,523/1894; D31,522/1887: Discovery of the fact that the lesions of urticaria pigmentosa consist almost exclusively of MCs. To a lesser extent, the MCs may be increased also in various other dermatoses.

Waldeyer D27,091/1895: Recognizes that the MCs form a separate group within the category that he described as plasmacells. They can be identified by their metachromatic staining.

Bäumer D27,593/1896: Review of early literature on the relationship between MCs and pigmentation, including the alleged observation of pigment granules within MCs.

Calleja D39,609/1896: MCs are demonstrable throughout the loose connective tissue of man.

Jolly D27,449/00: First clear distinction between MCs and clasmatocytes. The huge arborizing cells of amphibia are the tissue MCs of this species. In mammals some of the clasmatosing cells are MCs, while others are not.

Cajal D27,596/06: The author calls attention to the fact that in his *Manual de Anatomia patologica general* (Barcelona, 1890) he had already described Unna's plasmacells under the name of "syphilitic cells." In January, 1896 he reported in the *Boletin del Colegio médico de Madrid* that similar cells which he then called "corpuscles with chromophile protoplasm" appear around epitheliomas and may have a defensive value. The author admits that, since his observations were published in texts not commonly consulted outside of Spain, they could easily have escaped attention and as soon as he mentioned his work to Unna, the latter rushed into print to give him full credit. "However," Cajal goes on to say regretfully, "the generosity of the scientist of Hamburg [Unna] produced no effect. I have before me four monographs published these last years: those of Dantchakoff, E. Meyer, Veratti and Maximow. Among these four scientists, only Veratti mentions our investigations doing us justice, for which we are grateful to him; however, owing to a curious circumstance difficult to understand, instead of mentioning what he knows about our work in the historic part of his text and in the order of the publication dates, he puts us almost at the end of his otherwise interesting communication. The inattentive reader might conclude that our observations are only a confirmation of the publications of Unna, Marschalkó, Jadassohn, Marchand, etc. We are not accustomed to discuss questions of priority because we are convinced that in the development of scientific discoveries, the merit of individual work is often rather limited . . . Nevertheless, to honor justice and historic exactitude these facts had to be mentioned."

Biedl & Kraus D30,639/09: In the dog, Witte peptone i.v. produces an anaphylaxis-like shock with a delay in blood coagulation.

Webb D27,897/31: The peritoneal MCs of the rat show degranulation and vacuolation following i.p. injection of India ink, egg white, or potassium ferrocyanide with iron and ammonium citrate.

Selye 38,798/37: First description of an anaphylactoid inflammation. In rats, i.p. injection of egg white produces hyperemia and edema of the lips, ears, tongue, paws, and clitoris. The phenomenon diminishes in intensity after repeated daily injections. Pretreatment with a stressor (formaldehyde) abolishes anaphylactoid reactivity while adrenalectomy aggravates it. Apparently, there exists some relationship between the adrenals and inflammation. The possible role of histamine discharge during stress is considered only on theoretic grounds without experimental proof.

Jorpes et al. D26,888/37: Evidence in support of the view that the MCs contain heparin.

Michels C72,066/38: First authoritative and exhaustive review of the literature on MCs.

Wilander D29,595/38: During peptone shock, the hepatic MCs disintegrate and release their metachromatic granules which presumably contain heparin. This may account for the associated coagulation defect.

Jaques & Waters B40,648/41: The hepatic MCs of the dog disintegrate both in peptone shock and in anaphylactic shock. The anticoagulant substance responsible for the characteristic prolongation of blood-clotting time during anaphylactic shock in dogs is identified as heparin. Crystalline heparin has been isolated in good yield from the blood of dogs in anaphylactic shock but not from that of normal dogs. No heparin is liberated into the blood of sensitized hepatectomized dogs in anaphylactic shock. Much less than the normal amount of heparin can be extracted from the liver of dogs in anaphylactic shock. "It is concluded that in the dog in anaphylactic shock the heparin is liberated into the blood from the liver only."

Cazal D39,786/42: First suggestion of some relationship between histamine and MCs.

Riley & West B96,668/53: First experimental evidence supporting the view that MCs are particularly rich in histamine.

Asboe-Hansen D27,999/54: The MCs are thought to produce hyaluronic acid.

Benditt et al. B91,948/54: Ovomucoid produces MC discharge in the anaphylactoid shock organs of the rat. This change with the accompanying histamine liberation is held responsible for the phenomenon of anaphylactoid inflammation.

Benditt et al. C9,838/55: The MCs of the rat can produce 5-HT.

Jasmin C24,745/56: Degranulation of the MCs in the shock organs may be the cause of anaphylactoid reaction in the rat.

Uvnäs D25,283/61: SRS (slow reacting substance that causes smooth-muscle contraction) may be released conjointly with histamine from the MCs.

Selye D15,540/62, *pp. 16, 448*: In calciphylactically-sensitized rats, treatment with polymyxin results in the precipitation of calcific material around each MC granule. If certain iron compounds (e.g., ferric dextran, or "Fe-Dex") are injected i.v. simultaneously with polymyxin s.c., iron becomes fixed around the discharged MCs and then appears to attract calcium from the blood. If calciphylactically-sensitized rats are treated with iron preparations in which the metal is combined with a strong MC-discharger (e.g., ferric dextrin, or "Fe-Din," thorium dioxide with dextrin, or "Th-Din"), an acute anaphylactoid inflammation occurs immediately after the injection and subsequently the anaphylactoid shock organs (lips, ears, tongue, paws) become heavily calcified. Apparently, in all these instances, the MC discharge helps to localize metals selectively in certain regions.

Selye et al. D24,159/63: If the MC-discharger, polymyxin, is given s.c. simultaneously with India ink i.v., the carbon particles localize specifically in a halo around the polymyxin injection site "perhaps because mastocyte material can fix blood-borne particles by increasing the adhesiveness of tissue." If polymyxin s.c. is given somewhat prior to the India ink i.v., there is no local carbon fixation in the subcutis, but numerous pulmonary capillaries are occluded by thrombi which contain carbon aggregates. Here, the MC granules discharged from the polymyxin injection site may have reached the pulmonary circulation by the time the carbon was introduced into the circulation. It is perhaps for this reason that the carbon particles are fixed in the lung.

Repeated i.v. injections of ferric oxide saccharate (Fe-OS) produce heavy iron precipitation in the choledochus and duodenum. There is extreme dilatation of the bile ducts and

duodenal ulcer-formation in the heavily ferrified areas. Degranulated MCs are particularly numerous in the extrahepatic bile ducts and the duodenum of the rat; the iron particles precipitate around these cells. Pretreatment with an MC-discharger protects against these effects of Fe-OS.

Both these models show how MCs can participate in the localization of pathogens, drugs, and particularly pigments. The underlying process of particle binding by MC products may be referred to as "mastocytopexis" or simply "mastopexis." (*Figs. 13* and *14, pp. 180, 182.*)

Selye et al. E24,136/64: Special histochemical stains were used for the demonstration of metachromatic materials, lead, calcium phosphate, and carbonate, to study calcergy, the induction, without previous sensitization, of soft-tissue calcification by certain compounds such as lead acetate.

In simple calcergy, when lead acetate is directly injected into the subcutis, it is seen to impregnate the collagen fibers in the injection site without noteworthy participation of the MCs. The lead-treated area secondarily attracts phosphate, calcium, and possibly carbonate.

In mastocalcergy, the lead acetate is injected i.v. and local calcification is produced by the simultaneous s.c. injection of an MC-discharger such as polymyxin. Here, the MCs in the treated area first show degranulation without any mineralization, but this is soon followed by lead uptake on the MC granules with secondary attraction of phosphate, calcium, and possibly carbonate. Finally, the discharged and calcified MC granules disintegrate into a dust-like, fine precipitate which is transferred to the circumjacent collagen fibers where it initiates an intense process of mineralization, eventually leading to the complete petrification of the polymyxin-injected area.

Apparently, in addition to its already well-established functions of histamine, heparin, and serotonin production, the MC also plays a role in mineralization. (*Plate IV.*)

2

Definition and Terminology

DEFINITION

WHAT is a mast cell?

This question has been debated ever since Ehrlich defined the MC as a cell possessing metachromatic granules. But does a histiocyte become an MC upon phagocytosing metachromatic material (e.g., heparin, carrageenin, carboxymethylcellulose) being introduced into its surroundings? Does a fibroblast which takes up granules discharged from an MC automatically become an MC itself? Conversely, it may be asked whether an MC loses its identity after discharging its granules. And what if the granules are retained in the cell but merely lose their metachromasia (as occasionally happens in mastocytomas)? What if the granules are simply not yet metachromatic (as is the case in immature MCs)? Is a blood basophil an MC just because it also contains metachromatic granules? All these problems are still highly controversial today.

A good deal of confusion has also arisen in the literature because even normally orthochromatic material can be made to stain metachromatically by the use of special techniques (e.g., sulfation, oxidation, exposure to high *p*H). Do such techniques unmask a hidden natural metachromasia in certain MCs, which otherwise could not be correctly recognized as such, or is this a false metachromasia which makes other cells appear to be MCs?

The acceptance of metachromatic granules as the single diagnostic criterion of the MC has met with many additional difficulties. Epithelial mucins stain metachromatically and often form small granules within the cytoplasm before coalescing into the large masses characteristic of goblet cells. On purely morphologic grounds, it is sometimes difficult to distinguish between an intraepithelial MC and a roundish epithelial cell laden with fine mucinous granules. This difficulty is further accentuated by the fact that some histologists believe the MC granule to contain mucin, a material which eludes strict definition.

"In some disciplines (for instance, in jurisprudence and in mathematics), definitions are rigid laws which make a concept what it is; in biology, definitions can only serve as concise descriptions of the way we perceive phenomena" (*Selye* C19,000/-56). All the constituents of Nature overlap and thereby defy our urge to delimit them from each other by strict definitions; yet, we cannot study any subject without first identifying it. The possession of metachromatic granules is a highly characteristic and natural feature of the MC. Its value as an identifying tag has amply proved itself throughout the years. It was this indicator that enabled Ehrlich to recognize the MC among the largely unrelated mixture of cell types that constituted Waldeyer's plasmacells and, to date, no better single identifying characteristic has been found.

Even after having learned so much about the specific products of MCs, we cannot use any of these for histologic identification. Under the microscope, heparin, histamine, 5–HT, etc. are even more difficult to recognize with certainty than metachromasia; besides, there is good reason to believe that these compounds do not accumulate in MCs only.

In view of all these considerations, we still cannot replace Ehrlich's definition by a more appropriate one; at best, we can adjust it to eliminate the most common misconceptions created by its too rigid application to problems posed by new techniques and new observations. In this sense, and keeping in mind the many limitations inherent in all biologic definitions, it may be best to say that:

> *A mast cell is a connective-tissue element which possesses cytoplasmic granules that stain metachromatically under ordinary conditions.*

By stipulating that the MC is a connective-tissue cell, we separate it from epithelial elements containing metachromatically staining granules of mucus and even from the closely related basophils which are blood-borne and myelogenous. By specifying that the staining must occur only under "ordinary conditions," we include immature, neoplastic, or discharged true MCs (whose metachromasia is abolished only as a result of a deviation from the ordinary). At the same time, our definition excludes other cells which merely phagocytose metachromatic foreign materials or become metachromatic as a result of abnormal histochemical manipulations.

TERMINOLOGY
(Cf. also CLASSIFICATION)

Numerous terms have been proposed for the MCs, but none of these have proved to be better or more popular than Ehrlich's original designation. The term "mastocyte" is perhaps the only one that has some merit as a synonym since it substitutes the internationally understandable and generally used Greek root of "cyte" for the German "Zelle." Besides, this term is commonly employed in such expressions as "mastocytosis" or "mastocytomas." In any case, our abbreviation "MC" corresponds to both these synonyms.

Especially spirited efforts have been made to introduce the term "clasmatocyte." In some lower species, cells which contain metachromatic granules possess branching long processes, parts of which can be shed ("clasmatosis"), but it is questionable whether these really correspond to the MCs of mammals; even if they did, this would hardly be sufficient reason to rename the MCs.

The discovery that the MCs contain heparin led to the suggestion of the name "heparinocyte" but this term has also failed to become popular because, with equal reason, the MCs could be given a name reminding us of any other among their characteristic constituents. Additional proposed designations deserve no special comment here.

Reviews: *Lehner* D27,094/24, *p. 182*; *Hissard et al.* B92,293/53; *Arvy* D26,724/55, *p. 55*; *Kelsall & Crabb* D26,076/59, *p. 57*; *Macaluso & Pasqualino* D5,225/60

MASTZELLEN

Ehrlich D27,092/1879: Since metachromatic granule-containing cells are particularly numerous in tissues which proliferate as a result of inflammation or stasis, they presumably represent overfed (gemästete) elements. "From this point of view, the granular cells may, in a sense, be considered products of overfeeding of connective-tissue cells and, hence, designated as 'Mastzellen'."

MASTOCYTE

Laguesse D27,510/19: First use of the term "mastocyte."

CLASMATOCYTE

Ranvier D31,575/1890: First description of the "clasmatocytes," some of which contain metachromatic granules and may be related to MCs.

Stassano & Haas D33,741/00: The clasmatocytes of the frog are probably closely related to, if not identical with MCs.

Jolly D27,449/00; D27,635/01: The clasmatocytes of batrachians are arborizing MCs that have long pseudopodia. On the other hand, the MCs of mammals differ from clasmatocytes since they do not stain metachromatically.

Marchand B79,772/01: Clasmatocytes are not identical with MCs but they may be transformed into MCs.

Schreiber & Neumann D27,639/01; D28,537/01: The clasmatocytes of Ranvier are presumably identical with Ehrlich's MCs.

Schreiber D33,633/02: In the sciatic nerve of the frog, MCs may reach a length of ⅓–½ mm. They correspond to the clasmatocytes of Ranvier.

Schreiber D27,643/03: Polemic remarks concerning the relationships between MCs and clasmatocytes.

Schuberg D39,531/03: In the skin of the axolotl there are cells which contain metachromatic granules and possess branching long processes which give them an appearance similar to that of glia cells. Along the pseudopodia, there are many constrictions which eventually may lead to a breaking-off ("clasmatosis") of cell parts. "On the basis of these findings, I believe that there is no difference between mast cells and clasmatocytes but that these are identical."

Maximow D27,642/03; B79,778/06; D28,534/27: "The clasmatocytes of the rabbit and the mastocytes of the rat do not resemble each other even remotely." Although the two cell types are presumably related, they should not be considered identical. In mammals, no MCs are found that would correspond to the clasmatocytes described by Ranvier in amphibia. It is true that in certain amphibia, the MCs have long processes, parts of which are often detached (clasmatosed), but in mammals the MCs are essentially different from the clasmatocytes (or histiocytes) since the latter normally contain no metachromatic granules.

McKibben D27,954/14: In the meninges of the amphibian, *Necturus maculosus,* spider-shaped MCs with long filamentous pseudopodia are found. These are indistinguishable from clasmatocytes and can easily be confused with nerve cells.

Hirt et al. D33,724/39: Following treatment with trypaflavine, the subcutaneous MCs of the mouse show red fluorescent granules which turn dark brown under ultraviolet light. The MCs also exhibit slow ameboid motion and, frequently, detachment of large portions of the cytoplasm (clasmatocytosis?). Heparin solutions show a fluorescence similar to that of the MC granules.

Niessing et al. D33,744/38–39: In the subcutaneous MCs of the mouse, it is possible to follow the detachment of comparatively large cytoplasmic portions (clasmatocytosis?) under the dark-field illumination in the ultra-microscope.

Arvy D26,724/55, *p. 78*: Still uses the term "clasmatocytes" to describe MCs.

CELLULES GRANULIFÈRES

Browicz E25,818/1890.

BASOPHIL TISSUE GRANULOCYTES

Bergonzini D27,587/1891.

BASOPHIL GRANULE CELLS

Bois D27,594/04.

CELLULES GRANULEUSES

Greggio D31,536/11.

LABROCYTE

Laguesse D27,510/19; *Michels* D27,501/22; *Argaud & Pesqué* 90,375/29.

CELLULE GRANULOSE BASOFILE

Negri D31,632/41.

BASOPHILE MIT UNLÖSLICHER GRANULATION

Undritz D30,200/46: The tissue basophils of the bone marrow are designated as "basophils with insoluble granulation" because their granules, unlike those of blood basophils, are insoluble in methyl alcohol.

CELLULES ISOPLASTIQUES

Audry D27,714/1896; D27,885/1896.

CELLULE TIAZINOFILE

Vallone D26,432/44: The so-called "cellule tiazonofile" of Diamare and Tangari are identical with MCs.

HEPARINOCYTES

Härmä & Suomalainen B65,284/51; *Werle & Amann* C18,291/56.

HEPARINOCITO

de Viñals D30,196/54.

HEPARINOFORO

Paniagua et al. D39,785/53; *de Viñals* D30,196/54.

HISTAMINOCYTE

Riley B86,264/53; *Werle & Amann* C18,291/56.

HIZÓSEJT

Kelényi & Gógl G19,262/63: The term "hizósejt" ("fattened cell") is used as a synonym for MC in Hungarian.

TREPHOCYTES

Liebman D61,516/47: Trephocytes are defined as cells "which produce and ultimately liberate nutritive and growth stimulating substances." Typical trephocytes are most common among invertebrates, but in the vertebrate series, the MCs and lymphocytes belong to this group.

Kelsall & Crabb D26,076/59, *p. 1*: Discussion of the term "trephocyte."

SAGMATOCYTE

Gruber D39,683/54: The term "mastocyte" is considered unsuitable because it suggests mammary-gland cells. The German "mästen" meaning overfeeding or oversaturation, corresponds to the Latin "saginare" and the Greek "sagma" or "saktos." Hence, MC should be translated as "saginocyte", "sagmatocyte", or "saktocyte."

EXPLOSIVE CELL

Kanthack & Hardy D28,369/1894–95: Because of their great instability, the MCs of mammals are called "explosive cells" in analogy to similar unstable cells in invertebrates, particularly *Astacus*.

CELLULES ENGRAIS

Greggio D31,536/11; *Argaud & Pesqué* 90,375/29.

NEUROHORMONAL CELLS

Niebauer C90,011/60: The MCs should be considered as neurohormonal cells because "both morphologically and functionally they are integrated into the periphery of the vegetative nervous system."

MYXOBLASTS

Urtubey D27,059/48: The name "myxoblasts" (mixa = mucus) is proposed for MCs on the assumption that they produce mucoid materials.

MUCINOBLAST

Harris D26,716/00.

WANDERZELLEN

Bierich D27,096/22.

3

Histology

GENERALITIES

THIS chapter deals with the morphology of the MCs in the normal postnatal individual. In particular, we shall have to consider the classification of MCs, the techniques used for their microscopic study, and their distribution in various organs. The embryologic development and the comparative anatomy of these cells in various species will be dealt with separately in the following chapters.

By way of an introduction it should be said that, despite their widespread and irregular distribution throughout the body, the tissue MCs and blood basophils exhibit the characteristics of a single system. In this respect they are comparable to the cells of reticuloendothelial or lymphatic systems whose elements are likewise topographically diffuse and yet united by common functional characteristics. The individual members of the MC-blood-basophil system also differ greatly in their size, shape, chemical composition, and specific granule content. In addition, the nucleus of the tissue MC is essentially ovoid, while that of the blood basophil (like that of other leukocytes) exhibits characteristic constrictions. Yet, all members of the MC-basophil system possess metachromatic granules containing heparin, histamine, and, in some species, 5–HT; furthermore, all these cells respond to certain stimuli (for example, histamine-dischargers, anaphylaxis, and so on) by the discharge of their granules.

Much of the literature on MCs and blood basophils is difficult to interpret because these cells cannot be identified with certainty unless their granules are preserved and properly stained with metachromatic dyes. Many erroneous statements in the literature are due to the fact that the MCs and blood basophils are highly subject to artifacts owing to improper handling and poor fixation, which may lead to the loss of granules. In our interpretation of the results, we shall take such sources of error into consideration, but in the abstracts of original articles, we shall adhere strictly to the descriptions given by the authors in order to avoid confusion between the views expressed by them and our own evaluation.

Reviews:

Schwenter-Trachsler E21,126/10
Beylot & Baudrimont D65,654/22
Michels D65,511/23; C72,066/38
Trincão D26,962/53
Asboe-Hansen D27,999/54
Baglioni C16,539/54, *p. 173*
McManus C821/54
Rondanelli D26,656/55
Arvy D26,724/55, *p. 56*
Pindborg E20,183/56
Fulton et al. C35,831/57
Goldstein D65,537/62
Benditt & Lagunoff G10,074/64

TOTAL MASS

Asboe-Hansen C65,350/59; *Rupe* D58,296/63: The total mass of all the MCs in the body is estimated to be larger than that of the liver. [?(*H.S.*)]

DRY MASS

Ottoson et al. D31,592/58: Both by interference microscopy and by X-ray absorption measurements, the dry mass of MCs from the peritoneal cavity of the rat was found to be approximately 2.0 ± 0.1 g 10^{-10}. This was not altered by treatment with compound 48/80. "Thus it appears that 48/80 in vitro does not cause loss of dry mass from those mast cells which remain intact."

ARTIFACTS

Devitt et al. B96,691/54: The appearance of swelling, degranulation, or granule conglomeration is so common in the MCs of the rat that no definite change can be registered following intense overdosage with thyroxin, desoxycorticosterone, cortisone, heparin, hyaluronidase, or even 48/80. [?(*H.S.*)]

Mills et al. D39,712/58: Specimens of human and rat tissues, fixed at intervals up to 24 hours, showed no appreciable disintegration of MCs as a consequence of autolysis.

Parish E4,391/64: Cleavage lines appearing in MCs are probably due to pressure by contiguous collagen fibrils. Granule shedding may be caused by mechanical injury. Vacuolation of the cytoplasm or the granules and change from orthochromatic to metachromatic staining may follow delay of fixation after death and trauma to tissues. Another artifact resulting from poor fixation or staining is the diffusion of metachromatic or orthochromatic material into the surroundings of the MCs. "Blisters" of the cell wall may likewise be artifacts but they can also occur as a natural phenomenon in vivo.

INTERPRETATION

Cawley et al. D26,741/59: Detailed discussion of the interpretation of the staining qualities of MC granules as shown by diverse methods. It is pointed out that the MCs of human mastocytomas stain well with alcian blue, colloidal iron, and toluidine blue.

Montagna et al. D27,628/54: The cutaneous MCs of patients with urticaria pigmentosa show maximal metachromatic staining of their granules with toluidine blue at *p*H 5.0. At a lower *p*H, not all the granules stain; at a higher one, the granules and the intergranular cytoplasm progressively stain more orthochromatically. After digestion with ribonuclease and staining with toluidine blue, buffered to *p*H 4.0 or 5.0, the MC granules are cherry-red and all traces of orthochromatic staining are abolished. When stained at *p*H 6.0 or above, the cytoplasm and the granules attain their strong blue stain as if they had not been enzymatically digested. The same sections may be stained, destained, and restained at any desired *p*H, with excellent results. Both the cytoplasm and the granules are PAS-positive, but the granules stain more intensely than the background. After PAS, subsequent staining with toluidine blue reveals brilliantly metachromatic MC granules "suggesting that the metachromatic and the Schiff-reactive substances, although co-existent, may be in fact separate elements. Mast granules, according to these tinctorial reactions, then, may contain four substances: (*a*) a protein cytoskeleton stainable with toluidine blue, buffered to *p*H 6.0 or above; (*b*) some ribonucleic acid removable with ribonuclease and stainable with toluidine blue, buffered to *p*H 5.0 or below; (*c*) an acid mucopolysaccharide which stains metachromatically; and (*d*) a Schiff-reactive substance."

CLASSIFICATION

Numerous attempts have been made to classify the MCs into different groups on the basis of their shape, staining properties, or functional responses to various agents. It is well known that both the shape and the tinctorial properties of MCs vary greatly in different species and even in different tissues of the same individual.

Some MCs are small and roundish, while others may be spindle or star-shaped and occasionally they are provided with extremely long processes that give them a neuroglia or nerve-cell-like appearance. In some MCs ortho-, in others metachromatic granules predominate, and several special staining techniques have been shown to distinguish between various types of MCs. However, there are many intermediate stages between the diverse forms of MCs and there is no convincing evidence to prove that there exist essentially distinct strains of them. It is much more probable that the manifold types merely represent variants of the same cell at different stages of maturity or activity and structural adaptations to the surrounding tissues.

The presence of metachromatic granules in plasmacells, lymphocytes, and Russell body cells induced some authors to distinguish the *"plasmamastcell", "lymphomastcell", "histocytoid mast cell",* and *"Russell body mast cell"* as special types. However, all these elements might result from the phagocytosis of metachromatic granules discharged by true MCs. We have often seen the ingestion of metachromatic granules by polymorphonuclear leukocytes in the connective tissue of rats at sites where massive doses of MC-dischargers were injected. Here, one could even raise the question whether the resulting elements are *"polymorphonuclear leukocyte mast cells"* or artificially produced blood basophils arising outside the bone marrow.

The so-called *"pigment mast cells"* and *"lipid mast cells"* ("cellule mast-lipoidi") could be interpreted as histiocytes which have ingested pigment or lipid particles as well as metachromatic granules. An alternative possibility is that ordinary MCs can phagocytose pigment and lipid. We have amply demonstrated, in connection with our work on calciphylaxis and calcergy, that MCs can bind various metals to their specific granules, but, of course, the resulting elements do not represent new cell types.

Certain cells in human skin have been designated as *"chromaffin mast cells"* because they allegedly contain both chromaffin and metachromatic material but their relationship to true MCs is far from definitely established. The same is true of the *"specific cells of the uterus"* and the epithelioid elements in the *juxtaglomerular apparatus* which, under certain circumstances, also contain metachromatically-staining materials.

The term *"quasi mast cell"* has been applied to connective-tissue cells which have phagocytosed heparin or other exogenous metachromatic materials. This designation has its merits since it emphasizes the difference between such MC-like elements and true MCs. "*Pseudo mast cells*" may be a better term for them.

In conclusion, it would seem advisable not to accept any strict system of classification until more is learned about the possible existence of essentially different MC categories. In the meantime, it will suffice to characterize the various forms by mentioning their most outstanding features (small, large, stellate, orthochromatic, lipid-containing, etc.), keeping in mind that the distinct types may well represent only stages in the life cycle of the same structural element.

Reviews: *Vallone* D26,432/44
Baglioni C16,539/54
Nepriakhin D26,879/56

SIZE AND SHAPE

Harris D26,716/00: Four essentially different types of MCs are distinguished: (1) the *large* MCs of Ehrlich; (2) comparatively *small* MCs with nuclei similar to those of lymphocytes and relatively few granules; they are found around the lymphatics; (3) the *blood* MC or basophil; and (4) the *muscle-fiber* MCs which have the shape of smooth muscle cells and contain particularly fine metachromatic granules.

de Viñals D13,202/31: Observations on the mouse support the concept of Urtubey that we must distinguish four types of MCs: (1) *large oval* cells; (2) large cells with *fringy* cytoplasm; (3) large cells with *irregularly expanded* cytoplasm; and (4) *spindle-shaped* cells. However, all these forms are considered as evolutionary changes in the development of the same structural element (*Fig. 1*).

Holmgren 93,302/46: Two types of MCs are distinguished: *Type A* possesses a large nucleus which is poor in chromatin and resembles that of mesenchymal cells, and *Type B* which has a small nucleus, rich in chromatin, similar to that of lymphocytes. These two cell types are distinguishable in early human embryos and remain evident during post-embryonic life.

Kabelitz D33,664/49: Two types of MCs are found in human sternal bone marrow: *Type 1* has a small round, dense nucleus, *Type 2* a larger, oval nucleus with a fine chromatin network.

Montagna & Melaragno D26,849/53: In the human skin, two types of MCs can be distinguished, one is designated as *"typical"* and possesses a rounded or oval outline with many coarse granules which stain strongly metachromatically with toluidine blue even at a low *p*H. The other type resembles *fibroblasts* in shape, possesses sparse, fine granules which stain metachromatically only at a low *p*H. The latter are considered to be immature precursors of the former.

de Viñals D30,196/54: According to their size, shape, and granulation, four types of MCs are distinguished.

Szirmai C43,968/57: Attention is called to the difficulty of distinguishing the different types of MCs merely on the basis of structural characteristics. Mechanical and chemical influences from the adjacent tissues may modify the appearance of these cells and thus give the impression of different types.

ORTHO- AND METACHROMATIC

Riley B90,275/53: Two types of MCs are distinguished in the subcutis, mesentery, and omentum of the rat: *Type I* is found chiefly in the adventitia of vessels with muscle coats often lying in rows. It stains orthochromatically and so densely as to obscure the nucleus. *Type II* are larger cells filled with metachromatic granules and found mainly around capillaries as well as free in tissue spaces. The orthochromatic Type I cells are considered to be early forms from which Type II develop.

Villavicencio & de Takats C56,397/58: In the rat mesentery, the perivascular MCs show orthochromatic staining, with some metachromatic granules, while most of those in the connective tissue, far from vessels, show intense metachromasia (purple-red color) upon staining with toluidine blue.

Takeda C60,737/58: On the basis of their tingibility, the tissue MCs of the rat and mouse can be classified into the "immature" and "mature" types. The immature type contains PAS-positive granules (presumed to be mono-sulfated heparin acid) and stains orthochromatically with toluidine blue and thionine. These cells lie chiefly around muscular blood vessels. The mature type, on the other hand, contains no PAS-positive material, stains metachromatically with toluidine blue and thionine, and lies predominantly around capillaries and in loose connective tissue. It is supposed to contain polysulfatic esters of heparin. The different forms of stainability are assumed by the author to reflect different stages in the esterification of heparin.

Jasmin & Bois D27,951/61: Following double staining with alcian blue and cresyl violet, two types of MCs are distinguished according to their affinity for one or the other of these dyes. "It was concluded that alcian blue stains immature mast cells that do not contain

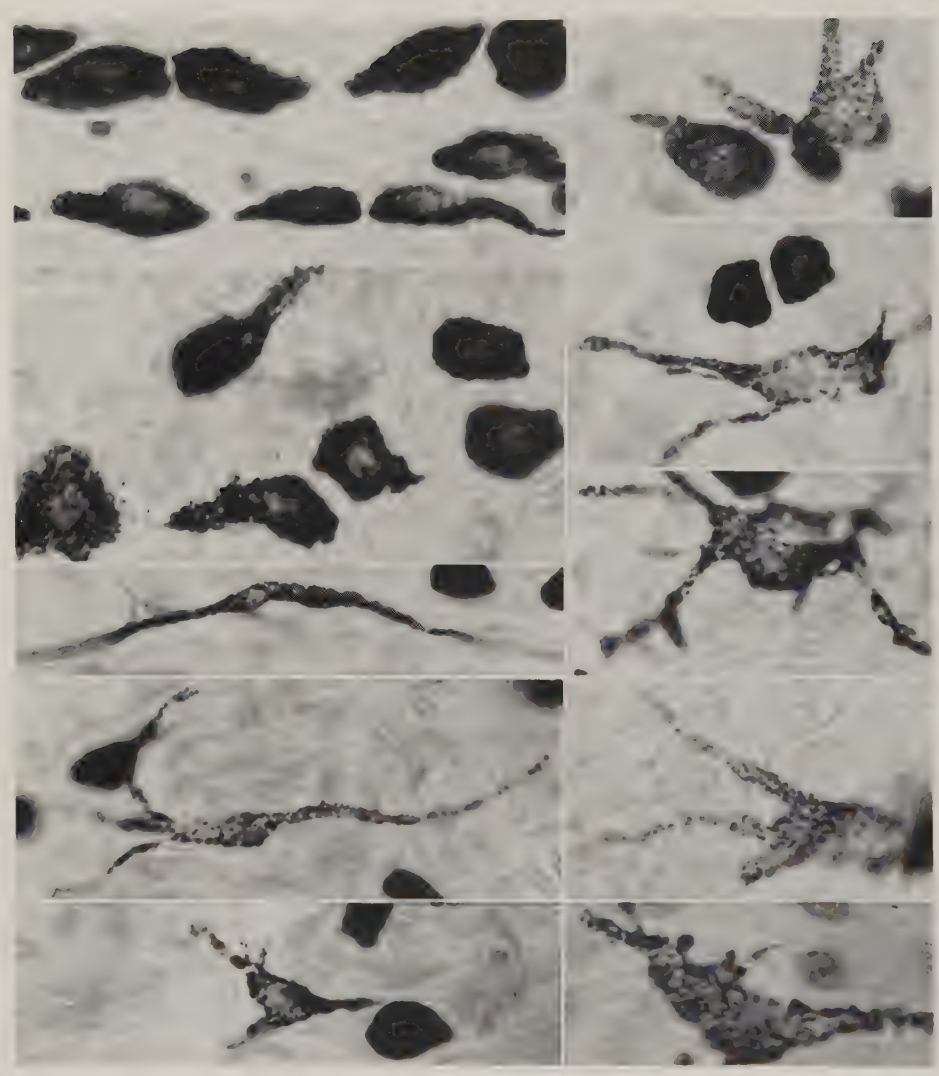

Figure 1.—Roundish, elongated, and spider-shaped mast cells in the external periosteum of the calvarium of the rat. (Azure A, X 750.)

sulfated polysaccharides, whereas cresyl violet stains mature mast cells in which sulfate polysaccharides are found." Upon sulfation, all MCs stain metachromatically with cresyl violet.

Simpson D58,271/63: Occasionally, MCs can contain both ortho- and metachromatically-staining granules.

OTHER SPECIAL STAINS

Wislocki & Fawcett D30,373/51: In the rat mesentery, two types of MCs (with intermediate forms) are distinguishable on the basis of size and of staining with *PAS*: "compact cells with both granules and intergranular cytoplasm stained an intense red, and larger cells in which the reaction—mainly intergranular—was faint or negative."

Spicer C92,580/60: With combined *alcian blue safranin* stain, certain MCs color blue, others red. In aged mice, MCs are often closely associated with iron and lipofuscin-laden

macrophages in many organs. "It is possible that mast cells phagocytize iron or lipid or that, alternatively, heparin functions in some manner to influence phagocytic processes."

Radden D33,222/62: The specific *stain of Radden* (D26,768/60) dyes only mature MC granules (thought to contain highly sulfated forms of heparin) in various organs of the rat. The immature MCs (presumably containing heparin monosulfate) were not stained by this specific stain but by aqueous methylene blue.

DEGRANULATION, LYSIS, SPONGIOSIS

Hill C64,094/58: On the basis of histologic observations, it is assumed that vacuolization of MCs is related to histamine discharge, complete lysis of the granules to the secretion of heparin, and excretion of granules after intracellular loss of their tingibility to the production of ground substances, particularly mucopolysaccharides of the hyaluronic acid type. Thus, apparently there are three types of MC responses preponderantly characterized by degranulation, lysis and spongiosis. [In practice, there are so many transitions between these types, however, that it remains questionable whether such a distinction can be strictly applied (*H.S.*).]

SENSITIVITY TO HISTAMINE-LIBERATORS

Lagunoff & Benditt D26,708/60: Rat peritoneal MCs, isolated on the surface of a Millipore filter, released their granules and histamine upon exposure to 48/80 or polymyxin but not under the influence of dextran or ovomucoid. [It will be remembered that dextran and ovomucoid, unlike compound 48/80 and polymyxin, produce the "acral type" of anaphylactoid reaction in vivo. It remains to be seen whether the MCs of the face and paws, which are particularly sensitive to dextran and ovomucoid, would respond to these agents in vitro also, thus suggesting the existence of two types of MCs that can be distinguished by their sensitivity to certain histamine liberators (*H.S.*).]

WATER SOLUBILITY OF GRANULES

Michaelis D27,717/02: Two classes of MCs can be distinguished in man: those with water-soluble and those with water-insoluble granules.

Séguin D27,447/12: In the horse, the MCs of the submucosa in the large intestine contain water-insoluble granules while those of the mucosa are water soluble. This may depend upon the different origin or different functional activity of the two types of MCs.

HYALURONIDASE RESISTANCE OF GRANULES

Velican & Velican D27,405/59: When exposed to hyaluronidase in vitro, the metachromatic granules of certain MCs of man do, while others do not, lose their metachromasia. Apparently, "in certain mast cells the metachromatic content consists exclusively of hyaluronic acid, while in others this substance forms a certain part of the metachromatic material."

FLUORESCENCE

Adams-Ray E37,378/64: As judged by fluorescence microscopy there exist two types of MCs in the skin of various species. This confirms earlier electron-microscopic observations on human MCs which likewise revealed two types of cells with different morphology (*Hibbs et al.* D26,893/60; *Phillips et al.* D26,570/60). [Cf. also CHROMAFFIN MCs.]

Falck et al. G19,000/64: Cells, whose chromaffinity derives from stored dopamine, occur widely distributed in the tissues of ruminants. This cell system has now been studied by a fluorescence method highly sensitive and specific for catecholamines and 5–HT. Cells with an intense green granular fluorescence, typical for primary catecholamines, were found in all tissues of the cow and sheep. Their distribution corresponded with the occurrence of dopamine, but not with that of noradrenaline. "The fluorescent cells had the typical morphology, distributional pattern and staining properties of mast cells and must thus be considered to be such."

PLASMAMASTCELLS

Krompecher D28,276/1898; *Martinotti* D30,606/1891: Certain otherwise typical plasma cells contain metachromatic granules and may represent transitional forms between Unna's plasma cell and Ehrlich's MC. They are designated as "plasmamastcells."

Schridde D31,610/05; *Marschalkó* D31,616/00: Plasma cells with typical metachromatic granules do occur occasionally in various tissues of man.

Downey D33,660/11: There are intermediate forms between plasma cells and MCs. It is assumed that the latter can develop from the former.

Greggio D31,536/11: It is questionable whether the so-called plasmamastcells are really true MCs.

Proell D33,635/11: Basophil granules, similar to those of MCs, occur in plasma cells and lymphocytes. "The occurrence of basophil granules in lymphocytes, plasma cells and fibroblasts signifies a close relationship between the three cell forms which apparently represent only different stages in the development of the same fundamental cell type."

Weill A1,826/13: In the human thymus, transitional forms between plasma cells and MCs are frequently found.

Michels & Globus D27,401/29: Transitional types between the plasma cell and the MC are described as "plasmamastcells" in syphilitic perivascular infiltrates of the central nervous system in man.

Michels D28,685/31; C72,066/38, *p. 298*: General characterization of plasmamastcells.

Asplund & Holmgren B17,599/47: A review of the literature, and personal observations, throw doubt upon the existence of a special "plasmamastcell."

Larsen D33,726/61: In rabbits in which uveitis was produced by intraocular injection of horse serum, "plasmacytoid" cells with metachromatic granules appear but these are distinguished from true MCs.

LYMPHOMASTCELLS

Maximow B79,779/07: During embryonic life in various species, MCs develop by the gradual accumulation of metachromatic granules in lymphocytoid wandering cells.

Pappenheim D33,701/08: Discussion of possible transitional changes between lymphocytes and MCs.

Downey D33,660/11: There are intermediate forms between lymphocytes and MCs. It is assumed that the latter can develop from the former.

Proell D33,635/11: Basophil granules, similar to those of MCs, occur also in plasma cells and lymphocytes. "The occurrence of basophil granules in lymphocytes, plasma cells and fibroblasts signifies a close relationship between the three cell forms which apparently represent only different stages in the development of the same fundamental cell type."

Larsen D33,726/61: In rabbits in which uveitis was produced by intraocular injection of horse serum, MC degranulation is accompanied by the appearance of metachromatic granules in "lymphocytoid" cells but the latter are not considered to be true MCs.

RUSSELL-BODY MASTCELLS

Prus D31,542/1895: In the intestinal wall of horses affected by "petechial fever" or "horse typhoid," MCs with fuchsinophilic bodies are found. These are considered to be transitional types between the Russell-body cells and MCs. The cell inclusions are designated as "secretory fuchsinophilic degeneration."

Michels C72,066/38, *p. 306*: General description of Russell-body mastcells.

Pearse D30,087/49: The relationship between Russell bodies, the Kurloff bodies of the guinea-pig, and the Auer bodies of human myeloblasts is still debated and some investigators consider them as possible homologues. Since the granules stain metachromatically with thionine, possible relationships between these elements and MCs must also be kept in mind.

Brinkmann D33,665/59: In a case of mastocytosis, many of the MCs were found to phagocytose erythrocytes. [This phenomenon might lead to the formation of the so-called "Russell-body mastocytes" (*H.S.*).]

PIGMENT-MASTCELLS

Rheindorf D33,731/05: Certain cells found in nevi, freckles, and melanosarcomas, contain both metachromatic and pigment granules. They are designated as "pigment mastcells" and are considered to be precursors of chromatophores.

Coupland & Heath D2,439/61: Para-aminosalicylic acid stains some but not all MCs and melanophores in human skin.

CELLULE MASTLIPOIDI

Brugnatelli 46,135/14: Lipid-containing MCs are distinguished as a special cell form.

CHROMAFFIN MASTCELLS

Rhodin et al. D39,527/59: Electron-microscopic observations on the so-called chromaffin cells of human skin, suggest that they contain granules "that chemically and structurally are closer related to the chromaffin granules of the adrenal medullary head cells than to the granules of the mast cells." The close relationship of these cells to unmyelinated nerve fibers and smooth muscle cells, suggests that they may "release some substance into the smooth muscle cell by impulses through the nerve fiber."

Phillips et al. C91,246/60; D26,570/60: Electron-microscopic studies suggest that there are at least two types of MCs in the human skin and gastric mucosa: one shows "peculiar rolled, laminated scroll forms," while the other is an elongated cell with granules showing an amorphous architecture. The latter cells appear to be identical with the chromaffin cells as seen on light microscopy and are thought to contain adrenaline or noradrenaline.

Hibbs et al. D26,446/60; D26,893/60: "Light and electron-microscopic observations show that mast cells differ in morphology from one area to another in the same person." One type is more elongated and possesses comparatively small granules, which also give the chromaffin reaction, while the other is larger and round or oval with somewhat more voluminous granules. However, transitional types between these two do occur.

Matz & Skinner D33,711/62: The so-called "chromaffin cells" previously described in human digital skin, differ from ordinary MCs in their shape but have the same tinctorial characteristics. Their granules do not produce the true chromaffin reaction of catecholamines, they are unaffected by intra-arterial reserpine injections and remain normal in patients with chronic degeneration of the sympathetic nerves. "It is suggested that the 'chromaffin cells' are mast cell variants and are not involved in the autonomic effector mechanism."

STELLATE MASTCELLS

Stassano & Haas D33,741/00: Star-shaped clasmatocytes (possibly identical with MCs) with numerous metachromatic granules are demonstrable in the omentum of the guinea-pig.

McKibben D27,954/14: In the meninges of the amphibian, *Necturus maculosus*, spider-shaped MCs with long filamentous pseudopodia are found. These are indistinguishable from clasmatocytes and can easily be confused with nerve cells (*Fig. 2*).

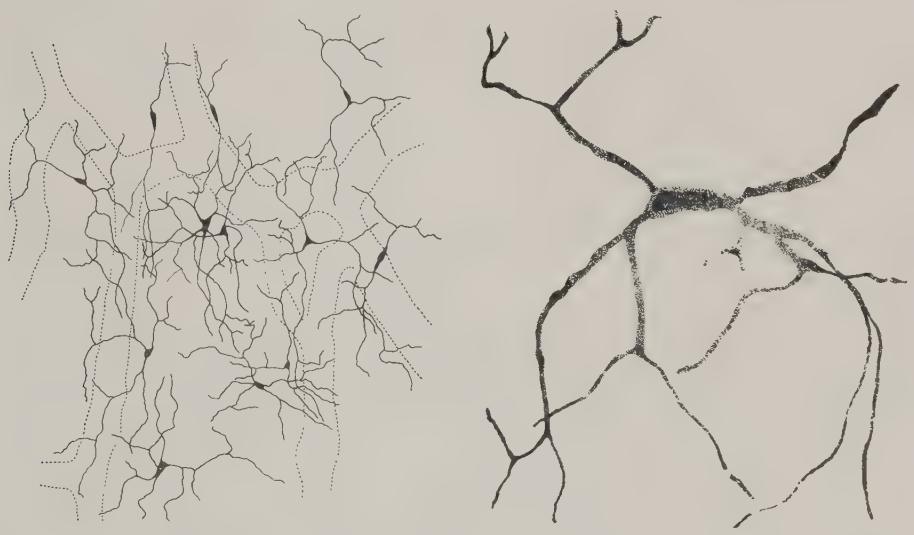

Figure 2. McKibben's spider-shaped mast cells. Left: Whole mount of the dura mater from the roof of the cranial cavity of *Necturus*. Capillaries are indicated by the dotted lines. (X 50.) *Right:* Single MC in the same dura mater. (X 315.) [After *McKibben* D27,954/14.]

Nepriakhin D26,879/56: The tissue MCs, the blood basophils, and the glia astrocytes are considered to be three related groups of MCs, although the two former are mesenchymal, the latter ectodermal in origin.

Zwillenberg D42,931/58: The "high-level dendritic cells" with long, slender processes that are demonstrable in various non-epidermal stratified squamous epithelia (esophagus, vagina, portio vaginalis uteri) and their basal counterparts, generally contain granules which stain metachromatically with toluidine blue, in vivo. The granules are unevenly distributed but often lie in pairs. They frequently occur together with typical intra-epithelial MCs which here, likewise, tend to assume a dendritic shape in that they form processes which protrude between the Malpighian cells. Such intra-epithelial MCs are common in the esophagus of the cat and macaque but rare or absent in the esophagus of the pig and cow. In the vaginal epithelium of women and macaques, the occurrence of intra-epithelial MCs is variable.

HISTIOCYTOID MASTCELLS

Asplund et al. D15,852/40: Metachromatically-granulated cells of the "metrial gland" at the placental insertion site can be demonstrated in the rat, mouse, guinea-pig and, less clearly, in the rabbit uterus; they are absent in cattle, pig, horse, and sheep uteri. Such cells can also be produced in nonpregnant animals by the induction of deciduomas. They do not disappear upon extirpation of the embryos but vanish if both embryo and placenta are removed. Injected trypan blue is phagocytosed by these granulated cells. It is assumed that the latter, like MCs, contain heparin and thereby can prevent clotting, yet, there are definite morphologic differences between the metrial-gland cells and true MCs.

Larsen D33,726/61: In rabbits in which uveitis is produced by intraocular injection of horse serum, histiocytoid cells with metachromatic granules appear simultaneously with a discharge of MCs but these are not true MCs.

SPECIFIC CELLS OF UTERUS

Asplund & Holmgren B17,599/47: "In the normal and pregnant uterine mucous membrane cells with occasional metachromatic granulations [called by the authors 'specific cells'] are found. These cells are neither mast cells nor apparently plasmamastcells. The 'specific' cells are met more frequently during the secretion phase. After the cessation of menstruation, they seem to disappear from the mucous membrane. As the cells are only met during the fertile age, it is assumed that they have a function associated with the functioning uterine mucous membrane. . . . In view of its tinctorial properties, the substance in question will probably consist of high molecular ester sulphuric acids."

QUASIMASTCELLS

Walton G21,527/54: Parenteral administration of large molecular dextran sulfates results in the deposition of metachromatic granules in large mononuclear cells in the blood as well as in the Kuppfer cells and other members of the RES. They are often difficult to distinguish from true MCs.

Higginbotham & Dougherty C21,716/56: Heparin i.v. and compound 48/80 s.c. elicit a local accumulation of numerous cells with metachromatic granules. When heparin and 48/80 are mixed, a complex is formed which, when injected subcutaneously, produces quasimastcells owing to the phagocytosis of the heparin–48/80 complex by fibroblasts. "The binding of the toxic phenyl alkylamine, 48/80, by heparin and its sequestration in granular form by fibroblasts of the tissue has been presented as a model of this local detoxifying response of the loose connective tissue."

Padawer D30,194/57: The "quasimastcells" that result from the phagocytosis of various polysaccharides and particularly heparin, as well as fibroblasts or histiocytes ingesting MC debris, should not be considered as MCs. The author insists that "all is not mast cell that stains metachromatically."

Higginbotham (Padawer et al.) D58,297/63: "Quasimastcells" are produced by the addition of heparin to fibroblasts in tissue culture, the virus-induced myxoma of the rabbit, and i.v. injection of chondroitin sulfate-B in the mouse.

"KUGELHAUFEN"

Lauda & Flaum D26,828/29: The so-called basophil "Kugelhaufen", which are commonly present in the bone marrow of the mouse and rat, differ in their staining and solubility characteristics from true MCs and are probably RES cells which have phagocytosed some basophilic material.

BLOOD BASOPHILS

Cf. Section on Basophils (*p.* 331).

FIXATION

The most important fact concerning the fixation of MCs is that artificial degranulation must be avoided. Hence, specimens should be removed from the body with a minimum of mechanical trauma and aqueous fixatives must not be used, particularly in studies on species (e.g., fish, birds, rabbits, and man) whose MCs possess especially water-soluble granules. This latter precaution is less necessary in the case of other animals (e.g., rat, hamster, mouse, dog) whose MC granules are comparatively water-insoluble.

Following 24 hours of fixation in 4 per cent basic lead acetate, even the normally water-soluble MC granules become resistant to aqueous extraction and, hence, this fixation is widely used.

In our studies on the histology and histopathology of rat MCs, we employ alcohol-formol (4 parts of absolute alcohol and 1 part of neutral 10 per cent formalin) because it proved highly satisfactory in preserving not only the metachromatic granules, but also trace amounts of various metals (calcium, iron, lead) which may be absorbed to these granules (e.g., in mastocalciphylaxis and mastocalcergy).

After using any of the appropriate fixatives, the MC granules are no longer susceptible to discharge or dissolution under the influence of mechanical trauma or contact with water.

Reviews: *Schwenter-Trachsler* D27,426/06; *Nepriakhin* D26,879/56; *Takeda* C60,733/58; *Kelsall & Crabb* D26,076/59, *p.* 68; *Smith* D63,031/63

Michaelis D27,717/02; *Maximow* B79,778/06: Aqueous fixatives should be avoided in the study of MCs because of the fact that their granules are always more or less soluble in water.

Szécsi D27,988/13: Lucidol, $(C_6H_5CO)_2O_2$, is recommended as a histologic fixative. It is particularly useful in preserving the metachromasia of MCs.

Regaud & Lacassagne D26,872/22: The MCs of the rat omentum and of human carcinomas show eosinophilia of their granules following fixation in bichromate-formalin mixtures (Helly, Zenker-Helly, Tellyesniczky-formol, bichromate formol, etc.) while they are distinctly basophilic and metachromatic to toluidine blue after their fixation in formol alone or in osmic acid.

Holmgren D29,498/38: Following 24 hours of fixation in 4 per cent basic lead acetate, even the otherwise water-soluble MC granules of such species as the rabbit become resistant to aqueous extraction. The method has been found useful in the demonstration of MCs in adult man, human embryos, cattle, pig, dog, guinea-pig, rabbit, salamander, and alligator.

Campani D39,607/49: Following fixation in 80 per cent alcohol, the MCs of the rat, guinea-pig, and man are well preserved while those of the rabbit lose their metachromatic stainability.

Montagna et al. D27,628/54: After fixation in Helly's fluid, cutaneous MCs from patients with urticaria pigmentosa can be washed in running water overnight without dissolution of the mast granules or diminution in their metachromatic staining.

Paff & Mergenthaler D27,516/55: Contrary to common belief, it is stated that "mast cell granules can be demonstrated in unfixed rat mesentery immersed in water for days. Fresh undried connective tissue spreads placed in water show mast cell granules at the end of a month. Mast cell granules of the rat are not soluble in water." Of course, these statements do not apply to living MCs which the authors admit "literally explode when in contact with water.

Nepriakhin D26,879/56: In opposition to most contemporary investigators, it is stated that aqueous fixation is quite adequate for the histologic study of human MCs.

Padawer D30,194/57: The MC granules are extremely water-soluble in various species of fishes and birds but not in the rat, mouse, hamster, and dog. Basic lead-acetate, though useful in making MC granules water-insoluble, is a very poor fixative.

Saal & Riek D31,598/58: Formalin is an acceptable, though not an ideal fixative for bovine-skin MCs. The optimum time for formalin fixation is 24–36 hours. Exposure to water after fixation does not produce artifacts.

Shelley & Florence D33,736/61; E91,256/61: Numerous well-preserved MCs can regularly be demonstrated in the mesentery of the guinea-pig by the use of a special technique for the preparation of whole mounts in glass capsules which "form a conveniently-sized unit in which to trap and remove the mesentery in a safe, uniform fashion. Ethylene glycol monoethyl ether (Cellosole Solvent®) is recommended as a special fixative for mast cells."

Adams & Paff D33,746/62: Although the MCs of the rat are insoluble in water, prolonged washing of unfixed preparations in water removes the metachromatic reaction and causes considerable swelling of these specific granules. Furthermore, the surrounding lymphocytes degenerate and liberate a metachromatically staining detritus which interferes with histologic observation.

Parish E4,391/64: 10 per cent formalin saline solution is an adequate fixative for MCs in human tissues, but Bouin's solution and lead subacetate-formalin solution give better fixation of the granules. Still, Bouin's solution is less reliable and Susa, though preserving the cells, causes much shrinkage. The MCs of mice, rats and hamsters are not soluble in aqueous fixatives but for guinea-pig MCs, 4 per cent basic lead subacetate is recommended.

SPREAD

Spreads of thin connective-tissue lamellae lend themselves particularly well to the study of MCs. Such preparations show these cells in their natural habitat along the course of uninterrupted long sections of a vascular network. Spreads of this kind can be prepared by the fixation of mesentery on a cover glass or between two interlocking rings ("embroidery-hoop technique"). Even the thin skin of small rodents can be used as a spread when stretched over a stopper and fixed in this position by pressing it through a perforated plastic plate.

We have obtained the best results by using the MC-rich periosteum of the calvarium of rodents. This membrane need not be stretched because it is held in a flattened position by its attachment to the underlying bone plate from which it can be peeled off after fixation for subsequent staining.

Zahl & Nowak D72,190/49: The cutaneous MCs of the mouse can be easily visualized if the skin is stretched and pinned to a cardboard frame prior to fixation in absolute ethanol and staining with methylene blue. After dehydration and clearing in xylene, these specimens are ready for histologic examination.

Paff & Mergenthaler D27,516/55: The following "embroidery-hoop technique" is recommended for the study of MCs in the rat mesentery: "A rat was etherized and a loop of gut with its mesentery was rapidly removed by placing two hemostats close together at the

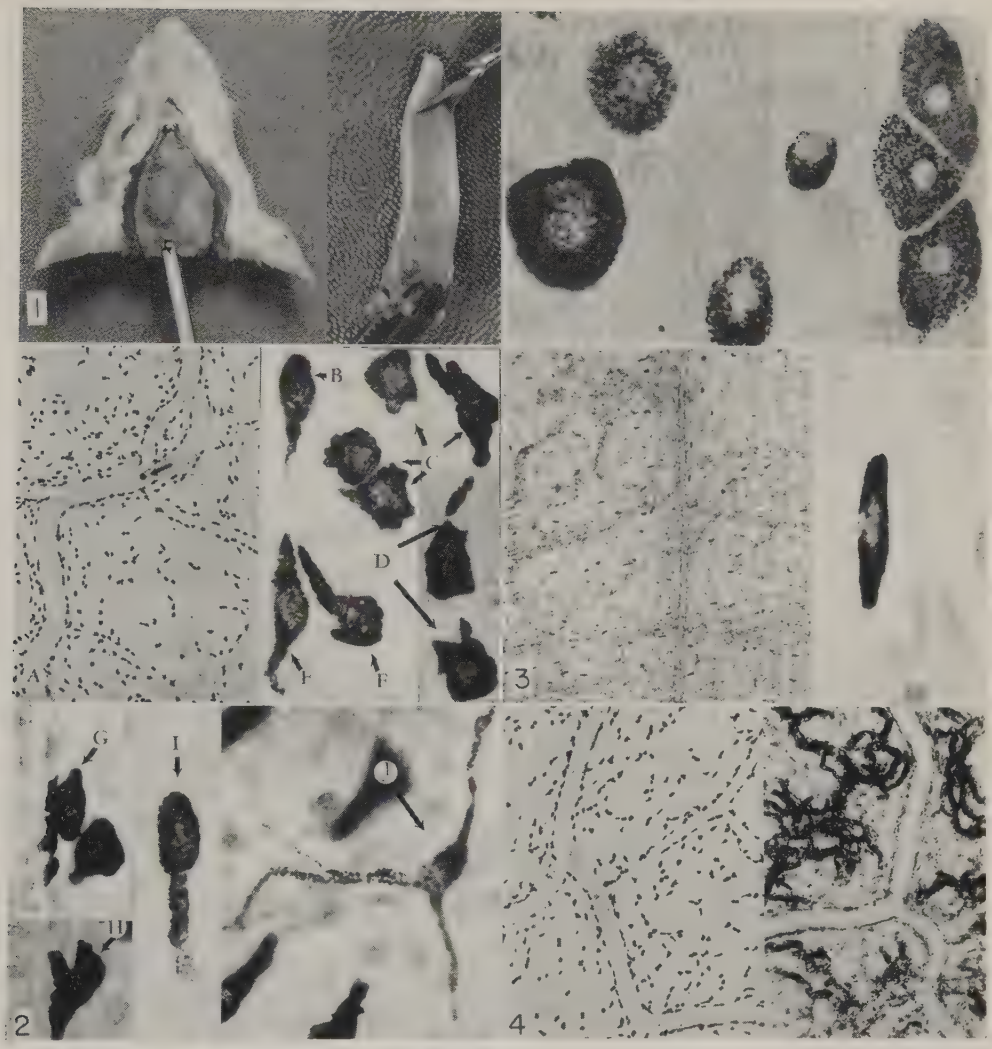

Figure 3.—(1) *Preparation of "periosteal spread." Left:* After decapitation and careful removal of the skin, the skull cap is freed by a circular incision and lifted up with forceps applied to occiput. *Right:* After fixation, top of frontal bone is broken off by dorsad reflection with forceps and external periosteum peeled off.

(2) *Typical mast-cell forms found within external periosteum.* (*A*) General view showing preferential arrangement of mostly fusiform MCs in two rows along sides of blood vessels, and more polymorph cells at distance from vessels. Most of the large ovoid cells on surface of periosteum are not visible (since, being in another layer, they are out of focus) but a few of them are seen near left upper corner and one (*arrow*) just behind the largest vessel is visible though slightly out of focus. (X 27.) (*B*) Pear-shaped MC with beginning degranulation around pointed pole. (*C*) Various bizarre-shaped cells with pseudopodia. (*D*) Two cells in the process of shedding part of their granule-laden cytoplasm (clasmatocytosis?). (*E*) Fusiform. (*F*) Hook-shaped MCs. (*G* and *H*) Two MCs with plate-like portions extended towards the faintly visible wall of adjacent vessel. (*I*) Comet-shaped MC with degranulation in tail region, possibly representing wake in the course of

ameboid motion. (J) Spider-shaped MC with metachromatic granules in its four elongated processes. (*A* X 27; *B–J* X 225 under oil immersion; all sections azure A.)

(3) *Mast cells on surface of external periosteum and in dura. Top:* On periosteal surface all MCs are more or less ovoid and flat, with little or no metachromatic granules in nuclear region. Note great difference in sizes of both cells and granules themselves. At right, three large MCs form chain with contiguous surfaces flattened. (Azure A, X 225.) *Bottom left:* General view of dura showing predominantly rod-shaped MCs without obvious relationship to blood vessels. (Azure A, X 27.) *Bottom right:* Typical appearance of rod-shaped dural MC. (Azure A, X 225.)

(4) *Ink fixation in vessels after topical treatment with compound 48/80.* External periosteum of two rats which received 1 ml. of 30 per cent Higgins' American India ink i.v. Just before this, one animal (*right*) received 50 μg of compound 48/80 in 0.2 ml. of water s.c., above the calvarium. The specimens were fixed 24 hours after these injections. *Left:* Mast cells are normal; no ink fixation. *Right:* All MCs are disrupted but their granules are still distinguishable around the vessels (here black, on slide purple), while adjacent vessels have fixed black ink particles. (Azure A, X 27.) [After *Selye et al.* D36,698/63. Courtesy *Proceedings of the Society for Experimental Biology and Medicine.*]

---

base of the loop and cutting gut and mesentery between the hemostats. The mesentery was then laid over the smaller hoop and the larger hoop was discarded and a trace of Tyrode solution was dropped on the mesentery, held by the hoops. The preparation was then laid on a coverslip and scaled in a hollow ground slide. Critical examination under oil immersion is possible if fat-free areas of mesentery are chosen for study."

Pettersson D7,232/56: Technique for the preparation of rat mesenteric spreads between two interlocking plastic rings.

Villavicencio & de Takats C56,397/58: The mesenteric MCs of the rat can be conveniently fixed by the following method: "After a laparotomy, a glass slide was slipped into the abdominal cavity, then a freely movable intestinal loop was gently picked up, and the mesentery was spread on the slide with a minimum of trauma. With a clean, quick cut of sharp scissors, this segment was freed of its mesenteric attachment, fixed in absolute alcohol for 8 hours and stained by immersing the slides for 15 seconds in 0.5 per cent solution of toluidine blue. The slides were then gently rinsed for 1 to 2 seconds with 95 per cent alcohol, cleared through xylene for 12 hours, and mounted with Clarite under a glass coverslip."

Antweiler D39,651/61: Description of a simple plastic instrument consisting of two rings between which spreads of omentum, mesentery, or subcutaneous connective tissue can be prepared for the study of MCs.

Stach D39,563/61: Spreads of the musculo-cutaneous tissue of rats can be vitally stained with methylene blue to demonstrate simultaneously the terminal reticulum of vegetative nerves and the MCs. A definite topographic relationship between these structures suggests a functional participation of MCs in nervous activity.

Shelley & Florence D33,736/61: Well-preserved MCs can regularly be demonstrated in the mesentery of the guinea-pig by the use of a special technique for the preparation of whole mounts in glass capsules.

Kátó & Gözsy D30,021/62: After shaving the abdominal skin of the rat, it is stretched inside-out over a stopper and fixed in this position by pressing it through a perforated plastic plate in a manner reminiscent of the "embroidery-hoop technique" of Paff and Mergenthaler (D27,516/55) recommended for the preparation of mesenteric spreads. Without fixing or washing, appropriate stains are poured over the exposed subcutaneous connective tissue (e.g.,

MCs can be stained by treating them for two minutes with a 0.1 per cent aqueous solution of toluidine blue and 4 per cent formaldehyde). The capillary network can be visualized by injecting the rat intravenously with India ink in vivo. The whole preparation is then washed with tap water and submerged in toluol for three hours. Excess toluol is removed and the skin left on the gadget overnight, to dry. After disassembling stopper and perforated plate, a square piece of the skin is cut out and dried with filter paper. The resulting transparent parchment-like skin lamella is then mounted on a glass slide with Scotch tape on two sides and examined without coverglass in transparent light or the phase-contrast microscope.

Selye et al. D36,698/63: Excellent spreads of connective tissue can be obtained with a minimum of injury by using the MC-rich periosteum of the calvarium which is held in position by its natural attachment to the underlying bone plate. After killing the animal (e.g., a rat), the skin over the calvarium is gently pulled off and the entire skull-cap with the attached periosteum, cut off with a pair of scissors. The skull-cap is then fixed (e.g., in alcohol-formol for 48 hours), whereupon the periosteum can be pulled off as a thin, natural spread of connective tissue which no longer has any tendency to shrink. A square piece of the periosteum is cut out, stained (e.g., with methylene blue or cresyl violet), and then mounted between glass slide and cover slip, as if it were a frozen section (*Fig. 3*).

Csaba & Kulmann G2,694/63: The granuloma pouch technique (without the injection of an irritant into the air sac) is employed to prepare connective-tissue spreads for the study of MCs in the rat.

COUNTING

The counting of normal and degranulated MCs within a well-delimited area of tissue is indispensable to obtain quantitative data on the comparative MC density and granule discharge in different regions. For this purpose, various techniques have been recommended which are based on: (1) selective staining that makes MCs particularly prominent, and (2) ways of singling out similar microscopic fields for comparative study. Still, it must be admitted that the obtention of such strictly quantitative measurements encounters great difficulties because of the highly irregular distribution of MCs throughout the tissues. However, semi-quantitative data can be procured if some stable landmarks (e.g., the triangle formed by a vascular bifurcation or the limits of a microscopic field) are used for the delimitation of areas to be examined. In the case of peritoneal fluid or bone marrow, suspensions can be made for counting with a red-cell pipet.

Larsson & Sylvén D26,790/47: Technique for the counting of MCs in the skin and subcutaneous tissue of the mouse.

Frick B62,124/50: Quantitative determinations of the mesenteric MCs in the mouse may readily be achieved on toluidine-blue-stained mounts of the mesentery within the triangle formed by a vascular bifurcation, just above the cecum.

Mota D26,756/51: In the bone marrow of the rat, MCs can be quantitatively estimated by dilution of bone-marrow tissue in a red-cell pipet with a 1:50,000 solution of toluidine blue in 3 per cent acetic acid.

Norton D26,564/54: A method for the counting of rat mesentery MCs with which degranulation by compound 48/80 can be calculated by probit analysis.

Benditt et al. C13,402/55: Method for the counting of MCs in the skin of the rat.

Smith & Atkinson D26,639/56: A technique is described in which the MCs are stained very selectively with toluidine blue, the background being understained, thereby increasing the prominence of the MCs which facilitates their counting under low power.

Padawer D58,275/63: Detailed description of improved techniques for the enumeration of MCs in solid tissues and serous fluids.

ISOLATION

The isolation of entire MCs or of discharged MC granules is of special importance for studies concerning the chemical constituents of these particles. For this purpose, a variety of techniques have been described which are mainly based on the differential centrifugation of MC or MC granule suspensions in special fluid media of appropriate specific densities to permit the separation of the desired elements.

Reviews: *Baglioni* C16,539/54, *p. 154*
Benditt et al. C9,838/55
MacIntosh D30 560/56

Köksal B93,664/53: Mouse skin is pinned out and the exposed subcutaneous fascia dissected away. The fascial tissue from fifty mice is placed in 50 ml. of sterile, distilled water in a sterile, stoppered bottle and shaken 1–2 hours, at a maximal speed with a "Towers" shaker. The fluid is removed with a sterile pipet and centrifuged at about 1,000 rev./min. for 10 minutes. The precipitate consists predominantly of granules which stain metachromatically with toluidine blue.

Hedbom & Snellman D27,627/55: The large cytoplasmic granules of bovine connective-tissue MCs have been isolated by differential centrifugation. They contain no anticoagulant property but histamine was found to be connected with the granular fraction.

Padawer & Gordon D27,619/55: Isolation of rat peritoneal MCs by differential centrifugation in a special medium which takes advantage of the greater density of the MCs.

Mongar & Schild D27,601/56: Isolation of MC granules from the lung of guinea-pigs by differential centrifugation.

Higginbotham et al. D15,838/56: Sheets of loose subcutaneous connective tissue were stripped from the skins of freshly-killed mice by applying the connective-tissue surface of the skin to a freezing surface. This tissue was then scraped into an isotonic sucrose solution and the MC granules isolated by differential centrifugation. When, prior to this procedure, $Na_2S^{35}O_4$ is injected i.p., radioactive MC granules can be obtained from the subcutaneous tissue.

Glick et al. D26,300/56: Technical improvements in the procedure for the isolation of peritoneal MCs of the rat permitted the obtention of preparations 100 per cent pure with respect to cell type, in yields of up to 87 per cent with respect to the original washings.

Padawer D30,194/57, *p. 698*: The following technique for the isolation of peritoneal MCs is particularly recommended: adult rats (180–300 g.) are injected i.p. under light ether anesthesia with from 20 to 25 ml. of "solution A" composed of: EDTA 0.00001 g., NaCl, 0.85 g., gelatin 0.01 g., distilled water 100 ml. "This solution is brought to room temperature before injection. The animal is allowed to regain consciousness and to move about for 5 min. and is then decapitated. The peritoneal cavity is then exposed by laparotomy along the mid-ventral line, and as much fluid as possible is collected with a medicine dropper and transferred to a tube kept at ice-bath temperature. Following 8 min. of centrifugation at approximately 1000 RPM (International centrifuge, size 2, Model V, with head No. 250) the supernate is decanted, the cells resuspended and washed twice with ice-cold solution A, and finally resuspended in approximately 3 ml. of this same medium. One half the cell suspension is now drawn up into a Van Allen tube. High density sucrose solution [described by *Padawer & Gordon* D27,619/55] diluted just before use with 0.00001 per cent Na_4EDTA is then drawn slowly up into the Van Allen tube until the interface reaches the belly of the bulb and thus its maximal area. The clip is then fastened, taking care to avoid mixing the two layers. Proceed similarly with the remainder of the cell suspension. These two tubes are balanced in 50 cc. centrifuge cups and spun for 6 min. at 100 g. (700 RPM). Allow the centrifuge to come to rest without braking, but with the cover opened. The clips are removed and the lower layer allowed to drain by gravity into a tube, taking care to stop before contaminating the yield with interface cells. Under proper side lighting conditions, the process can be carefully controlled with the naked eye. The mast cells, now in sucrose solution, are diluted with an equal volume of ice-cold solution A and centrifuged for 16 min. at 700 RPM. After decantation, the cells are washed twice with saline and are now ready for chemical analysis or

biochemical characterization. It should be noted that no exogenous heparin is involved in this procedure."

Uvnäs & Thon D26,067/59: When the peritoneal MCs of the rat are isolated by differential centrifugation in Ficoll (a polysaccharide of high molecular weight) dissolved in isotonic saline solution, the cells retain their histamine even when repeatedly washed. If subsequently exposed to MC-depletors (e.g., 48/80, antigen) they release their granules with particular ease unless serum is added to the suspension.

Archer C78,034/59; D26,626/59: "The mast-cell suspensions were prepared by injecting 40 ml. of physiological saline solution into the peritoneal cavity of the rat and aspirating the fluid after approximately 30 sec. Cellular elements were concentrated by centrifuging the aspirate. The mast cells were separated by layering the cellular concentrate on top of a 4-cm. column of 50 per cent albumin solution in a Wintrobe hematocrit tube and centrifuging the tube at 250 g for 5 min. The mast cells were recovered from the bottom of the tube and were found to be almost free of other types of cells which remained above the albumin layer."

Lagunoff & Benditt C68,450/59: "A new method of separating mast cells was developed employing concentrated bovine albumin solution. The mast cells could be centrifuged through this solution; most other cells remained at the interface."

Lagunoff & Benditt D7,116/59; D26,708/60: A technique by which MCs of the rat peritoneum can be deposited on the surface of a Millipore filter without gross injury, permitting observation of morphologic and chemical changes induced by various agents. The MCs are collected from the rat peritoneum in the customary manner and then filtered through Millipore. The MC-laden Millipore filters can then be treated chemically or stained (together with the MCs) for microscopic study.

Mota & da Silva D26,065/60: A technique which permits the isolation of the peritoneal MCs of the rat with a minimum of damage, so that they do not discharge their granules.

Uvnäs & Thon D26,478/61: Rat peritoneal MCs can be isolated by differential centrifugation in a polysaccharide (Ficoll) for histologic or chemical study.

Bloom & Valmet D67,421/61: Modified centrifugation technique for large scale separation of rat peritoneal MCs. "The method is based on density gradient centrifugation with sucrose as a medium and the use of a special centrifuge constructed to permit a long continuous gradient, and which makes it possible to centrifuge pooled peritoneal washings from a large number of rats simultaneously. The technique regularly provides peritoneal mast cells 95–100 per cent pure with respect to cell type and in total numbers, from 40 rats, of about 18 x 10^6 mast cells."

Keller & Oppliger D27,077/61: MCs can be isolated by differential centrifugation from specimens of human bronchial mucus removed in vivo with the aid of the bronchoscope.

Parekh & Glick D27,898/62: Isolation of rat peritoneal MCs by the Ficoll density gradient procedure.

METACHROMASIA

It is beyond the scope of this monograph to discuss the complex physicochemistry of metachromatic staining in detail. We must keep in mind, however, that metachromasia is readily influenced by many factors. It can be blocked, for example, by streptomycin and various basic colloids such as protamine, lysozyme, thymus histone, and hemoglobin. Mast cells treated with these materials lose their ability to stain metachromatically with toluidine blue. This inhibition can be reversed by subsequent treatment with acid colloids (e.g., dextran, chondroitin sulfuric acid, ovalbumen, gelatin). The possibility has been considered that even in vivo the stainability of MCs and, hence, their apparent number, may depend upon the balance between acid and basic colloids in the surrounding fluids. Metachromasia is also dependent upon the *p*H at which staining is performed and upon many other factors.

At one time it was thought that all metachromatically-stained compounds are high-molecular sulfuric acid esters, because if the sulfuric radical is removed, the metachromasia disappears while certain normally non-metachromatic compounds become metachromatic when sulfated. However, subsequent work revealed that the metachromasia of mucopolysaccharides is not necessarily dependent upon the presence of sulfate linkages. For example, the hyaluronic acid present in the vitreous body and synovial fluids contains no sulfate and yet stains metachromatically. Furthermore, in ordinary cell nuclei and in myelin sheaths, phosphate groups are probably responsible for the linkage of toluidine blue to the substrate, and treatment with uranyl acetate can induce metachromasia in tissues. According to current opinion, the mechanism of tissue metachromasia depends upon the fact that macromolecules, which contain electronegative radicals and exhibit a periodic negative surface charge, bind dye molecules so that an interaction between them can occur. This interaction is thought to depend upon van der Waal forces or H-bridges. After this polymerization, the dye molecules acquire a new metachromatic absorption maximum, similar to that obtained in concentrated dye solutions. Water molecules appear to play some role in this dye polymerization, although the nature of their effect is not yet understood.

A faint, diffuse cytoplasmic metachromasia is observable under various conditions in glia cells, epithelium of the choroid plexuses, megakaryocytes, cells of the epidermis, placental syncytium, rapidly growing granuloma, or neoplastic cells. The stromal papillae and the proliferating epithelia of rat-hair roots as well as ovarian follicular fluid also tend to stain metachromatically.

We speak of true metachromasia only when a new gamma absorption band appears at a shorter wave length of the spectrum than the normal alpha and/or beta bands. The gamma metachromasia, characteristic of aggregate formation with the material of MC granules, is stable, while false metachromasia, owing to absorption of dye molecules, is usually unstable.

Synonyms

Metachromatism *(Clowes & Owen* D28,257/04). Metachromasy *(Halmi & Davies* B87,805/53).

Reviews:

Lehner D27,094/24
Michels C72,066/38
Bank & de Jong D67,712/39
Sylvén D26,048/41
Landsmeer D26,778/51
Dalcq & Massart D30,530/52
Schubert & Hamerman D28,653/56
Diezel & Neimanis D27,958/59
Ghiara D27,960/59
Kelsall & Crabb D26,076/59
Rosenbaum & Deane D27,959/59
Schöll et al. D27,961/59
Lindner D48,381/60
Jaques D26,299/61
Romhányi E25,972/63
Barka & Anderson E4,491/63

Ehrlich D31,521/1891: Five classes of granules should be distinguished in the "wandering cells" of connective tissue: The α or eosinophilic granulation stains only with acid dyes; β granulation stains both with acid and with basic dyes (amphophile); γ granulation stains only with basic dyes and the individual granules are large and often metachromatic; δ granulation stains only with basic dyes but the individual granules are small; and ε granulation which stains only with neutral dyes.

Clowes & Owen D28,257/04: "The metachromatism exhibited by the granules of mast cells on staining with ten per cent polychrome methylene blue may be considered as a simple, acid-alkali reaction, the compound formed between the methylenazure of the stain and the

granules being sufficiently sensitive to acids and alkalis to function as an indicator, in the strict chemical sense of the word. The granules exhibit a blue coloration with acids and a red with alkalis."

Neumann D27,640/07: Certain cell constituents which do not stain either with eosin alone or with azure alone take on a bright red color if first stained with azure and then lightly with eosin. This phenomenon is referred to as "relative metachromasia."

Bensley D28,924/34: "By treating sections with dilute acids or alkalis, the physical state of the structures in the sections may be modified so that everything stains metachromatically with toluidine blue. Moreover, if the dye is used in too concentrated a solution or for too long a period, the differential staining of the connective tissue is lost and all the elements save the nuclei may be stained metachromatically."

Lison D26,856/35; D26,967/35; D26,729/36: All metachromatic compounds are high-molecular sulfuric acid esters. If the sulfuric radical is removed, the metachromasia disappears and, conversely, certain otherwise non-metachromatic compounds assume metachromatic properties when sulfated. Metachromatic staining with cresyl violet and toluidine blue is considered to be a highly specific reaction to sulfated, high-molecular polysaccharides. Confusion can arise only as a result of the "ionic" metachromasia obtained by staining in highly alkaline solutions, but this source of error is easily avoided.

Sylvén D26,877/38: Study on a variety of rapidly-growing granuloma and neoplastic tissues led to the conclusion that metachromasia is characteristic of active growth. The highest degree of diffuse metachromasia was observed in a synovial tumor.

Holmgren D28,926/40: All substances which stain metachromatically under the conditions specified by Lison are considered to be high-molecular sulfuric acid esters.

Ferràta D39,598/42: The metachromasia of rat connective-tissue MCs is demonstrable even at *p*H 4 with highly dilute solutions of toluidine blue (1:5,000,000) acidified with HCl.

Wislocki et al. D26,750/47: "The metachromatic substances present in synovial fluid, vitreous body, Wharton's jelly, ovarian follicular fluid, nucleus pulposus matrix, papillary layer of the skin, perilobular stroma of the breast, and in the stroma of the mucous membranes of the nasal cavity and trachea, are variably soluble in hyaluronidase. The degree of their solubilities depends, it would seem, upon the relative amount of hyaluronic acid contained in each. Contrary to the concepts of Lison and of Holmgren, metachromasia in the case of mucopolysaccharides is not necessarily dependent upon the presence of sulphate-linkage; so, for example, the mucous substance (hyaluronic acid) present in the vitreous body and synovial fluids is metachromatic without containing any sulphate. . . . Faint cytoplasmic metachromasia is observable under various conditions in many cells of the body, including nerve cells, glial cells, epithelium of the chorioidal plexuses, megakaryocytes, cells of the epidermis, placental syncytium, and various other elements. The metachromasia of certain of these cells, for example, nerve cells, chorioidal epithelium, hepatic cells and placental syncytium, is abolished by ribonuclease; that of megakaryocytes, however, is not so destroyed." Wislocki & Dempsey (D27,437/46) observed, nevertheless, a faint, saliva-resistant Bauer reaction in the MC granules of the rat and thought that it might be due to an affinity of the granules for basophilic dyes, in this case an attraction for the slight amount of recolored basic fuchsin produced in the reagent. Subsequent checks using samples of fresh as well as recolored reagents, have not substantiated this surmise. Consequently, we now regard this as well as the similar staining of other metachromatic substances as being related more probably to reducing substances either derived from the partial hydrolysis of the carbohydrate moiety of the mucopolysaccharides in question or adventitiously present in the granules of the rat's MCs.

Mutsaars & Lison D26,715/50: Streptomycin possesses an antimetachromatic effect in that it blocks the metachromatic staining of sulfated starch with toluidine blue. No explanation of this phenomenon can be given.

Sylvén D29,140/50: With the freeze-vacuum dehydration technique, considerable amounts of metachromatic material can be demonstrated in the stromal papilli and in the rapidly growing epithelia of rat hair roots. "This material is associated with periods of intense proliferation of hair epithelia, and is most likely supplied via the stromal matrix. The pronounced alcohol stability of the staining reaction is regarded as indicative of polysaccharide ester sulfate, but analytical evidence is still lacking." Mast cells have not been observed in the rat hair papilli but occur occasionally in human ones.

Lansing & Opdyke B60,712/50: Keratohyaline granules in the nipple of the guinea-pig stain metachromatically with toluidine blue. Their number increases under the influence of

estrogen treatment and they are associated with calcium and/or magnesium deposits as demonstrated by micro-incineration.

Follis D25,569/51: "When unfixed [human] skin collagen, which ordinarily is only lightly orthochromatic, is treated with pepsin, it becomes metachromatic. Trypsin does not have this effect. Collagen denatured by alcohol or formalin fixation is rendered metachromatic by both pepsin and trypsin. . . . It would seem highly suggestive then, that pepsin may attack the protein component so as to free groups of the mucopolysaccharide which might then combine with the dye. On the other hand, since trypsin is not able to split the protein, no groups would be available to bind the dye."

Landsmeer D26,778/51: "To make an attempt to determine the ionogenic groups in the tissue elements stained with toluidine blue, whether metachromatically or not, we measured the influence of various cations on the staining of mast cells, nuclei of the mesentery and myelin sheaths, and cells of brain tissue. A comparison of our salt-spectra with those already laid down in literature revealed that in the mast cells, sulphate groups, and in ordinary cell-nuclei and in myelin sheaths, phosphate groups are responsible for the linkage of toluidine blue to its substrate. The influence of alcohol on metachromasia of myelin sheaths would appear not to be caused by the chromotropic component being dissolved, but by the interference of the alcohol with the metachromatic association of dye molecules. Though electrostatic forces are definitely at the base of the metachromatic effect, other factors seem to exert a certain influence."

Vimeux D33,732/52: In the mature, unlike in the primary follicles of women, cows, rabbits, sheep and rats, the follicular fluid is strongly metachromatic. This phenomenon is independent of the local MC count and clearly demonstrable even in the rabbit which possesses virtually no MCs in the ovary. Yet, follicular fluid may contain heparin since it possesses a definite anticoagulant effect. Addition of hyaluronidase diminishes the metachromasia of follicular fluid.

Dalcq D31,604/52: Toluidine blue stains certain portions of the cytoplasm (presumably mitochondria) metachromatically, in the cleaving ovum of rodents, in vivo. Similar metachromatic vital staining is demonstrable, for example, in the cells of the corona radiata in ovarian follicles, the oviduct, spermatic epithelium, reticuloendothelial cells, mucous and serous glandular epithelia, etc. No suggestions are made concerning possible relationships between such metachromatic granules and those found in MCs.

Sylvén & Malmgren D26,590/52: In the sol state, purified hyaluronic acid is devoid of metachromasia. In order to speak of true metachromasia, "we require the appearance of a new absorption band gamma (γ) at a shorter wave length than the 'normal' alpha (α) and/or beta (β) bands. Changes in alpha (α) and/or beta (β) band extinction values alone are not considered as metachromasia since such changes do not imply the appearance of new complement colors. We also require a certain stability of the new aggregate compounds (responsible for the γ band) to distinguish between stable metachromasia and adsorption of dye molecules producing 'nonstable' metachromatic reactions."

French & Benditt D31,601/53: Various proteins may modify the reaction between metachromatic dyes and polysaccharides by competing with the dye for the stainable groups.

Benditt & French D31,572/53: Observations on the effect of enzymes upon metachromasia.

Halmi & Davies B87,805/53: Systematic studies reveal that most of the metachromatic substances (including MC granules) are also aldehyde fuchsin positive, but fixation abolishing metachromasia does not necessarily diminish the affinity for aldehyde fuchsin.

Kramer & Windrum D30,593/53: Following brief immersion of sections in concentrated sulfuric acid, followed by staining with a dilute solution of a metachromatic dye, all normally PAS-positive elements (except glycogen) stain metachromatically. This is true of mucins, basement membrane, and reticulin, the brush borders of renal tubular and intestinal epithelium, thyroid colloid, hyalinized renal glomeruli, basement membranes, intra- and extracellular gastric mucin, etc. The capacity of such elements as cartilage or MCs to stain metachromatically is not impaired by the acid treatment. The distinction between the reticulin and collagen is emphasized since the latter continues to stain orthochromatically.

Kramer & Windrum B93,619/54: Methods for the sulfation and the desulfation of tissue carbohydrates in histologic sections.

Grossfeld D26,727/54: MCs cannot be specifically identified by supravital metachromasia since intracellular granular metachromasia is a general phenomenon found in a variety

of living cells in tissue cultures. "In tissue culture cells, the appearance of intracellular granular metachromasia is evidence of cell viability and intracellular orthochromasia, one more criterion of cell death." It is thought that dye condensation effected by an active process within the cell is one possible factor in producing vital metachromasia.

Kramer & Windrum D26,969/55: The significance of metachromatic staining reaction is reviewed, and emphasis is laid upon the point "that when the metachromatic staining reaction is used for histochemical purposes it is essential that steps be taken to differentiate histochemically significant irreversible metachromasia from the nonspecific reversible metachromasia which can be exhibited under certain conditions by an extremely wide range of tissue elements. This can be done either by mounting the sections after staining in Apathy's medium or syrup of laevulose, as recommended by Lison [D26,856/35; D26,967/35], but far more effectively by alcoholic dehydration."

Piccaluga D28,533/56: Exposure of alcohol-fixed rat peritoneal MC smears to lysozyme causes a marked diminution of their metachromasia. Exposure to ovalbumen and ovomucoid is much less active or inactive. On the other hand, even heparin loses its metachromasia when thus treated with lysozyme. Apparently, such basic colloidal proteins as lysozyme interfere with metachromasia and may thus give the impression of MC disappearance.

Schubert D31,611/56: The number of MCs, demonstrable by metachromatic staining in human bone marrow, depends upon the *p*H of the dye solution.

Fulton et al. C35,831/57: Lison (D26,856/35; D26,967/35; D26,729/36; D26,968/60) claimed that metachromasia is a specific characteristic of sulfated mucopolysaccharides. However, it was subsequently demonstrated that this reaction may occur with a number of acid polyelectrolytes containing no sulfate (*Sylvén* D26,590/52). The fact that heparin also gives metachromasia with toluidine blue (*Jorpes* D26,965/39) called attention to the possible production of heparin by MCs. However, the true significance of metachromatic staining is still much discussed.

Caselli & Schumacher D33,666/58: The metachromatic staining ability of heparin solutions and of rat peritoneal MCs is blocked by various basic proteins. Mast-cell granules do not stain even orthochromatically (at a neutral *p*H) with basic dyes after exposure to basic proteins. Apparently, the acid polysaccharides of heparin and MC granules form complexes with the proteins and such complex formation is held responsible for the well-known "disappearance of MCs" in edema, inflammation, and various intoxications. It is thought that the MCs may exert a buffer effect with regard to the tissue concentration in electro-positive substances.

Zachariae & Jensen C48,660/58: In rabbit ovaries, the follicular fluid stains metachromatically with toluidine blue.

Windrum D33,686/58: Discussion of the histochemical mechanism of metachromasia with special reference to the induction of metachromasia in hyaluronic acid by sulfation.

Kelly G19,255/58: "Fundamentally, the metachromasy of cationic dyes reflects no more than the relative density of free electronegative groups, probably but not necessarily in compounds of high molecular weight. Practically, the metachromasy of cationic dyes detects sulfuric esters and metaphosphate under the widest conditions. Under special conditions or within narrow limits, compounds containing phosphate or carboxyl groups may be detected. The most important cellular or tissue inhibitors affecting the interpretation of these reactions are proteins."

Velican & Velican D27,405/59: When exposed to hyaluronidase in vitro, the metachromatic granules of certain MCs of man do, while others do not, lose their metachromasia. Apparently, "in certain mast cells the metachromatic content consists exclusively of hyaluronic acid, while in others this substance forms a certain part of the metachromatic material."

Macaluso & Salerno D26,434/60: Following pretreatment in vitro of the isolated rat mesentery with various basic colloids (e.g., protamine, lysozyme, thymus histone, hemoglobin), they lose their stainability with toluidine blue. This inhibition can in turn be blocked by subsequent treatment with acid colloids (e.g., heparin, dextran, chondroitin sulfuric acid, ovalbumen, gelatin). The possibility is considered that, even in vivo, the stainability of MCs (and, hence, their apparent number) may depend upon the balance between acid and basic colloids in the surrounding tissue fluid.

Spicer D30,596/60: Comparative studies of the conditions under which various mucopolysaccharides, including MC granules, exhibit metachromasia and staining with orthochromatic mucopolysaccharide dyes, including alcian blue.

Brusca et al. G17,025/60: Methyl-lysozyme, which is devoid of enzymatic activity, nevertheless diminishes the in vitro metachromatic tingibility of human MCs. This effect presumably depends upon the basic colloidal nature and not upon the enzymatic potency of lysozyme.

Caselli et al. D26,433/60: If smears of rat peritoneal fluid are brought in contact with various electropositive colloids, the metachromasia of the MCs disappears. In this respect, salmine, lysozyme, cytochrome C, ACTH, papain, and thymic histone proved to be particularly active, while chymotrypsin, trypsin, ribonuclease, globin, and hemoglobin were less effective. Lysozyme retained its ability to block metachromasia even after having been enzymatically inactivated. Histamine, though known to combine with MC granules, was inactive. The metachromasia of isolated peritoneal MCs of the rat can be inhibited by various proteins of low molecular weight and high isoelectric point.

Radden D63,164/61: "In the mast cell, the staining of metachromatic granules is influenced by the *p*H of the solution—at a level of *p*H 3, metachromatic granules stain rapidly, and orthochromatic staining is retarded. The presence of metallic cations delays granule staining, the duration of the delay being proportional to the cationic concentration, related to the cationic valency, and to the position of the cation in its valency group."

Macaluso et al. D33,720/61: Various large molecular basic histamine-liberators (48/80, protamine, lysozyme) inhibit the metachromatic staining of rat mesenteric MCs in vitro without causing granule discharge. It is concluded that, at least in vitro, many histamine-liberators act by blocking metachromatic staining rather than by granule discharge. It is possible that even histamine release may result as a consequence of such treatment without granule discharge.

Spicer D63,192/62: "Chromatin and nucleoli of tissues fixed with formalin-free, mercurial or alcoholic solutions, have the unique property of staining metachromatically with the acid dye Biebrich scarlet in the restricted *p*H range 9.0–10.0." The mechanism of this staining reaction has been studied in a great variety of cells other than MCs.

Thiéry D5,220/64: When viewed with the electron microscope, diverse metachromatic substances exhibit a lamellar structure similar to that of MC granules. "It appears, therefore, that metachromasia is related not only to the chemical nature of metachromatic substances but also to their ultrastructure."

Selye & Jahnke G11,105/65: In the rat, uranyl acetate s.c. produces intense MC degranulation with diffuse metachromasia of the adjacent connective tissue and striated cutaneous musculature at the injection site. These changes differ from those elicited by classical MC-dischargers in that the liberated MC granules assume a peculiar yellowish-violet tinge after staining with azure A, and remain demonstrable in the connective tissue for a long time, without being absorbed or phagocytosed. Furthermore, the MC degranulation elicited by uranyl acetate is accompanied by diffuse metachromasia of the surrounding tissues and elimination of metachromatic material in the renal tubules.

SPECIAL STAINS

Undoubtedly the most important histologic methods for MCs depend upon the metachromatic staining of their specific granules with basic aniline dyes, among which toluidine blue, cresyl violet, azure A, and methylene blue are most commonly used. All of these stains also visualize the general histologic structure which, being orthochromatic, contrasts with the metachromatic MC granules.

Because of this difference in stainability, the recognition and counting of the MCs rarely poses any problems, but if it does we can use procedures which stain only the MCs with great selectivity. For this purpose chrysoidin, Bismarck brown, or a modification of the astrablue technique have been recommended.

In order to stain the metachromatic granules and the rest of the cell (nucleus, cytoplasm) in contrasting colors, the Feulgen + methyl-green, or the Feulgen + Bismarck-brown techniques may be recommended, especially since they also show mitotic figures in MCs with great clarity.

Frequently, granules with different staining properties can be demonstrated in adjacent MCs or even within the cytoplasm of the same MC by certain dye combinations, for example: alcian blue + PAS, toluidine blue + astrablue, or alcian blue + cresyl violet.

Histochemical procedures for the detection of individual compounds (e.g., tryptophan, 5–HT, histamine, enzymes) in MCs will be discussed in the next chapter.

Reviews: *Sumi* C60,846/58
Kelsall & Crabb D26,076/59, *p. 72*

ALCIAN BLUE

Gomori D33,670/54: The MCs of different tissues in various animal species stain intensely with alcian blue.

Spicer C92,580/60: With combined alcian blue + *safranin* stain, certain MCs color blue, others red.

Orlandi D26,658/61: Staining of the acid mucopolysaccharide granules with alcian blue and counterstaining of the nuclei with *Kernechtrot* gives particularly-clear pictures of human MCs.

Jasmin & Bois D27,951/61: Following double staining with alcian blue and *cresyl violet,* two types of MCs are distinguished according to their affinity for one or the other of these dyes. "It was concluded that alcian blue stains immature mast cells that do not contain sulfated polysaccharides, whereas cresyl violet stains mature mast cells in which sulfated polysaccharides are found." Upon sulfation, all MCs stain metachromatically with cresyl violet.

Arvy E37,387/62: Simultaneous staining with alcian blue and *PAS* shows granules staining selectively with one or the other of these dyes within the same cell. "This proves that all the granules do not attain simultaneously the same degree of sulfation."

Worthington & Bailey D14,170/62: By staining rat MCs with alcian blue and *safranin,* it is possible to show that some of the granules take up one or the other of these dyes selectively.

Lorentz D29,001/62: A detailed analysis of the physico-chemical basis of alcian blue staining led to the conclusion that the uptake of this dye by mesenchymal structures depends mainly upon their sulfuric acid radical content and, to a much lesser extent, upon the presence of amino and glycol groups. Aldehydes are of negligible importance. Stainability also depends considerably upon *p*H.

ASTRABLUE

Pioch D33,707/57: Astrablue (a copper phthalocyanin dye) is suitable for the specific staining of acid mucopolysaccharides in general and of MC granules as well as mucoid substances in particular.

Bloom & Kelly D65,674/60: Observations on the rat lead to the conclusion that "when staining with astrablue is carried out at *p*H 0.2 there is absence of nuclear staining, absence of cytoplasmic background in the mast cell, absence of most staining in connective tissue ground substance and good granular detail in the mast cell. In peritoneal smears at *p*H 0.2 Astrablau stains nothing but mast cell cytoplasmic granules."

Schauer & Eder D30,202/62: Sections fixed in formaldehyde and then embedded in paraffin are stained with astrablue 0.5 per cent in 1 per cent acetic acid (*p*H 3) for ten minutes. Rinse in distilled water and subsequently stain with *PAS* as usual. In rat MCs, PAS and astrablue-positive granules may be found within the same cell.

AZURE

Lillie B44,595/47: Azure C (C.I. No. 923) is recommended.

Kramer & Windrum D26,969/55: A technique for specific metachromatic staining with azure A.

Fullmer D27,394/59: Normally, mouse MC granules stain metachromatically with azure A. "After peracetic acid oxidation, both glucuronidase and lysozyme enzymatically remove a component from mast cells that is stained with aldehyde fuchsin and the Hale stain, and there remains a component inducing strong metachromasia with azure A."

BISMARCK BROWN

Lillie B44,595/47, *p. 285*: Bismarck brown Y (C.I. No. 331) is recommended.

Shubich D39,830/58: Upon staining with Bismarck brown, only the MCs are colored and, hence, they become easily detectable.

Gottlieb et al. D26,743/61: The metachromatic granules of mouse mastocytomas, which normally are not readily tingible, can be demonstrated by a technique "based on fixation in a solution of lead subacetate in ethyl alcohol slightly acidified with acetic acid, and staining with hematoxylin and Bismarck brown, or with nuclear fast red and Bismarck brown."

CADMIUM DYE COMPLEXES

Quensel D39,827/28: Neutral-red cadmium and Neublau-cadmium are recommended for the metachromatic staining of human MCs.

CARMINE, MUCICARMINE

Arnold D29,582/13; *Lehner* D27,094/24; *Wermel & Sassuchin* D39,520/28: Best's carmine stains MCs only quite irregularly.

Wermel & Sassuchin D39,520/28: Mucicarmine stains MCs only superficially and not very intensely.

Gomarasca D39,761/34: The granules of human MCs stain well with carmine red according to the method of Vastarini-Cresi.

Sylvén D31,570/39: Mucin was originally defined as "a viscous thread-forming slippery fluid which upon addition of acetic acid forms a fibrous precipitate of characteristic aspect." It was at first thought to be a protein but it is now classed as a mucoprotein. The only characteristic feature of epithelial mucin is the presence of mucoitin-sulfuric-acid and a high molecular estrified sulfuric acid. The mucus of goblet cells and salivary glands may now be defined as "an epithelial-secretion product containing mucoitin-sulfuric-acid as its only characteristic constituent". The staining with mucicarmine depends upon the formation of a bond between the aluminum carminate of the mucicarmine solution and mucoitin-sulfuric-acid. However, mucicarmine is by no means a characteristic stain for mucins; they stain even more easily with metachromatic dyes. For the staining of MCs, the mucicarmine method is of no practical value. Although heparin stains with mucicarmine and a mucicarmine-positive halo develops around MCs, the granules themselves are difficult to demonstrate with this technique.

Gomori D33,670/54: Mucicarmine fails to stain the MCs of various tissues in different animal species.

CELESTIN BLUE

Gomori D33,670/54: The MCs of various tissues in diverse animal species are stained purplish blue-black by celestin blue.

CHRYSOIDIN

Harada D33,734/57: "A simple chrysoidin stain (0.5% aqueous solution, 5–10 min.) is selective for mast cell granules; alum-hematoxylinchrysoidin stains histological features in addition to the granules and periodic acid-Schiff can be used for cytological and histochemical features."

DIMETHYL-P-PHENYLENEDIAMINE

Bonomi D92,205/51: MCs take on a dark brown color when stained with dimethyl-p-phenylenediamine.

ELASTICA

Bierich D27,096/22: Among two elastica stains tested, resorcin-fuchsin stained a sponge-like reticulum within the MC cytoplasm deep blue, while orcein did not stain the MCs. It is

assumed that either the former stain is not specific for elastic fibers or the preparation of orcein may have been of poor quality.

FEULGEN + METHYL GREEN

Allen D61,514/61; D61,513/61: For the staining of mitotic figures in MCs, rat mesenteric "spreads were fixed in neutralized 4% formaldehyde for 30 minutes and colored by the Feulgen reaction and methyl green [*Allen* D29,603/60]. The Feulgen hydrolysis was performed at 60°C for 12 minutes. The spreads were reacted with leuco-fuchsin solution for two hours and were carried through three changes of bleaching solution, 5 minutes in each. After rinsing in tap water, the spreads were colored for 10 minutes in 0.5% methyl green (chloroform extracted) in 50% ethanol. They were rinsed briefly in 70 and 95% ethanol and dehydrated in normal-butyl alcohol before being cleared in xylene. The alcohol solutions rapidly removed the methyl green from all of the structures of the mesentery except the cytoplasmic granules of the mast cells; thus, the mast cells were clearly demonstrated and the nucleus and cytoplasm were colored in complementary colors."

FEULGEN + BISMARCK BROWN

Meggers & Allen D27,664/62: The Feulgen + methyl green method, previously used for the demonstration of mitosis in MCs, can be improved by substituting Bismarck brown for methyl green as a cytoplasmic stain because of its greater permanence in tissues previously subjected to the Feulgen reaction. The procedure was performed as follows: "Segments of mesentery of 30-day-old rats were spread on glass slides and fixed in 10% formalin for 1 hr. They were stained first by the Feulgen reaction, then by a solution of 0.5 Bismarck brown in 50% ethanol containing 0.2% acetic acid. The tissues were dehydrated, cleared, and mounted in synthetic resin (Permount). Nuclei and mitotic figures in mast cells were stained reddish violet; cytoplasmic granules, yellow-brown. The nuclei were clearly visible through the cytoplasm. Similar results were obtained with formalin-fixed, paraffin-embedded tissue."

FITE-FARACO STAIN

Gupta & Ghosh D39,828/63: The cutaneous MCs in leprosy as well as in many other dermatoses of man and in the normal mesentery of the guinea-pig, show acid-fast granules, demonstrable with the Fite-Faraco modification of the Ziehl-Neelsen stain. These granules, which were first thought to be partially-digested mycobacteria of leprosy, are apparently normal MC constituents.

FUCHSIN, ALDEHYDE-FUCHSIN

Bergonzini D27,587/1891: A special stain consisting of methyl green acid fuchsin and orange-G is described, which lends itself particularly well for the staining of connective tissue and especially MCs.

Bujard D27,581/30: A special stain for MCs is based on pretreatment with fuchsin and subsequent exposure to bromine. The staining of the MC granules is allegedly highly specific.

Gomori C14,604/50: Basic fuchsin combines with certain aldehydes to yield dyes with selective staining-power for elastic fibers, MCs and certain other structures. Mast cells are stained in a deep purple shade by aldehyde-fuchsin.

Halmi & Davies B87,805/53: Systematic studies reveal that most of the metachromatic substances (including MC granules) are also aldehyde-fuchsin-positive, but fixation abolishing metachromasia does not necessarily diminish the affinity for aldehyde fuschin.

Buño B94,605/53: Basic fuchsin is allegedly one of the most useful stains for the demonstration of MCs. The orthochromatic staining of the granules is attributed to heparin since this substance is tingible with basic fuchsin according to the technique of Coujard.

Nepriakhin D26,879/56: The MC granules are strongly fuchsinophilic. In this respect they resemble the so-called "basophilic fuchsinophilic granules of nervous tissue."

Fullmer D27,394/59: Normally, mouse MC granules stain with aldehyde fuchsin but "after peracetic acid oxidation, both glucuronidase and lysozyme enzymatically remove a component from mast cells that is stained with aldehyde fuchsin and the Hale stain, and there remains a component inducing strong metachromasia with azure A."

Barlow D31,600/57: A "tribasic stain", consisting of acridine red, neutral red, and basic fuchsin, is recommended. "The method gives satisfactory results on the tissues of man,

ox, pig, dog and rat. Mast-cell granules stain orange to red, the shade varying somewhat with the species of animal. Both the type-I and type-II mast cells described by Riley [B90,275/53] are stained positively. Cartilage, keratin and bacteria stain pink or red, and mucin occasionally a faint pink. Nuclei are blue, and other tissue elements green or clear yellow depending on the counter-stain employed."

Stolk D26,444/61: The MCs of various viviparous *Cyprinodonts* react well with aldehyde fuchsin.

GOLD

Raudnitz D28,536/1883: The MC granules stain black with gold chloride.

IRON, COLLOIDAL (HALE)

Hale D33,678/46: The following technique is recommended for the histochemical demonstration of acid polysaccharides: after fixation in Carnoy's fluid, paraffin sections are treated with an acid solution of ferric hydroxide, whereupon the iron combines with acid polysaccharides but not with neutral polysaccharides or proteins. The iron can be demonstrated by the Prussian blue reaction and if counterstained with fuchsin, the acid polysaccharides are blue against a red background of other structures.

Rinehart & Abul-Haj D33,696/51: Modification of Hale's stain for the demonstration of acid mucopolysaccharides in tissues.

Gomori D33,670/54: Hale's colloidal iron stains the MCs in various tissues of diverse animal species intensely.

Fullmer D27,394/59: Normally, mouse MC granules stain with Hale's procedure but, even after the material that stains with aldehyde fuchsin and the Hale stain is removed, the metachromatic substance remains.

Stolk D26,444/61: The MCs of various viviparous *Cyprinodonts* react well with Hale stain.

METHYLENE AZURE

Michaelis D27,717/02: Methylene azure is the active principle in Unna's polychrome methylene blue which stains the MC nuclei blue and their granules red.

METHYLENE BLUE

Unna D28,273/1891; D28,274/1894: MCs stain metachromatically red with methylene blue. If pure methylene blue solutions are "ripened" by the addition of sodium carbonate and ammonium carbonate under specified conditions, a *polychrome* stain results presumably because of the formation of methylene violet and methylene red. With this solution, the red MC granules are most readily differentiated from the blue plasmacells.

Unna D28,274/1894: Combined staining with *orcein* and polychrome methylene blue is recommended for the simultaneous demonstration of metachromatic MC granules, plasmacells, and cytoplasm in general.

Löwit E78,718/03: Methylene blue with *lithium carmine* is recommended.

Highman D29,566/45: Methylene blue N can be used for the metachromatic staining of both MC granules and mucinous substances, for example, the mucus of intestinal epithelial cells.

Stinson et al. D26,841/61: Terry's neutralized *polychrome* methylene blue stain is excellent for the demonstration of MC granules, but permanent sections are difficult to prepare. A modification of the technique is developed for fresh tissues or tissues preserved in 10 per cent formalin which readily permits the preparation of permanent sections.

Nielsen G2,900/u.p.: Fixation: Alcohol-formol 48 hours. Dehydration: Dioxane. Embedding: Paraffin. Cut at 5 μ. Deparaffinize with xylol. Three changes of 95 per cent alcohol and bring into water. Stain for 8 minutes in mixture of 0.5 g. methylene blue, 2000 ml. distilled water, 1 ml. lactic acid (concentrated), 8 ml. 1 per cent aqueous *orange G*, 5 ml. 1 per cent aqueous *acid fuchsin*. Rinse briefly in distilled water, dehydrate in one change of 70 per cent alcohol, followed by 2 changes of absolute alcohol; clear in xylol.

MULTIPURPOSE POLYCHROME STAIN

Selye & Nielsen D78,786/65: The following "multipurpose polychrome" (MP) stain has been devised primarily for general orientation because it stains a multitude of specific elements in distinctive colors and yet permits an excellent overview of general structure. Normal MCs are stained dark purple, but discharged granules are often clearly distinguishable from the intracytoplasmic ones by their bright red color. In addition, elastic membranes, the β-cells of the Langerhans' islets and of the anterior pituitary, the neurohumoral material in the posterior lobe, and fibrin are stained violet. The cross-striations of skeletal musculature is clearly shown. The anterior pituitary eosinophils, erythrocytes, and cardiac muscle fibers undergoing "fuchsinophilic degeneration" stain bright red. Collagen fibers are orange and certain polysaccharides exhibit the greenish-blue color of alcian blue. The procedure is as follows:

1. Fix in Helly's Fluid for 24 hours. Wash in running water overnight, embed in paraffin.
2. Remove mercury-bichloride precipitate in the usual manner with iodine-thiosulfate.
3. Oxidize 1 minute in 0.3 per cent potassium permanganate + 0.3 per cent sulfuric acid in distilled water.
4. Rinse in water.
5. Two per cent sodium metabisulfite 1 minute.
6. Running water 5 minutes.
7. Stain in the following solution for 10–30 minutes, depending on the age of the stain:

70 per cent Alcohol	200 ml.
Basic fuchsin	0.2 g.
Alcian blue 8 GS	1.2 g.
Paraldehyde	2 ml.
Hydrochloric acid	2 ml.

Let ripen for 24 hours before using.

8. Rinse well in 70 per cent alcohol.
9. Running water 5 minutes.
10. Mordant for 15 minutes in 1% phosphotungstic acid.
11. Rinse briefly in water.
12. Stain 1–2 hours in following solution:

Acid fuchsin 1 per cent	2 ml.
Orange G 1 per cent	0.4 ml.
Lactic acid	0.5 ml.
Distilled water	47 ml.

The staining time in this step is not critical; 2 hours may be needed for pituitary.

13. Rinse in tap water.
14. Rinse in absolute alcohol.
15. Stain for 12 minutes in a saturated solution of saffron in absolute alcohol.
16. Absolute alcohol; clear in xylol; mount.

(All dyes obtained from Chroma-Gesellschaft, Schmid & Co., Stuttgart-Untertürkheim, Germany.)

NEUTRAL RED + HEMATOXYLIN

Allen D92,603/60; D61,513/61.

NIGHT BLUE

Winkelmann C77,749/59: The affinity of MC granules for night blue was demonstrated in fresh and fixed specimens of rat lip, dog mastocytoma, normal human ileum, and human mastocytoma tissue.

Klaus & Winkelmann C80,962/59: With night blue, MCs stain orthochromatically deep blue in the rat but not in all other species.

Winkelmann D33,685/59: "Night blue will stain the mast cells of rat, mouse and hamster selectively if alcohol differentiation is controlled. The technical steps are: Dewax

paraffin sections with xylene, 2 changes; air dry; 2% Na_2SO_4, 3–5 sec; 0.5% night blue in 10% ethanol, 1 hr. at 60°C; rinse in water; 9% HNO_3, 15 sec; water 1–5 min; 70% ethanol, 2 changes, 30 sec each; wash; 0.01% safranin, 3–5 sec; rinse, blot, air-dry, mount in synthetic resin. A clear orthochromatic stain of the mast-cell granules occurs. Acid fixation prevents the staining reaction."

Stolk D26,444/61: Night blue is especially recommended for MCs.

NUCLEAR FAST RED

Coupland & Heath D2,439/61: Nuclear fast red is said to be a specific stain for dopamine, and it also stains the granules of MCs.

PAS

Jorpes et al. D27,623/48: "The granules of the mast-cells in the subcutaneous tissue of the rat are strongly colored with Schiff's reagent, which could indicate the presence of heparin monosulfuric acid or some other heparin precursor."

Wislocki et al. D28,970/49: The MCs in the connective tissue of various organs of man and monkey, stained much more intensely with PAS than those of the rat. On the other hand, all MCs examined stained metachromatically with toluidine blue.

Jeanloz D26,450/50: "Since the information bearing on the mechanism of the Hotchkiss reaction is only fragmentary, we consider it unsafe to use this reaction for identification of polysaccharide structure."

Lillie D26,787/50: Detailed analysis of the significance of PAS and metachromatic stainability in various tissues, with special reference to the MCs, shows the nonspecificity of these techniques.

Compton B90,594/52: Hamster MCs do not stain consistently with PAS and, indeed, are more frequently unstained than stained. "Various interpretations of this are: 1) the hamster mast cell granule contains no heparin; 2) the hamster mast cell contains mainly the trisulfuric form of heparin; 3) irregularity in staining may represent different stages of esterification during the synthesis of heparin."

Buño B94,605/53: A review of the literature shows that data concerning the PAS tingibility of MC granules are contradictory. It is thought that the granules are not inherently tingible with PAS but that their occasional staining depends upon the presence of minute amounts of non-decolorized fuchsin in the Schiff-reagent.

Lillie D28,666/56: It is claimed that, with PAS, "mast cells seem to react in a considerable number of instances, especially in man, but not always and not in some species."

Moore & Schoenberg D30,210/57: In mature umbilical cords, the MCs stain metachromatically with toluidine blue at the entire *p*H range between 2.0 and 7.5 although discrete granules could not be identified. In younger cords (less than 12 weeks in age), MCs were only occasionally identified and only at *p*H ranges between 6.0 and 7.5. After sulfation, a larger number of metachromatic MCs could be identified and stained throughout the entire *p*H range. Here, the MCs also stained with PAS and that quite independently of sulfation. Hyaluronidase and amylase had no effect on either metachromatic staining or PAS reaction.

Lennert & Schubert D33,718/61: Tissue MCs, like blood basophils, give a positive PAS reaction.

Stolk D26,444/61: *Tartrazine* counterstaining in connection with the PAS method is recommended for the staining of MCs.

Feagler & McManus G19,927/64: PAS stains the MCs of the rat to a variable extent and the granules are not much darker than the cytoplasm.

PINACYANOL ERYTHROSINATE

Bensley D28,535/52: "An alcoholic solution of the compound dye, pinacyanol erythrosinate when diluted to the optimum dissociation point is a differential tissue stain which, in addition, selectively stains and differentiates mast cells. It can be made up and used like any other compound dye (e.g., Bowie's stain, neutral gentian, etc. or like a blood stain). It can be used after any of the common fixatives and has the advantage of selectively staining all types of mast cells in their various functional phases, even in those species (notably rabbit and man) in which they may be difficult to demonstrate with other mast cell stains after aqueous fixatives."

PYRONIN + METHYL GREEN

Trevan & Sharrock D39,525/51: A pyronin methyl green-orange G stain is described, which "usually" stains MC granules from very dense red-brown to almost black.

Buño B94,605/53: MC granules stain metachromatically with pyronin and methyl green; the staining with pyronin is attributed to RNA while the reaction with methyl green is assumed to depend upon DRNA.

Chen & Chang D59,711/63: Procedure for the use of methyl green + pyronin as a stain for MCs in paraffin sections.

RHODAMIN S

Kardos D27,980/11: Rhodamin S stains MC granules metachromatically brownish-red.

RINEHART STAIN

Stolk D26,444/61: The MCs of viviparous *Cyprinodonts* react well with Rinehart stain.

SAFRANIN

Unna D28,274/1894: MCs stain metachromatically orange with safranin.

Federici D27,595/06: A method is developed for the staining of MC granules with safranin O and *Lichtgrün*. The technique is compared with the methods in which dahlia (*Ehrlich* D26,864/1877), vesuvine (*Nordmann* D28,272/1885), methylene blue (*Unna* D28,273/1891; D28,274/1894; *Hoyer* D28,275/1890) or methyl green-pyronin-resorcin (*Pappenheim* D28,277/01) are used and is found superior to all of these.

Lillie B44,595/47: Paraffin sections of formalin-fixed material are deparaffinized and brought up to 80 per cent alcohol, as usual.

1. Weigert's acid iron chloride hematoxylin six minutes.
2. Wash in water.
3. 1:5,000 aqueous *Fast Green* (FCF) for three minutes.
4. Wash in 1 per cent acetic acid.
5. Stain 4–6 minutes in 0.1 per cent safranin 0 (C.I. No. 841) in water.
6. Dehydrate with 95 per cent and two changes of 100 per cent alcohol, clear with one change of 50:50 alcohol xylene mixture and two changes of xylene. Mount in synthetic resin.

Results:—Nuclei, black; cytoplasm, gray-green; mucus, cartilage, and MC granules, orange-red. If cytoplasms, collagen, muscle etc., do not stain green, reduce the time in Step 5.

TANNIN + IRON HEMATOXYLIN

de Sousa D39,787/45.

THIONIN

Levine 68,868/28: A technique for the staining of MCs with thionin and orange G.

Lillie B44,595/47:

1. Deparaffinize and hydrate section as usual.
2. Stain 30 minutes in 0.5 per cent thionin (C.I. No. 920), in 0.01 M acetate buffer.
3. Rinse, dehydrate in alcohol, clear with xylene, mount in polystyrene.

Results:—Connective-tissue mucins, purplish-red; MC granules, red-purple; nuclei, blue-violet; red corpuscles, pale yellow; basophil cytoplasm, blue; muscle and connective tissue, faint greenish or unstained.

Geyer D59,248/62: Comparison of the methanol-thionylchloride reaction with other stains.

TOLUIDINE BLUE

Lillie B44,595/47: Toluidine blue 0 (C.I. No. 925) is recommended.

Castiglioni E26,509/47: Modification of the toluidine blue method for the metachromatic staining of MCs.

Friberg et al. C72,065/51: Using a special variant of the toluidine-blue technique, it can be shown that the mesenteric MCs of the rat contain metachromatic material only in the

granules, while the cytoplasm is completely devoid of it. On the other hand, PAS stains the granules strongly and the cytoplasms faintly. It is concluded that heparin is confined to the granules, while precursors may exist in the intergranular cytoplasm.

Moore & Schoenberg D30,210/57: In mature umbilical cords, the MCs stain metachromatically with toluidine blue at the entire *p*H range, between 2.0 and 7.5, although discrete granules could not be identified. In younger cords (less than 12 weeks in age), MCs were only occasionally identified and only at *p*H ranges between 6.0 and 7.5. After sulfation, a larger number of metachromatic MCs could be identified and stained throughout the entire *p*H range. Here, the MCs also stained with PAS and that quite independently of sulfation. Hyaluronidase and amylase had no effect on either metachromatic staining or PAS reaction.

Kelly & Bloom G9,515/59: Rat peritoneal MC smears, stained with toluidine blue, are favorable objects for *spectrophotometric analysis*. The sum of extinctions at two wavelengths (546 mμ and 630 mμ for toluidine blue), to measure the total amount of metachromatic dye bound in the MCs, can be used as a basis for quantitation. "Calculated amounts of dye bound per cell are on the order of 3 x 10^{-14} mole or less, the average dye concentration being 0.06 M or 1.8 per cent."

Lennert et al. D26,817/59: Increased maturation of the MC granules is due to an increase in the number of SO_4 groups in its mucopolysaccharides. This manifests itself by increased toluidine-blue metachromasia and stainability at a high *p*H. Immature MCs (particularly those in mastocytosis), can thus be stained only at low *p*H under usual conditions but if they are *artificially sulfated*, then they become toluidine-tingible even at very high *p*H.

Padawer D30,206/59: Since aqueous fixatives and stains tend to damage MCs, the following *non-aqueous technique* is recommended: (1) Fix tissues, tissue spreads, or smears in ethanol 90 ml. = 10 ml. formalin. Smears may be fixed in absolute methanol. (2) Extract lipids with Folch solution (MeOH: $CHCl_3$, 2:1, v/v). Treat tissue spreads 24 hours; paraffin sections and smears may not require this step. (3) Rinse in absolute methanol, 2 changes, 10 minutes each. (4) Rinse in tetramethylene glycol ether (Ether 181, Ansul Chemical Co., Marinette, Wis.), 50 per cent aqueous (v/v), 10 minutes. (5) Stain in 0.05 per cent toluidine blue in 50 per cent aqueous Ether 181, from 20 to 60 minutes. The dye is first dissolved in water, then Ether 181 is added and the solution is filtered. This stain performs best if used within 24 hours. (6) Rinse in 50 per cent Ether 181, 10–15 minutes with occasional agitation. (7) Dehydrate in 100 per cent Ether 181, 2 changes, 20 minutes each. (8) Clear in xylene, 2 changes, 15 minutes each. (9) Mount in synthetic resin. "The mast cells of man, rat, mouse, hamster, cat, dog, rabbit, bat, chicken, and frog were stained selectively by this technique. No mast cells were found in tissues of the bass, sea robin, tautog, and Fundulus, but some metachromatic cells (possibly mast cells) were noted in the scup. Cartilage was the only other tissue examined that showed any metachromasia; no metachromasia was observed in ground substances, or in goblet cells. Basophilic leukocytes of man and rabbit did not stain." Fine metachromatic granules were also demonstrated in cells of a solid mouse mastocytoma and in those ascitic mastocytoma cells which had invaded the mesenteries. On the other hand, free cells of the ascites form, or similar cells grown in tissue culture, revealed no metachromatic granules.

Radden D26,768/60: The *specificity* of the staining reaction with toluidine blue can be greatly increased if paraffin-embedded sections are treated as follows: "(1) remove paraffin wax with xylene, and hydrate in descending grades of ethyl alcohol; (2) wash in distilled water; (3) immerse in a 'pretreatment' solution of 1 in 10 dilution of McIlvaine's sodium hydrogen phosphate citric acid buffer at *p*H 3.0 for 1 hr.; (4) stain for 10 min. in a 0.01 per cent toluidine blue (Gurr 2706) solution in a 1 in 10 dilution of buffer at *p*H 3.0 to which 2 gm. per cent crystalline magnesium chloride have been added; (5) counterstain with 0.1 per cent *nuclear fast red* (Gurr 3569) for 5 min.; (6) rinse in distilled water; (7) dehydrate with three changes of isopropyl alcohol for 2 min. each; (8) clear in toluene or terpineol; (9) mount in toluene-balsam, and dry away from heat." By combining this "specific" stain with the *Feulgen* reaction, the precise relationship of the nuclei to the granules of the MCs can be particularly well demonstrated.

Lennert & Back D27,076/61: Using a technique in which the MCs of inflamed human lymph nodes are stained with toluidine blue buffered to maintain a steady *p*H at levels between 2.4 and 5.0, it is possible to differentiate between MC granules of different maturity judged by their ability to stain metachromatically even at a low *p*H.

Schauer & Eder D30,202/62: In rat MCs, stained with the combined toluidine-blue and *astrablue* technique, certain granules stain orthochromatically with astrablue, others metachromatically with toluidine blue.

Holczabek D41,584/63: *Cryostat* sections are highly suitable for the demonstration of MCs in human lung material. Here, metachromasia is most evident after staining in aqueous 0.05 per cent toluidine blue buffered with phosphate to *p*H 7.0.

VESUVIN

Nordmann D28,272/1885: Vesuvin is recommended as a particularly specific stain for MCs in various tissues of animals and man.

HISTOCHEMISTRY

With the development of histochemical technology, much research has been done to identify individual compounds in MCs.

5–HT can be visualized in the MC granule by specific procedures and the fact that, at least under certain circumstances, MC granules are argentaffinic, has suggested some relationship between MCs and the argentaffin cells (probably the main producers of 5–HT).

Histamine and, owing to its metachromasia, *heparin* can also be identified histochemically in MCs, while the presence of *adrenaline, noradrenaline,* and *DOPA* is still much debated. Certain MC-like cutaneous cells, closely associated with peripheral nerve endings, appear to be weakly metachromatic and tingible with chromium salts, but it is highly dubious whether these elements are related to true MCs.

It appears that there may be some *tryptophan, arginine,* and perhaps even *hyaluronic acid* in MCs, but the presence of *ascorbic acid* could not be demonstrated by histochemical means.

Some MCs (especially those situated near inflammatory foci or fat tissue) appear to contain *lipid* granules, stainable with Sudan III, Sudan black, Scharlach R, and Nile blue, perhaps owing to the presence of fats or phospholipids. But the typical MC contains no noteworthy amounts of either fat or *glycogen.*

Iron has only occasionally been demonstrated in the MCs of otherwise untreated animals or men. However, several investigators have called attention to the curious fact that iron-containing phagocytes tend to accumulate in the vicinity of MCs. As we shall see in discussing the phenomenon of "mastopexis", it is possible to induce massive iron deposition on MC granules regularly by combined systemic treatment with iron preparations and MC-dischargers.

The normal MC contains no histochemically-demonstrable *calcium* but upon microincineration, it leaves abundant ash, part of which may represent calcium, *magnesium,* or *zinc.* In any event, several metals (including iron, calcium, lead) can be made to adhere to MC granules through mastopexis.

Considerable attention has been given of late to the great variety of *enzymes* which occur in MCs. Among these, several esterases, lipase, phosphatase, ATP-ase, histidine decarboxylase, 5–HTP-decarboxylase, leucine aminopeptidase, trypsin and chymotrypsin-like enzymes, β-glucuronidase, and β-hydroxybutyric acid dehydrogenase appear to be especially important. On the other hand, MCs do not contain any appreciable amount of oxidase or peroxidase, although they may contain cytochrome oxidase. The fact that blood basophils do, while tissue MCs usually do not give oxidase and peroxidase reactions, has been mentioned as an argument in favor of some essential difference between these two cell types.

HEPARIN

Jorpes D26,892/36; B3,995/47: Heparin gives a strong metachromasia upon staining with toluidine blue, a reaction which, according to Lison (D26,856/35), is assumed to be characteristic of high-molecular esters of sulfuric acid. This observation first suggested that heparin is produced by MCs (*Holmgren & Wilander* D26,887/37; *Jorpes et al.* D26,888/37; *Jorpes* B3,995/47). The preferentially-perivascular position of the MCs has also been cited in support of the heparin theory. It was thought that "this appearance is so consistent that it must have some relation to the hitherto unknown function of the mast cells" (*Quensel* D26,221/33). This concept was formulated even more precisely after the discovery of heparin in MCs by Jorpes (B3,995/47), as follows: "The mast cells, because of their position around capillaries and the small blood vessels without a muscular coat, are able to void their granular contents into the peripheral tissue juices, or almost directly into the blood stream, a state of affairs which indicates that these cells—and with them the heparin—may have a physiological function to fulfill. The mast cells evidently form a hormonal system, with the cells widely distributed around the capillaries in the body."

Jorpes et al. D27,623/48: "The granules of the mast-cells in the subcutaneous tissue of the rat are strongly colored with Schiff's reagent, which could indicate the presence of heparin monosulfuric acid or some other heparin precursor."

Friberg et al. C72,065/51: Using a special variant of the toluidine-blue technique, it can be shown that the mesenteric MCs of the rat contain metachromatic material only in the granules, while the cytoplasm is completely devoid of it. On the other hand, PAS stains the granules strongly and the cytoplasm faintly. It is concluded that heparin is confined to the granules, while precursors may exist in the intergranular cytoplasm.

Compton B90,594/52: Hamster MCs do not stain consistently with PAS and, indeed, are more frequently unstained than stained. "Various interpretations of this are: 1) the hamster mast cell granule contains no heparin; 2) the hamster mast cell contains mainly the trisulfuric form of heparin; 3) irregularity in staining may represent different stages of esterification during the synthesis of heparin." On the basis of this and other observations the author concludes that "although evidence indicates that mast cell granules contain heparin, this content is still unproven."

Buño B94,605/53: The staining of MC granules with fuchsin as well as their argentaffinity is attributed to heparin since the latter substance responds to these dyes in the same manner in vitro.

Hill C64,094/58: On the basis of histologic observations, it is assumed that vacuolization of MCs is related to histamine discharge, complete lysis of the granules to the secretion of heparin, and excretion of granules after intracellular loss of their tingibility to the production of ground substances, particularly of mucopolysaccharides of the hyaluronic acid type.

Gillman C52,329/58: On the basis of histologic observations it is assumed that MCs may play an important role in the turnover of metachromatic mucopolysaccharides.

TRYPTOPHAN

Celestino E21,500/63: Tryptophan could be demonstrated by Adams' paradimethylaminobenzoaldehyde (DMAB) reaction in the tonsil (presumably human, although this is not stated). Attention is drawn to the possible relationship between tryptophan storage and the production of 5–HT.

Crespi & Celestino E38,732/64: Description of a canine mastocytoma in which two types of MCs can be distinguished: (1) small cells giving a positive DMAB reaction and (2) large alcian-blue positive cells. The small DMAB-positive elements are alcian-blue negative. DMAB-positivity presumably indicates the presence of the 5–HT precursor tryptophan or possibly neuraminic acid both of which react positively with DMAB.

ARGININE

Arvy D26,724/55, *pp. 64, 65*: Detection of arginine in MCs.

HYALURONIC ACID

Arvy D26,724/55, *pp. 64, 65*: Detection of hyaluronic acid in MCs.

ASCORBIC ACID

Padawer D64,997/54: No ascorbic acid could be demonstrated in the peritoneal MCs of various species by histochemical means.

RNA

Rheingold & Wislocki D39,650/48: The granules of human bone-marrow MCs contain no RNA.

5–HT AND ARGYROPHILIA

Buño B94,605/53: Under certain circumstances, MC granules are definitely argentaffinic. This tingibility is attributed to heparin since the latter substance can be stained in this manner, even in vitro, by the method of Coujard.

Arvy D26,724/55, *pp. 64, 65*: Discussion of literature on histochemical demonstration of 5–HT in MCs.

Benditt et al. C9,838/55: The demonstration of 5–HT in MCs suggests some relationship between these cells and the argentaffin cells.

Nepriakhin D26,879/56: MCs are not argyrophilic.

Coupland & Riley D26,772/60: Description of a technique for the histochemical demonstration of 5–HT in MCs.

Rice & Mitchener D2,299/61: Discussion of various histochemical techniques suitable for the demonstration of 5–HT in tissues.

Adams-Ray E37,378/64: Using fluorescence microscopic techniques, it is possible to demonstrate in various species cutaneous MCs which contain 5–HT.

HISTAMINE

Schauer & Werle D31,603/59: In rat mesenteric spreads, it is possible to precipitate histamine with Reinecke salt and subsequently to visualize it with diazotized sulfanilic acid.

Lagunoff et al. D289/60: First histochemical demonstration of histamine in MCs after fixation in gaseous formaldehyde, using para-bromobenzenediazonium chloride as a reagent. This salt yields orange azo derivatives with formaldehyde-treated histamine and 5–HT. However, the possibility that 5–HT might have been stained was excluded by: "1. the 10 fold molar excess of histamine with respect to serotonin in intact mast cells and 2. a negative reaction of mast cells with the formaldehyde-ninhydrin method, equally sensitive and highly specific for indole ethylamines."

Lagunoff et al. D30,207/61: "The use of formaldehyde vapor fixation following freeze-drying of tissues permits the histochemical demonstration of histamine in rat mast cells by several color-producing reactions and fluorescence. Formaldehyde vapor fixed, frozen-dried mast cells develop an orange color on reaction with diazotized p-bromoaniline; the cells reduce both ferric ferricyanide and methenemine silver, and fluoresce yellow-green in ultraviolet light. These reactions are consistent with the presence of a tetrahydropyridoiminazole formed in rat mast cells by the reaction of the contained histamine with the applied formaldehyde."

ADRENALINE, NORADRENALINE, DOPA

Zwillenberg D42,931/58: Dihydroxyphenylalanine could not be demonstrated histochemically in intra-epithelial MCs of the esophagus and vagina of various species, but it was found to be present in certain cells of the human portio vaginalis uteri which were "hanging under the epithelium", not unlike active melanocytes in the skin.

Burch & Phillips C64,614/58: Certain chromaffin-reacting cells can be demonstrated in the human digital skin. Initially, differentiation of these special cells from MCs was difficult because they appeared to stain similarly. However, with special methods it can be shown that the chromaffin granules are not in MCs.

Coupland & Heath D26,426/60: Melanin is capable of chelating chromium and, hence, it gives a nonspecific chromaffin reaction, but true chromaffin cells could not be detected in the human dermis, although it contains numerous MCs.

Coupland & Heath D2,440/61: In the hepatic capsule and gut of cattle and sheep, there are dopamine-containing MCs.

Matz & Skinner D33,711/62: The so-called "chromaffin cells", previously described in human digital skin, differ from ordinary MCs in their shape but have the same tinctorial characteristics. Their granules do not produce the true chromaffin reaction of catecholamines, they are unaffected by intra-arterial reserpine injections and remain normal in patients with chronic degeneration of the sympathetic nerves. "It is suggested that the 'chromaffin cells' are mast cell variants and are not involved in the autonomic effector mechanism."

Coupland D58,276/63: "No evidence has been adduced to support the suggestion that chromaffin cells occur at the periphery of the body—particularly in the integument."

Adams-Ray E37,378/64: Using fluorescence microscopic techniques, it is possible to demonstrate in various species cutaneous MCs which contain catecholamines.

Falck et al. G19,000/64: Cells, whose chromaffinity derives from stored dopamine, occur widely distributed in the tissues of ruminants. This cell system has now been studied by a fluorescence method highly sensitive and specific for catecholamines and 5–HT. Cells with an intense green granular fluorescence, typical for primary catecholamines, were found in all tissues of the cow and sheep. Their distribution corresponded with the occurrence of dopamine, but not with that of noradrenaline. "The fluorescent cells had the typical morphology, distributional pattern and staining properties of mast cells and must thus be considered to be such."

LIPIDS

(Reviews on lipid granules in MCs: *Lehner* D27,094/24, *p. 139*; *Michels* C72,066/38, *p. 315; Arvy* D26,724/55, *pp. 64, 65; Padawer* D30,194/57, *p. 697; Kelsall & Crabb* D26,076/59, *p. 67*).

Unna D31,522/1887: MCs in miliaria vesicles may contain fat granules which stain with osmium.

Lombardo D39,600/06: Lipid granules stainable with Sudan III and osmic acid are demonstrable in human MCs even during embryonic life but they become more numerous in aging individuals. Such lipid-containing MCs have also been found in the rat but not in the cat.

Huguenin D27,303/12: Lipid-containing (ether, alcohol, and acetone soluble, acetic acid insoluble, sudanophilic but not Nile blue tingible) granules were observed in the MCs of the uterus of a 1½ year-old child who died suddenly from status thymicolymphaticus.

Ciaccio D26,438/13: Lipids cannot be demonstrated in normal MCs by the usual techniques but they appear in MCs situated within chronically inflamed tissues, both in man and in animals. They are designated as "Mastlipoidzellen."

Arnold D29,582/13: Occasional lipid granules are found in the MCs of various species.

Brugnatelli 46,135/14: Many of the MCs in the human mammary gland contain lipid granules in addition to their typical metachromatic granules.

Gruber D27,100/24: In the human mammary gland, there are MCs which, in addition to metachromatic granules, also contain lipid droplets.

Tuma D27,638/28: The MCs of the rat mammary gland contain lipids stainable with Sudan III, Scharlach R and Nile blue.

Nagayo D26,871/28: No lipids could be found in the MCs of various species.

Grassi D47,550/34: Lipid granules are found in normal MCs but even more regularly in MCs of pathologic tissue, e.g., in leprosy, tertiary syphilis, and tumors of the nipples.

Wislocki & Dempsey D27,437/46: The MCs of the rat contain no sudanophilic material, while in those of man, lipid droplets are sometimes found in the peripheral part of the cytoplasm.

Paff et al. D27,729/47: Normal and neoplastic MCs of the dog contain lipids.

Montagna & Noback D26,642/47: Although lipids cannot be demonstrated with Sudan IV in the MCs of the rat, when Sudan black B is applied to frozen sections of tissues fixed in formol calcium-cadmium, black granules are demonstrable in the cytoplasm of the MCs. The granules resist dissolving with the usual fat solvents and may represent phospholipids.

Montagna & Noback D26,717/48: The MCs of man, dog, hamster, rat, and mouse contain lipid substances stainable by Sudan black and positive to the Baker acid-hematin test. They are presumably phospholipids.

Rheingold & Wislocki D39,650/48: Human bone-marrow MCs contain fine, Sudan-black positive granules.

Wislocki & Fawcett D30,373/51: In the rat mesentery, the MC granules consist of an intensely metachromatic central core coated by material which stains with Sudan black B.

Berg D27,523/51: Brief mention of masked lipids in MCs.

Compton B90,594/52: In the hamster "the majority of mast cells treated with Sudan black B for 7 minutes do not stain; however, many mast cells near fat cells contain positive granules."

Zitcer D26,964/53: In MCs from an infant with urticaria pigmentosa cultivated in vitro, Scharlach R-positive lipid granules could not be seen.

Astaldi et al. D39,597/54: The MCs of the human bone marrow contain no histochemically-demonstrable lipids.

Rondanelli D26,656/55: No lipids can be demonstrated in human MCs with the Sudan black B reaction.

Nepriakhin D26,879/56: The MCs contain no histologically-demonstrable lipids.

Horváth C71,332/59: Judged by their histochemical behavior, the MC granules in the subcutaneous tissue and mesentery of the rat appear to be surrounded by a layer of fat-like substances.

Spicer D58,289/63: MCs are particularly numerous in the vicinity of siderophages and lipophages in various tissues (lymph nodes, uterus, mammary gland, stomach, and intestine) of various species (mouse, rat, hamster, guinea-pig, rabbit).

Padawer D58,275/63: Rat peritoneal MCs stain with Sudan black B but this "does not indicate necessarily that lipid is present, since the preparation subsequently can withstand dehydration and clearing in fat solvents as well as mounting in resin. Phosphatides, however, also survive such treatments, and they too stain with Sudan black B."

Feagler & McManus G19,927/64: In the rat, Sudan black B alone stains the MCs only faintly, but when PAS and Sudan black are used together, the MC granules are intensely blackened.

Trautwein & Stöber D97,999/65: No lipids could be demonstrated by Sudan black in the MCs of cattle mastocytosis.

GLYCOGEN

(Reviews on glycogen in MCs: *Lehner* D27,094/24, *p. 140; Arvy* D26,724/55, *pp. 64, 65; Nepriakhin* D26,879/56).

Huguenin D27,303/12: No glycogen could be detected in human MCs.

Nagayo D26,871/28: The MCs of various species contain no glycogen.

Wislocki & Dempsey D27,437/46: The MCs of the rat contain no stainable glycogen.

Rheingold & Wislocki D39,650/48: Human bone-marrow MCs contain no glycogen.

Nepriakhin D26,879/56: The MCs contain no histologically-demonstrable glycogen.

Trautwein & Stöber D97,999/in press: Glycogen granules could be demonstrated in the MCs of cattle mastocytosis lesions (PAS controlled by diastase digestion).

AMYLOID

Nagayo D26,871/28: The MCs of various species contain no amyloid.

IRON

Asboe-Hansen D39,743/50: Two cases of urticaria pigmentosa haemorrhagica, with the accumulation of melanotic and iron pigment in the skin, are described. The hemorrhages may have been related to heparin production by the MCs.

Dunn D27,626/54: MCs and siderophages are increased in the lymph-node hili of aged mice.

Padawer D64,997/54: No iron could be demonstrated in the peritoneal MCs of various species by histochemical means.

Nepriakhin D26,879/56: The MCs contain no histologically-demonstrable iron.

Velican & Velican D20,431/58: Iron and carbon particles can be detected in the MCs of tracheobronchial lymph nodes in man.

Spicer C92,580/60: In aged mice, MCs are often closely associated with iron and lipofuscin-laden macrophages in many organs. "It is possible that mast cells phagocytize iron or lipid or that, alternatively, heparin functions in some manner to influence phagocytic processes."

Spicer D58,289/63: MCs are particularly numerous in the vicinity of siderophages and lipophages in several tissues (lymph nodes, uterus, mammary gland, stomach, and intestine) of various species (mouse, rat, hamster, guinea-pig, rabbit).

Padawer D58,275/63: Upon microincineration, the MC granules leave abundant ash, and on theoretical grounds the presence of iron is suspected.

Hall F1,129/64: In the uterus of the mouse, there are many siderophil macrophages, usually in close association with MCs. Some of the MCs themselves gave a positive Schmorl reaction.

CALCIUM

Padawer D64,997/54: No calcium could be demonstrated by histochemical means in the peritoneal MCs of various species.

Nepriakhin D26,879/56: The MCs contain no histologically-demonstrable calcium.

Padawer D58,275/63: Upon microincineration, the MC granules leave abundant ash, and on theoretical grounds the presence of calcium is suspected but not proved.

MAGNESIUM

Padawer D58,275/63: Upon microincineration, the MC granules leave abundant ash, and on theoretical grounds, the presence of magnesium is suspected.

ZINC

Amann E37,264/62: Zinc can be demonstrated in the MCs of the mesentery in rats and guinea-pigs by the use of the dithizone reagent. The metal is thought to be part of protein-enzymes or of a histamine-zinc complex.

CHLORIDES

Arvy D26,724/55, *pp. 64, 65*: Discussion.

ENZYMES IN GENERAL

(Reviews: *Arvy* D26,724/55, *pp. 64, 65; Kelsall & Crabb* D26,076/59, *p. 66; Schauer* E4,510/64).

OXIDASE, PEROXIDASE

(Review: *Michels* C72,066/38, *p. 321.*)

Klausner & Kreibich D27,434/13: Blood basophils do, while tissue MCs do not give oxidase and peroxidase reactions.

Nakajima D39,782/28: Oxidase and peroxidase-positive granules are frequently seen in MCs of various animal species.

Stockinger D65,522/28: An oxidase can be demonstrated in the MCs of the mouse.

Nagayo D26,871/28: Both oxidase and peroxidase can be detected in the MCs of various animal species.

Tokué D26,880/28–29: The blood MCs of all animal species examined, including man, do not give histochemical reactions for oxidase or peroxidase. Only the guinea-pig blood basophils contain oxidase, though even they possess no peroxidase. These results "make very doubtful the alleged essential difference of the blood mast cell and the histogenous cell concerning both the oxidase and the peroxidase reactions."

Doan & Reinhart D26,488/41: The MCs of both blood and tissue are oxidase-negative.

Noback & Montagna 95,640/46: Detailed studies on the MCs in the preputial glands and the mesentery of female rats led to the conclusion that the cytochrome C-cytochrome oxidase system is evident in granules which are probably associated with MC granules.

Paff et al. D27,729/47: Both normal and neoplastic MCs of the dog contain cytochrome oxidase in their cytoplasm but not in the nucleus.

Montagna & Noback D26,717/48: The MCs of man, dog, hamster, rat, and mouse contain thermostable peroxidase and a "stabile" cytochrome oxidase (pseudoperoxidase).

Hopf D30,201/52: The MCs in the human umbilical cord give no histochemical reaction for oxidase.

Compton B90,594/52: Hamster MCs do not stain with M or G Nadi reagents for oxidases.

Lennert & Schubert D33,718/61: Unlike blood basophils, tissue MCs of human bone marrow never give a positive peroxidase reaction.

Schauer E4,510/64: Intense activity of various typical mitochondrial enzymes such as diaphorases, dehydrogenases, and mono-aminoxydases are demonstrable by histochemical means in murine mastocytoma cells.

Trautwein & Stöber D97,999/65: No peroxydase-positive granules could be found in the MCs in cattle mastocytosis.

REDUCTASE

Arvy C41,778/56: The MCs of the frog transform neotetrazolium into formazon and, hence, are thought to contain a reductase.

ESTERASES IN GENERAL

Gomori D28,363/53: "α-Chloracyl esters of α-naphthol and of naphthol AS are hydrolyzed by mast cells and myeloid elements at a much faster rate than the corresponding regular acyl esters. The enzyme responsible for their hydrolysis is not a cholinesterase."

Eder & Schauer D33,687/61: Nonspecific esterase (substrate-α-naphthylacetate) activity is not demonstrable in the MCs of the rat, mouse, hamster, and guinea-pig, but weakly-positive responses are obtained in human MCs.

Lennert & Schubert D33,718/61: Nonspecific esterase is plentiful in the blood basophils and tissue MCs of human bone marrow.

Keller D33,742/62: In isolated rat peritoneal MCs, the "detection of non-specific esterase is unsuccessful or unsatisfactory with the substrates α-naphthylacetate and naphthol-AS-D-chloroacetate. On the other hand, the use of naphthol-AS-acetate or 5-bromoindoxylacetate results in an intensive staining which is clearly localized in the granules of the mast cells." This activity is not influenced by incubation with eserine or paraoxon unless these compounds are added in very high concentrations. Copper sulfate, lead nitrate, silver nitrate and β-phenylpropionic acid are also inhibitory. "Histochemically the enzyme thus appears to be a non-specific organophosphate-resistant esterase. In so far as comparative experiments are available, its properties are identical with those of the enzyme responsible for the anaphylactic release of histamine."

Keller E38,771/63: The anaphylactic release of histamine from isolated rat peritoneal MCs is inhibited by various substances. This inhibition does not run parallel with the histochemically-demonstrable chymotrypsin-type esterase present in the MCs.

Leder E76,509/64: Development of a technique which permits the demonstration of naphthol-AS-D-chloroacetate-esterase on formalin-fixed paraffin sections.

Schauer E4,510/64: Histochemical demonstration of nonspecific esterase in the MCs of various species.

Trautwein & Stöber D97,999/65: A nonspecific esterase (demonstrated by the naphthol-AS-D-chloroacetate technique) in the MCs in cattle mastocytosis.

LIPASE

Noback & Montagna 95,640/46: Detailed studies on the MCs in the preputial glands and the mesentery of female rats led to the conclusion that here there is no lipase (nor is there stainable glycogen, fat, or iron).

Montagna & Noback D26,717/48: The MCs of man, dog, hamster, rat, and mouse contain lipase.

PHOSPHATASE

Wislocki & Dempsey D27,437/46: The MCs of the rat contain phosphatase.

Noback & Montagna 95,640/46: Detailed studies on the MCs in the preputial glands and the mesentery of female rats led to the conclusion that alkaline phosphatase occurs in small foci, presumably localized in MC granules. Acid phosphatase is present only occasionally.

Montagna & Noback D26,642/47: Both acid and alkaline phosphatase are demonstrable in MCs of the rat.

Paff et al. D27,729/47: Normal and neoplastic MCs of the dog contain both alkaline and acid phosphatase, not only in their cytoplasm but also in their nucleus.

Montagna & Noback D26,717/48: The MCs of man, dog, hamster, rat, and mouse contain acid and alkaline phosphatase.

Rheingold & Wislocki D39,650/48: The granules of human bone-marrow MCs contain both acid and alkaline phosphatase but the nucleus is free of these substances.

Riley & Drennan D26,775/49: Using the Gomori technique for alkaline phosphatase, granules of the enzyme were found only in the MCs of the mouse and rat, not in those of man, cat, dog, horse, rabbit, guinea-pig, mole, fowl, frog, axolotl, and brown trout. Even in the mouse and rat, only a small proportion of the MCs contained granules of the enzyme and these cells were chiefly near capillaries. No alkaline phosphatase was found in the free metachromatic substance.

Wislocki & Fawcett D30,373/51: Both acid and alkaline phosphatase could be demonstrated in rat mesenteric MCs.

Arvy D65,694/55: No acid phosphatase could be demonstrated in the lingual MCs of the frog *Rana esculenta.*

Eder & Schauer D33,687/61: Acid phosphomonoesterase activity is demonstrable in the MCs of the rat, hamster, and mouse, but not in those of the guinea-pig and man. Alkaline phosphatase activity is very weak in the rat and mouse, stronger in the hamster and absent in the guinea-pig MCs.

Lennert & Schubert D33,718/61: Ample amounts of acid phosphatase are demonstrable in blood and tissue MCs of human bone marrow while alkaline phosphatase is absent.

Schauer & Eder D30,202/62: Acid phosphatase can readily be demonstrated both in late fetal and in postnatal MCs of the rat, using either the Gomori or the diazonium method. It is very doubtful, on the other hand, whether MCs also contain alkaline phosphatase.

Trautwein & Stöber D97,999/65: Acid phosphatase can be demonstrated in some of the MCs in cattle mastocytosis but alkaline phosphatase is not found.

ATP-ASE

Eder & Schauer D33,687/61: ATP-ase activity is very strong in the MCs of the rat, hamster, mouse, and man, but weak (though definitely positive) in those of the guinea-pig.

Schauer & Eder D764/61: The MCs of the rat, hamster, and mouse are especially rich in ATP-ase. "The fact that histamine can be bound to the ATP of mast cells, assumes a special significance in view of the demonstration of strong ATP-ase activity in mast cells and of the finding that the incorporation of sulfate groups into heparin necessitates the presence of considerable amounts of ATP."

Schauer & Eder D30,202/62: ATP-ase can be demonstrated histochemically in late fetal and postnatal MCs of the rat. The reactive areas correspond to the metachromatic granules.

Keller D33,742/62; *Schauer* E4,510/64: ATP-ase in histochemically demonstrable in isolated rat peritoneal MCs.

HISTIDINE DECARBOXYLASE

Schayer D27,727/56: "Suspensions of the cells of rat peritoneal fluid have a marked ability to decarboxylate C^{14} L-histidine and bind the resulting histamine in stable form. The evidence is strong that this activity is due almost entirely to mast cells. . . . Disruption of the mast cells results in a considerable loss in histamine forming activity."

Rothschild & Schayer C76,258/59: The histidine decarboxylase activity in the peritoneal fluid of rats is almost entirely associated with the MCs. This is of interest since histidine decarboxylase plays an important role in the production of histamine in vivo.

5–HTP-DECARBOXYLASE

Lagunoff & Benditt C68,450/59: In the isolated peritoneal MCs of the rat, 5-hydroxytryptophan-decarboxylase could be demonstrated. The presence of this enzyme suggests that the MCs of the rat can synthesize 5–HT.

LEUCINEAMINOPEPTIDASE

Braun-Falco & Salfeld D39,714/59: Leucineaminopeptidase is present in rat peritoneal MCs and is discharged from them when they are disrupted by distilled water.

Stolk D39,816/60: Leucineaminopeptidase is demonstrable histochemically in the mesenteric MCs of the carp (*Cyprinus carpio*).

Stolk D39,817/60: "The cutaneous mast cells of the precancerous skin (carcinoma planocellulare) in the lizard (*Lacerta agilis L.*) showed a positive leucineaminopeptidase activity."

Eder & Schauer D33,687/61: The MCs of the rat, hamster, mouse, and man are extraordinarily rich while those of the guinea-pig are poor in leucylaminopeptidase.

Schauer & Eder D30,202/62: Beginning on the 17th day of embryonic life, leucylaminopeptidase can be demonstrated histochemically in rat MCs in close association with the granules.

Keller D33,742/62: Leucineaminopeptidase can be demonstrated in isolated rat peritoneal MCs.

Schauer D62,962/63: Leucylaminopeptidase could be demonstrated histochemically in rat mesenteric MCs.

TRYPSIN, CHYMOTRYPSIN AND OTHER PROTEASES

Benditt & Arase D26,709/59: The peritoneal MCs of the rat contain an enzyme which hydrolyzes 3-chloroacetoxy-2-naphthoic acid anilide, and which possesses properties similar to those of chymotrypsin. "This constituent of mast cells must rank in functional importance with heparin, histamine, and the other potent agents now identified in these cells."

Glenner & Cohen D26,769/60: A trypsin-like enzyme can be demonstrated histochemically in the MCs of dog and man, but not in those of rat, rabbit, guinea-pig, and mouse. "The physiological function of this trypsin-like enzyme in mast cells of certain species is not known, but it may possibly act to liberate secretory granule substance."

Glenner et al. G5,260/62: A trypsin-like esterase can be demonstrated histochemically in the MCs of various species. It catalyzes the hydrolysis of -aminocaproic acid naphthol-AS esters.

Hopsu & Glenner D69,723/63: A histochemical enzyme kinetic system "as applied to trypsin-like esterase and amidase activities in human mast cells indicates that a single enzyme or closely related enzymes in this site are responsible for the hydrolysis of both the amide and ester substrates and that typical trypsin substrates act as competitive inhibitors of their hydrolysis."

Kwaan G17,226/64: Rat connective tissue and peritoneal MCs contain little fibrinolytic activity (plasminogen activator) as judged by histochemical studies, although they do contain definite proteolytic activity. There is a close correlation between the localization of plasminogen activator and the presence of small blood vessels which are often surrounded by MCs. However, plasminogen activator is concentrated around small vessels, independently of the presence or absence of MCs. It is considered unlikely therefore, that the MCs provide the vessels with fibrinolytic enzyme, and the high fibrinolytic activity of certain tissues rich in MCs is more probably due to the fact that MCs in small blood vessels rich in plasminogen activator occur together in tissues.

β-GLUCURONIDASE

Montagna D28,264/57: The MCs in human skin contain much β-glucuronidase.

Eder & Schauer D33,687/61: β-glucuronidase activity could be demonstrated in the MCs of the rat, mouse, hamster, and guinea-pig.

Schauer & Eder D30,202/62; *Schauer* E4,510/64: β-glucuronidase is demonstrable in close association with the metachromatic granules in rat MCs beginning just before birth and continuing during postnatal life.

β-HYDROXYBUTYRIC ACID DEHYDROGENASE

Eder & Schauer D33,687/61; *Schauer* E4,510/64: β-hydroxybutyric acid dehydrogenase activity could not be demonstrated in the mesenteric MCs of the rat, mouse, hamster, and guinea-pig.

SUCCINIC DEHYDROGENASE

Trautwein & Stöber D97,999/65: Both succinic dehydrogenase and lactate dehydrogenase can be demonstrated in the MCs of cattle mastocytosis infiltrates.

DPN-DIAPHORASE

Eder & Schauer D33,687/61; *Schauer* E4,510/64: DPN-diaphorase activity could not be demonstrated in the MCs of the rat, mouse, hamster, or guinea-pig mesentery.

VARIOUS OTHER COMPOUNDS

Campani & Benassi D5,729/50: No *RNA* could be demonstrated histochemically in the metachromatic granules of rat peritoneal MCs.

Eder & Schauer D33,687/61: In the MCs of the rat, mouse, hamster, and guinea-pig mesentery, it was not possible to demonstrate by histochemical means the presence of *lactic acid, isocitric acid, ethanol, glutamate, glucose-6-phosphate,* or *malic acid.*

Crespi & Celestino E38,732/64: In a canine mastocytoma there were DMAB-positive MCs. This reaction presumably indicates the presence of *tryptophan* or possibly *neuraminic acid,* both of which react positively with DMAB.

Trautwein & Stöber D97,999/65: Using the methyl-green pyronin method, *RNA* granules can be detected in the cytoplasm of MCs in cattle mastocytosis.

AUTORADIOGRAPHY

Autoradiographic techniques have proved their value in the study of MCs, especially in connection with the labeling of metachromatic granules by S^{35} and the detection of DNA-synthesis by tritiated thymidine.

Following administration of S^{35}-labeled sodium sulfate, the uptake of radiosulfur by the granules is quite selective and intense both in normal and in neoplastic MCs of various species. The process usually reaches a maximum after about 48 hours, thereafter declining very slowly during the next 1–3 weeks. Following administration of S^{35}, it is also possible to isolate labeled MC granules (by differential centrifugation) or labeled heparin (by extraction).

Tritiated thymidine has been used successfully to demonstrate mitosis in MCs because, owing to active DNA-synthesis, dividing nuclei become especially intensely labeled. However, as shown by this technique, mitotic divisions are rare in MCs. Tritiated cytidine, on the other hand, labels almost every intact MC but also other cells, without any great selectivity.

Review: *Baglioni* C16,539/54, *p. 202*

Jorpes et al. D26,754/53: Following s.c. injection of S^{35}-labeled sodium sulfate, S^{35} can be demonstrated in the cutaneous MCs of the rat by means of stripping-film autoradiography. A maximum uptake is found 48 hours after the injection and the decrease after this is fairly small, up to 18 days later.

Boström et al. D65,096/53: The cutaneous MCs of the rat readily take up S^{35}-labeled sodium sulfate.

Asboe-Hansen B85,960/53: "Stripping film autoradiography of connective tissue in experimental skin tumors in mice injected i.p. with S^{35}, with sodium sulfate as carrier, showed that the majority of the mast cells take up sulfur."

Bélanger D65,099/54: The connective-tissue MCs of the rat readily take up radiosulfur.

Magnusson & Larsson D26,475/55: Heparin has been obtained from a dog mastocytoma and it was shown that the sulfuric-acid groups of this heparin can be labeled with S^{35}.

Higginbotham et al. D15,838/56: Sheets of loose subcutaneous connective tissue were stripped from the skin of freshly-killed mice by applying the connective-tissue surface of the skins to a freezing surface. This tissue was then scraped into an isotonic sucrose solution and the MC granules isolated by differential centrifugation. When prior to this procedure, $Na_2S^{35}O_4$ is injected i.p., radioactive MC granules can be obtained from the subcutaneous tissue.

Larsson E81,440/56: Canine mastocytomas avidly take up radiosulfur as shown by autoradiography.

Guidotti D65,255/57: Following radiosulfur administration, the autoradiographically determined S^{35}-uptake of the cutaneous MCs reaches the same maximum level in rats of different ages, but the rate of exchange is higher in younger than in older animals.

Asboe-Hansen et al. C61,920/57: Use of autoradiography for the demonstration of S^{35}-labeled sulfate uptake by MCs, around Rous fowl sarcoma transplants.

Watson & Kennedy D26,562/60: Following i.p. injection of S^{35}-labeled sodium sulfate, the utilization of S^{35} can be estimated on autoradiograms in two ways: "(*a*) Low power examination of coarse grain films and rough assessment of the cluster of activity over the whole

spread on a scale 0 to 4+; (*b*) counting 50 mast cells in each fine grain preparation and noting how many showed S^{35} uptake."

Stutzman et al. C95,789/60: In a case of mastocytoma, traces of S^{35} were incorporated into MCs, as shown by autoradiography.

Lagunoff et al. D26,885/60: Studies on peritoneal rat MCs, collected on Millipore filters, showed that "following a single intravenous injection of $S^{35}O_4$, rat peritoneal mast cells take up the radioactivity; the maximum is reached by 48 hours. No loss of radioactivity is evident in the following 5 days. Radioactivity in other free cells of peritoneal fluid attains a maximum at 4 hours and then falls rapidly to low levels."

Ringertz D67,467/60: In vitro studies on murine mastocytomas revealed that "the incorporation of S^{35}-sulphate was higher into those tumour polysaccharides, which were poor in sulphate than into those which were already rich in sulphate."

Padawer D26,701/61: Rat peritoneal MCs were incubated with tritiated L-histidine, cytidine, and thymidine. With histidine, most of the labeled grains were located over the cytoplasm of the cell but even the relatively high resolution available with tritium was not sufficient to show whether the intergranular cytoplasm or the granules themselves were involved. With cytidine, almost every intact MC became appreciably labeled as did virtually all the other peritoneal fluid cells. With thymidine, however, only a few cells of any type became labeled, and the proportion of labeled MCs was low. Eosinophils were completely free of label. Loose granules were not labeled with histidine, cytidine, or thymidine.

Walker D27,899/61: Using tritiated thymidine for the detection of DNA synthesis in MCs with aldehyde-fuchsin as a counter stain, counts of nonradioactive and radioactive MCs have been made in the connective tissues of the mouse. Radioactive MCs were rare, regardless of the time interval between repeated tritiated thymidine injections, while radioactive fibrocytes, macrophages, neutrophils, lymphocytes, and plasma cells were plentiful. "The mast-cell population sampled in this work was obviously very stable in terms of cell turn-over."

Allen D26,855/62: Description of a technique for the autoradiographic study of MCs in rat mesentery by labeling with tritiated thymidine.

Roth et al. E34,000/63: Following treatment with S^{35} sulfate, autoradiographs of the rat lung and skin show the incorporation of sulfate into MC granules. Compound 48/80 causes discharge of the marked MC granules followed by an increased incorporation of radioactive sulfate.

Sacerdote & Pennisi G12,876/64: The peritoneal MCs of *Triturus cristatus* readily take up S^{35} sulfate.

LIGHT-MICROSCOPIC CYTOLOGY

The MC does not lend itself well to the exploration of its cytology with the light microscope because the abundant metachromatic granules tend to obscure details of cytoplasmic structure; indeed, sometimes they make it impossible to see even the nucleus. Using techniques which leave the metachromatic granules unstained or only slightly stained, it has nevertheless been possible to establish a few basic facts concerning the cytology of the MC; additional pertinent observations were made on MCs artificially depleted of their granules and on immature cells which had not yet formed many granules. Still, the early cytologic studies on MCs have become largely obsolete in view of the data subsequently revealed by the electron-microscope (which will be discussed in the next chapter) and by histochemistry (dealt with in the preceding pages). Hence, it will suffice here to mention a few of the salient results of light microscopy mainly because of their historic interest.

Even the earliest investigators realized that as a rule the MC possesses a single roundish or slightly oval *nucleus,* although occasionally one does find a binucleated MC. The *centriole* and the *Golgi apparatus* are rarely evident under the light microscope but with suitable methods it is usually possible to demonstrate a few roundish *mitochondria* between the *metachromatic granules*. The latter are of course always

easily demonstrable, especially by metachromatic dyes. There is still some uncertainty concerning the hyaluronic-acid content of the metachromatic granules since some of them are, while others are not, destroyed by hyaluronidase. Judged by their differential staining with various dyes, the metachromatic granules of different MCs, and even those within the same cell, do not appear to be of uniform chemical constitution. Sometimes, the light microscope also reveals *pigment* granules within the cytoplasm of MCs and, as we have seen before, the MCs can take up a variety of *foreign materials* (such as lipids or metals) through the process of mastopexis.

Review: *Lehner* D27,094/24, *pp. 88, 139*

Compton B90,594/52: Construction of a very detailed and instructive table which summarizes the literature on the cytologic and cytochemical characteristics of MCs in various species.

NUCLEUS

Arnold D27,305/06: In the frog tongue, binucleated MCs are common.

Compton B90,594/52: Some of the hamster MCs contain a "cartwheel" nucleus, similar to that of plasma cells.

Velican & Velican D20,112/58: In human MCs, metachromatic material can be detected within the nucleus.

Lennert & Remmele D65,262/59: Karyometric studies on human MCs according to Jacobj's classification, show that "senile tissue mast cells have a peak at K ¼, but the majority of nuclei of young tissue mast cells belong to type K ⅜."

Allen D61,513/61: Binucleated MCs are common in the mesentery of the rat, especially during the first month of life.

Padawer D58,275/63: Review on binucleated MCs in various species.

CENTRIOLE

Lehner D27,094/24, *p. 139*: The centriole is rarely evident in MCs.

GOLGI APPARATUS

Compton B90,594/52: In the hamster, some MCs contain a small, circular Golgi apparatus.

Schauer D30,586/62: It has been assumed previously, on theoretic grounds, that the MC granules are formed within the Golgi apparatus (*Braunsteiner & Pakesch* D30,632/57). Electron-microscopic studies revealed close relationships between the granules and the Golgi field, but it was thought that the former develop through transformation from mitochondria (*Gusek* D39,516/60; D14,871/60; D12,407/61). The normal MCs of the adult mouse, rat or hamster exhibit no Golgi field although this is quite obvious in the MCs of mouse embryos just before birth, as well as in the cells of two types of mouse mastocytomas. In these cases, the MC granules are so closely associated with the Golgi apparatus that the formation of granules in this zone is considered to be very probable.

MITOCHONDRIA

Nagayo D26,871/28: A few round mitochondria can be demonstrated between the granules in the MCs of various species, by using either Altmann-Schridde's or Heidenhain's method.

Compton B90,594/52: Hamster MCs contain no, or exceedingly few, mitochondria.

Bloom et al. C12,081/56: Although it is difficult to see them with the light microscope, mitochondria are found in MCs as shown by electron-microscopic studies. They are usually densest within a zone immediately adjacent to the nucleus and are distinct from the secretion granules.

Barrnett et al. D27,610/58: On the basis of studies on mouse mastocytoma, fractions separated by centrifugation and checked for homogeneity by the ultramicroscope, it is concluded that "the granules bearing the histamine, heparin and 5-hydroxytryptamine, are morphologically as well as biochemically distinct from mitochondria."

GRANULES

(Reviews on specific granules of MCs: *Lehner* D27,094/24, *p. 140; Michels* C72,066/38 *p. 262; Kelsall & Crabb* D26,076/59, *p. 65.*)

Kreibich D27,585/16: Upon rubbing the rabbit's ear with stinging nettles (*urtica urens*), metachromatic MC granules are allegedly formed from *nuclear material* of MCs.

Nagayo D26,871/28: The MC granules of various species are "sometimes" tingible with mucicarmine, but otherwise their staining properties differ from those of other *"mucins"* in the body.

Bates D26,774/35: In an extensive study of the rat MC, no cells were encountered with *eosinophilic and basophilic granules intermingled,* such as had been described by some earlier investigators.

Caselli D26,830/45: While the cutaneous MCs of the rabbit are destroyed by hyaluronidase, those of man are not. Hence, the assumption that the MC granules contain *hyaluronic acid* and are important for the formation of ground substance, while possibly valid for the rabbit, cannot be extended to man.

Wislocki & Dempsey D27,437/46: The basophilic, metachromatic granules of the rat are not digested by either *ribonuclease* or *hyaluronidase.*

Julén et al. D26,818/50: On the basis of cytologic studies and differential centrifugation of suspensions of ox-liver-capsule MCs, it is concluded that the large MC granules do not contain *heparin* but presumably *protein, lipids,* and *enzymes.* They are basophilic. The easily water-soluble metachromatic and oxyphilic anticoagulant is thought to be located in the intergranular cytoplasm "and is provisionally regarded as a microsome structure." The anticoagulant is thought to be present as a heparin-protein complex.

Prakken & Woerdeman D26,813/52: The metachromasia of cutaneous MCs was not altered by *hyaluronidase* treatment in a variety of dermatoses associated with cutaneous mastocytosis.

Horváth D27,703/52: It is claimed that "the granules of mastocytes are *artifacts* produced by the influence of toluidine blue" because, by dark-field illumination in the native MCs of rat connective tissue, no corpuscular elements can be seen unless toluidine blue is added, in which case luminescent granules appear. [?(*H.S.*)]

Compton B90,594/52: Hamster MC granules do not include *hyaluronic acid;* they remain metachromatic after hydrolysis of the sections with hyaluronidase.

Lennert & Schubert D26,816/59: Among the bone-marrow MCs, there are some which stain with toluidine blue only at a high *p*H and are presumed to contain heparin, while others stain at a low *p*H and, since their granules are destroyed by hyaluronidase, they are thought to contain *hyaluronic acid* esters of low acidity.

PIGMENTS

(Reviews on MC pigments: *Lehner* D27,094/24, *p. 149*; *Michels* C72,066/38, *p. 318*; *Asboe-Hansen* D27,999/54; *Nepriakhin* D26,879/56.)

Staffel D33,661/08: The MCs in human skin may contain pigment granules and presumably participate in pigment formation.

Nepriakhin D26,879/56: The MCs of old people or old dogs may contain a yellow, natural pigment, readily visible on unstained sections under ordinary light.

ELECTRON MICROSCOPY

The results of early electron-microscopic studies on the structure of the MC were somewhat confusing and contradictory. This was partly due to imperfect techniques but partly also to the fact that the material for observation consisted of MCs derived

from different species, different portions of the body, cells in different stages of maturation or degranulation, and even of pathologic MCs from the cutaneous lesions of urticaria pigmentosa or mastocytomas. It is obvious that such a heterogeneous collection of material cannot serve as a basis for the establishment of the normal MC structure.

Modern electron-microscopy reveals that the MC does not differ essentially in its cytology from other cells except in the possession of the specific metachromatic granules. The typical MC has a mean diameter of about 15 μ when it is not provided with long pseudopodia. It usually contains a single, sometimes indented, nucleus, a comparatively poorly developed endoplasmic reticulum and Golgi apparatus, as well as relatively inconspicuous mitochondria. The latter are often adjacent to the nucleus. The nuclear and cell membranes appear to be double and the cell surface frequently exhibits villosities which appear to participate in the excretion of the specific granules. In mature MCs, these corpuscles occupy most of the cytoplasm and are enclosed within small vacuoles which tend to enlarge and even coalesce during degranulation.

Some of the specific MC granules are very electron-dense and of homogeneous or granular appearance but, presumably with increasing maturity, the granule contents rearrange themselves to form spiral lamellae which on cross section resemble fingerprints. In certain regions these lamellae tend to become very dense and assume the aspect of intragranular cylinders or "scrolls". Many of the granules contain small, strongly osmiophilic bodies and the lamellar structures are thought to consist of lipoproteins. The electron-microscopically identified specific granules can be separated by ultracentrifugation and, at least in mouse mastocytomas, they have been shown to contain histamine, heparin, and 5-hydroxytryptamine.

An attempt has been made to differentiate between two types of MCs: one spindle-shaped with comparatively small (0.5 μ) homogeneous granules which contain one or more centrally located dense bodies; the other ovoid or spherical with larger (0.75 μ) granules consisting of lamellar systems and scrolls. The spindle-shaped type, which is most common in the skin, is allegedly related to chromaffin cells and supposed to contain adrenaline and noradrenaline, but this interpretation is not generally accepted.

While some investigators believe that the specific granules develop from mitochondria, others think that they arise from the Golgi apparatus, the endoplasmic reticulum and the ground substance or even as a result of pinocytosis.

Reviews: *Bloom et al.* D26,753/55; *Smith & Lewis* D33,719/57; *Policard et al.* D26,749/60; *Gusek* D12,407/61; *Orfanos & Stüttgen* D32,154/62; *Thiéry* E39,146/63

Köksal C1,302/53: Early electron-histologic studies on human MCs.

Bloom & Friberg D26,647/53: Description of a technique for the electron-microscopic study of rat peritoneal MCs. The granules are, as a rule, completely electron-impermeable except when they take up water. In this case an intragranular structure can be observed which may represent the previously-postulated granule skeleton thought to consist of lipoprotein complexes.

Smith & Lewis C11,751/55: Electron micrographs reveal that the peritoneal MCs of the rat and hamster possess discrete, limiting, and nuclear membranes as well as mitochondria similar to those of other mammalian cells. The granules almost completely occupy the cytoplasm and show a delicate internal structure.

Bloom et al. D26,753/55: By electron microscopy, the MCs "are recognised by their typical granular appearance. Their shape varies from round to oval, their size around 10 microns. The nucleus is rather large and varies in shape from completely round to kidney-shaped, and sometimes a number of deep indentations are found. It is surrounded by a distinct nuclear membrane which reveals a typical double membrane structure. In the nucleus a network is observed which probably corresponds to the chromatine net. One or two nucleoli are generally present. The cytoplasm is completely filled with granules of a size varying around 0.7 microns." The mitochondria are generally located in the perinuclear zone and they have a typical inner structure with transverse double membranes as in other cells. In some MCs, large, seemingly empty vacuoles are found. A special feature is a great number of small filamentous, cytoplasmic protrusions on the surface of the MCs. They are about 0.6 μ long and 0.08 μ in thickness. [These observations made on dog mastocytomas may not necessarily reflect the normal structure of the MC (*H.S.*).]

Grey & Biesele D39,702/55: Brief description of the electron-microscopic appearance of the peritoneal basophils (MCs?) of the mouse.

Stoeckenius D27,740/56: Brief description of the electron microscopy of MCs from the human tonsil.

Rogers D27,741/56: Study of the cutaneous MCs of 3-day-old mice led to the conclusion that "the metachromatic granules are electron dense bodies which appear to be made up of filamentous material. Each granule has a dense periphery and is generally surrounded by a cytoplasmic space. In addition to the granules, the cytoplasm contains spherical and rod-like mitochondria of typical internal structure. Closely-packed Golgiform membranes are present in the cytoplasm together with small vesicular components but there is little or no endoplasmic reticulum contrasting with the situation found in the cytoplasm of fibroblasts."

Bloom et al. C12,081/56: Electron-microscopic studies based on material from MC tumors of dogs.

Bloom et al. C34,040/57: Observations show that the peritoneal MCs of the rat and hamster normally form vacuoles, most of which contain a single, small, specific granule. (As judged by phase-contrast microscopy, the latter exhibits lively Brownian movements.)

Smith & Lewis D33,719/57: The peritoneal MCs of rats and hamsters contain densely-packed cytoplasmic granules which possess a distinct boundary and an internal reticular or vacuolar structure. Between the granules are elongated mitochondria and the endoplasmic reticulum. Mitochondria are in the granule-free areas adjacent to the nucleus. The nuclear and cell membranes appear to be double. Upon treatment with toluidine blue, protamine sulfate, or stilbamidine, the granules are surrounded by clear areas and the endoplasmic reticulum becomes more conspicuous, but the internal structure of the granule remains unchanged. Upon X-irradiation, the granules tend to coalesce.

Bloom et al. D39,809/58: Electron microscopy of dog mastocytoma tissue.

Burton & Bensley D33,750/58: Observations on mouse MCs suggest that the specific granules develop as vesicles by pinocytosis. These increase in density within the cytoplasm, so that in any given cell the granules vary in size, density, and composition.

Hagen et al. C70,407/59: Studies of mouse mastocytoma cells, combined with ultracentrifugation and biochemical as well as bioassay analysis of its particles, led to the conclusion that: "Histamine, heparin and 5-hydroxytryptamine are contained within specific granules, which are clearly separable from mitochondria and other intracellular organelles."

Rhodin et al. D39,527/59: Observations on the so-called chromaffin cells of human skin suggest that they contain granules "that chemically and structurally are closer related to the chromaffin granules of the adrenal medullary head cells than to the granules of the mast cells." The close relationship of these cells to unmyelinated nerve fibers and smooth muscle cells suggests that they may "release some substance into the smooth muscle cell by impulses through the nerve fiber."

Hagihara D68,589/60: Study of rat MCs by electron-microscopy.

Hibbs et al. D26,893/60; D26,446/60: By electron microscopy, two types of MCs can be distinguished in the human skin and stomach. One, consisting of spindle-shaped cells, is found in large numbers, often around vessels, in the dermis and subcutis, and less frequently in the tunica propria and submucosa of the stomach. The granules of such cells measure about 0.5 μ and are nearly homogeneous, but some of them contain one or more centrally-located dense bodies. The second cell type consists of ovoid or spherical cells, scarce in the skin but more

numerous in the stomach wall. The granules of these cells measure about 0.75 μ and are made up of a finely granular substance and groups of lamellae, some of which form "scrolls" (*Fig. 4*).

Phillips et al. D26,570/60; C91,246/60; *Phillips & Hibbs* C84,241/60: At least two types of MCs can be distinguished by electron microscopy. One form has an oval shape and its granules are composed of subgranular, laminated, scroll-like bodies with a finely particulate substance filling the spaces between and within these bodies. The other type of cell is elongated and its granules contain an amorphous material enclosed by a membrane. It seems probable that the oval-type cell with its complex granules is the more classic form of tissue mast cell,

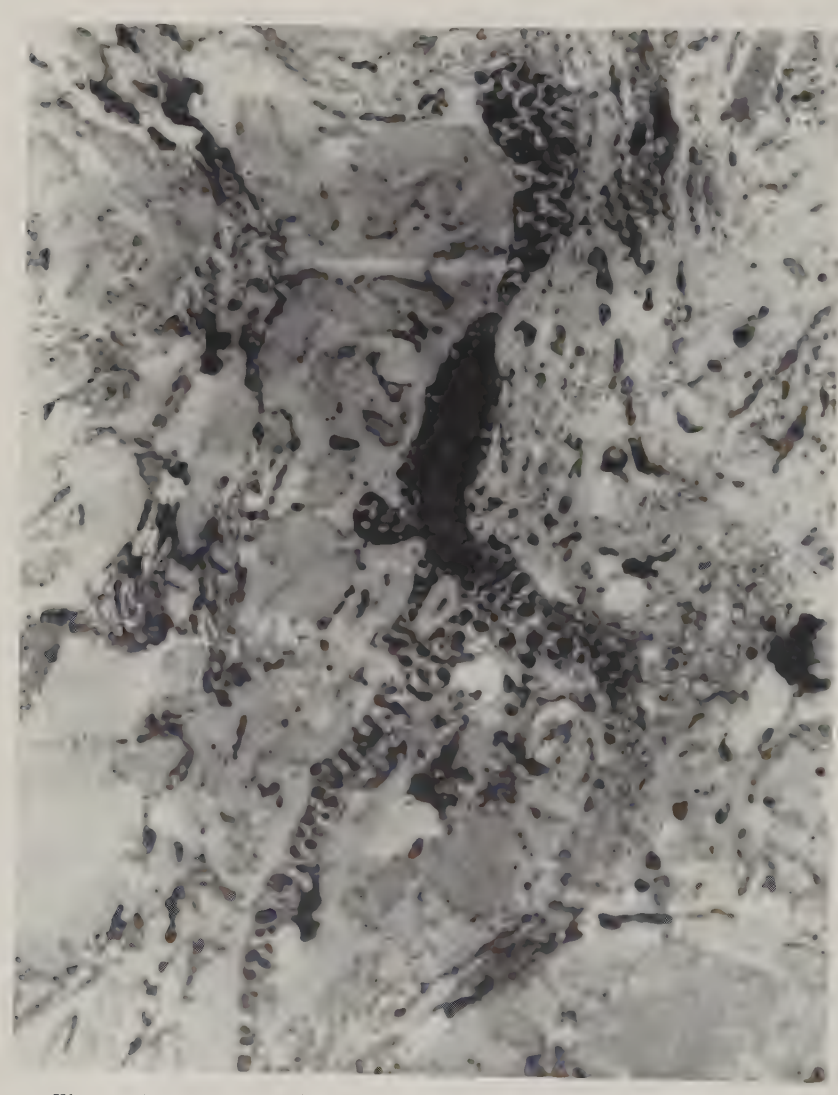

Figure 4.—A so-called "chromaffin mast cell" from the human dermis. Note characteristic elongated cell body with several processes. (X 4400.)
[After *Hibbs,* unpublished.]

while the elongated type with its rather simple granule is the so-called fibroblastic mast cell some or all of which may be chromaffin cells (containing adrenaline and noradrenaline). Both types of cells were found in the gastric material as well as the skin, although in the stomach the oval type of cell was more numerous than the elongated."

Policard et al. D26,749/60: Studies on the MCs of the human pleura as well as on the submaxillary gland, the omentum, and the lung of rats, in which aseptic inflammations were produced at these sites by injection of silica, lead to the conclusion that the MC does not possess a continuous cellular membrane. This fact may explain the ready extrusion of cellular material. Around each granule there develops a clear zone, "a kind of pseudovacuole", which may be important in the process of degranulation. The nucleus has the aspect of "a mass of degenerated proteinaceous material. It has no longer the morphologic aspect of an active nucleus. Indeed, one may ask whether often the classical mastocyte nucleus does not in reality represent a kind of cellular cadaver", a kind of "sac of heparin granules."

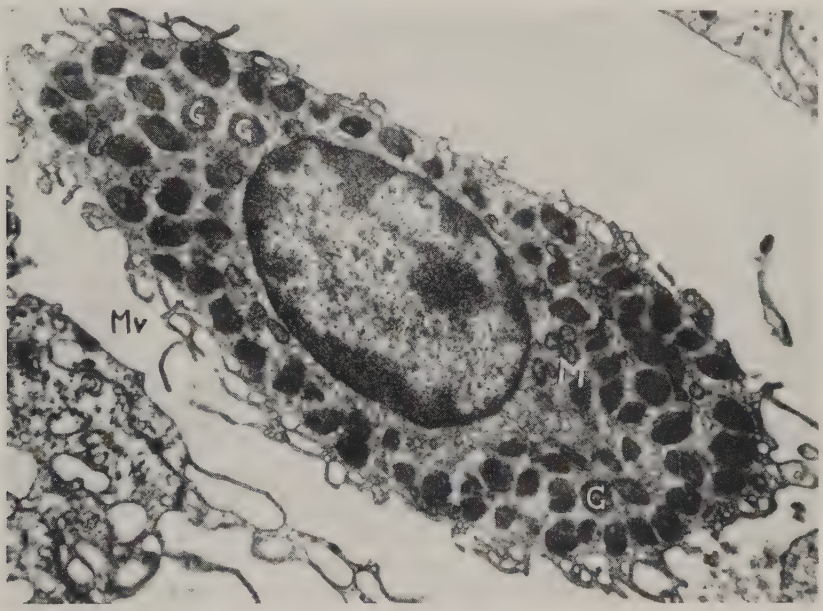

Figure 5.—Mast cell of man, from a meningioma. Oval nucleus with broad peripheral chromatin accumulations: mitochondria (*M*); granules (*G*); microvilli (*Mv*). (X 12,000.) [After *Gusek* D12,-407/61. Courtesy *Archiv für klinische und experimentelle Dermatologie.*]

Gusek D14,871/60: In mastocytoma tissue the specific metachromatic granules probably arise from mitochondria. In the karyoplasma, there are large electron-dense granules which appear to be extruded into the cytoplasm where they enter the structure of mitochondria and metachromatic granules.

Klug D27,650/61: "In the voluminous cytoplasma near the mitochondria with lamellar inner structure, several osmiophilic ball-shaped granules are located which have a diameter of 0.5–0.7 μ and are surrounded by a simple membrane. Single granules show clearly a structure of layers, others show a strongly osmiophilic body. The genesis of these granules is discussed. The endoplasmatic reticulum consists of numerous vesicular and lamellar structures."

Hagen D2,370/61: Excellent review concerning evidence obtained by electron microscopy and differential centrifugation, showing that the MC granules contain heparin, histamine, and 5–HT but are devoid of such characteristic mitochondrial enzymes as fumarase, amine oxidase, and succinic dihydrogenase. The reverse is true of mitochondria.

Gusek D39,516/60; D12,407/61: Studies on the MCs of the rat and of human mastocytomas show that these cells have an oval outline with numerous "micro villi" and an endoplasmic reticulum consisting of fine vesicles. Sometimes, there are vortex-shaped, double-lamellar systems which may consist of lipoproteins. The metachromatic granules appear to develop from mitochondria and, if granules are plentiful, mitochondria are scarce or absent. In the MCs of mastocytosis, there frequently is a large lamellar Golgi apparatus. Within the specific granules, one or two electron-dense, osmiophilic corpuscles, about 200 Å in diameter are frequently found (*Figs. 5* and *6*).

Orfanos & Stüttgen D32,154/62: Excellent description and illustration of the electron-microscopic structure of MCs in a patient with mastocytosis with special emphasis upon the changes induced by topical application of cold or 48/80. Discharge is initiated by a peripheral rarefaction of the granule which may be due to water uptake. Then, the granule material condensates and intragranular cylinders or scrolls are found.

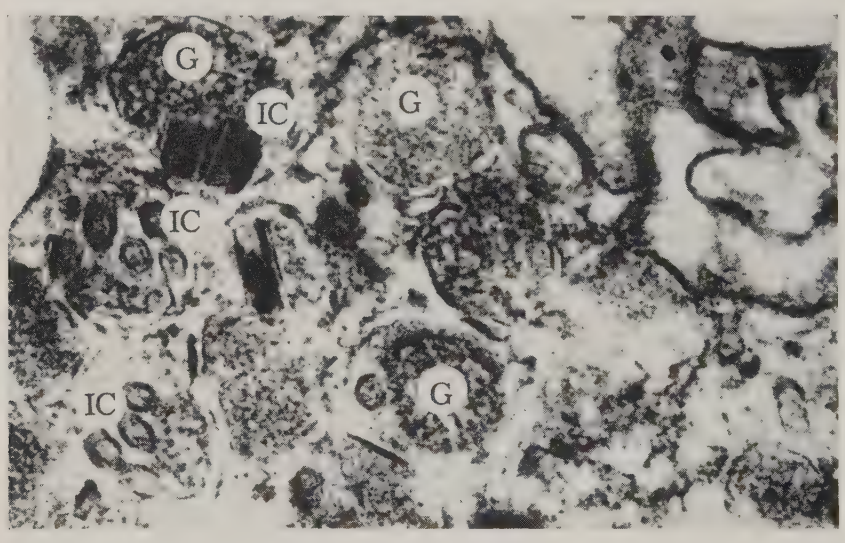

Figure 6.—Intragranular cylinders in a mast cell of a patient with mastocytosis. Some of the granules (*G*) contain characteristic intergranular cylinders (*IC*) sectioned transversally, obliquely, or longitudinally. They are assumed to be condensation products of intragranular lamellar systems. (One per cent OsO_4 Vestopal W embedding. Uranyl acetate. Siemens' Elmiscope I. X 45,000.) [After *Orfanos and Stüttgen* D32,154/62. Courtesy *Archiv für klinische und experimentelle Dermatologie.*]

Policard et al. D42,103/62: In the popliteal lymph nodes of guinea-pigs treated with antigens, the basophilic MC granules show periodic striations when examined with the electron microscope.

Smith D58,273/63: Brief review of the electron microscopy of normal MCs from various organs of the mouse, rat, and hamster.

Christensen et al. D64,073/63: Studies on a transplantable murine MC tumor revealed "a well-developed Golgi region; numerous ribosomes, free or attached to membranes; a highly organized endoplasmic reticulum; a smooth membrane-like inner surface in the lacunae which lodged the mast cell granules; mast cell granules located in the outer zone of the cytoplasm in most cells, but occasionally occupying the entire cell body and appearing as loose curls with all transitional stages to condensed, homogeneous material; long, slender protrusions projecting from the cell surface. From previous and present investigations, it is suggested that there may

be a direct connection from the interior of the mast cell through the channels of the endoplasmic reticulum to the lacunae, and from the lacunae during the release of the mast cell granules to the extracellular space. This system may reflect the synthesis of the tumor mast cell granules."

Sellyei & David E30,333/63: Studies on Furth's mastocytoma revealed that the specific granules arise from the ground substance and the canaliculi of the endoplasmic reticulum. The shrinking of the granules and their vesicular transformation were interpreted as secretory phenomena. These changes were further enhanced by treatment with protamine sulfate.

Thiéry E39,146/63: Studies on the MCs of various species, including man, revealed a lamellar and an amorphous component in mature granules. Discharge occurs through openings in the cell membrane (*Fig. 7*).

Fernando & Movat E28,375/63: The electron-microscopic structure of MCs from the cheek pouch and omentum of the hamster, the tongue of rats, the human female breast, and the skin of a case of urticaria pigmentosa lead to the following conclusions: "The metachromatic granules seen in the light microscope appear in electronmicrographs as dense granules of a finely or coarsely granular texture, which are not membrane bound and which have an average diameter of 0.5 μ. Ergastoplasm was not found in mast cells. Their Golgi apparatus is small; their mitochondria inconspicuous. In common with certain other mesenchymal cells, they have fingerlike or villous processes at the cell border. The granules probably develop in situ in the hyaloplasm. Some evidence of the dissolution of granules and their extrusion at the cell surface was encountered."

Kelényi & Gógl G19,262/63: The microvillous appearance of cell surface is typical of the neoplastic MCs in Furth mastocytomas. There is an inverse relationship between the numbers of mitochondria and granules and the latter are thought to have developed from the former.

Thiéry D5,220/64: Electron-microscopically, polysaccharides can be demonstrated on the lamellae of mature MC granules by a special silver nitrate-methenamine technique.

Ubukata D18,745/64: Electron-microscopic studies on murine mastocytoma cells suggest that the specific granules are formed in close relation to the Golgi apparatus.

IN-VIVO OBSERVATION

A number of techniques have been developed to study behavior of MCs in vivo. For this purpose, very thin membranes of tissue can be transilluminated and examined with the ordinary microscope under suitable conditions. Dark-field illumination in the ultramicroscope has also been recommended. However, the most successful procedures for the study of living MCs are based on vital staining, phase-contrast microscopy, and fluorescent microscopy combined with cinematographic observation (cf. *pp.* 66, 67, 69).

Niessing et al. D33,744/38–39: In the subcutaneous MCs of the mouse, it is possible to follow the detachment of comparatively large cytoplasmic portions (clasmatocytosis?) under dark-field illumination in the ultramicroscope.

Paff & Mergenthaler D27,516/55: For the study of rat mesenteric MCs in vivo, it is recommended to open the abdomen under Nembutal anesthesia and lay the mesentery over the raised portion of a lucite platform fitted to a mechanical stage of a binocular microscope, always maintaining isotonic conditions by bathing the specimen with Tyrode solution. Observation with the oil-immersion objective is possible without an intervening coverslip.

Burton & Bensley D33,750/58: The MCs of the iris can be observed in vivo in the mouse.

VITAL AND SUPRAVITAL STAINING

In thin membranous tissues (e.g., rat mesentery, hamster cheek-pouch, frog tongue or web, dog urinary bladder), MCs can be colored with vital or supravital stains. Basic aniline dyes stain MC granules metachromatically under these conditions, but vital and supravital metachromasia is not suitable for the identification of MC granules since, in living cells, various other structures stain the same way.

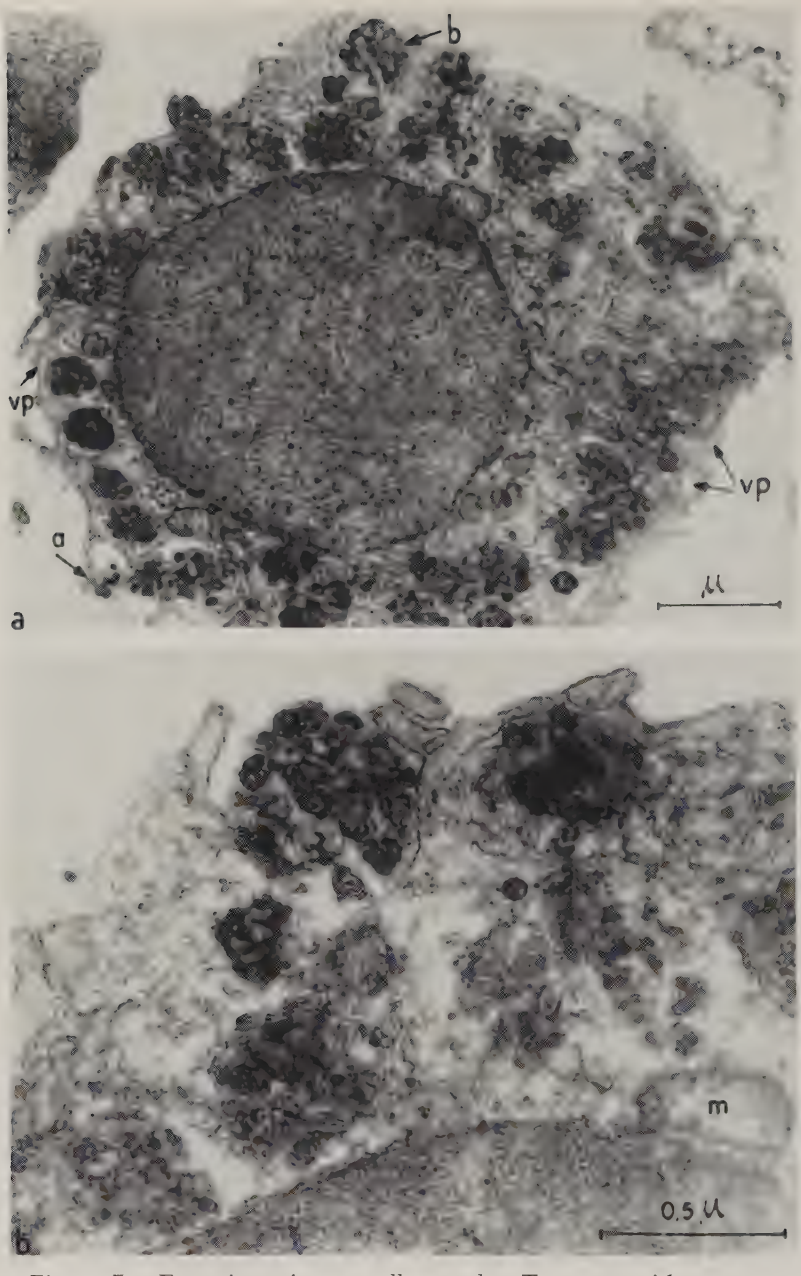

Figure 7.—Excretion of mast-cell granules. Top: MC with numerous mature granules. At *a* and *b*, excretion of two granules. The cell is active, emitting microvillae and exhibiting vesicles of micropinocytosis (*vp*). (X 16,000.) Bottom: Enlargement of the portion *b* of figure above. The cytoplasmic membrane is opened and the granules ready to be excreted. The two typical constituents (parallel or concentric lamellae and vacuolar gray substance) are readily recognizable. In the unchanged cytoplasm between the mature granules, mitochondria (*m*) and small vesicles are visible. (X 48,000.) [After *Thiéry* E39,146/63. Courtesy *Journal de Microscopie.*]

Furthermore, metachromatic dyes such as toluidine blue can cause MC disruption; hence, the action of other MC-dischargers cannot be adequately appraised on tissues stained in this manner during life.

Reviews: *Michels* C72,066/38
Arvy D26,724/55, *p. 58*

Lavdowsky D42,233/1895; *Arnold* D30,521/00: The MCs in the tongue, web, and mesentery of the frog can be stained vitally and supravitally with neutral red or methylene blue.

Wolff D27,718/02: Vitally-tingible MCs can be found in tuberculous exudates.

Arnold D30,522/03: The urinary bladder of the dog is an excellent test object for the study of MCs with vital or supravital stains. Methylene blue stains some of the living MCs blue, others metachromatically red.

Arnold D27,305/06: The MCs of the frog tongue can readily be stained metachromatically with methylene blue and polychrome methylene blue, vitally and supravitally. They also stain vitally with neutral red.

Pappenheim & Nakano D27,418/12: The tissue MCs of the spleen can be stained supravitally with neutral red and many basic dyes.

Nakajima D39,782/28: The MCs of various species failed to show vital staining with carmine or trypan blue.

Nagayo D26,871/28: The MCs of various species can be stained both vitally and supravitally by neutral red, but they do not store acid dyes such as carmine or trypan blue.

Dalcq D31,604/52: In the cleaving ovum of rodents, toluidine blue stains portions of the cytoplasm (presumably mitochondria) metachromatically in vivo. Similar metachromatic vital staining is demonstrable, for example, in the cells of the corona radiata in ovarian follicles, the oviduct, spermatic epithelium, reticuloendothelial cells, mucous and serous glandular epithelia, etc. No suggestions are made concerning possible relationships between such metachromatic granules and those found in MCs.

Grossfeld D26,727/54: MCs cannot be specifically identified by supravital metachromasia since intracellular granular metachromasia is a general phenomenon found in a variety of living cells in tissue culture. "In tissue culture cells, the appearance of intracellular granular metachromasia is evidence of cell viability and intracellular orthochromasia, one more criterion of cell death." It is thought that dye condensation, effected by an active process within the cell, is one possible factor in producing vital metachromasia.

Wegelius & Hjelmman C10,599/55: In the cheek-pouch of the hamster, the MCs stain metachromatically following local injection of toluidine blue. Under these circumstances, some metachromatic granules are also detectable in fibrocytes.

Wegelius et al. D27,732/55: The MCs in the hamster cheek-pouch can be studied in vivo, following staining with toluidine blue in dilutions of from 1:1,000 to 1:100,000 with the aid of water-immersion objectives.

Hjelmman & Pettersson D39,845/55: Technique for the vital staining of MCs in the abdominal musculature and mesentery of the rat, using water-immersion microscopy. Not only the MCs but even the fine granules in fibrocytes stain metachromatically with toluidine blue.

Paff & Mergenthaler D27,516/55: Living rat mesentery can be prepared for vital observation under high magnification with the "embroidery hoop technique." The embroidery hoops consist of two polyethylene rings which fit tightly into each other. The rat mesentery is spread over the smaller hoop and fixed in this position with the larger one. The preparation is then laid on a coverslip and sealed in a hollow-ground slide. Examination under oil immersion is possible if fat-free areas of mesentery are chosen.

Mergenthaler & Paff D27,407/56: Loops of rat mesentery were examined in vivo, on a specially-constructed stage by transillumination; then, the loops were returned into the peritoneum and the wound closed. After several days, the loops could be re-examined by the same technique and the disappearance and new appearance of individual MCs could be established after having "marked" the cells in a given field by the identification of their exact position. With this technique, the rate of MC disappearance and new MC formation could be roughly estimated, but the experiment is greatly complicated by the unavoidable repeated traumas.

Hjelmman D39,689/56: The MCs of the hamster cheek-pouch and of the rat mesentery can readily be observed by the use of vital stains.

Pettersson D7,232/56: Rat mesenteric MCs can be vitally stained with isotonic (4.8 %) aqueous toluidine blue and viewed on spreads of mesentery held between two interlocking plastic rings.

Gustafsson & Cronberg D26,757/59: Following a review of the literature concerning the use of toluidine blue as a vital stain for MCs, this technique is rejected because the dye itself can cause MC disruption.

Geiger et al. F11,948/64: Time-lapse motion pictures of murine mastocytoma cells in vitro. Vital staining of the granules can be effected by neutral red and Janus green.

PHASE-CONTRAST MICROSCOPY

(Cf. also CINEMATOGRAPHIC OBSERVATION, *p.* 69.)

Phase-contrast microscopy does not give as clear a picture of detail in MCs as can be obtained by special stains or, even better, by the electron microscope; it does, however, permit the examination of MCs in vivo under natural conditions without interference by dyes.

The formation of pseudopodia and their shedding by clasmatosis, the slight motility characteristic of the MCs, and the explosive discharge of their granules which are subsequently phagocytosed by histiocytes and eosinophils, are all processes especially well seen under the phase microscope.

Reviews: *Baglioni* C16,539/54, *p. 159*
Smith D63,031/63

Sylvén D65,265/50: Phase-contrast observations on living mesenteric mouse MCs permitted the clear distinction of the following cytoplasmic structures: "(a) Large spherical granules, (b) Diffusely scattered 'intergranular' amorphous cytoplasmic material, and (c) Areas of small interspersed 'clear' spaces, e.g., cytoplasmic vacuoles presenting maximum light transmission."

Zollinger D10,328/50: Phase microscopic examination of the peritoneal MCs of mice shows them to possess large, brilliant granules which contain heparin, since the same granules stain metachromatically with toluidine blue. In vitro, the granules immediately release heparin when suspended in distilled water and more slowly in contact with physiologic saline solution. The granular skeleton, which apparently consists of protein, remains. "It seems highly probable that the heparin-containing granules of mast cells represent a special form of mitochondria."

Compton B90,594/52: Under the phase microscope, the MCs of the hamster are easily recognizable. They contain a round, pale nucleus and highly refractile granules. Binucleate cells are rare. Vacuolation is also uncommon and probably an artifact. No evidence is found of degenerative changes associated with heparin secretion as previously postulated by others.

Paff & Mergenthaler D27,516/55: For phase-contrast microscopy "peritoneal fluid from anaesthetized rats was drawn into fine, blunt tipped glass tubing and placed on a 40 × 50 mm coverslip and covered by a second coverslip ⅞ inch square. This was then inverted over a previously prepared depression chamber consisting of a metal plate with a central hole (obtained from Wyble Engineering Development Corporation, Silver Spring, Md.) over which a 40 × 50 mm coverslip had been sealed and which contained a damp washer-shaped piece of filter paper and a drop of high viscosity immersion oil. This type of preparation can be set up in a few seconds." Using this technique, the presence of granule-containing vacuoles and granule-free tracts or "canals" could be verified in normal rat peritoneal MCs.

Bloom et al. C34,040/57: Electron-microscopic observations show that the peritoneal MCs of the rat and hamster normally form vacuoles, most of which contain a single, small, specific granule. As judged by phase-contrast microscopy, the latter exhibits lively Brownian movements.

Ottoson et al. D31,592/58: Judged by phase-contrast microscopy, the peritoneal MC of the rat is spherical and contains a central spherical nucleus. The density of the latter appears

to be less than that of the surrounding cytoplasm. Both by interference microscopy and by X-ray absorption measurements, the dry mass of MCs from the peritoneal cavity of the rat was found to be approximately 2.0 ± 0.1(g 10^{-10}). This was not altered by treatment with 48/80. "Thus it appears that 48/80 in vitro does not cause loss of dry mass from those mast cells which remain intact."

Policard & Collet D33,662/59: Observation of rat peritoneal MCs by phase-contrast microscopy and cinematographic registration of their movements shows perfectly spherical granules 0.5–0.7 μ in diameter, with an intergranular cytoplasm of filamentous and floccular aspect sometimes containing vacuoles. Mitochondria are not seen by this technique and the nucleus is indistinct. The cell diameter varies between 10 and 30 μ. Often, bizarre pseudopodia are formed whose outlines are always rounded, never angular. Sometimes small cytoplasmic fragments are detached and subsequently reunited with the main cell body (clasmatosis). Granules and vacuoles may be discharged individually or in groups. Spontaneous movements of MCs have not been seen, although internal rearrangements of cytoplasmic constituents are commonly observed. Individual granules are often explosively discharged and a vacuole of similar size remains in their place. The discharged granules are frequently phagocytosed by histiocytes or eosinophils.

Hagihara D68,589/60: Study of rat MCs by phase-contrast microscopy.

Keller & Schwarz-Speck D25,586/61: Phase-contrast studies on the disruption of rat MCs under the influence of immune serum.

FLUORESCENCE MICROSCOPY

Normally, MC granules do not show fluorescence but they do after treatment with certain fluorescent dyes and histamine-liberators, particularly trypaflavin and stilbamidine. Since under such circumstances the MC-discharger demonstrably accumulates within the MCs, its degranulating action has been assumed to be topical and direct. Using fluorescent antibody techniques, it is possible to show that immune bodies likewise accumulate in MCs when these discharge their granules in anaphylaxis.

Adrenaline, noradrenaline, histamine, and 5–HT, all form highly-fluorescent condensation products when treated with formaldehyde; since upon such treatment MCs also become fluorescent, this reaction has been recommended for the identification of these biogenic amines within MCs.

Haitinger E34,499/38: First recommendation of the fluorescence microscopic demonstration of MCs.

Hirt et al. D33,724/39: Following treatment with trypaflavin, the subcutaneous MCs of the mouse show red fluorescent granules which turn dark brown under ultraviolet light. The MCs also exhibit slow ameboid motion and, frequently, detachment of large portions of the cytoplasm (clasmatocytosis?). Heparin solutions show a fluorescence similar to that of the MC granules.

Noback & Montagna 95,640/46: Detailed studies on the MCs in the preputial glands and mesentery of female rats led to the conclusion that normal MCs do not fluoresce under ultraviolet light.

Riley B90,276/53: Stilbamidine (a fluorescent histamine-liberator), while causing an MC discharge, actually accumulates in many, though not in all, MCs. Riley's Type II MCs in the sex fat and mesentery do become fluorescent, while many toluidine-blue staining MCs in the subcutaneous connective tissue (Riley's Type I or Type II) do not.

Riley C69,692/58: Painting of the skin with 9,10-dimethyl,-1,2-benzanthracene in acetone causes a marked increase in the MC population of the dermis in the mouse. If such skin is treated with formaldehyde, there appears a brown fluorescent pigment which, judged by direct bioassay and chromatography, is the β-carboline of 5–HT.

Lagunoff et al. D30,207/61: The use of formaldehyde vapor fixation following freeze-drying of tissues permits the demonstration of histamine in the rat MCs by fluorescence.

Falck D46,277/62: Adrenaline, noradrenaline, and 5–HT form highly-fluorescent condensation products when treated with formaldehyde. This method permits the demonstration of catecholamines and 5–HT in neurons and of 5–HT in MCs (rat and mouse) and in blood platelets.

Falck et al. G19,000/64: Cells, whose chromaffinity derives from stored dopamine, occur widely distributed in ruminants. This cell system has now been studied by a fluorescence method, highly sensitive and specific for catecholamines and 5–HT. Cells with an intense green granular fluorescence, typical for primary catecholamines, were found in all tissues of the cow and sheep. Their distribution corresponded with the occurrence of dopamine, but not with that of noradrenaline. "The fluorescent cells had the typical morphology, distributional pattern and staining properties of mast cells and must thus be considered to be such."

Saunders G19,424/64: Acridine orange precipitates acid mucopolysaccharides and the precipitate can be redissolved in solutions of graded NaCl concentration. A fluorescence microscopic technique, based upon such fractional precipitation and solution, permits differentiation between hyaluronic acid, chondroitin sulfuric acid, and heparin in various tissues, including MCs.

POLARIZED LIGHT MICROSCOPY

Normally, neither the granules nor cytoplasm of MCs are birefringent, but, using certain dyes, it is possible to induce anisotropy in the cytoplasm and thereby to detect otherwise indistinguishable details in the intergranular substance.

Reviews: *Baglioni* C16,539/54, *p. 155*
Smith D63,031/63

Horváth C71,332/59: Certain dyes (pyronin G, toluidine blue, neutral red), dissolved in acid medium, produce anisotropy in the cytoplasm of MCs. This "birefringence cannot be extinguished by imbibition." These facts were confirmed on the MCs of the subcutaneous connective tissue and the mesentery of the rat.

Horváth C88,558/60: "The submicroscopic structure of mast cells, isolated from the abdominal cavity of rats, has been examined under the polarization microscope. Stained with a mixture of acid neutral red and toluidine blue, the mast cells display a positive polarization cross which points to the existence of a circularly arranged protoplasmic structure. Anisotropy is due to the intergranular substance."

White E22,503/63: Using a modification of the fluorescent antibody technique, it has been shown that globulin from the serum of a variety of animal species can be taken up on murine-lingual MCs in vitro. Thus, the MCs are rendered brilliantly fluorescent when treated with guinea-pig serum plus fluorescein-labeled rabbit anti-guinea-pig globulin, or with human serum plus fluorescein-labeled rabbit anti-human globulin, etc.

Adams-Ray E37,378/64: Using fluorescence-microscopic techniques, it is possible to demonstrate in various species cutaneous MCs which contain catecholamines and 5–HT.

Holländer G10,073/64: Two methods have been developed for the histochemical demonstration of sulfate esters. Method I uses trypaflavin as a fluorochrome which makes sulfate esters visible owing to their orange-yellow fluorescence metachromasia. Method II permits the previously-deposited fluorochrome to become visible in the light microscope owing to the formation of a red complex with p-dimethylaminobenzaldehyde.

Hultén & Pontén G2,982/64: In human colon fixed with formalin-methanol, fluorescence was observed in MCs. The reaction may be indicative of histamine.

INTERFERENCE MICROSCOPY

Interference microscopy has very rarely been used in the study of MCs and up to now it has revealed no particularly novel data.

Review: *Smith* D63,031/63

Ottoson et al. D31,592/58: Discussion of the use of interference microscopy for the determination of the dry mass of MCs.

CINEMATOGRAPHIC OBSERVATION

Time-lapse cinephotomicrography is the most useful technique for in-vivo study of MC movements in tissue spreads and tissue cultures. Observations are usually made under the phase-contrast microscope which permits the demonstration of MC degranulation with subsequent phagocytosis of the discharged granules by histiocytes and eosinophils, the formation of pseudopodia and clasmatosis.

MCs exhibit a very slight motility but they show phagocytosis, pinocytosis and, very rarely, divisions. By time-lapse cinematography, it is also possible to show that, in tissue cultures, various exogenous metachromatically-staining polysaccharides can be ingested by fibroblasts and histiocytes; the resulting elements are sometimes virtually indistinguishable from true MCs. These findings lead some authors to the assumption that the MC granule is not a secretory product but the result of phagocytosis.

Smith D63,185/58: Cinematographic recordings of MC changes in the transilluminated rat mesentery.

Dougherty & Schneebeli D61,515/58: Microcinematographic demonstration of MC disintegration in living, isolated, loose connective tissue of mice.

Policard & Collet D33,662/59: Cinematographic observations on rat peritoneal MCs observed with the phase-contrast microscope fail to reveal any ameboid motion but clearly show phenomena of surface deformation, explosive degranulation with phagocytosis of the discharged granules by adjacent histiocytes or eosinophils, etc. Under the influence of distilled water and various drugs which cause complete degranulation, numerous granules are simultaneously, but not explosively, discharged together with cytoplasm which eventually disintegrates.

Burton D26,702/60: A technique is described for the preparation of tissue cultures from peritoneal or subcutaneous MCs of the rat and their study by time-lapse cinephotomicrography. The technique reveals a slow ameboid motion and occasional divisions in MCs, but it is impossible to determine whether the latter represents mitosis or amitosis.

Smith et al. D63,177/60: Cinematographic studies on transilluminated rat mesenteries show that following treatment with toluidine blue, protamine sulfate, 48/80, d-tubocurarine, Phenergan, reserpine, and iproniazid "the granules lose their dark appearance and become barely visible; while the cell swells and later shrinks. The sequence and degree of these changes are specific for individual pharmacological agents."

Burton D58,284/63: Description of the technique for the cinematographic time-lapse observation of rat peritoneal MCs in tissue culture. The cells exhibit motility, pinocytosis, phagocytosis, and very rare divisions. "In the course of a study on the absorption of various polysaccharides (heparin, heparin-histamine complex, dextran, iron-dextran, carboxymethylcellulose) by connective-tissue cells in cultures, a very similar life cycle was found. These cells ingest polysaccharidic substances very actively; their cytoplasms become overloaded with the substances in granular form, and finally assume a round or oval shape resembling that of the mast cells. These observations and experiments suggest that mast cells originate through differentiation from mesenchymal cells or from any phagocytic cell type. The formation of the granules seems to be the result of the removal of a certain part of the ground substance, and not of the secretory activity of the cell."

Geiger et al. F11,948/64: Time-lapse motion pictures of murine mastocytoma cells in vitro show that proliferation occurs by amitosis. Degranulation is associated with changes in the nucleolus and other nuclear areas with transfer of macromolecular substances to the cytoplasm. The granules are released by contraction of the cell as a whole. Vital staining of the granules can be effected by neutral red and Janus green.

TISSUE CULTURE

The study of MCs in tissue culture furnishes important data concerning their proliferation by division or by transformation from other cells. Tissue cultures also

provide material for the identification and extraction of the biologically-active MC constituents.

Using various modifications of the roller-tube and hanging-drop culture techniques, it has been possible to grow diverse types of MCs (e.g., those of dog or mouse mastocytomas, murine MC leukemia, and human urticaria pigmentosa) in vitro for considerable lengths of time without loss of their specific structure and metachromatic staining ability. Neoplastic murine MC cultures, derived from single cells, have been maintained in vitro for nearly four years without losing their ability to synthesize histamine, 5–HT, and heparin. Even the normal MCs of rat mesentery can survive in roller-tube tissue cultures for as long as several weeks, but they show little if any ameboid motion and only occasional divisions.

On the basis of these observations, there can be no doubt that the MCs of mastocytomas can divide and proliferate as a pure strain, but there still remains the question concerning the origin of the normal MCs. Some of these may arise through mitotic or amitotic division of parent MCs, but observations on cultures of rat thymus suggest that perhaps MCs can also be formed by transformation of thymocytes into "mastoblasts" and, subsequently, MCs.

Reviews: *Baglioni* C16,539/54
Arvy D26,724/55, *p. 65*

Paff et al. D26,765/47: Fragments of two mastocytomas of dogs have been cultured in vitro, without loss of their metachromatic staining ability. "Only mast cells grew out from the original tumor fragments though these contained other types of cells. They grew in some of the roller tube cultures in a sheet resembling an epithelium but in hanging drop cultures they lay separate and were irregularly spindle or star-shaped with long protoplasmic processes."

Paff & Bloom D26,472/49: In aging tissue cultures of dog mastocytomas, the cells discharge their granules, become intensely vacuolated, and then appear to die. "These findings imply that the secretory cycle of heparin production and liberation involves degenerative changes and even death of the mast cells."

Zitcer et al. D26,964/53: Human MCs from a biopsy of an infant with urticaria pigmentosa have been cultured in vitro for thirteen months, in eight successful transfers. The cells stained metachromatically with toluidine blue, supravitally and in fixed preparations. They divided both mitotically and amitotically.

MacDougall D29,156/54: Three specimens of dog mastocytoma tissue grew well in tissue culture.

Zitcer & Kirk D26,428/54: Supravital staining with toluidine blue showed the presence of metachromatic material in tissue cultures (and subsequent subcultures) of a skin biopsy specimen taken from an infant with urticaria pigmentosa. No metachromasia was noted under similar conditions in the cultures of normal human skin. Mast cells responded to cord serum ultrafiltrate with an increase in their metachromatic granules while fibroblasts did not respond in this manner in vitro.

Schindler et al. C68,305/59: Technique for the continuous in-vitro culture of cells of the P–815 MC leukemia of the mouse. Under suitable conditions, the cells maintain their high 5–HT and histamine content, as well as their neoplastic ineffectivity.

Green & Day D26,854/60: "During culture in vitro of an ascitic mast-cell tumor of the mouse, P–815, three strains have been developed, two of which were obtained by a cloning-technique. One of these pure strains is near diploid, the other tetraploid. All strains maintain their intracellular levels of heparin, histamine, and 5-hydroxytryptamine (5HT) in culture." Strains vary in their capacity to incorporate S^{35}-sulfate and glucosamine-1-C^{14} into heparin, but in all cases, the amounts of heparin, 5–HT, and histamine are higher in culture than when the same strain of cells is grown in the mouse. The half-life of heparin in MCs is about 1.5 days.

Burton D26,702/60: Tissue cultures from peritoneal or subcutaneous MCs of the rat studied by time-lapse cinephotomicrography revealed a slow ameboid motion and occasional

divisions in MCs, but it is impossible to determine whether the latter represent mitosis or amitosis.

Colosi D30,552/60: In pieces of rat tissue maintained in rotating tubes in a suitable medium, metachromatically-staining MCs are demonstrable, particularly in the subpleural connective tissue.

Csaba & Mold D32,196/62: In tissue cultures of adult rat thymus, MCs develop, presumably from thymocytes. No MC formation was observed in tissue cultures from embryonic or very young rats.

Folkman et al. D63,244/63: Description of a technique for the in-vitro culture of the entire dog thyroid by a perfusion apparatus. Mouse MC tumors implanted into the gland during perfusion grew rapidly and liberated tumor cells into the circulation.

Green & Day D58,290/63: "Neoplastic murine mast cells, which are descendants of single cells, have been in culture for nearly four years and continue to synthesize histamine, 5-hydroxytryptamine, and heparin. The amines are eliminated by the cell."

Ginsburg D58,272/63: Thymus-cell suspensions were prepared by teasing mouse thymus tissue and inoculating it into a monolayer of mouse embryo connective-tissue cells. Under these conditions, some of the thymus cells transformed themselves into "mastoblasts" and gradually into mature MCs. At certain stages, these MCs show migratory activity and there are cell divisions, but only in immature forms. "Mast cells thus can be regarded as cells that have undergone, or are in the process of undergoing, differentiation from a stem cell that may be found in the lymphatic tissue (in our case the thymus), like other blood cells. However, one cannot ignore the possibility that the cells of the body known as mast cells may form a heterogeneous collection of cells, which have nothing more in common than that they contain materials that have the property of staining metachromatically."

Baeckeland G2,967/63: In tissue culture, rat peritoneal MCs inhibit the growth of other cells such as fibroblasts. Under the conditions used, the mean survival of MCs was 3–4 days and only after this time did fibroblasts begin to proliferate.

Baeckeland G4,532/63: Rat peritoneal MCs can be maintained in good condition for fifteen days in vitro, as long as a medium containing 80 per cent serum and an excess of SO_4 ions is used.

Baeckeland G1,481/63: MCs in pieces of rat mesentery can survive in roller-tube tissue cultures for as long as 3 weeks, although they show no sign of mitosis or migration.

HISTOPHYSIOLOGY

DEGRANULATION

The ability of MCs to discharge their metachromatic granules is their most striking histophysiologic feature, and presumably the very basis of their biologic activity. It is through the discharge of granules and their highly-active constituents that the MC influences not only its immediate surroundings but, via the lymphatic and blood-vascular system, also distant organs. It is not surprising, therefore, that almost every student of the MCs has given some attention to the factors affecting granule discharge.

Unfortunately, the voluminous pertinent literature is repetitious, confusing, and apparently contradictory; repetitious because few investigators could really master the entire pertinent literature, confusing and apparently contradictory because of the tacit assumption that MC degranulation is necessarily always due to the same fundamental mechanism. As we shall see, the available facts are not in agreement with a unitarian interpretation of MC discharge: depending upon the degranulating agent, the species, and even the affected region, the discharge appears to be effected through distinct mechanisms. Indeed, there is good reason to believe that even the individual active principles of the MCs (e.g., heparin, histamine, 5–HT) can be released more or less selectively and sometimes perhaps even without the liberation of metachromatic granules. These facts must be taken into account by any reasonable interpretation of MC activity.

According to the most popular concept, degranulation and histamine discharge depend upon an energy-requiring mechanism involving a *lytic enzyme* (probably phosphatase A or C), which is situated on the MC surface but normally remains inert because its active group is blocked by a special inhibitor. Only when the latter is removed by a histamine-liberator does the enzyme become active; it then attacks the cell membrane and liberates the granules. However, trypsin and chymotrypsin-like enzymes may also be responsible for the activation of the MC-discharging mechanism.

An apparently opposing view postulates that the MC-discharging histamine-liberators displace histamine (perhaps from a combination with heparin) because they are stronger bases than the biogenic amines contained in the MC. However, this *displacement* theory has been postulated on the basis of experiments in which simple amines (e.g., octylamine) or diamidines (e.g., stilbamidine) were used as histamine-liberators, and there is evidence that these do not act through the same energy-requiring enzymatic mechanism as the more complex agents (e.g., 48/80, antigens, or anaphylatoxin).

Certain *surface-active* compounds (e.g., decylamine, emulsifiers) allegedly also disrupt MCs by a nonenzymatic mechanism. Indeed, it has been suggested that in some species MC discharge is, while in others it is not, an enzymatic process even when the same MC-discharger is used.

In any event, *intact cells* appear to be necessary only when the discharge of biogenic amines is elicited by an antigen-antibody reaction, while 48/80 and similar compounds can release histamine even from isolated MC granules in vitro.

Any theory of MC discharge must also take into account that, apparently, histamine discharge may occur prior to MC degranulation, that not all histamine-dischargers degranulate the MCs, and that certain agents (e.g., reserpine) may deplete MCs of 5–HT without causing either histamine or granule release.

In areas of intense MC disruption (e.g., anaphylactoid shock organs), there develops a massive edema owing to serous inflammation. It is generally assumed that, here, water accumulation is the consequence of the release from MCs of histamine and 5–HT, since both these compounds produce edema when directly injected into connective tissue. However, it is equally well established that hypotonic solutions and particularly distilled water can secondarily cause MC disruption. It is often difficult to decide, therefore, *whether edema is the cause or the consequence of* MC *degranulation.*

A particularly interesting fact, which has received little attention up to now, is that some histamine-liberators are definitely *topotropic* in that they cause degranulation only in the MC population of certain regions (e.g., in the shock organs of the anaphylactoid reaction). Apparently, MC discharge is not merely dependent upon the presence of an MC-discharger in the blood, but also upon local factors which make the MCs particularly vulnerable to certain agents. Furthermore, in the event of chronic treatment with an MC-discharger, there develop regional differences in the appearance of the MCs. For example, in rats given daily injections of 48/80, the MCs rapidly disappear from the anaphylactoid shock organs (except the nerve sheaths) and thereafter they remain absent in these locations, while in the subcutaneous tissue small MCs soon reappear (especially around the smallest blood vessels) despite continued treatment.

The problem of *granule formation* will be discussed in the next section in connection with MC regranulation after discharge. It should be mentioned here, however, that the two phenomena appear to be closely interrelated. Thus, apparently 48/80 first produces an increased granule formation which is then overcompensated by a secondary, much more intense, degranulation.

A good deal of attention has been given to the *microscopic changes that follow* MC *degranulation*. Some investigators assume that, after complete granule discharge, the MC dies, but the bulk of evidence supports the view that survival with subsequent regranulation is possible. This process is best demonstrated by phase-contrast microcinematography, which also shows that many of the released granules are phagocytosed by adjacent eosinophils, histiocytes, and fibroblasts, some of which can then become virtually indistinguishable from ordinary MCs. In the case of massive and generalized MC discharge such as can be produced, for example, by protamine sulfate, "showers of metachromatic granules" appear in the thoracic duct whence they enter the blood stream and become part of the hemoconia.

From the physiologist's point of view, a cardinal question is whether the release of granules from MCs is always dependent upon pharmacologic (e.g., MC-discharging drugs) or pathologic (e.g., antigen-antibody reactions) factors, or whether it can also be induced by *natural endogenous agents*. Mechanical trauma can undoubtedly cause MC degranulation and the same is true of various tissue extracts, but in the latter case the dependence of the reaction upon specific biologic, physiologic compounds remains in doubt.

Reviews: *Paton* D39,572/55; *Högberg & Uvnäs* C47,831/57; D26,477/58; D26,422/60; *Uvnäs* D26,424/58; D25,283/61; *Fernö et al.* D23,700/60; *Macaluso & Pasqualino* D5,225/60; *Diamant* D33,745/62

Paff & Bloom D26,472/49: In aging tissue cultures of dog mastocytomas, the cells discharge their granules, become intensely vacuolated, and then appear to die. "These findings imply that the secretory cycle of heparin production and liberation involves degenerative changes and even death of the mast cells."

Drennan D26,722/51: Since edema, produced in various ways, causes MC degranulation, it is assumed that in urticaria pigmentosa, it is also the local edema that acts as a stimulus for MC secretion.

Riley B90,276/53: "Some of the diamidine histamine liberators are fluorescent and can be seen to localise in peritoneal mast cells prior to the disintegration of these cells. Further, the chemical histamine liberators and anaphylatoxin produce intracytoplasmic vacuoles not seen in the degranulation which follows non-specific or histamine-induced oedema. It is believed, therefore, that there is a direct effect by the histamine liberators on mast cells and it has been shown that these effects are prevented by premedication with an anti-histamine drug."

Grossberg & Garcia-Arocha D28,699/54: When the large granule fraction of dog liver homogenates is exposed to distilled water or various histamine-liberators such as 1,10-diaminodecane, 48/80, or rat serum anaphylatoxin, it releases its histamine. Since this fraction contains the histamine-storing MC granules, "it is attractive to suppose that the characteristic granules of these cells contain histamine and have a membrane that can be lysed by physical and chemical agents."

Norton D26,564/54: When rat mesentery is placed in hypotonic Ringer-Locke solution, disruption of MCs by 48/80 is inhibited. This evidence is allegedly "in favor of the possibility that 48/80 may make the cell more permeable to extracellular ions and thereby cause disruption of the cell." The authors admit, however, that this indirect evidence is by no means conclusive.

Paton D30,564/56: The simplest theory of histamine release—as it occurs under the influence of MC-degranulating substances—is "that histamine as a base is associated with some complex tissue acid, and that any base with a greater affinity for that acid will free the histamine from its attachment." However, there is some evidence that histamine is released also from tissues other than the MCs, perhaps because histamine-liberators form complexes with RNA. In fact, they do this; and furthermore, their readiness to do so runs parallel with their activity in releasing histamine.

Bhattacharya & Lewis C27,232/56: "Whereas 48/80 acts on mast cells, disrupting them, thereby releasing the histamine and 5HT they contain, reserpine does not disrupt them and specifically depletes them of 5HT, as it depletes other tissues of this amine."

MacIntosh D30,560/56: Experiments on intracellular particles isolated from dog liver and other tissues by ultracentrifugation, "suggest, as a working hypothesis, that basic histamine liberators act in vivo as follows: they are accumulated by mast cells in consequence of their affinity for heparin; the heparin-liberator complex increases the permeability of the mast cell granule; free histamine contained within the granule then diffuses out."

Högberg & Uvnäs C47,831/57: Among numerous enzymes studied, only lecithinase A had the ability of disrupting rat peritoneal MCs in vitro. Trypsin, fibrinolysin, ribonuclease, hyaluronidase, and other enzymes were inactive. The disruptive action of lecithinase A was inhibited by the same agents which also inhibit the action of 48/80. Among these agents are: low temperature, acetic anhydride, 1,3-diphosphimidazole, a polyvalent immune serum against snake venom, and specific immune serums from rabbits against lecithinase A from bee venom. "The observations are considered to support the hypothesis that 48/80 acts by activating a lytic enzyme attached to the cell membrane. The activity of the enzyme is normally blocked by an inhibitor. When this inhibitor is removed by liberators such as 48/80, the enzyme becomes active and the membrane structures are attacked."

van den Brenk C59,465/58: The cutaneous MCs of the rat respond normally with degranulation to the application of 48/80 even after they are seriously damaged by X-irradiation.

Uvnäs D39,577/58: Brief note on the MC-degranulating effect of both lecithinase A and C. It is still uncertain which, if any, of these lecithinases is normally involved in the degranulation of MCs by histamine-liberators.

Högberg & Uvnäs D26,477/58: Allacin (an enzyme inhibitor from garlic) prevents the degranulation of rat peritoneal MCs which is otherwise produced by 48/80, ascaris extract, antigen-antibody reaction, or lecithinase A. Glutathione in excess reverses this blockade of degranulation. These findings support the theory that MC degranulation, produced by the agents mentioned, is due to activation of a lytic enzyme attached to the MC membrane, presumably lecithinase A.

Riley D27,438/58: "If we modify the [Högberg-Uvnäs] hypothesis slightly and postulate that the mast cell enzyme is a Type-C phospholipase, attacking the ester linkage between the phosphoric acid and the alcohol (choline, serine, ethanolamine), then we may infer from known evidence that the newly formed primary phosphatide will render the film leaky to histamine." Thus, the active base ethanolamine could be formed intracellularly from a normal body constituent.

Lewis C54,180/58: Biochemical experiments suggest that the rat MC "may lose its pharmacologically active contents independently of one another, and without actual disruption."

Smith D63,185/58: On the basis of cinematographic studies on the transilluminated rat mesentery, it is suggested "that histamine is freed from its binding with heparin because the histamine liberators have a stronger affinity for heparin than does histamine."

Smith C54,403/58: While i.p. injection of such histamine-liberators as stilbamidine, d-tubocurarine, 48/80, and distilled water cause mesenteric MC disruption simultaneously with histamine discharge in the rat, the i.p. injection of toluidine blue or protamine sulfate may result in a similar histamine discharge without any microscopically-visible change in the mesenteric MCs. Indeed, repeated injection of the latter substances at intervals of from 20 minutes to 24 hours, results in repeated histamine discharges which are still unaccompanied by morphologic evidence of MC disruption. "It is concluded that secretion by the mast cell does not require cell disruption and death as much of the literature indicates but is merocrine in nature."

Giarman & Potter C51,848/58: Extracts of various rat tissues, especially those of brain and kidney, cause release of 5–HT from isolated mouse ascites tumor MCs. Blood is inactive and the releasing effect can be blocked by glucose. [It remains to be seen whether, here, we are dealing with a natural release factor (*H.S.*).]

Paton D39,576/58: "In the guinea-pig, a molecule of 48/80 releases 10 to 50 molecules of histamine." [This finding is incompatible with the concept of a molecule for molecule displacement (*H.S.*).]

Uvnäs & Thon D26,067/59: The isolated peritoneal MCs of the rat release their histamine and granules with particular ease unless serum is added to the suspension. Possibly in the absence of serum, some reactive groups on the MC surface are denatured, thereby preventing the action of a membrane-splitting enzyme.

Mota D26,627/59: It had previously been shown that the MC alterations produced by 48/80 or octylamine are morphologically different from those induced by antigen and can also be distinguished by the effect of several inhibitors of anaphylaxis. In guinea-pigs, anaphylatoxin produces an MC damage similar to that elicited by antigen-antibody reactions and distinct from that produced by histamine-liberators. It is concluded that anaphylatoxin acts through a mechanism different from that of histamine-liberators.

Welsh & Geer D39,505/59: Following 48/80 i.p., the granules discharged from the peritoneal MCs of the rat are taken up by eosinophilic leukocytes, as judged by electron-microscopic observations. This phenomenon may play a role in histamine release and allergic inflammation. "It is suggested that the phagocytosis of mast cell granules may be the basis for the 'basophilic bodies' seen in circulating eosinophils in human subjects."

Policard & Collet D33,662/59: Cinematographic observations on rat peritoneal MCs observed with the phase-contrast microscope clearly show phenomena of surface deformation, explosive degranulation with phagocytosis of the discharged granules by adjacent histiocytes or eosinophils, etc. Under the influence of distilled water and various drugs which cause complete degranulation, numerous granules are simultaneously, but not explosively, discharged together with cytoplasm which eventually disintegrates.

Archer D26,626/59: The isolated peritoneal MCs of the rat discharge their granules and histamine upon exposure to various tissue extracts. The responsible factor in splenic tissue extract, which was submitted to more careful scrutiny, appears to be an arginine-containing polypeptide, possibly derived from histone. It is assumed that tissue injury releases this factor from nucleated cells and that this endogenous principle is responsible for the degranulation and histamine release from MCs under injury. Rat plasma, to which dextran has been added, also causes disruption of mast cells with histamine release. "It is therefore possible that both release mechanisms may operate through the mast cell."

Archer D26,625/60: The peritoneal MCs of the rat discharge their granules and histamine within two or three minutes after antigen (human red cells), fresh antiserum (from rats immunized with human red cells), and MCs are placed together at 37°C and *p*H 7. The degranulation is ascribed to heat-labile substance which at 37°C disappears within 10 minutes. This substance was not formed if the immune serum was heated or treated with hydrazine to inactivate complement. The following sequence of events is postulated: antigen + antibody + complement form a labile degranulating substance. The latter disrupts MCs and liberates histamine. The relation of the degranulating substance to anaphylatoxin is not clear since the latter is presumably stable.

Fernö et al. D23,700/60: NH_2 and SH groups seem to be essential for the assumed enzymatic process lysing lipid membranes in MCs. (*Högberg & Uvnäs* C47,831/57; D26,-477/58; D26,422/60). Mast-cell disruption and histamine release are inhibited by polymeric, negatively-charged compounds, such as polysaccharide fractions from hip seeds (*Högberg et al.* D26,423/57), polyphloretin phosphate and polyestradiol phosphate (*Högberg & Uvnäs* C47,831/57; *Högberg et al.* D25,640/57). A synthetic polymeric carboxylic acid (polysalicylic acid) also inhibits both the MC disruption and the histamine release normally produced by 48/80, ascaris extract, *Cyanea capillata,* and antigen-antibody reaction, as shown by in-vitro observations on rat mesentery MCs.

Högberg & Uvnäs D26,422/60: Studies on the rat mesentery in vitro indicate that 48/80, decylamine, lecithinase, and antigen (after sensitization) disrupt the MCs. "A *p*H optimum around 7.4, the essentiality of Ca ++ ions, the influence of temperature and the inhibitory action of various enzyme inhibitors, especially those blocking protein NH_2-groups

and SH-groups, supported the view that compound 48/80 and antigen disrupt the mast cells by activating a lytic enzyme attached to the mast cell membrane. Decylamine, on the other hand, is a surface active agent that disrupts mast cells by a non-enzymatic mechanism."

Uvnäs et al. D26,167/60: "The possibility that the activation of a phospholipase triggers an energy requiring disruption process is discussed. The mechanism seems to be the same as for mast-cell disruption due to polymer amines (such as compound 48/80) and antigens."

Fredholm et al. D26,853/60: "From the observation that toxin from *Clostridium welchii* causes degranulation of mast cells it has been concluded that phospholipase C is responsible for this effect [*Riley* D27,438/58; *Habermann* D27,439/59]. In the present study, it has been shown that the MC-degranulating agent is not phospholipase C, but probably phospholipase A, originating from the sterile culture medium."

Glenner & Cohen D26,769/60: A trypsin-like enzyme can be demonstrated histochemically in the MCs of dog and man, but not in those of rat, rabbit, guinea-pig, and mouse. "The physiological function of this trypsin-like enzyme in mast cells of certain species is not known, but it may possibly act to liberate secretory granule substance."

Westerholm D65,672/60: Observations on chopped cat skin "suggest that histamine release from such tissue is a process requiring energy from oxidative or glycolytic processes."

Hill & Pospíšil C99,519/60: Two types of MC degranulation can be distinguished in the mesentery of the rat: shrinking with lysis of the granules and swelling with granule discharge. The former is considered characteristic of glucocorticoid, the latter of mineralocorticoid activity. [However, the evidence for this assumption is very indirect (*H.S.*).]

Mota & Ishii D26,569/60: Previous observations on guinea-pigs led to the conclusion that several agents which inhibit MC damage and histamine release by antigen do not inhibit the same effects of histamine-liberators. Furthermore, the morphologic changes produced by these two types of agents and MCs are different. "These results led to the conclusion that the histamine release mechanism of the antigen-antibody reaction and that of chemical releasers was quite different. However, this conclusion does not seem to apply to all species since, at least in the rat, there is a very close similarity between the histamine release mechanism of the antigen-antibody reaction and that of compound 48/80."

Keller & Oppliger D27,077/61: It had previously been shown that 48/80 and phosphatidase-A are highly effective in liberating histamine from the MCs of the rat and hamster while they are almost ineffective in guinea-pigs. This difference may be due to the fact that in the rat and hamster the liberation of MCs is an enzymatic process, while in the guinea-pig, it depends upon non-enzymatic lysis. It is of interest, therefore, that the MCs of man (removed from the bronchial mucosa by suction in vivo), like those of the rat and hamster, discharge their granules readily upon contact in vitro with bee venom, phosphatidase-A, 48/80, or chymotrypsin.

Uvnäs D25,283/61: In the rat and cat, the release of histamine (and presumably of MC granules) appears to be an enzymatic process. "The histamine release is blocked by heating of the tissue briefly to 45°C, and by the presence of enzyme inhibitors such as dinitrophenol, etc. [*Chakravarty et al.* D26,476/59; *Diamant & Uvnäs* D17,009/61]. Furthermore, the histamine release induced by compound 48/80 was shown in rat lung tissue to require oxygen or, under anoxia, glucose for its optimal course [*Diamant & Uvnäs* D17,-009/61]. Histamine-releasing principles extracted from *Ascaris suis* (eelworm of hog) and *Cyanea capillata* (stinging jellyfish) behaved similarly to compound 48/80 in their action on cat and rat tissues [*Högberg et al.* D25,640/57; D26,423/57; *Diamant* D26,421/61). The chemistry of the *Ascaris* and *Cyanea* principles is unknown. They may belong to the glucoproteins. In contrast to rat and cat tissue, guinea-pig tissue is rather insensitive to compound 48/80 and to extracts from *Ascaris* and *Cyanea*. The histamine liberation caused by high concentrations of these agents seems to be non-enzymatic in nature; at least it is not blocked by enzyme inhibitors, nor does it require the presence of high-energy substances [*Diamant* D26,421/61]. Simple amines such as octylamine, decylamine, etc. seem to liberate histamine non-enzymatically in all animal species investigated. Histamine, under these circumstances, is possibly released by simple replacement of one basic substance (histamine) by another (the releasing amine)."

Uvnäs & Thon D26,478/61: It is again suggested that granule discharge depends upon the activity of phospholipase A since, among 35 enzymes tested, this was the only one capable of degranulating rat mesentery MCs and its action was blocked by the same inhibitors that blocked the action of 48/80 and other MC-discharging compounds.

Diamant & Uvnäs D17,009/61: Both histamine released from lung tissue and degranulation of rat mesenteric MCs produced in vitro by 48/80 are blocked by anoxia and inhibitors of oxidative phosphorylation. Pre-incubation with glucose counteracts this inhibition. It is concluded that histamine discharge and mast cell degranulation require energy which can be derived from glucose.

Van Arsdel & Bray D26,617/61: The release of granules and histamine from rat peritoneal MCs by antigen and by 48/80 is blocked by different kinds of agents. Hence, it is concluded that 48/80 produces an MC depletion through a mechanism different from that effective in anaphylaxis.

Macaluso et al. D33,720/61: Since various histamine-liberators do not produce degranulation of MCs, histamine liberation and granular discharge from MCs seem to be potentially independent processes.

Bray & Van Arsdel D26,900/61: "Qualitative variations in the response of mast cells to different releasers suggested that mechanisms of histamine release vary considerably among the chemical agents now being investigated."

Garcia-Arocha C99,920/61: When cell suspensions of rat peritoneal MCs are exposed to various histamine-liberators, freezing and thawing, distilled water, mechanical trauma, or such lytic substances as saponin sodium taurocholate, etc., they quantitatively release their 5–HT and histamine. "The release of these amines by procedures not involving the rupture of primary chemical bonds provides evidence that both amines are enclosed in diffusible form or loosely bound, within the cell structure."

Uvnäs D68,430/62: Additional evidence that activation of phospholipase A acts as a trigger mechanism for MC discharge. "This hypothesis is supported by the disclosure of phospholipase A activity in isolated mast cells and by the detection of biologically active factors which behave like unsaturated fatty acids and phospholipids and appear concomitantly with histamine. Another trigger candidate recently came to light when chymotrypsin was found capable of releasing histamine from mast cells. A possible mechanism of action is suggested. The actual significance of these two enzymes in the histamine release process, as well as that of the energy-requiring links therein, remains to be established."

Moran et al. D33,693/62: Observations on isolated rat peritoneal MCs suggest that histamine and 5–HT are released by an enzymatic mechanism.

Adams & Paff D33,746/62: "Thoracic duct lymph of the rat contains granules which stain metachromatically with watery toluidine blue. Following rupture of the peritoneal mast cells by intraperitoneal injection of protamine sulfate, showers of such granules appear in the lymph. It is suggested that the peritoneal mast cell by total rupture or clasmatosis contributes granules to the peritoneal fluid. These granules pass into lymphatics to reach the thoracic duct and eventually the blood stream as one of the components of hemoconia." (Cf. accumulation of MCs in lymph nodes after 48/80: *Arvy* E25,129/62, on *p.* 159.)

Diamant D33,745/62: Observations on the effect of anoxia on histamine release from guinea-pig and rat lung tissue in vitro led to the "assumption that high-energy compounds available at the time of exposure of the lung tissue to the histamine-releasing agents are of consequence for histamine release to proceed. They also suggest that the initial reaction (coupling of antigen to antibodies and of compound 48/80 to active sites) occurs without involvement of high-energy compounds." It is not yet clear to what extent these conclusions are applicable to the metabolic changes in the MCs of the lung, "since histamine release from isolated rat mast cells is not affected by anoxia in the absence of glucose [*Uvnäs & Thon* D26,478/61; *Moran et al.* D33,693/61]. At first sight, this may appear inconsistent with the importance of the metabolic reactions occurring in MCs. Since albumin is necessary for histamine to be released from isolated rat MCs [*Uvnäs & Thon* D26,478/61], it was suggested that the albumin might render the mast cells insensitive to anoxia [*Moran et al.* D33,693/61]. The importance of the metabolic reactions occurring in isolated rat mast cells is, however, evident from the finding that histamine release induced by *Cyanea capillata* and by compound 48/80, was inhibited by dinitrophenol, whereas this inhibition was abolished in the presence of glucose [*Uvnäs* D26,479/60; *Moran et al.* D33,693/62]."

Keller D60,849/62: Normal rat peritoneal MCs contain much lecithin and little lysolecithin, while the reverse is true of MCs degranulated by 48/80 or anaphylaxis. It is assumed that during MC degranulation lecithin is transformed into lysolecithin.

Keller D33,742/62: Histochemical studies indicate that rat peritoneal MCs contain a nonspecific esterase with properties similar to the MC enzyme activated in anaphylaxis.

Keller & Schwarz D58,842/63: Isolated rat peritoneal MCs discharge their granules under the influence of anti-rat rabbit serum, even in the presence of antisera to phosphatidase A from bee venom and to bovine α-chymotrypsin. From this it cannot be concluded however, that these enzymes are not involved in the discharge of MCs, because the antisera may be species-specific and, hence, ineffective in inactivating the corresponding enzymes of the rat.

Meng & Westerholm D39,781/63: Various oil emulsions as well as their emulsifiers (i.p.) cause degranulation of rat mesenteric MCs in vivo and histamine discharge from isolated peritoneal rat MCs in vitro. "It is suggested that the action of these emulsifiers in causing disruption of rat mesentery mast cells in vivo and histamine release from isolated rat mast cells in vitro is of surface active nature."

Uvnäs D58,286/63: "The triggering enzyme on the mast cell surface—possibly phosphatidase A—requires free NH_2 groups for its activity. The enzyme is normally inhibited, since these NH_2 groups are masked. Chymotrypsin should be able to unmask NH_2 groups by breaking susceptible peptide bonds. Whether or not this purely hypothetical explanation holds true remains to be seen."

Mongar & Perera E32,256/63; *Perera & Mongar* E27,299/63: Chymotrypsin-like activity is present in isolated rat peritoneal MCs which do not discharge their histamine. DFP (in concentrations which irreversibly inhibit the activity of the enzyme) does not prevent the discharge of histamine. However, heating MCs to 45°C or incubation with N-ethyl maleimide inhibits histamine release by antigen without interfering with esterase activity. "It can be concluded that the active chymotrypsin enzyme in rat mast cells is not involved in the anaphylactic reaction."

Perera & Mongar E27,298/63: The MC-histamine-releasing effect of 48/80 was inhibited by various agents known also to inhibit the release of histamine from MCs in the anaphylactic reaction and guinea-pig lung, but none of them inhibited the esterase activity of MCs. "Conversely when the chymotrypsin-like enzyme was inhibited by 10^{-4} M DFP, the release of histamine by compound 48/80 was unaffected. Thus inhibition of the heat-labile SH enzyme activated by compound 48/80 had no effect on the chymotrypsin-like activity of the mast cell and inhibiting the chymotrypsin-like enzyme does not prevent histamine release by compound 48/80. It thus seems that the chymotrypsin-like enzyme found in rat mast cells is distinct from the heat-labile SH enzyme required for the release of histamine by compound 48/80." On the other hand, the synthetic ester used as a substrate for chymotrypsin released histamine from rat MCs, probably through a non-enzymatic reaction.

Orfanos & Stüttgen E37,429/63: Topical treatment with 48/80 first causes granule formation in immature human cutaneous mastocytoma cells but this is followed by degranulation. As judged by electron-microscopic studies, 48/80 acts primarily on granule formation and liberation of the granules is only secondary.

Liacopoulos et al. E27,304/63: It is calculated that several units of antigen-antibody complexes are necessary to deplete an MC of its histamine content.

Tuchweber et al. D27,884/63: In the rat, hexadimethrine i.v. produces an anaphylactoid reaction which is characterized by a predominant swelling of the snout with little or no change in the other anaphylactoid shock organs. The localization of the response is presumably due to a selective effect of hexadimethrine on the MCs of the snout.

Selye et al. E24,139/64: The topotropic effect of various MC-dischargers is apparently influenced by various systemically-administered challengers in mastocalciphylaxis. Thus, dextran, dextrin, compound 48/80, polymyxin, and viomycin all induce the "cephalonuchal syndrome" (with selective MC discharge in the neck region) in rats sensitized with DHT and subsequently given $FeCl_3$ i.v. However, the route of administration is also important since, upon i.p. injection, such MC-dischargers as dextran, dextrin, or viomycin produce a calcifying anaphylactoid reaction in the DHT-sensitized rat subsequently given $FeCl_3$ or other metallic challengers i.v.

Selye et al. G11,122/5; *Serafimov et al.* E24,149/5: After the induction of calcergic reactivity by lead acetate, i.v., various MC-dischargers (e.g., compound 48/80, polymyxin, stilbamidine, dextran, dextrin) and MC products (5–HT, histamine) produce essentially distinct patterns of calcification in the rat. The preferential deposition of calcium in one or the other organ is ascribed to selective MC degranulation with consequent mastocalcergy induced by different compounds in different regions.

REGRANULATION

It is difficult to estimate the part played by regranulation of depleted cells in the restitution of the normal MC population after treatment with MC-dischargers. Undoubtedly, some of the new MCs are formed by division of cells of their own kind; others may arise by transformation from different cell types. The phenomena of MC division and neo-formation from other cells will be discussed elsewhere (*pp.* 84, 86); here, we shall be concerned primarily with regranulation. However, in its final stages it is impossible to distinguish this phenomenon from the restitution of a depleted MC population by other means; hence, the end result of recovery will have to be considered irrespective of the means through which it is achieved.

After severe depletion of the MC population by chronic treatment with an MC-discharger such as 48/80, new MCs are gradually formed despite continued treatment. These are usually small and localized mainly along the course of minute blood vessels. The time necessary for complete restitution after cessation of treatment with an MC-discharger depends upon the dose administered, the length of treatment, and many other factors. Therefore, it is impossible to generalize but, after severe depletion, it may take weeks before the MC population returns to normal.

The mechanism through which regranulation is effected has not yet been fully clarified. Some investigators believe that new MC granules are formed by transformation from mitochondria, but electron-microscopic studies suggest that granule formation may occur independently of mitochondria in the Golgi field. In addition, undoubtedly, many new MCs—or at least cells indistinguishable from MCs—can be formed by the phagocytosis of discharged metachromatic granules by fibroblasts and histiocytes.

The whole problem of MC regranulation is still badly in need of further study with more quantitative methods than are now available. In particular, it would be instructive to determine the cause of the regional differences in the speed of regranulation and to determine whether recovery occurs more rapidly if only the MCs of a limited territory are depleted.

Webb D27,897/31: Following i.p. injection of ovalbumen, India ink, potassium ferrocyanide, and other foreign substances, the local MCs discharge their granules and regranulation is not completed for several weeks.

Degos & Cottenot D26,857/53: Following adrenalectomy, the MCs (site not mentioned) of the rat lose their granules and their cytoplasm becomes homogeneously very slightly metachromatic. Injection of cortisone restores the normal MC appearance. Since injected heparin is much more rapidly excreted in the urine (judged by metachromasia) by adrenalectomized than by intact rats, it is concluded that the storage of MC granules depends upon glucocorticoids.

Riley & West D39,574/55: Following short-duration, daily treatment with 48/80 i.p., an anaphylactoid inflammation develops and simultaneously the MCs and histamine of the ears and skin diminish in the rat. Only the small MCs of the perineurium appear to be resistant. About six days after the injections are stopped regranulation begins. In the event of prolonged daily treatment with as much as "1 mg. of the liberator, there is no mortality and the clinical signs of histamine release at this dose level are virtually absent. Nevertheless, there are regional differences in the appearances of the mast cells. They progressively disappear from the ears (except in the nerve sheaths) and thereafter remain absent. However, in the subcutaneous connective tissue, the initial disappearance of the cells is followed by the gradual development of numerous minute mast cells in the adventitia of the small blood vessels with

muscle coats, until by day 32 many of these vessels are surrounded by several layers of small, darkly staining, mast cells. These changes are again reflected in the tissue histamine values."

Higginbotham & Dougherty D33,668/55: "Heparin, heparin-protamine complex, heparin-histamine complex, agar-agar and other macromolecules readily form azure-staining granules in fibroblasts. Following shedding of granules of local mast cells (in response to a variety of stressors) it was noted that numerous granules appeared in the surrounding fibroblasts. To investigate the origin of these granules, a suspension of isolated mast cell granules was injected locally into the subcutaneous tissue of a number of mice and at intervals the animals were killed and samples of the loose connective tissue at the site of injection removed for microscopic observation. As early as 15 min. after injection of isolated mast cell granules, fibroblasts were incorporating these bodies. This is evidence that fibroblasts can absorb polysaccharides released endogenously under stressful conditions as well as administered substances of this type. It is suggested that this process (micellophagosis) plays a role in detoxification by absorption and intracellular degradation of conjugates of polysaccharides with noxious agents. This concept re-emphasizes Ehrlich's suggestion that mast cells are scavengers."

Arvy D27,873/56: When rats (135–190 g) are treated daily with 250 μg of 48/80 i.p., the MCs of the lips, tongue, and scrotum disappear or are severely altered within 4 days. In the sinusoids of the lymph nodes, numerous, more or less damaged MCs persist while the MCs of the thyroid, parathyroid, and extremities are but slightly modified and those in the perineurium remain intact. By the 8th day, MCs reappear in certain territories, particularly in the tongue but they are small, frequently appear in pairs or chains, and resemble embryonic MCs. At that time, the MCs in the lymph nodes are partly of the old and partly of the new generation. Upon cessation of treatment, MC regeneration occurs throughout the connective tissue and one week after cessation of a course of 8 injections, the MC population of the tissues returns to normal although the cells are still small. Regeneration occurs both by division and by transformation of connective-tissue cells into MCs.

Gustafsson & Cronberg D27,895/57: Regranulation of the mesenteric and peritoneal MCs of the rat, following injection of 48/80, turpentine, or protamine into the peritoneum, is incomplete even after 28 days. Phagocytes with ingested MC granules can still be found in the peritoneum at the end of this period.

Smith D63,176/58: Following degranulation of the MCs in the hamster cheek-pouch or the rat mesentery (induced by topical treatment with distilled water or 48/80, s.c. injection of ACTH or cortisone, and X-irradiation), the metachromatic granules are ingested by fibroblasts, macrophages, and leukocytes which then assume the aspect of somewhat abnormal MCs, showing conglomeration of metachromatic granules, colorless or metachromatic vacuoles, and alterations of shape.

Lennert et al. D26,817/59: Increased maturation of the MC granules is due to an increase in the number of SO_4 groups in its mucopolysaccharides. This manifests itself by increased toluidine-blue metachromasia and stainability at a high *p*H. Immature MCs (particularly those in mastocytosis), can thus be stained only at low *p*H under usual conditions but if they are artificially sulfated then they become toluidine tingible, even at very high *p*H.

Schauer D30,586/62; E54,510/64: It has been assumed, on theoretic grounds, that the MC granules are formed within the Golgi apparatus (*Braunsteiner & Pakesch* D30,632/57). Electron-microscopic studies revealed close relationships between the granules and the Golgi field but it was thought that the former develop through transformation from mitochondria (*Gusek* D39,516/60; D12,407/61; D14,871/60). The normal MCs of the adult mouse, rat, or hamster exhibit no Golgi field although this is quite obvious in the MCs of mouse embryos just before birth as well as in the cells of two types of mouse mastocytoma. In these cases, the MC granules are so closely associated with the Golgi apparatus that the formation of granules in this zone is considered to be very probable.

MOTILITY

The older literature contains many references to the ameboid motility of MCs, but these were based on observations on fixed cells using the light microscope. In most of these cases, the position of an MC in the vascular wall or the epithelium, the formation of pseudopodia, and the finding of a metachromatic "trail" or "wake" were interpreted as indications of motion. However, pseudopodia do not necessarily indicate any great ability to migrate and the "trails" of metachromatic substance

may well have been long and poorly-delimited pseudopodia. As judged by the more reliable in vivo observations, the MCs exhibit only very little, and slow, ameboid motility; indeed, several contemporary authors believe that at least some MCs do not actively migrate at all.

Reviews: *Lehner* D27,094/24, *pp. 103, 181* *Kelsall & Crabb* D26,076/59, *p. 57* *Michels* C72,066/38 *Baglioni* C16,539/54, *p. 148*

Hirschmann D27,099/01: MCs are numerous in the stroma of the larynx of patients with laryngitis. Here, the MCs are sometimes seen in the process of emigration through the vascular wall into the connective tissue.

Fahr D29,298/05: Following i.p. injection of various pathogenic microbes or toxic arsenic preparations, the peritoneal MCs of the rat migrate into the adjacent mesentery and omentum. Since local MC destruction has not been observed, this phenomenon was ascribed to a negative chemotaxis.

Arnold D27,305/06: Ameboid motion can be shown in the MCs of the frog tongue, especially after the induction of an edema, using vital staining.

Sansonow D27,433/08: MCs show ameboid motion.

Pappenheim D33,701/08: Certain MCs leave a trail of γ-metachromatic material as they move from one place to another. "Thus, it is possible to follow the path of this amebocyte like that of a snail leaving a wake of mucus."

Michels C72,066/38: Extensive review of the literature concerning the possible ameboid motion of MCs. It is assumed that the MCs are potentially capable of ameboid motion, although most of them are sessile. They belong to the group of "resting wandering cells".

Hirt et al. D33,724/38–39: The subcutaneous MCs of the mouse exhibit slow ameboid motion and, frequently, detachment of large portions of the cytoplasm (clasmatocytosis?).

Asboe-Hansen B60,548/50: Allegedly, MCs possess ameboid motility.

Cambel et al. D24,770/52: MCs have been observed, both in the wall of the stomach and in the gastric secretion of rats, but not in those of rhesus monkeys or guinea-pigs. It is assumed that in the rat, the MCs move into the gastric secretion by ameboid motion.

Serrão C8,615/53: MCs are allegedly capable of ameboid motion.

Mergenthaler & Paff D27,407/56: "Since we have never been able to observe convincing ameboid movement in a mature mesenteric mast cell in situ, we incline to the belief that mast cells leave the mesentery by being 'shelled out' as the mesentery is bent, twisted, and tensed by movements of the abdominal wall, diaphragm and gut."

Padawer D30,194/57: Although other investigators observed ameboid activity of MCs derived from mastocytoma tissue or skin, the author found no evidence of it in rat peritoneal fluid kept in a microscope incubator although other elements (eosinophils, monocytic cells) were actively motile.

West C64,139/58: On the basis of histologic observations, it is assumed that MCs originate perivascularly but then migrate away from the blood vessels.

Gillman C52,329/58: On the basis of histologic observations, MCs appear to move toward necrotic foci, as if attracted by a "chemotactic agent."

Policard & Collet D33,662/59: No ameboid motion could be demonstrated in rat peritoneal MCs observed cinematographically with the phase-contrast microscope.

Burton D26,702/60: A technique is described for the preparation of tissue cultures from peritoneal or subcutaneous MCs of the rat and their study by time-lapse cinephotomicrography. The technique reveals a slow ameboid motion and occasional divisions in MCs.

Arvy E25,129/62: Following treatment with compound 48/80, the disappearance of MCs in the connective tissue is associated with a marked increase in MC density within the lymph nodes. This is ascribed to a migration by way of the dilated lymphatics. (Cf. metachromasia of lymph: *Adams & Paff* D33,746/62, on *p.* 77.)

Orfanos & Stüttgen E37,429/63: Topical treatment with compound 48/80 first causes granule formation and only later degranulation in immature human cutaneous mastocytoma cells, as judged by electron microscopy.

Burton D58,284/63: Motility has been noted cinematographically in peritoneal rat MCs.

Ginsburg D58,272/63: Thymus-cell suspensions were prepared by teasing mouse thymus tissue and inoculating it into a monolayer of mouse embryo connective-tissue cells. Under these conditions, some of the thymus cells transformed themselves into "mastoblasts" and gradually into mature MCs. At certain stages, these MCs show migratory activity, and there are cell divisions but only in immature forms.

PHAGOCYTOSIS

Whether MCs are capable of phagocytosis has been a much debated problem. Of course, it is well established that discharged metachromatic MC granules can be phagocytosed by adjacent cells which then look like MCs. Even metachromatic foreign materials, such as carboxymethylcellulose or heparin can be thus phagocytosed by cells which then assume the appearance of MCs or "quasi-mastcells."

True MCs possess little if any phagocytic potency, in that they do not tend to ingest microscopically visible particles. However, occasionally erythrophagocytosis by MCs has been noted and it is possible that discharged MC granules play a decisive part in "endothelial activation" (the binding of blood-borne particles to the endothelial cells in damaged areas), because this phenomenon is associated with topical MC degranulation and it can be inhibited by antihistaminics.

Finally, recent experiments have amply demonstrated that, through the phenomenon of mastopexis, blood-borne soluble metal complexes can be bound by discharged or even intracellular MC granules.

Reviews: *Kiyono* B78,216/14; *Asboe-Hansen* D27,999/54; *Brodeur & Gardner* C21,475/56; *Kelsall & Crabb* D26,076/59

Metchnikoff B64,274/1892: MCs are thought to possess phagocytic properties.

Kiyono B78,216/14: The peritoneal MCs of the rat do not phagocytose i.v. injected lithium carmine.

Schaffer A54,121/22; *Ernst,* after *Tsuda* D27,349/23; *Marchand* 48,306/13; *Tschaschin,* after *Tsuda* D27,349/23: MCs are assumed to possess a phagocytic potency.

Tsuda D27,349/23: Injected cocci are occasionally found within MCs, yet, vital staining shows no ingestion of particulate dyes.

Nagayo D26,871/28: Although MCs usually show no evidence of phagocytosis, occasionally they may contain erythrocytes.

Stockinger D65,522/28: The metachromatic granules of mouse MCs allegedly arise from phagocytosed nonmetachromatic material.

Törö D33,638/42: If histamine is applied to the shaved skin of the rat, there is local storage of carbon particles in the endothelium of the small vessels. Hence, the ink granules are taken up by the pericytes. The regional MCs "first disappear and later reappear without granules. Sometimes, they are laden with India ink. Since, in the rat, the mast cells form a perivascular sheath and undergo pronounced changes, they may play an important role in vascular function. We did not succeed in obtaining a clear picture of this process."

Selye C8,400/55: Chronic s.c. treatment with carboxymethylcellulose results in the development of numerous MC-like cells in the adrenal medulla which stain metachromatically with Unna's mixture and toluidine blue. However, the granules are somewhat larger and less intensely staining than those of true MCs. [It is possible that true MCs, like these "pseudomastocytes" may develop by the phagocytosis of metachromatically-staining material (*H.S.*).]

Higginbotham & Dougherty D39,844/56: "The fibroblastic ingestion of macromolecular or micellular polysaccharide structures has been designated as 'micellophagosis'." [*Higginbotham et al.* D33,668/55.] MC granules may furnish substrate for this process.

Higginbotham & Dougherty C32,940/56; *Higginbotham* C61,457/58: Micellophagosis is described as a "mechanism in the loose connective tissue, dealing with the fibroblastic sequestration of both polysaccharides and polysaccharide complexes of either endogenous or exogenous sources." The connective-tissue cells, which phagocytose such materials, resemble MCs and have been termed "quasi-mast cells." . . . "It has been observed that injury to such tissue will cause a shedding of the experimentally prepared granules from these quasi-mast

cells. The resemblance of this to the injury response of the naturally occurring mast cells is evident. The presence of both an acidic mucopolysaccharide (heparin) and basic substances (histamine and possibly 5-OH-tryptamine) in the mast cell granule would suggest that the mast cell may originate by this same process."

Higginbotham & Dougherty D39,843/57: Discussion of the role of MCs in micellophagosis which is defined as "a phenomenon of the loose connective tissue concerning the interrelationships existing between the fibroblasts and the acidic mucopolysaccharides of their environment: the ground substance."

Gözsy & Kátó C46,650/57: Detailed review of earlier work on the "activation of the capillary endothelium" which endows ordinary endothelial cells with RES-like phagocytic powers for the topical fixation of i.v. injected particulate substances (e.g., carbon). Following India ink i.v., topical administration of histamine causes a local fixation of carbon particles on endothelial surfaces. The endothelial cells which ingested the carbon are either detached into the blood stream where they disintegrate to be captured by the RES elsewhere or they migrate as wandering histiocytes through the capillary wall into the adjacent tissues. This endothelial activation is prevented by antihistaminics and ascribed to a topical liberation of histamine. The fact that many other agents (peptone, snake venoms, xylol, morphine) act like histamine is attributed to histamine liberation by all these agents. Yet, not all antihistamines inhibit anaphylactoid inflammation and it is claimed that "antihistamines which do not inhibit the escape of H (histamine) from the mast cells cannot therefore prevent edema formation after degranulation of mast cells by H or 48/80." [If, in the final analysis, the response is due to histamine, it is difficult to see why antihistamines should not prevent the reaction even if histamine is liberated from the MCs (*H.S.*).]

Graumann D65,523/57: Following carboxymethylcellulose or polyphloretinphosphate s.c., these substances are ingested by phagocytes throughout the body and in particular by those of the adrenal medulla. (Confirming *Selye* C8,400/55.)

Brusca D39,526/58: In vitro treatment with hemoglobin abolishes the toluidine-blue metachromasia of cutaneous and peritoneal MCs of the rat. This loss of metachromasia is ascribed to the fixation of hemoglobin on the MC granules which is directly demonstrable by histologic observation. It is assumed that the MCs play a defensive role in taking up foreign particles from the connective tissue.

Gillman C52,329/58: Around areas of vitamin D_2-induced calcification with accumulation of metachromatic material, MCs may be formed by the phagocytosis of metachromatic granules.

Velican & Velican D20,431/58: Iron and carbon particles can be detected in the MCs of tracheobronchial lymph nodes in man.

Brinkmann D33,665/59: In a case of mastocytosis, intense erythrophagocytosis by MCs appears to have occurred in association with acute anemia.

Spicer C92,580/60: In aged mice, MCs are often closely associated with iron and lipofuscin-laden macrophages in many organs. "It is possible that mast cells phagocytize iron or lipid or that, alternatively, heparin functions in some manner to influence phagocytic processes."

Zemplényi et al. D27,057/60: Following protamine sulfate i.p., there is a marked disintegration of mesenteric MCs in the rat and colloidal India ink i.v. is intensely phagocytosed by the endothelium and perivascular histiocytes of the mesentery. This process can be blocked by antihistaminics. The fat particles of egg yolk i.v. are similarly deposited in the mesentery under comparable conditions. It is assumed that histamine, liberated from the peritoneal MCs, is responsible for the activation of the phagocyte system.

Brinkmann D26,693/62: The anemia of patients with mastocytoma is ascribed to erythrophagocytosis by the MCs.

Spicer D58,289/63: "The intimate association of these cells (MCs) with numerous siderophages and lipophages suggests a possible involvement of mast cells in phagocytosis."

Burton D58,284/63: Cinematographic observation shows that rat peritoneal MCs can phagocytose various polysaccharides (heparin, heparin-histamine complex, dextran, iron-dextran, carboxymethylcellulose). "Most probably the function of mast cells is to remove or to segregate some kind of polysaccharidic and other related material from the environment, rather than to secrete. In this case, mast cells would appear to play, for polysaccharides, a role similar to that of fat cells for lipids, or that of melanophores for pigment; a 'storage' function is possible."

Selye et al. D24,159/63: Polymyxin s.c., given simultaneously with India ink i.v., causes localization of carbon particles, particularly in a halo around the polymyxin injection site. Here, the India ink and discharged MC granules are found in close association with the connective tissue and in the walls of small blood vessels, perhaps because some component of the MCs fixes blood-borne particles by increased adhesiveness of tissues. This process is designated as mastopexis.

If a similar polymyxin injection is given somewhat prior to the i.v. administration of India ink, there is no local fixation of carbon particles in the subcutis, but numerous pulmonary capillaries are occluded by thrombi, which contain aggregates of India ink. Here, the discharged MC granules may have already been carried from the site of polymyxin injection to the pulmonary circulation by the time the India ink was introduced into the circulation. It is perhaps for this reason that the carbon particles are fixed in the lung.

Gözsy & Kátó F6,840/64: If India ink is injected i.v. and polymyxin B or 48/80 intradermally in the rat, the carbon accumulates at the injection site of the histamine liberators where the MCs are discharged. The carbon particles are attached to the capillary endothelium and appear also in the pericapillary space. This is ascribed to the liberation of histamine and 5–HT.

Ultmann et al. G19,654/64: Extensive erythrophagocytosis by MCs in the bone marrow and spleen of a patient with systemic mastocytosis.

MITOSIS AND AMITOSIS

Under normal conditions, mitotic figures in MCs are rare. However, their incidence appears to be increased upon irritation with talcum suspensions, 48/80, diphtheria toxin, and other injurious agents that cause MC degranulation. Mitoses are more frequent in tissue cultures and embryonic organs than in adult animals. Their demonstration can be greatly facilitated by the injection of tritiated thymidine. There is much less evidence for the occurrence of amitoses in MCs.

Reviews: *Michels* C72,066/38, *p. 295*
Arvy D26,724/55, *p. 74*

Sansonow D27,433/08: MCs can divide by mitosis.

Timphus D27,412/14: No mitoses were found in the MCs of human lymphatic tissue.

Michels D27,501/22: In various lower vertebrates, MCs are occasionally seen in mitosis but heteroplastic development from other connective-tissue elements is more common.

Nakajima D39,782/28: Mitotic figures are commonly seen in MCs of various species during embryonic life, but not in adults.

Michels C72,066/38: "Despite arguments to the contrary it has definitely been settled that mast cells divide by mitosis." A review of the literature shows that mitotic division among MCs has most frequently been observed in embryos, although they are rare in adults. Division by amitosis probably also occurs.

Bloom D10,421/42: Mitotic and amitotic divisions have been reported in mastocytomas of dogs.

Zitcer et al. D26,964/53; *Zitcer & Kirk* D26,428/54: Mitotic and amitotic divisions may apparently occur in tissue cultures of human skin.

Drennan & Beare D26,760/54: Many amitotic and a few mitotic divisions were seen in the tissue of an MC nevus.

Fawcett D26,781/55: Closely-approximated pairs of MCs have been found in the rat mesentery following treatment with 48/80. Similar observations have been made by others (*Maynard et al.*, unpublished) in the cheek pouch of the hamster following X-irradiation and other stresses. Hence, presumably a certain portion of the MC population arises as a result of cell division.

Padawer D30,194/57: Both mitosis and amitosis occur in tissue cultures of MCs in MC tumors or after treatment with MC degranulating substances but "in our own studies involving an appreciable number of tissue spreads or mesenteries and very numerous samples of peritoneal fluid, we have yet to see a mature mast cell undergoing mitosis in an intact animal."

Even after treatment with colchicine, podophyllotoxin, and other katyostatic substances, mitotic division could not be demonstrated and "it therefore appears unlikely that well-differentiated mast cells can multiply mitotically."

Hunt & Hunt D63,100/57: Mitoses are seen in adult MCs of the rat mesentery, after moderate doses of 48/80 (i.p.). After larger doses, which cause disintegration of mesenteric MCs, mitoses are found in the subcutaneous MCs. Replacement of the disintegrated MCs appears to occur from lymphocytes and undifferentiated mesenchymal cells.

Burton D26,702/60: In preparations of tissue cultures from peritoneal or subcutaneous MCs of the rat, time-lapse cinephotomicrography reveals a slow ameboid motion and occasional divisions in MCs, but it is impossible to determine whether the latter represents mitosis or amitosis.

Calzavara et al. D13,495/60: Following skin burns, there is degranulation of the peritoneal MCs in the rat, with subsequent amitotic division.

Padawer D26,620/60: Mitotic divisions have never been observed in the peritoneal MCs of rats even after treatment with sublethal doses of colchicine. "It is unlikely that well-differentiated mast cells, seen in normal connective tissues of the rat, can undergo mitosis."

Speirs et al. D63,716/61: The peritoneal MCs of mice, given diphtheria toxoid s.c., increase in number and some of them take up tritiated thymidine. "Only a small proportion of the cells originate by division of cells suspended in the inflammatory exudate."

Walker D27,899/61: In mice given repeated injections of tritiated thymidine and killed at intervals 1–21 days after the initial injection, radioautography revealed only very exceptional marked MC nuclei. Even these "may represent transformations rather than DNA synthesis by mature mast cells." Apparently, mitosis occurs only very exceptionally, if at all, in the MCs of the skin, foot-pad, and tongue, which were examined here.

Héroux D26,430/61: The MCs of the rat can divide by mitosis and mitotic proliferation is diminished by exposure to cold.

Padawer D63,166/61: Tritiated thymidine, cytidine, and histidine became localized in rat peritoneal MCs in vitro. Only a few MC nuclei became labeled with thymidine, and free granules were not labeled with any of these substances.

Allen D61,513/61; D61,514/61: Using the Feulgen + methyl-green stain, many dividing MCs were noted in a localized area of the rat mesentery where other types of cells were also in mitosis, indicating that local inflammation may have been present. Stimulating fibroplasia with talcum i.p. also causes MC mitosis. The frequency of mitotic figures is greatest in young animals. Mitosis can also be induced by talc suspension i.p. which stimulates fibroplasia.

Allen E94,053/62: Mitotic activity, DNA doubling, and binucleation are enhanced in the peritoneal MCs of the rat by the injection of talc i.p.

Asboe-Hansen & Levi D39,755/62: The MCs in cutaneous carcinomas induced by local painting with 9,10-dimethyl-1,2-benzanthracene in the mouse, undergo active mitosis as indicated by autoradiography after tritiated thymidine i.p.

Meggers & Allen D27,664/62: Mitosis can be demonstrated in rat mesenteric MCs using the Feulgen + Bismarck brown or Feulgen + methyl-green method for the staining of specific MC granules.

Takeoka et al. D39,931/62: Mitosis of MCs was observed in the lymph nodes of rats fed seeds of *Crotalaria spectabilis.*

Roth et al. E34,000/63: Under normal conditions, mitotic figures are extremely rare in the MCs of the rat tongue or skin. However, after injection of H-3-Thymidin, marked nuclei are more often detectable, especially if the MCs are forced to discharge their granules as a consequence of treatment with 48/80. Presumably, MCs can multiply considerably as a consequence of mitotic division.

Padawer D58,275/63: Review of the literature on the uptake of tritiated thymidine by MCs. A high percentage of peritoneal MCs takes up tritiated thymidine, yet, no mitoses have been observed among them. "It therefore remains to be established that labeling with thymidine necessarily presages mitosis in all cells and under all conditions."

Walker & O'Steen D66,467/63: "Using thymidine-H^3 incorporation as a criterion of cell division, mast cells in adult mice show a very low rate of proliferation which may increase sporadically in dystrophic mice."

Geiger et al. F11,948/64: Time-lapse motion pictures of murine mastocytoma cells in vitro show that proliferation occurs by amitosis.

FORMATION OF MCS FROM OTHER CELLS

Ever since the end of the 19th century, there has been much speculation about the possible transformation of various cell types into MCs. In particular, it has been claimed that MCs can be formed from histiocytes, fibroblasts, perivascular adventitial cells, endothelial cells, eosinophils, clasmatocytes, lymphocytes, plasma cells, thymocytes, and the reticular cells of the thymus and bone marrow. Most of these concepts are based upon the demonstration of what seem to be transitional cells in that they retain some characteristics of the original type, but contain metachromatic granules. The existence of such intermediate cell forms has been amply confirmed; however, it remains a subject of controversy whether these really represent stages in the development of MCs from other cells or merely ingestion of metachromatic granules by diverse mesenchymal elements capable of phagocytosis.

Reviews: *Gherardini* D39,596/1898; *Lehner* D27,094/24, *p. 157*; *Michels* C72,066/38, *pp. 290, 294, 329*; *Vallone* D26,432/44; *Asboe-Hansen* D27,999/54; *Arvy* D26,724/55, *p. 73*; *Fulton et al.* C35,831/57; *Kelsall & Crabb* D26,076/59, *p. 57*; *Smith* D63,031/63; *Schauer* E4,510/64

Ranvier D31,524/1891: The transformation of frog lymphocytes into arborizing clasmatocytes has been directly observed in vitro.

Bäumer D27,593/1896: The author kept a patch of skin on his forearm in continuous edema, by repeated exposure to nettles (*Urtica urens*) and, upon excision, found an increase in the local MC population. He concluded that the MCs are formed from fibroblasts by the ingestion of excess nutrients that accumulate in edema.

Krompecher D28,276/1898: Certain otherwise typical plasma cells contain metachromatic granules and may represent transitional forms between Unna's plasma cell and Ehrlich's MC. They are designated as "plasma mast cells."

Harris D26,716/00: The MC is regarded as a separate cell type and not as a phase in the life of the fibroblast.

Marchand B79,772/01: Clasmatocytes are not identical with MCs but they may be precursors of them.

Heller D26,810/04: On the basis of histologic observations showing typical MCs in and around capillary walls, it is assumed that these cells originate from subendothelial phagocytes which attract metachromatic material from the blood and then migrate into the adjacent tissues.

Maximow B79,776/04: From studies on inflamed rat connective tissue, it is concluded that the MCs are essentially different from the clasmatocytes, although both may have a common origin. In the inflamed connective tissue of the rat, the MCs undergo regressive changes. They do not regenerate rapidly in newly-formed scars. At the borderline of the inflamed tissue, the MCs long continue to discharge their granules and become "exhausted." Only about six months after the onset of a severe inflammation do the MCs return to normal.

Ziegler D26,838/04: The histologic demonstration of transitional forms between lymphocytes and MCs in men suggests that the latter may develop from the former. The MCs of Ehrlich presumably correspond to clasmatocytes and differ from the latter only in that they possess metachromatic granules.

Pappenheim E90,962/05: MCs may develop from ungranulated lymphoid precursors.

Gulland D27,428/06: Brief report on a congress at which relationship between MCs and other connective-tissue cells was discussed.

Maximow B79,779/07: On the basis of embryologic studies in cats and rats, it is stated that "there can be no doubt that lymphocyte-like wandering cells of connective tissue can transform themselves into mast cells."

Dantschakoff A20,391/09: In the chick, MCs develop from small lymphocytes beginning on the 10th day of incubation.

Weidenreich A25,630/12: In the human thymus MCs are formed from thymocytes, since many transitional types can be seen between the two.

Weill A1,826/13: In the human thymus, transitional forms between plasma cells and MCs are frequently found.

Downey D26,823/13: In the guinea-pig, cat, and man, MCs appear to be formed by the gradual development of metachromatic granules in lymphocytes and plasma cells, a phenomenon particularly obvious in the lymph nodes. The metachromatic substance is believed to be formed within the nuclear chromatin and subsequently extruded into the cytoplasm.

Ringoen D27,738/15: The marrow MCs, like other granular leukocytes of the rabbit, develop by the formation of specific granules in the basophilic cytoplasm of mononuclear hemopoietic parent cells.

Herzog D26,808/16: MCs around sponge pieces in the peritoneum of guinea-pigs can develop from basophilic lymphoid cells and adventitial cells.

Weill D26,215/19: On the basis of a survey of the literature and of personal observations, it is concluded that MCs develop by direct transformation from lymphocytes.

Weill D27,097/19: Numerous MCs are found in the stroma of squamous epithelial carcinomas of the human cervix uteri. They are thought to form partly from lymphoid cells.

Michels D27,501/22: In various lower vertebrates, MCs are occasionally seen in mitosis but heteroplastic development from other connective-tissue elements is more common.

Alfejew D27,415/24: MCs arise in embryonic connective tissue from lymphocytoid and histioid wandering cells by the elaboration of the characteristic metachromatic granules.

Möllendorff B78,338/27; *Stockinger* D65,522/28: There exist transitional steps between plasma cells and MCs in the mouse.

Bensley & Vimtrup D28,923/28: An excellent review of the literature quotes numerous data suggesting that the contractile pericapillary Rouget cells can round off and become phagocytic histiocytes or even chromatophores, but no mention is made of their possible transformation into MCs.

Nagayo D26,871/28: Histologic studies on various species failed to confirm earlier claims that MCs can develop from lymphocytes, plasmacells, endothelial or Kupffer cells.

Argaud & Pesqué 90,375/29: In the course of bronchopneumonia, allegedly transitional forms appear between thymocytes (and perhaps reticular cells) and MCs, as judged by the development of metachromatic granules in the former. It is pointed out that earlier investigators likewise suspected the transformation of thymocytes, lymphocytes, or plasmocytes into MCs.

de Viñals D13,202/31: Observations on mice, following painting of the skin with tar, lead to the conclusion that the locally-proliferating MCs develop from histiocytes or undifferentiated mesenchymal cells which can change either into lymphocytes or, by the accumulation of metachromatic granules, into MCs.

Michels C72,066/38: Exhaustive review of the literature on the formation of MCs by mitosis, amitosis, or heteroplastic regeneration from lymphocytes, plasma cells ("plasma mast cells"), histiocytes, fibrocytes, and reticuloendothelial cells.

Holmgren 93,302/46: A review of the literature shows that the MCs have been thought to arise by direct transformation from fibroblasts, histiocytes, endothelial cells, indifferent adventitial cells, lymphocytes, plasma cells, and various forms of "wandering cells." Personal studies on embryos of various species suggest, however, that the MC represents a separate cell line which proliferates by division and not by transformation from other forms.

Hissard et al. B90,449/51: Intradermal injection of heparin in guinea-pigs and men allegedly produces the local appearance of MCs, as judged by cells containing granules which stain metachromatically with toluidine blue. It is concluded that MCs can be formed from fibroblasts. [It would be difficult to prove, however, that these cells actually correspond to true MCs rather than to phagocytes which have ingested metachromatic material (*H.S.*).]

Ryzhikh D39,895/52: Cutaneous MCs develop from the mesenchyma (not from lymphocytes) at about the fourteenth day of embryonic life in the rat.

Rohr D27,402/52: In patients with various forms of chronic anemia, there may be a considerable proliferation of MCs in the bone marrow, associated with plasmocytosis. Here, MCs apparently develop from the reticular cells or histiocytes of the bone marrow by the intracellular accumulation of metachromatic granules.

Bensly D26,489/52: Following injection of histamine, the MCs increase in number so rapidly that their multiplication cannot be ascribed solely to mitosis. Many typical MCs are

seen to be formed from "small round cells in the connective tissue" and typical MC granules appear in fibroblasts and endothelial cells. [Unfortunately, in this short abstract neither the species nor the site of histamine injection are specified. (*H.S.*).]

Compton B90,594/52: Some of the hamster MCs contain a "cartwheel" nucleus, similar to that of plasma cells.

Sannazzari & Visioli D66,745/53: On the basis of morphologic considerations, MCs are thought to be formed from fibroblasts.

Montagna & Melaragno D26,849/53: Since fine metachromatic granules are found in otherwise fibroblast-like cells of the human skin, it is considered that typical MCs can develop from fibroblast-like precursors.

Montagna et al. D27,628/54: As judged by studies on the cutaneous MCs of patients with urticaria pigmentosa, "mast cells in the skin differentiate from perivascular fibroblasts."

Fawcett D26,781/55: When the peritoneal MCs of the rat are disrupted by the i.p. injection of distilled water, they become irreversibly damaged and new MCs differentiate only slowly over a period of many weeks, from fibroblast-like precursors and later by cell division. Compound 48/80 causes a more "physiologic" type of change with discharge of MC granules, usually unaccompanied by the irreversible destruction of the cell. The discharged cells can multiply by division and regenerate their granules.

Higginbotham et al. D15,838/56: Following i.p. injection of $Na_2S^{35}O_4$, the labeled subcutaneous MC granules of mice were isolated by differential centrifugation. "Subcutaneous injection of the isolated mast cell granules showed that fibroblasts began to ingest the granules within 15 minutes after injection. Granulation appeared to be maximal within one to two hours and digestion of granules was apparent within four hours. These observations on the fibroblastic uptake of mast cell granules were confirmed by using S^{35}-labeled mast cell granules for injection."

Higginbotham & Dougherty C32,940/56; *Higginbotham* C61,457/58: Micellophagosis is described as a "mechanism in the loose connective tissue, dealing with the fibroblastic sequestration of both polysaccharides and polysaccharide complexes of either endogenous or exogenous sources." The connective-tissue cells which phagocytose such materials, resemble MCs and have been termed "quasimastcells" . . . "It has been observed that injury to such tissue will cause a shedding of the experimentally prepared granules from these quasimastcells. The resemblance of this to the injury response of the naturally occurring mast cells is evident. The presence of both an acidic mucopolysaccharide (heparin) and basic substances (histamine and possibly 5-OH-tryptamine) in the mast cell granule would suggest that the mast cell may originate by this same process."

Guimaraes & Taylor D26,762/57: Following treatment with radioactive gold, the number of bone-marrow MCs increases, particularly along the sinus walls. "It seems, on morphological ground alone, that the mast cells are produced locally, and their increase does not result from an invasion of cells from outside. The remarkable absence of mitosis suggests that the increase is not the consequence of a proliferation of existing mast cells but more probably results from transformation and differentiation of primitive reticular cells; the localization of the cells along the sinus walls is highly suggestive of this."

Hunt & Hunt D63,100/57: Mitoses are seen in adult MCs of the rat mesentery after moderate doses of 48/80 i.p. After larger doses, which cause disintegration of mesenteric MCs, mitoses are found in the subcutaneous MCs. Replacement of the disintegrated MCs appears to occur from lymphocytes and undifferentiated mesenchymal cells.

Takeda C60,734/58; C60,737/58: Histologic observations on the cutaneous MCs of mice, following painting of the skin with 10 per cent NaOH, suggest that new tissue MCs are formed from adventitial cells and histiocytes.

Gillman C52,329/58: Around areas of vitamin D_2-induced calcification with accumulation of metachromatic material, MCs may be formed by the phagocytosis of metachromatic granules.

Hill & Praslička D26,723/58: Following total body irradiation, numerous new MCs are formed from reticulum cells in the spleen of the mouse.

Verga & Pezzani C79,437/59: On histologic evidence of MC formation in the mesenteric lymph nodes of X-irradiated rats, it is concluded that: "Besides the cells of the reticulum and the fibroblast of the capsule, even endothelial elements possess the capacity of transformation into mastocytes."

Watson & Kennedy D26,562/60: As judged by radioautographic studies following i.p. injection of S^{35}-labeled sodium sulfate, on rat mesenteric spread (prepared on plain and gelatin-dressed glass slides, the latter being used for stripping-film autoradiography), it is concluded that, following degranulation by 48/80, MC regeneration begins within 24 hours, throughout the mesenteric tissue without being confined to perivascular areas. However, since histamine liberators (such as 48/80) act mainly to liberate histamine and have a less definite effect on the heparin content of the MCs, there is no definite proof that the utilization of sulfur (probably required for heparin and not for histamine production) actually reflects MC regeneration.

Csaba D2,230/60; *Csaba et al.* D2,228/60; D2,229/60: When boiled heparin (which has lost its metachromatic stainability) is added to rat thymus tissue cultures, the thymocytes and cells of the thymic reticulum turn into metachromatic MCs. This is viewed as additional proof of MC formation by the thymus. The author calls attention to earlier works showing that during pregnancy, PAS-positive thymocytes turn into MCs (*Csaba et al.* D2,227/60). However, similar experiments in which the same heat-treated heparin was injected directly into the thymus in vivo, led to no MC formation.

Csaba et al. D25,636/61: Intense topical MC proliferation was noted in mice at sites where benzopyrene was applied to the skin or homologous Ehrlich ascite cells were intracutaneously injected. Less pronounced MC proliferation occurred after similar implantation of Yoshida tumor suspensions, but only the latter procedure was associated with plasma-cell accumulation. On the basis of these and other experiments, it is suggested that "the first mast cells appearing around tumors arise from the connective tissue and subsequent ones from the epithelium, while those present in the subcutaneous connective tissue are rather suggestive of the 'classic' form of MC, i.e., of thymocytic origin" and perhaps also from reticular cells of the thymus.

Lindner D12,409/61: Following heparin injection into connective tissue, there is a topical increase in "mastocytoid" cells, presumably phagocytes, which after ingestion of heparin assume an MC-like appearance. It is postulated that MCs may arise normally through the ingestion of polysaccharides.

Walker D27,899/61: Counts of nonradioactive and radioactive MCs have been made in the connective tissue of the mouse using tritiated thymidine for the detection of DNA synthesis in MCs with aldehyde-fuchsin as a counterstain. Radioactive MCs were rare, regardless of the time interval between repeated tritiated thymidine injections while radioactive fibrocytes, macrophages, neutrophils, lymphocytes, and plasma cells were plentiful. "The mast-cell population sampled in this work was obviously very stable in terms of cell turn-over."

Bigelow D26,847/61: The histiocyte, like the MC, is thought to arise from the primitive reticulum cell and, similarly, may originate from the transformation of fibroblasts and lymphocytes. Furthermore, xanthomatosis in which xanthomas and non-lipid-producing histiocytomas are interspersed with the usual mastocytic lesions in the skin, suggest some relationship between these two cell types. These and many other similarities between mastocytosis and histiocytosis suggest that the two reaction forms may be essentially interrelated.

Csaba et al. D79,388/62: In rat thymus and lymph-node tissue cultures, MCs develop from reticulum cells.

Csaba & Mold D32,196/62: In tissue cultures of adult rat thymus, MCs develop presumably from the thymocytes themselves. No MC formation was observed in tissue cultures from embryonic or very young rats.

Allen D26,855/62: "Utilizing autoradiography and the Feulgen + methyl green technique of coloring mast cells, we found that, in 30-day-old rats killed 30 minutes after receiving a single injection of tritiated thymidine, 5.7 per cent of 4500 mesenteric mast cells counted, contained labelled interphasic nuclei. Of these nuclei, 75 per cent were considered to have 4C amount of deoxyribonucleic acid. Nonlabelled mitotic figures of metaphase to telophase were found in 0.49 per cent of the mast cells counted." It is concluded that "after mast cells appear in the mesentery, near the time of birth of the animals, mitosis is normally the primary means of cell production."

van den Hooff D61,469/62: In the connective tissue surrounding the vagina of the rat, eosinophilic cells may be the precursors of MCs. Immediately after parturition, only large mononuclear eosinophils are seen around blood vessels but subsequently, "metachromatic granules are formed in two phases: first an eosinophilic (protein) nucleus is laid down; then follows some sort of coating with polysaccharide."

Cannizzaro D31,003/62: Upon exposure to formaldehyde fumes, the tracheal MCs of the rat show an initial degranulation followed by excessive accumulation of MCs in the tracheal mucosa. It is assumed that during inflammation, new MCs are formed from fibroblasts.

Santini D64,084/62: Histologic studies on rat thyroids suggest that the local MCs can develop from fibrocytes by the phagocytosis of metachromatic granules.

Sacerdote D33,407/62: In the pelvic gland of *Triturus cristatus,* MCs are said to develop from "histiocytic lymphocytes".

Ginsburg D58,272/63: Thymus-cell suspensions were prepared by teasing mouse thymus tissue and inoculating it into a monolayer of mouse embryo connective-tissue cells. Under these conditions, some of the thymus cells transformed themselves into "mastoblasts" and gradually into mature MCs. At certain stages, these MCs show migratory activity, and there are cell divisions, but only in immature forms. "Mast cells thus can be regarded as cells that have undergone, or are in the process of undergoing differentiation from a stem cell that may be found in the lymphatic tissue (in our case, the thymus), like other blood cells. However, one cannot ignore the possibility that the cells of the body known as mast cells, may form a heterogeneous collection of cells, which have nothing more in common than that they contain materials that have the property of staining metachromatically."

Ginsburg & Sachs E21,572/63: Massive differentiation of MCs from tissue cultures of mouse thymus can be produced in vitro under certain experimental conditions. This differentiation is accelerated by the inoculation of the tissue culture with mammalian leukemia virus.

Burton D58,284/63: Description of the technique for the cinematographic time-lapse observation of rat peritoneal MCs in tissue culture. The cells exhibit motility, pinocytosis, phagocytosis, and very rare divisions. "In the course of a study on the absorption of various polysaccharides (heparin, heparin-histamine complex, dextran, iron-dextran, carboxymethylcellulose) by connective tissue, cells ingest polysaccharidic substances very actively: their cytoplasms become overloaded with the substances in granular form, and finally assume a round or oval shape resembling that of the mast cells. These observations and experiments suggest that mast cells originate through differentiation from mesenchymal cells or from any phagocytic cell type. The formation of the granules seems to be the result of the removal of a certain part of the ground substance, and not of the secretory activity of the cell."

Klein E26,609/63: Transitional stages between large thymocytes and MCs are described.

Bois F979/64: Since thymomas frequently develop in rats chronically maintained on a magnesium deficient diet which depletes the MCs, it is thought that the MCs may originate in the thymus.

REGIONAL DISTRIBUTION OF MAST CELLS

Although MCs are widely distributed throughout the body, they occur almost exclusively in connective tissue, particularly around small blood vessels, nerves, and glandular ducts.

In *epithelium,* MCs are uncommon but they do occur in the epithelial linings of the digestive tract (particularly the gingiva, esophagus, and pylorus) and they are especially plentiful in epithelium covering hypertrophic adenoids or tonsils. Occasionally, intraepithelial MCs are also seen in ovarian cystic adenomas and other tumors. The shape of intraepithelial MCs is very variable but, frequently, they possess long, slender, dendritic processes.

In the *skin,* MCs are plentiful in all mammals. Their number is usually greatest around hair follicles, sebaceous and sweat glands, as well as in the immediate vicinity of small vessels. In general, small (presumably immature) MCs are found mostly in the subepithelial portions of the cutis, their size and granule content gradually increasing towards the subcutis. In the human skin there are certain dendritic cells which contain faintly metachromatic material and which are presumed to be closely related to the Langerhans' cells or Riehl's dendrite cells of the epidermis. Because of their close relationship to nervous elements, these have been considered to be neurohormonal cells, but their function and possible relationship

to MCs remain doubtful. In rats, many MCs appear in the skin during the first days of a spontaneous hair cycle. MCs are especially numerous in the paws, snout, and perianal region of rats, that is, in the anaphylactoid shock organs.

In the *head* region, the MC population is also particularly dense around the lips and the oral mucosa (including gingiva), tongue, palate, tonsil, and pharynx, external ear, nose (including nasal mucosa), eye lids, cornea (near the limbus), iris, ciliary body, and choroid. On the other hand, the dental pulp appears to be devoid of MCs in all species examined.

In the *respiratory system,* the greatest concentration of MCs is found in the trachea and the large bronchi, especially just underneath the epithelium, but some MCs are present also within the bronchial epithelium and even in bronchial mucus. The MC density in the pleura varies in different species but it is usually much greater than between the pulmonary septa which contain significant numbers of MCs only in the event of inflammation.

Throughout the *digestive tract,* MCs tend to be concentrated mainly in the submucosa and allegedly they are sometimes eliminated through the epithelium. Here again, there are great species variations; a particularly large number of "basophilic granule cells," presumably MCs, are found in the intestinal wall of fish.

The stroma of the *salivary glands* is especially rich in MCs in various mammals. In the *liver* of most species, MCs occur in significant numbers only in the capsule, in the connective tissue around the hilum, and in the interlobular spaces. The dog liver is particularly rich in MCs which are predominantly arranged along the sinusoids and throttle veins. Frequently, they are so closely attached to the endothelium that they appear to be part of it. In cattle liver an unusually large concentration of MCs occurs in the capsule.

The *peritoneum* also contains many MCs and a significant number of these tends to migrate into the peritoneal fluid. Here, their concentration can be augmented by the injection of various fluids which attract them, thus yielding a useful source for the isolation of free MCs. Unlike the polymorph MCs of the mesentery, those in the peritoneal fluid assume a regular spherical or ovoid shape.

In the *thymus,* the MCs are almost exclusively situated within the stroma and capsule, but there exist some species variations in this respect. Thus in the rat, MCs are hardly ever found within the lymphatic tissue of the thymus while in man this is not exceptional. Some investigators even believe that MCs may originate from the lymphatic elements of the thymus.

In the *lymph nodes*, most of the MCs are also in the capsular and septal connective tissue, but a few of them may be seen occasionally in the interfollicular reticulum. Frequently they invade the lumina of the sinusoids and some are encountered free in the lymph vessels all the way to the thoracic duct. In inflamed lymph nodes the number of MCs increases and during anaphylactoid inflammation in the rat, the regional lymph nodes may accumulate disintegrated MC debris. In human lymph nodes the MCs situated in the pulp often have a reticulum-cell-like shape while those free in the sinusoids tend to be roundish.

The *spleen* is relatively poor in MCs and most of those present are in the capsule and stroma.

In the *bone marrow,* MC-like elements with metachromatically-staining granules are common in various species. However, here the identification of these elements as tissue MCs is often difficult because they may easily be confused with various

stages in the maturation of blood basophils or with the so-called "Kugelhaufen". The latter are metachromatically-staining basophilic granule clumps with indistinct cell membranes and a slight natural yellow color of their own.

The density of MC-like elements in the bone marrow is subject to great species variations. In man they are so scarce under normal conditions that some investigators considered their appearance as a sign of disease; by contrast, in the rat they are constantly present, although their density in the femur, tibia, and humerus is much greater than in the sternum or ribs. It is also noteworthy that the bone-marrow MCs of the rat are large but contain comparatively few granules.

Considerable attention has been given to the MCs of the *cardiovascular system* because of their possible role in preventing thrombosis through heparin formation. Here, as in other locations, there are striking species differences, and the MC density also varies considerably according to the region examined. However, in general the MCs tend to accumulate mainly around the smallest blood vessels. Presumably they play an important role here in "mastopexis", the attraction of various blood-borne compounds to sites of acute MC degranulation as seen, for example, in mastocalciphylaxis and mastocalcergy. In the hearts of most species, the greatest MC density is found underneath the pericardium and in the connective tissue especially around blood vessels, but some MCs are also present between the muscle fibers. The large vessels may show a diffuse metachromasia, but they contain comparatively few MCs.

The *joints* and the surrounding connective tissue possess a comparatively dense MC population. Some MCs are also seen in the synovial membrane and free in the joint cavity to which they allegedly contribute lubricating material.

Muscle tissue is poor in MCs while compact *bone* and *cartilage* are virtually free of them, although MCs do occur in the connective tissue surrounding these structures and around the vessels which invade them.

The *kidney* parenchyma and its internal stroma are very poor in MCs while the capsule and particularly the connective and fat tissue around the pelvis contain many MCs. In the juxtaglomerular apparatus there are cells which stain metachromatically (especially after fixation in strong oxidants) but data concerning the possibility of discharging these cells with MC-depletors are conflicting and according to predominant opinion, these cells are not true MCs. Numerous MCs are found around the *urinary passages* (ureter, bladder, urethra) especially underneath the epithelium but also in the smooth musculature.

In the *adrenals* of various animals and man, MCs are regularly present only in the capsule and the vicinity of the large vessels near the hilum.

In the *hypophysis* of most species there are very few if any MCs except in the capsule and stroma. However, impressive accumulations of MCs are noted in the pars nervosa and infundibulum of cattle and to a lesser extent occasionally also in the cat and man. Curiously, in the dog the anterior and intermediate lobes of the pituitary are very rich in MCs while the posterior lobe contains but few of them.

In the *pancreas* of most species, MCs are limited to the stroma, especially in the immediate vicinity of the ducts. In the *thyroid, parathyroid* and *pineal gland,* MCs are likewise limited to the stroma, particularly the perivascular areas.

In the *ovary,* MCs are scarce within the cortex but numerous in the medulla which is rich in connective tissue and blood vessels. Follicular fluid is strongly metachromatic but this phenomenon is independent of the local MC count and clearly demonstrable even in the rabbit which possesses virtually no ovarian MCs.

Among the female accessory sex organs, the stroma of the *mammary gland* is especially rich in MCs, particularly around the ducts. The mammary MCs allegedly contain lipid granules in addition to those which stain metachromatically. The density of the MCs in the mammary gland increases during milk stagnation and under the influence of various inflammatory and neoplastic processes. The nipples contain many MCs both in the male and in the female. The connective tissue and musculature of the *oviduct, uterus,* and *vagina* tends to be rich in MCs in most species. In the guinea-pig and rat, the epithelioid cells of the metrial gland possess metachromatically staining granules but they are not true MCs. Somewhat similar "specific cells" with metachromatic granules are found in the human uterus; however, these differ from those of the metrial gland. Certain decidual cells of women also contain metachromatic granules but, since these consist of ribonucleoprotein, they are not MCs but true decidual cells. In the chorion of the *placenta,* MCs are present in various species, including man, but the largest number is found in Wharton's jelly of the *umbilical cord* which is itself diffusely metachromatic.

MCs are also present in the *male accessory sex organs,* particularly underneath the epithelium of the glans penis (along the attachment of the prepuce), as well as in the connective and smooth-muscle tissue of the prostate and seminal vesicles. In the comb of the rooster, the ground substance is diffusely metachromatic and there are cells with metachromatic granulations but their identity with MCs is debatable.

The MC content of the various parts of the *nervous system* is variable. In the brain and cerebellum of most species, MCs are very rare, except around inflammatory foci; however, the olfactory bulb of the dog and hedgehog is extraordinarily rich in MCs. In the peripheral nerves, the MCs are usually located within the connective tissue. Variable numbers of MCs, often provided with long pseudopodia, are found in the meninges and some are present also in the choroid plexuses.

Little need be said about the MC content of *other tissues* except that these cells are present in the hibernating gland (brown fat) and in ordinary adipose tissue as well as in various purulent exudates.

Reviews: *Calleja* D39,609/1896; *Michels* C72,066/38, *p. 280*; *Serrão* C8,615/53; *Asboe-Hansen* D27,999/54; *Baglioni* C16,539/54, *pp. 167, 181 ff.*; *Arvy* D26,724/55, *p. 71*; *Nepriakhin* D26,879/56; *Riley* C70,315/59, *p. 39*

EPITHELIUM

(Cf. also individual organs with *epithelial components.*)

Hardy & Wesbrook D28,474/1895: In rats fed exclusively on fresh meat, many MCs were found within the intestinal epithelium itself.

Sussmann D27,432/11: A review of the literature indicates that, occasionally, MCs may be found within epithelial coverings, but this is rare. Intra-epithelial MCs are comparatively common, however, in hypertrophic adenoids and tonsils.

Klausner & Kreibich D27,434/13: Occasional MCs migrate into the epithelium of the skin, especially in certain dermatoses.

Lehner D27,094/24: MCs in epithelium of pylorus (mouse) and mastoid sinus (man).

von Numers & Fortelius D67,345/53: MCs are often found in the papilli of serous cystic adenomas of the ovary. Here, they lie within the epithelium and may contribute to the metachromatic content of the cysts.

Stella D63,057/55: MCs are constantly present in the epithelium of the human gingiva.

Zwillenberg D42,931/58: The "high-level dendritic cells" with long, slender processes that are demonstrable in various non-epidermal stratified squamous epithelia (esophagus, vagina, portio vaginalis uteri) and their basal counterparts generally contain granules which

stain metachromatically with toluidine blue in vivo. The granules are unevenly distributed but often lie in pairs. They frequently occur together with typical intra-epithelial mast cells which here likewise tend to assume a dendritic shape in that they form processes which protrude between the Malpighian cells. Such intra-epithelial MCs are common in the esophagus of the cat and Macaque.

Dockrill G10,498/61: In the buccal mucosa of man, MCs tend to invade the epithelium that overlies a pathologic condition in the submucosa.

SKIN AND APPENDAGES

Reviews: *Lehner* D27,094/24; *Brack* D26,821/25; *Michels* C72,066/38; *Baglioni* C16,539/54, *p. 181*; *Kelsall & Crabb* D26,076/59, *p. 97*

SKIN IN GENERAL

Zimmermann D27,591/08: In the skin of the guinea-pig, MCs are most numerous around the hair follicles, sebaceous, and sweat glands, less common in the dense chorion. They are present in the papillary layer in the subcutis, between the muscles, and wherever loose connective tissue is found. They tend to accumulate around the adventitia of vessels and in fat lobules of the subcutis.

Staemmler D26,807/21: In man, the skin is especially rich in MCs. They are absent from the epithelium and most numerous in the subepithelial portions of the cutis. Age does not influence their number significantly.

Vallone D26,432/44: MCs are numerous in the human derma.

Hellström & Holmgren D39,611/47: Quantitative analysis of the MC count in human skin (and heart) shows a gradual drop between birth and senility.

Hellström & Holmgren D25,620/50: Detailed description of the cutaneous MCs in man.

Asboe-Hansen B60,550/50: In the human skin, the number of MCs varies roughly in proportion to the metachromatic substance.

Asboe-Hansen B60,604/51: MCs are very common in the skin of man.

Compton B90,594/52: MCs are numerous in subcutaneous tissue and the dermal papillae of the hamster.

Arvy & Quivy D27,966/55: In newborn puppies, there are many MCs in the skin, particularly that of the lip where the MCs accumulate around the roots of the hair and especially the bristles.

Riley & West C29,554/56: MCs are numerous in the abdominal skin of the guinea-pig, rabbit, dog, cat, mouse, rat, and man. The histamine content of various skin layers roughly parallels the regional MC density.

Veil E62,531/57: The scales of various fish (carp, roach) contain many MCs from which heparin can be extracted.

Niebauer & Wiedmann D39,678/58: In the human skin, MCs, or at least similarly-staining cells, are frequently found in close contact with nervous elements. These pictures suggest a neurohumoral function.

Wiedmann D60,447/63: The Langerhans' cells of the epidermis, Riehl's dendrite cells on the internal surface of the epidermis, and the so-called neurohormonal cells of the skin are morphologically indistinguishable, although they differ in their function and histochemical properties. The neurohormonal cells are metachromatic. The cells of Langerhans and Riehl appear to participate in pigment metabolism.

Moretti et al. D64,379/63: An unusually large number of MCs appear in the skin of rats during the first days of a spontaneous hair cycle concurrently with a rise in skin histamine. "It seems possible that histamine, perhaps also liberated from the mast cells, may in part be responsible for 'triggering' the mechanism of the hair-growth cycle in the rat."

Brix E39,764/63: Extensive statistical studies on the distribution of MCs in the human skin.

EXTREMITIES

Iakovleva D25,508/54: MCs are particularly numerous in the connective tissue under the plantar skin of the rat paw.

Benditt et al. C13,402/55: An unusually large number of MCs is found in the paws of the rat.

Arvy C41,780/57: MCs are extraordinarily numerous in the paws of the rat, where they may form continuous sheaths around the tendons, vessels, and nerves.

SCROTUM

Arvy C41,780/57: There are many MCs in the scrotum and perineum of the rat.

HAIR

de Viñals D13,202/31: MCs are particularly numerous around the hair follicles in the mouse.

Montagna et al. D28,552/51: In the normal human skin of the mons pubis, intense metachromasia is observed in the papillae of growing hair follicles and in the cells of the external sheath. The adjacent MCs stain similarly, but no topographic relationship is noted between these and the diffuse metachromasia. "Metachromasia here described is visualized at acid *p*H and resists extraction in alcohol. The metachromasia in the hair papilla and in the external sheath is not abolished by testicular hyaluronidase, and may represent chondroitin sulfate B."

Kelsall & Crabb D26,076/59, *p. 107*: On MCs in hair follicles.

SCARS

Calleja D39,609/1896: Very few MCs are found in old cicatricial tissues of man.

Greggio D31,536/11: During the early stages of repair, MCs are virtually absent from abscesses and wounds in man, whereas they appear in large numbers later when the granuloma is transformed into permanent connective tissue.

Parish E4,391/64: "Wounds caused by skin biopsies of rats and guinea pigs, are followed immediately by local disappearance or damage to mast cells, and some of the granules may, for 24–48 hr., be found in the cytoplasm of fibroblasts and macrophages. This was followed by the appearance of more mast cells reaching a maximum number in 3–4 weeks, after which the numbers declined to about normal though none persisted in the scar."

HEAD

MOUTH, LIPS, GINGIVA

Raudnitz D28,536/1883: In man, numerous MCs are found in the lips, while they are comparatively scarce in the tongue.

Schwenter-Trachsler D27,711/08: MCs are plentiful in the lip of man.

Imanishi D63,800/37: MCs are abundant in the buccal mucosa and gingiva of the rat.

Todaro D63,791/38: MCs are numerous in the human gingiva and their number is augmented in the vicinity of carious teeth.

Todaro D39,783/39: MCs could not be demonstrated in the gingiva, palate, tongue, or lips of the rabbit, but they were present in variable amounts in the corresponding structures of man, monkey (*Semnopithecus entellus, Simia penicillata*), ass (*Equus taurus*), cattle (*Bos taurus*), sheep (*Ovis aries*), guinea-pig (*Cavia cobaja*), nutria (*Miopatamus cojpus*), mouse, dog, cat, lion, bat, and hedgehog.

Carranza & Cabrini D80,527/55: There are many MCs in the human gingiva. Their number is decreased, however, in acute necrotizing gingivitis.

Stella D63,057/55: A considerable number of MCs is found in the connective tissue of the human gingiva but some are present also in the epithelium under normal conditions. The MC count of the gingiva increases under the influence of various inflammatory processes, but degranulation is seen in pregnancy gingivitis.

Arvy C41,780/57: MCs are especially numerous in the lips and snout of the rat.

Takeda D63,362/58: In the normal human gingiva, one MC or less per $\times 400$ field of magnification is found. They are chiefly distributed along the small vessels in the lamina propria of the mucosa and they exhibit the usual histochemical reactions.

Calonius D39,832/59: The mean MC count in the human gingiva was "123 $\pm$ 88.9 cells, with a range of variation of about 20 to nearly 400 cells. Clinically healthy gingival papillae contained significantly more mast cells than were observed in the inflamed group. No difference could be established statistically between healthy and inflamed tissue subject to compression by a prosthesis."

Kelsall & Crabb D26,076/59, *pp. 86, 88, 115*: Discussion.

Carranza & Cabrini D65,112/59: In the oral mucosa of the rat, the MC count increases from the age of 3 days to 1 month and then decreases.

Dockrill G10,498/61: In the buccal mucosa of man, MCs tend to invade the epithelium that overlies a pathologic condition in the submucosa.

TEETH

Todaro D39,783/39: MCs were not seen in the alveolo-dental ligament or in the dental pulp in any of the following species: rabbit, man, monkey, ass, cattle, sheep, guinea-pig, nutria, mouse, dog, cat, lion, bat, and hedgehog.

Dockrill G10,498/61: In man, the pulp of the tooth is normally devoid of MCs but these appear "when tooth pulp is able to swell, as in pulp polyps."

Ebling & Barbachan E20,443/63: MCs are found in the periodontal membrane of the rat.

TONGUE

Raudnitz D28,536/1883: Comparative study of the MCs in the tongue of the dog, squirrel, cat, rat, rabbit, and man.

Nordmann D28,272/1885: MCs are numerous in the tongue of the dog.

Ballowitz D27,586/1891: Unusually many MCs are found in the tongue of the bat.

Lavdowsky D42,233/1895: MCs are plentiful in the tongue of the frog. They can be vitally stained, with methylene blue.

Solger D63,186/1897: Demonstration of MCs in the tongue of the dog.

Arnold D27,305/06: In the frog tongue, the MCs can readily be studied by vital stains.

Zimmermann D27,591/08: Most of the MCs in the tongue of the guinea-pig are situated at the borderline between mucosa and muscle, but some reach into the intermuscular connective tissue.

Staemmler D26,807/21: In the human tongue, MCs are particularly abundant in the subepithelial connective tissue, where they may sometimes form an almost uninterrupted line. Occasionally, MCs are found even within the epithelial lining of the tongue. In the depth of the organ, MCs are also plentiful, particularly around the glands and in the connective tissue between the muscle fibers. Age does not markedly influence the MC population of the tongue.

Lehner D27,094/24: Discussion.

Imanishi D63,800/37: MCs are plentiful in the tongue of the rat.

Drennan D26,722/51: MCs are particularly numerous in the tongue of man.

Compton B90,594/52: MCs are abundant in the tongue of the hamster.

Arvy C41,778/56; D65,694/55: In the tongue of *Rana esculenta,* there are numerous MCs.

Arvy & Quivy D27,966/55: Many MCs are found in the tongue of the dog at various ages.

Mota et al. C18,184/56: In the tongue of the dog, MCs are very numerous, mainly in the interstitial connective tissue of the muscle bundles but also in the lamina propria of the mucosa.

Kelsall & Crabb D26,076/59, *pp. 86, 115*: Discussion.

PALATE, TONSIL, AND PHARYNX

Zimmermann D27,591/08: In the soft palate of the guinea-pig, many MCs occur within the submucosa, but also in the tunica propria and around the small salivary glands and fat tissue. In the mucosa, some MCs reach almost into the epithelium.

Sussmann D27,432/11: MCs are frequently seen in hypertrophic or inflamed adenoids and tonsils of man.

Timphus D27,412/14; *Renn* D28,933/12: In the human tonsil, the MC count is very high.

Scevola D39,779/37: Description of the MC population in the palate, larynx, and pharynx of many animal species.

Scevola D27,701/38: The local MC count is very high in individuals with tonsillar hypertrophy and tonsillitis.

Todaro D39,783/39: MCs could not be demonstrated in the palate of the rabbit, but they were present in variable amounts in that of man, monkey (*Semnopithecus entellus, Simia*

penicillata), ass (*Equus taurus*), cattle (*Bos taurus*), sheep (*Ovis aries*), guinea-pig (*Cavia cobaja*), nutria (*Miopotamus cojpus*), mouse, dog, cat, lion, bat, and hedgehog.

Miskolczy-Fodor D31,580/50: MCs are normal constituents of the human tonsil.

Baglioni C16,539/54, *p. 184*: Discussion.

Stoeckenius D27,740/56: MCs are found in the human tonsil.

Filipo & Bernicchi D84,681/57: MC-proliferations are seen in the human tonsil, especially in cases of chronic inflammation with sclerosis.

Drabe D26,852/61: MCs are plentiful in the human tonsil, especially during chronic inflammation (normal material has not been examined).

Ali G14,207/64: MCs are especially numerous in the pharyngeal mucosa of man.

EAR

Arvy & Quivy D27,966/55: Numerous MCs are found at the base of the ear of the dog.

Riley & West C29,554/56: MCs are particularly plentiful in the external ears of cattle and pigs. Interestingly, the histamine content of such ears is highest in those layers in which the MCs are most numerous.

Arvy C41,780/57: MCs are particularly abundant around the root of the rat's ear.

Niccoli-Vallesi D39,807/56–57: In the skin of the external auditory meatus of man very few MCs are seen during embryonic life, but their number increases and reaches a maximum in senility.

Héroux D26,430/61: Detailed description of the MC distribution in the ear of the rat.

NOSE

Federici D27,595/06: MCs are particularly plentiful in the inferior turbinate of man.

Lehner D27,094/24; *Baglioni* C16,539/54, *p. 184; Kelsall & Crabb* D26,076/59, *pp. 86, 115*: Discussion.

Cattaneo D26,725/59: MCs are particularly numerous in the nasal mucosa and submucosa of patients who habitually suffer from epistaxis.

Carranza & Cabrini D65,112/59: MCs are scarce in the nasal mucosa of the rat.

Bryan & Bryan D26,624/59: MCs are not uncommon in the nasal secretion of man, especially in cases of food allergy.

Hussarek & Neuhold D26,850/60: In the human nasal mucosa, MCs are found especially underneath the epithelium, but occasionally also deep in the connective tissue.

Boréus E27,594/60: Quantitative determination of MCs in the nasal mucosa of the guinea-pig.

Orlandi D26,659/61: In the human nose, MCs are particularly numerous in the anterior portion of the septum, close to the locus valsalvae. Since these cells produce heparin, it is assumed that they may facilitate epistaxis.

Hlaváček & Lojda D68,124/63: MCs are normally present in the mucous membrane of the turbinates and maxillary sinuses of man.

Ali G14,207/64: MCs are especially numerous in the nasal mucosa of man.

EYE

Solger D63,186/1897: Demonstration of MCs in the eyelid of a child.

Lehner D27,094/24: Discussion.

Jorpes et al. D26,888/37: MCs are found in various parts of the eye in man and cattle. They are particularly abundant in the cornea near the limbus, but are also found in the iris, ciliary body, and choroid.

Holmgren D95,345/37: In the cornea of cattle there are few MCs except in the limbus region. It is assumed that these MCs may secrete heparin into the anterior chamber of the eye in order to prevent blood coagulation.

Holmgren & Stenbeck D26,779/40: The human cornea normally contains occasional MCs and exhibits a diffuse metachromasia which diminishes towards the limbus. The sclera is only very slightly metachromatic. In the normal choroid membrane, MCs are scarce except in the immediate vicinity of the vessels. In different parts of the eye, the MCs contain varying densities of granules; those of the iris contain the smallest number.

Zollinger D26,862/49: Normally, there are only few MCs in the iris and ciliary body and occasionally none were found, but the number is considerably increased in various forms of chronic inflammation.

Asboe-Hansen D26,784/50: Numerous large MCs are located in the human eye, particularly in the ciliary body and iris. In the retina, the choroid membrane, the sclera, and the subconjunctival tissue, MCs are found mainly around the blood vessels.

Asboe-Hansen B60,550/50: In the human eye, MCs are particularly abundant within the ciliary body and the corneal limbus, but they are seen also in the iris.

Asboe-Hansen B60,604/51: MCs are particularly numerous in the ciliary body of the human eye.

Compton B90,594/52: MCs are observed in the cornea of the hamster.

Günther D65,225/56: There are no MCs in the human cornea, but they are numerous in the limbus around it, as well as in the iris and ciliary body. In the palpebrae, the MC concentration is about the same as elsewhere in the skin. Comparatively few MCs are found in the muscles of the eye, the surrounding adipose tissue, and the tear glands.

Burton & Bensley D33,750/58: In the mouse, the MCs of the iris can be observed in vivo.

Weimar C71,862/58: In rats, "mast cells were never seen in the normal or wounded corneas but did occur in large numbers in the limbal tissues."

Kelsall & Crabb D26,076/59, *pp. 86, 115*: Discussion.

Larsen C67,796/59: The MC content of the uvea is particularly high in the guinea-pig and decreases in various species in the following order: rat, mouse, and rabbit. The highest number was invariably found in the choroid, especially in the posterior and thicker part of this membrane. In the ciliary body, considerably fewer MCs were found, and in the iris only few sections contained MCs.

Gemolotto & Patrone D64,690/61: In the human eye, MCs are especially plentiful in the ciliary body.

Kim D58,632/63: In the rat and guinea-pig anterior uvea, the MCs are irregularly distributed. In the ciliary body, few MCs are present, and in the iris only occasional MCs are seen near its insertion.

Cricchi G3,043/63; D34,314/63: MCs can be demonstrated throughout the choroid membrane of the guinea-pig eye.

Gróf et al. G17,921/64: In the eyes of cattle, the greatest MC concentrations are found in the conjunctiva, the optic nerve, and the ocular muscles. The sclera, iris, ciliary body, and choroid contained fewer MCs, while the cornea, lens, and retina were completely free of them. The histamine content of these tissues paralleled their MC concentration.

RESPIRATORY SYSTEM

LARYNX AND TRACHEA

Staemmler D26,807/21: In man, MCs are common in the mucosa of the trachea and the large bronchi, especially just underneath the epithelium. These MCs are small and contain coarse granules. Occasionally, they occur even within the epithelium itself. Less numerous but much larger coarsely-granulated MCs are found in the submucosa of the trachea. They are somewhat more abundant in adults than in infants less than one year old, but otherwise they do not appear to be markedly influenced by age.

Lehner D27,094/24: Discussion.

Scevola D39,779/37: Description of the MC population in the palate, larynx, and pharynx of many animal species.

Basserman G12,485/57: MCs are numerous in the bronchial epithelium and mucus (obtained by bronchoscopy) of man. Their number increases in various forms of bronchitis.

Kelsall & Crabb D26,076/59, *pp. 86, 115*: Discussion.

Messerklinger D26,431/60: MCs are plentiful in the maxillary sinus and trachea of man.

LUNG, PLEURA

Zimmermann D27,591/08: In the lung of the guinea-pig, MCs tend to accumulate, especially around the mucosal layer of the trachea and in the vicinity of the large vessels. In the cartilage of the trachea, no MCs are found. Large numbers of these cells are seen in the pleura, the peribronchial connective tissue, and the interlobular stroma, but a few MCs are also present in the alveolar septa.

Staemmler D26,807/21: In man, the lung is comparatively poor in MCs and those present are located preponderantly around the larger bronchi and blood vessels. None are

found in the alveolar septa. In various pulmonary diseases, particularly pneumonia and bronchopneumonia, the MC population is not especially affected but a considerable increase was found in cases of "brown induration" resulting from cardiac decompensation. Here, MCs are found even in the alveolar septa, presumably as a consequence of connective-tissue proliferation. Emphysema and edema of the lungs causes an increase in MCs only when there is hyperplasia of the connective tissue. Tumors of the lung do not significantly influence the MC population.

Sabrazès D65,653/22: Study of the MCs in the pleura of man under normal and pathologic conditions.

Brack D26,821/25: Discussion.

Holmgren D29,498/38: Demonstration of MCs in the lung of man, cattle, pig, dog, guinea-pig, rabbit, salamander.

Vallone D26,432/44: In the human lung, MCs are found particularly in the interalveolar septa and the loose connective tissue around blood vessels and bronchi.

Mendes Fagundes D39,676/49: In the guinea-pig, MCs are particularly abundant in the lung, especially around the bronchi and vessels. In the large arteries, diffuse metachromasia is seen, but this diminishes in the smaller arteries and is absent in veins.

Suomalainen & Härma D30,082/51: MCs are numerous around the bronchi of the hedgehog. Their number is increased during and immediately after hibernation.

Compton B90,594/52: MCs are scarce in the lung of the hamster.

Riley & West D39,662/53: The pleura of the ox is very rich in MCs and histamine.

Suomalainen C852/53–54: MCs are plentiful in the peribronchial tissue of the hedgehog.

Baglioni C16,539/54, *p. 183*: Discussion.

Arvy & Quivy D27,966/55: In the lung of the dog, MCs are found almost exclusively around the bronchi and blood vessels. On the other hand, the pleura is extremely rich in MCs and contains the largest number among all serous membranes (including the hepatic capsule) in this species.

Mota & Vugman D27,087/56: In the lung of the guinea-pig, numerous MCs are present not only around the bronchioles but also in the alveolar walls themselves.

Wegelius D67,713/56: In cattle and the horse, "the pleura pulmonalis showed a content of mast cells which was only a fraction of that in the liver capsule. The high histamine content found by Riley and coworkers when analyzing ox pleura seems to indicate that histamine is liberated not only from the mast cells, but also from other elements of the tissues."

Pernis et al. D39,793/58: The rat lung contains many MCs, especially around the bronchi.

Kelsall & Crabb D26,076/59, *p. 88*: Discussion.

Salvato C73,693/59; D27,641/62: MCs are particularly numerous in the bronchial connective tissue of normal man. In bronchial inflammation, particularly in bronchial asthma, they discharge their granules.

Holczabek D41,584/63: With suitable techniques, many MCs can be demonstrated in the pleura, perivascular connective tissue, around the bronchi and, to a lesser extent, in the alveolar walls of the human lung.

DIGESTIVE TRACT

Reviews: *Lehner* D27,094/24; *Brack* D26,821/25; *Ballantyne* D27,060/29; *Michels* C72,066/38; *Kelsall & Crabb* D26,076/59

Ballowitz D27,586/1891: The MC population of the intestine diminishes during hibernation in the bat.

Hardy & Wesbrook D28,474/1895: MCs are found in the intestinal tract of the rat.

Stintzing D31,578/1899; D30,650/1899: MCs are plentiful in gastric and duodenal tissue of various species including man.

Bois D27,594/04: The MCs in the intestinal mucosa of the pig "stand in no definite relation to the lumen of the canal, to the crypts, to any lamina or to the blood or lymph vessels."

Maximow B79,778/06: In the jejunal villi and submucosa of the rat, MC-like elements are common. However, these are believed to be plasma cells with granules whose metachromasia — unlike that of true MCs — is demonstrable only in weak alkaline, and not in strongly acid solutions. Some workers referred to these cells as "plasma mast cells" (*Krompecher* D28,-276/1898; *Michels & Globus* D27,709/29).

Zimmermann D27,591/08: In the esophagus of the guinea-pig, MCs are plentiful within the submucosa and underneath the muscularis mucosae. A few of them are actually within the muscular wall. In the stomach, most of the MCs are in the mucosa close to the glands, as well as in the submucosa around the blood vessels. In the muscularis, there are only few of them, but in the serosa they frequently form small cell aggregates. In the colon, there are MC accumulations in the mucosa, next to the glands and lymph follicles and particularly in the submucosa. MCs are also found in this species within the villi of the small intestine.

Sansonow D27,433/08: A detailed study on the MCs of the intestine in various vertebrates leads to the conclusion that the greatest concentration of these cells occurs in the appendix. MCs also are plentiful in other parts of the intestinal tract and tend to migrate between the epithelial cells of Lieberkühn's crypts.

Schwenter-Trachsler D27,711/08: MCs are plentiful in the mucosa of the human small intestine.

Séguin D27,447/12: MCs are numerous in the mucosa of the large intestine in the horse, but their granules are water-soluble and, hence, may be lost after aqueous fixation. Similar cells are plentiful in the submucosa where they are water insoluble.

Timphus D27,412/14: In the human intestine, the number of MCs is extremely variable.

Weill D27,707/20: MCs are regularly found in the interglandular spaces of the intestinal mucosa in dogs.

Staemmler D26,807/21: In the intestinal tract of man, MCs are found especially within the submucosa, although some are also present in the muscularis.

Jordan D27,521/26: The intestinal tract of various fish is unusually rich in MCs.

Nagayo D26,871/28: During inanition, numerous MC granules are eliminated through the intestinal epithelium of the rat.

Chyujo D64,795/28: Description of the MC population in the rat stomach.

Bolton D28,256/32: "Basophilic granule cells which occur in vast numbers in the connective tissue throughout all regions of the alimentary canal of sockeye salmon and speckled trout are interpreted as histogenous mast cells. Their occurrence in several other species is noted. None could be found in blood or in any other organs."

Plenk D39,521/32: MCs are present in the wall of the human stomach.

Quensel D26,221/33: In the normal stomach of man, MCs are not found in the mucosa itself, although occasionally they occur in the muscularis mucosae. They are particularly numerous in the loose connective tissue of the submucosa and in the connective tissue of the muscularis.

Konjetzny D39,522/38: There are many MCs in the human stomach.

Manzini & Conti D30,664/38: MCs in the human stomach are most frequently situated in the submucosa and the connective tissue of the muscularis.

Duthie D27,611/39: Unusually numerous MCs are found in the intestinal tract of various fish.

Vallone D26,432/44: In the stomach of man, MCs are particularly numerous within the mucosa and submucosa as well as in the interstitial connective tissue of the muscular coat.

al-Hussaini D27,614/49: In the intestinal tract of fish there are especially many MCs.

Bruni et al. D30,647/50; *Bruni & Caschera* D30,634/52: Study of intestinal MCs.

Suomalainen & Härma D30,082/51: MCs are numerous in the small intestine of the hedgehog. Their number is increased during and immediately after hibernation.

Drennan D26,722/51: In the human esophagus, MCs are plentiful, especially in the vicinity of the large veins in the submucosa.

Corbetta D26,439/51–52: Description of MC distribution in the stomach of man.

Cambel et al. D24,770/52: MCs have been observed both in the wall of the stomach and in the gastric secretion of rats, but not in those of rhesus monkeys or guinea-pigs. It is assumed that, in the rat, MCs move into the gastric secretion by ameboid motion.

Suomalainen C852/53–54: MCs are plentiful in the connective tissue of the intestine in the hedgehog.

Kelsall & Crabb D39,634/54: The MCs are more numerous in the connective tissue surrounding mucous alveoli than in that of the serous alveoli in the Brunner's glands of the hamster.

Arvy & Quivy D27,872/55: In the dog, the esophagus and colon are relatively poor in MCs while the stomach and duodenum contain many. This distribution roughly parallels the histamine content of these intestinal segments and constitutes additional proof of the presence of histamine in MCs.

Arvy & Quivy D27,966/55: In the dog, the MC population of the esophagus is less dense than that of the stomach where these cells are most numerous along the smaller curvature, while the pyloric region contains comparatively few of them. In the intestinal tract, the number of MCs diminishes from the duodenum to the colon and throughout the intestinal tract they are most numerous in the muscularis mucosae and in the stroma of the villi.

Arvy D65,694/55; C41,778/56: In *Rana esculenta,* there are numerous MCs in the intestinal tract.

Hunt & Hunt D27,054/56: In the intestine (segment not mentioned) of the rat, MCs are especially numerous in the villi and between the glands, as well as in the submucosa. They are very resistant to the induction of degranulation by 48/80.

Blomquist C34,388/56: The MC count in the submucosa of the guinea-pig is approximately 4,500 per cm^2.

Mota et al. D27,629/56; C31,032/56: In the rat, MCs are present in the tongue, esophagus, fore-stomach, but practically absent from the glandular stomach, duodenum, ileum, and rectum. In the dog, cat, and guinea-pig, MCs are numerous throughout the whole of the digestive tract. In the tongue and esophagus, MCs are found mainly within the submucosa and lamina propria near the epithelium. In the stomach, they are more numerous in the mucosa and concentrated in the muscularis mucosae between the necks of the glands. In the ileum and rectum, MCs are less numerous than in the stomach. In general, the histamine content of the various intestinal segments parallels their MC content.

Squartini et al. D30,195/56; D30,649/56: MCs are plentiful in the stomach and duodenum of man. In the normal duodenum of man, the MC count corresponds to 2.85 per 0.04 mm^2. More or less considerable increases are seen in peptic ulcer, carcinoma, and sarcoma, simultaneously with an increase in diffuse stroma metachromasia.

Johnson & McMinn D63,535/57: Comparatively large numbers of MCs are constantly present in the basal layers of the esophageal epithelium in the cat. The cranial two-thirds of the esophagus contain fewer MCs than the caudal third.

Zwillenberg D42,931/58: The "high-level dendritic cells" with long, slender processes that are demonstrable in various non-epidermal stratified squamous epithelia (esophagus, vagina, portio vaginalis uteri) and their basal counterparts generally contain granules which stain metachromatically with toluidine blue in vivo. The granules are unevenly distributed but often lie in pairs. They frequently occur together with typical intra-epithelial MCs which, here, likewise tend to assume a dendritic shape in that they form processes which protrude between the Malpighian cells. Such intra-epithelial MCs are common in the esophagus of the cat and Macaque, but rare or absent in the esophagus of the pig and cow. In the vaginal epithelium of women and Macaques, the occurrence of intra-epithelial MCs is variable.

Räsänen D27,066/58: MCs are found in the lamina propria of the human stomach, beginning on the fourth month of embryonic life. There are no significant differences in the MC frequencies between different parts of the stomach.

Siurala & Sundberg D27,075/58: The mean MC count in human gastric mucosa obtained by suction biopsy, is $79 \pm 8.6/mm^2$.

Lindholm C70,944/59: Detailed study of MC distribution in the human alimentary tract showed the highest count in the esophagus although the rectum also had a greater number of MCs than other parts of the gut.

Godlewski D26,858/59; E51,439/60: In the human intestinal tract, MCs are particularly numerous along the ileocecal junction and in the appendix.

Lindholm D26,614/60: In the gastrointestinal tract of the hamster, MCs are most numerous in the esophagus and small intestine, while the large intestine and rectum showed the smallest number. In the rat, the MC distribution was essentially similar, the small intestine and esophagus showing the largest number.

Räsänen C81,536/60: In the stomach of the rat, MCs are most numerous within a narrow strip of the glandular stomach, immediately below the surface epithelium.

Räsänen D3,451/61: MCs are numerous in the lamina propria of the gastric mucosa in the rat.

Foley & Glick D39,767/62: The gastric mucosa of the rat is rich in MCs.

Nozaka & Simpson D63,181/62: In the pyloric part of the human stomach, numerous MCs are found in the submucosa and muscularis. Their number increases with advancing age.

Norris et al. D68,628/63: Extensive studies on the distribution of MCs in the human gastrointestinal tract.

Thompson et al. F3,698/64: In the normal gastric mucosa of the dog, the mean number of MCs is 566 per mm^2.

Astaldi et al. G19,343/64; G18,060/64: As judged by biopsy specimens, MCs are constantly present in the submucosa of the human jejunum while in the tunica propria they lose their granules and may no longer be demonstrable during digestion. It is assumed that the MCs participate in the regulation of intestinal activity.

Salivary Glands

Zimmermann D27,591/08: Both in the small salivary glands of the palate and in the parotid gland of the guinea-pig, MCs are plentiful within the alveolar connective tissue and fat.

Staemmler D26,807/21: MCs are not particularly plentiful in the salivary glands of man although some can be found in the stroma. Their number is decreased in acute inflammations.

Bruni & Olivi D39,592/51: In the human parotid gland, MCs are usually numerous.

Kelsall & Crabb D28,690/53: MCs are more numerous in the sublingual gland (mucous) than in the submaxillary or parotid glands (chiefly serous) of the hamster. "The number, position and extrusion of granules of mast cells in the sublingual gland, suggest that these cells may provide mucopolysaccharides for mucous alveolar cells."

Arvy & Quivy D27,966/55: In the dog, few MCs are found in the stroma of the submaxillary and parotid gland.

Niccoli-Vallesi D31,597/56–57: In the submaxillary gland of the rat, both the number and the granule content of the MCs undergo considerable variations which reflect the functional activity of the glands.

Kelsall & Crabb D26,076/59, *pp. 87, 109*: Discussion.

Liver

Gherardini D39,596/1898: MCs are plentiful in the bovine liver but their number is further increased in *Echinococcus* infection.

Zimmermann D27,591/08: In the liver of the guinea-pig, MCs are especially numerous within the capsule, especially around the hilum. In the interlobular connective tissue, there are only few MCs.

Staemmler D26,807/21: The human liver is very poor in MCs and those that are demonstrable lie within the capsule or the perilobular connective tissue. Various hepatic diseases have little influence upon the abundance of MCs, except cirrhosis, which causes a considerable increase. In hepatic tumors, MCs are not abundant.

Nagayo D26,871/28: The liver of the dog is unusually rich in MCs.

Quensel D26,221/33: The human liver is very poor in MCs.

Holmgren D95,345/37: The hepatic capsule of cattle contains very many MCs.

Jorpes D27,887/38: In the cow, the liver capsule is much richer in MCs than the liver tissue itself. The heparin content of these tissues roughly parallels their MC population.

Holmgren D29,498/38: Demonstration of MCs in the liver of man, cattle, pig, dog, guinea-pig, rabbit, salamander, and alligator.

Schürer D40,720/46: Large MCs of the "Kugelhaufen" type are found on the capsule of the rat liver, but not within its parenchyma.

Mendes Fagundes D39,676/49: In the guinea-pig, MCs are particularly abundant in the hepatic capsule and hilum. In the large arteries, diffuse metachromasia is seen but this diminishes in the smaller arteries and is absent in veins.

Compton B90,594/52: MCs are scarce in the liver of the hamster.

Riley & West D39,662/53: The liver capsule of the ox, sheep, and cow, as well as ox pleura, is very rich in MCs and histamine.

Arvy & Quivy D27,966/55: In the dog, MCs within the liver tissue are most plentiful in the portal spaces.

Arvy D65,694/55: No MCs are found in the liver of the frog (*Rana esculenta*).

Hjelmman & Pettersson D39,850/55: MCs are found in clumps within the connective-tissue stroma, as well as in the interior of the lobules, particularly around the central veins in the guinea-pig.

Mota et al. C18,184/56: In the dog, the liver is particularly rich in MCs. They are predominantly arranged along the sinusoids and the throttle veins. Frequently, they are so closely attached to the endothelium that they appear to be part of it.

Wegelius D67,713/56: In cattle and horses, the hepatic capsule contained 5–10 times as many MCs as other tissues.

Hjelmman & Wegelius E20,252/56: The hepatic MCs of the toad (*Bufo bufo*), unlike those of the frog (*Rana temporaria*), show a great increase in number following exposure of the animals to low surrounding temperatures.

Kelsall & Crabb D26,076/59, *pp. 91, 96*: Discussion.

Togawa D39,528/60–61: Very few MCs are found in the stroma of the healthy human liver, but their number is greatly increased in chronic viral hepatitis, especially when combined with cirrhosis.

Coupland & Heath D2,440/61: In the hepatic capsule and gut of cattle and sheep, there are dopamine-containing MCs.

PERITONEUM

Review: *Michels* C72,066/38

Hardy & Wesbrook D28,474/1895: MCs are found in the peritoneum of the rat.

Ranvier D31,525/00; *Kanthack & Hardy* D28,369/1894–95; *Jolly* D27,449/00; *Weidenreich* D33,716/07: MCs are present in the peritoneal fluid of the rat.

Zimmermann D27,591/08: Particularly abundant MC accumulations are found in the mesentery of the guinea-pig, where they exhibit a very polymorph appearance. Elsewhere in the peritoneum, they tend to accumulate underneath the serosa, in the vicinity of fat tissue.

Sabrazès D65,653/22: Studies of the peritoneal MCs of man under normal and pathologic conditions.

Nakajima D39,782/28: MCs are plentiful in the peritoneal fluid of the rat and mouse, but they are absent in the peritoneal fluid of the rabbit, monkey, dog, cat, and guinea-pig.

Nagayo D26,871/28: In the peritoneal fluid of rats and mice, MCs are numerous, representing 3.5 and 1 per cent respectively, of the total cell population. However, no MCs could be found in the peritoneal fluid of man, monkey (*M. fuscatus*), dog, cat, guinea-pig, and rabbit.

Webb D27,897/31: MCs represent 7.36 ± 0.38 per cent of the free peritoneal cells in the rat.

Webb D26,822/34: A study of the MC population in the peritoneal fluid of the white rat between birth and sexual maturity revealed that "there is proportionately more fluid within the body cavity of the young rat than in the adult, whereas the number of cells per cubic millimeter is less," hence, the apparent increase in MCs may be explained in terms of their concentration, rather than in terms of an actual change in total number.

Schürer D40,720: Large MCs of the "Kugelhaufen" type are found in the peritoneal fluid of the rat.

Compton B90,594/52: MCs are very numerous in the mesentery of the hamster.

Padawer D64,997/54: Comparative studies on the peritoneal MCs of the mouse, guinea-pig, hamster, rabbit, and rat.

Padawer B95,453/54: There appears to be an essential difference between the MCs within the mesentery and those in the peritoneal or pleural fluids of the rat. The former are more irregularly shaped, the latter spherical or slightly ovoid; furthermore, the mesenteric, unlike the pleural and peritoneal MCs, do not respond readily to adrenalectomy, the stress of surgical operations, or hypophysectomy.

Padawer & Gordon D27,053/56: The MC content of the peritoneum shows great species variations as judged by comparative observations on the rat, mouse, guinea-pig, hamster, rabbit, cat, and monkey.

Padawer & Gordon C21,135/56: The peritoneal MCs of the rat show age dependent variations in number and shape. "The possibility exists that mast cells are affected differently depending on the site they occupy within the organism. We believe that this is not the case . . ."

Sumi C60,846/58: There are many MCs in the omentum of the mouse.

Cricchi D34,314/63: Both in the rat and in the guinea-pig, the MCs of the mesentery are situated not only along the blood vessels but also diffusely, often forming small cell accumulations.

THYMUS

Reviews: *Michels* C72,066/38
Kelsall & Crabb D26,076/59, *pp. 88, 92, 101*

Zimmermann D27,591/08: The MCs in the thymus of the guinea-pig are situated within the connective tissue of the stroma. MCs are particularly numerous in calf thymus tissue.

Maximow 87,251/09: Description of cells which may have been MCs in the thymus of embryos of various species.

Weidenreich A25,630/12: In the human thymus, MCs are formed from thymocytes since many transitional types can be seen between the two.

Barbano D29,284/12: MCs appear to develop from cells with eosinophilic granulation in the course of involution in the human thymus.

Weill A1,826/13: MCs are constantly found in the thymus of rat and man, but in the rat they are located only within the stroma, while in man they are found also in the midst of the thymus tissue itself. Many of the thymic MCs of man appear to be transitional forms in the evolution of these cells from plasma cells.

Staemmler D26,807/21: In the thymus of a seven-month-old human fetus, no MCs could be detected but they were constantly present during postnatal life from infancy to senility. Unlike in most other organs, here they occur not only in the connective tissue, but also in the purely lymphatic portions. However, their number is greatest in the interlobular connective tissue.

Lehner D27,094/24, *p. 160*: Discussion.

Argaud & Pesqué 90,375/29: The human thymus normally contains very few MCs but their number increases considerably in bronchopneumonia and diphtheria.

Peter D29,160/35: In the hedgehog, the thymic MCs greatly increase in number during the beginning of hibernation and then discharge their granules, gradually disappearing as the winter season progresses.

Baker et al. B63,170/51: Description of the MC distribution in the thymus of the rat.

Katzberg D28,661/54: In the rat thymus, MCs are located at the surface and in the stroma. "None were encountered in the cortex or medulla."

Benditt et al. C13,402/55: The thymus of the rat is particularly rich in MCs.

Arvy & Quivy D27,966/55: In the thymus of the dog, there are but few MCs in the stroma, whether the animals are young or old.

Allara C68,999/59: In the hedgehog (*Erinaceus europaeus*), there are numerous MCs in the stroma of the thymus under normal conditions, but their number diminishes sharply during hibernation, induced by exposure to cold during the fall season.

Csaba D2,230/60: MCs are numerous in the human thymus and on the basis of indirect evidence, it is assumed that many of them may originate there.

Klug D27,650/61: The rat thymus contains numerous MCs.

Klein E26,609/63: Transitional stages between large thymocytes and MCs are described. Theoretic considerations suggest that the thymic MCs may participate in tumor defense.

LYMPH NODES AND LYMPH VESSELS

Reviews: *Michels* C72,066/38
Baglioni C16,539/54, *p. 192*
Kelsall & Crabb D26,076/59, *p. 100*
Lennert & Illert D26,831/59

Drzewina D27,511/03: The lymph nodes of the opossum (*Didelphis lanigera*), may contain up to 150 MCs per mm^2. Most of these cells are in the capsular and septal connective tissue, but they also occur in the interfollicular reticulum.

Zimmermann D27,591/08: Most of the MCs in the lymph nodes of the guinea-pig are within the capsule and the stroma.

Downey D26,823/13: Detailed study of MC formation in the lymph nodes of the guinea-pig, cat, and man.

Timphus D27,412/14: MCs are constantly present in human lymph nodes during postnatal life although they have not been seen in the embryo. They frequently invade the lumina of the sinusoids and have once been seen in a blood capillary.

Forkner D33,709/27: In man, MCs are present though in small numbers in normal lymph-node specimens obtained by biopsy.

Dawson & Masur D28,377/29: Occasional MCs only are encountered in the inguinal lymph nodes of the rat.

Forkner D28,957/29: MCs were found in all lymph nodes of the rabbit. They frequently occur in groups of two or three cells.

Hoepke & Westenhoeffer 66,679/35: Debris of MCs can be found in the lymph vessels of the hedgehog.

Dreyfus E57,445/40: MCs are not uncommon in the lymph nodes of man.

Moeschlin D30,597/41: In specimens of human lymph nodes obtained by punch biopsy, MCs are fairly numerous.

Güttner D26,843/42: In human lymph nodes, the MCs are most numerous in the hilus region and in the sinusoids, but some occur also within lymphatic tissue itself.

Janes & McDonald B32,304/48: A moderate number of MCs are found in normal human lymph nodes.

Kluth D26,437/51: Although no tissue MCs occur in circulating blood, a small number of them can be detected in the lymph of the thoracic duct. It is assumed, therefore, that the MCs of the lymph are destroyed during their passage through the lung.

Dunn D27,626/54; *Spicer* C92,580/60: An increased number of MCs in close association with siderophages are seen in the lymph nodes of aged mice.

Katzberg D28,661/54: In the rat, "the capsule of the lymph node was devoid of mast cells while fairly large aggregates could be found within the cortex and medulla. None were present in the germinal centers. The cells were more rounded and appeared to have less free space between granules than was the case in the thymus."

Lucas D27,726/55: MCs are normal constituents of human lymph nodes.

Cazal D26,655/55: Normally, the MC count in the lymph nodes of man is low, corresponding to one MC per thousand nucleated cells on smears. The MC count increases, however, in various forms of subacute and chronic lymphadenitis.

Arvy et al. C41,781/56: Following application of histamine dischargers, the resulting anaphylactoid reaction is associated with an accumulation of disintegrated MC debris in the regional lymph nodes of the rat.

Ziliotto & Pellegrini D27,056/56: In patients with reticulum cell tumors, hepatic cirrhosis with venous stasis, and splenectomy because of Banti's disease, the MCs undergo striking changes which led to the conclusion that one function of the MCs may be "to exert a plastic effect upon the reticulum."

Ito E57,790/56–57: MCs are numerous in the popliteal lymph node of the rat.

Arvy D65,087/58: MCs are very scarce in the lymph nodes of the rat.

Lennert et al. D26,817/59: In chronic lymphadenitis in man, there is an increase in the MCs of the lymph nodes.

Lennert & Illert D26,831/59: In human lymph nodes, the MCs are situated partly in the pulp, where they often have reticulum-cell-like shapes with long processes, and partly in the sinuses where they are roundish.

Wilke E38,744/63: In patients with laryngeal carcinomas, the regional lymph nodes contain many plasma cells but the MC count is not regularly increased.

Takeoka et al. E20,322/63: Quantitative determination of the MC count in various lymph nodes of the bat.

SPLEEN

Zimmermann D27,591/08: In the guinea-pig, numerous MCs are found in the capsule of the spleen, but some of them are also in the stromal connective tissue. Within the pulp, the metachromatic cells exhibit the characteristics of blood basophils.

Timphus D27,412/14: In the human spleen, MCs are found particularly in the stroma and capsule and only rarely in the adjacent pulp parenchyma. In the lymphatic follicles of the spleen, they are exceptional.

Quensel D26,221/33: The human spleen is extremely poor in MCs.

Schürer D40,720/46: Large MCs of the "Kugelhaufen" type are found in the capsule but not in the depths of the rat spleen.

Katzberg D28,661/54: The rat spleen is almost devoid of MCs, only two or three being encountered on sections traversing the entire organ.

Arvy & Quivy D27,966/55: In the spleen of the dog, MCs are common in the capsule but rare in the parenchyma.

Ende & Cherniss D39,554/58: Only occasional MCs are detectable in the normal human spleen.

Ende & Cherniss C55,644/58: Splenic imprints from patients suffering various diseases show that 0–0.25 per cent of all nucleated cells are MCs. The highest count was found in a case of progressive spinal muscular atrophy. In a patient with mastocytosis, the values were far in excess of the norm.

Verga & Pezzani C83,626/59: In the spleen of the rat, MCs are found only in the capsule, while in the thymus and the mesenteric lymph nodes, they are present also within the parenchyma.

Kelsall & Crabb D26,076/59, *p. 104*: Discussion.

BONE MARROW

Reviews: *Lehner* D27,094/24; *Michels* C72,066/38; *Bremy* C72,062/50; *Mota* D26,756/51; *Baglioni* C16,539/54, *pp. 185, 224*

Zimmermann D27,591/08: MCs are rarely found in bone and bone-marrow tissue of guinea-pigs.

Maximow D29,301/10: In a large series of mammals examined, the bone marrow contained both "histogenic" and "hematogenic" MCs.

Benacchio D27,417/11: In the bone marrow of the rabbit and guinea-pig, there are allegedly no MCs. The coarse granular basophils that have been thought to be MCs are actually basophil-granulated, immature myelocytes, despite their metachromasia. They contain alpha granules and not gamma granules such as are found in true MCs.

Kardos D27,980/11: No MCs could be demonstrated by any technique in the bone marrow of the rabbit and guinea-pig.

Klieneberger D27,442/12: Large "basophilic granule clumps" (basophile Kugelhaufen) are regularly demonstrable in the bone marrow of the rat and mouse.

Maximow D29,280/13: Unlike in all other species examined, possible intermediate forms between MCs and mast myelocytes are found in the bone marrow of the rat. On the other hand, in lower vertebrates, particularly urodele amphibia, blood basophils which migrate into the tissues can transform themselves into MCs.

Ringoen D27,738/15: On properly fixed preparations of rabbit bone marrow, MCs can always be demonstrated.

Lauda & Flaum D26,828/29: The basophil "Kugelhaufen" may or may not be MCs, because, unlike the latter, they do not stain violet but deep blue with Jenner's stain. Re-examination of these structures showed their granules to be tingible with methylene blue, gentian violet, fuchsin, and Nile blue sulfate. They also stain slightly metachromatically with cresyl violet but the granules cannot be extracted with lipid solvents. The "Kugelhaufen" could be macrophages having ingested some special metabolite of the mouse and rat and are not considered to be MCs. They possess a distinct natural yellow color of their own and stain metachromatically with a number of aniline dyes. The granules contain oxidase but no doubly-refractory material.

Forkner D27,716/29: Metachromatic cells were found in the bone marrow of the domestic fowl. However, these might have been blood basophils.

Stasney & Higgins D27,357/35; *Jordan* D27,356/38; *Michels* C72,066/38: The bone-marrow tissue of rats always contains MCs.

Vallone D26,432/45: Allegedly, no MCs are found in the bone marrow of man.

Endicott & Ott D27,358/45: Description of bone-marrow MCs in the rat.

Schürer D40,720/46: Description of the basophil "Kugelhaufen."

Vogel B3,641/47: In femoral bone-marrow biopsies of rats, MCs are often missing and are rarely numerous.

Cameron & Watson B31,287/48: In femoral bone-marrow biopsies of normal rats, MCs were not constantly present and, on the average, represented 0.1 per cent of the total cell population.

Kabelitz D33,664/49: Two types of MCs are found in human sternal bone marrow: type 1 has a small, round, dense nucleus, type 2 a larger oval nucleus with a fine chromatin network.

Lopez-Netto et al. D27,359/49; *Mota* D26,756/51: Observations on thick bone-marrow smears of the rat revealed that in the femur, tibia, and humerus, the MC count is much higher than in the sternum or ribs.

Bremy C72,062/50; *Hauser* D26,883/53: The normal human bone marrow allegedly contains no tissue MCs.

Fadem D26,720/51: Tissue MCs were found only in 7 out of 2,800 human bone marrows studied and are, hence, considered to be abnormal constituents of human bone-marrow tissue. Their appearance is frequently associated with a depression of bone marrow activity and "it is suggested that when they accumulate in substantial numbers, they may cause marrow depression by elaborating growth inhibiting concentrations of heparin."

Williams D27,399/52: Although in a series of 325 patients, MCs were found in the bone marrow in only 56 cases, it is concluded that "tissue mast cells in small numbers are a normal constituent of human bone marrow."

Viñals D30,196/54: MCs are commonly found in the human bone marrow under normal conditions, but their number is increased in aplastic or inflamed marrow. For the demonstration of bone-marrow MCs, it is necessary to use certain techniques among which Löffler's procedure is the best.

Johnstone C11,069/54: Bone-marrow MCs could be found in 30 per cent of a series of 139 patients taken at random. Their proliferation appears to be enhanced by anemia and splenomegaly due to various causes.

Astaldi et al. D39,597/54: As judged by histochemical studies, the MCs of the human bone marrow contain no lipid but are rich in acid mucopolysaccharides. They also contain proteins "whose composition includes tryptophan and either histidine or tyrosine or both."

Iakovleva D25,508/54: In the bone marrow of the rat, the MC density varies greatly in different parts of the skeleton. In general, the bone-marrow MCs are large but contain comparatively few granules.

Messerschmitt D26,705/54: Among 277 patients who died of different diseases, MCs were found on bone marrow smears in 54 per cent of the cases.

Messerschmitt D26,636/55: In a series of 350 patients who suffered from various diseases, MCs were identified in bone-marrow smears in 56.7 per cent of the cases.

Cazal D25,410/55: Detailed description of the MCs in human bone marrow.

Johnstone C13,670/56: Normally, the human bone marrow contains only few MCs but their number increases in various forms of anemia.

Ende & Cherniss D39,554/58: A small number of MCs is normally found in the human bone marrow but they rarely exceed 1 per cent of the nucleated elements.

Sumi C60,846/58: Description of human bone-marrow MCs.

Lennert et al. D26,817/59: Detailed review on the bone MCs of man. Mast cells were present in every bone marrow examined, but they were most markedly augmented in cases of lymphadenosis, panmyelophthisis, and morbus Waldenström. There are bone-marrow MCs which contain highly-acid mucopolysaccharides (presumably heparin) and which stain with toluidine blue only at a low *p*H, while others (assumed to be hyaluronic acid esters) are less acid and subject to destruction by hyaluronidase. Only about two-thirds of the bone-marrow MCs are tingible with PAS.

Stutzman et al. C95,789/60: Review on the MC distribution in the spleen and bone marrow of men.

Takeoka et al. E20,322/63: Quantitative determination of the MC count in the marrow of different bones in the rat.

Juhlin E98,089/63: In patients suffering from various diseases, no correlation was found between the percentage of basophils in blood and bone marrow. Cells definitely

recognizable as tissue MCs were found in only 38 per cent of the bone-marrow specimens examined.

Morel & Perrin E4,489/64: Tissue MCs can occur in human bone marrow but they become numerous only under pathologic conditions. They must not be confused with basophils.

BONE

Mast cells do not normally occur in solid bone, but a large number of them accumulate along the endosteum in rats kept on a low calcium and vitamin-D deficient diet (cf. Dietary Factors Influencing Mast Cells, *p.* 237).

CARDIOVASCULAR SYSTEM

Reviews: *Baglioni* C16,539/54, *p. 184*
Kelsall & Crabb D26,076/59, *p. 88*

Browicz E25,818/1890: MCs are not found in the heart of newborn babies and are rare in infants, but increase in number as the individual reaches maturity.

Münchheimer A47,205/1895: Unlike in adults, MCs are absent in the cardiac muscle of newborn babies.

Zimmermann D27,591/08: In the guinea-pig, numerous MCs are found in the connective tissue and fat underneath the epicardium and in the adventitia of both small and large vessels.

Staemmler D26,807/21: MCs are found in moderate quantities between the muscle fibers and underneath the epicardium of the human heart. During the first years of life, they may be virtually absent and later they develop in proportion to the growth of the stroma. Their number is increased in the brown atrophy of the heart and in fibrous myocarditis, presumably again as a consequence of connective-tissue proliferation.

Quensel D26,221/33: In the cardiac, as in the skeletal musculature of man, MCs are sparse and localized only between the muscle fibers in the connective tissue.

Hoepke & Westenhoeffer 66,679/35: Debris of MCs can be found within the capillaries of the hedgehog.

Holmgren D95,345/37: The aorta and vena cava of cattle contain very many MCs. In the vessels they often accumulate just underneath the endothelium where heparin, liberated from their granules, may exert an anticoagulant action.

Jorpes et al. D26,888/37: MCs are numerous in the vena cava and, to a lesser extent, in the aorta of the cow and horse, while the aorta of the pig contains but very few MCs. In all these sites, the heparin concentration corresponds roughly to the MC density.

Jorpes D27,887/38: The aorta of the pig contains no MCs while both the aorta and the vena cava of cattle are rich in them. The heparin content of these tissues roughly parallels the density of their MC population.

Hellström & Holmgren D39,611/47: Quantitative analysis of the MC count in human skin and heart tissue shows a gradual drop between birth and senility.

Mendes Fagundes D39,676/49: In the guinea-pig, MCs are particularly abundant in the lung, especially around the bronchi and vessels. In the large arteries, diffuse metachromasia is seen but this diminishes in the smaller arteries and is absent in veins.

Hellström & Holmgren D25,620/50: Detailed description of the cardiac MCs in man.

Cairns & Constantinides C3,038/54: MCs are quite numerous in the human myocardium.

McGovern D31,617/55: Many MCs can be found beneath the endothelium of blood vessels in man. A few hours after death, the MC granules disappear and bubbles of metachromatic material seep through the endothelium causing the surface protein layer and intercellular cement lines to spread. This change is reproduced by histamine-releasing agents that cause an anaphylactoid reaction. "Neither histamine nor heparin separately or combined causes any anaphylactoid state in the rat, so that it seems that mast cells must produce a further substance which changes the consistency of the surface protein film of endothelial surfaces and alters their permeability. Mast cells are very scanty around small blood vessels in the

brain and choroid plexus of both rats and humans. Nor can they be found in the leptomeninges. This may be a factor in maintaining the blood brain barrier."

Hjelmann & Wegelius E20,252/56: The cardiac MCs of the toad (*Bufo bufo*) and the frog (*Rana temporaria*) show a considerable increase following exposure to low surrounding temperatures. This is interpreted as a defense measure against threatening blood coagulation.

Nepriakhin D26,879/56: In man and dog, the organs richest in MCs are the thymus, tonsils, tongue, gastrointestinal tract, uterus, and mammary gland. In all these organs, the MCs tend to lie preferentially in the vicinity of arterioles, venules, and capillaries, as well as in the small branches of the lymphatic vessel system.

McGovern D26,767/56: The endothelium of the peritoneum, pleura, and blood vessels has a very similar structure. There is a surface layer of argyrophilic protein material and argyrophilic cement lines separating the individual endothelial cells. Underneath the epithelium and closely attached to it are the MCs. When the peritoneum of the rat is mildly irritated by topical application of 1 per cent acetic acid or 48/80, there is an increased production of the surface protein film and imbibition with metachromatic substance of both the cement lines and the surface film, this being associated with degranulation of the subendothelial MCs. The so-called stigmata or stomata, which were thought to appear on the borderline between endothelial cells, are actually bubbles of metachromatic material which have an argyrophylic outline. "It is postulated that capillary permeability is partly due to a spreading factor, produced by mast cells, which acts on the surface protein layer of the endothelium."

Pollak D26,440/57: In the human heart, MCs are situated in the interstitial tissue and the epicardium, often in proximity to small blood vessels. In recently-infarcted areas, the MC density is the same as in adjacent normal areas, but organized infarcts contain virtually no MCs, save for isolated ones in the periphery of the scar tissue.

Stolk D65,681/59: Numerous MCs are found in the myocardium of various fish.

Fernex D26,660/61: Extensive study of the cardiac MCs of man under normal and pathologic conditions.

JOINTS

Davies D26,745/43: The frequency of MCs in the synovial membrane is demonstrated by studies on various joints of man, monkey, rabbit, rat, mouse, cat, and cattle. The synovial membrane itself can be stained with mucicarmine and metachromatic dyes both before and after treatment with hyaluronidase. It remains to be seen whether the MCs participate in the production of synovial mucin.

Ducci D39,802/46: A comparatively large number of MCs is present in the synovial membranes of man from infancy to adulthood; only with highly advanced age does their number diminish.

Janes & McDonald B32,304/48: In man, MCs are particularly numerous in the mesothelial layer of the synovial membranes. Their concentration here is greatly increased in chronic nonspecific inflammation and tuberculosis.

Asboe-Hansen B60,550/50; B60,548/50; D26,784/50; B60,604/51: Numerous large MCs are found in human synovial membranes. They are grouped along the surface, here apparently, independently of blood vessels while in the deep connective tissue they are arranged perivascularly. Near the surface, the MC granules appear to be discharged and there is free metachromatic substance in the joint fluid itself.

Compton B90,594/52: MCs are found in the synovial membranes of the hamster.

Baglioni C16,539/54, *p. 193*: Discussion.

Iakovleva D25,508/54: In rats, MCs are particularly numerous around the joints.

Jernstrom D28,481/54: An unusually large number of MCs was found in a synovial sarcoma of the pharynx in a young man.

Rosate D99,736/59: MCs are plentiful in the synovia and the adjacent adipose tissue of the knee joint in the rat.

MUSCLES

Zimmermann D27,591/08: MCs are found in the skeletal musculature of the guinea-pig (pectoralis, gluteus muscles), especially within the perimysium and fascial connective tissue.

Brack D26,821/25: Discussion.

Arvy C41,778/56: In the muscles of the frog (*Rana esculenta*), most of the MCs are situated around the vessels and the perimysium.

KIDNEY

Zimmermann D27,591/08: In the kidney of the guinea-pig, MCs are plentiful within the capsule and the connective tissue of the pelvis underneath the mucosa. Occasional MCs are also seen in Bowman's capsule.

Staemmler D26,807/21: In the human kidney, there are few MCs under normal conditions except in the region of the pelvis. Their number increases in the course of various inflammatory diseases of the kidney, wherever fibrous connective tissue proliferates, but few MCs are seen in foci of acute inflammation and in renal carcinomas.

Quensel D26,221/33: The human kidney is very poor in MCs.

Holmgren D29,498/38: Demonstration of MCs in the kidney of man, cattle, pig, dog, guinea-pig, rabbit.

Compton B90,594/52: MCs are scarce in the kidney of the hamster.

Arvy D65,694/55: No MCs are found in the kidney of the frog (*Rana esculenta*).

Arvy & Quivy D27,966/55: The renal parenchyma of the dog contains almost no MCs but at the hilum they penetrate into the organ around the blood vessels.

Pavone-Macaluso D26,615/60: Under normal conditions, the human kidney contains only very few MCs within its internal stroma.

Macaluso & Salerno D26,435/60: In man, MCs are particularly numerous in the submucosa of the renal pelvis, the connective tissue around the hilum, and the adventitia of the large renal vessels.

Corbascio D27,440/60: The cells of the juxtaglomerular apparatus of the rat kidney have many characteristics in common with MCs. Their granules stain metachromatically and are discharged under the influence of dextran or ovomucoid as are those of the MCs.

Demopoulos et al. D26,565/61: After fixation in a strong oxidant such as potassium dichromate, the cells of the juxtaglomerular apparatus can stain metachromatically (hence, they have been likened to MCs. *Harada* D27,441/54). However, these cells, unlike the MCs, do not discharge their granules under the influence of 48/80 or dextran, nor do they stain metachromatically under ordinary conditions as MCs do. They are not considered to be MCs.

URINARY PASSAGES

Arnold D30,522/03: The urinary bladder of the dog is an excellent test object for the study of MCs with vital or supravital stains. Methylene blue stains some of the living MCs blue, others metachromatically red.

Staemmler D26,807/21: In the urinary bladder of man, MCs are found in moderate numbers within the connective tissue of the musculature and, to a lesser degree, in the deeper layers of the mucosa. While scarce in very young infants, their number is not especially influenced by age in later years.

Negri D31,632/41: Extensive comparative investigations showed MCs in the connective tissue of the urethra within the pars cavernosa in the donkey, pig, cattle, sheep, cat, dog, guinea-pig, and rat. No MCs were detectable in this location in the rabbit and goat.

Arvy & Quivy D27,966/55: In the urinary bladder of the dog, only occasional MCs can be seen underneath the epithelium.

ADRENAL GLANDS

Ehrlich D27,092/1879: In the adrenal glands of various animals, MCs could be demonstrated only within the capsule.

Sabrazès & Husnot D27,507/07; D27,425/07: MCs are regularly found in the capsule of the human adrenal gland. They also often penetrate into the glomerulosa along the connective-tissue trabeculae but are not found in the fasciculata glomerulosa or medulla. They are never numerous.

Sabrazès & Husnot D27,508/07: There are MCs in the adrenal gland of various species such as amphibia, the pig, dog, horse, sheep, monkey, and man. In the adrenals of small rodents (rabbit, guinea-pig, rat) they can be detected only in the capsule.

Zimmermann D27,591/08: In the guinea-pig adrenal gland, few MCs are found within the capsule and the stroma.

Staemmler D26,807/21: In the human adrenal gland, MCs are almost exclusively in the capsule.

Tinel & Vimeux D33,688/52: No MCs were detectable in the adrenal gland of various animal species.

Arvy & Quivy D27,966/55: In the dog, "the capsule as well as the parenchyma of the medulla and cortex are free of mast cells, except in the glomerulosa where they line the cortical cell loops."

Kelsall & Crabb D30,528/57; *Crabb & Kelsall* D28,559/57: In the adrenal glands of the hamster, MCs are found only in the capsule.

HYPOPHYSIS

Zimmermann D27,591/08: No MCs are found in the hypophysis of the guinea-pig.

Kohn D28,271/10: In the posterior pituitary of cattle and certain other species, there is "an enormous number of mast cells" while in man, they are exceptional in this location.

Staemmler D26,807/21: In the human hypophysis, MCs are found almost exclusively in the capsule.

Nagayo D26,871/28: In a comparative study of various species, no MCs could be found in the brain, spinal cord, or hypophysis, although they were plentiful in the connective tissue of most other organs.

Nakajima D39,782/28: No MCs could be found in the hypophysis of man, mouse, rabbit, monkey, dog, cat, guinea-pig, and rat.

Gray 32,404/35: Numerous MCs are present in the pars nervosa and particularly in the infundibulum of cattle, cat, and man. They appear to be intimately associated with the primary capillary net of the hypophysioportal system.

Tavares de Sousa D39,613/37: There are many typical metachromatic MCs in the pars nervosa of beef, but only few in pars intermedia, pars anterior, and the stock. The tuber is devoid of them.

Holmgren D29,498/38: MCs are particularly numerous in the posterior lobe of the dog pituitary gland.

Floderus B27,201/44: In the human hypophysis, MCs are rare.

Castiglioni D39,812/48: MCs are constantly present both in the anterior and in the posterior lobes of the pituitary, especially at sites where there is cell disintegration.

Tinel & Vimeux D33,688/52: Especially large MCs are found near the posterior border of the anterior pituitary gland of the cow.

Consolandi & Briziarelli B84,591/52: MCs are normal and constant constituents of the human hypophysis. They are most numerous in the pars intermedia and the stalk, but occur also in the anterior and posterior lobes. Extraordinarily small MCs, "Micromastzellen," appear only in the anterior lobe.

Arvy & Quivy D27,966/55: In the dog, the anterior and the intermediate lobes of the pituitary are very rich in MCs, while the posterior lobe contains but few of them and almost exclusively in the immediate vicinity of blood vessels.

Crabb & Kelsall D28,559/57; *Kelsall & Crabb* D30,528/57: No MCs occur in the anterior pituitary of the hamster.

Kelsall & Crabb D26,076/59, *p. 85*: Discussion.

PANCREAS

Zimmerman D27,591/08: The pancreatic stroma of the guinea-pig contains many MCs.

Staemmler D26,807/21: In the human pancreas, there is a moderate number of MCs within the stroma. Their number is not significantly influenced by age or disease but many MCs were seen in a case of diabetes with pancreatic cirrhosis.

Arvy & Quivy D27,966/55: Almost no MCs are found in the pancreas of the dog, except in the immediate vicinity of the ducts, where they are plentiful.

Kelsall & Crabb D30,528/57; *Crabb & Kelsall* D28,559/57: In the Langerhans' islets of the hamster, MCs are found only within the stroma and capsule.

Kelsall & Crabb D26,076/59, *pp. 96, 113*: Discussion.

Godlewski D26,858/59: In the human pancreas, MCs are almost exclusively within the stroma.

THYROID GLAND

Zimmermann D27,591/08: The thyroid gland of the guinea-pig contains occasional MCs in the stroma, particularly near vessels.

Staemmler D26,807/21: In the human thyroid gland, a moderate number of MCs are within the stroma.

Ekman & Naumann B4,771/45: No MCs could be demonstrated in the thyroid glands (normal or Graves disease) of man following fixation in 4 per cent lead acetate and staining with toluidine blue.

Janes & McDonald B32,304/48: No MCs could be found in normal human thyroid tissue.

Tinel & Vimeux D33,688/52: The stroma of the rat thyroid gland is comparatively rich in MCs.

Arvy & Quivy D27,966/55: In the dog, the stroma of the thyroid gland is rich in MCs, especially when the glands have small follicles and little colloid, indicating intense activity.

Blomquist D27,524/56: MCs are normally present in the stroma and capsule of the human thyroid gland; their number is greatly increased in goitrous and other adenomatous glands.

Kelsall & Crabb D30,528/57; *Crabb & Kelsall* D28,559/57: In the thyroid gland of the hamster, MCs are present only in the capsule and stroma.

Kelsall & Crabb D26,076/59, *p. 87*: Discussion.

Santini D64,084/62: MCs are plentiful in the thyroid gland of the rat.

Bartolini & Berti E37,297/63: MCs are clearly distinguishable in the thyroid tissue of newborn human babies.

PARATHYROID GLAND

Levine 68,868/28: Description of the MCs in the parathyroid glands of the cow.

Arvy & Quivy D27,966/55: The parathyroid gland of the dog always contains a large number of MCs.

Kelsall & Crabb D30,528/57; *Crabb & Kelsall* D28,559/57: The parathyroid glands of the hamster contain MCs only in the capsule and stroma.

Kelsall & Crabb D26,076/59, *p. 87*: Discussion.

PINEAL GLAND

Staemmler D26,807/21: In the pineal gland of man, MCs are fairly numerous and invariably located in the stroma.

Henschen & Krabbe D39,826/28: The pineal gland of man is particularly rich in MCs throughout life.

Compton B90,594/52: MCs are scarce in the pineal body of the hamster.

OVARY

Zimmermann D27,591/08: In the guinea-pig ovary, MCs occur in the theca and in the capsule.

Greggio D31,536/11: Comparative studies on the MCs in the ovary of the guinea-pig, rabbit, dog, sheep, cow, pig, and man.

Staemmler D26,807/21: In the cortex of the human ovary, MCs are very scarce, while they are much more numerous in the medulla, which is rich in connective tissue. In various ovarian tumors, MCs are rare, despite the presence of fibrillar connective tissue.

Holmgren D29,498/38: Demonstration of MCs in the ovary of the dog and pig.

Vimeux D33,732/52: In the mature (unlike in the primary) follicles of women, cows, rabbits, sheep, and rats, the follicular fluid is strongly metachromatic. This phenomenon is

independent of the local MC count and clearly demonstrable even in the rabbit which possesses virtually no MCs in the ovary. Follicular fluid may contain heparin since it possesses a definite anticoagulant effect. Addition of hyaluronidase diminishes the metachromasia of follicular fluid.

Tinel & Vimeux D33,688/52: Many MCs are found in the ovaries of young women but they disappear almost completely after menopause. They are present also in the ovary of the cow but not in that of the rabbit or ewe.

Arvy & Quivy D27,966/55: In the ovary of the dog, the MCs are almost exclusively in the vicinity of blood vessels.

Crabb & Kelsall D28,559/57: No MCs occur in the ovary of the hamster.

Zachariae et al. C57,334/58: In the rabbit, basophils migrate from the blood into the genital organs (primarily the ovaries) at ovulation. A large number of them accumulates around ovulating follicles and fresh corpora lutea. [In the tissues, it is difficult to distinguish these basophils from MCs (*H.S.*).]

Zachariae & Jensen C48,660/58: In rabbit ovaries, the follicular fluid stains metachromatically with toluidine blue.

FEMALE ACCESSORY SEX ORGANS

MAMMARY GLAND

Berka D27,512/11: MCs are constantly present in the stroma of the mammary glands of women; their number increases during pregnancy.

Brugnatelli 46,135/14: Many of the MCs in the human mammary gland contain lipid granules in addition to their typical metachromatic granules.

Staemmler D26,807/21: MCs are plentiful in the mammary glands of women, particularly in the stroma around the glandular parenchyma. In adenocarcinomas of the breast there are few MCs, while in intracanalicular fibroadenomas they are plentiful in the stroma around the epithelial cells, but virtually absent in the purely sclerotic portions.

Gruber D27,302/21: Brief mention of the presence of MCs in the mammary glands of human fetuses and in the newborn.

Gruber D27,100/24: In the human mammary gland there are MCs which, in addition to metachromatic granules, also contain lipid droplets.

Brack D27,435/24: MCs are present in the male and female human mammary gland.

Brack D26,821/25: The MC concentration in the nipple diminishes at puberty in children.

Centeno D30,203/27: Numerous MCs are found in hyalinized portions of human mammary glands. These MCs may play a part in the removal of hyalin.

Higuchi D26,227/30: In the mammary glands of women, MCs are particularly numerous around the galactophores, especially where there is stagnation of secretion, but they also occur in the stroma between the acini.

Quensel D26,221/33: In the normal mammary glands of women MCs occur predominantly in the stroma around the acini and galactophores. As in other locations, they tend to be densest in the surroundings of vessels.

Michels C72,066/38: Discussion.

Vallone D26,432/44: In the mammary gland of women MCs are plentiful within the stroma.

Consolandi D39,594/47: There are many MCs in the nipples of both men and women.

Dempsey et al. D28,461/47: In the mammary gland of the rat, metachromatic substances are confined to the connective-tissue stroma and the granules of MCs.

Baglioni D28,698/52: MCs are commonly found in the connective tissue of the male nipple.

Tinel & Vimeux D33,688/52: In women and cattle, MCs are numerous in the stroma of the mammary gland, both at rest and during lactation.

Baglioni C16,539/54, *p. 182*: Discussion.

Arvy & Quivy D27,966/55: The nipple of the dog always contains enormous numbers of MCs; some are also present in the stroma, especially around the galactophores and blood vessels.

Olivi C14,795/55: MCs are numerous in the mammary glands of male or female mice.

Arvy C41,780/57: MCs are particularly abundant around the nipples in the rat.

Kelsall & Crabb D26,076/59, *p. 104*: Discussion.

Ehrenbrand F15,603/64: In the interlobular connective tissue of the human mammary gland, numerous MCs appear during lactation. In the hamster, these MCs may even pass into the milk where they discharge their granules. A survey of the literature shows that migration of MCs through epithelial surfaces has also been observed in other locations and in other species.

OVIDUCT

Zimmermann D27,591/08: In the oviduct of the guinea-pig, MCs occur in the serosa, but unlike in women, they are not found in the mucosa.

Lehner D27,094/24: Discussion.

Tinel & Vimeux D33,688/52: MCs are regularly present in the muscle and connective-tissue layers of the oviduct in various species.

UTERUS

Zimmermann D27,591/08: In the uterus of the guinea-pig, MCs are found both in the mucosa and in the serosa.

Huguenin D39,690/11: There are MCs in the loose connective tissue of the uterus, particularly in the vicinity of myomas in women.

Huguenin D29,587/12: In the pregnant and puerperal uterus of women there are fewer MCs than in the resting uterus.

Staemmler D26,807/21: MCs are plentiful in the human uterus, especially where fibrillar connective tissue is most abundant. In the mucosa, which is poor in fibrils, there are only very few or no MCs, while the connective tissue in the muscularis is rich in them. However, fibromyomas, though rich in fibrillar connective tissue, often contain fewer MCs than the normal muscularis and, in general, inflammatory processes likewise diminish the uterine MC population. Few MCs are found in uterine carcinomas while many are present in uterine polyps.

Lehner D27,094/24: Discussion.

Michels C72,066/38: Discussion.

Asplund et al. D28,695/39: Metachromatically-staining granules are normally found in the epithelioid cells of the metrial gland in the guinea-pig and rat.

Asplund et al. D15,852/40: Metachromatically-granulated cells of the "metrial gland" at the placental insertion site can be demonstrated in the rat, mouse, guinea-pig, and, less clearly, in the rabbit uterus; they are absent in cattle, pig, horse, and sheep uteri. Such cells can also be produced in nonpregnant animals by the induction of deciduomas. They do not disappear upon extirpation of the embryos but vanish if both embryo and placenta are removed. Injected Trypan blue is phagocytosed by these granulated cells. It is assumed that the latter, like MCs, contain heparin and thereby can prevent clotting, yet, there are definite morphologic differences between the metrial-gland cells and true MCs.

Sylvén D33,704/46: Investigations on normal and pathologic human material showed that the young growing stroma is poor in MCs while more highly differentiated stroma contains but few of them. Diffuse metachromatic staining of the stroma was also most evident in the growing regions.

Asplund & Holmgren B17,599/47: In the normal and pregnant human uterine mucosa there are cells with occasional metachromatic granules (called "specific cells"). "These cells are neither mast cells nor apparently plasma cells. The 'specific' cells are met more frequently during the secretion phase. After the cessation of menstruation, they seem to disappear from the mucous membrane. As the cells are only met during the fertile age, it is assumed that they have a function associated with the functioning uterine mucous membrane." The cells also should not be confused with the metachromatic granule-containing myometrial cells found in pregnant rats and mice immediately under the placental insertion. The specific cells are not so localized.

Wislocki & Dempsey D26,759/48: Certain decidual cells in women contain definitely metachromatic granules. However, "the observation that the granules are digested by ribonuclease indicates that they consist of ribonucleoprotein and rules out mast cells. The further observation that their nuclei are relatively large, clear and spherical, rather than small, dark and indented, identifies them as decidual cells rather than as macrophages." It remains to be seen whether these cells are responsible for the diffused metachromasia of the decidua.

Janes & McDonald B32,304/48: No MCs were seen in the human endometrium.

Brusa D39,831/49: In the mouse uterus, there are normally only few MCs, but their number increases greatly during pregnancy and lactation.

Wimsatt D27,404/49: MCs are abundant in the myometrium of the pregnant bat, *Myotis lucifugus*.

Compton B90,594/52: MCs are numerous in the uterus of the hamster.

Tinel & Vimeux D33,688/52: In the cow, ewe, and woman, there are cyclic variations in the MC content of the uterus which reach a peak during the follicular phase.

Westin C11,073/55: Brief survey of the literature and of personal observations of the MC count of the mouse uterus.

Arvy & Quivy D27,966/55: The uterus of senile dogs contains few MCs but immediately after delivery, there are enormous numbers of them both in the mucosa and in the muscularis.

Bergström et al. C53,172/58: In the uterus of the mouse, MCs are scarce within subepithelial and basal parts of the endometrium and are most numerous in the myometrium, especially near the covering serosa.

Kelsall & Crabb D26,076/59, *pp. 104, 108*: Discussion.

Iversen C90,461/60: In the myometrium of the human cervix uteri, MCs are most plentiful during the secretory phase of the cycle.

Spicer C92,580/60: Aggregates of pigmented siderophages and lipophages, as well as MCs, tend to develop at implantation sites in the mouse uterus.

Iversen D39,756/62: "As in other species of animals, the mast cells in the uterus of the guinea pig are scarce in the basal parts of the endometrium, while the myometrium contains very considerable quantities of mast cells, especially in the septa of connective tissue and more particularly congested around the vessels. In the myometrium, no difference between the cervix and the horns was observed."

Vara D39,825/62: The MCs of the human endometrium undergo cyclic variations with a discharge of their granules just premenstrually, and a gradual regeneration during the rest of the cycle. The MCs may play a role in making menstrual blood uncoagulable.

Nozaka & Simpson D63,181/62: Numerous MCs are seen underneath the squamous epithelium of the human cervix.

Voutsa et al. D69,713/63: In the human uterine cervix, MCs predominate around the blood vessels. Their number decreases in the gravid uterus at term.

Harvey G13,574/64: In the uterus of the hamster, MCs are most numerous within the myometrium, intermediate in the tunica vasculare of the endometrium, and least numerous in the mucosa.

Bulmer E23,380/64: The histochemical demonstration of a C-esterase in the metrial gland of the rat suggests "the possibility of a relationship between mast cells and metrial gland cells" since MCs are rich in a chymotrypsin-like esterase.

Hall F1,129/64: In the uterus of the mouse, there are many siderophil macrophages, usually in close association with MCs. Some of the MCs themselves gave a positive Schmorl reaction.

Likar & Likar G5,081/64: In the uterus of the cow, MCs are just below the epithelium, around the uterine glands, the myometrium, and the perimetrium. Their number increases during proestrus and estrus parallel to histochemically-demonstrable hyaluronate.

Likar et al. G19,263/64: In the bovine endometrium, the MC-count increases from metestrus through diestrus to proestrus. At the height of estrus there are many MCs and these show intense degranulation. Biochemically and histochemically estimations of hyaluronic acid and total acid mucopolysaccharides showed variations which roughly paralleled the MC-counts throughout the cycle. "The results of this investigation support the concept that mast cells participate in the production of hyaluronic acid."

VAGINA

Tinel & Vimeux D33,688/52: MCs are most plentiful in the subepithelial layer of the vagina in women, cows, and ewes.

Arvy & Quivy D27,966/55: The vagina of senile dogs is almost free of MCs, but immediately after delivery enormous numbers appear, especially under the epithelium.

Zwillenberg D42,931/58: The "high-level dendritic cells" with long, slender processes that are demonstrable in various non-epidermal stratified squamous epithelia (esophagus, vagina, portio vaginalis uteri) and their basal counterparts, generally contain granules which

stain metachromatically with toluidine blue in vivo. The granules are unevenly distributed but often lie in pairs. They frequently occur together with typical intra-epithelial MCs which here likewise tend to assume a dendritic shape in that they form processes which protrude between the malpighian cells. Such intra-epithelial MCs are common in the esophagus of the cat and Macaque, but are rare or absent in the esophagus of the pig and cow. In the vaginal epithelium of women and Macaques, the occurrence of intra-epithelial MCs is variable.

Jaffurs & Turner D26,770/59: MCs were observed in 4.3 per cent of patients with atrophic types of vaginal smears. "Their presence appears to be inversely related to the level of estrogens."

PLACENTA AND AMNION

Ferroni D69,360/1898: MCs are seen in the human amnion after the first few months of gestation.

Harris D26,716/00: MCs have been observed in the chorion of the human placenta which was in a condition of suppurative inflammation.

Lombardo D39,600/06: True MCs are not demonstrable in the human amnion.

Staemmler D26,807/21: MCs are occasionally found in the connective tissue of the placenta although they are rare in the chorionic villi and in the decidua.

Wislocki & Dempsey D26,759/48: The tissues of the human placenta and pregnant uterus show widespread diffuse metachromasia which resists ribonuclease digestion (unlike the metachromatic material of the human decidua), and is very probably due to mucopolysaccharides. Metachromasia is also intense in Wharton's jelly but there is no proof that the metachromatic material in these locations is an MC derivative.

Janes & McDonald B32,304/48: No MCs were found in human placenta and umbilical cord tissue.

Pescetto D27,071/50: In human chorionic villi, MC-like cells with metachromatic granules regularly occur between the age of 3.5 weeks to time. They are well preserved by fixation in basic lead acetate but the eosinophilia of the granules is difficult to explain (*Latta & Beber* D26,449/53), especially since other investigations revealed the presence of basophilic metachromatic granules in the human placenta.

Tinel & Vimeux D33,688/52: Few MCs are found in the chorionic villi of the human placenta.

Baglioni C16,539/54, *p. 191*: Discussion.

Nepriakhin D26,879/56: In the dog, the maternal placenta is very rich, but the fetal placenta is poor in MCs.

Beber et al. C85,594/60: The villi of the human placenta as well as the amnion contain some MCs but the decidua is apparently devoid of them. The largest number is found in Wharton's jelly.

UMBILICAL CORD
(Cf. also PLACENTA, *above*)

Schwenter-Trachsler D27,711/08: Using suitable staining techniques, MCs can be demonstrated in human umbilical-cord tissue.

Lehner D27,094/24, *p. 157*: Discussion.

Asboe-Hansen B60,550/50; B60,602/50; B60,604/51: Wharton's jelly is rich in hyaluronic acid and contains numerous mesenchymal cells with metachromatic cytoplasm or even metachromatic granulations.

Romanini D33,671/51: In an extensive study on the conditions permitting metachromatic staining of Wharton's jelly and the blood vessels of human umbilical cords, no special mention is made of MCs, but a classification of various mucins and mucoid substances is attempted.

Hopf D30,201/52: In newborn babies, MC accumulations are often seen at the borderline of the umbilical cord and cutis, especially when this region is inflamed.

Sundberg et al. D26,731/55: Wharton's jelly of the human umbilical cord contains many MCs.

Moore D26,869/56: MCs are numerous in the human umbilical cord, but perfect fixation and staining are required for their demonstration.

Moore & Schoenberg D30,210/57: In mature umbilical cords, the MCs stain metachromatically with toluidine blue at the entire *p*H-range between 2.0 and 7.5 although discrete granules could not be identified. In younger cords (less than 12 weeks in age), MCs were only occasionally identified and only at *p*H-ranges between 6.0 and 7.5. After sulfation, a larger number of metachromatic MCs could be identified and stained throughout the entire *p*H-range. Here, the MCs also stained with PAS and that quite independently of sulfation. Hyaluronidase and amylase had no effect on either metachromatic staining or PAS-reaction.

Schoenberg & Moore D27,894/58: In man, metachromatic ground substance appears in Wharton's jelly before any MCs are demonstrable. Furthermore, the potentially metachromatic material (made metachromatic by sulfation) in the intercellular spaces differs from the potentially metachromatic substrate of immature MCs in that it is sensitive to β-glucuronidase. "It seems more reasonable that the fibroblasts are the synthesizing cells of the connective-tissue polysaccharides."

TESTIS

Ehrlich D27,092/1879: MCs are not found in the testes of various species, but are numerous in the capsule.

Ballowitz D27,586/1891: Comparatively few MCs are seen in the testis of the bat.

Münchheimer A47,205/1895: MCs are present in the testis of man, horse, rat, cattle, and pig during adult life but are absent in newborn babies and pigs. No MCs were found in the testis of deer, sheep, dog, rabbit, and guinea-pig during adult life.

Zimmermann D27,591/08: MCs are plentiful in the stroma of the guinea-pig testis.

Staemmler D26,807/21: MCs become more numerous in the human testis at a time when the connective tissue begins to develop a typical fibrillar aspect and their number is roughly proportional to the development of the stroma. No striking changes in the MC population of the human testis have been seen in the course of various diseases.

Lehner D27,094/24: Discussion.

Tinel & Vimeux D33,688/52: No MCs were noted in the testis of the rat or bull.

Arvy & Quivy D27,966/55: The testis of the dog is virtually free of MCs.

MALE ACCESSORY SEX ORGANS

PENIS

Brack D26,821/25: MCs are very abundant in the prepuce and much less common underneath the epithelium of the glans penis. The greatest concentration is found along the attachment of the prepuce to the sulcus coronarius. In all these locations there are more MCs before than after puberty.

Noback & Montagna 95,640/46: In the stroma of the preputial gland of the female rat, the MC population is densest in the subepithelial connective tissue of the central duct, but MCs are also present in the interacinar connective tissue elsewhere throughout the gland.

Arvy & Quivy D27,966/55: The penis of the dog is extremely poor in MCs.

Kelsall & Crabb D26,076/59, *p. 104*: MCs are found in the prepuce.

PROSTATE AND SEMINAL VESICLES

Staemmler D26,807/21: The number of MCs in the human prostate increases with age, in proportion to the development of the connective-tissue stroma. In inflammation, their number is diminished but various other diseases have no striking influence upon them.

Holmgren D29,498/38: Demonstration of MCs in the musculature and capsule of the human prostate.

Arvy & Quivy D27,966/55: The prostate of the dog contains MCs, especially in its capsule. The seminal vesicles of the dog are poor in MCs.

COMB

Szirmai C47,033/56: "The ground substance of the mucoid layer of the cock comb has been found to show a strongly metachromatic reaction with toluidine blue, but the PAS reaction was negative. The fibrils, which do not stain metachromatically, show a significant PAS positivity." [These findings have not been correlated, however, with the presence of MCs (*H.S.*).]

Szirmai C43,968/57: There are cells with metachromatic granulations in the comb of white Leghorn roosters. Their morphologic characteristics are compatible with the assumption that these are MCs. The metachromasia of the granules is independent of the *p*H and they are resistant to hyaluronidase.

Kelsall & Crabb D26,076/59, *p. 104*: Discussion.

PELVIC GLAND

Sacerdote D33,407/62: In the pelvic gland (a male accessory organ) of *Triturus cristatus,* numerous stromal MCs develop at the height of sexual activity.

NERVOUS SYSTEM

Review: *Michels* C72,066/38

Rosenheim D26,865/1886: Studies on various peripheral nerves of man show that their connective tissue frequently contains MCs, though never before the fifth year of life. Their number greatly increases in old age.

Neumann D29,310/1890: MCs occur in the human brain under pathologic conditions, for example, in the vicinity of apoplectic cysts or thromboses and in the foci of multiple sclerosis.

Athias & França D27,513/01: MCs are found along the blood vessels of the brain in a patient with general paresis. No such cells have been found in this location in the brains of normal individuals.

Schreiber D33,633/02: In the sciatic nerve of the frog, MCs may reach a length of from ⅓ to ½ mm. They correspond to the clasmatocytes of Ranvier.

Zimmerman D27,591/08: In the central nervous system of the guinea-pig there are no MCs, as judged by observations on the brain, cerebellum, spinal cord, and meninges. However, in the sciatic nerve not only single, but even groups of MCs, are situated within the perineurium and epineurium.

Cerletti D27,715/11: In the bulbus olfactorius of the dog, MCs are commonly found in rows along the blood vessels. No similar MC accumulations were observed in the cat, rabbit, guinea-pig, and man.

Lehner D27,094/24: Discussion.

Romieu D27,443/24: Unusually numerous MCs are found within the peripheral nerves and sympathetic ganglia of the teleost fish, *Orthagoriscus mola Schn.*

Nakajima D39,782/28: No MCs could be found in the brain and spinal cord of man, mouse, rabbit, monkey, dog, cat, guinea-pig, and rat.

Nagayo D26,871/28: In a comparative study of various species, no MCs could be found in the brain, spinal cord, or hypophysis, although they were plentiful in the connective tissue of most other organs.

Krabbe D39,826/28: A considerable number of MCs is found in the brain substance of the hedgehog, particularly within the habenular ganglion.

Henschen D39,826/28: MCs are not infrequently found in and around the roots of cranial nerves in man.

Rivela G10,729/28: An unusually large number of MCs is found in the olfactory bulb of the dog.

Henschen & Krabbe D39,826/28: While the human brain contains no MCs, that of the European *erinaceus* is extremely rich in them, particularly at the habenular ganglion region.

Torsegno D39,595/35: Unusually numerous MCs are found in the olfactory bulb and tract of the newborn dog; they may be important for the function of the olfactory organ.

Torsegno D39,799/35: MCs are plentiful in the olfactory bulb of the dog and hedgehog. They are rare in the olfactory bulb of the rabbit and absent in that of the mouse, cat, guinea-pig, sheep, ox, and man.

Tavares de Sousa D39,613/37: Although the pituitary gland of cattle contains numerous MCs, none are found in the tuber cinereum.

Herzog & Sepúlveda D69,364/40: MCs are frequently found in the ganglion nodosum of the vagus nerve as well as in the large sympathetic ganglia, but their number is very variable in man and does not show a clear-cut relationship to any particular disease.

Vallone D26,432/44: No MCs could be found in the brain and spinal cord of man.

Holmgren & Rexed D26,230/46–47: In the sciatic nerve of the rat, MCs are found mainly around blood vessels.

Compton B90,594/52: MCs are scarce in the brain and cerebellum of the hamster.

Hermann D30,199/52: In human sympathetic ganglia, MCs are scarce and often missing. Their number varies greatly in ganglia of different regions but nowhere are they in such intimate contact with nerve cells as to justify the assumption of their participation in nervous transmission.

Mazzi D39,757/54: "In the brain of *Triturus cristatus carnifex, Triturus vulgaris,* and *Hydromantes italicus gormani,* mast cells are very numerous, they present a great diversity of form, and are localized in the leptomeninx, in the stroma of choroid plexuses, in the nervous tissue and around the walls of its capillaries. In *Rana esculenta,* mast cells are spherical or ovoid in form and are situated almost exclusively in the leptomeninx. In *Lacerta muralis nigriventris* and in *Lacerta sicula campestris,* mast cells are ovoid in form, and have been found in the leptomeninx and in the stroma of the choroid plexuses. In *Cyprinus carpio,* brain mast cells are completely absent."

McGovern D31,617/55: "Mast cells are very scanty around small blood vessels in the brain and choroid plexus of both rat and man. They are absent in the leptomeninges. This may be a factor in maintaining the blood brain barrier."

Nepriakhin D26,879/56: Occasional MCs are found in the connective tissue of the brain and peripheral nerves of man.

Squartini & Giacanelli D39,823/56: Systematic studies on 106 regions of the human brain failed to reveal the presence of MCs in central nervous tissue.

Niebauer & Wiedmann D39,678/58: In the human skin, MCs, or at least similarly-staining cells, are frequently found in close contact with nervous elements. These pictures suggest a neurohumoral function.

Nepriakhin D26,802/60: MCs are commonly found in both central and vegetative nerves of man. They show no particularly characteristic changes during various diseases.

Stach D39,563/61: Spreads of the musculo-cutaneous tissue of rats can be vitally stained with methylene blue to demonstrate simultaneously the terminal reticulum of vegetative nerves and the MC. A definite topographic relationship between these structures suggests a functional participation of MCs in nerve actions.

Gamble & Goldby D2,298/61: In the sural and caudal nerves of the rat, MCs are frequently found within the endoneurium, perineurium, and epineurium. Mast cells are also present in smaller numbers, often in contact with small blood vessels, in the guinea-pig sural nerve and in the splanchnic nerves of rat and man. These cells do not exhibit a chromaffin reaction after treatment with Orth's fluid. From one to eight days after transection of the nerves, the MCs become more numerous and many of them shed their granules. However, intense MC proliferation was seen only several months after nervous injury, "thus, while mast cell hyperplasia is marked in conditions of fibroplasia, the latter usually appears first."

Torp D27,063/61: Histologic study of various nerves from cattle, cat, rabbit, rat, and guinea-pig shows a striking correlation between the MC count and the histamine content. "The results support the view that the main part—if not all—of the histamine is present not in the nerve fibers but in the mast cells."

Kelsall & Lewis D19,437/64: In the hamster, MCs occur in the brain, especially around the blood vessels and in the choroid plexuses. No MCs were observed within the brain substance of the olfactory lobes or other regions including the cerebellum and the wall of the fourth ventricle.

MENINGES, CHOROID PLEXUSES

Calleja D39,609/1896: Virtually no MCs are demonstrable in the leptomeninges of man and various animals.

McKibben D27,954/14: In the meninges of the amphibian *Necturus maculosus,* spider-shaped MCs with long filamentous pseudopodia are found. These are indistinguishable from clasmatocytes and can easily be confused with nerve cells. "Under certain conditions and in certain tissues, treatment of these mast cells in amphibia by the *Golgi* impregnation method, by the Cajal silver method and its modifications and by other methods, gives a picture in which it is well nigh impossible to determine whether one is dealing with sympathetic nerve cells or with these branched mast cells."

Holmgren D29,498/38: MCs are found in the meninges of the dog.

Tsusaki et al. D30,211/51: Basophil granulated cells which may have been MCs were seen in the choroid plexus of various animal species.

Kappers et al. D65,524/58: A variable but rather large number of polymorphous MCs is demonstrated in the telencephalic and diencephalic choroid plexuses of the axolotl (*Ambystoma mexicanum*).

Cricchi D34,314/63: In the dura of the guinea-pig and rat, MCs are seen predominantly along the blood vessels.

OTHER TISSUES

HIBERNATING GLAND

Ballowitz D27,586/1891: The density of the MC population in the hibernating gland diminishes during hibernation in the bat.

Mazza E54,977/54: The hibernating gland of the rat contains numerous MCs.

ADIPOSE TISSUE

Hellman et al. E22,484/63: The MC count in the adipose tissue of mice is comparatively low, but it increases almost twenty-fold in various types of obesity.

PUS

Leuchs E38,234/04: MCs are frequently demonstrable in purulent exudates of patients with various forms of infection.

BONE AND CARTILAGE

Michels C72,066/38: Among all the tissues observed in various animal species, only bone and cartilage were consistently free of MCs.

Ehrenbrand D19,113/64: In the paraganglion caroticum of the calf, there are unusually many MCs, the granule content of which varies greatly. Masses of MCs are found within the myelinated nerves in the immediate vicinity of the carotid body. This anatomic arrangement suggests close correlations between MCs and the nervous system.

4

Embryology

It is somewhat difficult to summarize the literature on the embryology of the MCs because they tend to appear at different stages of embryonic development in different organs, and most investigators searched for them only in one or a few sites. Furthermore, some workers mention only the crown-rump length of the embryo at the time when MCs are first seen and the age of the embryo cannot be accurately gauged on this basis. Finally, it is probable that many negative results during early development were due to improper fixation or staining. Thus, one investigator believes he has demonstrated MCs on the fifteenth day of uterine life in a human embryo while another claims that these cells appear only during the seventh month. Similar wide discrepancies are noted in the literature concerning the embryonic development of MCs in other mammals. In the laboratory rat, for example, most investigators begin to find MCs after the 14–15th day, but one worker states that they can be demonstrated only just before birth.

In any event all workers agree that MCs do appear during embryonic life in all species examined and that mitoses are very rare; hence, it was assumed that the majority of MCs probably develop from other cell types during the prenatal period.

Histamine appears in fetal tissues before MCs, hence, the fetal histamine must arise from elements other than MCs.

Reviews: *Lehner* D27,094/24, *p. 157* *Baglioni* C16,539/54, *p. 170*
Michels C72,066/38, *p. 249* *Arvy* D26,724/55, *p. 73*

Lombardo D39,600/06: In human embryos, no MCs could be demonstrated between the 15th and 60th day of uterine life. MCs with sparse metachromatic granulations appear in the subcutaneous tissue of human embryos after the second month. Some of these cells have two nuclei but only once has a mitosis been noted among them. At birth, the MC system is essentially as well developed as in adults.

Maximow B79,779/07: MCs appear in the connective tissue of the skin during embryonic life at the stage of 11 mm in the rat and 4 cm in the cat. In the rabbit, cutaneous and bone marrow MCs begin to appear at about the 22nd day of embryonic life.

Sabrazès & Husnot D27,425/07: MCs were not found in the adrenals of four-month-old human embryos but they were numerous at 7 months.

Dantschakoff A20,391/09: In the chick, MCs develop from small lymphocytes beginning on the 10th day of incubation.

Greggio D31,536/11: In the from five to six-month-old human fetus, MCs are demonstrable in the kidneys, liver, spleen, skin, and muscles, but are of smaller size than in adults.

Laguesse D27,510/19: MCs appear in the rat "just before birth" and are plentiful in newborn animals.

Webb D30,627/35: In the dermis of the rat, a constant increase in MC density is noted between the 5th day before birth and the 19th day after birth, during which period the number

of MCs per standard area increases ten times. After that, no pronounced change is noted up to the 50th day.

Holmgren 93,302/46: MCs become demonstrable in the mesenchyme of the skin and intestine in human embryos at the 9 cm stage. In the lung, kidney, and adrenal, the MCs appear only at the end of fetal life in man. In the rat, MCs are found only in fetuses exceeding 1.4 cm in length. In fetuses of the cat (15 cm) and rabbit (8–9 cm), MCs were also detected in various organs but in this respect no systematic studies have been performed. As judged by the structural characteristics of the developing MCs, it is assumed that they arise early in embryonic life from undifferentiated mesenchymal cells and then represent a separate cell line which multiplies by division and not by transformation from other types.

Urtubey D27,059/48; D27,728/48: In the rat embryo, MCs appear within the connective tissue between the 8 and 12 mm stage.

Hjelmman D15,553/52: In human embryos, the first MCs appear during the later part of the second month of fetal life in the liver and gallbladder. During the first half of the third month, MCs appear also in the ciliary body and choroid membrane of the eye and the subcutaneous connective tissue. In the heart and vessels they become evident a few weeks later. During the beginning of the fourth month, MCs appear in the lung, spleen, stomach, and intestine. The intensity of granulation increases during embryonic life.

Ryzhikh D39,895/52: Cutaneous MCs develop from the mesenchyma (not from lymphocytes) at about the 14th day of embryonic life in the rat.

Arvy C41,780/57: MCs appear in the subcutaneous connective tissue of the rat at about the 16th day of embryonic life.

Niccoli-Vallesi D39,807/56–57: In the skin of the external auditory meatus of man, very few MCs are seen during embryonic life, but their number increases and reaches a maximum in senility.

Räsänen D27,066/58: MCs are found in the lamina propria of the human stomach, beginning in the 4th month of embryonic life. There are no significant differences in the MC frequencies between different parts of the stomach.

Grahne D25,637/59: The smallest human embryo in which MCs could be detected had a crown-rump length of 5.4 cm. Here, the MCs were found in the larynx. Subsequently, the larynx MCs increased by 3 per cent for each 1 per cent of increase in the length of the embryo in the trachea and bronchus. Mast cells appeared somewhat later and the increase in their number was slightly less rapid. No difference in MC count was observable between the sexes.

Lindholm C70,944/59: The earliest occurrence of MCs in human fetuses was observed in the wall of the stomach and small intestine during the 3rd month (crown-rump length 4.7 cm).

Csaba et al. C98,159/60: MCs were not found in the thymus of 15-day-old rat fetuses, but were present regularly at from 18 to 19 days.

Grahne D26,613/61: Studies of the larynx, trachea, and bronchi revealed mitosis in MCs of human embryos with a crown-rump length of 16–23.5 cm. Apparently, "mitotic division of the mast cells is possible during certain developmental stages, at least."

Gamble & Stempak D26,648/61: In the rat fetus, MCs appear in the subcutaneous tissue at about the 15th day of gestation and in the liver, as well as throughout the connective tissue, including the mesentery; they can be demonstrated during the next few days. Blood MCs were not seen in any of the fetuses. Although other investigators stated that histamine appears in the rat fetus much before MCs are demonstrable, the present observations do not support such a view. "It is equally clear, however, that histamine is first present in rat foetal tissues some four to five days before mast cells may be recognized there and that the source of this histamine, while still unknown, is in cells other than mast cells."

Schauer & Eder D30,202/62: Metachromatic granules are first demonstrable in rat MCs on the 16–17th day of fetal life. One or two days before this, the MCs give a diffuse positive PAS reaction. The histochemically-demonstrable enzymes (leucylaminopeptidase, acid phosphatase, ATP-ase, β-glucuronidase) that are found in close association with the metachromatic granules of adult rats are also demonstrable in late fetal life as soon as the granules are formed. The earliest detectable fetal MCs of the rat stain metachromatically with toluidine blue only at a low *p*H, 2.6–3.6, while at and immediately after birth, the number of cells stainable at higher *p*H levels increases rapidly.

Bartolini & Berti E37,297/63: MCs are clearly distinguishable in the thyroid tissue of newborn human babies.

5

Comparative Anatomy

ALTHOUGH many publications deal with the MCs of different species, an evaluation of available data for comparative anatomical purposes is difficult because no investigator has undertaken the formidable task of comparing the MC concentration of many tissues throughout the animal kingdom, using uniform and satisfactory techniques of fixation and staining. In most instances, observations on the MCs of different species have been made incidentally in the course of studies concerned with other subjects; hence, the pertinent information was not easy to compile and is not readily intercomparable.

There is some doubt whether there are any homologues of MCs in *microbes and invertebrates*. The metachromatic volutin granules of certain microbes resemble MC granules in some of their histochemical reactions but there is no other reason to suspect that they are related to the metachromatic material in MCs. Cells with metachromatically-staining granules have also been noted in various invertebrates but here again a close relationship to MCs is questionable.

Fish possess an extraordinarily large number of MCs throughout the connective tissue, especially in the swimming bladder, mesentery, and throughout the intestinal tract, but also within the nerves (though not in the brain), kidney, lung, and the cutaneous scales. The blood of fish contains few or no basophilic leukocytes, which may suggest that the functions of the latter are related to and may be taken over by tissue MCs.

The clasmatocytes of *amphibia* contain very fine, dustlike metachromatic granules and are probably homologous to mammalian MCs. They distinguish themselves by extraordinarily long and often ramifying processes which may break off (clasmatosis). In the sciatic nerve of the frog, for example, the MCs allegedly can reach a length of 0.5 mm. Because of their spider-like shape, these cells have often been confused with nervous elements and indeed their identity with mammalian MCs is still not generally accepted.

Among the *reptilia* rather typical MCs have been noted in turtles, lizards, and alligators. (Curiously, we have not been able to locate any information concerning the MCs of snakes.)

Few investigations deal with the MCs of *birds*. Some cells with metachromatic granules were found in the bone marrow of the domestic fowl, but these might have been blood basophils. The cells with metachromatic granules that occur in the comb of roosters are presumably true MCs.

Most of the literature on the comparative morphology of MCs deals with *mammals*. Suffice it here to note a few especially interesting data. An unusually high concentration of MCs was found in the liver capsule and posterior pituitary

of cattle, the olfactory bulb and liver of the dog, the hepatic capsule and lung of the guinea-pig, the olfactory bulb and adjacent brain regions in the hedgehog, and the calvarial periosteum of the rat.

Some investigators have claimed that the guinea-pig and the rabbit have few if any tissue MCs, but this view was based upon material fixed in aqueous solutions which dissolve the MC granules in these species, although those of other animals (e.g., the rat) are quite resistant to aqueous fixation.

Reviews: *Maximow* D29,280/13; D28,534/27
Michels D65,511/23; C72,066/38, *pp. 246, 251, 332*
Nakajima D39,782/28
Oria D26,726/45
Trincão D26,962/53
Baglioni C16,539/54, *pp. 156, 168, 183*
Arvy D26,724/55, *p. 67*
Riley C70,315/59

COMPARISONS BETWEEN VARIOUS SPECIES

Maximow B79,778/06: MCs are constantly present in the connective tissue of various mammals including the rabbit, although they may not be demonstrable if aqueous fixatives are used.

Greggio D31,536/11: Comparative studies on the MCs in the ovary of the guinea-pig, rabbit, dog, sheep, cow, pig, and man.

Nagayo D26,871/28: MCs are plentiful, especially in the perivascular areas of the connective tissue of man, monkey (*M. fuscatus*), dog, cat, guinea-pig, rat, and mouse, but only few MCs are detectable in the rabbit.

Negri D31,632/41: Extensive comparative investigations showed MCs in the connective tissue of the urethra within the pars cavernosa in the donkey, pig, cattle, sheep, cat, dog, guinea-pig, and rat. No MCs were detectable in this location in the rabbit and goat.

Riley & West C29,554/56: MCs are numerous in the abdominal skin of the guinea-pig, rabbit, dog, cat, mouse, rat, and man. Interestingly, the histamine content of various skin layers roughly parallels the regional MC density.

Padawer & Gordon D27,053/56: The MC density in the peritoneum shows great species variations as judged by comparative observations on the rat, mouse, guinea-pig, hamster, rabbit, cat, and monkey.

West C19,992/56: MC counts have been made on various organs of several species. Rat liver, pig aorta, and dog kidney contain virtually no MCs. From low to medium MC densities were noted in ox liver, parenchyma, ox aorta, rat subcutaneous tissue, ox inferior vena cava, and dog liver and lung, while the highest MC counts were registered in ox liver capsule, dog mastocytoma tissue, and the lymph nodes and spleen of mastocytoma-bearing dogs. In all these instances, the histamine and heparin content of the tissues roughly paralleled the MC count.

Smith D26,773/59: Many MCs were found in the mesentery and fewer in the cheek pouch of the hamster. Spreads of mouse mesentery or rat skin contain a slightly smaller number of MCs than hamster cheek pouch. A similar number of MCs were observed in the omentum, mesentery, and pleura of the guinea-pig. In the parenchyma of the lung, around the major blood vessels and air passages, no MCs were seen in either normal or sensitized unshocked guinea-pigs. They were also absent in sections of guinea-pig skin (*sic!*) There are many MCs in normal dog liver but they were slightly less numerous and not quite so well differentiated as in other tissues. No MCs could be demonstrated in rabbit lung adjacent to the point of entry of the pulmonary artery.

MICROBES, INVERTEBRATES

Kanthack & Hardy D28,369/1894–95: Because of their great instability, the MCs of mammals are called "explosive cells" in analogy to similar unstable cells in invertebrates, particularly *Astacus*.

Guilliermond & Mawas D27,506/08: The so-called metachromatic corpuscles found in certain protozoa may be related to MCs.

Wermel & Sassuchin D39,520/28: The metachromatic volutin granules of yeast resemble MC granules in many of their histochemical reactions.

Duguid et al. D27,621/54: Some metachromatically-staining basophilic material is present in certain bacteria. This has been identified as volutin, but there is no reason to suspect that it is related to the metachromatic material of MCs.

Arvy E37,387/62: In opposition to a commonly-held opinion, the granular cells of arthropods and sponges (often referred to as "Körnchenballen," "thesocytes," or "cellules sphéruleuses") are essentially different from the MCs of vertebrates in their morphology and staining qualities. The author also gives a brief review of the MCs in different vertebrates.

FISH

Downey D27,983/09: MCs are very plentiful in the kidney of *Polyodon spathula.*

Michels D27,501/22; D27,502/22: In the teleostean fish *Leuciscus sp.* (*Gardon*), *Cyprinus carpio* (*Carp*), and *Anguilla vulgaris,* "immense quantities" of MCs were found throughout the connective tissue, especially in the swimming bladder, mesentery, and the vicinity of blood vessels. On the other hand, basophils were either absent or extremely scarce in the blood of fish.

Romieu D27,443/24: In the teleost fish, *Orthagoriscus mola Schn.,* there is an extraordinarily large number of MCs throughout the connective tissue and within the nerves.

Jordan D27,521/26: The intestinal tract of various fish is unusually rich in MCs.

Bolton D28,256/32: "Basophilic granule cells which occur in vast number in the connective tissue throughout all regions of the alimentary canal of sockeye salmon and speckled trout are interpreted as histogenous mast cells. Their occurrence in several other species is noted. None could be found in blood or in any other organs."

Duthie D27,611/39; *al-Hussaini* D27,614/49: Unusually numerous MCs are found in the intestinal tract of various fish.

Veil & Gabe D33,689/50: Accumulations of MCs are regularly found in the pigmented portion of the cutaneous scales of the carp (*Cyprinus carpio*).

Veil & Quivy D10,146/50: The scales of the carp contain numerous MCs and considerable amounts of heparin can be extracted from them.

Mazzi D39,757/54: In the brain of the carp (*Cyprinus carpio*), MCs are absent.

Veil E24,154/56: Description of MCs in the scales of the carp.

Veil E62,531/57: The scales of various fish (carp, roach) contain many MCs from which heparin can be extracted.

Arvy D65,058/58: In the perirenal organ, renal parenchyma, lung, and nervous tissue of the fish *Protopterus annectens,* MCs are plentiful and, judging by their shape and tinctorial properties, they resemble the MCs of *Batrachians.*

Stolk D26,444/61; D65,681/59: MCs are present in the mesentery and myocardium of the viviparous *Cyprinodonts Lebistes reticulatus, Xiphophorus helleri, Xiphophorus maculatus,* as well as in the mesentery of *Cyprinus carpio* and in the precancerous skin (carcinoma planocellulare) of the lizard *Lacerta agilis.*

Veil & Denèfle D66,476/63: In *Cyprinus carpio,* the scales are rich in MCs and these show seasonal variations. Between October and January they are mobile, while in February they begin to become immobilized and rounded. In March and April they lose their granules.

AMPHIBIA (Frogs, Toads, Newts, Salamanders)

Reviews: *Lehner* D27,094/24; *Maximow* D28,534/27; *Arvy* D26,724/55, *p. 69;* C41,778/56

Lavdowsky D42,233/1895: MCs are plentiful in the tongue of the frog. They can be vitally stained with methylene blue.

Stassano & Haas D33,741/00: Clasmatocytes (possibly identical with MCs) are plentiful in the periesophageal membrane of the frog. They discharge their granules upon exposure to cold.

Schreiber D33,633/02: In the sciatic nerve of the frog, MCs may reach a length of ⅓ to ½ mm. They correspond to the clasmatocytes of Ranvier.

Schuberg D39,531/03: In the skin of the axolotl there are cells which contain metachromatic granules and which possess branching long processes giving them an appearance similar to that of glia cells. Along the pseudopodia, there are many constrictions which eventually may lead to a breaking-off ("clasmatosis") of cell parts. "On the basis of these findings, I believe that there is no difference between mast cells and clasmatocytes."

Arnold D27,305/06: In the frog tongue, the MCs can readily be studied by vital stains.

Sabrazès & Husnot D27,508/07: In the adrenal glands of amphibia, there are cells with metachromatic granules, which have been designated as "summer cells" and which presumably represent MCs.

McKibben D27,954/14: In the meninges of necturus, there are MCs with long cytoplasmic processes. The cells may be mistaken for nerve cells but contain characteristic metachromatic granules.

Jordan D27,529/19: MC-like cells with metachromatic granules are found in the bone marrow of the leopard frog, *Rana pipiens.*

Holmgren D29,498/38: In the salamander (*Salamandra maculosa*) MCs with distinctly metachromatic, though small, granules are found in the liver, lung, and skin.

Mazzi D39,757/54: "In the brain of *Triturus cristatus carnifax, Triturus vulgaris,* and *Hydromantes italicus gormani,* mast cells are very numerous, they present a great diversity of form, and are localized in this leptomeninx, in the stroma of choroid plexuses, in the nervous tissue and around the walls of its capillaries. In *Rana esculenta,* mast cells are spherical or ovoid in form and are located almost exclusively in the leptomeninx . . ."

Arvy D65,694/55: In the frog *Rana esculenta,* no MCs are found within the liver and kidney but they are numerous in the stomach and particularly the tongue.

Hjelmman & Wegelius E20,252/56: The cardiac MCs increase in number both in the toad (*Bufo bufo*) and in the frog (*Rana temporaria*) upon exposure to low surrounding temperatures. On the other hand, the hepatic MC count rises only in the toad and not in the frog upon exposure to cold. The mastocytosis is interpreted as a defensive measure against threatening blood coagulation.

Sacerdote D33,407/62: In the pelvic gland (a male accessory organ) of *Triturus cristatus,* numerous stromal MCs develop at the height of sexual activity.

REPTILES (Snakes, Lizards, Turtles)

Reviews: *Lehner* D27,094/24
Arvy D26,724/55, *p. 70*

Jordan & Flippin D27,962/13: True MCs are found in the blood of the box-turtle (*Cistudo carolina*) and in other chelonia.

Michels D27,501/22: MCs with metachromatic granules are found in the spleen of the tortoise *Testudo mauritanica.*

Holmgren D29,498/38: Demonstration of typical MCs in the liver and gut of *Alligator mississippiensis.*

Mazzi D39,757/54: "In *Lacerta muralis nigriventris* and in *Lacerta sicula campestris,* mast cells are ovoid in form and have been found in the leptomeninx and in the stroma of the choroid plexuses."

Kelly et al. E43,287/61: In a series of 29 post-hibernation, horned lizards (*Phrynosoma cornutum*), the mean blood-basophil count was only about 8 per cent of the leukocytes. Mast cells were not especially numerous in the tissues and were entirely absent from the peritoneal fluid. It is possible that the higher counts reported by earlier investigators may have been due to seasonal variations.

BIRDS

Reviews: *Danchakoff* D27,400/16
Arvy D26,724/55, *p. 70*

Forkner D27,716/29: Metachromatic MCs are found in the bone marrow of the domestic fowl. However, these may have been blood basophils.

Szirmai C43,968/57: Cells with metachromatic granulations are located in the comb of white Leghorn roosters. Their morphologic characteristics are compatible with the assumption that these are MCs. The metachromasia of the granules is independent of the *p*H and they are resistant to hyaluronidase.

MAMMALS

BAT

Ballowitz D27,586/1891: MCs are plentiful in various tissues of the bat (*Vesperugo noctula K.* and *Blas.*). In the spring, at the end of the hibernation period (when the animals were greatly emaciated as a result of fasting for 5–6 months) the MC count was moderately decreased in the hibernating gland and the intestinal tract but their density was essentially normal in the testis, tongue, and other organs.

Wimsatt D27,404/49: Numerous MCs are found in the myometrium of the pregnant bat, *Myotis lucifugus.*

CAT

Raudnitz D28,536/1883: MCs are plentiful in the tongue of the cat.

Weill D27,707/20: MCs are present in the intestinal mucosa of the cat.

Nakajima D39,782/28: Discussion.

Gray 32,404/35: Numerous MCs are found in the posterior pituitary gland and infundibulum of the cat.

Johnson & McMinn D63,535/57: Comparatively large numbers of MCs are constantly present in the basal layers of the esophageal epithelium in the cat. The cranial two-thirds of the esophagus contains fewer MCs than does the caudal third.

CATTLE

Münchheimer A47,205/1895: MCs are very numerous in the testis of the adult bull.

Lehner D27,094/24: Discussion.

Gray 32,404/35: Numerous MCs are found in the posterior pituitary gland and infundibulum of cattle.

Holmgren D95,345/37: The hepatic capsule, aorta, and vena cava of cattle contain very many MCs. In the vessels they often accumulate just underneath the endothelium where heparin, liberated from their granules, may exert an anticoagulant action.

Tavares de Sousa D39,613/37: Numerous typical metachromatic MCs are found in the pars nervosa of beef pituitary gland but there are only occasional MCs in the pars intermedia, pars anterior, and the stalk. The tuber is devoid of them.

Holmgren D29,498/38: Discussion.

Takeda D63,362/58: MCs are present in the gingiva of the cow.

Gróf et al. G17,921/64: In the eyes of cattle the greatest MC concentrations are in the conjunctiva, the optic nerve, and the ocular muscles. The sclera, iris, ciliary body, and choroid contained less MCs, while the cornea, lens, and retina were completely free of them. The histamine content of these tissues paralleled their MC concentration.

DEER

Münchheimer A47,205/1895: MCs are absent in the testis of the adult deer.

DOG

Raudnitz D28,536/1883: Numerous MCs are located in the tongue of the dog, especially in the submucosa and the stroma of the musculature.

Münchheimer A47,205/1895: MCs are absent in the testis of the adult dog.

Sabrazès & Husnot D27,508/07: MCs are found in the adrenal capsule and parenchyma of the dog.

Cerletti D27,715/11: The olfactory bulb of the dog is especially rich in MCs.

Weill D27,707/20: MCs are present in the intestinal mucosa of the dog.

Rivela G10,729/28: An unusually large number of MCs is found in the olfactory bulb of the dog.

Nakajima D39,782/28: Discussion.

Torsegno D39,799/35; D39,595/35: MCs are plentiful in the olfactory bulb and tract of the dog. They may have some physiologic function in relation to the sense of smell, which is highly developed in this species.

Holmgren D29,498/38: Discussion.

Arvy & Quivy D27,872/55; D27,966/55: In the dog, the esophagus and colon are relatively poor in MCs while the stomach and duodenum contain many of them. This distribution roughly parallels the histamine content of these intestinal segments and constitutes additional proof of the presence of histamine in MCs.

GUINEA-PIG

Reviews: *Lehner* D27,094/24
Nakajima D39,782/28
Holmgren D29,498/38

Münchheimer A47,205/1895: MCs are absent in the testis of the adult guinea-pig.

Calleja D39,609/1896: MCs are demonstrable throughout the loose connective tissue of the guinea-pig.

Sabrazès & Husnot D27,508/07: MCs are found only in the capsule of the guinea-pig adrenal.

Zimmermann D27,591/08: An extensive study of MC distribution in the guinea-pig shows that these cells are particularly numerous wherever there is loose connective tissue or fat (for a detailed description see individual organs in Chapter 3, HISTOLOGY).

Mendes Fagundes D39,676/49: In the guinea-pig, MCs are particularly abundant in the hepatic capsule and hilum as well as in the lung, especially around the bronchi and vessels. In the large arteries, diffuse metachromasia is seen, but this diminishes in the smaller arteries and is absent in veins.

Hjelmman & Pettersson D39,850/55: MCs are found in clumps within the connective-tissue stroma as well as in the interior of the lobules, particularly around the central veins in the guinea-pig liver.

Boréus & Chakravarty C86,027/59: In the guinea-pig, the MC density decreases in the order of: aorta, trachea, uterus, abdominal skin, heart, liver, and striated muscle. The histamine content of these tissues decreases in the same order.

Shelley & Florence D33,736/61: Numerous well-preserved MCs can regularly be demonstrated in the guinea-pig mesentery by the use of a special technique for the preparation of whole mounts in glass capsules.

Iversen D39,756/62: "As in other species of animals, the mast cells in the uterus of the guinea pig are scarce in the basal parts of the endometrium, while the myometrium contains very considerable quantities of mast cells, especially in the septa of connective tissue and more particularly congested around the vessels. In the myometrium, no difference between the cervix and the horns was observed."

HAMSTER

Compton B90,594/52: In the hamster, MCs are most common in the mesentery, tongue, subcutaneous tissue, dermal papillae, and uterus. They are scarce in the lung, liver, kidney, cerebrum, cerebellum, and pineal body.

Kelsall & Crabb D28,690/53: MCs are more numerous in the sublingual than in the submaxillary or parotid glands of the hamster.

Kelsall & Crabb D39,634/54: MCs are more numerous in the connective tissue surrounding mucous alveoli than in that of the serous alveoli in Brunner's glands of the hamster.

Wegelius & Asboe-Hansen C29,551/56: Description of MCs in the cheek pouch of the hamster.

Crabb & Kelsall D28,559/57: No MCs occur in the adrenal gland, ovary, and anterior pituitary gland of the hamster, while they are present in the thyroid glands, parathyroid glands, and Langerhans' islets.

Kelsall & Crabb D30,528/57: In the adrenal gland, Langerhans' islets, thyroid gland, and parathyroid gland of the hamster, MCs are found only in the capsule and stroma. The anterior lobe contains no MCs in this species.

Lindholm D26,614/60: In the gastrointestinal tract of the hamster, MCs are most numerous in the appendix, esophagus, and small intestine while the large intestine and rectum contain the smallest number.

Kelsall & Lewis D19,437/64: In the hamster, MCs occur in the brain, especially around the blood vessels and in the choroid plexuses. No MCs were observed within the brain substance of the olfactory lobes or other regions including the cerebellum and the wall of the fourth ventricle.

HEDGEHOG

Henschen & Krabbe D39,826/28: While the human brain contains no MCs, that of the *Erinaceus europaeus* is extremely rich in these cells, particularly at the habenular ganglion region.

Hoepke & Westenhoeffer 66,679/35: Detailed description of the MCs in the mesentery of the hedgehog.

Peter D29,160/35: In the hedgehog, the thymic MCs greatly increase in number during the beginning of hibernation and then discharge their granules, gradually disappearing as the winter season progresses.

Torsegno D39,799/35: MCs are plentiful in the olfactory bulb and tract of the hedgehog *Erinaceus europaeus.*

Härmä & Suomalainen B65,284/51: In the hedgehog, MCs are particularly numerous in the small intestine, the lungs (especially around bronchial branches), and throughout the connective tissue, especially around blood vessels. In the liver, few MCs occur in the parenchyma and the capsule. The meninges and the vena cava posterior are virtually free of MCs.

Suomalainen & Härmä D30,082/51: The MC population of the small intestine and bronchi is increased during hibernation in the hedgehog. Perhaps increased heparin production by these MCs accounts for the absence of thrombosis, despite the greatly reduced pulse rate during hibernation.

Suomalainen C852/53–54: MCs are especially numerous in the peribronchial and intestinal connective tissue of the hedgehog, especially during hibernation.

Allara C68,999/59: In the hedgehog, the MC population of the thymus is greatly influenced by hibernation.

Harvey G13,574/64: In the uterus of the hamster, MCs are most numerous within the myometrium, intermediate in the tunica vasculare of the endometrium, and least numerous in the mucosa.

HORSE

Münchheimer A47,205/1895: Few MCs are found in the testis of the adult horse.

Sabrazès & Husnot D27,508/07: MCs are found in the adrenal capsule and parenchyma of the horse.

Séguin D27,447/12: MCs are numerous in the mucosa of the large intestine in the horse but their granules are water-soluble and, hence, may be lost after aqueous fixation. Similar cells are plentiful in the submucosa where they are water-insoluble.

MONKEY

Sabrazès & Husnot D27,508/07: In a monkey (*Cercopithecus ruber*), MCs were found only in the capsule but not in the parenchyma of the adrenal glands.

Nakajima D39,782/28: Discussion.

MOUSE

Reviews: *Lehner* D27,094/24; *Maximow* D28,534/27; *Stockinger* D65,522/28; *Nakajima* D39,782/28

Weill D27,707/20: The MCs of the intestinal mucosa of the mouse are different from those in other tissues of this species. They are unusually large and their granules tend to

coalesce less into voluminous droplets; furthermore, some of the granules are eosinophilic. Hence, the question has been raised whether these elements are not essentially different from the usual type of MC.

Brodersen D12,773/28: Detailed description of the subcutaneous MCs in the mouse. In contact with foreign bodies (e.g., a hair, metal needle, or carbon granule), brilliant and poorly tingible inclusions appear in the adjacent MCs but these are not due to phagocytosis of the foreign material since they structurally differ from the latter.

Takeda D63,362/58: MCs are present in the gingiva of the mouse.

Sumi C60,846/58: Description of MCs in mouse omentum.

Einbinder et al. G18,460/64: Comparative studies on the MC distribution in mice show that in the brain, liver, spleen, ovary, and adrenal parenchyma there are no MCs, although some occur occasionally in the stroma of the spleen and ovary. MCs are rare in the lung and in the parenchyma of the thymus as well as in the capsule of the kidney. The MC density is greater in the heart and skeletal muscle, but the largest number of MCs is found in connective tissue and especially in the skin.

OPOSSUM

Drzewina D27,511/03: The lymph nodes of the opossum *Didelphys lanigera* may contain up to 150 MCs per mm^2. Most of these cells are in the capsular and septal connective tissue but they also occur in the interfollicular reticulum.

PIG

Münchheimer A47,205/1895: MCs are very numerous in the testis of the adult pig.

Bois D27,594/04: The MCs in the intestinal mucosa of the pig "stand in no definite relation to the lumen of the canal, to the crypts, to any lamina or to the blood or lymph vessels."

Sabrazès & Husnot D27,508/07: MCs are found in the adrenal capsule and parenchyma of the pig.

Weill D27,707/20: MCs are present in the intestinal mucosa of the pig.

Holmgren D29,498/38: Discussion.

Takeda D63,362/58: MCs are present in the gums of the pig.

Lindner G20,217/64: Detailed description of the MCs in the subcutis of the pig.

RABBIT

Reviews: *Maximow* D28,534/27
Nakajima D39,782/28
Holmgren D29,498/38

Münchheimer A47,205/1895: MCs are absent in the testis of the adult rabbit.

Calleja D39,609/1896: MCs are demonstrable throughout the loose connective tissue of the rabbit.

Maximow B79,778/06: MCs are constantly present in the connective tissue of various mammals including the rabbit, although they may not be demonstrable if aqueous fixatives are used.

Sabrazès & Husnot D27,508/07: MCs are found only in the capsule of the adrenal glands in rabbits.

Ringoen D27,738/15: On properly-fixed preparations of rabbit bone marrow, MCs can always be demonstrated.

Forkner D28,957/29: MCs were found in all lymph nodes of the rabbit. They frequently occur in groups of two or three cells.

Scevola D27,705/38: No MCs could be demonstrated in the palatopharyngeal region, the skin, or the mesentery of the rabbit. [Since the method of fixation was not mentioned, it is possible that the MC granules were dissolved in an aqueous fixative (*H.S.*).]

Constantinides B81,085/53: MCs are very abundant in the thymus, skin, circulatory, urinary, and respiratory systems of the rat. Comparatively few MCs are seen in the gastrointestinal tract and none in the brain and spleen. By contrast, in the rabbit, no MCs were found in the majority of these organs with the exception of the skin, skeletal muscle, heart, and intestine. These observations essentially confirm earlier but less systematic studies (*Holmgren*

& Wilander D26,887/37; *von Möllendorf* D28,534/27; *Michels* C72,066/38; *Westphal* A8,394/1877). Indeed, it has been claimed that there are no MCs in the rabbit (*Raudnitz* D28,536/37). However, some of the earlier reports may not have been conclusive because the MCs of the rabbit, unlike those of the rat, are difficult to stain after fixation in aqueous solutions (*von Möllendorf* D28,534/27; *Michels* C72,066/38). It has also been emphasized that some strains of rabbits are rich, others poor in MCs (*Schreiber & Neumann* D28,537/37). In the present study, alcoholic fixation was used and the rabbits employed have been verified to be highly atherosclerosis-susceptible. This point was particularly emphasized because of the suspected relationship between MCs and susceptibility to atherosclerosis.

RAT

Reviews: *Lehner* D27,094/24
Maximow D28,534/27
Nakajima D39,782/28

Münchheimer A47,205/1895: MCs are numerous in the testis of the adult rat.

Sabrazès & Husnot D27,508/07: MCs are found only in the adrenal capsule of the rat.

Weill D27,707/20: The MCs of the intestinal mucosa of the rat are different from those in other tissues of this species. They are unusually large and their granules tend to coalesce less into voluminous droplets; furthermore, some of the granules are eosinophilic. Hence, the question has been raised whether these elements are not essentially different from the usual type of MC.

Hissard et al. B92,293/53: Detailed description of the distribution of MCs in the skin, muscles, heart, stomach, lymph nodes, lungs, and liver of the rat. No MCs were found in this species in the blood, spleen, kidney, or adrenal gland, although the connective tissue surrounding the renal and adrenal tissue was rich in MCs.

Marx et al. C28,984/57: "Tissue heparin contents and mast cell counts were determined on liver, lung, intestine, kidney, spleen and thymus of male rats and rabbits. In most instances, distribution of heparin and mast cells did not follow the same pattern. Rat organs showed higher heparin values, but lower mast cell numbers than the corresponding rabbit tissues."

Takeda D63,362/58: MCs are present in the gingiva of the rat.

Lindholm D26,614/60: In the gastrointestinal tract of the rat, MCs are most numerous in the small intestine and esophagus.

SHEEP

Münchheimer A47,205/1895: MCs are absent in the testis of the adult sheep.

Sabrazès & Husnot D27,508/07: MCs are seen in the adrenal capsule and parenchyma of the sheep.

Torsegno D39,799/35: No MCs are found in the olfactory bulb of the sheep.

SQUIRREL

Raudnitz D28,536/1883: Numerous MCs occur in the tongue of the squirrel.

6

Agents Affecting Mast Cells

HORMONES

No pronounced and consistent changes have been observed after *hypophysectomy* in various species. Among the *pituitary hormones,* ACTH appears to be most effective in producing MC degranulation, TTH tends to cause an increase in tissue MCs while STH, as well as the gonadotrophic hormones, produces only minor and inconstant variations.

Data concerning the effects of *adrenalectomy* are somewhat contradictory but *glucocorticoids* (cortisone, cortisol, etc.), unlike *mineralocorticoids,* cause vacuolation, granule clumping, and degranulation of MCs in most of the species examined.

Ovariectomy and *orchidectomy* do not produce any noteworthy changes in MCs. *Folliculoids* (estradiol, estrone, stilbestrol) have been reported to increase the MC count in the mammary glands, but their effect upon the MCs of other organs is variable.

Thyroidectomy, or treatment with thioureas, which inactivate the thyroid gland, increase the MC count in several tissues while *thyroxin* exerts an opposite effect.

However, none of these claims have remained uncontradicted and the effect of other hormones is still less spectacular.

Reviews: *Asboe-Hansen* D27,999/54; *Padawer* D30,194/57; *Fulton et al.* C35,831/57; *Kelsall & Crabb* D26,076/59; *Smith* D63,031/63

HYPOPHYSECTOMY

Bonati et al. B88,320/52: Although many of the stressor actions of sodium salicylate are prevented by hypophysectomy in the rat, its ability to increase the number of peritoneal MCs appears to be independent of the pituitary gland.

Padawer & Gordon B83,891/53: Hypophysectomy induces an increase in the size and distinct alterations in the shape of the peritoneal MCs in the rat.

Padawer B95,453/54; *Padawer & Gordon* C19,322/56: Hypophysectomy causes an increase in the size and alterations in the shape of the MCs in the peritoneal and pleural fluids of the rat. The MCs in the mesentery are not affected. The changes induced by hypophysectomy can be reversed by implantation of fresh anterior pituitary or by injections of STH.

Smith & Lewis C1,168/54: Hypophysectomy does not alter the absolute number of MCs in the skin and mesentery of the rat, but increases the number of abnormal MCs that show vacuolation and conglomeration of granules. ACTH further increases the number of these abnormal cells. The response of the MCs to X-irradiation is not altered by hypophysectomy.

Padawer & Gordon C7,186/55: The peritoneal MCs of the rat undergo degenerative changes following hypophysectomy. STH prevents these changes, but its effect is, in turn, blocked by concurrent treatment with cortisol.

Smith & Lewis C4,564/55: Hypophysectomy appears to have no effect upon the number and appearance of the MCs in the skin, mesentery, and cheek pouch of the hamster.

Constantinides & Rutherdale C56,628/57: Hypophysectomy significantly increases the cardiac MC count of the rat.

Marx et al. D26,895/60: In the rat "removal of the pituitary gland caused a significant elevation of the mast cell numbers in liver, lung and kidney, but not in the spleen; the thymus showed a trend toward increased values. The heparin contents of the organs examined were not significantly modified by the operation; the kidneys exhibited a trend toward higher values."

Padawer D58,275/63: Remarks on the effect of 5–HT upon the peritoneal MCs of hypophysectomized rats.

Selye et al. E24,147/64: In rats sensitized by DHT for calciphylaxis, ferric dextran or $FeCl_3$ i.v. + polymyxin s.c. causes intense local calcification at the polymyxin injection site owing to the discharge of metachromatic MC granules which immediately surround themselves with calcified precipitate and secondarily induce calcification in the adjacent connective tissue. Hypophysectomy prevents this form of mastocalciphylaxis.

ACTH

Asboe-Hansen B59,548/50: ACTH causes discharge of MCs and diminution of metachromatic ground substance in the skin of patients suffering from a variety of collagen diseases.

Stuart D2,340/51: ACTH i.p. produces "changes" (not characterized) in the peritoneal MCs of the mouse.

Mari & Rizzatti B85,212/51: ACTH greatly increases the MC population of the rat peritoneum with intense discharge of the metachromatic granules.

Baker et al. B63,170/51: Following ACTH treatment, the MC population of the rat thymus increases considerably, particularly in the capsule and septa.

Schoch & Glick D26,848/53: ACTH causes no consistent changes in the cutaneous MCs of rats.

Kelényi C10,851/54: ACTH causes swelling and degranulation of the peritoneal and cutaneous MCs of the rat.

Asboe-Hansen C1,756/54: ACTH causes degranulation of MCs in various animal species.

Baglioni C16,539/54, *p. 198*: Discussion.

Smith & Lewis C1,168/54: ACTH increases the percentage of abnormalities (vacuolation and granule conglomeration) in the cutaneous but not in the mesenteric MCs, both in intact and in adrenalectomized rats.

Smith & Lewis C4,564/55: The total number of MCs in the skin, mesentery, and cheek pouch of the hamster is not altered by ACTH, but the percentage of abnormal cells (vacuoles and granule clumping) is markedly increased in proportion with the amount of hormone given. This effect is prevented by adrenalectomy.

Wegelius & Asboe-Hansen C18,789/56: ACTH causes degranulation, granule clumping, and vacuolation in hamster cheek-pouch MCs.

Constantinides & Rutherdale C56,628/57: ACTH fails to affect the cardiac MC count in the rat.

Asboe-Hansen C77,655/57: ACTH causes degranulation of the cheek-pouch MCs in the hamster.

Villavicencio & de Takats C56,397/58: ACTH causes intense degranulation of the mesenteric MCs in the rat.

Smith D63,176/58: ACTH s.c. causes discharge of the mesenteric MCs in the rat with subsequent phagocytosis of their granules by fibroblasts, macrophages, and leukocytes.

Siurala et al. C79,697/59: Prolonged administration of ACTH i.v. produces a significant decrease not only of the circulating eosinophils but also of those in the gastric mucosa (obtained by suction biopsy) in man. At the same time the MC count in the gastric mucosa definitely increases.

Räsänen & Siurala D26,630/60: In patients with ulcerative colitis, ACTH causes eosinopenia, but no change in the MCs of the sigmoid mucosa.

Räsänen C81,536/60: ACTH causes rapid degranulation of the MCs in the gastric mucosa and subcutaneous tissue of the rat.

Glick & Pothapragada D2,215/61: ACTH s.c. increases the succinic dehydrogenase activity of peritoneal rat MCs.

Räsänen D33,725/61: In intact rats, ACTH causes almost complete degranulation of the MCs in the gastric mucosa with a pronounced decrease in tissue eosinophils. Both these actions are prevented by adrenalectomy.

Räsänen D33,740/62: ACTH i.m. causes destruction of gastric MCs in the rat. Heparin i.p. causes no change in these cells nor does it influence MC destruction by ACTH.

Parekh & Glick D27,898/62: ACTH does not alter the hexosamine content of intact rat peritoneal MCs.

Csaba & Mold D32,196/62: ACTH pretreatment in vivo stimulates the subsequent production of MCs in rat thymus tissue cultures.

Boseila D58,293/63: Discussion.

Räsänen D33,739/62; D39,969/63; E22,623/63: ACTH i.m. causes degranulation of the gastric MCs in the rat and mouse. Such a discharge may play a part in the production of the stress-induced gastric ulcers.

STH

Constantinides & Rutherdale C2,644/54: STH fails to influence the cardiac MC count of the rat.

Baglioni C16,539/54, *pp. 223, 225*: Discussion.

Wegelius & Asboe-Hansen C18,789/56: Observations in vivo on the cheek pouch of the hamster show that STH causes the appearance of numerous well-granulated MCs.

Constantinides & Rutherdale C56,628/57: STH causes no change in the cardiac MC count of the rat.

Asboe-Hansen C77,655/57: STH causes degranulation of the cheek-pouch MCs in the hamster.

Smith & Lewis C72,227/58: STH has no effect upon the MC of the rat skin and mesentery.

Dyrbye et al. C77,936/59: STH fails to influence the cutaneous MCs in the mouse.

Räsänen C81,536/60: STH causes an increase in the MC population of the gastric mucosa but not in the submucosa or the skin of the rat.

Räsänen D6,149/61: The MCs in the superficial layer of the gastric mucosa undergo degranulation under the influence of prednisolone i.m. and, to a lesser extent, of DOC. These effects are not significantly influenced by simultaneous treatment with STH.

Boseila D58,293/63: Discussion.

THYROTROPHIC HORMONE (TTH)

Ekman & Naumann B4,771/45: In guinea-pig thyroid glands activated by TTH the MC count increases.

Asboe-Hansen & Iversen B62,207/51: TTH s.c. causes an accumulation of MCs and hyaluronidase-sensitive mucopolysaccharides in the connective tissue of various sites (particularly in the retrobulbar tissue) in guinea-pigs concurrently with the development of exophthalmos.

Iversen & Asboe-Hansen B75,178/52: Both in intact and in thyroidectomized guinea-pigs, crude TTH preparations increase the MC population.

Baglioni C16,539/54, *p. 201*: Discussion.

Wegelius & Asboe-Hansen C18,789/56; *Asboe-Hansen* C77,655/57: Observations in vivo on the cheek pouch of the hamster show that TTH causes the appearance of numerous well-granulated MCs.

Dyrbye et al. C77,936/59: TTH fails to influence the cutaneous MCs in the mouse.

Kelly & Bloom G9,515/59: In rats treated with TTH, the peritoneal MCs show coarsening of granules and degeneration. There is a preponderance of the young, small forms.

Santini D64,084/62: In rat thyroids stimulated by TTH or thiouracil, the MC count is considerably increased and many MCs show degranulation.

Boseila D58,293/63: Discussion.

GONADOTROPHIC HORMONES (GTH)

Brusa D39,831/49: In the uterus of the normal prepubertal mouse, there are only few MCs and their number is not altered by treatment with LH or folliculoids. On the other hand, during pregnancy and lactation, the uterine MC count increases considerably.

Baglioni C16,539/54, *p. 191*: Discussion.

Constantinides & Rutherdale C2,644/54: LTH fails to influence the cardiac MC count in the rat.

Tuci & Cipriani C24,338/56: Impure GTH preparations increase the peritoneal MC count both in intact and in gonadectomized male or female rats. [Route of hormone administration not mentioned (*H.S.*).]

Smith & Lewis C72,227/58: GTH has no effect upon the MCs of the rat skin and mesentery.

Csaba & Mold D32,196/62: In vivo pretreatment with LH does not influence the production of MCs in subsequently removed rat thymus tissue cultured in vitro.

ADRENALECTOMY

Padawer & Gordon B83,891/53: In adrenalectomized rats the peritoneal MCs are usually smaller than in intact controls.

Baker B84,820/53–54: Adrenalectomy does not modify the peritoneal MCs of the rat.

Padawer B95,453/54; D58,275/63: Following adrenalectomy, the diameter of the MCs in the peritoneal and pleural fluids of the rat decreases while the mesenteric MCs are not affected. However, this action is due to the operation itself since other surgical procedures duplicate it.

Constantinides & Rutherdale C2,644/54: Adrenalectomy significantly increases the cardiac MC population in the rat.

Baglioni C16,539/54, *pp. 199, 200, 209*: Discussion.

Constantinides & Rutherdale C56,628/57: Adrenalectomy has no effect upon the cardiac MC count in the rat.

Hill & Pospíšil C99,519/60: Following a single i.m. injection of formalin, the mesenteric MCs of the rat exhibit a biphasic reaction. Swelling with degranulation in the initial stage (referred to as the "glucocorticoid phase of stress") is followed by shrinking with granule lysis (in the "mineralocorticoid phase"). In adrenalectomized rats, formalin elicits only shrinkage and lysis of MC granules; on the other hand, cortisol produces swelling with degranulation both in adrenalectomized and in intact rats. Hence, these MC changes are viewed as part of the G.A.S.

Frenger et al. D25,504/61: In adrenalectomized rats, the MCs in various tissues show less degranulation and disintegration than in normal controls. [The author used only 5 adrenalectomized and 2 intact control rats whose weight and sex is not mentioned. The adrenalectomized animals survived 30 days but the presence of accessory adrenal glands or adrenal remnants is not mentioned (*H.S.*).]

Räsänen D33,725/61: Adrenalectomy causes a slight increase in the MC and eosinophil content of the gastric mucosa in the rat.

ADRENALECTOMY + HORMONES

Stuart D2,340/51: DOC i.p. produces "changes" (not characterized) in the peritoneal MCs of the mouse.

Mari & Rizzatti B85,212/51: Adrenalectomy prevents the increase in number and the degranulation of the peritoneal MCs normally induced by ACTH in the rat.

Degos & Cottenot D26,857/53: Following adrenalectomy, the MCs (site not mentioned) of the rat lose their granules and their cytoplasm becomes very slightly and diffusely metachromatic. Cortisone restores the normal MC appearance. Since injected heparin is much more rapidly excreted (judged by metachromasia of urine) by adrenalectomized than by intact rats, the storage of MC granules presumably depends upon glucocorticoids.

Smith & Lewis C4,564/55: Adrenalectomy has no significant effect upon the total number or structure of the MCs in the skin, mesentery, and cheek pouch of the hamster. However, the effect of injected ACTH is prevented by adrenalectomy.

Padawer & Gordon C19,322/56: Adrenalectomy causes a decrease in the average size without any change in the other morphologic features of the peritoneal MCs in rats. This change is duplicated by sham-adrenalectomy. Neither of these operations causes any significant alteration in the absolute number of MCs within the peritoneal fluid; minor changes are probably due to fluid shifts. The MC-changes induced by adrenalectomy cannot be prevented either by cortisone or by cortical extract.

Selye & Bois C23,958/57: In the rat, repeated injections of 5–HT s.c. elicit an anaphylactoid inflammation which differs from the classical form (induced by ovalbumen or

dextran) in that it takes several days to develop, consists more of hyperemia than of edema, affects the paws more than the snout, and is frequently associated with gastric ulcers. Though evident in the intact rat, it is even more pronounced in adrenalectomized animals maintained on DOC and almost absent in those maintained on cortisol. One mg per day suffices to elicit the anaphylactoid inflammation but gastric ulcers are more evident with higher doses. Single doses of up to 32 mg per 100 g body weight are tolerated. [In the paper, mg is misprinted as μg (*H.S.*).]

Hill & Pospíšil D26,881/60; C99,519/60: In adrenalectomized rats cortisol produces swelling of granules and the formation of metachromatic vacuoles in the peritoneal MCs.

Räsänen D33,725/61: In intact rats, ACTH causes almost complete degranulation of the MCs in the gastric mucosa and a pronounced decrease in tissue eosinophils. Both these actions are prevented by adrenalectomy.

ADRENALECTOMY + CHEMICAL AGENTS

Mari & Rizzatti B85,211/51; B85,212/51: After adrenalectomy, the increase in the number and size of peritoneal MCs, normally induced by s.c. injection of sodium salicylate, is considerably inhibited but not totally prevented.

Speirs C3,414/55: "Oil" (kind not indicated) i.p. induces topical MC discharge both in intact and in adrenalectomized mice.

Bartlet & Lockett D27,074/59: Adrenalectomy increases the histamine content of the skin and delays the restoration of cutaneous histamine following its depletion by 48/80. [Although no mention is made of the MCs, these findings suggest the dependence of these cells upon the adrenal glands (*H.S.*).]

Hill & Pospíšil C99,519/60; C73,689/59: Following a single i.m. injection of formalin, the mesenteric MCs of the rat exhibit swelling with degranulation in the initial stage (referred to as the "glucocorticoid phase of stress"), followed by shrinking with granule lysis (in the "mineralocorticoid phase"). In adrenalectomized rats, formalin elicits only shrinkage and lysis of MC granules. Cortisol produces swelling with degranulation both in adrenalectomized and in intact rats; hence, these MC changes are viewed as part of the G.A.S.

Hill & Pospíšil D26,881/60: Even after adrenalectomy, heparin s.c. causes swelling of granules and the development of metachromatically-staining vacuoles in the mesenteric MCs of the rat.

Paplanus & Sheldon E21,614/63: In rats with cutaneous Rhizopus oryzae infection, "degranulation and regranulation of the tissue mast cells at the site of injury have been found to correlate respectively with the onset and subsidence of the exudative cellular phase of inflammation. In the adrenalectomized animals regranulation of these cells and correspondingly termination of the exudative phase are delayed." The animals were maintained on NaCl solution.

Selye et al. E24,147/64: In rats calciphylactically sensitized with DHT and subsequently given ferric dextran i.v., minute doses of polymyxin s.c. cause intense local calcification. This is due to the discharge of metachromatic MC granules which immediately surround themselves with calcified precipitate and secondarily induce extensive connective-tissue calcification. In similarly treated adrenalectomized rats, maintained on desoxycorticosterone, this response was unchanged or accentuated while cortisol, given alone or with desoxycorticosterone, abolished the mastocalciphylactic reactivity both in intact and in adrenalectomized rats. Apparently, those forms of calciphylaxis that depend upon MC discharge are highly subject to regulation by adrenocortical hormones.

ADRENALECTOMY + PHYSICAL AGENTS

Arvy et al. D26,834/52; D26,704/54: X-irradiation increases the MC population of the thymus and lymph nodes in the intact but not in the adrenalectomized mouse. Cortisone reproduces this change even without X-irradiation and the mastocytosis is accompanied by the thymolysis characteristic of the alarm reaction; hence, it is assumed that mastocytosis of the lymphatic organs is characteristic of the G.A.S.

Kelényi C12,639/53: The granule clumping and discharge in the mesenteric and subcutaneous MCs induced by X-irradiation in the intact rat is unchanged by adrenalectomy.

Smith & Lewis C1,168/54: Adrenalectomy is without influence upon the total number and percentage of deformed (vacuolation and conglomeration of granules) MCs in the skin and mesentery of the rat; it also fails to alter the response of these cells to X-irradiation.

Pianigiani & Fiornovelli C71,744/58: Adrenalectomy accentuates the degranulation of MCs and the increase in extracellular metachromasia that is characteristic of acute exposure to cold, but it diminishes the second "counter-shock phase" of the response to stress, namely the disappearance of extracellular metachromatic material.

ADRENALINE

Boseila D58,293/63: Discussion.

Cronberg & Nilsson G10,504/64: Adrenaline or noradrenaline i.p. does not cause degranulation of rat peritoneal MCs.

Gabbiani & Rojo Ortega D55,958/64: Pretreatment with adrenaline protects the DHT-treated rat both against production of local calciphylactic response at the site of a subcutaneous ferric-dextran injection and against the production of a calcifying anaphylactoid reaction by ferric dextrin i.v. Curiously, the iron deposition in the shock organs is not prevented by any of these stressors.

Geiger et al. F11,948/64: When adrenaline is added to the culture medium of a murine mastocytoma cell suspension, there is increased cell proliferation, granule formation, and release.

Selye et al. G11,118/65: In rats pretreated with a single intravenous injection of lead acetate, the topical connective-tissue calcification produced by minute doses of various MC components (histamine, 5–HT) or MC-dischargers (48/80, polymyxin) can be inhibited by systemic treatment with large doses of any one among these same compounds. Adrenaline, another biogenic amine, exerts a similar protective effect although it does not produce mastocalcergy at any dose level.

GLUCOCORTICOIDS

Cavallero & Braccini B66,152/50: In the rat, cortisone s.c. causes a decrease in the number of MCs with degranulation of those remaining.

Cavallero & Braccini B63,645/51: Cortisone s.c. causes a decrease in the MC population of the skin, muscle, and heart in the rat. At the same time, the hyaluronic acid content of the connective tissue also diminishes. Similar changes are obtained topically at site of cortisone administration.

Stuart D2,340/51: Cortisone i.p. produces "changes" (not characterized) in the peritoneal MCs of the mouse.

Asboe-Hansen B74,068/52: Cortisone causes vacuolization, granule clumping, and degranulation of the cutaneous MCs of the guinea-pig, rabbit, mouse, and man. The apparent decrease in the total number of MCs induced by cortisone is ascribed to the fact that the cells are no longer demonstrable after they discharge their granules.

Charpy et al. D52,314/52: Intracutaneous injection of cortisone produces local MC proliferation in man. [It is possible that these cells were pseudo MCs, resulting from the phagocytosis of metachromatic carboxymethylcellulose contained in the vehicle (*H.S.*)].

Bloom B69,764/52: A spontaneous, malignant mastocytoma in a dog underwent rapid though not permanent involution under the influence of cortisone.

Arvy et al. D26,834/52: X-irradiation increases the MC population of the thymus and lymph nodes in the intact but not in the adrenalectomized mouse. Since cortisone reproduces this change even without X-irradiation and since the mastocytosis is accompanied by thymolysis it is assumed that mastocytosis of the lymphatic organs is characteristic of the G.A.S.

Kelsall & Crabb D26,640/52: The thymic atrophy induced by adrenal cortical extract or cortisone is not associated with any significant change in the thymic MC population of the hamster.

Buño B94,605/53; B90,623/53; D69,633/53; *Buño & Poletti* B94,604/53: Cortisone s.c. produces local MC degranulation at the site of injection in the rat; it exhibits the same effects even in vitro.

Romani B90,840/53: In rats given large doses of cortisone in carboxymethylcellulose as a suspending medium (route of administration not mentioned), a great increase in the number of MCs was noted in the skin, lymph nodes, spleen, and thymus. [It is very probable, however, that many of these cells were histiocytes with metachromatic carboxymethylcellulose granules (*H.S.*).]

Paff & Stewart B85,351/53: In tissue cultures of embryonic chick skin, the migration of MCs is inhibited in the vicinity of cortisone crystals added to the medium.

Schoch & Glick D26,848/53: Cortisone causes no consistent changes in the cutaneous MCs of the rat.

Kelsall & Crabb D28,690/53: Cortisone does not affect the MC population of the salivary glands in the hamster.

Fulton & Maynard D27,953/53: Cortisone s.c. causes a decrease in the number, size and granule content of the cheek-pouch MCs in the hamster.

Devitt & Samuels D26,863/53: Cortisone s.c. causes no change in the peritoneal, cardiac, and muscular MCs of the rat.

Devitt et al. B84,254/53: Observations on rats "failed to provide any evidence supporting the contention that the tissue mast cells are affected by cortisone."

Baker B84,820/53–54: Cortisol or cortisone s.c. does not influence the peritoneal MCs of the rat; on the other hand, local treatment of the skin with adrenal extract or cortisone reduces the size, granulation, and number of the MCs at the site of application only.

Zachariae & Moltke D26,761/54: Intradermal administration of cortisone or cortisol causes vacuolization of the MC-cytoplasm with great unequality of the granules, but no diminution of the MC-population within the injected area. Presumably, glucocorticoids act directly upon MCs.

Fulton et al. D39,660/54: Cortisone s.c. causes marked reduction of the mesenteric and cheek-pouch MCs with a corresponding reduction of histamine values in the hamster.

Asboe-Hansen C1,756/54: Cortisone causes degranulation of MCs in various species.

Devitt et al. B96,691/54: Repeated large doses of cortisone s.c. fail to alter the morphology of the MCs in various organs of the rat.

Baglioni C16,539/54, *pp. 198, 203*: Discussion.

Smith & Lewis C1,168/54: Small doses of cortisone increase the percentage of abnormal (vacuolation and granule conglomeration) MCs in the skin but not in the mesentery of the rat.

Arvy et al. D26,704/54: In mice exposed to severe total body X-irradiation, there develops a great increase in the MC count of the thymus, lymph nodes, Peyer's plaques, and bone marrow. The change is prevented by adrenalectomy but duplicated (even without X-irradiation) by cortisone. Presumably, mastocytosis represents one manifestation of the G.A.S. On the other hand, the local MC proliferation in the ear of the rat, produced by topical application of small doses of nonpenetrating X-rays is independent of the adrenal glands and cannot be attributed to the G.A.S.

Constantinides & Rutherdale C2,644/54: Cortisone s.c. significantly diminishes the cardiac MC population in the rat.

Turchini & van Kien D65,691/55: In the dog, chronic overdosage with cortisone considerably increases the number and heparin content of the hepatic MCs.

Smith & Lewis C4,564/55: The total number of MCs in the skin, mesentery, and cheek pouch of the Syrian hamster is not altered by cortisone but the percentage of abnormal cells (vacuolation, granule clumping) is considerably raised.

Rawlins C22,570/56: Discussion.

Bloom C74,089/56: Following local treatment with cortisone, the MCs in urticaria-pigmentosa lesions of man show vacuolization and disruption with release of granules and an increase in the number of binucleated and even multinucleated forms.

Ito E57,790/56–57: Following cortisone i.m., the MCs in the popliteal lymph node of the rat disintegrate.

Wegelius & Asboe-Hansen C18,789/56; *Asboe-Hansen* C77,655/57: In the cheek pouch of the hamster cortisone causes degranulation, clumping, and vacuolation of MCs.

Constantinides & Rutherdale C56,628/57: Cortisone produces a significant decrease in the cardiac MC count of the rat. Lipoadrenal extract has no effect.

Kelsall & Crabb D30,528/57: In the hamster "cortisone did not alter the number of mast cells in islands of Langerhans, thyroid, parathyroid, and adrenal glands."

Speirs & Wenck C34,890/57: In amounts suitable for the inhibition of inflammation, cortisone fails to affect the peritoneal MCs of the mouse.

Smith D63,176/58: Cortisone s.c. causes discharge of the mesenteric MCs in the rat and cheek pouch MCs in the hamster, the granules being subsequently phagocytosed by fibroblasts, macrophages and leukocytes.

Kelly & Bloom G9,515/59: In rats treated with cortisone, the peritoneal MCs show degeneration of granules and cellular polymorphism. In some cells, the nucleus allegedly disappears.

Salvato C73,693/59: In patients treated with dexamethasone, biopsies of the orifice of the middle-lobe bronchus reveal degranulation or orthochromatic granulation of MCs.

Hill & Pospíšil D26,881/60; C99,519/60: Cortisol i.m. causes swelling of granules and vacuole formation in the mesenteric MCs of the rat.

Räsänen C81,536/60: Cortisone causes rapid MC-degranulation in the gastric mucosa and skin of the rat.

Alonzo & Cilento D26,832/60: Cortisol causes inflammation and edema in the gastric mucosa of the rat. This is associated with an increase in MC count.

Messerklinger D26,431/60: Topical MC atrophy is seen in the trachea at the site of cortisone administration in man.

Bloom E22,677/60: Rat peritoneal MCs decrease in number, size, and dry mass after injection of cortisone.

Smyth & Gum D4,499/61: Purpura and necrotizing vasculitis may complicate heavy corticoid therapy in rheumatoid arthritis. This is ascribed to the liberation of heparin, hyaluronic acid, and histamine from the MCs.

Räsänen D3,451/61: In the rat prednisolone i.m. causes degranulation of the gastric MCs with a drop in tissue eosinophils in the lamina propria of the stomach. DOC produces neither MC degranulation nor disappearance of eosinophils. "It is suggested that glucocorticoids conjugate in the lamina propria of the gastro-intestinal canal with the polysaccharides of the mast granules, and that the tissue eosinophils eliminate the histamine and serotonin liberated."

Cronberg D16,785/61: The MCs in the free peritoneal fluid and in the mesentery of the rat show no significant changes following cortisol or prednisolone s.c. or i.p. Only after 14 days of continuous cortisol i.p. do the MCs disappear from the peritoneal fluid.

Kelsall D7,784/61: MCs are rare along the afferent lymphatics and lymph nodes in hamsters treated with cortisone.

Räsänen D33,739/62; E92,220/62; D33,740/62: Dexamethasone (16α-methyl-9α-fluoroprednisolone), prednisolone, and cortisol i.m. cause degranulation of the gastric MCs in the rat. The intensity of the change appears to be "correlated with the catabolic biological activity of the glucocorticoids."

Csaba & Mold D32,196/62: Cortisone pretreatment in vivo stimulates the production of MCs in subsequently-removed rat thymus tissue cultured in vitro.

Parekh & Glick D27,898/62: Cortisone does not alter the hexosamine content of intact rat peritoneal MCs.

Foley & Glick D39,767/62: Cortisone causes a roughly parallel diminution of MCs and histamine in the gastric mucosa of the rat. At the same time there is an increase in parietal cells. These findings "might be interpreted in support of a functional relationship between the depletion of mast cells with an accompanying liberation of histamine from the gastric mucosa, and an increase in parietal cells, with greater tendency to formation of gastric ulcer in rats deprived of food."

Boseila D58,293/63: Discussion.

Haikonen & Räsänen G1,314/63; *Räsänen* D39,969/63; *Räsänen* E22,623/63: Various glucocorticoids cause degranulation of the gastric MCs in the mouse and rat. This may play a role in the production of stress-induced gastric ulcers.

Monkhouse & Baker E27,204/63: Even large doses of cortisone failed to alter the peritoneal MC content of the rat.

Csaba & Kulmann G2,694/63: *Csaba et al.* E36,438/63: Cortisone injected into an air sac (granuloma-pouch technique) in the subcutaneous tissue of the rat causes an initial increase after three minutes, followed by a decrease after fifteen minutes, of the local MC population.

GLUCOCORTICOIDS + OTHER AGENTS

Romani C672/53: In the surroundings of a subcutaneous *turpentine* abscess the MC-count increases in the rat. This increase is further augmented by cortisone or cortisol s.c. It is concluded that glucocorticoids exert a strong "trophic effect" upon the MCs. No mention is made of the many contrary claims in the literature.

Baker B84,820/53–54: The degranulation of the peritoneal MCs produced by *peptone* i.p. in the rat is associated with the appearance of stellate clasmatocytes which may be newly-formed MCs or phagocytes that have ingested MC granules. "Cortisone failed to protect mast cells from loss of granules and also did not modify significantly the uptake of release granules by paravascular clasmatocytes."

Asboe-Hansen B91,127/54: Cortisone diminishes the number and S^{35}-uptake of the MCs that appear in the mouse skin areas painted with *9,10-dimethyl-1,2-benzanthracene.*

Asboe-Hansen & Zachariae C10,677/55: In mice, cutaneous papillomas induced by *9,10-dimethyl-1,2-benzanthracene,* regress following injection of cortisone or cortisol into the connective tissue just beneath the tumors. This is accompanied by moderate changes in the local MC population, yet, the experiment was interpreted as suggesting some relationship between MCs and carcinogenesis.

Gemählich et al. D27,072/58: The "anaphylatoxic shock" produced in guinea-pigs by a single intracardiac injection of *anaphylatoxin* (prepared by treating rat serum with insulin) is associated with intense degranulation of the MCs in the skin, lung, liver, spleen, and mesentery. This response is not altered by pretreatment with stilbamidine but both the shock and the MC degranulation are prevented by pretreatment with prednisone.

Calzavara et al. D10,222/60: The peritoneal MC degranulation (associated with amitosis) elicited by *X-irradiation* in the rat is inhibited by pretreatment with hyaluronic acid and an antihistaminic (Fargan), but not by cortisone.

Togawa D39,528/60–61: The MC-count which normally rises during chronic viral hepatitis in man is diminished as a consequence of glucocorticoid therapy.

Valtonen & Kock D66,170/63: Cortisone diminishes the cutaneous mastocytosis normally produced by ultraviolet irradiation in the mouse.

MINERALOCORTICOIDS

Devitt & Samuels D26,863/53; *Devitt et al.* B96,691/54; DOC s.c. causes no change in the MCs of the mesentery, heart, or skeletal musculature of the rat.

Smith & Lewis C1,168/54: Even large doses of DOC (5 mg/rat/day) s.c. induce no change in the cutaneous and mesenteric MCs of the rat.

Constantinides & Rutherdale C2,664/54; C56,628/57: DOC s.c. has no effect upon the cardiac MC population of the rat.

Smith & Lewis C4,564/55: Even heavy overdosage with DOC remains without influence upon the MCs in the skin, mesentery, and cheek pouch of the hamster.

Räsänen E92,220/62: Aldosterone, unlike DOC, causes no degranulation of the gastric-mucosa MCs in the rat.

Csaba & Mold D32,196/62: DOC treatment in vivo has no effect upon the subsequent production of MCs in rat thymus tissue cultured in vitro.

Csaba et al. E36,438/63: DOC causes a decrease in the MC population of the rat thymus and, in this respect, cortisone exerts an antagonistic effect.

Boseila D58,293/63: Discussion.

OVARIECTOMY

Iversen D39,756/62: Ovariectomy causes no change in the number of uterine MCs in the guinea-pig but the granules become denser. Testosterone increases the number of MCs in the uterus of ovariectomized guinea-pigs. The cells also become larger and the granules almost orthochromatic.

Harvey G13,574/64: Ovariectomy does not significantly alter the MC density in the hamster uterus, but it prevents the usual cyclic changes. "Estrogen" (kind not stated) did not significantly alter uterine MC density in spayed females.

FOLLICULOIDS (ESTROGENS)

Aykroyd & Zuckerman 73,722/38: The swelling and hyperemia of the sexual skin elicited by estriol in the rhesus monkey (*M. mulatta*) is accompanied by the formation of a gelatinous exudate and enlargement of the fibroblasts (*Bachman et al.* 31,404/35) and occurs even after denervation in skin transplants (*Bachman et al.* 66,256/36). Furthermore, the erection of the cock's comb under the influence of androgens is due to the secretion of mucoprotein into the intercellular spaces (*Hardesty* 29,533/31). Yet, in the rhesus monkey,

the intercellular spaces give negative reactions for mucoproteins with various dyes (including toluidine blue, mucicarmine, and mucisudan) in both active and inactive sexual skin. "The main difference between the two types of skin lies in the fact that mast cells filled with granules of what is generally believed to be mucoprotein are present in the inactive phase, and appear to be partly depleted of their granules when the skin is oedematous." This observation "suggests that in phases of oestrogenic stimulation the mast cells discharge mucoprotein into the intercellular spaces. This mucoprotein may be able to hold some of the intercellular water."

Baglioni D28,698/45: During chronic treatment with estradiol, the MCs in the nipple of male rats initially increase but later diminish in number, concurrently with the development of cystic changes.

Brusa D39,831/49: In the uterus of the normal prepubertal mouse there are only few MCs and their number is not altered by treatment with LH or folliculoids. On the other hand, during pregnancy and lactation the uterine MC count increases considerably.

Baglioni C16,539/54, *pp. 182, 192*: Discussion.

Constantinides & Rutherdale C2,644/54: Stilbestrol significantly diminishes the cardiac MC population of the rat.

Baglioni & Lorenzoni C15,454/55: The number of MCs in the capsule and stroma of Walker tumors initially increases and then decreases below control values in rats chronically treated with stilbestrol. Parallel changes are seen in the argentaffin reticulum of the neoplastic tissue, but it remains to be seen whether the latter are consequences of the former.

Arvy C9,738/55: Estradiol increases the MC count in various tissues (lymph nodes, thymus, salivary glands, intestine, genital organs, skin) of the mouse. "This increase in the number of mast cells is different from that described in the general syndrome of adaptation, either after injections of alloxan, or after irradiation with X-rays, because it is generalized and not limited to haemopoietic organs."

Olivi C14,795/55: Following intense overdosage with estradiol, there is a considerable increase in the MC population of the mammary glands, both in intact and in ovariectomized female mice. At the same time, the secretion within the galactophores occasionally becomes metachromatic. Conversely, in males, estradiol diminishes the mammary-gland MC population.

Westin C11,073/55; C23,800/56: Following ovariectomy, the MC population of the mouse uterus increases, while subsequent estradiol treatment reduces it below normal. Progesterone slightly offsets this action of the estradiol.

Kelsall & Crabb D29,289/56: Treatment with "aqueous estrogen" (kind not stated) increases the MC population of the mammary gland, uterus, and lieno-pancreatic mesentery, but not that of the other organs in the female hamster.

Kelsall & Crabb D28,657/56; D30,528/57: In hamsters treated with "aqueous estrogen", alone or in combination with progesterone, uterine stimulation is unaccompanied by any increase in MC content or diffuse metachromasia of the endometrium.

Westin & Odeblad C22,791/56: The MC count in the vagina of ovariectomized mice is greatly diminished by estradiol. This suppression appears to be partly inhibited by progesterone.

Constantinides & Rutherdale C56,628/57: Ovariectomy does not affect the cardiac MC count in the rat. Concurrent treatment with progesterone also causes no change, while stilbestrol and estradiol significantly diminish the cardiac MCs of the ovariectomized rat.

Johansson & Westin C37,608/57: Estradiol significantly decreases the number of MCs in the uterus of the spayed mouse.

Smith & Lewis C72,227/58: Folliculoids have no effect upon the MCs of rat skin and mesentery.

Bergström et al. C53,172/58: Prolonged treatment with estradiol decreases the MC population of the uterus in ovariectomized mice, concurrently with the development of a local tissue edema.

Johansson & Westin C67,836/59: Estradiol s.c. causes a diminution of the MC population in the uterus and vagina of the mouse, as judged by metachromasia and S^{35}-content. However, the number of cutaneous MCs and the blood-coagulation time remain unchanged. Hence, "the conclusion is drawn that the effect of oestrogen on the mast cells is a local process within the reproductive organs."

Kelsall & Crabb D26,076/59, *p. 118*: Discussion.

Iversen C90,461/60: There is a significant decrease in the MC-count of the myometrium of the human cervix uteri during estrogenic treatment.

Kelsall D7,784/61: Discussion.

Schiff & Burn D3,030/61: Conjugated estrogens i.v. cause diffuse metachromasia and MC-degranulation in the oral mucosa of the hamster, monkey, and man.

Schiff & Burn D28,988/61: The degranulation of the MCs in the buccal mucosa, produced by traumatic surgical interventions in man, can be partly inhibited by pretreatment with conjugated estrogens (Premarin).

Csaba & Mold D32,196/62: In vivo treatment with estrone has no effect upon the MC-production in rat thymus tissue subsequently cultured in vitro.

Iversen D39,756/62: While small doses of estradiol decrease the number of uterine MCs in the guinea-pig, prolonged treatment with large doses has an opposite effect.

Carril et al. G16,997/62: Treatment with conjugated estrogens increases the MC-concentration in the oral mucosa of man.

Boseila D58,293/63: Discussion.

Winer et al. D32,027/63: Estrone was applied by daily inunction to the skin of hairless mice, since earlier experiments (*Selye* A57,745/44) had shown that, under these conditions, topical applications of estrogens produce a nonpitting edema. "Degranulation of mast cells occurred extensively in all mice treated with estrone. The intensity of mast cell degranulation was directly related to the presence of acid mucopolysaccharide in the dermis."

LUTEOIDS (PROGESTOGENS)

Baglioni C16,539/54, *pp. 191, 192*: Discussion.

Constantinides & Rutherdale C2,644/54: Progesterone fails to influence the cardiac MC population of the rat.

Smith & Lewis C72,227/58: Progesterone has no effect upon the MCs of the rat skin and mesentery.

Persson D9,616/60: Simultaneous treatment with estradiol and progesterone increases the MC count in the mammary gland of the rat.

Boseila D58,293/63: Discussion.

TESTOIDS (ANDROGENS)

Constantinides & Rutherdale C2,644/54; C56,628/57: Neither testosterone nor orchidectomy exert any significant influence upon the cardiac MC population of the rat.

Szirmai C43,968/57: The MCs in the rooster's comb are not significantly affected either by castration or by subsequent testosterone treatment.

Johansson & Westin C37,608/57: Testosterone significantly decreases the number of MCs in the uterus of the spayed mouse.

Smith & Lewis C72,227/58: Testosterone has no effect upon the MCs of the rat skin and mesentery.

Iversen C90,461/60: Testoids significantly decrease the MC count in the human cervix uteri.

Kelsall D7,784/61: In male hamsters, testosterone increases the number of MCs along capillaries in the connective tissues surrounding the sebaceous glands.

Csaba & Mold D32,196/62: In vivo pretreatment with testosterone does not influence the production of MCs in tissue cultures of subsequently-removed thymus fragments.

Gabbiani D32,379/62: Pretreatment with methyltestosterone prevents the calciphylactic responses obtainable in DHT-pretreated rats by subsequent administration of thorium dextrin, ovalbumen, or 5-HT. [Although MCs play a decisive role in the pathogenesis of some of these calciphylactic responses, the protective effect of methyltestosterone is probably not due to a direct action upon the MCs, but to the well-known anti-DHT effect of anabolic androgens (*H.S.*).]

Boseila D58,293/63: Discussion.

THYROID HORMONES

Arvy et al. D31,614/50: Thiourea greatly increases the number of MCs in the intestinal tract, skin, and bone marrow of the rat. This effect is not observed in animals simultaneously treated with thyroxine.

Arvy & Gabe B50,130/50: In rats, thiocarbamide p.o. considerably increases the MC population of connective tissues, spleen, lymph nodes, and bone marrow.

Asboe-Hansen B60,548/50: Thyroxin considerably decreases the otherwise numerous MCs of myxedematous skin in man.

Devitt & Samuels D26,863/53; *Devitt et al.* B84,254/53; B96,691/54: Thyroxin s.c. does not alter the peritoneal, cardiac, or skeletal-muscle MCs of the rat.

Conte et al. D65,692/54: In the rat, thyroidectomy (or thiouracil treatment) increases the dermal but not the bone-marrow concentration of MCs and mucopolysaccharides.

Constantinides & Rutherdale C2,644/54: Thyroidectomy has no effect, but thyroxin significantly diminishes the cardiac MC population of the rat.

Baglioni C16,539/54, *pp. 200, 201*: Discussion.

Conte et al. D26,730/55: Thyroidectomy and, to a lesser extent, thiourea increase the dermal-acid mucopolysaccharides and the MC count in the rat, while iodine administration brings about no change. In bone-marrow smears, however, the MCs decrease after thyroidectomy, and are unaltered by thiourea. Iodine decreases the MC count in the bone-marrow of intact rats but increases it in thyroidectomized animals.

Wegelius & Asboe-Hansen C18,789/56: Thyroxin degranulates the MCs in the cheek pouch of the hamster; only the small perivascular MCs remain intact.

Asboe-Hansen C77,655/57: Thyroxin causes no change in the cheek-pouch MCs of the hamster.

Grunbaum et al. C31,429/57: Overdosage with propylthiouracil induces no change in the MCs of the external ear in rats.

Constantinides & Rutherdale C56,628/57: Both thyroidectomy and thyroxin fail to affect the cardiac MC count in the rat.

Dyrbye et al. C77,936/59: Thyroxin fails to influence the cutaneous MCs of the mouse.

Hughes & Claudatus D40,024/62: Thyro-parathyroidectomy decreases the uptake of radioactive sulfate by rat peritoneal MCs.

Fernex D66,465/62: In the mesentery and myocardium of rats fed an infarct-producing high lipid diet with thiouracil, the number of MCs decreases and at the same time there is blood eosinopenia.

Santini D64,084/62: In rat thyroid glands made hypoactive by thyroxin treatment, MCs are numerous and show no sign of degranulation.

Boseila D58,293/63: Discussion.

Räsänen G19,874/64: The gastric MCs of the rat undergo degranulation and decrease in number following treatment with insulin.

INSULIN AND ALLOXAN

Arvy & Gabe B44,853/49: During alloxan intoxication the number of MCs in the thymus, bone marrow, and lymph nodes of the rat increases considerably, perhaps as a consequence of the resulting G.A.S.

Härmä & Suomalainen B65,284/51: Insulin induces artificial hibernation in the hedgehog, even during the summer and with particular ease in October when the animals are approaching the time of normal hibernation. Here, insulin increases the MC count as does normal hibernation.

Arvy et al. D26,704/54: Alloxan increases the MC population of the lymphatic and hemopoietic organs in the mouse, but this may be a stress effect.

Csaba & Mold D32,196/62: In vivo pretreatment with insulin does not influence the production of MCs in tissue cultures of subsequently removed thymus tissue of the rat.

Boseila D58,293/63: Discussion.

OTHER HORMONES AND TISSUE EXTRACTS

Plimpton D76,318/40: Ventriculin (a powdered, defatted hog gastric-tissue preparation) produces accumulation of basophils and MCs at subcutaneous injection sites in the guinea-pig. Since basophil myelocytes also appear in the exudate, it is assumed that the basophils come from the bone marrow.

Giarman & Potter C51,848/58; *Giarman et al.* C99,663/60: Extracts of various rat tissues, especially those of brain and kidney, cause release of 5-HT from isolated mouse ascites tumor MCs. Blood is inactive. The releasing effect can be blocked by glucose.

Archer D27,393/58: Isolated rat peritoneal MCs exposed to saline extracts of spleen, kidney, liver, or lung (from rat or rabbit), disintegrate and release their histamine. Extracts of erythrocytes (human or rat) have no such effect. "These experiments in vitro with mast cells suggest that injured nucleated cells produce a factor which leads to the disintegration of mast cells and the release of histamine. The active principle derived from injured cells appears to be an arginine containing polypeptide. The same mechanism may be responsible for the release of histamine when cells are injured in vivo."

Archer D26,626/59; C78,034/59: Splenic extracts and particularly rat spleen histone, added to a suspension of rat peritoneal MCs, cause granule discharge and a release of histamine. It is thought that the degranulating factor is released from nucleated cells and represents an arginine-containing polypeptide, possibly derived from histone.

Csaba et al. D33,082/61: Following thymus involution owing to advanced age, as well as after thymectomy, the MC count in the lymph nodes of the rat increases. It is assumed that the lymph nodes may take over the supposed MC-producing ability of the thymus.

Boseila D58,293/63: Discussion on the effect of relaxin on MCs.

Walker D19,393/64: The frequency of MCs in the tissues of dystrophic mice is not altered by thymectomy.

Walker F9,506/64: Neonatal thymectomy did not significantly reduce the MC-population in the skin and tongue of young and adult mice. "Consequently, the thymus is not necessary for mast cell production during postnatal development."

Zeppa et al. F14,725/64: Gastrin causes histamine release from rat peritoneal MCs in vitro. It is assumed "that histamine release by gastrin is of sufficient magnitude to be involved in the mechanism of gastric secretion."

Cărbunescu et al. E96,976/64: In rats with Guérin tumor transplants, hypophyseal implants increase, while adrenal implants decrease MC density within the tumor capsule.

DRUGS IN GENERAL

The following pages represent essentially an alphabetic index of those drugs whose effects upon MCs have been examined. The actions of such a large and heterogenous group of compounds do not lend themselves well to a synoptic discussion; hence, in this preamble we shall only comment on a few particularly striking observations, those that permit generalizations or appear to open up especially fruitful avenues for further research.

To start with, it must be understood that any compound — including even distilled water or physiologic salt solutions — will cause topical MC degranulation if injected in sufficiently large amounts. The ability of certain compounds to produce MC degranulation specifically (at low dose levels and with the least possible side effects) is essentially a matter of degree.

The following are some of the most commonly used and specific MC degranulators:

Anaphylotoxin
Bacterial toxins
Compound 48/80
Decamethylene diamine
Decylamine
Dextran and its metallic chelates
Dextrin and its metallic chelates
Emulsifiers
Enzymes (lecithinase A, chymotrypsin)
Hexadimethrine
Invertebrate, plant, and microbial toxins
Octylamine
Ovalbumen and ovomucoid
Peptone
Polymyxin
Polyvinylpyrrolidone (PVP)
Protamine
Stilbamidine
Viomycin
Water (osmotic pressure)

Among these there are different types of MC-dischargers: (1) Those which act only locally at the site of their injection (e.g., distilled water); (2) Compounds

which affect the MCs more or less diffusely throughout the organism (e.g., 48/80, polymyxin); and (3) Agents having a specific organotropicity. These discharge the MCs only in certain regions, even if they are given systemically (e.g., ovalbumen, dextran, and dextrin cause MC discharge in the anaphylactoid shock organs, ferric oxysaccharate in the choledochus of the rat).

There are also great species variations in sensitivity to certain MC-dischargers. For example, the MCs of the rat are very sensitive to 48/80 and polymyxin, while those of the guinea-pig are not; the MCs of the rat are comparatively resistant to PVP and peptone, while in the dog PVP causes intense MC degranulation in the skin and peptone in the liver.

The mechanism of MC discharge likewise varies, depending upon the species and the agent under study: the discharge may apparently be induced through an energy-requiring enzymatic process or through various nonenzymatic mechanisms.

A few of these points, as well as the relationship between granule discharge and the release of histamine, 5–HT and heparin, the extinction of metachromasia without granule discharge, the formation of "pseudo mast cells" by the ingestion of exogenous metachromatic substances, etc., deserve special comment.

It has been recommended to *distinguish between histamine releasers and histamine liberators* mainly on the basis of the specificity of the response elicited by the latter; however, there are so many transitions between substances causing histamine release as a side effect and the more specific histamine liberators, that this classification is often difficult to apply.

A great deal of work on MC degranulation has been done with *compound 48/80,* a condensation product of p-methoxyphenethylmethylamine with formalin, which we might use as our prototype in the discussion of typical MC-dischargers.

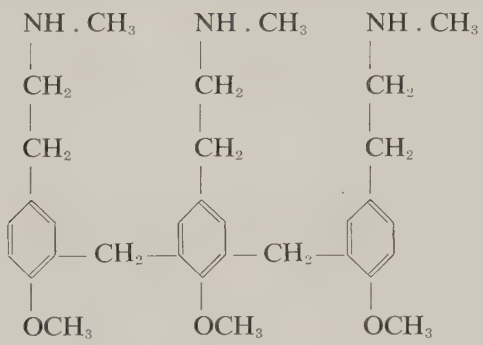

Compound 48/80 (general type of polymeric structure)

48/80 is especially effective in producing MC degranulation in various species, in vivo and in vitro, presumably through an enzymatic energy-requiring metabolic process. This release can be blocked by various enzyme inhibitors and the blockade can in turn be overcome by antagonists of the inhibitors. However, in the guinea-pig 48/80 hardly affects the MCs and the agents that do apparently act through nonenzymatic mechanisms. Whereas in the rat, the MC-disruptive action of 48/80 is maximal, it is never more than slight in the mouse. The guinea-pig intestine is most resistant to the MC-degranulating and histamine-depleting action of 48/80.

Systemically-administered 48/80 (as many other histamine liberators) acts upon the MC population of almost all parts of the body, but even this compound exhibits some degree of selective organotropicity. Following chronic treatment with 48/80 (and many other MC-dischargers), a certain adaptation occurs and here again the MCs of different regions do not necessarily recover at the same time.

Histamine release usually parallels the degree of MC degranulation.

Curiously, 48/80 releases histamine even from isolated MC granules while antigens release it only from intact MCs of sensitized animals. Compound 48/80 or polymyxin, unlike dextran or ovomucoid, release the granules and histamine from rat peritoneal MCs isolated on a Millipore filter. It was assumed, therefore, that 48/80 and polymyxin do, while dextran and ovomucoid do not act directly upon MCs. In any event, these two types of MC-dischargers differ from each other in many respects. For example, 48/80 and polymyxin produce only a very diffuse type of anaphylactoid skin reaction but, in rats prepared by lead acetate for calcergy, they cause intense peritoneal calcification when injected i.p. Conversely, dextran and ovomucoid produce a severe anaphylactoid inflammation selectively in the shock organs but they fail to elicit peritoneal calcification in rats prepared for calcergy.

Histamine is virtually ineffective as an MC-degranulator when given systemically. Even upon topical administration, its MC-discharging effect is extremely mild and presumably secondary to the local edema which it produces.

Up to now little attention has been given to the antagonists of MC-dischargers, yet some *antihistaminics* do not merely antagonize histamine but inhibit MC disruption and the associated histamine liberation as well. On the other hand, under appropriate conditions certain antihistaminics can cause MC discharge.

Peptone i.v. disrupts only few cutaneous MCs in the dog although it causes pronounced MC-degranulation in the liver.

During the acute edematous phase of inflammation produced by various *phlogogens,* (microbial or chemical irritants), the local MC population becomes depleted of granules while in chronic inflammations the number of MCs may rise above normal.

Various edema-producing *toxic substances of invertebrates and plants* (e.g., those of stinging nettles, stinging jellyfish, *Ascaris lumbricoides,* bee venom, snake venom, etc.) all produce intense MC degranulation. Certain helminthic infestations, on the other hand, increase the number of MCs in connective tissue.

Among the *enzymes,* lecithinase A has received special attention because it is assumed that a number of MC-dischargers act by removing an inhibitor of this enzyme which is a strong and perhaps a natural endogenous MC-discharger. Its MC-degranulating effect is blocked by anoxia and the blockade is prevented by glucose. Yet, chymotrypsin-like enzymes are also strong MC-degranulators and they may be involved in the activation of lecithinase A through the destruction of its physiologic inhibitor. Although large doses of hyaluronidase can produce MC discharge, this effect is presumably nonspecific since it is shared by a great variety of other agents. According to most investigators, the metachromatic granules themselves are not dissolved by hyaluronidase and, hence, they are unlikely to contain large amounts of hyaluronic acid. The mechanism of MC degranulation is still far from being elucidated, but available evidence suggests that different MC-degranulators probably act through distinct mechanisms.

In experimental *lathyrism,* the bone-MC count is increased and the blood-clotting time is prolonged.

Repeated intravenous injections of *lead acetate* can produce osteomyelosclerosis with the formation of numerous MCs in and around the newly-formed bone trabeculae in the rat.

Carboxymethylcellulose, mucin, carrageenin, heparin, chondroitin sulfate, and other metachromatically-staining polysaccharides can be taken up by phagocytes and thus form "quasi mast cells" or *"pseudo mast cells"* which may be difficult to distinguish from true MCs.

It has also been said that following s.c. injection of hexose polysaccharides (glycogen inulin, dextran), numerous MCs appear in the regional lymph nodes of the rat. It should be kept in mind, however, that these may be "pseudo mast cells" resulting from the ingestion by phagocytes of materials that can be transformed into metachromatic granules.

Colchicine and podophyllin produce a curious deformation of MCs which is allegedly quite characteristic for this group of antimitotic compounds.

A variety of *basic colloids* (e.g., protamine, lysozyme, thymus histone, hemoglobin) induces loss of metachromatic stainability both in living and in fixed MCs. Acid colloids block this inhibition. It has been assumed that the stainability of MCs (and, hence, their apparent number) may depend upon the balance between acid and basic colloids in the surrounding tissue fluid.

Topical infiltration of the connective tissue with MCs has been observed at the site of application of various *carcinogens,* particularly tar, dimethylbenzanthracene, benzpyrene, and methylcholanthrene. The response is more evident in mice than in rats or other species, and usually reaches a maximum just prior to the appearance of malignant changes. The resulting tumors themselves are not especially rich in MCs. The MC accumulation is often associated with a topical increase in 5–HT or some related compound which gives a brown fluorescence upon treatment with formaldehyde. Most of the relevant work has been performed by the application of carcinogens to the skin; little information is available on similar responses in internal organs.

It remains to be proved whether the carcinogen-induced MC accumulation represents a specific antitumoral defense reaction, as some authors believe, since mastocytosis also occurs in chronic inflammations induced by other means. In spontaneous and transplanted tumors, the MC count shows no constant increase, but this fact does not invalidate the view that MC proliferation has an antitumoral defensive value because even the carcinogen-induced mastocytosis tends to vanish once a neoplasm is fully established.

A great deal of work has been done on the participation of MCs in *calciphylaxis and calcergy.* Following appropriate pretreatment, various MC-dischargers (polymyxin, 48/80, viomycin, stilbamidine) or MC products (5–HT, histamine) can cause calcification at the site of their injection when given s.c., or even at distant sites when introduced into the blood stream. Histochemical studies showed that, here, calcification begins around discharged MC granules or the exogenously-introduced MC products. Pretreatment with histamine-dischargers, which deplete the MC population, or with antihistaminics and antiserotonins, which antagonize the MC products, offers protection against this type of calcification. These observations suggest that the MC can play an important role in soft-tissue mineralization.

ACETONE

Larsson & Sylvén D31,567/47; *Sylvén & Larsson* D26,612/48: Topical application of acetone to the shaved skin of the mouse causes no obvious change in the local MC population.

ACHROMYCIN

Norton & de Beer D30,591/55: Topical application of achromycin to the rat mesentery in vitro failed to cause MC degranulation.

AGAR-AGAR

Higginbotham et al. D15,838/56: Topical treatment with agar-agar solution causes local MC degranulation in the mouse skin.

ALEURONAT

Coenen D29,293/01: In the pleuritic fluid, which develops after intrapleural injection of aleuronat in the rabbit, only few MCs are found.

ALLICIN

Högberg & Uvnäs D26,477/58: Allicin (an enzyme-inhibitor from garlic) prevents the degranulation of rat peritoneal MCs which is otherwise produced by 48/80, ascaris extract, antigen-antibody reaction, or lecithinase A. Glutathione in excess reverses this blockade of degranulation.

ALUMINUM DEXTRAN

Selye et al. D58,540/63; E24,102/64: In rats calciphylactically sensitized with DHT, aluminum dextran produces calcification in the autonomic nervous system and anaphylactoid shock organs. Since aluminum dextran is a MC-discharger which produces an anaphylactoid reaction in non-sensitized animals, it is assumed that the calcifying syndrome that develops in the DHT-treated rat is, at least partly, dependent upon MC degranulation.

AMINO-CAPROIC ACID

Fergula et al. D68,157/63: In rats bearing a granuloma pouch induced with croton oil, pretreatment with epsilon-amino-caproic acid reduced the inflammation parallel to an inhibition of MC disruption. It is concluded that the MCs may play a role in inflammation and that epsilon-amino-caproic acid protects them from disruption.

AMMONIUM HYDROXIDE

West C19,992/56: NH_4OH i.p. depletes the omental and mesenteric MCs but not the subcutaneous MCs in the rat. The histamine content of these tissues roughly parallels the MC count.

AMMONIUM OXALATE

Bray & Van Arsdel D26,900/61: The isolated peritoneal MCs of the rat discharge their histamine under the influence of ammonium oxalate.

ANAPHYLOTOXIN

Riley B90,276/53: Anaphylotoxin (prepared by incubating agar with rat serum) produces degranulation of the Type II peritoneal MCs in the rat while the Type I MCs are comparatively little affected. Similar degranulation of peritoneal MCs may also be obtained by the topical application of anaphylotoxin to the mesentery.

Grossberg & Garcia-Arocha D28,699/54: When the large granule fraction of dog-liver homogenates is exposed to anaphylotoxin, it releases its histamine.

Gemählich et al. D27,072/58: Shock was produced in guinea-pigs by a single intracardiac injection of anaphylotoxin (prepared by treating rat serum with inulin). There resulted intense degranulation of the MCs in the skin, lung, liver, spleen, and mesentery. This was not altered by pretreatment with stilbamidine, but both the shock and the MC-degranulation could be prevented by pretreatment with prednisone.

Mota D26,627/59: When isolated guinea-pig mesentery is exposed to anaphylotoxin (prepared by incubating rat serum or heparinized plasma with agar) the MCs discharge their granules in a manner quite similar to the degranulation elicited by anaphylaxis. This degranulation can be largely inhibited by iodoacetate, p-chloromercuribenzoate, and phenol. Calcium lack (calcium-free Tyrode containing 0.01 per cent "Versine") or previous heating of the tissue to 45°C does not inhibit the MC-damaging effect of anaphylotoxin. On the other hand, exposure to cold prevents it. These and other observations led to the conclusion that the mechanism of action of anaphylotoxin is quite different from that of chemical histamine liberators.

ANTIBIOTICS

Cf. also POLYMYXIN, STILBAMIDINE, AUREOMYCIN, BACITRACIN, CYCLIZINE, ACHROMYCIN, PENICILLIN.

Baglioni C16,539/54, *p. 208:* Discussion.

ANTIHISTAMINE LIBERATORS

Högberg et al. D25,640/56; *Högberg & Uvnäs* C47,831/57: Polyphloretin phosphate and polyestradiol phosphate inhibit MC disruption and histamine release.

Högberg et al. D26,423/57: MC disruption and histamine release are inhibited by polymeric, negatively-charged compounds such as polysaccharide fractions from hip seeds.

Fernö et al. D23,700/60: A synthetic polymeric carboxylic acid (polysalicylic acid) inhibits both the MC disruption and the histamine release normally produced by compound 48/80, ascaris extract, *Cyanea capillata,* and antigen-antibody reaction, as shown by in vitro observations on rat mesentery MCs.

ANTIHISTAMINICS

Stuart D15,D89/52: In rabbits, guinea-pigs, dogs, and mice in which anaphylactic shock is induced by egg albumen, the organs most affected by anaphylaxis are those richest in MCs. Here, the MCs show marked degranulation, but this change is diminished if anaphylaxis is prevented by pretreatment with antihistaminics. "These correlations suggest that the mast cell acts as a defense mechanism against alterations induced by anaphylaxis".

Riley B90,276/53: Pretreatment with anthisan protects the rat against the MC-disruptive effect of subsequently-administered histamine liberators or anaphylotoxin.

Arvy D65,694/55: Neo-Antergan (pyrilamine maleate) topically applied to the tongue causes no local MC degranulation.

Wegelius et al. D27,732/55: Injection of anthisan into the cheek pouch of the hamster results in unusually intense toluidine-blue staining of the local MCs.

Arvy C41,778/55: Injection of Neo-Antergan into the base of the tongue causes no change in the local MCs of *Rana esculenta.*

Norton & de Beer C5,279/55: Brief abstract which merely mentions that various antihistaminics differ in their ability to prevent the induction of MC-disruption in vitro in the rat mesentery.

Mota & Vugman D27,087/56: In guinea-pigs sensitized with egg albumen, reinjection of the antigen causes intense degranulation of the pulmonary MCs. This change is not prevented by pretreatment with an antihistaminic such as chlorprophenpyridamine. "Thus, antihistamine is ineffective in protecting mast cells from damage resulting from the specific antigen, seeming rather to act by blocking tissue receptors against free histamine than by preventing the release of histamine".

McGovern D28,556/56: Antazoline i.v. in near lethal doses produces MC disruption and "the appearance of metachromatic bubbles in the intercellular cement lines of the various endothelia in the same way as other well-recognised histamine-release agents", both around the bronchi and in the peritoneum of the rat. Similar changes are produced on the peritoneal surface mesothelium. Apparently, this antihistaminic has some MC-disrupting and histamine-liberating effect.

Braunsteiner et al. D27,986/57: The degranulation of the bone marrow MCs, normally induced by i.v. injection of the histamine liberator diaminodecane in the rat, is considerably diminished following pretreatment with the antihistamine Phenergan.

Fontanini et al. D39,752/58: The MCs of the rat mesentery discharge their granules under the influence of various antihistaminics (Antistine, Fargan, and Trimeton) irrespective of the

route of administration. This is not accompanied by a prolongation of the blood-clotting time, and may or may not be associated with signs of systemic histamine intoxication.

Mota & da Silva D26,563/60: Experiments on the rat and guinea-pig led to the conclusion that antihistamines can act in three ways: (1) by competitive inhibition of histamine; (2) by destroying MCs and releasing histamine; and (3) by preventing MC damage and histamine release in anaphylaxis. Antihistamines also potentiate MC damage and histamine release by 48/80 when acting on guinea-pig tissues and inhibit these phenomena when acting on rat tissues. "It is concluded that the effect of antihistamines in anaphylaxis is possibly due both to their competitive inhibition of histamine on smooth muscle receptors and to their inhibition of mast cell damage and histamine release by antigen".

Colosi D30,552/60: The addition of antihistamines to the medium of rat-lung fragments maintained in rotating tubes causes degranulation and a decrease in the number of the subpleural MCs. At the same time, it blocks the MC-increasing effect of histamine.

Calzavara et al. D10,222/60: The peritoneal-MC degranulation (associated with amitosis) that occurs following X-irradiation in the rat is inhibited by pretreatment with hyaluronic acid and an antihistaminic (Fargan) while cortisone has no such protective effect.

Jamieson & van den Brenk D8,004/61: Mepyramine i.p. does not cause disruption of the mesenteric MCs of the rat even in lethal doses.

Rowley D69,169/63: Combined treatment with antihistamine and anti-5-HT drugs prevents the vascular injury but not the MC damage caused in the anaphylactoid shock organs of the rat by dextrin or thorium dextrin i.v.

Dieudonné E24,128/64: In the rat, cyproheptadine prevents the topical soft-tissue calcification elicited by 48/80 or polymyxin, while it aggravates that induced by hexadimethrine, another MC-depletor.

ANTIMITOTICS

Cf. COLCHICINE AND PODOPHYLLIN, NITROGEN MUSTARDS, PYRILAMINE.

ANTIMONY DEXTRAN

Selye et al. E24,102/64: In rats calciphylactically sensitized with parathyroid extract, subsequent injection of antimony dextran produces calcification in the uterus and skeletal muscles. Since antimony dextran is a MC-discharger, it is probable that the MCs participate in this response.

ARSENIC

Fahr D29,298/05: Upon i.p. injection of arsenic (Fowler's solution), the peritoneal MCs of the rat migrate into the mesentery and omentum as a consequence of negative chemotaxis. Local MC degeneration in the peritoneum has not been observed.

ASBESTOS

Räsänen D33,739/62; D33,740/62: An asbestos suspension i.p. causes peritonitis with degranulation of the gastric MCs, presumably as a consequence of systemic stress.

ATROPINE

Niccoli-Vallesi D31,597/56-57: Atropine decreases the number of MCs in the submaxillary gland of the rat, presumably in relation to an inhibition of salivary secretion.

AUREOMYCIN

Norton & de Beer D30,591/55: Aureomycin is less active than 48/80 in causing degranulation of mesenteric rat MCs in vitro.

BACITRACIN

Norton & de Beer D30,591/55: Topical application of bacitracin to the mesentery of the rat failed to cause MC-degranulation.

BACTERIA, BACTERIAL TOXINS

Cf. also INVERTEBRATES, *p.* 196, PHLOGOGENS, *p.* 204, ALLERGY, *p.* 225.

Fahr D29,298/05: After i.p. injection of bacilli from a gangrenous spleen, the peritoneal MCs disappeared.

Gastreich B80,067/24: Various bacterial toxins s.c. produce a local MC increase both in unpretreated and in immunized mice.

Olsen & Smith D39,507/49: Injection of pneumococci into the popliteal lymph node of the rat causes a topical discharge of MCs.

Stuart D2,340/51: Lipopolysaccharides i.p. cause "changes" (not characterized) in the peritoneal MCs of the mouse.

Schoch & Glick D26,848/53: Pyromen causes no consistent change in the cutaneous MCs of the rat.

Ito E57,790/56-57: Following i.p. inoculation with staphylococci, the MCs in the popliteal lymph node of the rat disintegrate.

Villavicencio & de Takats C56,397/58: Pyromen causes intense degranulation of the mesenteric MCs in the rat.

Asboe-Hansen & Glick C56,235/58: *E. coli* endotoxin does not appear to affect rat MCs in vitro.

Habermann D27,439/59: Paper on hemolytic substances from *Clostridium welchii.* In the discussion, Uvnäs points out that all hemolytic substances are MC-dischargers. It is presumably because of this hemolytic potency that various compounds of *Clostridium welchii* cause MC degranulation.

Sheldon & Bauer C96,633/60: In alloxan-diabetic rats, unlike in normal controls, *Rhizopus oryzae* s.c. does not produce a local MC discharge. At the same time the usual inflammatory response is markedly delayed and decreased, but the infection progresses with unusual rapidity and intensity. "A severe metabolic disorder such as acute alloxan diabetes with acidosis, inhibits the normal function of the tissue mast cells, delays and decreases inflammation, and in this manner contributes to the greatly increased susceptibility of the host to infection."

Glick & Pothapragada D2,215/61: *E. coli* endotoxin s.c. increases the succinic dehydrogenase activity of rat peritoneal MCs.

Speirs et al. D63,716/61: The peritoneal MCs of mice, given diphtheria toxoid s.c., increase in number and some of them take up tritiated thymidine. "Only a small proportion of the cells originate by division of cells suspended in the inflammatory exudate."

Goldie et al. D22,813/62: *B. coli* i.p. causes disappearence of the peritoneal MCs in the mouse, with recovery after the infection is overcome.

Keller D58,041/62: "α- and d-toxin from *Clostridium perfringens* liberate histamine from normal isolated peritoneal rat mast cells . . . It is possible by means of starch gel electrophoresis to separate chymotrypsin from the enzyme responsible for mast cell disruption."

Gustafsson & Cronberg D58,841/62: "Mast cells occurred in the same numbers in the mesentery and peritoneal fluid of germfree and non-germfree rats . . . These results do not seem to be consistent with the concept that these cells have primarily a defensive function although such a possibility is not necessarily excluded by the present work."

Gustafson & Cronberg D61,874/63: Topical treatment with bacterial endotoxins causes little, if any, MC degranulation in the peritoneum of the rat and hamster, or in the cheek pouch of the hamster.

Higginbotham D58,297/63: Cells very similar to MCs ("quasi-mast cells") are produced by the addition of heparin to fibroblast in tissue culture, the virus-induced myxoma of the rabbit, and chondroitin sulfate-B i.v. in the mouse.

BENADRYL

Goldie et al. D22,813/62: Benadryl i.p. causes disappearance of the peritoneal MCs in the mouse.

BENZENE

Orr D27,606/38: After repeated skin painting with various carcinogens dissolved in benzene, there develops topical mastocytosis in the mouse. However, when benzene alone is used "mast cells are numerically increased, almost to as great an extent as with the carcinogens."

Larsson & Sylvén D31,567/47; *Sylvén & Larsson* D26,612/48: Topical application of benzene to the shaved skin of the mouse causes intense local degranulation of MCs.

BLOOD CLOTS

Baeckeland D27,744/50; D27,745/50: Subcutaneous implantation of blood clots or fibrin causes a local MC accumulation in the guinea-pig.

Hissard et al. B92,293/53: Implantation of a bovine blood clot between the two layers of the cutaneous muscle of the rat produces a considerable local accumulation of MCs; this is evident within 1 hour and reaches a maximum on the 3rd day. The phenomenon is thought to be related to the lysis of the clot by the heparin of MCs. The number of MCs also rises in the portal spaces, in the lungs, the capsules of lymph nodes and, to a lesser extent, throughout the entire connective tissue.

CANTHARIDIN

Raab D64,083/63: Cantharidin application to the skin of a guinea-pig causes vesicle formation with disappearance of MCs. However, if the MCs are previously destroyed by 48/80, the cantharidin vesicles develop nevertheless. Apparently, the MCs are not causally related to the response; their degranulation appears to be merely the consequence of local edema.

CARBON TETRACHLORIDE

Piccinelli C28,175/56: Inhalation of $CC1_4$ causes MC degranulation, followed by a secondary increase in the MC population of the rat.

Lacaz et al. C33,366/57: Chronic hepatitis and hepatic cirrhosis produced by $CC1_4$ in the rat are accompanied by an initial local mastocytosis, eventually developing towards pronounced sclerosis with total disappearance of the MCs. The histamine and heparin content runs roughly parallel to the MC count of the liver.

CARBOXYMETHYLCELLULOSE

Romani B90,840/53: In rats given large doses of cortisone in carboxymethylcellulose as a suspending medium (route of administration not mentioned), a great increase in the number of MCs was noted in the skin, lymph nodes, spleen, and thymus. [It is very probable, however, that many of these cells were histiocytes with metachromatic carboxymethylcellulose granules (*H.S.*).]

Selye C8,400/55: Chronic treatment with carboxymethylcellulose s.c. results in the development of numerous MC-like cells in the adrenal medulla, which stain metachromatically with Unna's mixture and toluidine blue. However, the granules are somewhat larger and less intensely staining than those of true MCs. [It is possible that true MCs, like these "pseudomastocytes" may develop by the phagocytosis of metachromatically-staining material (*H.S.*).]

Jasmin & Bois D63,182/61: Various preparations of carboxymethylcellulose were injected into rats and their distribution followed histochemically. "The localization of each CMC preparation varies according to the route of administration and the size of the particles." [The intercellular granules thus obtained stain with cresyl violet, toluidine blue, aldehyde fuchsin, alcian blue, and Hale's stain, but no mention is made of any resemblance to MCs or to our findings along these lines, although CMC granule-containing cells are described even in the adrenal medulla where we had found them (*H.S.*).]

Burton D58,284/63: The ingestion of CMC by rat peritoneal MCs can be followed cinematographically in vitro.

Selye et al. E24,139/64: In rats sensitized for mastocalciphylaxis by pretreatment with DHT and subsequent $FeC1_3$ i.v., carboxymethylcellulose s.c. produces local calcification at the site of MC-discharge.

CARCINOGENS

Reviews: *Baglioni* C16,539/54; *Fulton et al.* C35,831/57; *Riley* C70,315/59, *pp. 22, 33, 152*; *Kelsall & Crabb* D26,076/59, *pp. 79, 80*; *Simpson et al.* E21,127/62; *Simpson* D58,271/63

Tar

Dreifuss & Bloch D27,078/22: Intense MC proliferation in the skin of rats painted with tar products.

Bierich D27,096/22: Topical application of tar to the skin of the mouse causes considerable increases in the local MC population.

Borrel et al. D26,809/23: In the initial stages of tar-cancer formation, the skin of the mouse is heavily infiltrated with MCs, which invade the malpighian layer of the epidermis.

Peyron D26,801/23: Following local application of tar to the skin of the mouse, there is a pronounced MC proliferation in the dermis.

Schreus D39,778/23: Tar painting resulted in the production of a cutaneous mastocytoma in the mouse. The surrounding connective-tissue cells contained a Prussian-blue positive iron pigment.

Lipschütz D28,696/23–24: Chronic tar painting of the skin often leads to local mastocytosis combined with melanosis or even to mastocytoma and melanoma formation in the mouse.

Franco & Affonso D26,878/24: Repeated painting of the skin with tar causes topical MC accumulations in the mouse. In the ear, well-circumscribed nodules consisting exclusively of MCs, have sometimes been produced in this manner but mastocytosis occurs wherever the tar is applied to the skin surface. In the stroma of the resulting cutaneous tumors, MCs were less numerous and none were found in pulmonary metastases or in the bone marrow.

Franco & Affonso D39,765/26: The production of cutaneous cancers in the mouse by tar painting is accompanied by local mastocytosis and an interstitial chronic myocarditis.

Woglom D26,714/26: Following application of carcinogenic tar preparations to the skin of the mouse, the local MC population increases considerably before the tumors develop.

Fabris D39,684/27: In rats exposed to tar dust, multiple subcutaneous MC nodules appear which are considered to be mastocytomas.

Ulesco-Stroganowa D28,927/27: During carcinogenesis induced by tar painting of the mouse skin, the MC population in the underlying connective tissue increases.

Twort & Twort D26,712/30: Topical mastocytosis is common in the skin of mice where carcinogenic tar compounds are applied. In a few animals, the proliferation of these MCs was so excessive that an infiltration of internal organs eventually caused death.

de Viñals D13,202/31: In the mouse, painting of the skin with tar induces within 8–10 days alopecia, dyskeratosis, and a remarkable local accumulation of MCs. However, when evident neoplasia begins, the MCs disappear at the point of malignant transformation. Hence, the local proliferation of MCs in tar-painted areas is considered a consequence of the inflammatory reaction and not of the "stroma reaction" to the cancer itself.

Guldberg D28,471/31: MCs are plentiful in the corium of mice whose skin was painted with tar for the induction of cancers.

Bogowski D39,513/61: Painting of the skin with tar products induces local proliferation of MCs in the mouse. In about 1 per cent of the animals these accumulations are considered to be true mastocytomas.

Benzanthracene

Olsen & Smith D39,507/49: Injection of dibenzanthracene into the popliteal lymph node of the rat causes a topical discharge of MCs.

Asboe-Hansen B85,960/53: Cutaneous papillomas induced in mice by a single painting with 9,10-dimethyl-1,2-benzanthracene are very rich in MCs. The latter actively take up intraperitoneally injected S^{35}.

Engelbreth-Holm & Asboe-Hansen D27,522/23: Painting of the skin with 9,10-dimethyl-1,2-benzanthracene causes local mastocytosis underneath the developing papillomas. Cortisone delays tumorigenesis and diminishes the number and granule content of the local MCs.

Asboe-Hansen B91,127/54: Following one painting with the carcinogenic hydrocarbon 9,10-dimethyl-1,2-benzanthracene, the dermal MC count of the mouse increased in the treated area. These MCs exhibit a great affinity for S^{35} i.p., presumably because they are rich in sulfo-mucopolysaccharides.

Asboe-Hansen & Zachariae C10,677/55: The production of experimental papillomas in the skin of mice by 9,10-dimethyl-1,2-benzanthracene is inhibited by the systemic application of cortisone. At the same time, there is a diminution of the usually-intense local MC proliferation. It is postulated, therefore, that the MCs may play a part in providing the connective-tissue ground substance necessary to form the matrix of the neoplasms. [There is no proof, however, that the effects of cortisone upon the tumor are mediated through the MCs; the action upon the neoplasm and the MCs may be independent effects of the hormones (*H.S.*).]

Cass et al. C54,014/58: Painting of the skin with the carcinogen 9,10-dimethyl-1,2-benzanthracene resulted in a considerable increase of the local MC population within the

dermis of the mouse. This was accompanied by a substantial increase in the 5-HT-content of pre-cancerous skin.

Riley C69,692/58: Painting of the skin with 9,10-dimethyl-1,2-benzanthracene in acetone causes a marked increase in the MC population of the dermis in the mouse. If such skin is treated with formaldehyde, there appears a brown fluorescent pigment which, judged by direct bioassay and chromatography, has been identified as the beta-carboline of 5-HT.

Asboe-Hansen & Levi D78,274/59: In squamous-cell carcinomas induced by painting with dimethyl-benzanthracene, the MCs and also nongranulated metachromatic cells incorporated S^{35}.

Coupland & Riley D26,772/60: Following painting with 9,10-dimethyl-1,2-benzanthracene, the MC content of the skin rises considerably during the initial stages of carcinogenesis.

Jasmin & Bois D27,951/61: The stroma of the mammary tumors that develop in rats given dimethylbenzanthracene p.o. is particularly rich in MCs.

Fiore-Donati et al. D26,837/62: Following a single application of 9,10-dimethyl-1,2-benzanthracene to the skin of the mouse, it is possible to demonstrate on formalin-fixed skin specimens that, in the superficial parts of the dermis, very small, scarcely-granulated, and poorly-metachromatic MCs accumulate which give a golden-yellow fluorescence. The MCs in deeper areas and in adjacent skin are strongly metachromatic, of normal size, and not fluorescent. "From these findings it would appear that metachromasia and golden-yellow fluorescence are apparently non-related phenomena, depending on the presence within the mast cells of different substances. No conclusive evidence can be given on the exact nature of the fluorescing material. However, the close relationship of the increase of mast cell number with the intensity of fluorescence and the rise of 5-HT level supports the hypothesis that a high content of 5-HT accounts for the fluorescing properties of the reacting mast cells." It is noteworthy that a similar golden-yellow fluorescence after formol fixation is exhibited by enterochromaffin cells that physiologically contain large amounts of 5-HT.

Asboe-Hansen & Levi D39,755/62: The MCs in cutaneous carcinomas, induced by local painting with 9,10-dimethyl-1,2-benzanthracene in the mouse, undergo active mitosis as indicated by autoradiography after tritiated thymidine i.p.

Chieco-Bianchi et al. E22,251/63: Following painting with 9,10-dimethyl-1,2-benzanthracene a "remarkable accumulation of mast cells" appears beneath the hyperplastic epidermis. "However, when the sections were examined in ultra-violet light both the normal and reacting mast cells failed to exhibit any fluorescing property. Moreover, the determination of 5-HT skin level did not reveal any difference between control and treated animals, the values obtained being less than μgm/gm 0.08 in both groups. These findings indicate that no production of 5-HT occurs in normal skin mast cells of hamsters as well as in mast cells appearing in the dermis during carcinogenic treatment in these animals".

Stolk D39,819/63: After local application of 9,10-dimethyl-1,2-benzanthracene to the skin of the lizard *Lacerta agilis,* the developing papillomas contain numerous MCs many of which show golden-yellow fluorescence in ultraviolet light following formalin-vapor fixation.

Caschera et al. E21,879/63: In the mammary glands of female BALB/c/Cb/Se mice, oral administration of dimethylbenzanthracene and three other carcinogens (MC, DBA, and BP) induced a moderate increase in MC density. There was no relationship between the MC count and the appearance of precancerous lesions, a fact taken to show that the MCs have no defensive function against neoplastic invasion.

Benzpyrene

Baglioni D26,894/44: The connective-tissue stroma of 3,4-benzpyrene-induced sarcomas in the rat is particularly rich in MCs.

Koenig D65,252/55: In benzpyrene-induced sarcomas of the rat, MCs are particularly numerous at certain points where mitotic proliferation is lowest. It is concluded that the MCs may help in the defense against tumors by liberating antimitotic histamine compounds.

Csaba et al. D25,636/61: Intense topical MC-proliferation was noted in mice at sites where benzpyrene was applied to the skin or homologous Ehrlich ascites cells were intracutaneously injected. Less-pronounced MC proliferation occurred after similar implantation of Yoshida tumor suspensions but only the latter procedure was associated with plasma-cell accumulation. "It is suggested that mast cells, which may have various origins, inhibit

tumorous growth by neutralizing the polysaccharides necessary for development of tumors, in the course of their genesis, i.e., during the process in which other cell types are transformed into mast cells."

Landsberger E31,716/63: In benzpyrene-induced rat sarcomas, the growth rate is most inhibited whenever MCs are plentiful within the neoplasm. In mice, Ehrlich-ascites-tumor transplants show growth inhibition under the influence of heparin or heparinoids. From all this, it is concluded that the MCs possess some anti-tumoral defensive value.

Methylcholanthrene

Cramer D28,366/42: MCs frequently accumulate in the neighborhood of areas of massive epithelial hyperplasia following painting of the mouse skin with 20-methylcholanthrene.

Cramer & Simpson D26,710/44: Following repeated skin-painting with methylcholanthrene, MC-accumulations appear in the skin, simultaneously with the initial epidermal hyperplasia, much before actual carcinogenesis. In fully-developed carcinomas, this MC hyperplasia vanishes again. Particularly-pronounced MC-accumulations are seen in the skin of cancer-resistant mice. "These observations suggest that the mast cell reaction is associated with a defensive process against the development of skin cancer".

Holmgren & Wohlfart B41,911/47: In rats in which sarcomas were induced by methylcholanthrene, s.c., numerous MCs appear within the tumor tissue. These cells "develop locally in the connective tissue of the tumors, and this suggests that they take part in the reaction of the system against the tumor cells".

Sylvén & Larsson D26,612/48: A single application of 20-methylcholanthrene dissolved in benzene to the skin of the mouse causes topical MC-degranulation. However, the intensity of the reaction is not in excess of that obtainable by benzene itself. If the carcinogen is applied in a solvent such as acetone, which is inactive in itself, only insignificant MC degranulation results. "Thus, the mast cell depletion following the application of methylcholanthrene in benzene seems to be attributable to the benzene itself".

Balázs & Holmgren D30,635/49: "Sulfomucopolysaccharides (sodium heparinate and the sodium salt of agar acid) suppress the growth of cells from methyl cholanthrene tumors in the rat in vitro." In vivo, these same substances diminish mortality in mice inoculated with Ehrlich's carcinoma. The sulfomucopolysaccharides of MCs may enhance resistance to tumors.

Olsen & Smith D39,507/49: Injection of methylcholanthrene into the popliteal lymph node of the rat causes a topical discharge of MCs.

Riley & West D39,662/53: The histamine and MC content of mouse skin can be increased by painting with methylcholanthrene.

Montgomery et al. D65,675/56: Following cutaneous painting with methylcholanthrene, topical MC proliferation precedes the appearance of neoplasms. Daily injections of 48/80 i.p. accelerated the induction of neoplasia but had no demonstrable effect on the local MC-response. "These experiments suggest certain relationships between mast cells and carcinogenesis."

Caschera et al. E21,879/63: In the mammary glands of female BALB/c/Cb/Se mice, oral administration of methylcholanthrene and three other carcinogens (DMBA, DBA, and BP) induced a moderate increase in MC density. There was no relationship between the MC count and the appearance of precancerous lesions, a fact taken to show that the MCs have no defensive function against neoplastic invasion.

Carcinogens, various

Bierich D27,096/22: In the mouse, MCs are not particularly plentiful in the connective tissue around the sites of application of carcinogenic *arsenic* preparations or X-rays.

Orr D27,606/38: MC-proliferation in the skin of the mouse occurs after topical treatment with *various* carcinogens.

Sylvén & Larsson D26,612/48: A single application of *phenanthrene* to the skin of the mouse causes no local MC-degranulation.

Tusini C11,236/55; *Mosinger et al.* C97,657/60: In the rat and guinea-pig, MCs are plentiful in connective-tissue areas to which *various* carcinogens or transplantable tumors are applied.

CARCINOLYTICS

Oliverio & Kelly F2,926/64: A carcinolytic methyl-hydrazine derivative increases the survival of mice bearing an MC tumor.

CHLORPROMAZINE

LeBlanc C55,959/58: Chlorpromazine i.p. causes a considerable decrease in the MC count of the rat mesentery.

LeBlanc D39,725/59: Chlorpromazine i.p. causes disruption of the peritoneal MCs and hypothermia in the rat. Both these effects are prevented by KCN. The experiments suggest "a possible relationship between mast cell disruption and hypothermia caused by chlorpromazine."

Jamieson & van den Brenk D8,004/61: Chlorpromazine and various other phenothiazines i.p. cause intense disruption of the mesenteric MCs in the rat.

CHOLESTEROL

Baratta et al. G1,475/53: In rats kept on a high-cholesterol diet, the peritoneal MCs show a pronounced initial rise during the first week followed by a drop below control values after 15–65 days. It is suggested that the initial rise in MC count reflects an increased demand for heparin to metabolize the excess cholesterol, while the secondary decrease indicates an exhaustion of the heparin-forming mechanism.

Douglas et al. E42,119/64: In rats kept for three months on a high-cholesterol diet, the cutaneous MCs are reduced in number, often deformed in shape, and degranulated. At the same time, the mucoprotein content of the aorta rises while its content in protein-bound hexose and hexosamine diminishes and the sialic-acid concentration remains unchanged.

CHONDROITIN SULFATE

Higginbotham D58,297/63: Cells very similar to MCs ("quasimastcells") are produced by chondroitin sulfate B i.v. in the mouse.

CHROMIUM

Selye et al. E24,102/64: In rats calciphylactically sensitized with parathyroid extract or DHT, the subsequent injection of chromium dextran causes calcification in the spleen, skin, lung, and adrenal medulla. Chromium dextran is a MC-discharger but it remains questionable whether the MCs participate in all these responses.

COLCHICINE AND PODOPHYLLIN

Baglioni C16,539/54, *p. 209*: Discussion.

Kelényi C10,851/54: Colchicine (like nitrogen mustard) causes granule clumping and degranulation in the peritoneal and cutaneous MCs of the rat.

Padawer D64,997/54: The peritoneal MCs of the rat show marked deformation under the influence of colchicine, but mitotic figures were not observed.

Padawer & Gordon D26,447/55: Within 1 hour after a single i.p. injection of colchicine, severe fragmentation without nuclear damage develops in the peritoneal, and to a lesser extent in the mesenteric, MCs of the rat.

Padawer & Gordon D63,174/55: Methanol-fixed and unfixed air-dried smears of rat or hamster peritoneal fluid reacted to the in-vitro addition of 48/80 by losing their metachromasia, suggesting "that 48/80 influences mast cell staining in the dead as well as living state and acts directly". D-tubocurarine and colchicine did not affect metachromasia under these conditions, whereas protamine sulfate suppressed it completely.

Padawer et al. D26,480/56: After colchicine s.c., the peritoneal MCs undergo a peculiar change characterized by a very eccentric position of the nucleus, constrictions in the cytoplasm, and formation of pseudopod-like extensions. When the peritoneal MCs of the colchicine-treated rats are placed under high hydrostatic pressure in a chamber they round up, "suggesting that the abnormal morphology is maintained by a strongly gelated cytoplasm. Induction of localized foci of gelation by colchicine is postulated to explain the formation of polymorphic mast elements."

Padawer & Gordon D33,681/56: "Administration of colchicine to rats results in characteristic damage to the mast cells of peritoneal fluid (*Padawer and Gordon* D26,447/55).

These studies have now been extended with colchicine and another mitotic poison, podophyllotoxin, in both rats and hamsters. The effects obtained on the mast cells of rat peritoneal fluid at 1–3 hours following subcutaneous injections of colchicine (0.1 mg/100 gm of body weight) or podophyllotoxin (1 mg/100 gm of body weight) are reproduced by the addition of these drugs to peritoneal fluid in vitro, suggesting that colchicine and podophyllotoxin may act directly. Hamsters, known to be more tolerant to colchicine than rats, also possess more resistant peritoneal-fluid mast cells; dosages of colchicine corresponding to 10 mg/100 gm of body weight are required to induce damage in these elements within three hours. Podophyllotoxin produces changes in the peritoneal fluid mast cells of both rats and hamsters identical with those following colchicine treatment, but these effects are obtained with similar dose levels in both species (1 mg/100 gm of body weight)."

Padawer D30,194/57: Detailed review on the changes in shape of rat peritoneal MCs induced by various antimitotic agents such as colchicine and podophyllotoxin.

Padawer D33,680/59: Following colchicine s.c. the peritoneal MCs of the rat show displacement of the nucleus to the periphery and elongation of the cytoplasm. "If the degree to which affected cells are deformed is disregarded, a straight line plot obtains when the percent affected cells is graphed versus the logarithm of colchicine dosage. Such data suggest that nuclear displacement and cytoplasmic polymorphism are expressions of a single process."

Padawer D26,620/60; D26,320/61: Rats treated with a single, near lethal dose of colchicine exhibit changes in their peritoneal MCs which are highly specific for this compound and its closest derivatives. The MCs become nodular, their cytoplasm is segmented, and the nucleus invariably located at one pole. This deformation must be differentiated from that induced by hypophysectomy or old age (elongation without segmentation of cytoplasm and slightly eccentric location of nucleus). It is totally different from the degranulation and vacuolation induced by histamine-liberators. Not only MCs but other peritoneal cells react in the same manner to colchicine. Numerous metabolic poisons, MC metabolites, and alkaloids failed to elicit this typical response. Indeed, even some close derivatives of colchicine, such as tropolone and its non-colchicine derivatives hinokitiol, purpurogallin, and stipitatic acid are ineffective. Mitotic figures in MCs are never observed after colchicine treatment.

Padawer D58,275/63: Discussion.

Csaba et al. E36,438/63: Colchicine causes an increase in the MC population of the rat thymus which is ascribed to its stressor effect.

COLLOIDS

Piccaluga D28,533/56: Exposure of heparin or of alcohol-fixed rat peritoneal MC-smears to lysozyme causes a marked diminution of their metachromasia. Ovalbumen and ovomucoid are much less active or inactive. Apparently, such basic colloidal proteins as lysozyme interfere with metachromasia and may thus give the impression of MC disappearance.

Macaluso & Salerno D26,434/60: Following pretreatment in vitro with various basic colloids (e.g., protamine, lysozyme, thymus histone, hemoglobin), rat MCs lose their stainability with toluidine blue. This inhibition can in turn be blocked by subsequent treatment with acid colloids (e.g., heparin, dextran, chondroitin sulfuric acid, ovalbumen, gelatin). Perhaps even in vivo, the stainability of MCs and, hence, their apparent number, depends upon the balance between acid and basic colloids in the surrounding tissue fluid.

COMPOUND 48/80

Review: *Riley* C70,315/59

In vitro

Grossberg & Garcia-Arocha D28,699/54: When exposed to 48/80, the large granule fraction of dog liver homogenates releases its histamine.

Norton & de Beer C5,279/55: 48/80 (like hypotonic solutions) causes disruption of rat mesenteric MCs in vitro.

Junqueira & Beiguelman D26,706/55: Low concentrations of 48/80 suffice to produce vigorous MC degranulation in the rat mesentery in vitro. Cold, acid *p*H, and various metabolic inhibitors prevent this effect. "Glutathione reverts the action of the so-called sulfhydrile blocking substances (iodoacetate, o-iodosobenzoate and p-Cl-Hg-benzoate) while ATP does not revert the action of 2,4-dinitrophenol, arsenite and urethane. It is suggested that metabolic

phenomena occurring in mast cells are of importance in their responses to the action of Compound 48/80".

Padawer & Gordon D63,174/55: Methanol-fixed and unfixed air-dried smears of rat or hamster peritoneal fluid, reacted to the in vitro addition of 48/80 by losing their metachromasia, suggesting "that 48/80 influences mast cell staining in the dead as well as living state and acts directly".

Högberg & Uvnäs C47,831/57: Among numerous enzymes studied, only lecithinase-A had the ability of disrupting rat peritoneal MCs in vitro. Trypsin, fibrinolysin, ribonuclease, hyaluronidase, and other enzymes were inactive. Disruption by lecithinase A was inhibited by the same agents which also inhibit the action of 48/80, e.g.: cold, acetic anhydride, 1,3-diphosphoimidazole, a polyvalent immune serum against snake venom, and specific immune serums from rabbits against the lecithinase A of bee venom. "The observations are considered to support the hypothesis that 48/80 acts by activating a lytic enzyme attached to the MC-membrane. The activity of the enzyme is normally blocked by an inhibitor. When this inhibitor is removed, as by liberators such as 48/80, the enzyme becomes active and the membrane structures are attacked".

Asboe-Hansen & Glick C56,235/58: Rat MCs suspended in vitro show loss of metachromasia and granule clumping upon treatment with 48/80, but no degranulation or disintegration.

Lagunoff & Benditt D7,116/59: 48/80 degranulates rat peritoneal MCs (isolated on a Millipore filter) in vitro while dextran and ovomucoid do not.

Archer D26,626/59; C78,034/59: Exposure of fresh rat peritoneal MCs to minute doses of 48/80 causes liberation of their granules and histamine; however, the cells rapidly become refractory to this effect.

Lagunoff & Benditt D7,116/59; D26,708/60: 48/80 or polymyxin, unlike dextran or ovomucoid, release the granules and histamine from rat peritoneal MCs isolated on a Millipore filter. Compound 48/80 and polymyxin are assumed to act directly on MCs while dextran and ovomucoid might act indirectly "at an unidentified site in the tissues to release a compound of the direct-acting type." [Dextran and ovomucoid produce the selectively "acral type" of anaphylactoid reaction in vivo, while 48/80 and polymyxin cause much more generalized cutaneous responses so that these agents differ in vivo also (*H.S.*).]

Boréus D65,098/60: In vitro studies on the mesenteric MCs have suggested that 48/80 and lecithinase A cause disruption through an enzymatic mechanism. In the guinea-pig 48/80 does not affect the MCs and in this species their disruption under other conditions is non-enzymatic.

Högberg & Uvnäs D26,422/60: 48/80 discharges rat peritoneal MCs in vitro.

Yamura & Watanabe D58,429/61: 48/80 discharges the histamine and the specific granules from rat peritoneal MCs in vitro.

Keller & Oppliger D27,077/61: 48/80 causes immediate degranulation of human bronchial MCs in vitro.

Van Arsdel & Bray D26,617/61: The discharge of histamine by 48/80 from the isolated rat peritoneal MCs is blocked most effectively by cyanide but uranyl nitrate, 2,4-dinitrophenol, o-iodosobenzoate, heparin, and arsenite are also efficacious. On the other hand, EDTA, iodoacetate, fluoride, urethane, salicylate, amidopyrine, phenol, and procaine, or withdrawal of calcium from the medium, are ineffective in this respect. The blockage by the otherwise effective inhibitors can be overcome by increasing the concentration of 48/80. None of the inhibitors are effective if introduced into the MC suspension 30 seconds after the 48/80. "The effects of the various inhibitors had little relationship to their known effects on enzyme systems, and our data provide little support for enzyme mediation of 48/80 activity".

Uvnäs & Thon D26,478/61: The 48/80-induced release of granules and histamine from isolated rat peritoneal MCs diminishes with falling incubation temperature and occurs best at the *p*H of 6.5–7.0. The release is not dependent upon the presence of calcium and magnesium ions, while in the mesentery in situ 48/80 fails to cause a discharge in the absence of calcium. Various enzyme-inhibitors and metabolic-inhibitors prevent the action of 48/80 upon the isolated rat peritoneal MCs. Rather low concentrations of both ninhydrin (thought to block NH_2-groups) and allicin (thought to block SH-groups) abolish histamine release from the isolated peritoneal MCs; and glutathione, in turn, abolishes the inhibitory action of allicin. The discharge depends upon the presence of oxygen and hence, presumably upon an energy-requiring metabolic process. The rapid release of granules and histamine from isolated rat peritoneal MCs by 48/80 contrasts sharply with the slow release that occurs when isolated

granules are exposed to 48/80. Possibly some extra-granular cell constituents facilitate release.

Bray & Van Arsdel D26,900/61: Rat peritoneal MCs were exposed in vitro to various histamine liberators (48/80, 1935L, protamine, stilbamidine, octylamine, parachlormercuribenzoate, formaldehyde, 5-hydroxytryptamine, phenol, tannic acid, ammonium oxalate, ethanol, methanol). Of these 48/80 was the most potent; it released histamine at concentrations as low as 2×10^{-7} M. "Qualitative variations in the response of these mast cells to different releasers suggested that mechanisms of histamine release vary considerably among the chemical agents now being investigated".

Archer D26,441/61: Though 48/80 disrupts rat peritoneal MCs in vitro, it leaves the granules themselves intact.

Higginbotham D58,297/63: When isolated rat peritoneal MC granules are exposed in vitro to 48/80, the concentration of the histamine-discharger in the suspension medium decreases one-hundred fold and a clear center appears in each of the MC granules. It is assumed that "the heparin inside mast cell granules has the ability to take up and neutralize basic histamine releasing agents".

Mode of administration, selective regional actions, species-specific responses

Devitt & Samuels D26,863/53; *Devitt et al.* B96,691/54: A single s.c. dose of 2.5 mg of 48/80 caused no change in the peritoneal, cardiac, or skeletal muscle MCs of the rat.

Arvy & Quivy D27,966/55: 48/80 i.v. causes a sharp drop in the lingual MCs of the dog.

Arvy D65,694/55; C41,778/56: In *Rana esculenta,* injection of 48/80 into the base of the tongue causes local MC degranulation within 30 minutes. No free granules are seen, only diffuse metachromasia. In the immediate vicinity of nerves the MCs are least affected.

Arvy & Quivy D99,937/55: Both 48/80 and peptone shock are associated with a decrease in the number of lingual MCs in the dog. Unlike peptone, 48/80 causes only a slight decrease in blood coagulability.

Veil E24,154/56: 48/80 causes degranulation of the MCs in the scales of the carp. At the same time, the fish become sick and eventually die. This toxic effect cannot be ascribed to histamine, since fish are extremely resistant to histamine.

Hunt & Hunt D27,054/56: One mg of 48/80 s.c. produces local MC-degranulation within 60 minutes but does not affect MCs at a distance from the injection site. The same amount, injected i.p., causes MC degranulation not only in the peritoneum, omentum, and mesentery, but also in the subcutaneous tissue. Small (young?) MCs in the intestinal wall are especially resistant.

Keller D26,882/56: 20 μg. of 48/80 i.p. suffices to discharge some of the peritoneal MCs of the rat; 50 μg. discharges most of them.

Asboe-Hansen & Wegelius C29,324/56: 48/80 i.p., i.m., or i.v. causes degranulation and granule clumping in the MCs of the hamster's cheek pouch.

Keller C34,639/57: 48/80 i.p. discharges the peritoneal MCs of the rat.

Veil E62,531/57: The MCs in the scales of various fish (carp, roach) show degranulation following treatment with 48/80 and under the influence of anaphylaxis.

Bloom et al. C34,040/57: Electron and phase-contrast microscopy revealed that 48/80 i.v. in the rat (like stilbamidine, protamine, or toluidine blue i.p. in the rat and hamster) increases the formation of granule-containing vacuoles in the peritoneal MCs, at the same time causing disintegration and release of granules.

Smith & Lewis D63,176/58: Following local treatment with 48/80, the MCs of the hamster cheek pouch or peritoneum discharge their granules which are subsequently phagocytosed by fibroblasts, macrophages, and leukocytes.

Smith D63,185/58: 48/80 directly applied to the transilluminated rat mesentery causes MC discharge which can be followed cinephotomicrographically.

Arvy D65,087/58: In the rat, 48/80 i.p. causes a diminution of the MCs in most tissues, with a simultaneous augmentation of their number in the lymph nodes. This response is thought to be related to an increased lymph flow.

Welsh & Geer D39,505/59: Following 48/80 i.p., the granules discharged from the peritoneal MCs of the rat are taken up by eosinophilic leukocytes (as judged by electron microscopy). This phenomenon may play a role in histamine release and allergic inflammation. "The phagocytosis of mast cell granules may be the basis for the 'basophilic bodies' seen in circulating eosinophils in human subjects".

Salvato D10,341/61; D27,641/62; G12,997/63: 48/80 i.m. or i.v. causes degranulation of the peribronchial MCs both in asthmatic and in nonasthmatic patients.

Raab D39,956/62: 48/80, i.p. or topical, causes degranulation of the cutaneous MCs in the guinea-pig.

Arvy E25,129/62: Following treatment with 48/80, the disappearance of MCs in the connective tissue is associated with a marked increase in MC density within the lymph nodes. This is ascribed to a migration by way of the dilated lymphatics.

Kim D58,632/63: 48/80 i.v. causes degranulation of the uveal MCs in the rat but not in the guinea-pig.

Sicuteri et al. E21,615/63: Following injection of 48/80 into the brachial artery of man, the cutaneous MCs (obtained by biopsy) in the forearm show degranulation with the release of histamine and heparin; there is vasodilatation, edema, and pruritus in the affected skin region. Similar effects are seen in the scalp skin after intracarotid injection of the 48/80.

Bhatt et al. F8,369/64: 48/80 i.p. causes wide-spread MC degranulation in the mouse and rat.

Anaphylactoid inflammation

Paton & Schachter D30,372/51: The anaphylactoid facial swelling and itchiness, produced by 48/80 in the unanesthetized dog, is almost completely eliminated by *mepyramine,* but the stimulation of gastric secretion is not inhibited. Apparently, this antihistaminic has no effect upon the actual release of histamine but only prevents its peripheral effects in certain regions. [Although no mention is made of the MCs, the possibility should be kept in mind that the antihistaminic might act only by preventing MC discharge, with the associated local histamine release, in certain regions. Blood-histamine determinations were not performed; the intensity of the histamine discharge into the blood was gauged merely by gastric secretion (*H.S.*).]

Riley & West C14,427/55: An anaphylactoid inflammation develops in rats following a single injection of 48/80 i.p. The peritoneal MCs that come into direct contact with the histamine liberator disintegrate completely; they are apparently irreversibly damaged. The local fibroblasts swell and show increased basophilia. The MCs remote from the 48/80 application (e.g., in the skin and ears) also show granule discharge, but this is presumably a reversible change since the cells themselves are not permanently damaged. Compound 48/80 injected into the first branch of one external carotid artery causes an anaphylactoid response, with discharge of MC granules and histamine only in the ear of the same side.

Jasmin C24,745/56: The anaphylactoid inflammation produced by 48/80 s.c. in the rat is accompanied by a local degranulation of the MCs in the shock organs.

Rowley & Benditt C15,372/56: Injection of 48/80 into the rat's paw causes intense local anaphylactoid edema with MC discharge.

Parratt & West C37,858/57: Repeated injections of 48/80 i.p. cause widespread MC degranulation in the skin, feet, and ears of the rat, with a correspondingly severe depletion of both 5-HT and histamine in these areas. Yet, no release of either amine occurs from the spleen, lung, liver, or brain, where the MCs are scanty. An anaphylactoid inflammation develops at the beginning of treatment, but decreases in intensity following repeated injections, as the MC and histamine content of the skin drops.

Regeneration of mast cells, adaptation to 48/80

Fawcett D26,781/55: Following 48/80 i.p., the peritoneal MCs of the rat discharge their granules but are not irreversibly destroyed as they are by distilled water. With moderate doses of 48/80, some MCs succumb but others survive and regeneration occurs by cell division as well as by differentiation of new MCs from fibroblasts.

Riley & West C14,427/55: After a single injection of 48/80 i.p., recovery of MCs is far advanced by the 8th day and complete by the 15th day. Histamine depletion from all affected areas parallels the MC degranulation. In the case of daily i.p. injections with gradually-increasing doses of 48/80 (up to 1 mg and then continuing at this dose level for 31 days), the picture is essentially the same but degranulation is much more pronounced: perivascular MCs are no longer seen but debris-laden histiocytes appear in the mesentery. MCs also progressively disappear from the ears, with the exception of the nerve sheaths. In the subcutis, the initial disappearance of MCs is followed by the gradual development of numerous minute

MCs in the adventitia of small blood vessels until, by the end of a month, these vessels are surrounded by several layers of small darkly-staining MCs. Again, the fall in tissue-histamine parallels the intensity of the MC-degranulation.

Bhattacharya & Lewis C27,232/56: 48/80 i.p. causes much more generalized MC degranulation in the mesentery than in the subcutis of the rat. However, 48/80 i.p. on each of three consecutive days (in doses increased from 100μg by 50μg with each injection) caused almost total degranulation of the subcutaneous MCs also. If 48/80 i.p. is continued for ten days, increasing the dose given per injection up to 500μg, no further MC damage occurs. MCs reappear only several days after cessation of the injections.

Mergenthaler & Paff D27,407/56: Following depletion of rat peritoneal MCs by 48/80, their number in the peritoneal fluid begins to increase noticeably after 9 days, but anaphylactoid inflammation returns after 28 days.

Arvy D27,873/56: In rats (135–190g) treated daily with 250μg of 48/80 i.p., the MCs of the anaphylactoid shock organs (lips, tongue, and scrotum) disappear or are severely altered within 4 days. Numerous more-or-less damaged MCs persist in the sinusoids of lymph nodes. In the thyroid gland, parathyroid gland, and extremities they are but slightly modified; in the perineurium they remain intact. By the 8th day, MCs reappear in certain territories, particularly in the tongue, but they are small, frequently appear in pairs or chains, and resemble embryonic MCs. At that time, the MCs in the lymph nodes are partly of the old and partly of the new generation. Then regeneration begins and, one week after cessation of a course of eight injections, the MC population of the tissues returns to normal although the cells are still small. Regeneration occurs both by division and by transformation of fibroblasts.

Hunt & Hunt D63,100/57: Mitoses are seen in adult MCs of the rat mesentery after moderate doses of 48/80 i.p. After larger doses, which cause disintegration of mesenteric MCs, mitoses are found in the subcutaneous MCs. Replacement of the disintegrated MCs appears to occur from lymphocytes and undifferentiated mesenchymal cells.

Gustafsson & Cronberg D27,895/57: 48/80 i.p. causes MC degranulation in the peritoneum and mesentery of the rat. The ejected granules show swelling and pink metachromasia. Regeneration begins after a few hours but is still incomplete after 28 days. The ejected granules are taken up by phagocytes.

Klaus & Winkelmann C80,962/59: Repeated injections of 48/80 cause moderate degranulation and minimal losses in night-blue stainability of the cutaneous MCs in the rat.

Fernex G9,088/63: In rats chronically treated with 48/80, the dermal and peritoneal MCs tend to disappear but, if treatment is interrupted for three weeks, a reactive increase in MC-density occurs in the same locations.

Douglas et al. E42,119/64: Upon chronic treatment with 48/80, the cutaneous MCs of the rat are diminished in number to about one-sixth of the norm. They are often reduced in size, deformed in shape, and depleted of granules.

Histamine liberation

Fawcett D28,375/54: 48/80 i.p. releases both the granules and the histamine from the local MCs of the rat. However, if the MCs have been destroyed several days earlier by an i.p. injection of distilled water, 48/80 no longer causes histamine release. "These observations strongly support the thesis that mast cells are unusually rich in histamine which is released under experimental conditions which cause them to discharge granules."

Fawcett D26,771/54: Following i.p. injection of graded doses of 48/80, the peritoneal MCs of the rat discharge their granules and histamine into the surrounding fluid in dose-dependent amounts.

Riley & West D39,574/55: "The chronic administration of compound 48/80 to rats and mice results in a loss of tissue histamine and of mast cells of the ears and subcutaneous connective tissue. Whereas in the rat the disruptive action is maximal, it is never more than slight in the mouse. Since the maximal tolerated doses were used, it is concluded that histamine release in the mouse is only a small part of the action of compound 48/80."

Braun-Falco D26,884/55: 48/80 i.p. discharges the mesenteric MCs of the rat and increases the histamine content of the peritoneal fluid. Compound 48/80 s.c. also induces a local MC discharge.

Keller & Burkard C29,951/56: 48/80 i.p. degranulates the peritoneal MCs of the rat with a corresponding depletion of tissue histamine. If the injection is repeated after one week, the resulting histamine discharge is proportional to the number of MCs remaining in the peritoneum.

Mota et al. C31,032/56: Comparative determinations show a positive correlation between the MC count and histamine content in various tissues of the rat. However, the fundic region of the stomach and the duodenum contain much, and the ileum moderate amounts of histamine, although there are only very few MCs in these regions. Compound 48/80 greatly reduces the histamine content of tissues rich in MCs, but it does not reduce the histamine in the fundic region of the stomach, duodenum, ileum, or liver.

Mongar & Schild D27,601/56: Antigen (egg albumen) releases histamine only from intact MCs of sensitized guinea-pigs in vitro, but 48/80 releases it even from isolated MC granules.

Mota et al. D27,629/56: The guinea-pig intestine is unusually resistant to the MC-degranulating and histamine-depleting action of 48/80.

Nishiyama et al. D31,565/57: Comparative study on the regional histamine release induced by diverse histamine liberators leads to the conclusion that: "by compound 48/80, the rates were especially marked from the liver and muscle and only slight from the skin, while those by sinomenine, tween 20 and PVP were largest from the skin, followed by those from the liver and muscle, in that order. The rate of histamine release from the skin by PVP was characteristic in that it was far larger than that by other releasers." However, there appears to be no proportionality between regional histamine release and MC degranulation. "Therefore, difference in the site of histamine release can not be explained only by the affinity of certain substances to mast cells."

Smith C54,403/58: In the rat, 48/80 i.p. causes discharge of mesenteric MCs simultaneously with histamine release.

Jóhannesson & Norn E33,916/63: Upon exposure of rat peritoneal MCs in vitro, "morphine was found to be a 300–400 times weaker liberator of histamine than compound 48/80 or polymyxin B."

Heparin liberation

Mota et al. B85,350/53: 48/80 and stilbamidine degranulate rat peritoneal MCs in vivo and in vitro, without affecting blood-coagulation perhaps because they also have a protamine-like action and form insoluble complexes which remove heparin from the system.

Watson C59,777/58: MC-depletion by 48/80 does not sensitize rats to the production of atheroma or hyperlipemia by a high fat diet. "Within the limits of this experiment the tissue mast cell is considered not to have a direct action in preventing atherosclerosis in the rat".

Other biochemical changes

Ottoson et al. D31,592/58: Both by interference microscopy and X-ray absorption measurements, the *dry mass* of MCs from the peritoneal cavity of the rat was found to be approximately 2.0 g $\times$ 10^{-10}. "Compound 48/80 in vitro does not cause loss of dry mass from those mast cells which remain intact."

Eder & Schauer D33,687/61: Following 48/80 i.v., the mesenteric MCs of the rat discharge their granules; then *leucylaminopeptidase, ATP-ase,* and *alkalinephosphatase* are demonstrable in the extracellular granules approximately as long as they retain their toluidine-blue metachromatic-staining ability.

Glick & Pothapragada D2,215/61: 48/80 s.c. increases the *succinic dehydrogenase* activity of rat peritoneal MCs.

Parekh & Glick D27,898/62: 48/80 does not alter the *hexosamine* content of intact rat peritoneal MCs.

Roth et al. E34,000/63: Following treatment with S^{35}-sulfate, autoradiographs of the rat lung and skin show the incorporation of sulfate into MC granules. 48/80 causes discharge of the marked MC granules followed by an increased *incorporation of radioactive sulfate.*

Kwaan G17,226/64: Rat MC granules released by 48/80 in vitro or in vivo exhibit little *protease* or *plasminogen activator* activity as judged by histochemical means.

Compound 48/80 and antihistaminics

Norton & de Beer D30,591/55: The degranulation of rat peritoneal MCs normally produced by 48/80 is inhibited by cyclizine in vitro.

McGovern D28,556/56: Antazoline i.p. does not prevent MC disruption by 48/80 in the peritoneum of the rat. Apparently, this antihistaminic compound does not possess any antihistamine-liberator action.

Mota & Vugman D26,566/56: Lethal doses of 48/80 i.v. do not produce emphysema in the guinea-pig and death cannot be prevented by antihistaminics. Furthermore 48/80 i.p. fails to cause any changes in the MCs of the lung, skin, or mesentery; even topical application of 48/80 to the guinea-pig mesentery does not induce MC degranulation. "The effect of 48/80 on the guinea pig is thus not mediated through histamine liberation, and the mast cells and the tissue histamine in this species behave quite differently from those of the rat and dog, being very resistant to the action of compound 48/80."

Zeppa & Hemingway E39,862/63: The histamine release from isolated rat peritoneal MCs is inhibited by low concentrations of various antihistamine drugs such as cyproheptadine, methdilazine, SA–97, and promethazine. High concentrations of the same antihistaminics on the other hand augment the histamine release. It is "suggested that inhibition of histamine release rather than block of effect may be a more important function of these agents."

Salvato G12,997/63: As judged by histologic study of biopsy specimens, 48/80 causes MC degranulation in the bronchi of man. This effect is not prevented by the antihistaminic "Ilvin" (Merck), although the manifestations of histamine liberation are blocked.

Compound 48/80 + immunity or anaphylaxis

Mota & Vugman D27,087/56: In the guinea-pig, 48/80 produces a clinical picture similar to that of anaphylaxis elicited by the reinjection of antigen, but it does not appear to cause any change in the morphology or number of the pulmonary MCs. Apparently, the guinea-pig's MCs are much more resistant to 48/80 than those of the rat and several other species.

Raab D39,956/62: In guinea-pigs sensitized with dinitrochlorbenzol, the subsequent application of this allergen to the skin normally produces an eczema with proliferation of local MCs. In 48/80-pretreated guinea-pigs, this form of eczema can no longer be elicited.

Gözsy & Kátó D56,953/62: Rats sensitized with horse serum and pertussis vaccine were depleted of their histamine, 5-HT, and MC granules by 48/80. This pretreatment delayed, but did not prevent, the onset of fatal anaphylactic shock following challenge. Apparently "neither histamine nor 5-HT are the toxic factors of shock . . . it is the disbalance between histamine and catecholamines which is responsible for the profound alterations in the circulatory network and the hemodynamical changes thus leading to the lethal outcome."

Compound 48/80 + calciphylaxis

Selye et al. D40,219/63: Calcified skin plaques are produced if rats, pretreated with DHT p.o., are calciphylactically challenged through the infiltration of a subcutaneous tissue area with dilute solutions of ferric dextran. Compound 48/80 and other MC dischargers selectively inhibit this skin calcification at the point where they are applied within the challenged area.

Selye et al. D15,989/63: In rats sensitized for mastocalciphylaxis (by DHT p.o. and subsequently ferric dextran i.v.), polymyxin, 48/80, or stilbamidine s.c. produce topical calcinosis, presumably owing to the fixation of iron and then of calcium salts on the discharged MC granules. Thus, the MCs participate in pathologic calcification.

Gabbiani et al. D64,692/64: In rats calciphylactically sensitized with DHT, subsequent challenge with 48/80, dextran, dextrin or polymyxin induces a dermatosis characterized by widespread calcification of the most superficial layers of the dermis and epidermis. In the initial stages, calcification is limited to discharged MC granules.

Selye et al. E24,139/64: In rats sensitized for calciphylaxis by pretreatment with DHT, the topical calcinosis induced by $FeCl_3$ s.c. is enhanced by the admixture of an MC-discharger such as 48/80. In rats sensitized for mastocalciphylaxis by pretreatment with DHT and subsequently $FeCl_3$ i.v., 48/80 s.c. produces local calcification at the site of MC discharge.

Under similar conditions, systemic treatment with 48/80 induces the "cephalonuchal syndrome," characterized by massive MC discharge and subsequent calcification in the head and neck region.

Compound 48/80 + calcergy

Serafimov et al. E24,149/64: In rats prepared by a single i.v. injection of lead acetate, 48/80 (like dextran, dextrin, polymyxin, and viomycin) produces mastocalcergy in different parts of the body, depending upon the MC-discharger given and the route of its administration. "Presumably systemically administered histamine liberators can act selectively upon certain regions and thereby elicit *specific organotropic effects,* depending upon the agent used and the route of administration."

Selye et al. G11,121/64: In rats pretreated with lead acetate i.v., topical connective-tissue calcification is produced by minute doses of various MC components (histamine, 5-HT) or MC-dischargers (48/80, polymyxin) as a consequence of mastocalcergy. This response can be *inhibited by topical* pretreatment with any of the substances just mentioned.

Dieudonné E24,128/64: Cyproheptadine prevents the topical calcification normally produced by various MC-depletors such as 48/80, polymyxin, stilbamidine, or pentamidine in the rat. However, it actually aggravates the local calcification induced by hexadimethrine, another MC-depletor.

Selye and Tuchweber G11,117/65: In rats pretreated with lead acetate i.v., *topical* connective-tissue calcification is produced at sites where minute doses of various MC-dischargers (polymyxin, 48/80, viomycin, stilbamidine, trypsin) or MC products (5-HT, histamine) are injected s.c. Heparin and various other compounds tested were ineffective. Histochemical studies showed that polymyxin and 48/80 first produce MC discharge, followed by calcium incrustation of the metachromatic granules, while 5–HT and histamine cause no MC discharge at comparable dose levels, but produce a fine precipitate of calcium salts in and around the connective-tissue fibers at the injection sites.

Selye et al. G11,122/65: After the induction of calcergic reactivity by lead acetate i.v., *systemic* treatment with various MC-dischargers (e.g., 48/80, polymyxin, stillbamidine, dextran, dextrin) and MC products (5-HT, histamine) produce essentially distinct patterns of calcification in the rat. The preferential deposition of calcium in one or the other organ is ascribed to selective MC degranulation with consequent mastocalcergy induced by different compounds in different regions.

Selye et al. G11,118/65: In rats pretreated with lead acetate i.v., the topical connective-tissue calcification produced by minute doses of various MC-components (histamine, 5–HT) or MC-dischargers (48/80, polymyxin) can be *inhibited by systemic pretreatment* with large doses of any one among these compounds. Adrenaline, another biogenic amine, exerts a similar protective effect although it does not produce mastocalcergy at any dose level.

Compound 48/80 + other agents

Montgomery et al. D65,675/56: Following cutaneous painting with *methylcholanthrene,* topical MC proliferation precedes the appearance of neoplasms. Daily injections of 48/80 i.p. accelerated the induction of neoplasia but had no demonstrable effect on the local MC response. "These experiments suggest certain relationships between mast cells and carcinogenesis."

Högberg & Uvnäs D26,477/58: *Allicin* (an enzyme-inhibitor from garlic) prevents the degranulation of rat peritoneal MCs which is otherwise produced by 48/80, Ascaris extract, antigen-antibody reaction, or lecithinase A. Glutathione in excess reverses this degranulation blockade.

Cass et al. C54,014/58: 48/80 is less effective in discharging the granules and the histamine from the proliferating MCs in the bone marrow of rats fed a special *calcium-deficient diet,* than from the skin of the same animals.

Sheldon & Bauer C96,633/60: In rats in which the MCs are discharged by 48/80, infection by subsequent s.c. inoculation with *Rhizopus oryzae* is somewhat delayed and decreased in intensity. While the fungus growth was increased, the infection did not spread and the lesions were well localized. It was concluded that the MCs play an important role in inflammation and local resistance.

Fisher & Paar C94,668/60: In the rat, the production of an inflammatory granuloma by *carrageenin* s.c. was not influenced by the prior depletion of the MCs by 48/80.

Fisher & Hellstrom D6,683/61: MC depletion by 48/80 "failed to influence tensile strength, rate of wound contraction or qualitative aspects of *wound healing* in these animals (rats). These findings appear to minimize the role of the tissue mast cell in fibrillogenesis in this species."

Uvnäs D26,479/60; *Moran et al.* D33,693/62; *Diamant* D33,745/62: Observations on the effect of *anoxia* on histamine release from guinea-pig and rat lung tissue in vitro led to the "assumption that high-energy compounds available at the time of exposure of the lung tissue to the histamine-releasing agents are of consequence for histamine release to proceed. They also suggest that the initial reaction [coupling of antigen to antibodies and of compound 48/80 to active sites] occurs without involvement of high-energy compounds". It is not yet clear to what extent these conclusions are applicable to the metabolic changes in the MCs of the lung "since histamine release from isolated rat mast cells is not affected by anoxia in the absence of glucose" (*Uvnäs & Thon* D26,478/61; *Moran et al.* D33,693/62). At first sight, this may appear inconsistent with the importance of the metabolic reactions occurring in MCs. Since albumin is necessary for histamine to be released from isolated rat MCs (*Uvnäs & Thon* D26,478/61), it was suggested that the albumin might render the MCs insensitive to anoxia (*Moran et al.* D33,693/62). The importance of the metabolic reactions occurring in isolated rat MCs is, however, evident from the finding that histamine release induced by *Cyanea capillata* and by 48/80 was inhibited by dinitrophenol, whereas this inhibition was abolished in the presence of glucose.

Raab D39,956/62: In guinea-pigs sensitized with *dinitrochlorbenzol,* the subsequent application of this allergen to the skin normally produces an eczema with proliferation of local MCs. In the 48/80-pretreated guinea-pig, this form of eczema can no longer be elicited.

Antweiler D64,030/63: Following pretreatment with *polyvinylpyridin-N-oxide* i.p., 48/80 i.p. loses much of its MC-granule and histamine-discharging effect in the rat. It is assumed that polyvinylpyridin-N-oxide protects the MCs against osmotic stimulation.

Moran & Westerholm D69,395/63: *Reserpine* was shown to release neither 5-HT nor histamine from rat peritoneal MCs in vitro. Reserpine in vivo caused a moderate reduction of the number of MCs in peritoneal fluid. "A reduction of the cellular content of 5-HT was also observed. Peritoneal mast cells obtained from reserpine-treated rats responded normally to compound 48/80 . . . the results indicate that reserpine has no effect on mast cells in vitro and only negligible effect in vivo."

COMPOUND 1935L

Arvy et al. C41,781/56: Rats, given a single i.p. injection of the histamine-liberator compound 1935L (a substituted butylamine), develop an acute anaphylactoid inflammation with an increase in blood histamine. At the same time, the MCs in the shock organs are disrupted and their debris is carried to the regional lymph nodes. MC destruction is most intense in the scrotum, less in the upper lip, and almost absent in the paws, although all three organs are affected by edema. The MCs in different parts of a given shock organ, for example the ear, are also unequally affected, being most degranulated on the internal, and least on the external (posterior) aspect of the pinna. These differences in sensitivity are ascribed to the structure of the tissues surrounding the MCs; high vascularity and a loose, distendable, connective tissue predispose for the degranulation of the local MCs.

Bray & Van Arsdel D26,900/61: The isolated peritoneal MCs of the rat discharge their histamine under the influence of 1935L.

CROTON

Pültz D30,085/12: In the fluid of cutaneous vesicles produced in man by the local application of croton oil, as well as in cutaneous vesicles occurring in the course of various diseases, numerous MCs [possibly basophils (*H.S.*)] and eosinophils are simultaneously present. Hence, some relation between eosinophils and MCs is suspected.

Nikulin et al. E24,333/62: In the walls of granuloma pouches induced by croton oil in the rat, MCs are quite regularly present.

CYANIDES

Jamieson & van den Brenk D8,004/61: KCN or NaCN i.p. cause no disruption of the mesenteric MCs of the rat nor do they prevent the disruption normally induced by chlorpromazine i.p.

CYCLIZINE

Norton & de Beer D30,591/55: Cyclizine inhibits the degranulation of rat peritoneal MCs normally produced by polymyxin, distilled water, and 48/80 in vitro.

CYPROHEPTADINE

Selye et al. D26,792/62: Various mastocalciphylactic reactions and anaphylactoid inflammations that are preventable by pretreatment with histamine liberators are also blocked by cyproheptadine, an antihistamine and anti-5-HT agent.

DECAMETHYLENE DIAMINE (1,10-DIAMINODECANE)

Riley B90,276/53: When injected i.v. in lethal or sublethal doses, or when applied in vitro to preparations of the mesentery, the histamine liberator diaminodecane hydrochloride causes degranulation of the MCs in the rat.

Grossberg & Garcia-Arocha D28,699/54: When the large granule fraction of dog liver homogenates is exposed to diaminodecane, it releases its histamine.

Braunsteiner et al. D27,986/57: Diaminodecane i.v. causes pronounced degranulation of the bone-marrow MCs in the rat while the MCs in spleen, lymph nodes, and mesentery are not significantly influenced.

DECYLAMINE

Högberg & Uvnäs D26,422/60: Decylamine disrupts the peritoneal MCs of the rat in vitro.

Boréus D65,098/60: Decylamine disrupts the MCs in the rat and hamster by virtue of an enzymatic mechanism.

Uvnäs D25,283/61: Unlike 48/80 and many other highly active histamine liberators, simple amines, such as decylamine, liberate histamine non-enzymatically perhaps by simply replacing endogenous histamine by the exogenous amine.

Moran et al. D33,693/62: N-decylamine releases 5-HT and histamine from the peritoneal MCs of the rat in vitro.

DEXTRAN

Lindner D63,794/54: Following s.c. injection of hexose polysaccharides (glycogen, inulin, dextran), numerous MCs appear in the regional lymph nodes of the rat. Paper-chromatographic studies suggest that the injected polysaccharides are metabolized and transformed into MC granules.

Rowley & Benditt C15,372/56: Injection of dextran into the rat's paw causes intense local edema with MC discharge.

Jasmin C24,745/56: The anaphylactoid inflammation produced by dextran in the rat is accompanied by degranulation of the MCs in the shock organs.

Keller C54,750/57: Dextran s.c. causes degranulation of the peritoneal MCs with an increased histamine excretion in the rat.

Keller D94,203/57: In the anaphylactoid shock organs of the rat, the MCs undergo degranulation under the influence of s.c. injected water (more than 10 per cent of body weight), dextran or trypsin, all of which produce more or less intense anaphylactoid inflammation.

Parratt & West C56,384/57; *West* C45,485/57: The anaphylactoid inflammation produced in the rat by dextran (or ovalbumen) is associated with a release of both 5–HT and histamine from the skin. This response is prevented by depletion of skin-5–HT by reserpine or prolonged 48/80 treatment; it is not prevented by depletion of histamine alone. The reaction is also prevented by pretreatment with the anti-5–HT BOL 148. "The anaphylactoid reaction in rats is mediated chiefly through the release of 5–HT." Yet the source of this 5–HT is not thought to be in the MCs since these undergo comparatively slight damage during the anaphylactoid inflammation and even when they are depleted of granules (e.g., by intense polymyxin pretreatment) a maximal anaphylactoid inflammation can still be produced.

Lagunoff & Benditt D7,116/59: Dextran does not degranulate rat peritoneal MCs isolated on a Millipore filter in vitro, hence, its action in vivo may be indirect.

Corbascio D27,440/60: Dextran i.p. discharges the metachromatic granules of the renal juxtaglomerular cells and those of the cutaneous MCs in the anaphylactoid shock organs in the rat.

Lagunoff & Benditt D26,708/60: Peritoneal MCs of the rat, isolated on a Millipore filter, release their granules and histamine under the influence of 48/80 or polymyxin but not upon treatment with dextran or ovomucoid. "Four agents which in vivo appear to have similar activities have been found by means of in vitro analysis to operate by at least two different mechanisms." [Dextran and ovomucoid produce the selectively "acral type" of anaphylactoid inflammation in vivo, while 48/80 and polymyxin cause much more generalized cutaneous responses. Furthermore, in rats pretreated for mastocalciphylactic or mastocalcergic reactivity, i.p. injection of ovalbumen or dextran (unlike 48/80 or polymyxin) causes no peritoneal calcification. Hence, these agents differ also in vivo (*H.S.*).]

Selye et al. D26,792/62: The anaphylactoid reaction and the associated MC degranulation in the shock organs are both prevented by pretreatment with cyproheptadine, an antihistamine and anti-5–HT agent. Colloidal carbon (India ink) given i.v. during the anaphylactoid reaction causes permanent staining of the shock-organs as a consequence of carbon binding in the regions in which the MCs discharge their granules. This selective staining is likewise prevented by cyproheptadine (*Fig. 8*).

Kátó & Gözsy D30,619/62: Neither i.v. nor i.p. injection of dextran in doses conducive to strong anaphylactoid inflammation produce any MC discharge even in the shock organs themselves "thus suggesting that liberation of loose binding histamine and serotonin from the mast cells is not involved in the dextran induced acute inflammatory reaction."

Beraldo et al. D39,770/62: MC degranulation and histamine release, produced in rat skin by dextran in vitro, is inhibited by glucose and other related carbohydrates. "The inhibitory effect of carbohydrates may be understood on the basis of a competitive mechanism."

Selye et al. D10,088/62: The topical calcinosis produced by $CrCl_2$ or $FeCl_3$ in rats sensitized for calciphylaxis by DHT is greatly enhanced when certain compounds, such as dextran, gelatin, dextrin, or polyvinylpyrrolidone are added to the metals. This phenomenon of "adjuvation" may depend upon the MC-discharging effect of the adjuvants which facilitates the spreading of the metal.

Burton D58,284/63: The ingestion of dextran granules by rat peritoneal MCs in vitro can be followed cinematographically.

Gözsy & Kátó E37,126/63: "In the rat, intravenous injection of minute amounts (7.9 mg/kg) of dextran induced edema formation of the same intensity as high doses (300–600 mg/kg). With the high doses, mast-cell disruption (histamine and serotonin release), vasodilatation, hypothermia, hypotension, hemoconcentration and edema occurred. Since minute doses of dextran induced only vasodilatation and edema formation, this response is considered as the pure anaphylactoid reaction. The syndrome provoked by high doses is a consequence of conditions created by the physical presence of large quantities of dextran in the blood, rather than an integral part of the proper anaphylactoid sequence. Minute doses of dextran induced edema without mast-cell disruption, hypothermia, hypotension or hemoconcentration, thus showing that the dextran response in the rat is mediated by factors other than histamine and serotonin of mast-cell origin."

Baeckeland E65,987/64: Rat peritoneal MCs cultured in vitro do not show degranulation when placed in contact with dextrin or polyvinylpyrrolidone.

Cronberg & Nilsson G10,504/64: Dextran i.p. does not cause degranulation of rat peritoneal MCs.

Gabbiani et al. D64,692/64: In rats calciphylactically sensitized with DHT, subsequent challenge with dextran, dextrin, polymyxin, or 48/80 induces a dermatosis characterized by wide-spread calcification of the most superficial layers of the dermis and epidermis. In the initial stages, calcification is limited to discharged MC granules.

Selye et al. E24,102/64: In rats pretreated with parathyroid extract, subsequent injection of dextran produces no calcification.

Selye et al. E24,139/64: In rats sensitized for mastocalciphylaxis (by DHT p.o. and $FeCl_3$ i.v.), dextran s.c. produces local calcification at the site of MC discharge. Under similar conditions, systemic treatment with dextran induces the "cephalonuchal syndrome" with massive MC discharge and subsequent calcification in the head and neck region. Furthermore, in rats sensitized only with DHT, the topical calcinosis induced by $FeCl_3$ s.c. is enhanced by the admixture of an MC-discharger such as dextran.

Caruso G11,119/64: In rats mastocalciphylactically sensitized with DHT p.o. and $FeCl_3$ i.v., the injection of dextran into the lip (which has a dense MC population) causes much more local calcinosis than when given s.c. on the back (where MCs are less numerous). It is concluded that the MCs play an important part in this type of mastocalciphylaxis.

Serafimov et al. E24,149/64: In rats prepared by lead acetate i.v., injection of dextran, dextrin, 48/80, polymyxin, and viomycin produce mastocalcergy in different parts of the body, depending upon the MC-discharger given and the route of its administration. "Presumably systemically administered histamine liberators can act selectively upon certain regions and thereby elicit specific organotropic effects, depending upon the agent used and the route of administration."

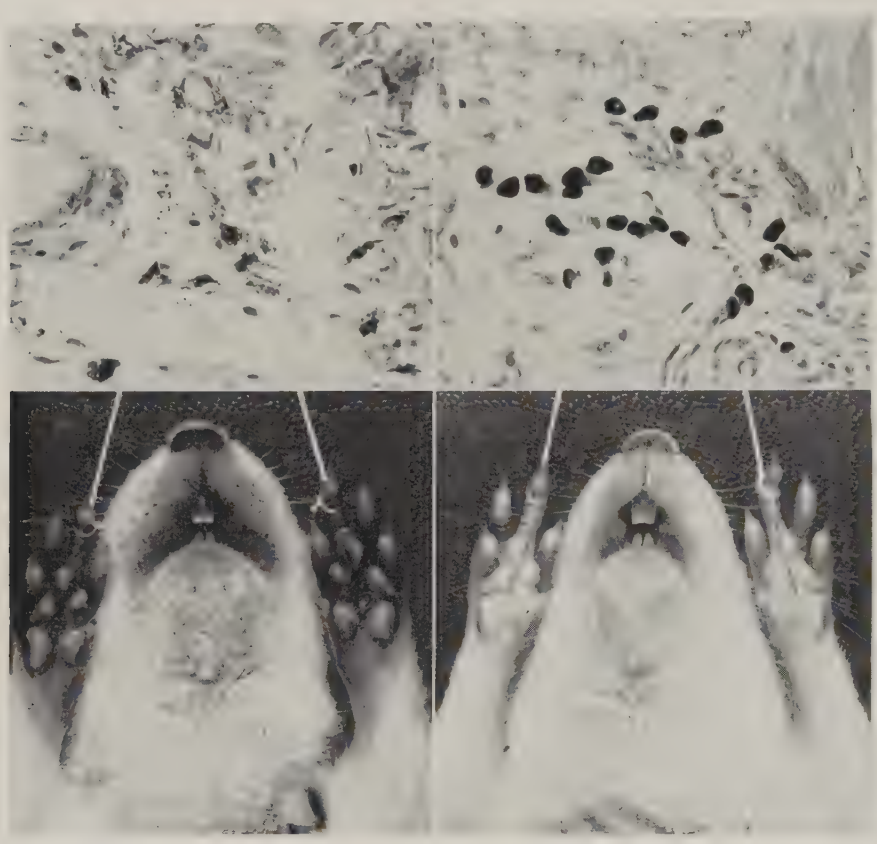

Figure 8.—Prevention by cyproheptadine of the anaphylactoid reaction normally induced by dextran. (*Top*) Histologic appearance of the MCs in the snout following dextran injection. In the otherwise untreated rat in which a marked anaphylactoid swelling appeared, the MCs discharged their granules (*left*), whereas in the cyproheptadine-protected animals the MCs are normal. (Cresyl violet, X 420.) (*Bottom*) Macroscopic appearance of the shock organs in similarly treated rats which, in addition, received Higgin's India ink (30 per cent 1 ml) i.v. simultaneously with the dextran. Marked anaphylactoid swelling and black staining of the snout and forepaws in the dextran-treated rat (*left*), whereas neither swelling nor ink fixation is noted in the cyproheptadine-protected animal. [After *Selye et al.* D26,792/62. Courtesy *Annals of Allergy*.]

Caruso E24,145/65: In rats given lead acetate i.v., subsequent injection of dextran into the lips, which are rich in MCs, causes much more calcification than if the same amount is injected into the hypodermis of the back where the MC population is less dense. These observations further illustrate the importance of the MCs in this form of calcergy.

Selye et al. G11,122/65: After the induction of calcergic reactivity by lead acetate i.v., systemic treatment with various MC-dischargers (e.g., 48/80, polymyxin, stilbamidine, dextran, dextrin) and MC products (5–HT, histamine) produces essentially distinct patterns of calcification in the rat. The preferential deposition of calcium in one or the other organ is ascribed to selective MC degranulation with consequent mastocalcergy induced by different compounds in different regions.

DEXTRIN

Selye et al. D10,088/62: The topical calcinosis produced by $CrCl_2$ or $FeCl_3$ in rats sensitized for calciphylaxis by DHT is greatly enhanced when certain compounds, such as dextran, gelatin, dextrin, or polyvinylpyrrolidone are added to the metals. This "adjuvation" may depend upon the MC-discharging effect of the adjuvants which facilitates the spreading of the metal.

Veilleux D20,584/63: First description of the production of an anaphylactoid reaction with dextrin in the rat. Only certain dextrins of relatively low molecular weight produce this reaction (perhaps they exert a specific degranulating effect upon the MCs of the anaphylactoid shock organs).

Rowley D69,169/63: Dextrin causes MC degranulation and vascular damage in the anaphylactoid shock organs of the rat.

Selye et al. E24,102/64: In rats calciphylactically sensitized with parathyroid extract, subsequent injection of dextrin produces no calcification.

Gabbiani et al. D64,692/64: In rats calciphylactically sensitized with DHT, subsequent challenge with dextrin induces a dermatosis characterized by wide-spread calcification of the most superficial layers of the dermis and epidermis. In the initial stages, calcification is limited to discharged MC granules.

Selye et al. E24,139/64: In rats sensitized for mastocalciphylaxis by pretreatment with DHT p.o. and $FeCl_3$ i.v., injection of dextrin s.c. produces local calcification at the site of MC discharge. Under similar conditions, systemic treatment with dextrin induces the "cephalonuchal syndrome" with massive MC discharge and subsequent calcification in the head and neck region. Furthermore, in rats sensitized only with DHT, the topical calcinosis induced by $FeCl_3$ s.c. is enhanced by the addition to the latter of a MC-discharger such as dextrin. This phenomenon is referred to as "adjuvation."

Serafimov et al. E24,149/64: In rats prepared by lead acetate i.v., injections of dextrin, dextran, compound 48/80, polymyxin, and viomycin produce mastocalcergy in different parts of the body, depending upon the MC-discharger given and the route of its administration. "Presumably systemically administered histamine liberators can act selectively upon certain regions and thereby elicit specific organotropic effects, depending upon the agent used and the route of administration."

Selye et al. G11,122/65: After the induction of calcergic reactivity by lead acetate i.v., systemic treatment with various MC-dischargers (e.g., compound 48/80, polymyxin, stilbamidine, dextran, dextrin) and MC products (5–HT, histamine) produces essentially distinct patterns of calcification in the rat. The preferential deposition of calcium in one or the other organ is ascribed to selective MC degranulation with consequent mastocalcergy induced by different compounds in different regions.

DICUMAROL

Giannico & Marrazza B47,769/50: Dicumarol p.o. diminishes the number of peritoneal MCs in the rat and causes degranulation of those remaining.

Baglioni C16,539/54, *p. 204*: Discussion.

DIETHYLAMINOLEATE

Blomquist C34,388/56: Following injection of diethylaminoleate (a sclerosing agent) into the submucosa of the guinea-pig stomach, the topical MC count remained unchanged during the first 10 days but rose significantly after 5 months as a consequence of the developing gastritis.

DIHYDROTACHYSTEROL (DHT)
Cf. VITAMIN D.

DOPA

Adams-Ray E37,378/64: Following injection of DOPA, there is an increase in the catecholamine content of the cutaneous MCs in various species, as judged by fluorescence microscopy.

DYES

Toluidine blue

Camble D39,585/52: Toluidine blue i.p. causes degranulation and vacuolation of MCs in the skin, stomach, mesentery, heart, and lymphatic organs of the rat.

Smith & Lewis C11,751/55: Following treatment with toluidine blue, the electron-micrographic structure of the granules in the peritoneal MCs of the rat and hamster remains unchanged.

Smith & Lewis D33,719/57: Electron-microscopic studies on the peritoneal MCs of the hamster and rat show that following treatment with toluidine blue, the specific granules become surrounded by clear areas and are widely separated from each other, while the endoplasmic reticulum becomes more conspicuous.

Bloom et al. C34,040/57: Electron and phase-contrast microscopy revealed that in the rat and hamster, toluidine blue i.p. increased the formation of granule-containing vacuoles in the peritoneal MCs, at the same time causing disintegration and release of granules.

Smith D63,185/58: Toluidine blue directly applied to the transilluminated rat mesentery causes MC discharge which can be followed by cinephotomicrographic observation.

Smith C54,403/58: In the rat, toluidine blue i.p. can cause histamine discharge without any microscopically-visible change in the mesenteric MCs.

Gustafsson & Cronberg D26,757/59: Toluidine blue i.p. causes disruption of the mesenteric and peritoneal MCs, both in the rat and in the hamster. Hence, toluidine blue cannot be used as a vital dye for MCs.

Gawecka E32,148/63: The discharge of peritoneal MCs produced by bacterial pyrogens i.p. in the rat can be prevented both in vivo and in vitro by the concurrent administration of toluidine blue i.p.

India ink

Webb D27,897/31: Following India ink i.p., the local MCs discharge their granules and regranulation is not complete for several weeks.

Antweiler D33,672/59: Intratracheal or i.p. administration of carbon (or silica) dust in distilled water causes local MC degranulation and histamine liberation in the rat. The same dusts suspended in Tyrode or Ringer solution do not possess this effect. Yet, isotonicity is not the only determining factor since these dusts given in isotonic dextrose are fully effective.

Trypaflavin

Hirt et al. D33,724/38: Trypaflavin causes intense fluorescence in murine MCs which renders them readily visible. Special attention is placed upon the shedding of large protoplasmic particles without the death of the cell.

EGG WHITE
Cf. OVALBUMEN.

EMULSIFIERS

Meng & Westerholm D39,781/63: Various oil emulsions as well as their emulsifiers i.p. cause degranulation of rat mesenteric MCs in vivo, and histamine discharge from isolated peritoneal rat MCs in vitro. "It is suggested that the action of these emulsifiers in causing disruption of rat mesentery mast cells in vivo and histamine release from isolated rat mast cells in vitro is of surface active nature."

ENZYMES

Hyaluronidase

Mannozzi-Torini B39,995/42: When paraffin sections of rabbit skin are exposed to aqueous solutions of testicular hyaluronidase, the MCs lose their metachromatic granules. From this it is concluded that the granules contain mucin which is attacked by hyaluronidase. [Control experiments with water alone have not been performed although it is known that the granules of rabbit MCs are especially soluble in water (*H.S.*).]

Santamaria D39,715/48: The ovarian MCs of the rabbit and cattle as well as the intestinal MCs of the rat show a lysis of their granules upon in-vitro treatment of hyaluronidase. These observations are thought to support the concept that the granules contain hyaluronic acid.

Bensley D42,231/49: A hyaluronidase-containing testicular extract caused local degranulation of MCs in the skin of the rat and mouse. By the 4th day, there was evidence of new fiber formation around active fibroblasts and the MCs began to reappear. The possible participation of MCs in collagen formation is considered.

Castiglioni E25,535/49–50: The granules of human connective-tissue MCs are partially dissolved by contact with hyaluronidase in vitro.

Asboe-Hansen B60,602/50: An injection of hyaluronidase into normal human corium causes an accumulation of MCs, which gradually discharge their granules.

Devitt & Samuels D26,863/53: Hyaluronidase i.p. causes no change in the MCs of the mesentery, heart, or skeletal musculature of the rat.

Baglioni C16,539/54, *p. 202*: Discussion.

Devitt et al. B96,691/54: Repeated i.p. injections of hyaluronidase failed to alter the morphologic appearance of the MCs in various tissues (including the mesentery) of the rat.

Braun-Falco D26,884/55: Hyaluronidase i.p. induces no significant discharge of the mesenteric MCs in the rat.

Hjelmman & Pettersson D39,851/55; *Hjelmman* D39,689/56: Hyaluronidase A and, to a much lesser extent, hyaluronidase B i.p., cause degranulation of the rat peritoneal MCs.

Pettersson D7,232/56: Rat peritoneal MCs discharge their granules when placed in contact with testicular or bacterial hyaluronidase.

Arvy D65,694/55: Topical treatment with hyaluronidase causes no degranulation of the lingual MCs in the frog *Rana esculenta*.

Wegelius & Asboe-Hansen C29,551/56: The cheek-pouch MCs of the hamster discharge their granules following topical treatment with hyaluronidase.

Rowley & Benditt C15,372/56: Injection of a hyaluronidase containing testicular extract into the rat's paw causes intense local edema with MC discharge.

Högberg & Uvnäs C47,831/57: Hyaluronidase causes no disruption of rat peritoneal MCs in vitro.

Lacaz et al. C33,366/57: In-vitro exposure of MCs to hyaluronidase does not interfere with their metachromasia.

Asboe-Hansen & Glick C56,235/58: Metachromatic granules are partially removed by testicular hyaluronidase from rat MCs in vitro.

Gustafsson & Cronberg D26,757/59: Hyaluronidase i.p. caused no obvious change in the peritoneal and mesenteric MCs of the rat or hamster.

Esterase

Keller G18,239/64: Anaphylaxis in vitro has been investigated in a system consisting of rat peritoneal MCs and an anti-rat γ-globulin from rabbit serum. From these studies "it is concluded that a proesterase, present in complement, is the key to the reaction whereby pharmacologically-active agents are released from the mast cell."

Lecithinase, phosphatidase

Högberg & Uvnäs C47,831/57: Among numerous enzymes studied, only lecithinase A had the ability of disrupting rat peritoneal MCs in vitro. This disruption was inhibited by agents which also inhibit the action of 48/80, namely: low temperature, acetic anhydride, 1,3-diphosphimidazole, a polyvalent immune serum against snake venom, and specific rabbit immune serum against lecithinase A from bee venom. "The observations are considered to

support the hypothesis that 48/80 acts by activating a lytic enzyme attached to the mast cell membrane. The activity of the enzyme is normally blocked by an inhibitor. When this inhibitor is removed, as by liberators such as 48/80, the enzyme becomes active and the membrane structures are attacked."

Riley D27,438/58: A toxin of *Cl. welchii,* purified bee venom and its heat-stable, nonenzymatic derivative, Melittin, as well as the powerful lecithinase which is present in the venom of the Indian cobra (*Naja naja*) "all bring about disruption of mast cells parallel to their ability to attack lecithin prepared from nerves or egg yolk; Melittin appears to act as a histamine-liberator by virtue of its basicity and surface active properties. But this does not explain why a histamine-liberator, such as compound 48/80, specifically destroys the mast cells in the rat, leaving the myelin in the nerve sheaths intact; indeed, the few mast cells which are present in the nerve sheaths entirely escape the action of the liberator, which itself has no specific action on lecithin in model systems."

Högberg & Uvnäs D26,477/58: Allicin (an enzyme-inhibitor from garlic) prevents the degranulation of rat peritoneal MCs which is otherwise produced by lecithinase A. Glutathione in excess reverses this blockage of degranulation.

Högberg & Uvnäs D26,422/60: Lecithinase A discharges the peritoneal MCs of the rat in vitro.

Boréus D65,098/60: In-vitro studies on the mesenteric MCs have suggested that lecithinase A (like 48/80) causes disruption through an enzymatic mechanism. In the guinea-pig, 48/80 does not affect the MCs, and in this species their disruption under other conditions is nonenzymatic.

Keller & Oppliger D27,077/61: Bee venom, or phosphatidase-A isolated from bee venom, causes immediate degranulation of human MCs removed from the bronchial tree by suction.

Keller D39,671/61; D39,659/62: Phosphatidase-A releases histamine and granules from isolated rat peritoneal MCs in vitro.

Moran et al. D33,693/62: Phospholipase-A releases histamine and 5-HT from the peritoneal MCs of the rat.

Uvnäs et al. D39,811/62: Phospholipase-A disrupts the mesenteric MCs of the rat in vitro. This action is blocked by anoxia and the block is prevented by glucose. "The results are taken as further evidence that phospholipase A 'disrupts' the mast cells not directly by its lytic action but by triggering an energy-requiring release mechanism."

Keller & Schwarz D58,842/63: Isolated rat peritoneal MCs discharge their granules under the influence of anti-rat rabbit serum, even in the presence of antisera to phosphatidase-A from bee venom and to bovine α-chymotrypsin. From this it cannot be concluded, however, that these enzymes are not involved in the discharge of MCs, because the antisera may be species-specific and, hence, ineffective in inactivating the corresponding enzymes of the rat.

Keller D17,764/64: Phosphatidase A does not produce lysis either of sheep erythrocytes or of rat peritoneal MCs in vitro unless lecithin or fresh serum is added as a substrate. In serum, the substrate is heat labile and probably not identical with complement.

Lysozyme

Piccaluga D28,533/56: The metachromatic staining of MCs is prevented by exposure to lysozyme.

Brusca et al. D27,392/59: When the peritoneal MCs are treated with enzymatically-inactivated lysozyme preparations, their metachromatic staining is still inhibited. Apparently, this action upon the MCs is not due to the enzymatic activity of lysozyme but to the fact that this electropositive colloid interacts with the electronegative MC-granules.

Heparinase

Isidor D30,595/54: If heparin is applied to skin wounds of guinea-pigs, many cells accumulate granules which stain metachromatically with toluidine blue. However, these granules, unlike those of true MCs, are dissolved by the topical application of heparinase. Presumably, in the MC heparin is bound to a substrate (perhaps a protein) which protects it against heparinase.

Lindner G17,153/55: The metachromatic granules of cutaneous MCs are not completely dissolved by contact with heparinase and, hence, they do not consist exclusively of heparin. [No experimental details are given (*H.S.*).]

Trypsin, plasmin, fibrinolysin

Dragstedt et al. A55,982/42: Heparin inhibits the release of histamine from cells (MCs not particularly mentioned) by trypsin and proteose in the rabbit.

Horvath D27,703/52: In-vitro exposure of isolated rat connective-tissue to trypsin shows that the MCs are resistant to this enzyme, presumably because heparin exerts an antitryptic activity.

Keller D94,203/57: In the anaphylactoid shock organs of the rat, the MCs undergo degranulation under the influence of s.c. injected water (more than 10 per cent of body weight), dextran or trypsin, all of which produce more or less intense anaphylactoid inflammation.

Keller C54,750/57: In the rat, trypsin s.c. causes degranulation of the peritoneal MCs with an increase in urinary histamine excretion.

Högberg & Uvnäs C47,831/57: Trypsin or fibrinolysin cause no disruption of rat peritoneal MCs in vitro.

Archer D26,626/59: Disruption of peritoneal rat MCs occurs upon exposure to trypsin in vitro.

Craps D12,408/61: Intracutaneous injection of trypsin causes moderate MC-degranulation associated with a decrease in the histamine and 5–HT content of the injected area in the guinea-pig and rat.

Yamura & Watanabe D58,429/61: Exposure to plasmin and trypsin discharges the granules and histamine from rat peritoneal MCs in vitro.

Watanabe E48,030/62: By treating rat MCs with plasmin, a discharge of histamine and a disintegration of MCs is observed in vitro. Since plasmin produces anaphylactoid shock, it is assumed to play a role in anaphylactic and allergic reactions, perhaps as a consequence of its effect upon MCs.

Cronberg & Nilsson G10,504/64: Plasminogen i.p. does not cause degranulation of rat peritoneal MCs.

Selye et al. E24,139/64: In rats sensitized for mastocalciphylaxis by DHT p.o. and $FeCl_3$ i.v., trypsin s.c. produces local calcification at the site of MC discharge.

Selye and Tuchweber G11,117/65: In rats pretreated with a single i.v. injection of lead acetate, topical connective-tissue calcification is produced at sites where trypsin is injected s.c.

Chymotrypsin

Lagunoff & Benditt D7,116/59: Chymotrypsin degranulates rat peritoneal MCs isolated on Millipore filters in vitro and releases their histamine.

Keller & Oppliger D27,077/61: Upon treatment with chymotrypsin, the MCs of the human bronchial mucosa (removed by suction in vivo) exhibit immediate degranulation.

Keller D39,671/61; D39,659/62: Of a great variety of enzymes studied, only phosphatidase-A and α-chymotrypsin were found to release granules and histamine from isolated rat peritoneal MCs in vitro.

Keller D58,041/62: Chymotrypsin is particularly effective in causing disruption of isolated rat peritoneal MCs.

Keller & Schwarz D58,842/63: Isolated rat peritoneal MCs discharge their granules under the influence of anti-rat rabbit serum, even in the presence of antisera to phosphatidase-A from bee venom and to bovine α-chymotrypsin. From this it cannot be concluded, however, that these enzymes are not involved in the discharge of MCs, because the antisera may be species specific and, hence, ineffective in inactivating the corresponding enzymes of the rat.

Uvnäs & Antonsson E23,517/63: Chymotrypsin and phosphatidase-A cause degranulation of rat mesenteric MCs in situ. This effect can be blocked by several metabolic inhibitors, while glucose prevents this block.

Pepsin

Archer D26,626/59: Disruption of rat peritoneal MCs occurs upon exposure to pepsin in vitro.

Cronberg & Nilsson G10,504/64: Streptokinase i.p. does not cause degranulation of rat peritoneal MCs.

Ribonuclease

Högberg & Uvnäs C47,831/57: Ribonuclease causes no disruption of rat peritoneal MCs in vitro.

Papain

Archer D26,626/59: Disruption of rat peritoneal MCs occurs upon exposure to papain in vitro.

ERGOT

Fontanini et al. D39,752/58: Ergot (hydergine) i.v., i.p., or i.m. causes dilatation of the mesenteric vessels associated with local MC discharge.

ETHANOL

Larsson & Sylvén D31,567/47; *Sylvén & Larsson* D26,612/48: Topical application of ethanol to the shaved skin of the mouse causes no obvious change in the local MC population.

Bray & Van Arsdel D26,900/61: Isolated rat peritoneal MCs discharge their histamine under the influence of ethanol.

ETHANOLAMINE

McGovern D27,739/57: When local inflammation is produced in the hind paw of the rat by the injection of ethanolamine (or by ethylchloride spray), the local MCs discharge their granules. When the MCs have been previously depleted by 48/80, the inflammatory edema is lessened but leukocytic migration into the tissues is hastened. Local injection of heparin does not influence the edema but retards the migration of leukocytes. The MCs may play a role in regulating inflammation.

ETHER

Larsson & Sylvén D31,567/47: Topical application of ether to the shaved skin of the mouse causes no obvious change in the local MC population.

ETHIONINE

Benson D18,867/64: The cyclic administration of DL-ethionine and N-2-fluorenylacetamide (alone and in combination) to rats, causes structural changes in the exorbital lacrimal glands which are associated with local MC-proliferation and are interpreted as manifestations of premature tissue aging.

FERRIC DEXTRAN

Baker et al. D14,284/61: In the discussion of a paper on the topical effects of ferric dextran in various species, it is stated that "iron-dextran passes into most local tissue cells, including muscle and mast cells, almost immediately; and almost as quickly it disappears, except from collagen fibres and necrotic muscle." [The particular species and the experimental conditions (timing, dosage, etc.), under which this observation was made, are not mentioned (*H.S.*).]

Selye et al. D8,490/61: After calciphylactic sensitization with DHT, systemic treatment with polymyxin produces a generalized discharge of cutaneous MCs with subsequent calcification of their liberated granules. This response is enormously increased if small amounts of ferric dextran are given i.v. concurrently with the polymyxin. Under these circumstances, a dermatomyositis-like inflammation of the skin and skeletal muscles results, presumably because "the calcified granules stimulate inflammation and connective-tissue proliferation, particularly in those areas of the muscular and cutaneous systems where MCs are notoriously abundant."

Selye et al. D10,088/62: Administration of ferric dextran or $FeCl_3$ i.v. to rats sensitized for calciphylaxis by DHT facilitates the production of topical calcinosis at sites where gelatin, dextran, ovalbumen, dextrin, polymyxin, 48/80, and various other agents are injected s.c. This enhanced reactivity was designated as "siderocalciphylaxis", but its mechanism could not

yet be elucidated. [Subsequent experiments showed that numerous other metals can substitute for iron in inducing this increased reactivity to challengers which cause MC degranulation. Hence, we now know that siderocalciphylaxis is merely one modification of mastocalciphylaxis in which various metals are attracted to sites of MC degranulation and subsequently localize blood-borne calcium salts (*H.S.*).]

Selye et al. D15,688/62: In rats sensitized for calciphylaxis with DHT, s.c. injection of distilled water produces no local calcinosis, unless the animals simultaneously receive small amounts of ferric dextran i.v. This action of water appears to depend upon its MC-depleting potency. Near isotonic solutions of NaCl or glucose have little or no calcium precipitating effect under similar circumstances, while highly-hypertonic solutions of these compounds are virtually as effective as distilled water, presumably because, like the latter, they discharge MCs. Apparently, the ability of discharged MC granules to attract calcium salts is greatly enhanced if they are first incrusted by blood-borne iron, which acts as a calcium trap.

Selye et al. D15,989/63: In rats sensitized for mastocalciphylaxis by pretreatment with DHT p.o. and ferric dextran i.v., polymyxin, compound 48/80, or stilbamidine s.c. produce topical calcinosis, presumably owing to the fixation of iron and then of calcium salts on the discharged MC granules. Thus, the MCs participate in pathologic calcification.

Burton D58,284/63: The ingestion of ferric dextran granules by rat peritoneal MCs can be followed cinematographically in vitro.

Gabbiani & Tuchweber D63,219/63: Histochemical studies show that the various calciphylactic reactions, induced in DHT-sensitized rats by ferric dextran, ferric dextrin, ferric sorbitol, and other iron compounds, depend upon the extracellular localization of iron. The metal is demonstrable in the target organs before calcification, but only those iron compounds that do not tend to be rapidly phagocytosed, attract calcium secondarily. [The participation of the MCs in the localization of iron, though probable, has not been examined here (*H.S.*).]

Selye et al. D40,219/63: Large calcified skin plaques are produced if rats, pretreated with DHT p.o., are calciphylactically challenged by ferric dextran s.c. A variety of agents such as distilled water, mechanical trauma, formaldehyde, croton oil, or histamine liberators (48/80, polymyxin), selectively inhibit this skin calcification at the point where they are applied within the challenged area *(Figs. 9, 10, and 11).*

Kunz D42,047/64: In sarcomas produced by repeated administration of ferric dextran s.c., neoformation of MCs was demonstrated by staining with toluidine blue and autoradiography.

Selye et al. E24,102/64: In rats calciphylactically sensitized with parathyroid extract (just as in those pretreated with DHT), subsequent injection of ferric dextran s.c. produces topical calcinosis, while the same compound i.p. elicits calcinosis in the pancreas, stomach, and mesentery.

Gabbiani & Rojo Ortega D55,958/64: Pretreatment with various stressors (restraint, spinal cord transection, transection of various motor nerves, formalin, cold baths, fasting, reserpine, adrenaline) protects the DHT-pretreated rat against the production of a local calciphylactic response at the site of an s.c. ferric-dextran injection.

Selye et al. E24,147/64: In rats mastocalciphylactically sensitized with DHT p.o., and ferric dextran i.v., minute doses of polymyxin s.c. caused intense local calcification owing to the discharge of metachromatic MC granules which immediately surrounded themselves with calcified precipitate and secondarily induced extensive connective-tissue calcification.

Jahnke G11,110/64: In rats calciphylactically sensitized with DHT, small doses of ferric dextran i.v. permit the production of topical calcinosis at sites where polymyxin is injected s.c. On the other hand, large doses of ferric dextran protect against this topical action of polymyxin but at the same time induce pronounced renal and cardiac calcification. [It remains to be seen to what extent the local protection against polymyxin-induced hypodermic calcinosis depends upon the influence of ferric dextran on the MC population (*H.S.*).]

Gabbiani & Nielsen G11,130/64: In rats given ferric dextran i.v., the MCs discharge their granules in the anaphylactoid shock organs and iron appears in close contact with the discharged MC granules within four minutes. Cyproheptadine (an antihistamine and anti-5-HT agent) protects all the anaphylactoid shock organs against these changes when given i.v. and induces topical protection when injected into one of the shock organs (e.g., a paw). On the other hand, when ferric dextran is injected directly into connective tissue, its localization in

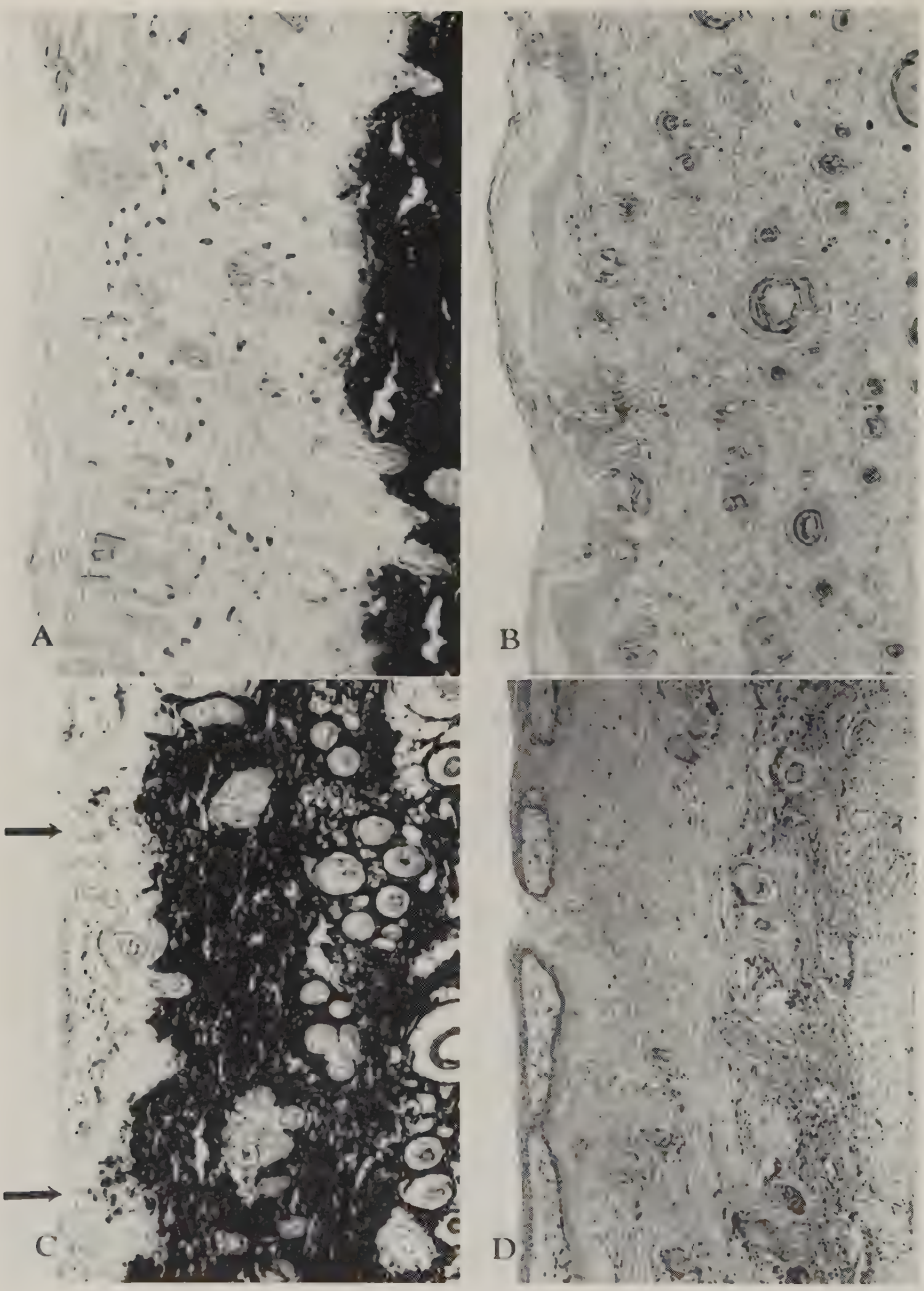

Figure 9.—Prevention of cutaneous calciphylaxis by compound 48/80. Histologic changes seen after treatment as in *Figure 11, c.* (*A*) Heavily-calcified peripheral zone of the challenged area. Only the subepidermal layer is free of calcium and here we see numerous MCS. (*B*) Protected central zone where compound 48/80 was injected. Here, there is no calcification and MCS are extremely scarce (von Kóssa + azure A, X 96). (*C*) Another heavily-calcified portion of the peripheral zone showing the characteristic ingrowth of the epithe-

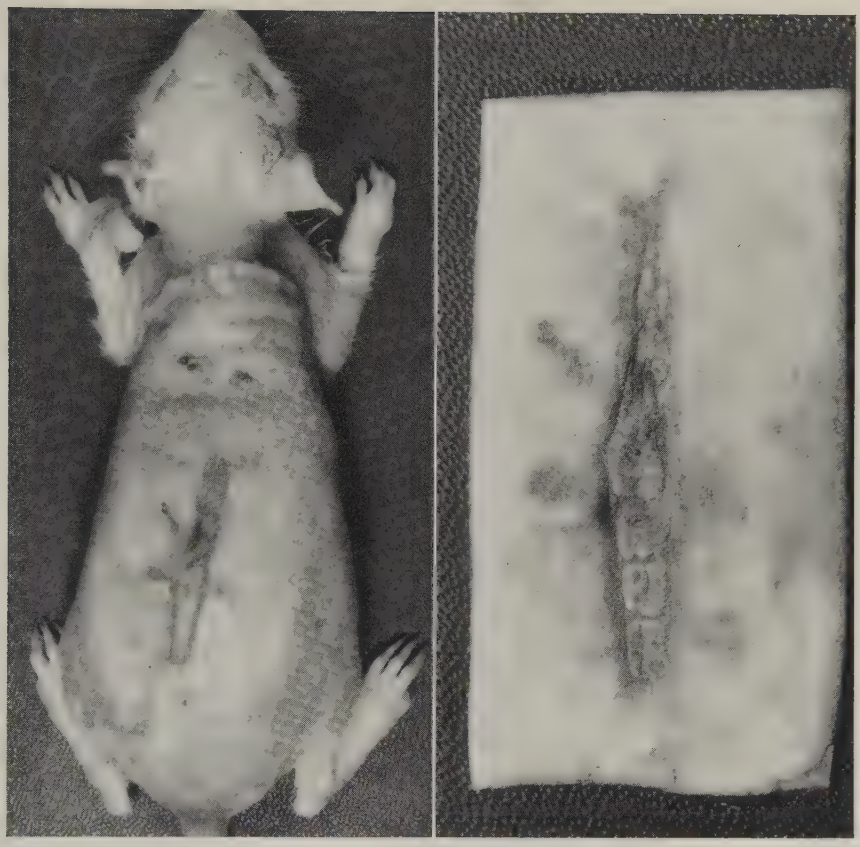

Figure 10.—Prevention of cutaneous calciphylaxis by topical trauma. (*Left*) General aspect of the calciphylactically-produced carapace comprising virtually the entire back, excepting a well-delimited, narrow central band where the skin was pinched with a hemostat. (*Right*) Higher magnification of the traumatized area shows essentially normal appearance of the traumatized skin band in the midst of its heavily calcified surroundings. Only thin, white (calcified) epidermal scales cover the protected area. [After *Selye et al.* D40,219/63. Courtesy *A.M.A. Archives of Dermatology*.]

---

lium at two perforation points (*arrows*). The uncalcified subepidermal connective tissue is now completely surrounded by ingrowing epithelium and still contains undischarged MCs (von Kóssa + azure A, X 144). (*D*) Lower magnification of another portion of the skin shown in the preceding picture. This slide was stained only for iron and exhibited a diffuse blue staining in the necrotic central zone. On the surface, several subepidermal, uncalcified connective-tissue islets are seen to be separated by perforation points from which the surface epithelium grows under them with reversal of layering (Prussian-blue, X 96). Using appropriate dyes, the entire necrotic central zone could be shown to contain histochemically-demonstrable iron, diffuse metachromatic material, and calcium phosphate in extracellular location. [After *Selye et al.* D40,219/63. Courtesy *A.M.A. Archives of Dermatology*.]

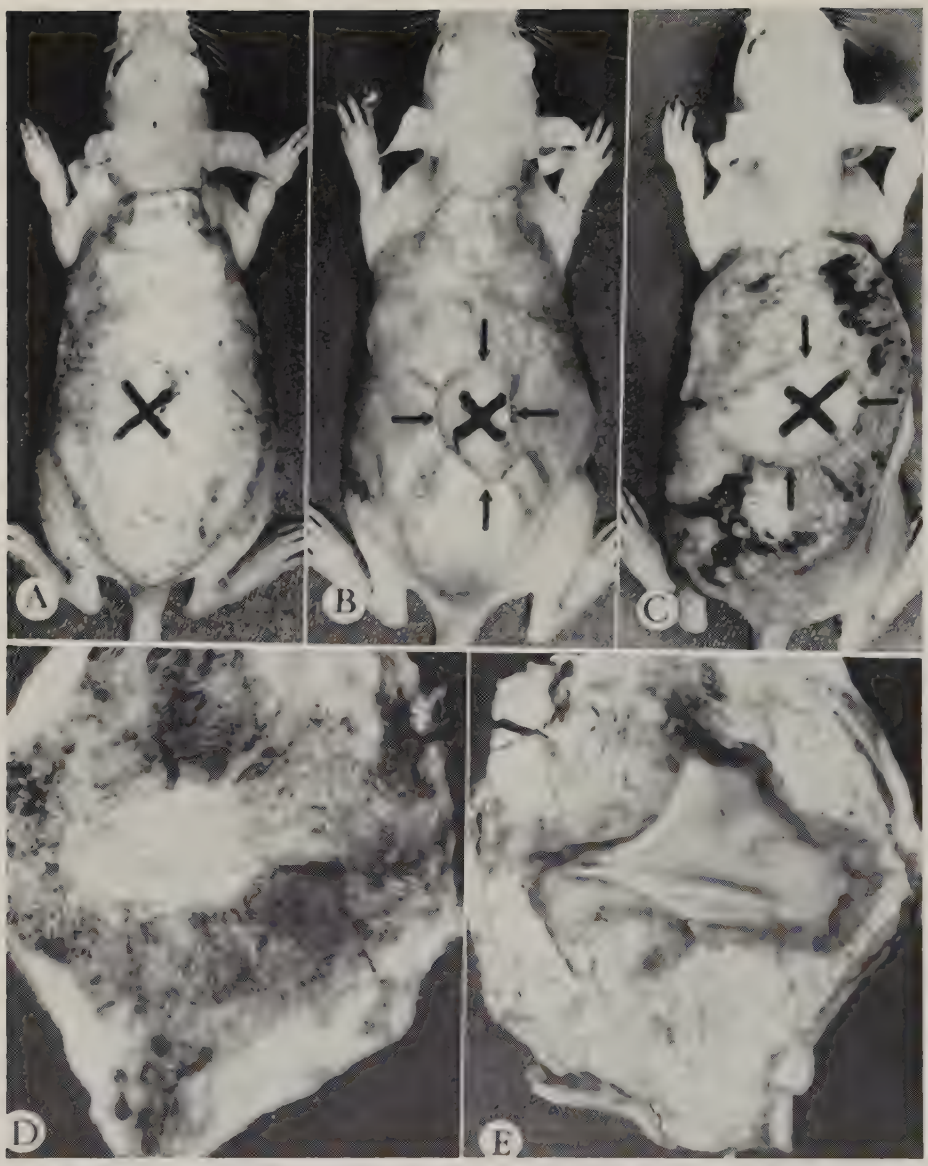

Figure 11.—Prevention of cutaneous calciphylaxis by histamine liberators. All rats received DHT p.o. and Fe-Dex by s.c. infiltration whereby a large calcified shield was produced on the back. Potentially-protective agents were applied near the center of this area, at the point marked with a cross. (*A*) Tyrode solution offers no protection. (*B*) Polymyxin and (*C*) compound 48/80 offer topical protection and the skin appears normal within the limits of the injection area (demarcated by arrows) despite massive calcification of the surroundings. The dark spots and lines in the calcified area (particularly evident in *C*) are scratch wounds. (*D* and *E*) Higher magnification of the dissected cutaneous shield in another rat treated like that shown in *C*. The clear-cut demarcation of the heavily calcified peripheral from the protected central zone is evident both on the epidermal (*D*) and the subcutaneous (*E*) aspect. [After *Selye et al.* D40,219/63. Courtesy *A.M.A. Archives of Dermatology*.]

MCs as well as the subsequent MC discharge and inflammation cannot be altered by cyproheptadine. "Therefore, it seems reasonable to assume that cyproheptadine inhibits the migration of Fe-Dex (ferric dextran) from vessels to the connective tissue of the shock organs."

FERRIC DEXTRIN

Gabbiani & Tuchweber D63,219/63: Histochemical studies show that the various calciphylactic reactions, induced in DHT-sensitized rats by ferric dextrin and other iron compounds, depend upon the extracellular localization of iron. [The participation of the MCs in the localization of iron, though probable, has not been examined here (*H.S.*).]

Veilleux D55,007/64: In rats calciphylactically sensitized with DHT, the calcification of the anaphylactoid shock organs normally induced by the injection of ferric dextrin i.v. is suppressed by dextran i.p. given 1 hour prior to the ferric dextrin. Histochemical studies indicate that in the latter case the iron does not reach the shock organs; presumably, this is why calcification fails to occur. [Although the author does not say so, the prevention of iron deposition may well be related to the previous discharge of the MCs induced in the shock organs by dextran pretreatment (*H.S.*).]

Selye et al. E24,102/64; E24,139/64: In rats calciphylactically sensitized with parathyroid extract (just as in those pretreated with DHT) and challenged with ferric dextrin, calcification appears in the esophagus, palate, paws, lips, and large joints. Since ferric dextrin is an MC-discharger, it is probable that the MCs participate in these responses *(Fig. 12)*.

Tuchweber D57,153/64: In rats calciphylactically sensitized with DHT, ferric dextrin i.v. produces a calcifying anaphylactoid reaction which can be prevented by pretreatment with ferric dextran. [It remains to be seen whether, here, the ferric-dextran pretreatment exerted its protective effect through the discharge of MCs or through some calcium-deviating action of the iron (*H.S.*).]

Gabbiani & Rojo Ortega D55,958/64: Pretreatment with various stressors (restraint, spinal-cord transection, transection of various motor nerves, formalin, cold baths, fasting, reserpine, adrenaline) protects the DHT-pretreated rat against the production of a calcifying anaphylactoid reaction by ferric dextrin i.v. Curiously, the iron deposition in the shock organs is not prevented by any of these stressors.

Figure 12.—Systemic mastocalciphylaxis (calcifying anaphylactoid inflammation). (*Left*) Control rat to show normal skin after treatment with hair remover. (*Right*) DHT-sensitized rat given ferric dextrin i.v. The anaphylactoid shock organs, lips, periorbital tissue, roots of ears, and paws underwent heavy calcification. [After *Selye et al.* E24,139/64. Courtesy *Annals of Allergy*.]

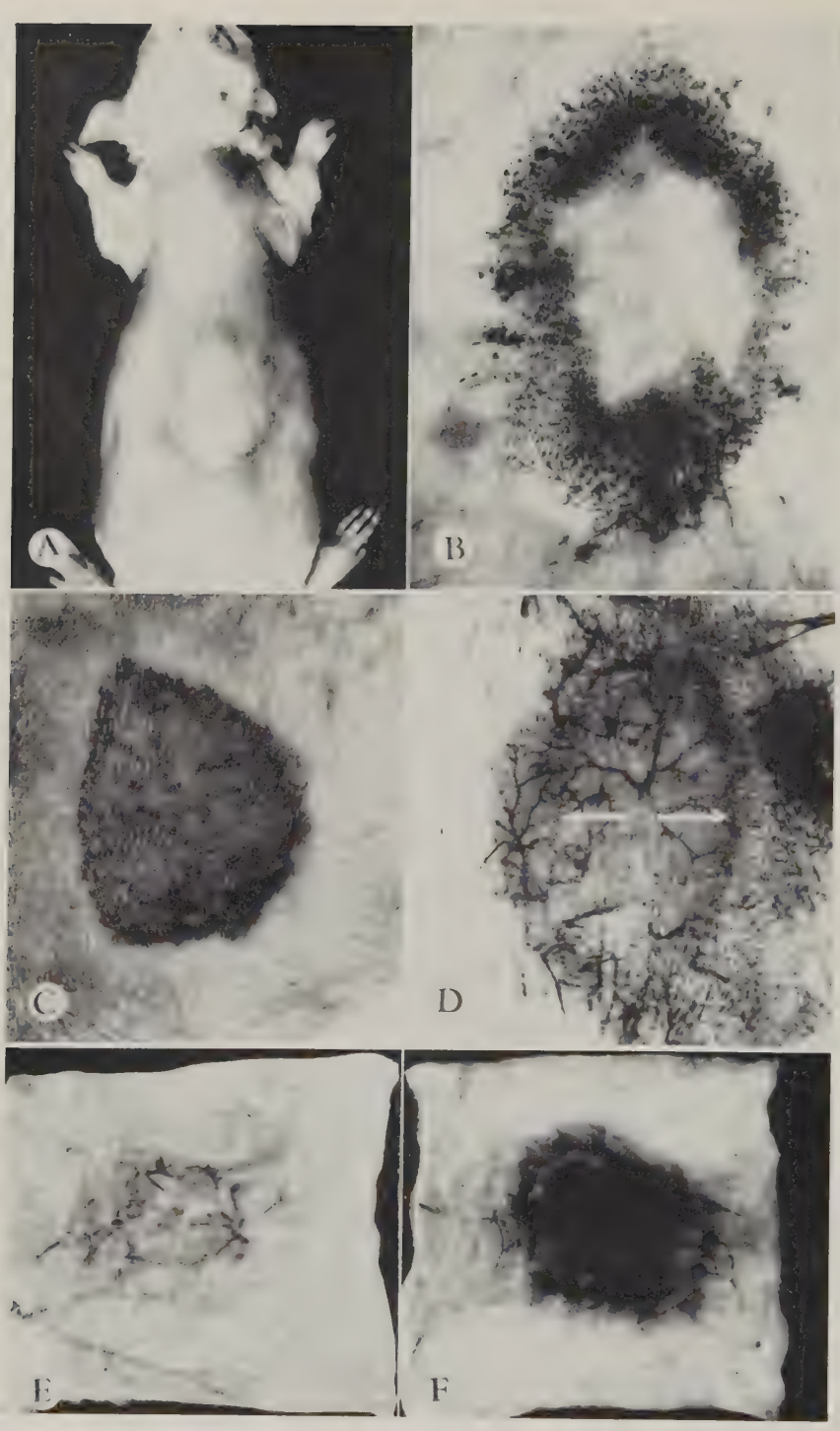

Figure 13.—Mastopexis produced with polymyxin + India ink or ferric oxysaccharate. (*A*) Rat simultaneously treated with India ink i.v. and polymyxin s.c. Halo of India ink demarcates the central area where polymyxin was injected.

FERRIC OXYSACCHARATE

Selye et al. D24,159/63: When rats are given ferric oxysaccharate i.v. and polymyxin s.c., the cutaneous area, in which the MCs are discharged, exhibits hemorrhagic necrosis similar to that seen in the Shwartzman-Sanarelli phenomenon. Repeated i.v. administration of ferric oxysaccharate produces heavy selective iron precipitation in the choledochus and duodenum; this results in an extreme dilatation of the bile ducts and development of duodenal ulcers with necrosis. Here, the iron particles precipitate predominantly in the immediate vicinity of the MCs, which are particularly numerous around the extrahepatic bile ducts and the duodenum of the rat. To test the hypothesis of a causal relationship between MC discharge and iron precipitation, polymyxin was given prior to the administration of ferric oxysaccharate. Here, after depletion of the MCs, the bile duct and choledochus lesions, normally elicited by the iron preparation, were prevented *(Figs. 13 and 14)*.

Veilleux D27,369/63: A calcifying anaphylactoid reaction can be produced in DHT-sensitized rats either by ferric dextrin i.v. or by ferric oxysaccharate i.v. + dextran i.p. Pretreatment with dextran (which discharges the MCs in the anaphylactoid shock organs) prevents both these responses.

Selye et al. E24,102/64: In rats calciphylactically sensitized with parathyroid extract, subsequent systemic treatment with ferric oxysaccharate produces calcification in the left cardiac auricle, the hepatic veins, the Kupffer cells, and the choledochus. It is questionable to what extent MC discharge participates in these responses.

FERRIC SORBITOL

Gabbiani & Tuchweber D63,219/63: Histochemical studies show that the various calciphylactic reactions, induced in DHT-sensitized rats by ferric sorbitol and other iron compounds, depend upon the extracellular localization of iron. [The participation of the MCs in the localization of iron, though probable, has not been examined in these series (*H.S.*).]

FLUORENYLACETAMIDE

Benson D18,867/64: The cyclic administration to rats, of D1-ethionine and N-2-fluorenylacetamide (alone and in combination) causes structural changes in the exorbital lacrimal glands which are associated with local MC-proliferation and are interpreted as manifestations of premature tissue aging.

FORMALDEHYDE

Hill C64,094/58: Formaldehyde i.m. induces lysis of the mesenteric and omental MCs of the rat without vacuolization or degranulation.

Histologically, ink granules are found in the immediate vicinity of perivascular MCs. (*B*) Skin of animal shown in *A* reflected and viewed from subcutis. Note arrangement of ink granules around arborizing blood vessels in the halo surrounding the polymyxin-injection site. (*C*) Surface view of cutaneous necrosis produced at site of s.c. polymyxin injection in rat given Fe-OS i.v. (*D*) View from the subcutis of the preparation shown in *C* after staining with Prussian blue. Perivascular ferrification in halo surrounding the central necrotic area. Arrows mark border line between central necrosis (brown) and peripheral ferrified halo (bright-blue). Prussian blue-positive granules proved to be in the immediate vicinity of discharged perivascular MCs. (*E*) Rat treated with polymyxin s.c., three hours before Fe-OS i.v. With this timing, no noteworthy tissue damage is visible even upon inspection from subcutis site. (*F*) Rat treated like that shown in *E*, except that polymyxin was given simultaneously with Fe-OS. Here, the injection site exhibits severe hemorrhagic necrosis with thrombotic occlusion of the larger veins. [After *Selye et al.* D24,159/63. Courtesy *British Journal of Experimental Pathology*.]

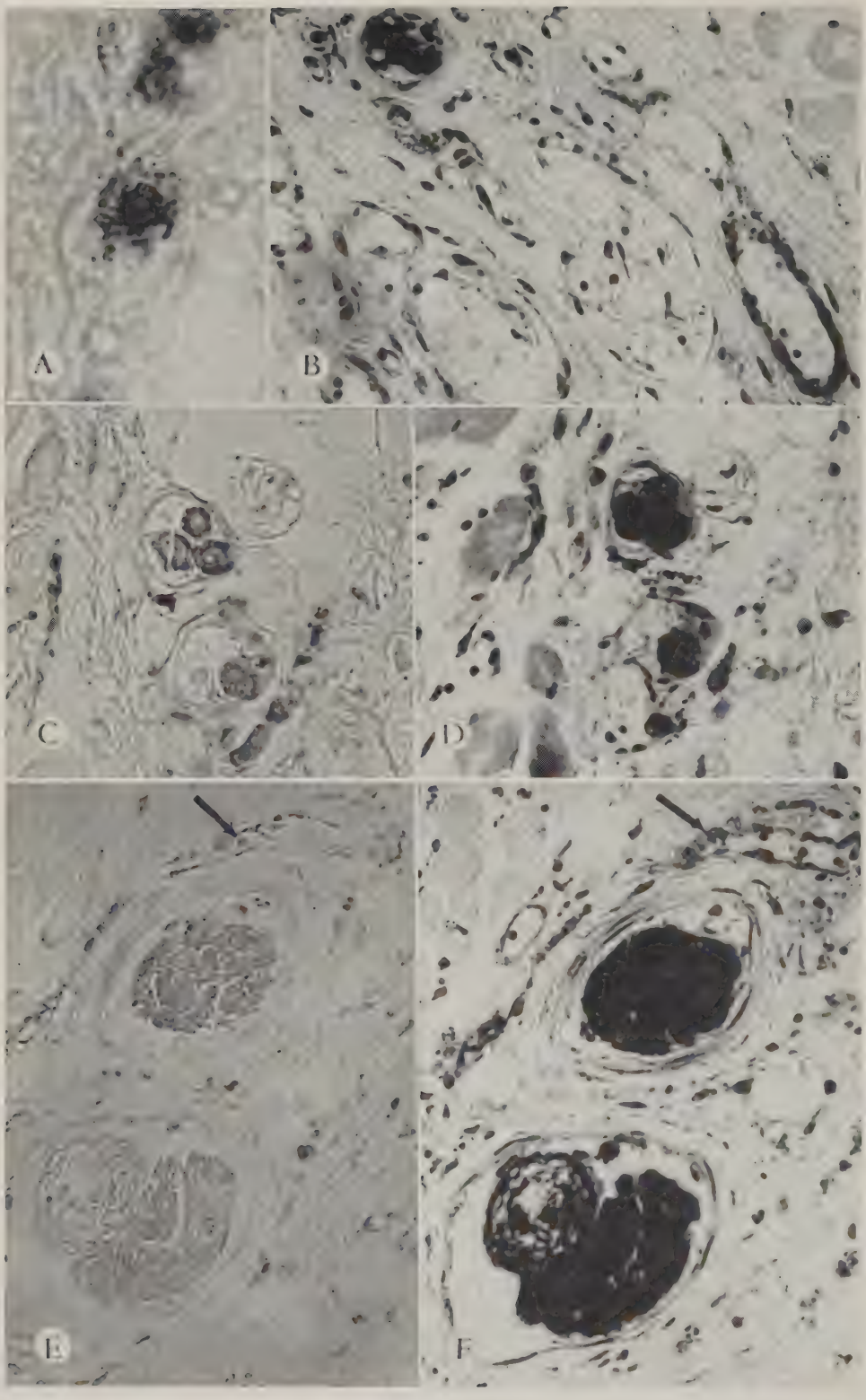
A
B
C
D
E
F

Hill & Pospíšil C73,689/59; C99,519/60: Following a single i.m. injection of formaldehyde, the mesenteric MCs of the rat exhibit a biphasic reaction: swelling with degranulation in the initial stage (referred to as the "glucocorticoid phase of stress"), followed by shrinking with granule lysis (the "mineralocorticoid phase"). In adrenalectomized rats, formaldehyde elicits only shrinkage and lysis of MC granules. On the other hand, cortisol produces swelling with degranulation both in adrenalectomized and in intact rats. Hence, these MC changes are viewed as part of the G. A. S.

Bray & Van Arsdel D26,900/61: The isolated peritoneal MCs of the rat discharge their histamine under the influence of formaldehyde.

Cannizzaro D31,003/62: Upon exposure to formaldehyde fumes, the tracheal MCs of the rat show an initial degranulation followed by excessive accumulation of MCs in the tracheal mucosa. It is assumed that during inflammation new MCs are formed from fibroblasts.

GELATIN

Higginbotham et al. D15,838/56: Topical injection of gelatin causes degranulation of the cutaneous MCs of the mouse.

Selye et al. D10,088/62: The topical calcinosis produced by $CrCl_2$ or $FeCl_3$ in rats sensitized for calciphylaxis by DHT is greatly enhanced when certain compounds, such as dextran, gelatin, dextrin, or polyvinylpyrrolidone are added to the metals. This phenomenon of "adjuvation" may depend upon the MC-discharging effect of the adjuvants which facilitates the spreading of the metal.

GLOBULIN

Kelsall D7,784/61: In the hamster, injection of bovine gamma-globulin increases the formation of MCs along the afferent lymphatics of the regional lymph nodes.

GLUCOSAMINE

Paschoud D26,812/54: Repeated s.c. injection of glucosamine or heparin (unlike glucuronic acid and NaCl solutions), causes dark pigmentation with melanophore formation and the appearance of MC-like cells with metachromatic granules, both in grey rabbits and in man. In the rabbit, heparin and glucosamine also produce local blackening of the hair. Presumably, the glucosamine and not the glucuronic-acid compound of heparin is responsible for these changes. Glucosamine may play a role both in the formation of MCs and in melanin formation. [It should be kept in mind, however, that nonspecific local damage (trauma, heat) can produce pigmentation (*H.S.*).]

GLUCOSE

Vezzini D39,606/33: The MC-count of the mesentery and small intestine rises in rats kept on a pure meat or sugar diet, but remains normal during fasting. Conversely, the number of disintegrating MCs rises on the meat diet and during fasting in comparison with the control values of animals kept on a normal mixed diet.

Bartoli D39,605/38: 30 per cent glucose i.p. causes intense degranulation of the mesenteric MCs in the rat.

Figure 14.—Histologic appearance of injection site in rats given polymyxin s.c. simultaneously with Fe-OS i.v. (*A*) The occurrence of calcified granules (black) around the nucleus and metachromatically-staining granules (gray) near the periphery of an MC at the site of polymyxin injection (von Kóssa + methylene blue. X 600). (*B, D, E*) Iron deposition is demonstrated around discharged perivascular MC granules in the vessel walls and in intravascular thrombi by the Prussian-blue reaction. (*C* and *E*) Methylene-blue stain shows metachromatic material in positions in which iron was demonstrable on the adjacent sections represented in *D* and *F* (X 250). [After *Selye et al.* D24,159/63. Courtesy *British Journal of Experimental Pathology*.]

Baglioni C16,539/54, *p. 208*: Discussion.

Fontanini et al. D39,752/58: Hypertonic glucose solutions cause destruction of the MCs in the rat mesentery, but only upon i.p. injection.

Antweiler D33,672/59: Carbon or silica dust, intratracheally or i.p., causes local MC degranulation and histamine liberation in the rat if suspended in distilled water but not if given in Tyrode or Ringer solution. Yet, isotonicity is not the only determining factor since the same dusts, given in isotonic dextrose solution, are fully effective.

GLYCOGEN

Lindner D63,794/54: Following s.c. injection of hexose polysaccharides (glycogen, inulin, dextran), numerous MCs appear in the regional lymph nodes of the rat. Paper-chromatographic studies suggest that the injected polysaccharides are metabolized and transformed into MC granules.

GOLDTHIOGLUCOSE

Hellman et al. E22,484/63: The MCs of the mouse were examined in the epididymal and subcutaneous adipose tissues. "Both with the obesity induced by goldthioglucose and that associated with the American variety of the obese-hyperglycemic syndrome there was a considerable accumulation of mast cells in the fat depots. While the relative number of mast cells was calculated as 3 per 100 epididymal fat cells in the lean controls, it was more than 50 for the obese-hyperglycemic animals. . . . The greatly increased mast cell content of the adipose tissue in obesity would be consistent with previous work on the rat, in which it was suggested that the lipase activity of the adipose tissue is concerned with accumulation of fat in depots."

HEMOGLOBIN

Brusca D39,526/58: In-vitro treatment with hemoglobin abolishes the toluidine-blue metachromasia of cutaneous and peritoneal MCs of the rat. This loss of metachromasia is ascribed to the fixation of hemoglobin on the MC granules which is directly demonstrable by histologic observation. It is assumed that the MCs play a defensive role in taking up foreign particles from the connective tissue.

HEPARIN

Cf. also HEXADIMETHRINE, PROTAMINE AND OTHER ANTIHEPARINS

Asplund et al. D28,695/39: Repeated i.v. or i.p. injections of heparin cause depositions of metachromatic material throughout the RES in the rat, guinea-pig, and rabbit. Most of the injected heparin appears to be eliminated in the form of metachromatic granules through the tubular cells of the kidney. At the site of injection, large metachromatically-staining, heparin-containing phagocytes and fibroblasts are found, but their relationship to MCs is not discussed. In pregnant rats and guinea-pigs, heparin is deposited in the yolk sac entoderm and uterus, but large doses produce abortion.

Schürer D40,720/46: Heparin i.p. or i.v. increases the number of large basophils ("Kugelhaufen") in the peritoneal fluid of the rat; presumably, these cells arise as a result of phagocytosis.

Paff et al. D26,765/47; *Roth* D30,553/52; *Paff et al.* D28,673/52: Heparin added to embryonic chick heart cultures inhibits mitosis in the outgrowing fibroblasts which phagocytose metachromatic heparin granules. This antimitotic effect is attributed to an interference with nucleoprotein metabolism. "As evidence that heparin inhibition of mitosis may act in the intact animal, we offer the observation that when pieces of mast cell tumors are grown in tissue culture, only mast cells grow. This despite the fact that the tumor contains other cell types. Since mast cells produce heparin or a precursor, it seems that the explanation for the phenomenon may also lie in Roth's observation that heparin inhibits ribonuclease."

Meneghini D39,768/49; D39,847/50: Repeated cutaneous infiltration with heparin produces an urticaria pigmentosa-like mastocytosis in the skin of normal human subjects. The author concludes that MCs are merely connective-tissue cells which have phagocytosed metachromatic granules.

Frick B62,124/50: Heparin i.p. increases the number and granularity of the mesenteric MCs in the mouse.

Hissard et al. B90,449/51: Intradermal injection of heparin in the guinea-pig and man results in the local appearance of cells containing granules which stain metachromatically with toluidine blue. It is concluded that MCs can be formed from fibroblasts. [It would be difficult to prove, however, that these cells actually correspond to true MCs rather than to phagocytes which have ingested metachromatic material (*H.S.*).]

Devitt & Samuels D26,863/53; *Devitt et al.* B96,691/54: Repeated s.c. injections of large doses of heparin failed to alter the morphology of the MCs in various organs of the rat.

Constantinides & Rutherdale C2,644/54: Daily treatment with heparin failed to influence the cardiac MC population of the rat.

Paschoud D26,812/54: Repeated s.c. injections of heparin or glucosamine (unlike glucuronic acid and NaCl solutions), cause dark pigmentation with melanophore formation and the appearance of MC-like cells with metachromatic granules, both in the gray rabbit and in man. In the rabbit, heparin and glucosamine also produce a local blackening of the hair. It is concluded that presumably the glucosamine and not the glucuronic-acid component of heparin is responsible for these changes and that glucosamine plays a role both in the formation of MCs and in melanin formation.

Isidor D30,595/54: If heparin is applied to skin wounds of guinea-pigs, many cells accumulate granules which stain metachromatically with toluidine blue. However, these granules, unlike those of true MCs, are dissolved by heparinase. Presumably, in the MC, heparin is bound to a substrate (perhaps a protein) which protects it against this enzyme.

Baglioni C16,539/54: Discussion.

Braun-Falco D26,884/55: Heparin (in Tyrode solution) i.p. causes no significant change in the mesenteric MCs of the rat. If the same solution is injected s.c. there is some MC-discharge associated with a considerable increase in the metachromatic staining but not in the PAS affinity of the adjacent connective tissue.

Wöringer D26,819/55: Repeated s.c. injections of heparin do not tend to produce local hyperpigmentation in normal man but they sometimes do so in urticaria pigmentosa.

Barbry & Langeron D26,835/55: Following s.c. injection of lethal or sublethal doses of heparin, the number of MCs in the skin and skeletal musculature of the mouse diminishes considerably and the granules become less tingible.

Constantinides & Rutherdale C56,628/57: Heparin causes no change in the cardiac MC count of the rat.

Villavicencio & de Takats C56,397/58: Heparin increases the granularity of the mesenteric MCs in the rat. ACTH discharges the granules from these heparinized cells.

Asboe-Hansen & Glick C56,235/58: In vitro, rat MCs disintegrate upon treatment with heparin.

Velican & Velican D43,694/58: Following instillation of heparin into the trachea of guinea-pigs, numerous fibroblasts in the RES cells of the lungs phagocytose the metachromatic material and are transformed into "experimental mastocytes." Some of the intracellular heparin is allegedly transformed into hyaluronic acid.

Hill & Pospíšil D26,881/60: Heparin s.c. causes swelling of granules and formation of metachromatically staining vacuoles in the peritoneal MCs of the rat.

Csaba et al. D2,229/60; D2,227/60; D2,228/60: Tissue cultures of rat thymus form MCs under the influence of heat-treated (non-metachromatic, but PAS-positive) heparin. Similarly treated explants of other tissues do not respond in this manner. In vivo, heat-treated heparin injected into the thymus causes no MC formation.

Csaba & Kapa D63,190/60: Following addition of decomposed heparin to tissue cultures of various organs, thymus and, to a lesser extent, lymph-node and splenic cells are found to take up granules which assume metachromatic properties.

Loomis D63,173/61: "Experiments indicating that injected heparin S^{35} appears in the granules of peritoneal mast cells of the rat suggest that the mast cells may function as a storage depot for administered heparin."

Lindner D12,409/61: Following heparin injection into connective tissue, there is a topical increase in "mastocytoid" cells, presumably phagocytes, which after ingestion of

heparin assume an MC-like appearance. It is postulated that MCs may arise normally through the ingestion of polysaccharides.

Pyziol D25,216/62: In the local MCs of the mouse, heparin s.c. causes hypertrophy, increased granule density and granule discharge. "It seems that the heparin injected is stored in the mast cells." [The photographs show mainly disrupted "MCs", surrounded by numerous free granules (*H.S.*).]

Velican & Velican D34,404/62: Intratracheal instillation of heparin, histamine, or silica induces an "experimental mastocytogenesis" in that pulmonary phagocytes ingest metachromatic granules.

Burton D58,284/63: The ingestion of heparin granules by rat peritoneal MCs in vitro can be followed cinematographically.

Räsänen D33,740/62; D33,739/62; E22,623/63: Heparin i.p. causes no change in the gastric MCs of the rat nor does it influence MC destruction by ACTH i.m.

Cronberg & Nilsson G10,504/64: Heparin i.p. does not cause degranulation of rat peritoneal MCs.

Heparin plus other agents

Dragstedt et al. A55,982/42: Heparin inhibits the release of histamine from cells (MCs not particularly mentioned) during anaphylactic shock in the rabbit.

Higginbotham & Dougherty C21,716/56: Heparin i.v. and 48/80 s.c. elicit a local accumulation of numerous cells with metachromatic granules. When heparin and 48/80 are mixed, a complex is formed which, when injected s.c., produces quasi-MCs owing to the phagocytosis of the heparin-48/80 complex by fibroblasts. "The binding of the toxic phenyl alkylamine, 48/80, by heparin and its sequestration in granular form by fibroblasts of the tissue has been presented as a model of this local detoxifying response of the loose connective tissue."

Lindner E25,941/63: Following percutaneous application of heparin, MC-like elements develop in the skin of the rat as a consequence of heparin phagocytosis by mesenchymal cells.

Thompson et al. E39,861/63: 48/80 and many other gastric secretory stimulants (except exogenous histamine) caused degranulation of the gastric MCs. This degranulation and loss of gastric MCs was prevented by heparin i.v., which also inhibits the secretagogue effect. It is postulated that the local MCs may be responsible for gastric secretion.

Selye & Tuchweber G11,117/65: In rats pretreated with a single i.v. injection of lead acetate, topical connective-tissue calcification is produced at sites where minute doses of various MC-dischargers or MC-products (5-HT, histamine) are injected s.c. Heparin was ineffective at comparably low dose levels.

HEPTAMETHYLENE DIAMINE

Riley B90,276/53: Heptamethylene diamine hydrochloride i.v., in lethal or sublethal doses (or when applied in vitro to preparations of the mesentery), degranulates the MCs of the rat.

HEXADIMETHRINE

Kimura et al. C94,625/59: Hexadimethrine bromide (an antiheparin agent) is even more effective than protamine in causing disruption of mesenteric MCs in the rat both in vivo and in vitro.

Kimura et al. D33,717/61: Hexadimethrine bromide causes MC disruption both in vitro and in vivo in the rat. Animals partially depleted of their histamine and 5–HT by pretreatment with 48/80 became less sensitive to the toxic effects of hexadimethrine. It is thought that some of the toxic effects of hexadimethrine may be mediated through the release of histamine, 5–HT, and heparin.

Young & Kimura G6,599/62: Hexadimethrine (route of administration not stated) causes degranulation of rat mesenteric MCs.

Kimura et al. D36,398/62: Hexadimethrine causes the degranulation of mouse mesenteric MCs in vitro. "Polymers of average molecular weight as well as dialysates of several such

polymers were used in these studies. Results showed (a) that there is a definite trend for the toxicity of hexadimethrine to increase concomitantly with an increase in average polymer size, (b) that both intravenous toxicity and effects on mast cells are interrelated through the average molecular size of the samples used, and (c) that dialysis can fractionate the average molecular weight polymers into their components of varying toxicity without appreciable loss of antiheparin potency."

Tuchweber et al. D27,884/63: In the rat, hexadimethrine i.v. produces an anaphylactoid reaction which is characterized by a predominant swelling of the snout with little or no change in the other anaphylactoid shock organs. The localization of the response is presumably due to a selective effect of hexadimethrine on the MCs of the snout.

Dieudonné E24,128/64: In rats, cyproheptadine (which prevents the topical calcification normally produced by various MC-depletors such as 48/80, polymyxin, stilbamidine, or pentamidine) actually aggravates the local calcification induced by hexadimethrine, another MC-depletor.

HISTAMINE

Törö D33,638/42: If histamine is applied to the shaved skin of the rat, there is first a local storage of carbon particles in the endothelium of the small vessels, later the ink granules are taken up by the pericytes. The regional MCs "first disappear and later reappear without granules. Sometimes they are laden with India ink. Since, in the rat, the mastocytes form a perivascular sheath and undergo pronounced changes they may play an important role in vascular function. We did not succeed in obtaining a clear picture of this process."

Horváth D27,703/52: In-vitro exposure of rat connective tissue to histamine abolishes the metachromatic-staining ability of the MCs and if these had been previously stained metachromatically with toluidine blue, they change color and become orthochromatic. Presumably histamine liberates toluidine from its combination with heparin.

Bensley D26,489/52: Histamine increases the number of MCs so rapidly that the effect cannot be ascribed solely to mitosis. Many typical MCs are formed from "small, round cells in the connective tissue" and typical MC-granules appear in fibroblasts and endothelial cells. [In this short abstract neither the animal species nor the site of histamine injection are specified (*H.S.*).]

Riley B90,276/53: Only extremely high doses of histamine i.v. cause MC disruption in the rat and even then only in areas of vasodilatation and tissue edema. Mast cell degranulation is much more readily obtained when histamine is directly applied to fresh mesenteric tissue spreads. Presumably in both instances it is through the production of edema that histamine acts upon MCs.

Constantinides & Rutherdale C2,644/54: Daily treatment with histamine fails to influence the cardiac MC population of the rat.

Braun-Falco D26,884/55: Histamine i.p. or s.c. causes no significant change in the local MC population of the rat.

Arvy D65,694/55; C41,778/56: Injection of histamine into the base of the tongue causes no change in the local MCs of *Rana esculenta.*

Wegelius et al. D27,732/55: Injection of histamine into the cheek pouch of the hamster in doses conducive to mild shock causes no degranulation of the local MCs.

Antalóczy D26,874/55: Histamine applied by iontophoresis to the skin of rats causes disappearance of the topical MCs.

Asboe-Hansen & Wegelius C29,324/56; *Asboe-Hansen* C77,655/57: Histamine produces MC discharge in the cheek pouch of the hamster quite comparable to that obtained by histamine liberators.

Rowley & Benditt C15,372/56: Injection of histamine into the rat's paw causes intense local edema without MC discharge.

Higginbotham et al. D15,838/56: Topical injection of histamine causes degranulation of the cutaneous MCs of the mouse.

Löfgren E61,351/56: Histamine (embedded in beeswax) caused no significant change in the pulmonary MCs of the guinea pig.

Keller C54,750/57: Histamine i.v. causes no degranulation of the peritoneal MCs in the rat.

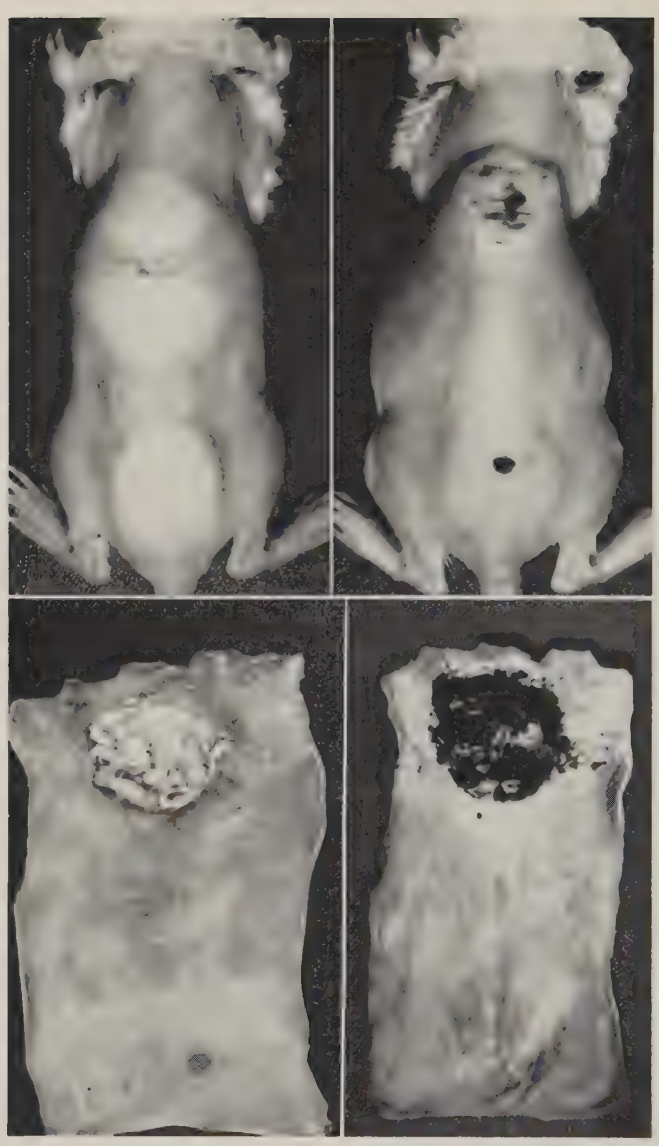

Figure 15.—Topical resistance to mastocalcergy. (*Top left*) Shaved skin of a lead acetate pretreated rat which received two equal injections of polymyxin, the cranial site being pretreated by crushing with a hemostat. Calcified wheals are detectable at both sites but the cranial one shows a bridge of normal skin corresponding to the hemostat crush. (*Top right*) Another, similarly pretreated rat which also received two equal injections of polymyxin (at the sites indicated by the black grease pencil marks). At the unpretreated cranial point, a large calcium deposit raises the skin surface. The superficial scratch marks were inflicted upon the apparently itchy skin by the rat itself. The caudal point was pretreated with polymyxin which offered complete protection. (*Bottom left*) Subcutaneous aspect of the reflected skin of the rat shown in the previous picture. Here, the large mineral deposit at the cranial injection site is even more distinctly visible, while the pretreated caudal site (indicated by the grease pencil mark which shines

Constantinides & Rutherdale C56,628/57: Histamine causes no change in the cardiac MC count of the rat.

Fontanini et al. D39,752/58: 50–500 μg. of histamine i.p., i.v., or i.m. cause moderate degranulation of the rat mesenteric MCs.

Asboe-Hansen & Glick C56,235/58: Histamine appears not to affect rat MCs in vitro.

Klaus & Winkelmann C80,962/59: Following histamine i.p., the cutaneous MCs of the rat show moderate degranulation and no loss of stainability with night blue.

Jamieson & van den Brenk D8,004/61: Even large doses of histamine i.p. cause no disruption of the peritoneal MCs in the rat.

Glick & Pothapragada D2,215/61: Histamine s.c. does not influence the succinic dehydrogenase activity of rat peritoneal MCs.

Postnov & Nikolaeva G1,181/63: Following repeated s.c. histamine administration, the MCs disappear from the injection site in the rat. At the same time, there is coalescence of granules with a change in their tinctorial properties throughout the organism.

Furano & Green G4,979/64: The peritoneal MCs of the rat take up histamine and 5–HT both in vivo and in vitro but they do not attract 3-hydroxytyramine or noradrenaline.

Cronberg & Nilsson G10,504/64: Histamine i.p. does not cause degranulation of rat peritoneal MCs.

Postnov et al. D60,610/64: Chronic treatment with large doses of histamine s.c. causes degranulation and loss of metachromasia in the connective-tissue MCs of the rat.

Selye et al. E24,139/64: In rats sensitized for *mastocalciphylaxis* by DHT p.o. and $FeCl_3$ i.v., histamine s.c. produces local calcification (*Fig. 12, p. 179; Plates II* and *III*).

Selye et al. G11,112/65: In rats pretreated with lead acetate i.v., histamine s.c. produces calcification not only locally but also in the autonomic nerves. 5–HT or acetylcholine cannot substitute for histamine in the production of this *"neurotropic calcergy."* However, since similar results have been obtained with various MC-dischargers, it appears that adequate amounts of endogenous MC products can be liberated to produce this response (*Figs. 16* and *17, pp. 190, 192*).

Selye et al. G11,123/64: In rats, *"neurotropic calcergy"* produced by lead acetate i.v. and histamine s.c., can be *inhibited* by pretreatment with various MC-dischargers (48/80, polymyxin, chlorpromazine), MC components (histamine, 5–HT), or drugs known to inhibit the pharmacologic actions of such MC components (cyproheptadine, neo-antergan). The prophylactic effect appears to be largely specific to compounds related to MC activity since it was not shared by various other drugs and stressors tested (*Fig. 18, p. 194*).

Selye et al. G11,121/64; G11,118/65: In rats pretreated with lead acetate i.v., the *topical* connective-tissue calcification produced by minute doses of various MC components (histamine, 5–HT) or MC-dischargers (48/80, polymyxin) can be *inhibited* by systemic or topical pretreatment with large doses of any one among these compounds (*Fig. 15, p. 188*).

Selye et al. G11,122/65: After the induction of calcergic reactivity by lead acetate i.v. *systemic* treatment with various MC-dischargers (e.g., 48/80, polymyxin, stilbamidine, dextran, dextrin) and MC products (5–HT, histamine) produce essentially distinct patterns of calcification in the rat. The preferential deposition of calcium in one or the other organ is ascribed to selective MC degranulation with consequent mastocalcergy induced by different compounds in different regions.

Selye & Tuchweber G11,117/65: In rats pretreated with a single i.v. injection of lead acetate, topical mastocalcergy is produced at sites where minute doses of various MC-dischargers (polymyxin, 48/80, viomycin, stilbamidine, trypsin) or MC products (5–HT, histamine) are injected s.c. Histochemical studies showed that polymyxin and 48/80 first produce MC discharge, followed by calcium incrustation of the metachromatic granules, while 5–HT and histamine cause no MC discharge at comparable dose levels, but produce a fine precipitate of calcium salts in and around the connective-tissue fibers at the injection site.

---

through the skin) is free of calcification. (*Bottom right*) Same skin specimen after fixation and staining with the von Kóssa technique. The mineral deposit became black, as is characteristic for calcium salts. [After *Selye et al.* G11,121/64. Courtesy *Journal of Pharmacology and Experimental Therapeutics.*]

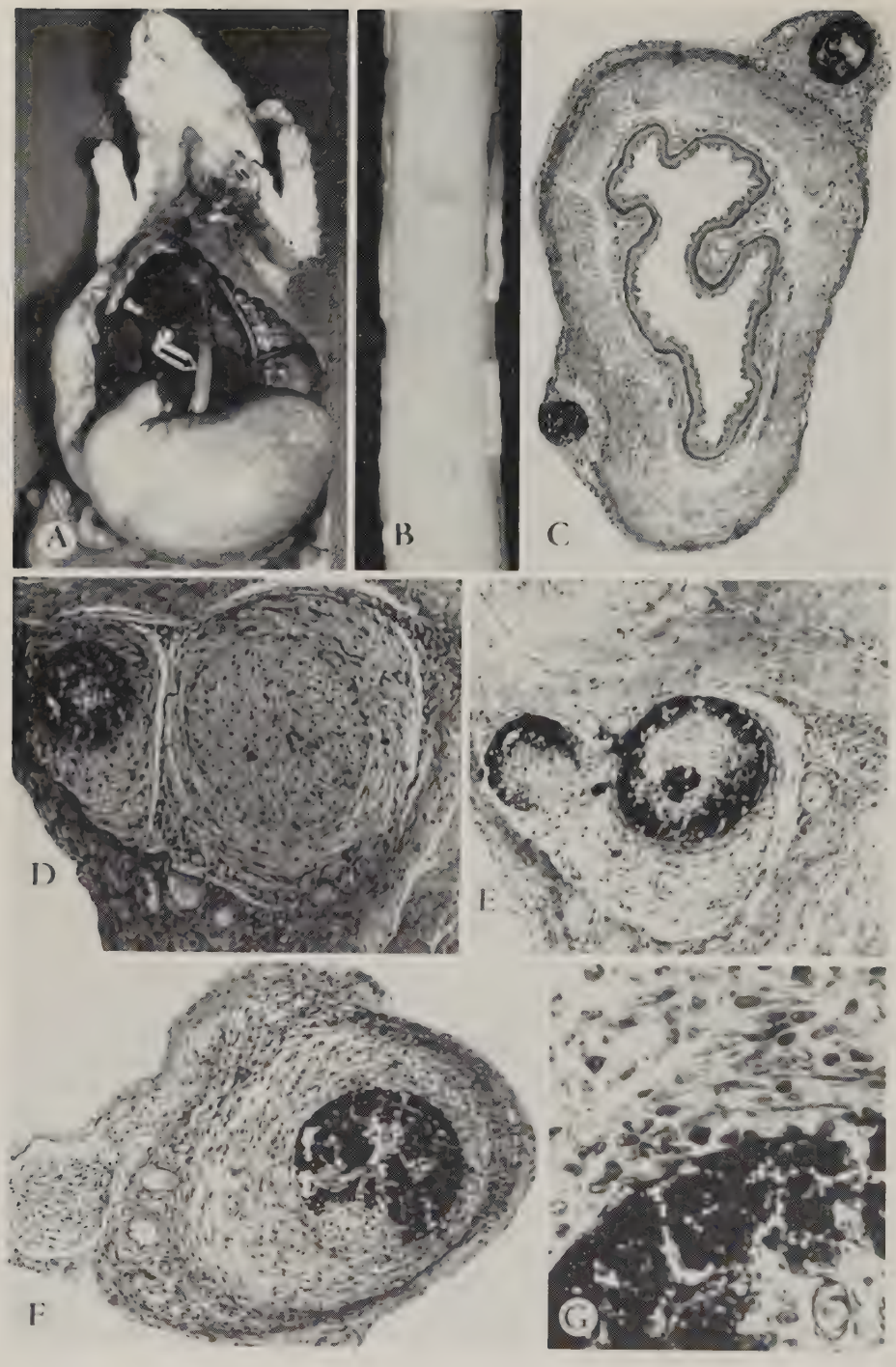

Figure 16.—Calcification of the vagus induced by lead acetate i.v. + histamine s.c. (*A*) Paralytic dilatation of the stomach owing to destruction of the vagi. White calcified nodules are detectable (*arrow*) in the left vagus as it descends

Histamine-releasers and liberators

Cf. also POLYMYXIN, STILBAMIDINE, COMPOUND 48/80, DEXTRAN, DEXTRIN, WATER, POLYVINYLPYRROLIDONE, SINOMENINE, PENTAMIDINE, VIOMYCIN, OVALBUMEN, FERRIC DEXTRAN, THORIUM DEXTRIN, FERRIC DEXTRIN, etc.

Reviews: *Baglioni* C16,539/54; *Riley* C9,303/55; *Kelsall & Crabb* D26,076/59; *Macaluso & Pasqualino* D5,225/60; *Raab* D68,111/63

Generalities

Riley B90,276/53: When injected i.v., in lethal or sublethal doses, or when applied in vitro to preparations of the mesentery, stilbamidine, 2-hydroxy-stilbamidine, propamidine, pentamidine, heptamethylene diamine hydrochloride, decamethylene diamine hydrochloride, d-tubocurarine chloride and peptone, all caused degranulation of the MCs in the rat. The Riley "Type II" MCs of the peritoneum (which are filled with discrete metachromatic granules and line the capillaries, or lie free in tissue spaces) are particularly sensitive.

Norton & de Beer D30,591/55: Degranulation of MCs in the rat mesentery occurs in vitro upon application of polymyxin in concentrations equal to those of 48/80. Aureomycin was much less effective while bacitracin, penicillin, achromycin, and sulfanilamide were ineffective. Cyclizine actually inhibits the MC-degranulating effect of polymyxin, 48/80, and hypotonic solutions.

Paton D30,564/56: There exists a "group of bases known as histamine liberators, a name that serves usefully to distinguish them within the general class of histamine releasers." The various types of histamine-releasing agents are classified into seven groups as follows: "1. *Sensitizing Compounds:* antigens, reagents with proteins forming antigens. 2. *Compounds Damaging Tissues:* venoms, toxins, traumatic agents. 3. *Proteolytic Enzymes:* trypsin. 4. *Surface-active Agents:* tween 20, bile salts. 5. *Large Molecules:* egg white, dextran, P.V.P., horse serum, 'anaphylatoxin'. 6. *Histamine Liberators:* dibasic and polybasic compounds, compound 48/80. 7. *Monobasic Compounds:* alkylamines, antihistamines, Q.P.E."

Smith C54,403/58: In the rat, i.p. injections of such histamine-liberators as stilbamidine, d-tubocurarine, 48/80, and distilled water cause mesenteric MC disruption simultaneously with histamine discharge; toluidine blue or protamine sulfate i.p. can cause a similar histamine discharge without any microscopically-visible change in the mesenteric MCs. Repeated injections of the latter substances (at intervals of from 20 minutes to 24 hours) result in repeated histamine discharges which are still unaccompanied by morphologic evidence of MC-disruption. "It is concluded that secretion by the mast cell does not require cell disruption and death, as much of the literature indicates, but is merocrine in nature."

West C64,139/58: Fluorescent MC-dischargers are actually concentrated within the MC.

Paton D39,576/58: The histamine-releasers (which in general are also MC-degranulators) are subdivided as follows:

(1) Antigens causing anaphylactic and allergic reactions, which act only after sensitization.

(2) A wide range of toxins, venoms, and proteolytic enzymes, which cause profound tissue damage.

(3) A group of large-molecular-weight materials such as dextran, ovalbumen, P.V.P., horse serum, anaphylotoxin.

---

along the ventral wall of the esophagus. (*B*) Loupe magnification of the esophagus flanked by two vagi whose course is interrupted by heavy white calcium deposits. (*C*) Horizontal section through the esophagus with heavy calcification (black) in both vagi. (von Kóssa, X 32.) (*D, E, F*) Horizontal sections through closely adjacent levels of a bifurcation in the left vagus, just above the diaphragm. Intensity of calcium deposition varies in the main trunk and the branch, at different levels. Intense thickening and inflammation of perineurium with disintegration of the nerve fibers is evident even where calcification is lacking. (von Kóssa, X 96.) (*G*) Higher magnification of upper edge of calcified vagus shown in *F*. Inflammation of epineurium around calcified nerve fibers. (von Kóssa, X 368.) [After *Selye et al.* G11,112/64. Courtesy *Neurology*.]

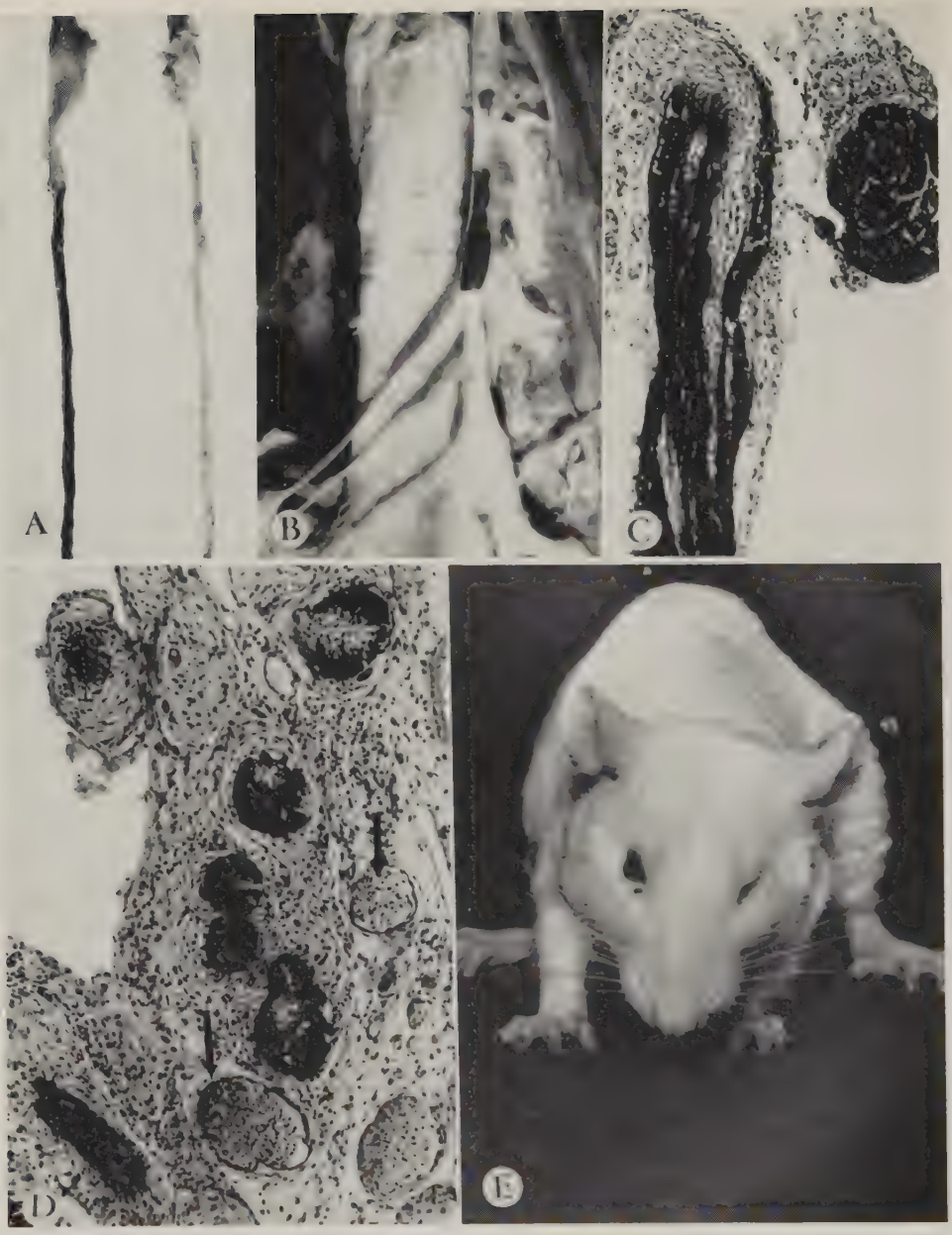

Figure 17.—Calcification in sympathetic nerves induced by lead acetate i.v. + histamine s.c. (*A*) Heavy calcification (black) of cervical sympathetic stops sharply at borderline between nerve and superior cervical sympathetic ganglion. The cervical portion of the vagus with the ganglion nodosum (*right*) is not calcified (loupe magnification of defatted specimen stained in toto with the von Kossa technique). (*B*) Origin of left greater splanchnic just above the diaphragm. The nerve fibers are reflected to the right for better visualization against the aorta as a background. One small and one large calcified (black) region in thoracic sympathetic trunk just above origin of splanchnic branches (defatted specimen

(4) Surface-active materials such as lysolecithin, tween 20, bile salts, whose strong interfacial activity makes it probable that they function chiefly by lysing some limiting cell membrane.

(5) Comparatively simple monobasic compounds of which octylamine may be taken as a prototype.

(6) Histamine-liberators which differ from the previously listed histamine-releasers in that (*a*) they act the first time they are administered (unlike antigens); (*b*) they do not cause major tissue damage; (*c*) their potency is approximately uniform when tested on various tissues of diverse species, thus suggesting some consistent mode of action; (*d*) in the case of the most specific members of this group, histamine release appears to be the only detectable action, and if they are tested again after a pronounced release has taken place, their physiologic effects become steadily smaller; (*e*) they act very promptly at small dose levels in the whole animal after administration, although the skin appears to be their major target.

Colosi D30,552/60: The addition of an antihistaminic to the medium of rat lung tissue maintained in rotating tubes, "appears to increase the number of subpleural mastocytes."

HISTONE

Yamura D39,162/61: Histone releases histamine from rat peritoneal MCs in vitro. In the guinea-pig, histone produces an anaphylactoid reaction (emphysema, itching). Hence, it is assumed that tissue injury can activate proteases which attack the lipoproteins of cell membranes and release histone; the latter attacks the MCs and, in turn, releases histamine from them.

HYALURONIC ACID

Wegelius & Asboe-Hansen C29,551/56; *Asboe-Hansen* C77,655/57: Topical application of hyaluronic acid causes little or no change in the MCs of the hamster cheek-pouch.

Asboe-Hansen & Glick C56,235/58: Hyaluronic acid does not appear to affect rat MCs in vitro.

Calzavara et al. D10,222/60: The peritoneal MC degranulation (associated with amitosis) that occurs following X-irradiation in the rat, is inhibited by pretreatment with hyaluronic acid and an antihistaminic (Fargan).

HYDRALAZINE

Selye & Bois C23,958/57: Hydralazine daily s.c. produces an anaphylactoid inflammation in the rat, but the MCs have not been studied.

HYDRAZINE

Takeoka et al. D39,931/62: Hydrazine sulfate produced a significant increase in the MCs of the mesenteric lymph nodes in the rat.

5-HYDROXYTRYPTAMINE (5–HT, SEROTONIN)

Rowley & Benditt C15,372/56: Minute amounts of 5–HT suffice to produce local edema of the rat's paw (similar to that elicited by MC-dischargers) yet the MCs remain intact.

Asboe-Hansen & Wegelius C25,969/56: In the hamster, 5–HT i.p. produces pronounced degranulation of the MCs and a typical anaphylactoid inflammation with cyanosis of the snout and paws.

Selye & Bois C23,958/57: Repeated injections of 5–HT s.c. in the rat cause an anaphylactoid inflammation which differs from the classical form (induced by ovalbumen or

---

stained in toto by von Kóssa technique). (*C*) Calcium deposition in two sympathetic nerves of celiac plexus, one sectioned longitudinally, the other transversally. (von Kóssa, X 96.) (*D*) Section through celiac plexus. Most of the nerves show calcification in endoneurium but in two branches (*arrows*) calcification is limited to the perineurium (von Kóssa, X 96.) (*E*) Ptosis and enophthalmos of the left eye as part of the Claude Bernard-Horner syndrome, due to (exceptional) unilateral calcification of the cervical sympathetic. [After *Selye et al.* G11,112/64. Courtesy *Neurology*.]

Figure 18.—Calcification in sympathetic nerves induced by lead acetate i.v. + histamine s.c. (*Top*) Fresh preparation showing white calcium deposits in both vagi (*arrows*) to the right and left of the esophagus near the cardia. The stomach is reflected to the right to show the connecting branch which originates from the left vagus (*lower arrow*) and joins the celiac plexus (right side of picture). The celiac ganglion itself is not calcified but the branches emerging from it are so heavily mineralized that many of them broke during the process of dissection. (*Bottom*) Same preparation after fixation, defatting and staining with the von Kóssa procedure for the demonstration of calcium salts. There is perfect agreement between the white segments in the top

dextran) in that it takes several days to develop, consists more of hyperemia than of edema, affects the paws more than the snout, and is frequently associated with gastric ulcers. This response is even more pronounced in adrenalectomized animals maintained on DOC but almost absent in those maintained on cortisol. One mg per day of 5–HT suffices to elicit the anaphylactoid inflammation but gastric ulcers are more evident with higher doses. Single doses of up to 32 mg per 100 g body weight are tolerated.

Keller C54,750/57: 5–HT i.v. causes no degranulation of the peritoneal MCs in the rat.

Asboe-Hansen C77,655/57: 5–HT causes degranulation of the cheek-pouch MCs in the hamster.

Asboe-Hansen & Glick C56,235/58: Upon treatment with 5–HT, rat MCs suspended in vitro show loss of metachromasia and clumping of granules but no degranulation or disintegration.

Fiore-Donati & Moltke C88,372/60: 5–HT causes a significant decrease in the tensile strength of linear cutaneous wounds in the rat. No concomitant change was noted in the cutaneous MCs.

Bray & Van Arsdel D26,900/61: The isolated peritoneal MCs of the rat discharge their histamine under the influence of 5–HT.

Jamieson & van den Brenk D8,004/61: Even large doses of 5–HT i.p. cause no disruption of the peritoneal MCs in the rat.

Glick & Pothapragada D2,215/61: 5–HT s.c. does not influence the succinic dehydrogenase activity of rat peritoneal MCs.

Haverback et al. D34,580/62: Brief abstract stating that in the rat "increasing serotonin levels by 5-hydroxytryptophan produced no change in gastrointestinal, brain, or mast cell histamine." [No other details were given concerning this point, hence it is difficult to evaluate it (*H.S.*).]

Tuffanelli E28,359/63: Repeated intradermal injection of 5–HT produces an initial MC accumulation at the injection site in hairless mice. Later, exulceration follows.

Rowley D69,169/63: 5–HT injected into the paws produced severe local edema, but no MC-degranulation in the rat. Yet, the vascular injury produced by 5–HT appeared to be the same as that caused by thorium dextrin (Thorotrast) which does discharge the MCs.

Cronberg & Nilsson G10,504/64: 5–HT i.p. does not cause degranulation of rat peritoneal MCs.

Furano & Green G4,979/64: The peritoneal MCs of the rat take up histamine and 5–HT both in vivo and in vitro but they do not take up 3-hydroxytyramine or noradrenaline.

Selye et al. E24,139/64: In rats sensitized for mastocalciphylaxis by DHT p.o. and $FeCl_3$ i.v., injection of 5–HT s.c. produces local calcification. (Apparently, here, the effect of an MC-product is the same as that of an MC-discharger) (*Fig. 12, p. 179; Plates II* and *III.*)

Selye et al. E24,102/64: In young rats calciphylactically sensitized with parathyroid hormone, systemic treatment with 5–HT produces calcification of the salivary gland, while in old animals it induces necrosis of the skeletal musculature. It remains to be seen to what extent MCs participate in these responses.

Selye et al. G11,121/64: In rats pretreated with lead acetate i.v., *topical* connective-tissue calcification is produced by minute doses of various MC components (histamine, 5–HT) or MC-dischargers (48/80, polymyxin) as a consequence of mastocalcergy. This response can be *inhibited by topical* pretreatment with any among the substances just mentioned (*Fig. 12, p. 188*).

Selye & Tuchweber G11,117/65: In rats pretreated with lead acetate i.v., *topical* connective-tissue calcification is produced at sites where minute doses of various MC-dischargers (polymyxin, 48/80, viomycin, stilbamidine, trypsin) or MC products (5–HT, histamine) are injected s.c. Histochemical studies showed that polymyxin and 48/80 first produce MC-discharge, followed by calcium incrustation of the metachromatic granules, while 5–HT and histamine cause no MC discharge at comparable dose levels, but produce a fine precipitate of calcium salts in and around the connective-tissue fibers at the injection sites.

Selye et al. G11,118/65: In rats pretreated with lead acetate i.v., the *topical* connective-tissue calcification produced by minute doses of various MC components (histamine, 5–HT)

---

picture and the black areas of reduced silver nitrate which, here offer histochemical proof of calcification. [After *Selye et al.* G11,123/64. Courtesy *Experimental Neurology*.]

or MC-dischargers (48/80, polymyxin) can be *inhibited by systemic* treatment with large doses of any one among these compounds. Adrenaline, another biogenic amine, exerts a similar protective effect although it does not produce mastocalcergy at any dose level.

Selye et al. G11,122/65: After the induction of calcergic reactivity by lead acetate i.v., *systemic* treatment with various MC-dischargers (e.g., 48/80, polymyxin, stilbamidine, dextran, dextrin) and MC products (5–HT, histamine) produces essentially distinct patterns of calcification in the rat. The preferential deposition of calcium in one or the other organ is ascribed to selective MC-degranulation with consequent mastocalcergy induced by different compounds in different regions.

INULIN

Lindner D63,794/54: Following s.c. injection of hexose polysaccharides (glycogen, inulin, dextran), numerous MCs appear in the regional lymph nodes of the rat. Paper-chromatographic studies suggest that the injected polysaccharides are metabolized and transformed into MC granules.

INVERTEBRATE AND PLANT TOXINS

Bäumer D27,593/1896: The author kept a patch of skin on his forearm in continuous edema by repeated exposure to stinging nettles (*Urtica urens*) and, upon excision, found an increase in the local MC population. He concluded that the MCs are formed from fibroblasts by the ingestion of "excess nutrients" that accumulate in edema fluid.

Kreibich D27,585/16: Upon rubbing the rabbit's ear with stinging nettles, metachromatic MC granules are allegedly formed from the nuclear material of MCs.

Högberg et al. D26,423/56–57: Extracts from stinging jellyfish (*Cyanea capillata*) and the eelworm of swine (*Ascaris lumbricoides*), like 48/80, are highly effective both in causing disruption of mesenteric rat MCs in vitro and in inducing a histamine discharge from the perfused cat's paw. An extract from hip seed blocks both the MC-disrupting and the histamine-liberating effects of all these compounds.

Högberg & Uvnäs D26,477/58: Allicin (an enzyme-inhibitor from garlic) prevents the degranulation of rat peritoneal MCs which is otherwise produced by 48/80, ascaris extract, antigen-antibody reaction, or lecithinase A. Glutathione in excess reverses this blockade of degranulation.

Riley D27,438/58: α-Toxin of *Cl. welchii,* purified bee venom and its heat-stable, non-enzymatic derivative, Melittin, as well as the powerful lecithinase which is present in the venom of the Indian cobra (*Naja naja*) "all bring about disruption of mast cells parallel to their ability to attack lecithin."

Uvnäs et al. D26,167/60: A method for the purification of the histamine- and MC-granule-discharging principle of *Ascaris.*

Uvnäs D26,479/60: When the peritoneal MCs of the rat are treated with cyanea extract they release both their histamine and their metachromatic granules. "Similar principles probably occur also in shellfish, strawberries, and other agents known to cause allergic reactions in hypersensitive individuals."

Uvnäs D25,283/61: The liberation of histamine and MC granules by the cyanea principle is inhibited by dinitrophenol and this inhibition is in turn blocked by glucose.

Keller & Oppliger D27,077/61: Bee venom (or phosphatidase-A isolated from bee venom) causes immediate degranulation of human MCs removed from the bronchial tree by suction.

Diamant D26,421/61: In guinea-pigs, ascaris extract i.p. (in doses effective in rats) causes neither histamine nor MC-granule discharge from the mesentery.

Antweiler & Hirsch D26,707/61: Various cotton plant extracts as well as dusts of the cotton industry contain a histamine-liberator which is heat-stable and ultra-filtrable. It causes histamine liberation and MC degranulation in the mesentery of the rat. The effect is not due to endotoxins of bacteria contained in the cotton dust since extracts of cultures of these are ineffective. Furthermore, purified endotoxin from *S. abort. equi* and *E. coli 0111* proved inactive in causing MC degranulation in the rat mesentery. Apparently, the histamine-liberator is bound to some component of the cotton wool itself.

Wells D63,160/62: Rats infested with the nematode worm *Nippostrongylus brasiliensis* exhibit a greatly increased intestinal MC and eosinophil count. "Evidence is produced which suggests that mast cells play a part in cellular reactions to parasitic infection".

Fernex & Fernex D39,820/62: In mice with various experimental helminthic diseases, the cutaneous MC number increases sharply and at the same time there is blood eosinophilia. It is thought that the increased number of the MCs in the connective tissue of Africans (frequently associated with blood eosinophilia) may result from helminthic infections.

Fernex D66,465/62: In the mouse "two months after repeated infestations with *Schistosoma mansoni,* mast cell values were three times higher in the skin of infected mice than in a control series. A similar phenomenon can be observed in man, adult patients with chronic filariasis presenting a mast-cell hyperplasia which can last as long as seven years after healing of filariasis. The mastocytosis commonly observed in Africans, may thus be related to helminthic infections, which are highly endemic in tropical countries."

Takeoka et al. D39,931/62: In rats fed *Crotalaria spectabilis,* a conspicuous increase in MCs occurred both in the lung and in the mediastinal lymph nodes. Purified monocrotaline acted the same way.

Coleman & DeSalva D65,237/63: In infested rats "mast cells have been found in the cyst wall of a larval cestode parasite (*Hydatigena taeniaeformis*)." This proves that the wall of the parasite is derived from the host tissue.

Hausner G14,240/63: Brief preliminary paper on the MC-degranulating power of various plant extracts.

Paplanus & Sheldon E21,614/63: "The effects of the absence of adrenal tissues on the inflammatory reaction and on the relationship of the tissue mast cells to the inflammatory process have been studied histologically in rats with cutaneous Rhizopus oryzae infection. Degranulation and regranulation of the tissue mast cells at the site of injury have been found to correlate respectively with the onset and subsidence of the exudative cellular phase of inflammation."

Fernex G9,088/63: Review of experimental and clinical data, showing that various forms of helminthiasis produce an increase in tissue MCs.

Fernex G10,072/64: There is an increase in cardiac MC density in patients with carcinoid or endomyocardial fibrosis due to helminthiasis. It is assumed that the MCs render the cardiac connective tissue particularly subject to inflammation and connective-tissue proliferation in both these diseases.

LATHYROGENS

Gillman & Hathorn C70,377/58: In rats, in which lathyrism is produced by the feeding of ground sweet-pea (*Lathyrus odoratus*) seeds, the MC count in the bone marrow is greatly increased. It had previously been shown that the blood-clotting time is considerably prolonged in experimental osteolathyrism (*Selye & Bois* C23,297/57) and histochemically-detectable increases in circulating mucopolysaccharides accompany the osseous and vascular lesions. Hence, it is concluded "that widespread disturbances in polysaccharide metabolism prevail in odoratus-intoxicated rats."

Gillman C52,329/58: During the induction of lathyrism by the feeding of sweet peas in the rat, the MC-count in the marrow of the newly-developed lathyric bone increases, while this is not the case in the marrow of the original shaft bone.

Takeoka et al. E20,322/63: "Feeding of BAPN and BMEA to rats produced an increased number of mast cells in the diaphyseal marrow of long bones and spinous processes of the vertebrae. However, the feeding induced no increase in the number of mast cells in the marrow of the epiphyseal ends in long bones and only minimal mast cell stimulation in the vertebral bodies. Mast cells were not observed in the peripheral blood even when there was a conspicuous increase in their numbers in bone marrow. The number of mast cells in the lymph nodes remained within normal limits following BAPN and BMEA feeding."

LEAD

Selye et al. D25,659/63: A widespread osteomyelosclerosis can be produced in the rat by repeated intravenous injections of lead acetate. The response is associated with the appearance of "basophilic bone granules" and numerous MCs in and around the newly formed bone trabeculae (*Figs. 19* and *20*). This is of interest because basophil proliferation also occurs in certain forms of osteomyelosclerosis in man.

LIPIDS

Lombardo D39,600/06: Following s.c. injection of oleic acid or sodium oleate in the cat, the local MCs accumulate lipid granules.

Figure 19.—Gross appearance of the lead-induced osteomyelosclerosis. (*Top left*) Macroscopic aspect of a saggital section through the lower end of the femur of a normal rat (the marrow has been flushed out with water). (*Top right*) Similar section through the femur of a lead-acetate-treated rat. Most of the marrow is replaced by spongy bone except in the epiphysis, the region just below the growth cartilage, and a narrow central canal (*between arrows*) in the midshaft region. (*Bottom left*) Histologic section through the lower end of the femur of a normal rat. (*Bottom right*) Similar

Arnold D29,582/13: The lipid granules of MCs increase "upon administration of various fats and soaps." [Nothing is said about the conditions under which these observations were made (*H.S.*).]

Baglioni C16,539/54, *p. 209*: Discussion.

Speirs C3,414/55: Intraperitoneal injection of "oil" (kind not indicated) induces topical MC discharge both in the intact and in the adrenalectomized mouse.

Fodor & Lojda D65,270/56: Following feeding of fat, the MCs of the rat peritoneum show only minor degrees of degranulation unless protamine i.v. is simultaneously administered. Protamine in itself has little effect. It is assumed that protamine neutralizes the released heparin and, hence, calls for more heparin discharge from MCs to clear the blood of chylomicrones. Such a clearing mechanism may play an important part in the pathogenesis of atherosclerosis.

Hill D26,788/57: Following i.v. injection of an olive-oil emulsion to rats, conglomerates of metachromatic granules are discharged from the mesenteric MCs with subsequent diffuse metachromasia of the surrounding tissue. This phenomenon is thought to be related to the lipid-clearing effect of discharged heparin.

Grunbaum et al. C31,429/57: The MC population in the external ears of rats fed a high lipid diet remains normal despite a considerably raised blood cholesterol.

Shoulders & Meng D27,067/57: Fat emulsions (stabilized with phosphatide and non-ionic detergents) i.p. cause degranulation of the mesenteric MCs and an increase in the histamine content of the peritoneal fluid in the rat. "These studies suggest that some of the reactions to these neutral fat emulsions might be explained by the liberation of histamine and related substances. Further work indicates that the responsible agents might be the phosphatide and non-ionic components of the emulsions."

Engelberg D27,081/58: Fat emulsion (Lipomul) i.v. raises the plasma heparin level in man presumably owing to its destructive action upon the MCs.

Fodor et al. D33,723/58: In rats kept on a high-fat and high-cholesterol diet, the number of mesenteric MCs decreased.

Stolk D39,774/59: In various viviparous toothcarps there was a marked decrease in mesenteric MCs following feeding on high-fat diets.

Stolk D65,681/59: The cardiac MCs of various fishes decrease on high fat diets.

Jennings et al. D26,618/60: Olive oil p.o., in amounts causing intense lipemia, causes no discharge of rat mesenteric MCs as judged by toluidine blue staining or labeling with radioactive sulfur.

Shoulders & Meng D26,886/60: Rats, given large quantities of a lipid emulsion (Lipomul) i.v., show degranulation of the mesenteric MCs and an increase in the histamine content of the peritoneal fluid. "It is suggested that histamine release may play an important role in the development of the occasional 'anaphylactoid' response following intravenous infusion of triglyceride emulsions in patients." [Nothing is said about an anaphylactoid inflammation in the rats in which these experiments were performed and, since 20 ml of lipid emulsion were injected i.p. in each rat, the specificity of the reaction may be questioned. Such large amounts of virtually any unphysiologic solution may cause MC degranulation (*H.S.*).]

Fodor et al. D26,899/60: Rats, fed a diet rich in fat and cholesterol, show rapid diminution of the mesenteric MC population in comparison with controls receiving a low fat diet. However, in chronic experiments, disappearance of mesenteric MCs was seen also in the latter group.

Watson D26,643/61: The myocardial MC population of the rat is not influenced when intense hypercholesterolemia and organ lipidosis are produced by a lipogenic dietary regime. Furthermore, depletion of tissue MCs by 48/80 does not affect recovery from such a state. "The myocardial mast cell is probably not involved in the early stages of vascular lipid infiltration."

Fernex D66,465/62: In the mesentery and myocardium of rats fed an infarct-producing high lipid diet with thiouracil, the number of MCs decreases and at the same time there is

---

section through the same region of a lead-acetate-treated rat. There is a small island of incipient osteomyelosclerosis in the epiphysis (*top arrow*) and, below the level of the horizontal arrow, the marrow in the shaft is replaced by newly-formed spongy bone. (PAS, X 7.) [After *Selye et al.* D25,659/63. Courtesy *Acta haematologica (Basel)*.]

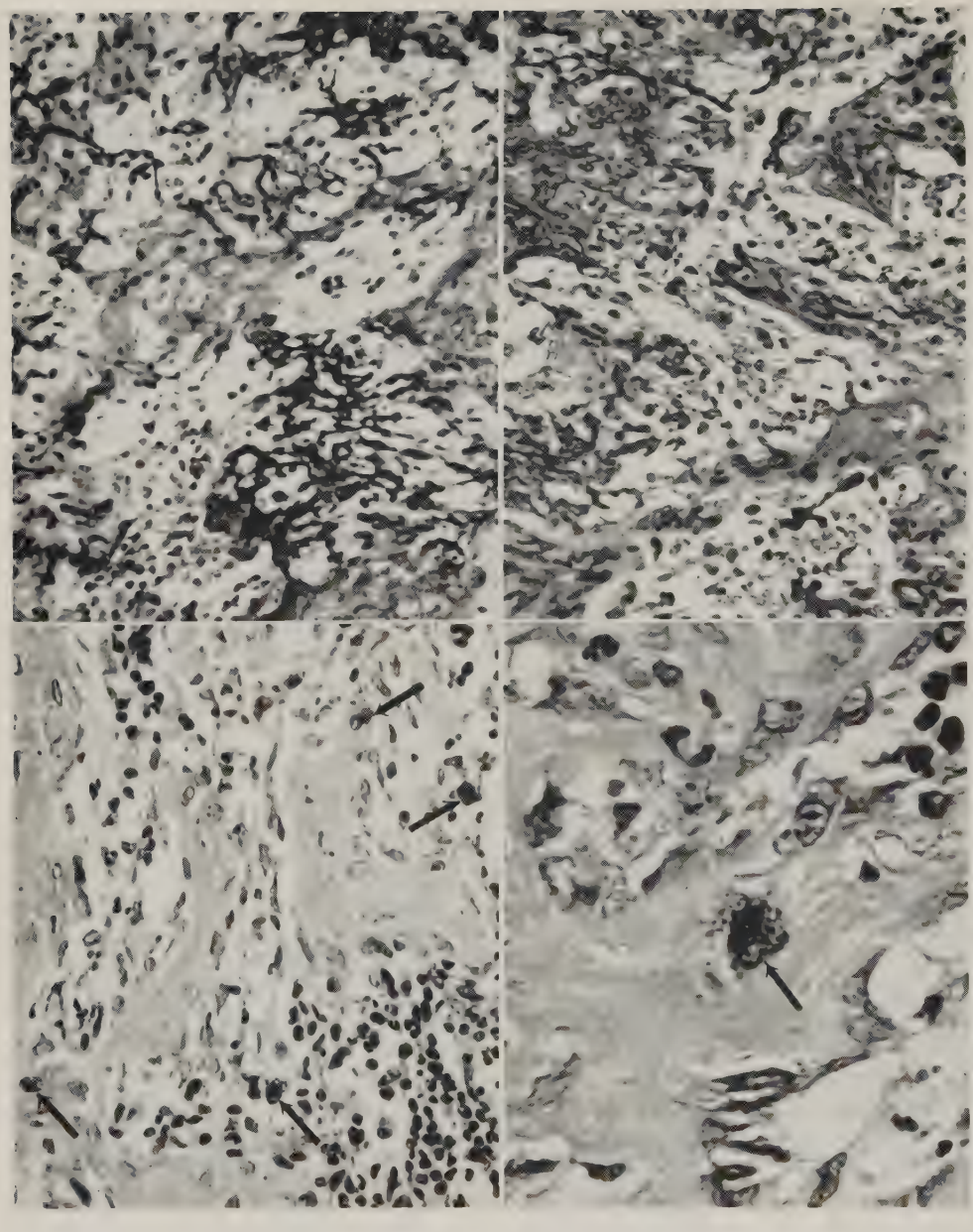

Figure 20.—"Basophilic bone granules" and mast cells in experimental osteomyelosclerosis. (*Top left*) "Basophilic bone granules" frequently arranged in rows within newly-formed spicules. (Bone-granule stain, X 315.) (*Top right*) Here, the bone granules and the rods formed by their coalescence are clearly seen to have a central cavity. (PAS, X 315.) (*Bottom left*) Four typical MCs (*arrows*) which stained metachromatically bright reddish-purple against a blue background. (Cresyl violet, X 315.) (*Bottom right*) Higher magnification of an MC with metachromatic granules within a bone spicule. (Cresyl violet, X 750.) [After *Selye et al.* D25,659/63. Courtesy *Acta haematologica* (*Basel*).]

blood eosinopenia. This observation is thought to give further support to some relationship between eosinophils and MCs.

Petrásek & Fábry D36,095/62: Chronic administration of high fat diets to rats causes a significant decrease in the MC count of the mesentery. This effect is further aggravated by the addition of cholesterol to the diet.

Meng & Westerholm D39,781/63: Various oil emulsions as well as their emulsifiers i.p. cause degranulation of rat mesenteric MCs in vivo, and histamine discharge from isolated peritoneal rat MCs in vitro.

Smith D63,031/63: Discussion.

METHANOL

Devitt et al. B96,691/54: Topical treatment of the rat mesentery with methanol induces swelling and degranulation of the local MCs.

Bray & Van Arsdel D26,900/61: The isolated peritoneal MCs of the rat discharge their histamine under the influence of methanol.

MONOCROTALINE

Takeoka et al. D39,931/62: In rats fed *Crotalaria spectabilis,* a conspicuous increase in MCs occurred both in the lung and in the mediastinal lymph nodes. Purified monocrotaline acted the same way.

MORPHINE

Bhattacharya & Lewis C27,232/56: After morphine i.p., the peritoneal MCs of the rat show much more degranulation than do the subcutaneous MCs.

Parratt & West C37,858/57: In rats, morphine i.p. has but little damaging effect upon tissue MCs (skin, feet, ears, tongue) and releases correspondingly little histamine. However, morphine releases 5–HT from areas of the skin where MCs are scarce and it does not produce an anaphylactoid inflammation.

Jóhannesson & Norn E33,916/63: Upon exposure of rat peritoneal MCs in vitro "morphine was found to be a 300–400 times weaker liberator of histamine than compound 48/80 or polymyxin B".

MUCIN

Meneghini D39,847/50: Repeated intracutaneous injections of heparin or mucin produce MC-like cells at the site of injection in man.

SODIUM SALTS

Cf. anions (e.g., CYANIDES). For NaOH cf. *p*H.

NAPHTHALENE

Sylvén & Larsson D26,612/48: A single application of naphthalene to the skin of the mouse causes topical MC degranulation.

NITROGEN MUSTARD

Schoch & Glick D26,848/53: Within 48 hours following nitrogen mustard i.v., intense cytotoxic degeneration of many cutaneous MCs occurs in the rat.

Ito E57,790/56–57: Following the i.p. injection of the radiomimetic substance Nitromin, the MCs in the popliteal lymph node of the rat disintegrate.

Villavicencio & de Takats C56,397/58: Treatment with nitrogen mustard causes particularly intense MC disruption in the rat mesentery.

OCTYLAMINE

Mota D26,755/59: Following exposure of their lung, ileum, uterus or mesentery to antigen (ovalbumen) in vitro, sensitized guinea-pigs exhibit dissolution and discharge of MC granules. Under similar conditions, octylamine produces morphologically-different changes characterized by an apparent diffusion of metachromatic material from the granules. "The morphological alterations induced by octylamine suggest that this base combines directly with the metachromatic material in the granules, and in doing so produces a complete disorganization

of the granular structure with subsequent histamine release. A similar mechanism of action was postulated by MacIntosh [D27,093/56] based on experiments with intracellular particles." Furthermore, the antigen-induced MC changes occur simultaneously with histamine release and both processes are inhibited by iodoacetate, phenol, lack of calcium, and previous heating or cooling of the tissue. Conversely, the MC changes induced by octylamine, though also accompanied by histamine release, cannot be inhibited by the various inhibitors of anaphylaxis. "It is suggested that most of the histamine released in anaphylaxis comes from the mast cells and that these cells may be concerned with the uptake of antibodies."

Uvnäs D25,283/61: Unlike 48/80 and many other highly-active histamine liberators, simple amines, such as octylamine, liberate histamine non-enzymatically. Perhaps endogenous histamine is simply replaced by the exogenous amine.

Bray & Van Arsdel D26,900/61: The isolated peritoneal MCs of the rat discharge their histamine under the influence of octylamine.

OVALBUMEN AND OVOMUCOID

Ringoen D27,892/23: In the guinea-pig the subcutaneous tissue contains no blood basophils but, following repeated injection of egg white s.c., basophils accumulate at the site of injection concurrently with polymorphonuclear leukocytes and are eventually destroyed. Their relationship to tissue MCs remains in doubt. The egg-white injections cause no blood basophilia but the erythrocytes assume a basophilic punctation and the bone marrow shows increased mast-leukocyte formation.

Webb D27,897/31: Following ovalbumen i.p., the local MCs discharge their granules and regranulation is not completed for several weeks.

Stuart D2,340/51: Ovalbumen i.p. causes "changes" (not characterized) in the peritoneal MCs of the mouse.

Benditt et al. B91,948/54: An anaphylactoid inflammation, produced by ovomucoid i.v., is associated with edema in the acral regions (in which MCs are most plentiful) and MC degranulation. Since ovomucoid releases histamine, it is thought "that ovomucoid may produce its action by damaging mast cells" and that histamine liberation may play a role as a mediator here.

Rowley & Benditt C15,372/56: Injection of ovomucoid into the rat's paw causes intense local edema with MC discharge

Piccaluga D28,533/56: Exposure of alcohol-fixed rat peritoneal MC smears to lysozyme causes a marked diminution of their metachromasia, but ovalbumen and ovomucoid are much less active, or inactive.

Arvy D65,673/56: Following injection of egg white i.p., the MCs tend to disappear in the anaphylactoid shock organs of the rat.

Ito E57,790/56–57: Following ovalbumen i.p. the MCs in the popliteal lymph node of the rat disintegrate.

Parratt & West C56,384/57; *West* C45,485/57: The anaphylactoid inflammation produced in the rat by dextran or ovalbumen is associated with a release of cutaneous 5–HT and histamine. This response is inhibited after depletion of skin 5–HT by reserpine or prolonged pretreatment with 48/80, but it is not prevented after discharge of histamine alone. The reaction is also blocked by pretreatment with anti-5–HT "BOL 148". It is concluded that "the anaphylactoid reaction in rats is mediated chiefly through the release of 5–HT" but the source of this 5–HT is not thought to be in the MCs since these undergo comparatively slight damage during the anaphylactoid inflammation and even when they are depleted of granules (e.g., by intense polymyxin pretreatment) maximal anaphylactoid inflammation can still be produced.

Lagunoff & Benditt D7,116/59: Ovomucoid does not degranulate rat peritoneal MCs isolated on Millipore filter in vitro; hence, its action in vivo may be indirect.

Lagunoff & Benditt D26,708/60: Rat peritoneal MCs isolated on a Millipore filter, release their granules and histamine under the influence of 48/80 or polymyxin but not upon treatment with dextran or ovomucoid. It is concluded that "four agents which in vivo appear to have similar activities have been found by means of in vitro analysis to operate by at least two different mechanisms." [It will be kept in mind, however, that dextran and ovomucoid produce the selectively "acral type" of anaphylactoid inflammation in vivo, while 48/80 and polymyxin cause much more generalized cutaneous responses. Hence, these agents differ in vivo also (*H.S.*).]

Corbascio D27,440/60: In rats, the metachromatic granules of the juxtaglomerular cells are discharged by ovomucoid as are those of the MCs in the cutaneous shock organs.

PARACHLOROMERCURIBENZOATE

Bray & Van Arsdel D26,900/61: The isolated peritoneal MCs of the rat discharge their histamine under the influence of parachloromercuribenzoate.

PENICILLIN

Norton & de Beer D30,591/55: Topical application of penicillin to the rat mesentery in vitro fails to cause MC degranulation.

PENTAMIDINE

Riley B90,276/53: When injected i.v., in lethal or sublethal doses, or when applied in vitro to preparations of the mesentery, pentamidine causes degranulation of the MCs in the rat.

Dieudonné E24,128/64: Cyproheptadine prevents the topical calcification normally produced by pentamidine in the rat.

PEPTONE

Baeckeland & Lecomte D27,995/53; *Lecomte & Baeckeland* B93,844/53: In contradiction of Wilander (D29,595/38), it is claimed that peptone shock causes no discharge of the hepatic MCs in the dog, despite the induction of an increase in blood heparin.

Riley B90,276/53: Peptone i.v., in lethal or sublethal doses, or applied in vitro to the mesentery, causes MC degranulation in the rat.

Baker B84,820/53–54: The degranulation of the peritoneal MCs produced by peptone i.p. in the rat is associated with the appearance of stellate clasmatocytes which may be newly-formed MCs or phagocytes that have ingested MC granules. "Cortisone failed to protect mast cells from loss of granules and also did not modify significantly the uptake of release granules by paravascular clasmatocytes."

Baglioni C16,539/54, *pp. 204, 207:* Discussion.

Mota et al. D26,758/54: In confirmation of Wilander (D29,595/38) and in opposition to Lecomte and Baeckeland (B93,844/53), peptone i.v. was found to cause degranulation of the hepatic MCs in the dog during shock. Simultaneously, there is degranulation of the lingual, splenic, mesenteric, and pulmonary MCs; thus this effect of peptone is by no means limited to the liver. Peptone apparently acts directly upon the MCs because in the tongue, (an organ particularly rich in these cells) intense MC degranulation can be produced selectively by injecting peptone directly into the lingual artery.

Arvy & Quivy D27,966/55; D99,937/55: Witte peptone (a heparin liberator) i.v. induces a sharp drop in the lingual MCs of the dog.

Mota et al. C18,184/56: Peptone i.v. causes a significant reduction in the number of hepatic MCs and a decrease in the metachromasia of the remaining cell granules within the dog liver. Similar but less intense changes are seen in the MCs of other organs. In the tongue, MC degranulation is most easily produced if peptone is injected into the lingual artery. At the same time the histamine content of the liver and tongue diminishes.

Asboe-Hansen & Wegelius C29,324/56: Peptone i.p., i.m., or i.v. causes degranulation and granule clumping in the MCs of the hamster's cheek pouch.

Keller C54,750/57: Peptone i.v. causes degranulation of the peritoneal MCs and increased urinary histamine excretion in the rat.

Yamasaki & Kawamoto D31,596/57: Peptone i.v. disrupts only few cutaneous MCs in the dog although it causes pronounced MC degranulation in the liver.

Keller C62,755/58: Peptone i.v. discharges both histamine and MCs in the peritoneum of the rat; at the same time there is a corresponding increase in the urinary histamine elimination

Hill C64,094/58: Peptone causes vacuolization and degranulation of the omental and mesenteric MCs of the rat.

Archer C78,034/59: Isolated peritoneal MCs of the rat discharge their histamine in vitro when treated with peptone.

Cronberg & Nilsson G10,504/64: Peptone i.p. causes intense degranulation of rat peritoneal MCs.

*p*H

Takeda C60,734/58: Application of 10 per cent NaOH to the skin of mice causes an initial degranulation of the cutaneous MCs with subsequent recovery after the 6th hour.

Scevola D27,705/38: In the rat and guinea-pig, chemical (NaOH, $AgNO_3$) or thermal (thermocautery) burns in the palatopharyngeal region, induce a local accumulation of MCs.

PHENOL

Sylvén & Larsson D26,612/48: A single application of phenol to the skin of the mouse causes topical MC degranulation.

Bray & Van Arsdel D26,900/61: The isolated peritoneal MCs of the rat discharge their histamine under the influence of phenol.

PHENYLBUTAZONE

Antweiler D39,512/62: Phenylbutazone i.p. causes degranulation of the peritoneal MCs and histamine discharge in the rat; it exerts a similar effect when topically applied to the isolated mesentery.

PHLOGOGENS

Cf. also BACTERIAL TOXINS (*p.* 150) and Chapter 7, DISEASES.

Ehrlich D27,092/1879: MCs are numerous in chronically-inflamed tissues of man.

Rosenheim D26,865/1886: The MC population of the connective tissue of peripheral nerves is considerably increased in chronic neuritis and other conditions that cause degenerative changes in the nerves.

Maximow B79,776/04: Following subcutaneous implantation of celloidin capsules, the resulting inflammatory reaction is characterized by the rapid degranulation of the MCs in the rat. In inflammation, the MCs undergo exclusively regressive changes and thereby differ from the clasmatocytes which actively participate in the phagocytosis of debris. The degranulation of MCs continues long after the implantation of the celloidin capsules.

Szécsi D27,413/12: Following tuberculin i.p., MCs appear in the peritoneal exudate of the guinea-pig.

Herzog D26,808/16: MCs tend to accumulate in the inflammatory tissue that develops around intraperitoneally-implanted sponge pieces during the late phases of inflammation in guinea-pigs.

Tsuda D27,349/23: At the site of subcutaneous inoculation with various cocci, the MCs of the mouse discharge their granules. The response is much less pronounced in immunized animals. To a still lesser extent this response can also be elicited by physiologic saline solution injections.

Ernst D26,867/26: In the rat, turpentine s.c. causes the MCs along the blood vessels to swell and discharge their granules within 1–3 hours. At about 9 hours the loose granules are taken up by fibroblasts and leukocytes. Eventually, MCs appear also in the regional lymph nodes.

Nagayo D26,871/28: Various inflammatory irritants cause MC degranulation as judged by observations on diverse animal species. The discharged granules are subsequently phagocytosed by leukocytes and histiocytes. Only in chronic inflammations is there an increase in the MC population.

Michels C72,066/38, *pp. 344–6:* Discussion.

Sylvén D26,048/41: During experimentally-induced granuloma formation, wound healing, and inflammation in animals (rabbit, rat, guinea-pig), as well as in various granulomas in man, the rapidly-growing regenerating tissue contains much diffuse metachromatic material which appears to be derived from the MCs that accumulate during certain stages of the reparative process. Following removal of the surface epithelium with sandpaper in rats, metachromatic "chromotrope substance" appears not only in the connective tissue underneath the epithelium but even in the cytoplasm of the epidermal cells themselves. At the same time, the MCs lose their granules but tend to accumulate on the borderline between epithelium and connective tissue. Thus, the impression is gained that the MCs furnish the metachromatic material which then impregnates the regenerating epidermal cells.

Baglioni D26,894/44: Various types of experimental inflammations produce local MC accumulations in the connective tissue of the rat.

Janes & McDonald B32,304/48: An increased number of MCs are found in types of inflammatory lesions in man.

Olsen & Smith D39,507/49: Injection of turpentine into the popliteal lymph nodes of the rat causes a topical discharge of MCs.

Ròmani C672/53: In the surroundings of a subcutaneous turpentine abscess the MC count increases in the rat. This increase is further augmented by cortisone or cortisol s.c.

Serrão C8,615/53: The MCs discharge their granules and diminish in number during acute inflammations produced by diverse agents; they become more numerous and rich in granules during the chronic stage of inflammation.

Baglioni C16,539/54: Discussion.

Szirmai C43,968/57: The MCs in the comb of the rooster considerably increase in number whenever inflammatory reactions develop accidentally.

Gustafsson & Cronberg D27,895/57: Turpentine i.p. degranulates the peritoneal and mesenteric MCs in the rat. Regeneration is quite incomplete even after 28 days because of the lasting inflammatory reaction induced by this compound.

Spector & Willoughby C63,466/59: In the rat, intrapleural injection of turpentine produces a protein-rich inflammatory exudate. Rats, previously depleted of their histamine stores (by repeated injections of 48/80 or polymyxin) or pretreated with an antihistaminic (mepyramine) show virtual suppression of this exudative reaction at 30 minutes after the turpentine injection. However, 4 hours later, the volume of the exudate in the treated and control animals became approximately equal. Presumably histamine plays a part only in the early exudative phase of inflammation. Curiously, the effective doses of 48/80 caused no degranulation of the MCs.

Sanyal C80.812/59: In the vicinity of an acute aseptic inflammation produced by subcutaneous implantation of turpentine-soaked pellets in the rat, the local MCs disappeared.

Riley C70,315/59, *p. 21*: Discussion.

Csaba et al. C98,159/60: In rats infected with *Mycobacterium tuberculosis* there was a great increase in the MC population of the thymus but no MCs were found around the pulmonary tubercles themselves.

Sheldon & Bauer C96,633/60: The experimental mucormycosis induced by *Rhizopus oryzae* s.c. causes intense local MC degranulation in the rat.

Allen D61,514/61; E94,053/62: Mitotic activity, DNA doubling, and binucleation are enhanced in the peritoneal MCs of the rat by the injection of talc i.p.

Smith D63,031/63: Discussion.

PHOSPHOLIPID-A

Uvnäs D25,283/61: Phospholipid-A causes degranulation of the peritoneal MCs in the rat.

PILOCARPINE

Niccoli-Vallesi D31,597/56–57: Pilocarpine increases the number of MCs in the submaxillary gland of the rat, presumably in relation to increased salivary secretion.

Takeda C60,737/58: Pilocarpine s.c. increases the mesenteric MC population of the rat.

PLANTS

Cf. INVERTEBRATE AND PLANT TOXINS (*p.* 196).

PODOPHYLLIN

Cf. COLCHICINE (*p.* 156).

POLYMYXIN

In vitro

Norton & de Beer D30,591/55: Polymyxin is as active as 48/80 in degranulating the mesenteric rat MCs in vitro. This effect is prevented by cyclizine.

Lagunoff & Benditt D7,116/59: Polymyxin degranulates rat peritoneal MCs isolated on a Millipore filter in vitro.

Lagunoff & Benditt D26,708/60: Peritoneal MCs of the rat, isolated on a Millipore filter, release their granules and histamine under the influence of 48/80 or polymyxin but not upon treatment with dextran or ovomucoid. Thus, "four agents which in vivo appear to have

similar activities have been found by means of in vitro analysis to operate by at least two different mechanisms."

Moran et al. D33,693/62: Polymyxin releases histamine and 5–HT from the peritoneal MCs of the rat in vitro.

Jóhannesson & Norn E33,916/63: Upon exposure of rat peritoneal MCs in vitro "morphine was found to be a 300–400 times weaker liberator of histamine than compound 48/80 or polymyxin B."

Higginbotham D58,297/63: When isolated rat peritoneal MC granules are exposed in vitro to polymyxin, the concentration of the histamine discharger in the suspension medium decreases one-hundred fold and a clear center appears in each of the MC granules. It is assumed that "the heparin inside mast cell granules has the ability to take up and neutralize basic histamine releasing agents".

Mode of administration — generalities

Klaus & Winkelmann C80,962/59: A single large dose of polymyxin i.p. causes no definite degranulation and moderate loss of night-blue stainability of the MCs in the rat.

Fiore-Donati & Moltke C88,372/60: Although polymyxin induces a pronounced MC degranulation, it causes no significant decrease in the tensile strength of linear cutaneous wounds in the rat.

Bhatt et al. F8,369/64: Polymyxin i.p. causes wide-spread MC degranulation in the mouse and rat.

Regeneration of mast cells, adaptation to polymyxin

Parratt & West C37,858/57: A single injection of polymyxin i.p. suffices to produce an anaphylactoid inflammation in the rat. Mast cell swelling and degranulation occurs in 30 minutes and is most intense in the peritoneum, but demonstrable in the skin also. These changes continue to increase during the following 9 days, recovery being initiated around the 15th day and completed by the 29th day. The histamine content of the affected areas roughly parallels the MC changes, but the 5–HT content is but little changed. Repeated i.p. polymyxin injections cause an even more intense degranulation of MCs with a virtually complete disappearance of skin histamine, yet, the treatment continues to cause generalized vasodilatation. Even 4 weeks after discontinuation of the treatment the cutaneous MC population has not yet returned to normal and the histamine content of the skin is still low. On the other hand, appreciable losses of 5–HT occur only in the paws.

Polymyxin and calciphylaxis

Selye et al. D8,490/61: After calciphylactic sensitization with DHT, systemic treatment with polymyxin produces a generalized discharge of cutaneous MCs with subsequent calcification of their liberated granules. This response is enormously increased if small amounts of ferric dextran i.v. are given concurrently with the polymyxin. Under these circumstances, a dermatomyositis-like inflammation of the skin and skeletal muscles results, presumably because "the calcified granules stimulate inflammation and connective-tissue proliferation, particularly in those areas of the muscular and cutaneous systems where MCs are notoriously abundant".

Selye et al. D40,219/63: Calcified skin plaques are produced if rats, pretreated with DHT p.o., are calciphylactically challenged through the infiltration of a subcutaneous tissue area with dilute solutions of ferric dextran. Histamine liberators such as polymyxin *selectively inhibit* this skin calcification at the point where they are applied within the challenged area (*Fig. 11, p. 178*).

Selye et al. D15,989/63; E24,147/64: In rats sensitized for mastocalciphylaxis by pretreatment with DHT and subsequent injection of ferric dextran i.v., polymyxin, 48/80, or stilbamidine s.c. produces *topical calcinosis,* presumably owing to the fixation of iron and then of calcium salts on the discharged MC granules. Thus, the MCs participate in pathologic calcification.

Selye et al. E24,138/64: Mastocalciphylaxis ensues when a DHT-sensitized animal is given a metallic challenger (e.g., $FeCl_3$) i.v. and simultaneously an MC-discharger (e.g., polymyxin) s.c. Here, the MC-discharger elicits a chain reaction, resulting in topical calcification *at the site of injection,* although the challenger is given systemically. Histochemical studies reveal four stages: (1) Liberation of metachromatic granules; (2) the metachromatic material

attracts iron; (3) the fixed iron in turn attracts calcium, phosphate, and probably carbonate; and (4) the calcium precipitate attaches to the adjacent connective-tissue fibers (*Plate I*).

Selye et al. E24,102/64: In rats calciphylactically sensitized with parathyroid extract or DHT, polymyxin s.c. produces *diffuse calcification of the skin,* presumably as a result of cutaneous MC discharge.

Caruso G11,119/64: In rats mastocalciphylactically sensitized with DHT p.o. and $FeCl_3$ i.v., injection of polymyxin into the *lips* (which have a dense MC population) causes much more local calcinosis than when given hypodermically on the back (where the MC population is less dense). It is concluded that the MCs play a decisive part in this type of mastocalciphylaxis.

Selye et al. E24,139/64: In rats sensitized for calciphylaxis by DHT, the topical calcinosis induced by s.c. injection of various challenging metals ($AlCl_3$, $CrCl_2$, $FeCl_3$, $SnCl_2$ $ZrOCl_2$) is enhanced by the admixture of an MC-discharger such as polymyxin. In similarly-sensitized animals, topical calcification is induced by an s.c. injection of comparatively small doses of polymyxin (1–50 μg) if, simultaneously, these rats receive an i.v. injection of a challenger such as $AlCl_3$, $CrCl_2$, $FeCl_3$, $SnCl_2$, $ZrOCl_2$, ferric dextran, aluminum dextran, ovalbumen, or egg yolk. In this *"systemic-local form of mastocalciphylaxis"* histochemical studies show that the MC-discharger first fixes the blood-borne challenger, which then secondarily attracts calcium salts. Furthermore, in rats sensitized with DHT, subsequent i.v. injection of $AlCl_3$, $CrCl_2$, $FeCl_3$, $SnCl_2$ or $ZrOCl_2$ combined with systemic treatment by polymyxin induces the *"cephalonuchal syndrome"* with massive discharge and subsequent calcification of MC-granules in the head and neck region (*Plates II* and *III*).

Gabbiani et al. D64,692/64: In rats calciphylactically sensitized with DHT, subsequent challenge with dextran, dextrin, polymyxin, or 48/80 induces a dermatosis characterized by widespread calcification of the most superficial layers of the dermis and epidermis. In the initial stages, *calcification is limited to discharged mast cell granules.*

Polymyxin and calcergy

Selye & Gabbiani E24,133/64: If lead acetate is injected i.v., subsequent s.c. injection of polymyxin produces *topical* calcification in the rat. After 1 hour, only discharged metachromatic granules, but no calcium, were demonstrable. After 7 hours, the discharged metachromatic granules swelled and showed central vacuoles. Von Kóssa-positive material then accumulated around these granules, forming a shell. After 24 hours, the calcified granules began to disintegrate, dustlike particles of their mineralized shells being transferred onto collagen fibers. After 24 hours, only few calcified MC granules remained intact, the mineralized material being taken up by the collagen. Apparently, the MC plays an important role as a mineral vector in certain forms of calcification (including both calcergy and calciphylaxis); it first captures blood-borne calcium and phosphate which are then transferred onto collagen.

Selye et al. E24,136/64: Mastocalcergy is produced by lead acetate i.v. and polymyxin s.c. The topical MCs in the treated area first show degranulation without any mineralization, but this is soon followed by lead uptake on the MC granules with secondary attraction of calcium (chloranilic acid reaction), phosphate, and possibly carbonate (von Kóssa reaction). Finally, the discharged and calcified MC granules disintegrate into a dust-like fine precipitate which is transferred to the circumjacent collagen fibers where it initiates an intense process of mineralization, eventually leading to the complete petrification of the polymyxin-injected area (*Plate IV*).

Selye et al. G11,107/64: When mastocalcergy is produced by lead acetate i.v. and polymyxin s.c. in the rat, there is *topical* discharge of MC granules followed by their calcification. This whole reaction proceeds also if the PMX-treated skin area is *transplanted* into an unpretreated control rat. Apparently, the whole complex mechanism necessary for the development of mastocalcergy is fully determined at the injection site within a few hours.

Jahnke G11,103/65; *Selye et al.* G11,121/64: In rats pretreated by lead acetate i.v., topical connective-tissue calcification is produced by minute doses of various MC components (histamine, 5–HT) or MC-dischargers (48/80, polymyxin) as a consequence of mastocalcergy. This response can be *inhibited by topical* pretreatment with any one among the substances just mentioned.

Caruso E24,145/65: In rats given lead acetate i.v., the s.c. injection of polymyxin into the *lips,* which have a dense MC population, causes much more calcification than if the same

amount is injected hypodermically on the back, where MCs are much less numerous. Apparently, the MCs plav an important part in this form of calcergy.

Gabbiani & Tuchweber G11,129/64: Following lead acetate i.v., polymyxin s.c. readily produces topical calcification, but no such reaction is obtained when *other calcergens* are given i.v. If Na_2HPO_4 is added to the s.c. injected polymyxin, then local calcification ensues under the influence of i.v. injections, not only of lead acetate but also of other calcergens, such as calcium gluconate, $CeCl_3$, $CdCl_2$ and $LaCl_3$. Oral pretreatment with Na_2HPO_4 also enables subthreshold doses of lead acetate i.v. to prepare for the production of topical calcinosis by polymyxin s.c. Furthermore, the topical calcification induced after lead acetate i.v. by polymyxin s.c. is inhibited by calcium acetate p.o. All these results "support the view that phosphate is primarily responsible for the initiation of this experimental calcification."

Dieudonné E24,129/64: Even when *given alone,* polymyxin s.c. discharges the granules of the topical MCs and these begin to calcify within 5 hours; subsequently, calcium salts can be histochemically demonstrated also in cutaneous muscle and subcutaneous nerves. This confirms the earlier observation (*Selye* D15,540/62) that polymyxin can act as a calcergen in itself, although only at extremely high dose levels.

Selye & Tuchweber G11,117/65: In rats given lead acetate i.v., *topical* connective-tissue calcification is produced at sites where minute doses of various MC-dischargers (polymyxin, 48/80, viomycin, stilbamidine, trypsin) or MC products (5-HT, histamine) are s.c. injected. Heparin and various other compounds tested were ineffective.

Selye et al. G11,118/65: In rats pretreated with a single i.v. injection of lead acetate, the *topical* connective-tissue calcification produced by minute doses of various MC components (histamine, 5-HT) or MC-dischargers (48/80, polymyxin) can be *inhibited by systemic* treatment with large doses of any one among these compounds. Adrenaline, another biogenic amine, exerts a similar protective effect although it does not produce mastocalcergy at any dose level.

Selye et al. G11,122/65; *Serafimov et al.* E24,149/65: In rats prepared by lead acetate i.v., *systemic* treatment with dextran, dextrin, 48/80, polymyxin, and viomycin produce mastocalcergy in different parts of the body, depending upon the MC-discharger given and the route of its administration. "Presumably systemically administered histamine liberators can act selectively upon certain regions and thereby elicit specific organotropic effects, depending upon the agent used and the route of administration."

Polymyxin and other agents

Selye et al. D24,159/63: Polymyxin s.c. given simultaneously with *India ink* i.v. causes localization of carbon particles, particularly in a halo around the polymyxin injection site. Here, the India ink and discharged MC granules are found in close association with the connective tissue and in the walls of small blood vessels, perhaps because some component of the MCs fixes blood-borne particles by increased adhesiveness of tissues. This process is designated as mastopexis. If a similar polymyxin injection is given somewhat prior to the i.v. administration of India ink, there is no local fixation of carbon particles in the subcutis, but numerous pulmonary capillaries are occluded by thrombi, which contain aggregates of India ink. Here, the discharged MC granules may have already been carried from the site of polymyxin injection to the pulmonary circulation, by the time the India ink was introduced into the circulation. It is perhaps for this reason that the carbon particles are fixed in the lung. (*Figs. 13* and *14, pp. 180, 182.*)

Dieudonné E24,128/64: *Cyproheptadine* prevents the topical calcification normally produced by various MC-depletors such as 48/80, polymyxin, stilbamidine, or pentamidine in the rat. However, it actually aggravates the local calcification induced by hexadimethrine, another MC-depletor.

Gabbiani & Nielsen C11,130/64: In rats given an i.v. injection of ferric dextran, polymyxin s.c. causes local iron fixation in the discharged MC granules with subsequent anaphylactoid inflammation. Cyproheptadine prevents the mastopexis of iron without influencing MC discharge (*Plate V*).

POLYVINYLPYRROLIDONE (PVP)

Nishiyama et al. D31,565/57: Compound 48/80 releases much histamine from the liver and muscle but only little from the skin, while other histamine liberators, such as sinomenine, tween 20, and PVP, release much from the skin and less from the liver and muscle, in that

order. PVP is most active in releasing histamine from the skin but there appears to be no proportionality between regional histamine release and MC degranulation. "Therefore, differences in the site of histamine release can not be explained only by the affinity of certain substances to mast cells."

Selye et al. D10,088/62: The topical calcinosis produced by $CrCl_2$ or $FeCl_3$ in rats sensitized for calciphylaxis by DHT is greatly enhanced when certain compounds, such as PVP (or dextran, gelatin, dextrin) are added to the metals. This phenomenon may depend upon the MC-discharging effect of the "adjuvants" which facilitates the spreading of the metal.

PROPAMIDINE

Riley B90,276/53: When injected i.v., in lethal or sublethal doses, or when applied in vitro to preparations of the mesentery, propamidine causes degranulation of the MCs in the rat.

PROTAMINE

Olsen & Smith D39,507/49: Injection of protamine into the popliteal lymph node of the rat causes a topical discharge of MCs.

Constantinides & Rutherdale C2,644/54: Daily treatments with protamine failed to influence the cardiac MC population of the rat.

Smith & Lewis C11,751/55: Protamine does not change the electronmicrographic structure of the peritoneal MC granules in the rat and hamster.

Paff & Mergenthaler D27,516/55: Protamine sulfate i.p. causes MC degranulation within 15–30 minutes in the rat, whereas protamine s.c. causes intense vacuolation of the local MCs.

Higginbotham et al. D15,838/56: Protamine s.c. degranulates the local MCs in the mouse.

Fodor & Lojda D65,270/56: Following feeding of fat, the MCs of the rat peritoneum show only minor degrees of degranulation unless protamine i.v. is simultaneously administered. Protamine in itself has little effect. It is assumed that protamine neutralizes the released heparin and, hence, calls for more heparin discharge from MCs to clear the blood of chylomicrones. Such a clearing mechanism may play an important part in the pathogenesis of atherosclerosis.

Bloom et al. C34,040/57: Electron and phase-contrast microscopy revealed that in the rat and hamster, protamine or toluidine blue i.p. increases the formation of granule-containing vacuoles in the peritoneal MCs, at the same time causing disintegration and release of granules.

Caselli D39,775/57: Topical application of protamine to the skin or peritoneum of the rat interferes with the metachromatic staining of the local MCs by toluidine-blue. The same phenomenon can be reproduced with various electropositive, but not with electronegative, proteins.

Smith & Lewis D33,719/57: Electronmicroscopic studies on the peritoneal MCs of the hamster and rat show that, following treatment with protamine, the specific granules become surrounded by clear areas and are widely separated from each other, while the endoplasmic reticulum becomes more conspicuous.

Gustafsson & Cronberg D27,895/57: Protamine i.p. degranulates the peritoneal and mesenteric MCs of the rat. The ejected granules cannot be distinguished from those found after the injection of a precipitate formed in vitro by protamine and heparin. The precipitate itself has no MC degranulating effect.

Constantinides & Rutherdale C56,628/57: Protamine causes no change in the cardiac MC count of the rat.

Asboe-Hansen & Glick C56,235/58: Rat MC suspensions show loss of metachromasia and clumping of secretory granules, but no degranulation or disintegration, upon in vitro treatment with protamine sulfate.

Smith C54,403/58: In the rat, protamine sulfate i.p. can cause histamine discharge without any microscopically-visible change in the mesenteric MCs.

Smith D63,185/58: Protamine sulfate directly applied to the transilluminated rat mesentery causes MC discharge which can be followed by cinephotomicrographic observation.

Archer D26,626/59: Protamine sulfate i.p. causes disruption and histamine release from isolated peritoneal MCs of the rat.

Klaus & Winkelmann C80,962/59: A single i.p. injection of protamine sulfate causes moderate degranulation of the cutaneous MCs and slight loss of night-blue stainability in the rat.

Archer C78,034/59: Isolated rat peritoneal MCs discharge their histamine in vitro when treated with protamine.

Jennings et al. D26,618/60: Combined treatment with parenteral protamine and oral olive oil causes no change in the peritoneal MCs of the rat.

Bray & Van Arsdel D26,900/61: The isolated peritoneal MCs of the rat discharge their histamine under the influence of protamine.

Adams & Paff D33,746/62: Protamine i.p. discharges the peritoneal MCs of the rat.

Smith D58,273/63: Protamine sulfate can liberate histamine from rat peritoneal MCs, even following repeated injections, when no visible change occurs any more in the cells. "Thus, secretion by the mast cell does not require cell disruption and death as much of the literature indicates but is merocrine in nature".

PYRAMIDON

Iakovleva D25,508/54: Pyramidon derivatives cause degranulation of connective-tissue MCs in the rat.

PYRILAMINE

Smith D27,082/58: Daily i.p. injections of the antihistaminic pyrilamine maleate largely prevent X-ray damage to MCs in the mesentery but not in the skin and cheek pouch of the hamster. However, pyrilamine offers no protection against MC damage in the tissues of irradiated rats. Low doses of promethazine hydrochloride fail to protect MCs against radiation damage in any tissue of the hamster while high doses destroy the mesenteric MCs even in non-irradiated hamsters. In any event, the protective action of antihistamines, where present, is limited to the site of the i.p. injection.

RES-STIMULATORS

Cf. DYES (*p.* 170) AND SILICA (*p.* 211).

RESERPINE

Bhattacharya & Lewis C27,232/56: Reserpine i.p. causes no degranulation either in the peritoneal or in the subcutaneous MCs of the rat. Only very high doses cause slight swelling and degranulation in some of the MCs.

Parratt & West C37,858/57: Reserpine i.p. causes no visible MC damage or degranulation and little histamine release from various tissues of the rat, but induces an intense discharge of 5–HT, especially from the skin and paws. There is no anaphylactoid inflammation. Following a dose of reserpine (which causes an 83 per cent depletion of the skin 5–HT and a 17 per cent depletion of histamine), 48/80 releases only histamine. Hence, 5–HT does not appear to be necessary for the release of histamine or 48/80.

Padawer D30,194/57: Both histamine and 5–HT are present in MCs and histamine liberators degranulate MCs; hence, it is noteworthy that even very high doses (10 mg/100 g body weight) of reserpine fail to change the appearance of rat peritoneal MCs.

Cass et al. C54,014/58: In rats in which the bone-marrow MC population was increased by feeding a special calcium-deficient diet, treatment with reserpine failed to alter the 5–HT content or the MC population in the bones.

Klaus & Winkelmann C80,962/59: Single or repeated injections of reserpine i.p. cause only slight degranulation of the cutaneous MCs and moderate loss of night-blue stainability in the rat.

Fiore-Donati & Moltke C88,372/60: Reserpine causes a significant decrease in the tensile strength of linear cutaneous wounds in the rat, without any concomitant change in the cutaneous MCs.

Jamieson & van den Brenk D8,004/61: Although reserpine is particularly associated with the release of tissue 5–HT, its i.p. injection in the rat causes no depletion of the mesenteric MCs.

Moran & Westerholm D69,395/63: "Reserpine was shown to release neither 5–HT nor histamine from rat peritoneal mast cells in vitro. In vivo reserpine caused a moderate reduction of the number of mast cells in peritoneal fluid. A reduction of the cellular content of 5–HT was also observed. Peritoneal mast cells obtained from reserpine-treated rats responded normally to compound 48/80. . . . The results indicate that reserpine has no effect on mast cells in vitro and only negligible effects in vivo".

Bhatt et al. F8,369/64: Reserpine i.p. causes only slight MC degranulation in the connective tissue of the mouse and rat.

Gabbiani & Rojo Ortega D55,958/64: Pretreatment with reserpine protects the DHT-treated rat both against the production of a local calciphylactic response at the site of a subcutaneous ferric-dextran injection and against the production of a calcifying anaphylactoid reaction by ferric dextrin i.v.

SALICYLATES

Mari & Rizzatti B85,211/51: Sodium salicylate s.c. increases the number and size of peritoneal MCs in the rat.

Baglioni C16,539/54, *p. 206:* Discussion.

SCLEROSING AGENTS

Hjelmman & Wegelius E20,255/56: The MC count increases in the walls of the rabbit's ear vein following the induction of thrombosis by the injection of coagulating materials.

Pettersson & Hjelmman G15,429/64: Around veins in which thrombosis was produced by sclerosing agents in rabbits, the MC density increases. At the same time, many of the surrounding fibrocytes become laden with metachromatic granules. These findings suggest some relationship between blood clotting and MC activity.

SEROTONIN

Cf. 5-HYDROXYTRYPTAMINE (*p.* 193).

SILICA

Pernis et al. D39,793/58: Injection of quartz dust into the rat trachea causes an increase in the MCs around the resulting silicotic nodules and many of the cells discharge their metachromatic granules, which are then phagocytosed by fibroblasts.

Rondez et al. D26,891/59; *Rondez & Rüttner* D27,391/59: If the eventrated mesentery of the mouse is brought in contact with the dust of quartz, corundum dust, or coal dust, an immediate MC degranulation is observed. "There is no reason to connect mast-cell degranulation with fibrogenetic processes, which are observed at a much later stage."

Antweiler D33,672/59: Intratracheal or i.p. administration of carbon or silica dust in distilled water causes local MC-degranulation and histamine liberation in the rat. The same dusts suspended in Tyrode or Ringer solution do not possess this effect. Yet, isotonicity is not the only determining factor since the same dusts given in isotonic dextrose are fully effective.

SILVER NITRATE

Scevola D27,705/38: In the rat and guinea-pig, chemical (NaOH, $AgNO_3$) or thermal (thermocautery) burns in the palatopharyngeal region induce a local accumulation of MCs.

SINOMENINE

Yamasaki et al. C21,613/55: The histamine liberator, sinomenine, causes MC degranulation concurrently with "anaphylactoid shock" in the dog.

Arvy D65,673/56: Sinomenine is an alkaloid of the root of *Sinomenium acutum Rehd. et Wilson (Fam. Ménispermacées),* which is a lymphagogue and has long been known to produce peripheral vasodilatation in the dog. In the rat, it causes an anaphylactoid inflammation with MC degranulation in the shock organs.

STILBAMIDINE

Riley B90,276/53: Stilbamidine and 2-hydroxy-stilbamidine i.v., in lethal or just sublethal doses, cause degranulation of the peritoneal MCs in the rat.

Mota et al. B85,350/53: Stilbamidine produces degranulation of the peritoneal MCs both in vivo and in vitro in the rat. The same is true of 48/80 and since both these compounds also delay blood coagulation (apparently through a protamine-like action) their effect may be due to the formation of insoluble complexes, which remove heparin from the system.

Smith & Lewis C11,751/55: Following treatment with stilbamidine, the fine electron-micrographic structure of the granules in the peritoneal MCs of the rat and hamster remain unchanged.

Asboe-Hansen & Wegelius C29,324/56: Stilbamidine i.p., i.m., or i.v. causes degranulation and granule clumping in the MCs of the hamster's cheek pouch in vivo.

Smith & Lewis D33,719/57: Electron-microscopic studies on the peritoneal MCs of the hamster and rat show that, following treatment with stilbamidine, the specific granules become surrounded by clear areas and are widely separated from each other, while the endoplasmic reticulum becomes more conspicuous.

Bloom et al. C34,040/57: Electron and phase-contrast microscopy revealed that 48/80 i.v. in the rat, and stilbamidine, protamine, or toluidine blue i.p. in the rat and hamster, increase the formation of granule-containing vacuoles in the peritoneal MCs, at the same time causing disintegration and release of granules.

Gemählich et al. D27,072/58: Anaphylatoxic shock was produced in guinea-pigs by a single intracardiac injection of anaphylatoxin (prepared by treating rat serum with inulin). This was associated with intense degranulation of the MCs in the skin, lung, liver, spleen, and mesentery. This was not altered by pretreatment with stilbamidine but both the shock and the MC degranulation could be prevented by pretreatment with prednisone.

Smith D63,185/58: Stilbamidine directly applied to the transilluminated rat mesentery causes MC discharge which can be followed by cinephotomicrographic observation.

Smith C54,403/58: Stilbamidine i.p. simultaneously discharges peritoneal MCs and histamine in the rat.

Bray & Van Arsdel D26,900/61: The isolated peritoneal MCs of the rat discharge their histamine under the influence of stilbamidine.

Selye et al. D15,989/63: In rats sensitized for mastocalciphylaxis by pretreatment with DHT and ferric dextran i.v., polymyxin, 48/80, or stilbamidine s.c. produce topical calcinosis, presumably owing to the fixation of iron and then of calcium salts on the discharged MC granules. Thus, the MCs participate in pathologic calcification.

Dieudonné E24,128/64: Cyproheptadine prevents the topical calcification normally produced by various MC-depletors such as 48/80, polymyxin, stilbamidine, or pentamidine in the rat. However, it actually aggravates the local calcification induced by hexadimethrine, another MC-depletor.

Selye and Tuchweber G11,117/65: In rats pretreated with lead acetate i.v., topical connective-tissue calcification is produced at sites where minute doses of various MC-dischargers (polymyxin, 48/80, viomycin, stilbamidine, trypsin) or MC products (5–HT, histamine) are injected s.c.

Selye et al. G11,122/65: After the induction of calcergic reactivity by lead acetate i.v., systemic treatment with various MC-dischargers (e.g., 48/80, polymyxin, stilbamidine, dextran, dextrin) and MC products (5–HT, histamine) produce essentially distinct patterns of calcification in the rat. The preferential deposition of calcium in one or the other organ is ascribed to selective MC degranulation with consequent mastocalcergy induced by different compounds in different regions.

SULFANILAMIDE

Norton & de Beer D30,591/55: Application of sulfanilamide to the rat mesentery in vitro fails to cause MC degranulation.

TANNIC ACID

Bray & Van Arsdel D26,900/61: The isolated peritoneal MCs of the rat discharge their histamine under the influence of tannic acid.

THIOUREA

Cf. THYROIDECTOMY (*p.* 142).

THORIUM DEXTRIN

Selye D59,442/63: In rats calciphylactically sensitized with DHT, thorium dextrin i.v. produces MC degranulation and calcification predominantly around the shoulder and hip joints in the rat. It is assumed that the periarticular discharged MC granules participate in the localization of first thorium, then calcium salts.

Rowley D69,169/63: Thorium dextrin i.v. causes MC degranulation and vascular damage in the anaphylactoid shock organs of the rat.

Selye et al. E24,102/64: In rats calciphylactically sensitized with parathyroid extract or DHT subsequent injection of thorium dextrin i.v. produces calcification in the esophagus, palate, and large joints. Since thorium dextrin is a MC-discharger, it is probable that the MCs participate in these responses.

THROMBIN

Baglioni C16,539/54, *p. 207:* Discussion.

Baeckeland D30,918/62: If rat peritoneal MCs are placed in contact with heparinized plasma in vitro, they lose their granules and their nucleus disintegrates, but only upon addition of thrombin. It concluded that the MCs undergo degranulation during blood coagulation and presumably participate in this process.

THROMBOKINASE

Frick B62,124/50: Thrombokinase i.p. discharges the granules from the mesenteric MCs of the mouse.

THROMBOPLASTIN

Myslivecek D31,571/48: Although intracardiac thromboplastin causes almost immediate death in the rat, it nevertheless discharges the cutaneous MCs.

Goth G7,587/62: Various thromboplastin-like substances release histamine from rat peritoneal MCs in vitro. The response is potentiated by adding dextran, although dextran itself failed to release histamine from suspended MCs.

TUBERCULOSTATICS

Iakovleva D25,508/54: Chronic treatment with the isonicotinic-acid derivative Ftivazid increases the number and "secretory activity" of the cutaneous MCs in the rat. Following intracysternal administration of this preparation, similar changes are observed in the MCs of the meninges.

d-TUBOCURARINE

Riley B90,276/53: d-Tubocurarine chloride causes degranulation of the MCs in the rat when it is injected i.v., in lethal or sublethal doses, or applied in vitro to preparations of the mesentery.

Fulton et al. D39,660/54: d-Tubocurarine i.v. causes intense MC disruption in the cheek pouch of the hamster simultaneously with histamine liberation. Mepyramine i.p. prevents these changes.

Padawer & Gordon D63,174/55: Methanol-fixed and unfixed air-dried smears of rat or hamster peritoneal fluid reacted to the in vitro addition of 48/80 by losing their metachromasia. This suggests "that 48/80 influences mast cell staining in the dead as well as living state and acts directly." d-Tubocurarine and colchicine did not affect metachromasia under these conditions, whereas protamine sulphate suppressed it completely.

Fontanini et al. D39,752/58: d-Tubocurarine i.v. in lethal doses causes MC destruction in the rat mesentery.

Smith C54,403/58: In the rat, d-Tubocurarine i.p. causes mesenteric MC disruption simultaneously with histamine discharge.

Archer D26,626/59: Isolated peritoneal MCs of the rat discharge their histamine and granules when exposed to d-Tubocurarine.

TWEEN 20

Yamura & Watanabe D58,429/61: Tween 20 discharges the histamine and the specific granules from rat peritoneal MCs in vitro.

URANYL ACETATE

Selye & Jahnke G11,105/65: In the rat, uranyl acetate s.c. produces intense MC degranulation with diffuse metachromasia of the adjacent connective tissue and striated cutaneous musculature at the injection site. These changes differ from those elicited by classical MC-dischargers in that the liberated MC-granules assume a peculiar yellowish-violet tinge after staining with azure A, and remain demonstrable in the connective tissue for a long

time, without being absorbed or phagocytosed. Furthermore, the MC degranulation elicited by uranyl acetate is accompanied by diffuse metachromasia of the surrounding tissues and elimination of metachromatic material in the renal tubules.

VIOMYCIN

Selye et al. E24,139/64: In rats sensitized for calciphylaxis by pretreatment with DHT, the topical calcinosis induced by s.c. injection of $FeCl_3$ is enhanced by the admixture of an MC discharger such as viomycin. Furthermore, in rats sensitized for mastocalciphylaxis by pretreatment with DHT and subsequent i.v. injection of $FeCl_3$, viomycin s.c. produces local calcification at the site of MC discharge. Under similar conditions, systemic treatment with viomycin induces the "cephalonuchal syndrome," presumably owing to massive MC discharge and subsequent calcification in the head and neck region. (*Fig. 12, p. 179* and *Plates II* and *III.*)

Serafimov et al. E24,149/65: In rats prepared by lead acetate i.v., dextran, dextrin, 48/80, polymyxin, and viomycin produce mastocalcergy in different parts of the body, depending upon the MC-discharger given and the route of its administration. "Presumably systemically administered histamine liberators can act selectively upon certain regions and thereby elicit specific organotropic effects, depending upon the agent used and the route of administration."

Selye & Tuchweber G11,117/65: In rats pretreated with lead acetate i.v., topical connective-tissue calcification is produced at sites where minute doses of various MC-dischargers (polymyxin, 48/80, viomycin, stilbamidine, trypsin) or MC products (5–HT, histamine) are injected.

VITAMIN-A

Hirt et al. D33,724/39: Vitamin-A overdosage tends to alter the trypaflavin-induced fluorescence of murine MCs.

Berdjis D68,096/63: In rats fed large amounts of vitamin-A, as well as in rat tissues explanted into vitamin-A-rich media, the MC count is very high. The increase is particularly obvious in bone and bone marrow.

Smith D63,031/63: Discussion.

VITAMIN-B

Cf. PERNICIOUS ANEMIA (*p.* 290).

VITAMIN-C

von Numers D26,635/53: In the scorbutic guinea-pig, the MC population of the skin is diminished and there is excessive deposition of free mucopolysaccharides in the epidermis. The metachromasia of hair follicles does not change during scurvy.

Pettersson C67,832/59: The mesenteric MCs of scorbutic guinea-pigs gradually lose their metachromatic granules.

VITAMIN-D

Shipley et al. D33,700/22: In rats on a low-calcium, vitamin-D-deficient diet "cells evidently derived from the fixed tissues with large basophilic granulations were numerous in the immediate vicinity of the trabeculae." [As judged by their histologic picture, these cells appear to have been MCs (*H.S.*).]

Urist & McLean D14,540/57: In rats maintained on a diet deficient in calcium and vitamin-D, numerous MCs accumulate in the endosteum of the subepiphyseal bone trabeculae.

Gillman C52,329/58: Seven days after an acute overdosage with calciferol the MCs disappear around the calcified foci in the stomach, while 70–200 days following discontinuation of the treatment, the MC count rises "apparently increasing pari passu with the diminution of both minerals and metachromatic material" although PAS positivity persists in the lesions. Similar, though less pronounced, rises in the MC count are seen during the healing of the lesions in the myocardium, in the aorta, and in the renal and coronary vessels.

Selye D25,668/62: The severe skin atrophy that accompanies the "progeria-like syndrome" induced by chronic DHT-treatment in the rat is accompanied by widespread MC degranulation throughout the cutis and subcutis. However, unlike following MC depletion by histamine dischargers, the extruded metachromatic granules do not disappear but remain in the connective tissue between the fibers, especially in the vicinity of blood vessels. Here they form dense, perivascular cuffs in and around the adventitia, sometimes penetrating into the

vessel wall. Ferric dextran prevents most of the manifestations of the DHT-induced progeria-like syndrome including the cutaneous atrophy, but the MC degranulation does not appear to be much affected. In the event of concurrent treatment with DHT and ferric dextran, the metachromatic granules are frequently seen in close association with iron particles around the blood vessels; indeed, sometimes both types of granules can be identified within the body of the same cell.

VITAMIN-K

Giannico & Marrazza D27,648/47: The peritoneal MCs of the rat diminish in number and size following "parenteral administration" of vitamin-K. Vitamin-K inhibits heparin formation with a consequent decrease in circulating antithrombins and may exert its effect on blood coagulation through this mechanism.

Myslivecek D31,571/48: Intracardiac injection of vitamin-K discharges the cutaneous MCs in the rat.

Takeda C60,737/58: Vitamin-K s.c. allegedly increases the mesenteric MC population of the rat and mouse.

VITAMINS (VARIOUS)

Tuma D27,638/28: In rats kept on a diet deficient in various vitamins, the mammary-gland MCs decrease in number. The granules of the remaining MCs retain their metachromasia but lose their normal tingibility with lipid stains. Unlike normal MCs, they also cannot be impregnated with ammoniacal silver solutions according to the methods of Masson and Smith-Dietrich.

WATER (INCLUDING OSMOTIC PRESSURE)

Hardy & Wesbrook D28,474/1895: The MCs in the intestinal tract of the dog exhibit an "exceeding instability of the granule substance in the presence of even small quantities of water. After death water induces a complete disruption of the granules of so marked a nature that it involves the whole cell body, swelling it up to a bladder-like form or even destroying it so completely that no traces can be recognized by subsequent treatment."

Tsuda D27,349/23: At the site of s.c. inoculation with various cocci, the MCs of the mouse discharge their granules but, to a lesser extent, the response can also be elicited by physiologic saline solution injections.

Bartoli D39,605/38: 30 per cent glucose i.p. causes intense degranulation of the mesenteric MCs in the rat.

Zollinger D10,328/50: Phase-microscopic examination of the peritoneal MCs of mice shows large brilliant granules which contain heparin since they stain metachromatically with toluidine blue. In vitro, the granules release heparin immediately when suspended in distilled water and more slowly in contact with physiologic saline solution. The granular skeleton, which apparently consists of protein, remains. "It seems highly probable that the heparin-containing granules of mast cells represent a special form of mitochondria."

Riley B90,276/53: Even physiologic saline solution causes degranulation of the peritoneal MCs of the rat when topically applied to the tissue in vitro.

Fawcett D26,771/54; D28,375/54: Following distilled water i.p., the MCs of the rat peritoneum discharge their granules and histamine.

Grossberg & Garcia-Arocha D28,699/54; *Hagen* D26,567/54: A suspension in isotonic sucrose of the large MC-granule-containing fraction of dog-liver homogenate is rich in histamine which it releases upon dilution with distilled water.

Devitt et al. B96,691/54: Direct application of distilled water to the mesentery of the rat causes local swelling and degranulation of the MCs.

Braun-Falco D26,884/55: Distilled water, i.p. or s.c., causes local osmotic destruction of the MCs in the rat. In the case of i.p. injection, this is associated with a discharge of histamine into the peritoneal fluid. On the other hand, neither i.p. nor s.c. injection of Tyrode produces more than a trace of MC discharge in the rat.

Norton & de Beer D30,591/55: The degranulation of rat peritoneal MCs, normally produced by distilled water, can be prevented by cyclizine.

Fawcett D26,781/55: Following distilled water i.p., the peritoneal MCs of the rat swell and disintegrate, whereupon they are replaced only slowly. Regeneration begins during the

second week but becomes complete only after about six weeks. The new MCs are derived from fibroblast-like precursors by cell division.

Hjelmman & Pettersson D39,845/55: The discharge of rat mesenteric MCs by hypotonic solutions can be followed in vivo through water-immersion microscopy and vital staining.

Riley C9,303/55: Discussion.

Arvy C41,778/56: When tissues of *Rana esculenta* are placed in physiologic NaCl solution, the number of histologically-detectable MCs increases rapidly.

Wegelius & Asboe-Hansen C29,551/56: The cheek-pouch MCs of the hamster discharge their granules following topical treatment with water. Even physiologic saline solution and Tyrode solution cause some degranulation; 2 per cent NaCl causes shrinkage.

Asboe-Hansen & Wegelius C29,324/56: Distilled water, i.p., i.m., or i.v. causes degranulation and granule clumping in the MCs of the hamster's cheek pouch in vivo.

Hjelmman D39,689/56: The mesenteric MCs of the rat show degranulation following local application of distilled water, a phenomenon which can readily be followed in vivo by the application of vital stains.

Archer D26,626/59: Exposure to distilled water in vitro liberates the granules and histamine from rat peritoneal MCs.

Keller D26,882/56: Distilled water i.p. causes degranulation of the mesenteric MCs in the rat, while Tyrode solution does not.

Keller & Burkard C29,951/56: Distilled water i.p. causes destruction of the peritoneal MCs with a corresponding release of histamine in the rat. Isotonic Tyrode solution produces neither MC degranulation nor histamine discharge under these circumstances.

Asboe-Hansen C77,655/57: Distilled water and even physiologic NaCl solution cause degranulation of the cheek-pouch MCs in the hamster.

Keller D94,203/57: In the anaphylactoid shock organs of the rat, the MCs undergo degranulation under the influence of s.c. injected water (more than 10 per cent of body weight), dextran or trypsin, all of which produce more or less intense anaphylactoid inflammation.

Keller C34,639/57: Even 80 days following a single i.p. injection of distilled water the peritoneal MCs of the rat show no definite sign of regeneration. [?(*H.S.*).]

Keller C54,750/57: 20 ml of distilled water s.c. degranulates the peritoneal MCs with an increase in urinary histamine excretion in the rat.

Hill D27,967/57: 10 ml/100 g body weight of distilled water i.p. produces shock but no osmotic disintegration of the mesenteric MCs in the rat. The metachromatic granules become less tingible and assume the aspect of "pseudovacuoles" as a result of swelling. This gives the cytoplasm a honeycomb structure. Later, the granules stain bright red with toluidine and are discharged from the cells. Since shock ensues during the first "honeycomb" stage this cellular change is assumed to be related to histamine discharge, while the degranulation is thought to be associated with heparin secretion. [The author cites observations of other workers who claim that the histamine and heparin content of the peritoneal fluid rises during two successive periods, corresponding respectively to the two types of MC changes. However, no determinations of histamine or heparin were performed in the present experiments; hence the evidence in support of this concept is indirect (*H.S.*).]

Quevedo et al. D27,069/58: Distilled water s.c. causes local depletion of MCs in the mouse, and even 14 days later the injected area is devoid of MCs. Growth and pigmentation of hair occurs in normal fashion in the complete absence of local MCs. "Contrary to previous reports, it is concluded that mast cells neither elaborate melanin pigment nor contribute to the melanogenic activity of melanocytes within hair follicles."

Smith C54,403/58: In the rat, distilled water i.p. causes mesenteric MC disruption simultaneously with histamine discharge.

Smith D63,176/58: Following topical treatment with distilled water, the MCs of the hamster cheek pouch and mesentery discharge their granules which are subsequently phagocytosed by fibroblasts, macrophages, and leukocytes.

Fontanini et al. D39,752/58: Distilled water causes destruction of the MCs in the rat mesentery, but only upon i.p. administration.

Redei et al. D65,502/58: H_2O i.p. causes local discharge of MCs and histamine shock in the rat. At the same time the "resistin" content of the blood is allegedly increased. "The increased production of resistin in animals subjected to stress by distilled water or other

histamine liberators may be responsible for their refractory state towards histamine liberators".

Rondez et al. D26,891/59: Distilled water i.p. causes intense MC degranulation in the mesentery of the mouse.

Antweiler D33,672/59: Carbon or silica dust in distilled water, intratracheally or i.p., causes local MC degranulation and histamine liberation in the rat. The same dusts suspended in Tyrode or Ringer solutions do not possess this effect; yet, isotonicity is not the only determining factor since the same dusts are fully effective when given in isotonic dextrose.

Archer C78,034/59: Isolated peritoneal MCs of the rat discharge their histamine in vitro when treated with distilled water.

Stolk D39,816/60: In the carp (*Cyprinus carpio*) the mesenteric MCs show degranulation upon exposure to distilled water.

Stolk D39,817/60: "The cutaneous mast cells of the precancerous skin (carcinoma planocellulare) in the lizard *Lacerta agilis L* showed a positive leucine aminopeptidase activity." These MCs in the stroma of spontaneous tumors show degranulation upon treatment with distilled water.

Boréus D65,098/60: Hypotonic solutions cause disruption of the MCs in the hamster and rat, while in the guinea-pig they induce MC dissolution without specific granule discharge.

Archer D26,441/61: The osmotic disruption of the peritoneal MCs of the rat, elicited by contact with distilled water, is not associated with a disruption of the liberated granules themselves.

Moran et al. D33,693/62: Distilled water releases histamine and 5–HT from the peritoneal MCs of the rat.

STRESSORS AND PHYSICAL AGENTS

Traumatic interventions undoubtedly can cause a topical MC degranulation although there is some difference of opinion concerning the intensity of the local stress required. Several investigators noted a secondary increase following the initial post-traumatic disappearance of MCs.

Compression and decompression deforms MCs but does not appear to induce granule release. The time required by MCs to recover their original shape after transitory compression increases with age.

Exposure to extremes of *heat* or *cold* can produce acute topical MC degranulation, but chronic exposure to cold may have an inverse effect. For example, in fishermen, skin regions frequently exposed to cold water allegedly contain an unusually large number of MCs. An increase in MC count has also been obtained experimentally in rats by chronic exposure to cold.

Data concerning the effect of systemic stress upon the MCs are difficult to interpret. Repeated *hemorrhages* allegedly induce an increase in the bone-marrow MC count, but various systemic *chemical or physical stressors* were found to produce widespread MC degranulation throughout the body. Reports concerning changes qualitatively characteristic for stress require confirmation.

An unusually-pronounced increase in MC density has been reported in the thymus of stressed animals. However, it must be kept in mind that during the alarm reaction, the thymus undergoes intense involution of its specific parenchyme and, hence, even if the absolute number of MCs does not change, the count within a given area would increase since the MCs are almost exclusively located within the stroma which does not undergo involution.

Although the MCs are not particularly sensitive to *ionizing rays*, intense total body irradiation may cause widespread damage to MCs. (Presumably, the contradictory results of various authors are due to differences in the intensity and duration of the irradiation.) Following exposure to a single large dose of roentgen

or gamma rays, there is local MC degranulation but in animals or man repeatedly exposed to moderate ionizing radiation, the MC count in various tissues (particularly in the thymus and other lymphatic organs) may rise markedly above normal. These responses have been ascribed to the alarm reaction and resistance phase of the general adaptation syndrome, but they may represent specific actions of ionizing rays.

To what extent heparin release from damaged MCs participates in the hemorrhages characteristic of the radiation syndrome remains questionable.

Reviews: *Baglioni* C16,539/54, *p. 208*
Smith D63,031/63

MECHANICAL TRAUMA, SURGICAL INTERVENTIONS

Holmgren & Rexed D26,230/46–47: Following transection of the sciatic nerve in the rat. metachromatic material appears in the cytoplasm of the proliferating Schwann cells (fixation: basic lead acetate; staining: toluidine blue). This change reaches a maximum on the 3rd and 4th day. Diffuse metachromasia of this sort occurs in many rapidly proliferating tissues (e.g., during embryonic life, in newly formed scars, in regenerating uterine mucosa, and growing tumor tissue). The MCs in and around the transected nerve show no obvious change and they do not appear to participate in the development of diffuse metachromasia.

Riley B90,276/53: Within 24 hours after the application of a light venous tourniquet to the hind limb of the mouse, there is almost complete disappearance of the MCs from the edematous area.

Baglioni C16,539/54, *p. 208*: Discussion.

Padawer B95,453/54: Following adrenalectomy, the diameter of the MCs in the peritoneal and pleural fluids of the rat decreases; the mesenteric MCs are not affected. However, this change is due to the operation itself since other surgical procedures can imitate it.

Holczinger & Dévényi D39,763/55: During the healing of cutaneous wounds in rats, the local MC population shows no obvious variations, and the different localization of ground substance and MCs led to the conclusion that the latter are not responsible for the production of ground substance. Very small doses of heparin neutralize the ground substance depolymerizing action of hyaluronidase, which "suggests that the mast cells, in their capacity of heparin producers, act as hyaluronidase inhibitors in the evolution of granulation tissue."

Wichmann D11,765/55: In skin wounds of rats, the number of MCs decreases during the first 24 hours but begins to increase on the next day, reaching a maximum on about the 8th–10th day after the operation. Then a decline begins with return to normal within about one month.

Wegelius & Asboe-Hansen C29,551/56: The cheek-pouch MCs of the hamster discharge their granules following trauma.

Padawer & Gordon C19,322/56: Both adrenalectomy and sham-adrenalectomy cause a decrease in the average size of the peritoneal MCs in the rat but this change cannot be prevented by cortisone or adrenocortical extract. These observations and an analysis of the literature lead to the conclusion that an effect of glucocorticoids upon the MCs has not yet been proven. Here, stress presumably acts through an extra-adrenal mechanism.

Keller C54,750/57: Tourniquet shock causes degranulation of the peritoneal MCs with an increase in urinary histamine excretion in the rat.

Telkkä & Kuusisto C45,221/57: Following ligature of the common bile duct, there is an initial fall followed by rise in the MC population of the rat liver. "The rapid decrease of the mast cells can be regarded as a stress-effect due to the operation" whereas the secondary rise is apparently related to connective-tissue proliferation.

Constantinides & Rutherdale C56,628/57: The stress of bone fractures fails to affect the cardiac MC count in the rat.

Boyd & Smith D65,097/59: Around linear skin wounds the MCs disappear during the first ten days and then gradually reappear in the rat.

Archer D26,626/59; C78,034/59; D26,441/61: Mechanical maceration of rat peritoneal MCs in a homogenizer liberates their granules and histamine, but it does disrupt the liberated granules themselves.

Kelsall D7,784/61: In hamsters, in which necrosis of skeletal muscles is produced by the formation of turpentine abscesses or growing transplantable tumors, there is an increase in the local MC population. This is attributed to the pressure of the growing inflammatory or neoplastic focus.

Smith D39,764/61: Following repeated iodine application and trauma to the rat cornea, the MCs normally found in the limbal capillary plexus are degranulated but, as the cornea becomes vascularized, MCs invade it.

Schiff & Burn D28,988/61: Surgical trauma incident to tonsillectomy causes degranulation of the oral MCs in man.

Carril et al. G16,997/62: Surgical interventions cause an increase in the MC count of the oral mucosa in man.

Reynolds et al. D64,852/63: During wound healing following the excision of skin laps the number and granularity of the MCs is increased at first and declines after the tenth day towards normal. "The mast cell is suggested as a mediator to peripheral tissue of the presence and activity of the wound."

Blomquist & Fock D69,669/63: An experimental ileus produced by ligature of the small intestine, causes severe stress but no significant change in the MC population of various tissues in the rat.

HEMORRHAGE

Baglioni C16,539/54: Discussion.

Messerschmitt D26,705/54; D26,636/55: In man, repeated hemorrhage, conducive to chronic hypochromic anemia, may result in a considerable increase in the bone-marrow MC count.

GRAVITY

(Cf. WATER, for osmotic pressure effects)

Padawer et al. D29,151/58; D26,629/60; D26,628/61: When peritoneal MCs of the rat are deformed by pressure centrifugation "mast cells of young rats behave as if invested with an elastic envelope" and rapidly return to their original spherical shape while those of older rats are much slower in reverting to their normal shape. Non-spherical peritoneal MCs are not uncommon even in untreated, old rats.

Kindwall et al. D31,658/62: Rapid decompression from high ambient pressures causes no degranulation of the mesenteric MCs or any evidence of histamine and 5–HT release from various organs of the rat.

DRUGS (INCLUDING INFLAMMATORY IRRITANTS)

(Cf. also BACTERIAL TOXINS, IMMUNE REACTIONS and general section on DRUGS. Here we consider only drug actions that have been specifically related to stress effects.)

Arvy & Gabe B44,853/49: During *alloxan* intoxication, the number of MCs in the thymus, bone marrow, and lymph nodes of the rat increases considerably, perhaps as a consequence of the resulting general adaptation syndrome.

Frick B62,124/50: The discharge of peritoneal MCs induced by *thrombokinase* i.p. in the mouse is ascribed to the induction of "shock" by this enzyme.

Mari & Rizzati B85,212/51: A great variety of drugs, such as *penicillin, colchicine, chloramine, trypaflavine, and salicylates* can cause an increase in number and degranulation of the peritoneal MCs in the rat. The same result is obtained by ACTH and none of the drugs act in absence of the adrenal glands; hence, the effect is ascribed to stress. Negative findings following prolonged treatment with ACTH or stressors (as reported in the literature) are attributed to an exhaustion of this mechanism.

Blomquist D31,590/56: Injection of the sclerosing agent, *diethylamine oleate,* into the submucosa of the guinea-pig, causes a statistically-significant increase in the MC count of the thyroid gland. The phenomenon may be related to systemic stress.

Jasmin C24,745/56: Stress induced by repeated s.c. injections of *croton oil* produces a degranulation of the MCs in the rat.

Asboe-Hansen & Wegelius C29,324/56: In-vivo observations on the cheek-pouch MCs of the hamster lead to the conclusion "that *histamine* exerts an action as powerful as that of the histamine-liberators. This indicates that the mast-cell changes are an unspecific response to the effect of histamine on tissues rather than a specific response to histamine-liberators."

Hill C64,094/58: Various stressors cause degenerative changes in the omental and mesenteric MCs of the rat. *Peptone and heat* induce discharge and vacuolization, whereas *formalin* causes mainly lysis of the granules without vacuolization or discharge.

Villavicencio & de Takats C56,397/58: *Bacterial toxins* (pyrogen) and *nitrogen mustard* cause intense degranulation of MCs in the mesentery of the rat. Presumably the MC plays an important role in the defense against stress.

Hill & Pospíšil C99,519/60: Following a single i.m. injection of *formalin*, the mesenteric MCs of the rat exhibit swelling with degranulation in the initial stage (referred to as the "glucocorticoid phase of stress"), being followed by shrinking with granule lysis (in the "mineralocorticoid phase"). In adrenalectomized rats, formalin elicits only shrinkage and lysis of MC granules; on the other hand, cortisol produces swelling with degranulation both in the adrenalectomized and in intact rats. Hence, these MC-changes are viewed as part of the G.A.S.

Csaba et al. E36,438/63: *Colchicine* causes an increase in the MC population of the rat thymus which is ascribed to its stressor effect.

Stone & Robillard E81,532/64: Chronic exposure to *submicronic dust* ("acetylene black") causes pronounced MC accumulation in the lungs and peribronchial lymph nodes accompanied by peribronchial fibrosis.

TEMPERATURE

(Cf. also HIBERNATION, *p.* 244.)

Scevola D27,705/38: In the rat and guinea-pig, chemical (NaOH, $AgNO_3$) or thermal (thermocautery) burns in the palatopharyngeal region induce a local accumulation of MCs.

Schoch & Glick D26,848/53: The stress of exposure to cold causes no consistent changes in the cutaneous MCs of the rat.

Riley B90,276/53: Within the local edema produced by scalding of the back or heating with an infrared lamp, the MCs assume an homogeneous, "glassy" appearance "as if the granule substance had run together." Some of the granules are discharged and occasional vacuoles appear in the cells. The degranulating effect is limited to the edematous area.

Smith et al. D67,482/54: The MC count in the duodenum of the bat increases during the winter season as well as upon exposure to cold during the summer. In summer bats the MC count is low and it can be lowered artificially during the winter, by exposure to heat. The blood-clotting time shows parallel variations. "The mast cell changes suggest that the alterations in clotting time are determined at least in part by alterations in the availability of heparin to the circulation."

Baglioni C16,539/54, *p. 208*: Discussion.

Arvy C41,778/56: In *Rana esculenta*, the MC distribution depends upon the ambient temperature. At 0–12°C the MCs accumulate mainly around vessels and the perimysium of the muscle fibers, whereas at 20–37°C they migrate from the muscles into the vicinity of nerves.

Hjelmman D39,689/56: In the frog, artificial hibernation, induced by exposure to cold, greatly increases the cardiac MC count.

Constantinides & Rutherdale C56,628/57: Cold fails to affect the cardiac MC count in the rat.

LeBlanc & Rosenberg C42,304/57: Upon prolonged exposure to cold, the MC count in the perivascular region of the rat mesentery increases, while in the intervascular region, it decreases. In the abdominal skin, there is an increase, while in the ear skin (which is much more affected by cold), the MC count decreases. "The increases in number of mast cells in abdominal skin and the changes in the mesentery are considered to be systemic effects of cold; the decreases in the skin of the ear are considered to be local effects."

McGovern D27,739/57: When local inflammation is produced in the hind paw of the rat by cold (ethyl-chloride spray) or by the injection of ethanolamine, the local MCs discharge their granules. If the MCs are previously depleted by 48/80, the inflammatory edema is lessened but leukocytic migration into the tissues is hastened. Local injection of heparin does not influence the edema but retards the migration of leukocytes. The MCs may play a role in regulating inflammation.

Hill C64,094/58: Exposure to heat causes vacuolization and degranulation of the MCs in the omentum and mesentery of the rat.

LeBlanc C55,959/58: The MC count of the rat mesentery normally decreases following treatment with chlorpromazine; however, animals previously adapted to cold become resistant to this action. [Here we are manifestly dealing with cross-resistance (*H.S.*).]

Pianigiani & Fiornovelli C71,744/58: During an alarm reaction produced by cold, diffuse and granular metachromatic material appears in the skin, especially in the vicinity of degranulated MCs; a few hours later (during the counter-shock phase) extracellular metachromasia disappears, but numerous degranulate MCs remain. Adrenalectomy accentuates the first and diminishes the second phase.

Marx et al. C80,411/60: Cold exposure caused a rise in MC density in young but a depression in old rats as judged by counts on the lung and thymus. There was no concurrent variation in heparin levels.

LeBlanc et al. D87,634/60: In fishermen, used to cold water, the pressor response to cold is diminished and pain is less easily induced by immersion into cold water than in control individuals. "Skin biopsies showed no difference in skin thickness or cell size but there was a significantly greater number of mast cells in the fishermen's skin. The difference between the fishermen and the control subjects may be related to repeated cold exposure."

Calzavara et al. D13,495/60: Following skin burns (immersion of the hind limbs into boiling water) there is degranulation, followed by regranulation, of the peritoneal MCs in the rat. This phenomenon is a nonspecific manifestation of the alarm reaction.

Craps D12,408/61: Freezing of the skin with ethylene chloride causes topical MC-degranulation and a decrease in tissue histamine both in the guinea-pig and in the rat.

Héroux D26,430/61: Exposure to cold causes a sharp decline in the MC population of the rat's ear. The discharge of granules resembles that caused by other types of injury, but unlike in the latter, the number of MCs does not begin to increase before the 7th day. This is ascribed to a diminished rate of mitosis.

Archer D26,441/61: Repeated freezing and thawing of isolated peritoneal rat MCs disrupt not only the cells but even the granules themselves.

Glick & Pothapragada D2,215/61: The stress of cold causes an increase in the succinic dehydrogenase activity of rat peritoneal MCs.

Jamieson & van den Brenk D8,004/61: Hypothermia itself does not alter the mesenteric MCs of the rat even when the rectal temperature is reduced to 18°C.

Sanyal D54,916/62: Both in the rat and in the mouse, skin burns cause rapid degranulation of the local MCs with a concurrent discharge of histamine and, to a lesser extent, of 5–HT.

LeBlanc D58,979/63: During chronic exposure to cold, the urinary excretion of histamine rises in the course of the first month, but then declines. The excretion of 5–HT also rapidly rises, but does not decline with time. Since the rise in urinary histamine-elimination is associated with an increase in cutaneous MCs, the possibility is considered that thyroid stimulation by cold affects histamine and 5–HT metabolism through its effect upon the MCs.

LeBlanc E21,031/63: While acute cold injury diminishes the number of MCs in the rat skin, chronic adaptation to cold causes a considerable increase. A large number of MCs is also found in the skin of fishermen, who are adapted to cold. The possibility is considered that increased histamine secretion by the proliferating MCs may participate in cold adaptation.

Smith D63,031/63: Discussion

Gabbiani & Rojo Ortega D55,958/64: Pretreatment with cold baths protects the DHT-pretreated rat against the production of a local calciphylactic response at the site of a subcutaneous ferric-dextran injection as well as against the production of a calcifying anaphylactoid reaction by ferric dextrin i.v. Curiously, the iron deposition in the shock organs is not prevented by any of these stressors.

VARIOUS OTHER STRESSORS

Smith & Lewis C1,168/54: In the rat, a great variety of stressors have no effect on the total number of cutaneous and mesenteric MCs but increase the percentage of abnormal forms (cells with vacuolation and granule conglomeration).

Riley C9,303/55: Discussion of effect of electric current on MCs.

West & Parratt C45,206/57: "Two days after weaning, the histamine and 5–HT levels for abdominal skin, ears and dorsal skin of the foot are about twice those found in unweaned litter-mate rats; yet mast cells in these regions are not increased in number or altered in appearance. The exact cause of these increases is still unknown, though it may be simply related to the stress involved in weaning, since the return to normal levels is complete in the next six days."

Fontanini et al. D39,752/58: Various stressors, especially if they act chronically, cause destruction of the MCs in the rat mesentery.

Rosate D99,736/59: Following prolonged immobilization of the rat's knee joint, the MCs tend to disappear from the synovia and to augment in the deeper layers, especially in the adipose tissue.

Csaba et al. D3,199/61: When a galvanic current is led through a rat, many MCs accumulate in the thymus and allegedly "some of the lobes underwent complete mast-cell transformation." Proliferation of thymic MCs was also seen after x-irradiation and particularly after combined treatment with the galvanic current and x-irradiation. The effect is ascribed to "stress-like stimuli."

Räsänen D39,969/63: Stress (swimming to exhaustion) causes degranulation of the gastric MCs in the mouse and rat. This may play a part in the production of stress ulcers.

Räsänen E22,623/63: The gastric MCs of the rat show mild degranulation following stress (peritonitis induced by asbestos) but simultaneous administration of ACTH produces profuse MC degranulation.

IONIZING RADIATION

Regaud & Crémieu D26,829/12; D27,341/13; *Regaud & Lacassagne* D26,872/22: MCs are abundant in the connective tissue of the thymus, following x-irradiation in the cat. These cells have previously been designated as "eosinophils with round nuclei" because, when fixed in formalinbichromate mixtures, the granules take up eosin.

Bierich D27,096/22: Following intense x-irradiation of the skin there is a great diminution of cutaneous MCs in the mouse.

Michels D27,955/33: The MCs of the rat peritoneum are unusually resistant to a single erythema dose of x-rays: they maintain their structure even when lymphocytes, pseudoeosinophils, plasma cells and many other peritoneal elements show signs of disintegration.

Sylvén D27,881/40: Following the local application of roentgen and gamma rays to the skin of the rat, the local MCs discharge their metachromatic granules, thereby causing diffuse metachromasia of the surrounding connective tissue.

Campani D39,614/48: Following intense total-body irradiation, the cutaneous MCs of the rat discharge their granules, thereby inducing a diffuse metachromasia of the connective tissue.

Liebow et al. D26,782/49: Description of MC-changes in atomic bomb casualties.

Spargo et al. B90,582/51: Repeated exposure of mice to external gamma-radiation from radium sulfate causes a gradual increase in the MCs of the thymus, spleen, bone marrow, and lymph nodes. However, in animals which developed lymphomas involving these organs, the MCs are decreased.

Arvy et al. B62,607/51: Total-body x-irradiation considerably raises the MC count in the thymus, lymph nodes, and bone marrow of the mouse.

Kelsall & Crabb D26,640/52: In the thymus of the hamster, the MC count increases following x-irradiation.

Arvy et al. D26,834/52: x-irradiation increases the MC count of the thymus and lymph nodes in the intact, but not in the adrenalectomized mouse. Cortisone reproduces this change even without x-irradiation and this mastocytosis is accompanied by the thymolysis characteristic of the alarm reaction. Presumably, mastocytosis of the lymphatic organs is characteristic of the G.A.S.

Smith & Lewis B79,377/53: Total body x-irradiation alters the MCs in the cheek pouch and mesentery of the hamster, as well as in the mesentery of the mouse. First there is clumping of granules and vacuole formation, then an increase in the size of the granule clumps and vacuoles and finally distension and rupture of the cell, whereupon the granule clumps and vacuoles are dispersed into the adjacent tissue. These changes may be related to the hemorrhage and clotting defect of the radiation syndrome.

Kelényi C12,639/53; C10,851/54: The mesenteric and subcutaneous MCs of the rat undergo granule clumping and discharge following total body irradiation with doses of 600–1600 r. This change may be related to the disturbance in blood clotting induced by x-irradiation.

Arvy et al. D26,704/54; D26,833/54: In mice exposed to severe total-body x-irradiation, there develops a great increase in the MC count of the thymus, lymph nodes, Peyer's plaques, and bone marrow. Since this change is prevented by adrenalectomy but duplicated (even without irradiation) by cortisone, it is assumed to be a manifestation of the G.A.S. On the other hand, the local MC proliferation in the rat's ear, produced by the topical application of small doses of nonpenetrating x-rays, is independent of the adrenals and cannot be attributed to the G.A.S.

Pettersson D33,702/54: In the guinea-pig, the cutaneous MC count decreases sharply after total body x-irradiation. This change may be related to heparin production and the resulting blood-coagulation defect.

Baglioni C16,539/54, *p. 203*: Discussion.

Smith & Lewis C1,168/54: x-irradiation does not alter the total number of MCs in the skin and mesentery of the rat but greatly augments the percentage of abnormal forms (vacuolation and granule conglomeration).

Smith & Lewis B91,529/54: Following whole-body x-irradiation there is a decrease in the total number of MCs with vacuolation, granule clumping, and discharge in the cheek pouch of the hamster. The MC population does not return to normal until about one month after irradiation.

Mazza E54,977/54: Following x-irradiation, the MCs of the hibernating gland in rats show only minor variations. Allegedly, the metachromasia of the granules is increased. At the same time many metachromatic granules infiltrate the vascular walls, presumably following their discharge from MCs.

Fulton et al. D39,660/54: Total-body x-irradiation causes striking changes in the mesenteric MCs, but less pronounced degranulation of the cheek pouch MCs in the hamster. Pretreatment with mepyramine maleate i.p. offers some protection against both these changes.

Upton & Gude C3,289/54: Following total-body x-irradiation of the rat, the number of dermal MCs decreases concurrently with an increase in the spreading of intradermally-injected Evans blue.

Kelsall & Crabb D39,634/54: Total-body x-irradiation causes a pronounced diminution of the MCs in the Brunner's glands of the rat duodenum.

Hjelmman & Pettersson D39,850/55: In guinea-pigs in which the cutaneous MCs diminished as the result of x-irradiation, there was a concurrent, pronounced increase in the MCs of the hepatic connective tissue but not in the hepatic parenchyma itself. The rise in hepatic MCs is considered to be a compensatory phenomenon.

Smith & Lewis C11,751/55: Electron-microscopy shows that, following x-irradiation, the fine structure of the granules in the peritoneal MCs of the hamster and rat disappears.

Smith & Lewis C4,564/55: x-irradiation increases the percentage of abnormal MCs in the skin, mesentery, and cheek pouch of the hamster. This effect is not prevented by adrenalectomy or hypophysectomy.

Crabb & Kelsall D28,681/56: x-irradiation, like many other stressors, causes an increase in the MC population of the thymus in the hamster. However, "no increase in mast cells or PAS-positive material occurred in the liver, pancreas, salivary glands, spleen, mesentery, ovaries, uterus, testes, adrenal glands, or kidneys of the irradiated, starved, or protein-low group. This actual and delimited increase of mast cells after x-irradiation suggests that these cells contribute amino-sugars and sulfuric and glucuronic acids for collagen in the thymus, rather than heparin to blood."

Conte et al. C25,678/56: After 75 r of whole-body x-irradiation, there is a transient increase in the number of mesenteric MCs in the rat during the first 24 hours. This is followed by a slight decrease in the MC count. After larger doses of x-irradiation (150–600 r), the MCs show no increase in number at any time and the decrease in MC count lasts for at least 2 weeks after exposure.

Eisen et al. C26,528/56: Following x-irradiation, there is a rapid decrease in skin histamine accompanied by significant damage to the cutaneous MCs. On the other hand, the concurrent decrease in the histamine content of the stomach and jejunum is not associated with MC degeneration. "It is suggested that the fall in skin histamine is attributable to the concurrent degeneration of subcutaneous mast cells, but that the depletion of histamine in the alimentary canal is largely independent of changes in the mast cells."

Sannazzari D68,633/56: Following repeated x-irradiation, the MCs in the connective tissue of the mouse first tend to migrate towards the capillaries and then greatly increase in number.

Ito E57,790/56–57: Following x-irradiation, the MCs in the popliteal lymph node of the rat disintegrate.

Eisen & Wilson D65,095/57: In β-irradiated areas of abdominal skin in the rat, the MCs degenerate and the histamine content falls considerably.

Fulton et al. C35,831/57: Discussion.

Smith & Lewis D33,719/57: As judged by electron-microscopy, total body x-irradiation causes coalescence of the granules with loss of intragranular structure in the peritoneal MCs of the hamster and rat.

Guimaraes & Taylor D26,762/57: In rats given colloidal Au^{198}, i.v. or i.p., there develop hepatic necroses and multiple hemorrhages, particularly in the intestinal tract, lung and testes, such as are characteristic of the x-irradiation syndrome. In addition, the bone marrow of these animals contains an unusually large number of MCs, especially along the walls of the sinuses. These MCs are enlarged, vacuolated and lacerated but no anomaly is found in the MCs of the thymus (other organs were not investigated). The MCs may play a role in the post irradiation syndrome in which an increase in heparin production and a prolongation of the clotting time are prominent.

Shikhodirov D27,086/57: Heavy exposure to ionizing rays (x-irradiation, Sr^{89}, Sr^{90}) produces swelling and degranulation of the connective-tissue MCs throughout the body in the dog, rat, and mouse. Pretreatment with cysteine or "myelocytotoxic serum" can largely prevent both the irradiation disease and the MC disintegration.

Crabb & Kelsall D28,559/57: x-irradiation in the hamster causes an increase in the MC population of the thyroid and parathyroid glands, but in the adrenal gland, ovary and anterior pituitary gland, which normally contain no MCs in this species, x-irradiation does not cause them to appear.

Smith D63,176/58: Following x-irradiation, the MCs of the hamster cheek pouch and rat mesentery discharge their granules which are subsequently phagocytosed by fibroblasts, macrophages, and leukocytes.

Fan & Sikov D27,070/58: P^{32} i.p. at MLD^{50} does not significantly alter the number of cutaneous MCs in the rat. However, the metachromatic granules in the small cells of the superficial layer of the dermis become fewer and subsequently the cells become irregular and polymorphic. The changes reach a maximum after 7–10 days. These results appear to be in conflict with the previously-reported increase in MC count induced by other means of ionizing irradiation but the reason for this difference is not evident.

Smith & Lewis C72,227/58: Following partial x-irradiation of rats and hamsters, only the MCs in the non-shielded areas undergo disintegration. "The results of the partial body irradiations show clearly that damage to mast cells is the result of local injury rather than to some general systemic effect. This finding does not obviate the possibility that the adrenal-pituitary system may add to the irradiation effect."

Smith D27,082/58: Total body x-irradiation causes pronounced MC discharge in the mesentery and skin of the rat and hamster as well as in the cheek pouch of the hamster.

van den Brenk C59,465/58: In the rat, severe x-irradiation causes MC-changes morphologically different from those elicited by 48/80 and the x-ray-damaged cells can still respond with degranulation to the subsequent application of this histamine-liberator. Following x-irradiation, "simple coalescence of granules to form large inclusions (3–10μ in size) and clasmatosis, cell irregularity, cytoplasmic vacuolation and nuclear swelling, all fail to prevent the typical morphological response of the affected cell to 48/80 and suggest that such grossly altered cells are still viable."

Villavicencio & de Takats C56,397/58: X-irradiation — like bacterial toxins (pyrogen) and nitrogen mustard — causes intense vacuolation and degranulation of the mesenteric MCs in the rat. These changes may still be evident 25 days after exposure. Presumably the MC plays an important role in the defense against stress.

Hill & Praslička D26,723/58: Following total-body x-irradiation of the mouse, many new MCs are formed from reticulum cells in the spleen. Some of these MCs show lysis, others granule-discharge.

Dutta-Choudhuri & Roy D65,258/58–59: In rats treated with Fe^{59}, Au^{198} or x-ray (10^6V and 250 kV), the peritoneal MC count increased and the cells became particularly polymorph.

Pezzani & Verga C83,622/59; *Verga & Pezzani* C79,437/59; C83,626/59: In the rat, total body x-irradiation, irradiation of the body with the thymus shielded, or selective irradiation of the thymus only, produces essentially similar changes in the MCs of the mesenteric lymph nodes: during the first 24 hours the MCs become numerous, large, replete with granules, and often vacuolized. The increase in the number of MCs remains demonstrable even after 30 days and is particularly obvious when only the thymus is irradiated. "It may be thought that the involution of the thymus produces a compensatory hypoplasia in other lymphatic organs and that the increase in MC population is a consequence of the RES stimulation in these sites".

Since there was no corresponding increase in the MC population of any other organ, it was assumed that this response — which coincides with the thymolysis of the alarm reaction — plays an important part in the G.A.S.

Kelsall & Crabb D26,076/59, *pp. 75,111*: Discussion.

Calzavara et al. D13,495/60: X-irradiation causes degranulation followed by regranulation of the peritoneal MCs in the rat. The phenomenon is considered to be a manifestation of the alarm reaction.

Calzavara et al. D10,222/60: Peritoneal MC degranulation (associated with amitosis) occurs following x-irradiation in the rat. This is inhibited by pretreatment with hyaluronic acid and an antihistaminic (Fargan) while cortisone has no such protective effect.

Vasilenko et al. D39,687/60: In the connective tissue of x-irradiated mice, the MCs exhibit degenerative changes.

Kelsall D7,784/61: Total-body x-irradiation increases the MC count in the thymus of the hamster.

Csaba et al. D3,199/61: When a galvanic current is led through a rat, many MCs accumulate in the thymus and allegedly "some of the lobes underwent complete mast-cell transformation." Proliferation of thymic MCs was also seen after x-irradiation and particularly after combined treatment with the galvanic current and x-irradiation. The effect was ascribed to "stress-like stimuli."

Brinkman D26,693/62: Bone-marrow damage induced by x-irradiation tends to cause an increase in the MC population of human hemopoietic tissue.

Csaba et al. D79,388/62: MCs are produced in vitro within the explanted thymus of x-irradiated, or albumin-immunized rats, especially if the medium contains heparin. Some MCs also appear under these conditions in explanted lymph nodes but not in splenic tissue. However, the latter produces plasma cells. It is concluded "that the thymus is principally involved in states where the correlation between the tissues is disturbed: it produces acid mucopolysaccharides and mast cells. The spleen, on the other hand, has an important function in states of tissue immunity; it produces immune substances and plasma cells."

Detrick D63,287/63: Marked electron-microscopic changes are seen in the intestinal MCs of the rat following total body irradiation, which eventually causes MC-disruption with swelling of the mitochondria and local edema.

Bercovici & Graham D18,598/64: In mice subjected to 375–465 r of ionizing radiation delivered locally in one dose to the abdomen, the MCs in the peritoneal fluid increased at 15 minutes and at no time showed any evidence of damage.

VISIBLE LIGHT AND ULTRAVIOLET RAYS

McGovern D26,442/61: When the isolated peritoneal MCs of the rat are sensitized to light by hematoporphyrin, eosin or erythrosin, subsequent exposure to light causes them to lose their basophilic staining reaction. Mast cells so treated no longer release histamine upon treatment with 48/80. "These features seem to indicate that release of histamine from mast cells depends in some way on the presence of basophilia." Apart from these photo-sensitizing substances, which are active only on exposure to light, chlorpromazine and promethazine cause loss of MC basophilia in the dark, with enhancement of this property upon exposure to light. Heating likewise causes MCs to lose their basophilia and to become refractory to the action of 48/80. Reserpine affects MCs in the same way, but here, exposure to light has only a small enhancing effect.

Valtonen D26,623/61: Ultraviolet irradiation, in doses conducive to mild cutaneous inflammation, initially decreases and then increases the MC count in the ears of the mouse.

Valtonen & Kock D66,170/63: Ultra-violet irradiation increases the cutaneous MC count in the mouse.

ALLERGY (INCLUDING ANAPHYLAXIS, IMMUNITY, AND OTHER ANTIGEN-ANTIBODY REACTIONS)

(Cf. also ANAPHYLOTOXIN)

An MC discharge has been observed in association with a great variety of antigen-antibody reactions and, as we shall see later (*p.* 342), the blood basophils respond in essentially the same manner. It has been assumed, therefore, that

an MC discharge plays a decisive role in various hypersensitivity reactions, particularly through the release of histamine, heparin, and, in certain species, perhaps also 5-HT. It has also been postulated that MCs contain antibody since their discharge by antigen can be accomplished even in vitro, and antigen uptake by MCs could be demonstrated by the fluorescent antibody technique.

Certain observations suggest that the anaphylactic release of histamine in rats is produced by a particular type of antibody, different from the usual serum precipitating antibody and designated as "mast cell lytic antibody."

Yet, this relationship between MC discharge and anaphylaxis does not appear to be obligatory in all cases. For example, in the carp, horse serum does not produce an anaphylactic shock, yet it can cause MC degranulation. In the sensitized mouse, the injection of an antigen can cause typical systemic anaphylactic reactions without any widespread MC discharge although topical anaphylactic reactions are associated with MC degranulation even in this species.

Although the MCs of the dog liver undergo degranulation during anaphylactic shock, the same is not true of the lungs of guinea-pigs or rabbits, since in these, MCs are virtually absent. It has been concluded, therefore, that in the guinea-pig and rabbit, anaphylactically-discharged histamine is not of MC origin.

According to one hypothesis, antigen + antibody + complement form a labile degranulating substance which disrupts MCs and liberates histamine. The degranulating substance may be related to anaphylotoxin although the latter is presumably stable. In-vitro studies on the rat mesentery suggested that various enzyme inhibitors can prevent granule discharge by blocking protein NH_2-groups and SH-groups. 48/80 and antigen disrupt MCs by activating a lytic enzyme attached to the MC membrane, while decylamine and related surface active agents disrupt MCs by a nonenzymatic mechanism not subject to similar blockade. In any event, there appears to be some fundamental difference between the MC discharging effect of 48/80 and of anaphylaxis, since the latter releases histamine only from intact MCs while 48/80 can discharge it even from isolated MC granules.

Both in the rat and in the mouse, passive anaphylaxis is unaccompanied by MC damage or histamine release and thereby differs from active anaphylaxis.

Several observations suggest that activation of the chymotrypsin-like enzyme is a necessary condition for the anaphylactic release of histamine from rat MCs.

On the other hand, inhibition of chymotrypsin-like enzyme does not inhibit histamine release from sensitized rat peritoneal MCs during anaphylaxis in vitro. From this it was concluded that the chymotrypsin-like enzyme in MCs is not involved in the anaphylactic reaction.

When nearly all MCs are discharged by 48/80, rats may remain as susceptible to anaphylaxis as unpretreated controls.

Certain antihistaminics protect the MCs against anaphylactically-induced degranulation. From this it was concluded that the function of MCs may actually be to protect against anaphylaxis, but several investigators were unable to prevent the anaphylactically-induced MC degranulation by antihistaminics.

Tanon D27,445/09: MCs are unusually abundant in the immediate vicinity of vaccination pustules and, allegedly, the potency of the vaccine roughly parallels the number of accumulating MCs. Hence, the latter are assumed to "produce a specific secretion related to defense."

Carvalho D27,504/22: Earlier investigators claimed that during antirabies vaccination, the number of blood basophils increases and that this indicates a participation of MCs in the development of immunity. These results could not be confirmed.

COLOR PLATES

PLATES I-V

PLATE I

A: Subcutaneous tissue at a distance from the polymyxin injection site shows no MC degranulation and no iron deposits are visible on the wall of the small vessel (Berlin blue-neutral red, × 460).

B: Five minutes after polymyxin administration the MCs at the injection site are degranulated and the walls of the small subcutaneous vessels are strongly impregnated with iron (Berlin blue-neutral red, × 460).

C: Twenty-four hours after polymyxin injection, these same small vessels already exhibit a strong phosphate + carbon reaction at the injection site (von Kóssa-azure A, × 460).

D: Following large doses of polymyxin (500 μg), many of the discharged metachromatic MC granules (violet) are seen to be impregnated with calcium particles (dark brown or black) (von Kóssa-azure A, × 460).

After *Selye et al.* E24,138/64, by courtesy of *Virchows Archiv für pathologische Anatomie und Physiologie und für klinische Medizin*

PLATE I

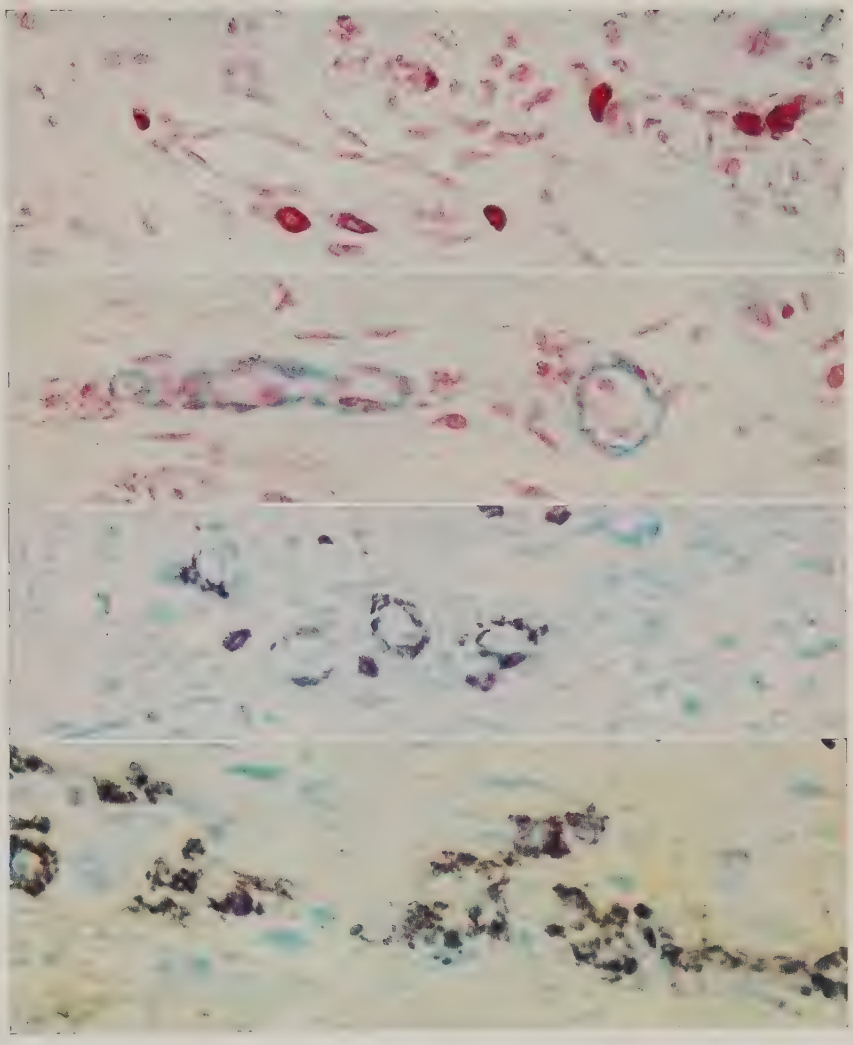

PLATE II

The "cephalo-nuchal syndrome." **A:** Normal MC distribution in the calvarial periosteum. **B:** DHT, 1 mg p.o. first day + Fe-Dex (= 1 mg Fe) i.v. second day + polymyxin, 2 mg s.c. in lumbar region second day. Intense discharge and calcification of MC granules 24 hours after injection of Fe-Dex + polymyxin. (**A** and **B** both periosteal spread technique, von Kóssa-azure, × 120.) **C** and **D:** Individual MCs from **B**, under higher magnification. Non-calcified metachromatic MC granules (purple), intermixed with calcified granules (von Kóssa-azure, × 1000). **E:** In somewhat more advanced stage, some of the MC granules are still recognizable (upper left) while in the three large MC groups, the calcium is already attached to the adjacent connective-tissue fibers (von Kóssa-azure, × 460).

Calcifying anaphylactoid reaction. DHT, 1 mg p.o. first day, Fe-Din (= 5 mg Fe) i.v. second day. Killed 24 hours after Fe-Din injection. **F:** Ferrification predominantly affecting small blood-vessel walls in lips (Prussian blue-neutral red, × 460). **G:** Similar preparation showing MC calcification in lip (von Kóssa-azure, × 460).

After *Selye et al.* E24,139/64, by courtesy of *Annals of Allergy*

PLATE II

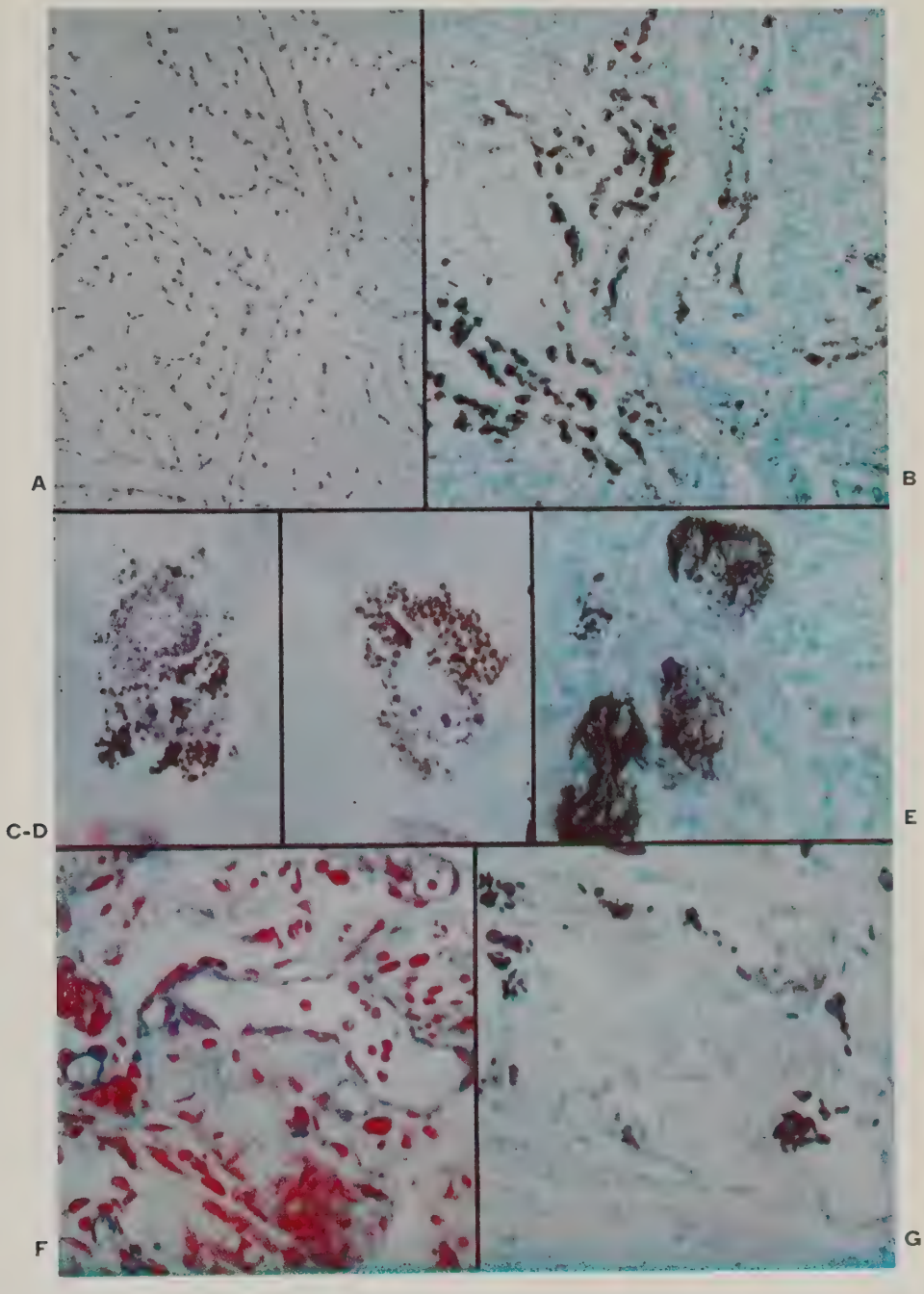

PLATE III

Purely local mastocalciphylaxis. DHT, 1 mg p.o. first day + Fe-Dex (= 50 μg Fe) s.c. second day. Killed 60 minutes after injection. **A:** Perivascular MCS showing degranulation and iron (here blue) accumulation. (Prussian blue-neutral red, $\times$ 1200.) **B:** Normal perivascular MCS of the animal shown in **A** but at a distance from the injection site. (Prussian blue-neutral red, $\times$ 1200.)

Local calciphylaxis. DHT, 1 mg p.o. first day + Fe-Cl_3 , 50 μg s.c. over calvarium. Two adjacent regions of calvarial periosteum. **C:** Calcification of collagen fibers (black) in a comparatively avascular territory. **D:** Intense calcification of blood vessels. In both specimens, the MCS appear to be unaffected. (Periosteal-spread technique, von Kóssa-azure, $\times$ 120).

After *Selye et al.* E24,139/64, by courtesy of *Annals of Allergy*

PLATE III

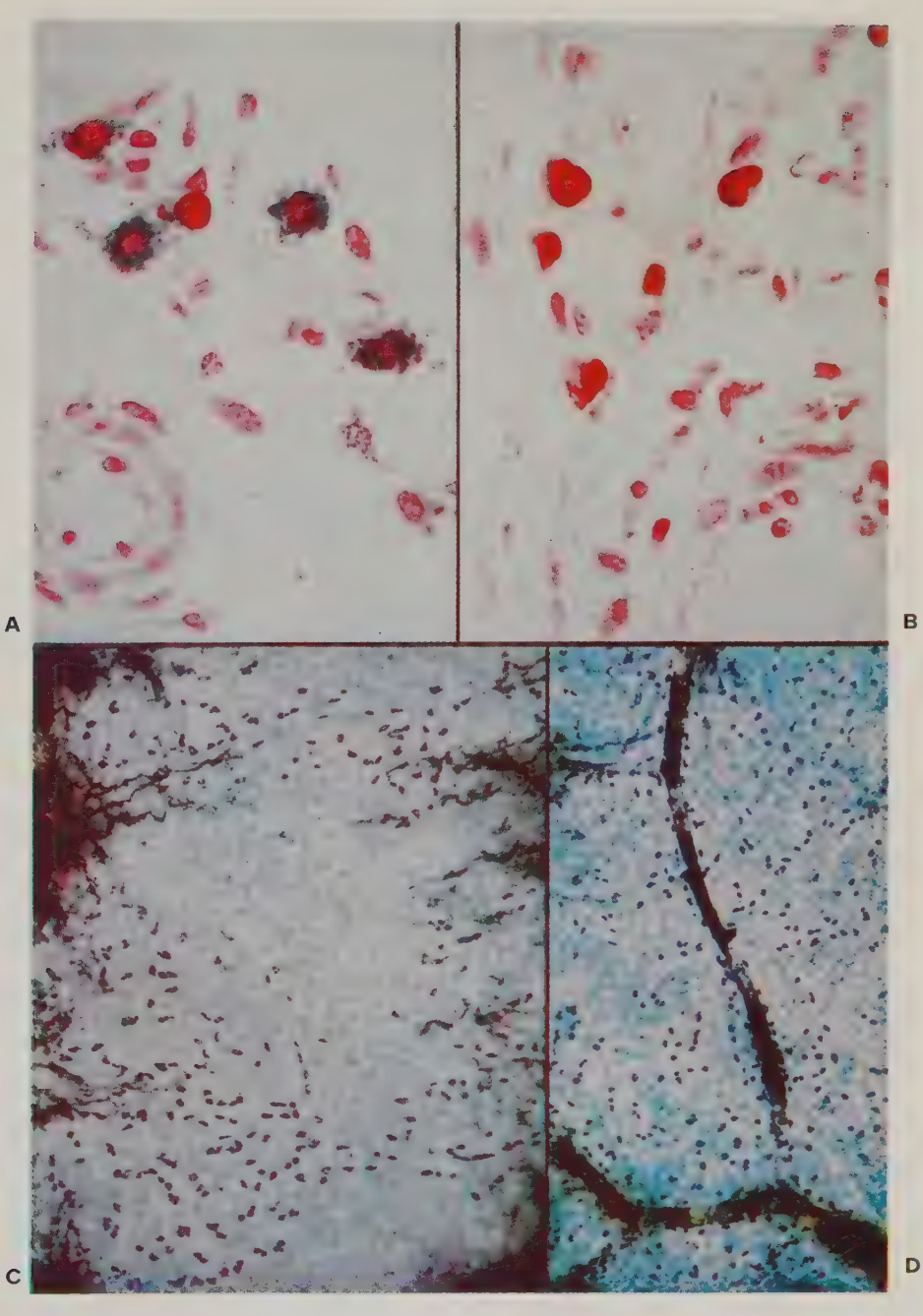

PLATE IV

Mastocalcergy induced by lead acetate i.v. and polymyxin s.c. A: Discharged MCS around a blood vessel 5 minutes after topical injection of polymyxin. No sign of mineralization (von Kóssa + azure, × 460). **B:** Normal perivascular MCS above the cutaneous muscle in the animals shown in **A**, but in the area removed from the polymyxin injection site (von Kóssa + azure, × 460).

C and **D:** Sixty minutes after polymyxin injection the MCS contain reddish-brown lead granules in the injection area (rhodizonate, × 460). **E:** Normal MCS in an area adjacent to that shown in **C** and **D** (rhodizonate, × 460).

F: Five hours after polymyxin injection the topical MCS are discharged and most of their metachromatic granules exhibit a positive von Kóssa reaction (von Kóssa + azure, × 460). **G:** Higher magnification of a completely disintegrated MC group from the specimen shown in **F.** Some of the calcified MC granules exhibit the characteristic light central area (von Kóssa + azure oil emersion, × 1200).

After *Selye et al.* E24,136/64, by courtesy of *Journal of Histochemistry and Cytochemistry*

PLATE IV

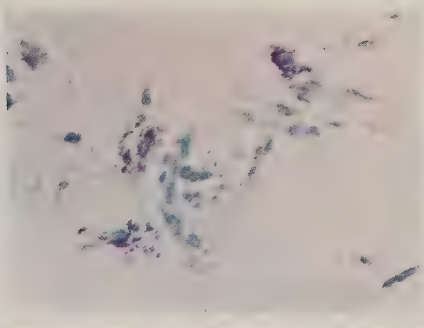

A

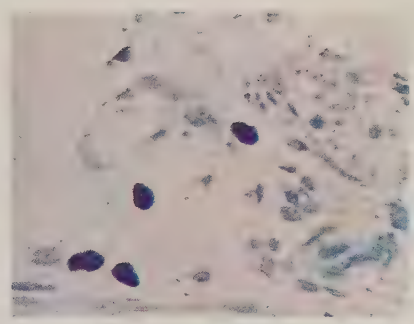

B

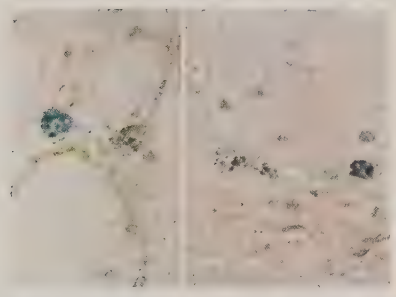

C-D

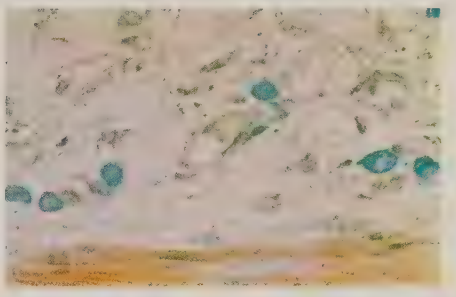

E

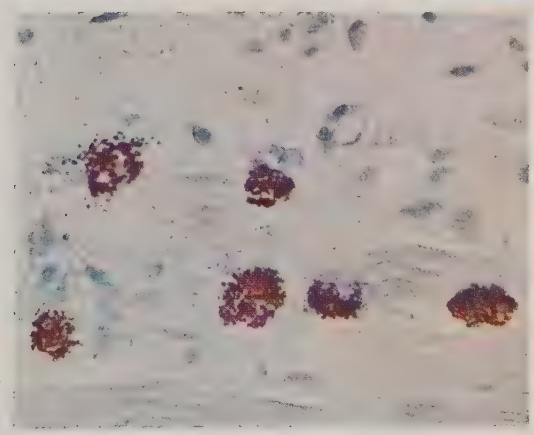

F



G

PLATE V

A: Lip of a rat treated with iron-dextran complex intravenously and killed two minutes after the injection. Iron appears intracellularly (Prussian blue + neutral red, × 460).

B: The same field as in **A**; the slide was immersed in ammonium sulfide (1 ml of the light solution in 50 ml of 95% alcohol) for two minutes to abolish the iron stain and then re-stained for metachromatic material. Comparison of the two pictures indicates that iron is present in MCS (cresyl violet, × 460).

After *Gabbiani & Nielson*, G11, 130/64, by courtesy of *A.M.A. Archives of Pathology*

PLATE V

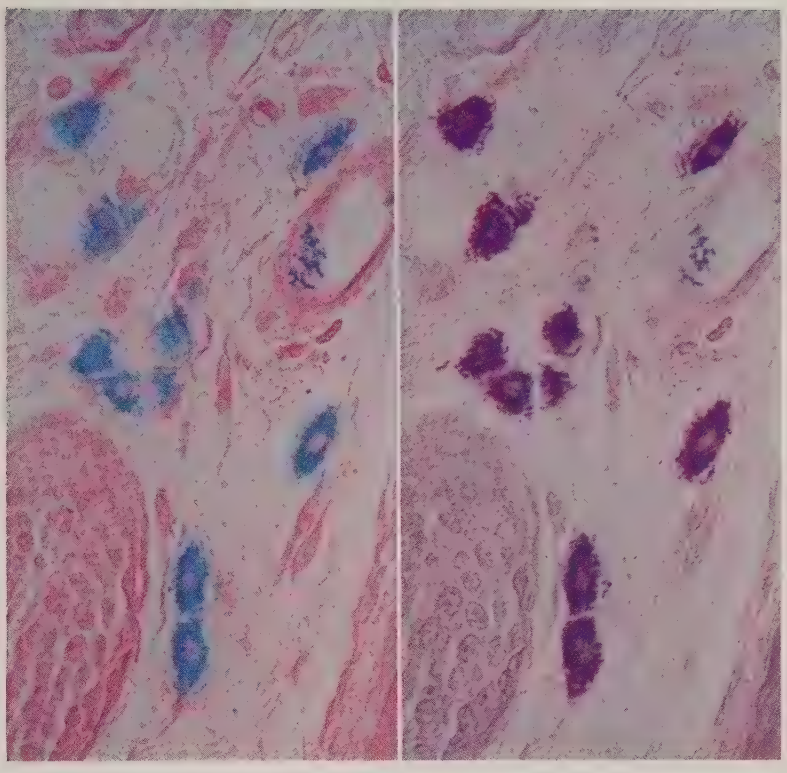

A B

Tsuda D27,349/23: At the site of s.c. inoculation with various cocci, the MCs of the mouse discharge their granules. The response is much less pronounced in immunized animals; to a still lesser extent, it can also be elicited by physiologic saline solution.

Jaques & Waters B40,648/41: By means of the protamine titration procedure, it is shown that, during anaphylactic shock, the dog liberates large quantities of heparin into the blood, that this heparinemia does not occur in hepatectomized dogs although the ulcers show anaphylactic shock, and that concurrently with shock symptoms in the normal animal, the heparin and MC content of the liver decreases acutely.

Olsen & Smith D39,507/49: Of many substances tested, only foreign proteins, protamines, peptones, turpentine, methylcholanthrene, 2,4-dibenzanthracene, caused topical MC-degranulation upon introduction into the popliteal lymph nodes of the rat. "The presence of a 'mast-cell reaction' in the popliteal lymph nodes of rats and the in vitro precipitation by heparin of antigenic proteins but not of components of the coagulation mechanism, suggest that heparin, in addition to its participation in blood coagulation, may be intimately associated with the mechanisms of immunity."

Veil & Gabe D33,689/50: It is not possible to elicit a typical anaphylactic shock by horse serum in the carp (*Cyprinus carpio*), yet the antigen induces a degranulation of the MCs in the pigmented portion of the cutaneous scales.

Stuart D2,340/51; D15,089/52: In rabbits, guinea-pigs, dogs, and mice, in which anaphylactic shock was induced by egg albumin, the organs most affected by anaphylaxis were those richest in MCs and, here, these cells show marked degranulation. These changes are diminished if anaphylaxis is prevented by pretreatment with antihistaminics. "These correlations suggest that the mast cell acts as a defense mechanism against alterations induced by anaphylaxis."

Fink & Rothlauf D31,599/55: When the uterus of an ovalbumen-sensitized virginal mouse is exposed to the antigen in the Schultz-Dale test, the in-vitro anaphylactic shock (manifested by contractions) is not accompanied by any detectable change in the morphology of the abundant uterine MCs.

Speirs et al. C10,808/56: The peritoneal MCs show no significant change following i.p. administration of various antigens to normal or sensitized mice, either in the presence or in the absence of the adrenal glands.

Mongar & Schild D27,601/56: While 48/80 releases histamine only from intact guinea-pig MCs in vitro, antigen (ovalbumen) releases histamine even from isolated MC granules of sensitized guinea-pigs.

Higginbotham et al. D15,838/56: Injection of a mild antigen (horse serum) into the connective tissue of sensitized mice produces a rapid and marked degranulation of the local MCs: in nonsensitized animals the same antigen is inactive.

Speirs & Wenck C34,890/57: In the mouse, reinjection of pollen as an antigen fails to affect the peritoneal MCs.

Keller C54,750/57: In the rat, after sensitization with an antigen (anti-rat-connective-tissue rabbit serum), the same antigen i.v. causes degranulation of the peritoneal MCs, with an increase in histamine excretion.

Mota D27,088/57: In rats, anaphylactic shock (using horse serum as an antigen) unlike anaphylotoxin, produced MC-disruption in the snout, tongue, and ears. The mesenteric MCs of the sensitized rat were also disrupted when incubated with antigen in vitro. The plasma histamine reaches a maximum about five minutes after injection of the antigen. Antihistamines protect the rat against anaphylactic shock but not against MC disruption. Pretreatment with 48/80 protects against anaphylactic shock and the rise in plasma histamine. "Probably nearly all the histamine liberated in anaphylaxis in rats comes from the mast cells."

Inderbitzen & Craps C38,962/57: In rats, passive, cutaneous, allergic reactions of the immediate type were induced by intracutaneous injection of globulins from ovalbumen-immunized rabbits, followed three hours later by the same antigen i.v. with pontamine blue added to test vascular permeability. Under these conditions, there is only very moderate histamine, 5 HT, and MC-granule discharge irrespective of the ensuing anaphylactic reaction and increase in vascular permeability. The response is not blocked by pretreatment with BOL 148 and pyrilamine maleate although the former blocks the increased vascular permeability caused by 5–HT injection and the latter that is caused by histamine injection. It is concluded that passive cutaneous anaphylaxis "cannot be explained only with an action of chemical mediators (histamine, 5-hydroxytryptamine) which are set free from the tissues in the process of this reaction."

Carter et al. D28,263/57: In mice, sensitized by horse serum s.c. on the belly, subsequent injection of the antigen into a dorsal air-pouch (modified granuloma pouch technique) causes intense local MC-degranulation. This is not nearly as obvious in nonsensitized controls. The discharged MC granules stain red with metachromatic dyes whereas, after discharge by 48/80, they stain purplish or blue.

Veil E62,531/57: The MCs in the scales of various fish (carp, roach) show degranulation under the influence of anaphylaxis.

Mota C61,610/58: Rats can be rendered sensitive to anaphylaxis by inoculation with *Hemophilus pertussis* conjointly with an antigen such as horse serum. When a second injection of horse serum is given 10 days later, it causes a typical anaphylaxis with pronounced disruption of MCs in the snout and an increase in blood histamine.

Mota D26,425/58; D26,755/59: When minced lung tissue or a piece of mesentery from a sensitized guinea-pig is incubated with antigen, MC-degranulation and disappearance ensues within 15 seconds. By contrast, histamine-dischargers (e.g., octylamine) cause fusion and clumping of granules without degranulation. Furthermore, the MC alterations produced by anaphylaxis, unlike those caused by the histamine releaser, are prevented by heating the tissue to 45°C, by lack of calcium, as well as by iodoacetate and phenol. There is a close parallelism between the effect of these agents on MCs and on histamine release. "The morphological alterations induced by octylamine suggest that this base combines directly with the metachromatic material in the granules, and in doing so produces a complete disorganization of the granular structure with subsequent histamine release. A similar mechanism of action was postulated by MacIntosh [D27,093/56] based on experiments with intracellular particles. . . . Since mast cell alterations are produced by the action of the antigen both in vivo [*Mota & Vugman* D27,087/56; *Mota* D27,088/57] and in vitro, it seems probable that the mast cells contain antibody and play an important role in anaphylaxis. . . ."

Humphrey & Mota D26,066/59: MC regranulation occurs whenever tissues of sensitized guinea-pigs are brought in contact with antigen in vivo or in vitro. In passively sensitized guinea-pigs, the MC-response is well correlated with the development of anaphylactic shock. After multiple sensitization, the antigen causes cumulative, though incomplete, disappearance of MCs.

Archer C78,034/59: When mouse ascites tumor cells, and fresh anti-serum prepared in rabbits against these cells, are incubated, a substance appears in the serum which causes MC-disintegration and histamine liberation from isolated peritoneal rat MCs. A similar phenomenon was observed with human white cells and fresh anti-human-white-cell serum prepared in rabbits.

Smith D26,773/59: Although the MCs of the dog liver undergo degranulation during anaphylactic shock, "The same is not true of the lung of the guinea-pig or rabbit, since, contrary to Stuart's [D15,089/52] suggestions, in these experiments mast cells appeared to be absent from the respective shock organs. It thus seems not unlikely that the histamine which causes rapid onset of fatal bronchoconstriction in the guinea-pig during anaphylaxis is derived from some structure other than the connective-tissue mast cell. Anaphylactic histamine in the rabbit is also most probably not of mast cell origin."

Welsh & Geer D39,505/59: Following 48/80 i.p., the granules discharged from the peritoneal MCs of the rat, are taken up by eosinophilic leukocytes, as judged by electron-microscopic observations. This phenomenon may play a role in histamine release and allergic inflammation. "It is suggested that the phagocytosis of mast cell granules may be the basis for the 'basophilic bodies' seen in circulating eosinophils in human subjects."

Bryan & Bryan D26,624/59: The MC count in the nasal secretion of man increases considerably in certain types of food allergy. Indeed, it has been suggested that "the findings of an increase in mast cells in nasal secretions may suggest food allergy."

Uvnäs & Thon D26,067/59: Isolated peritoneal MCs of both sensitized and nonsensitized rats release their histamine under the influence of 48/80, but only the sensitized cells act in this manner upon treatment with the antigen (horse serum). This observation suggests that antibodies are localized in the MCs themselves.

Boréus & Chakravarty C86,027/59: When an anaphylactic reaction is produced in vitro in isolated guinea-pig tissues, histamine and slow reacting substance (SRS) is liberated in amounts proportional to the MC population of the region in question. Blocking of histamine and SRS production by enzyme inhibitors also prevents MC-degranulation. "It is suggested that the tissue mast cells may be the common source of both histamine and 'SRS' in anaphylactic reaction."

Archer D26,625/60: The peritoneal MCs of the rat discharge their granules and histamine within 2–3 minutes after antigen (human red cells), fresh anti-serum (from rats immunized with human red cells) and MCs are placed together at 37°C and *p*H 7. The degranulation is ascribed to a heat labile substance which at 37°C disappears within 10 minutes. This substance is not formed if the immune serum was heated or treated with hydrazine to inactivate complement. The following sequence of events is postulated: antigen + antibody + complement form a labile degranulating substance which disrupts MCs and liberates histamine. The relation of the degranulating substance to anaphylotoxin is not clear since the latter is presumably stable.

Mota & Ishii D26,569/60: In-vitro observations on the skin and mesentery of rats, sensitized by various antigens, reveals that the subsequent induction of an anaphylactic reaction, by exposure of the tissues to the antigen, causes MC-damage with histamine release. Both these phenomena are inhibited by various metabolic inhibitors, antipyretics, lack of calcium in the medium and previous heating of the tissue to 45°C. Contrary to the authors' earlier observations on guinea-pigs, the MC damage produced by antigen in sensitized rats is morphologically similar to that induced by 48/80, both agents causing extrusion of granules. Since, furthermore, both antigen (after sensitization) and histamine liberators can be blocked by the same agents as regards their actions upon MCs and histamine release "it is suggested that in rats the histamine-releasing mechanism of the antigen-antibody reaction in anaphylaxis is very similar to that of compound 48/80."

Mota et al. D30,208/60: "In rats and guinea-pigs, both mast cell damage and histamine release in anaphylaxis were inhibited by pyridine, nicotinamide, diethylnicotinamide, nicotinic acid, isonicotinic acid and isonicotinic acid hydrazide, which are known to be inhibitors of diphosphopyridine nucleotidases. On the other hand, these compounds potentiated histamine release and mast cell damage by compound 48/80 in guinea pigs although inhibiting the same phenomena in rats." Apparently, in the rat, the mechanism of histamine release by compound 48/80 and antigen is more closely related than in the guinea-pig.

Uvnäs D26,479/60: When the peritoneal MCs of the rat are treated with an extract of the stinging jellyfish, *Cyanea capillata,* they release both their histamine and their metachromatic granules. "Similar principles probably occur also in shellfish, strawberries, and other agents known to cause allergic reactions in hypersensitive individuals." Here, we are manifestly dealing with a naturally occurring histamine liberator and MC-discharger.

Mota & da Silva D26,065/60: Rats were sensitized with horse serum and *Hemophilus pertussis* vaccine for the subsequent isolation of their peritoneal MCs. The fact "that washed isolated mast cells taken from sensitized animals are still able to respond to the specific antigen strongly suggests that mast cells contain antibodies and that damage induced to these cells in anaphylaxis is the consequence of an antigen-antibody reaction occurring in the mast cell itself."

Tokuda & Weiser D26,827/60: In the mouse, injection of antigen-antibody complex into the connective tissue (pneumoderma technique) produces MC-degranulation equal to that elicited by antigen alone or antibody alone. Hence, no conclusions can be drawn from these experiments concerning the participation of the MCs in immune reactions. The mesenteric MCs of sensitized mice, which died following subsequent challenge by pertussis vaccine, "likewise gave no indication that morphologic changes in mast cells accompany anaphylaxis." This is all the more noteworthy, since in these same mice, protection against anaphylaxis was afforded by pre-challenge treatment with reserpine and various 5–HT antagonists, suggesting that 5–HT liberation does play a part in the anaphylactic response of the mouse. These observations are contrary to earlier findings in which anaphylaxis was associated with MC degranulation. It is pointed out, however, that, since release of mediators from MCs can take place without apparent morphological change (*Parratt & West* C37,858/57; *Smith* C54,403/58) "the present results do not provide certain evidence that 5–HT is not released by challenge."

Högberg & Uvnäs D26,422/60: Studies on the rat mesentery in vitro indicate that 48/80, decylamine, lecithinase, and antigen (after sensitization) disrupt the MCs. "A *p*H optimum around 7.4, the essentiality of Ca^{++} ions, the influence of temperature and the inhibitory action of various enzyme inhibitors, especially those blocking protein NH_2 groups and SH-groups, supported the view that compound 48/80 and antigen disrupt the mast cells by activating a lytic enzyme attached to the mast cell membrane. Decylamine, on the other hand, is a surface active agent that disrupts mast cells by a non-enzymatic mechanism."

Boréus D26,859/60; E27,594/60: In sensitized guinea-pigs, intracarotid injection of antigen produces a degranulation of the MCs in the nasal mucosa which can be prevented by

antigen s.c. from one hour to two weeks prior to the intra-arterial challenge. "Desensitization with one antigen (egg albumin) did not influence the sensitivity of the mast cells to another antigen (horse serum) and vice versa in double-sensitized animals. In all experiments the inhibition of mast-cell reactivity to antigen corresponded to an inhibition of the general anaphylactic symptoms."

Boréus & Chakravarty D26,646/60: The anaphylactic histamine liberation, following antigen-antibody reaction in vitro, corresponds quite closely to the MC depletion in various organs increasing in the following order: trachea, uterus, nasal mucosa, aorta. On the assumption that all the histamine is localized in the MCs, it is calculated that each cell in these organs of the guinea-pig contains 25–34 $\mu\mu$g of histamine base and releases 12–17 $\mu\mu$g in the course of an anaphylactic reaction.

Kraft & Kirsner D33,708/60: "The known association of mast cell degranulation with a variety of immunologic reactions raises the question of mastocyte involvement in granulomatous disease of the gastrointestinal tract, regional enteritis, and ulcerative colitis."

Boréus D12,234/61: In guinea-pigs, sensitized with crystalline ovalbumen, intra-arterial challenge with the antigen produces extensive MC-disruption in the nasal mucosa. This depletion is maintained at the original low level for 3 weeks and then begins to rise, but does not reach normal values until the 7th week. Neither ACTH nor cortisone (given in high doses) prevent this MC-disruption or the associated anaphylactic inflammation.

Craps D12,408/61: Passive cutaneous anaphylaxis produces only moderate MC-degranulation and histamine as well as 5–HT liberation in the guinea-pig and rat.

Mota D10,505/61: It is known that soluble antigen-antibody complexes, preparing excess antigen, produce anaphylactic shock when injected into nonsensitized guinea-pigs or rats. Since anaphylactic shock, produced in sensitized animals by the reinjection of antigen, usually causes MC-disruption with histamine discharge, it is noteworthy that clinically similar manifestations, produced by antigen-antibody complexes in nonsensitized rats or guinea-pigs, are not accompanied either by histamine discharge or by MC disruption. This is true even when the antigen-antibody complexes are applied to guinea-pig lung or mesentery in vitro. Presumably soluble antigen-antibody complexes do not act preferentially by releasing histamine from the MCs.

Mota D27,900/61: "As a working hypothesis, we think that rat anaphylaxis is brought about by two different antigen-antibody reactions: (*a*) the reaction of antigen with precipitating antibodies — that do not cause mast cell damage; (*b*) the reaction of antigen with 'mast cell lytic antibodies,' which are responsible for the anaphylactic release of histamine. It seems that rats produce normally both types of antibodies and that, depending on the condition of immunization, one of these types of antibody would predominate over the other. Thus, rats sensitized with Freund's adjuvant would produce predominantly precipitating antibodies while rats injected with *B. pertussis* along with the sensitizing dose of antigen, would produce predominantly 'mast cell lytic antibodies.' "

Archer D16,849/61: In vivo and in vitro observations on various species show that MC-disruption can be induced following an antigen-antibody reaction, provided complement is present.

Archer D26,441/61: Contact with an antigen-antibody mixture, consisting of human erythrocytes and fresh rat serum, disrupts the isolated peritoneal MCs of the rat without disrupting the granules themselves.

Archer D26,443/61: When isolated rat peritoneal MCs are treated with human erythrocytes mixed with fresh rat antiserum under suitable conditions, the MCs discharge their granules and a 5–HT-like substance with the physiologic properties of SRS is discharged into the medium.

Larsen D33,726/61: Intra-ocular injection of horse serum in rabbits produces an uveitis with intense discharge of MC granules and a simultaneous appearance of lymphocytoid, plasmacytoid and histiocytoid elements which contain metachromatic granules. Under these circumstances, uveitis occasionally appears also in the contralateral non-injected eye. Since here antigen was applied only once, the allergic nature of the lesion may be in doubt, but other investigators have observed the appearance of circulating antibodies and the condition is attributed to a delayed hypersensitivity reaction. There is some evidence in the literature that MCs may contain (and perhaps produce) antibodies, and that a polysaccharide complex may result in autosensitization.

Smith & Lewis D2,416/61: By immunizing rabbits with rat peritoneal MCs, it is possible to obtain a serum which, upon i.p. injection into rats, destroys all the MCs in the mesentery

and the majority of MCs in the ear, scrotum and abdominal skin. Simultaneously, there develops a typical anaphylactoid inflammation in the snout, ears, scrotum and feet, while the histamine content of the tissues drops sharply. Curiously, the 5–HT content rises considerably above normal when the histamine and MC-content of the tissues are lowest.

Keller D26,631/61: In rats, sensitized with ovalbumen or horse serum plus pertussis vaccine, the peritoneal MCs are collected 4–6 weeks later and then exposed to the antigen in vitro. Within a few seconds after treatment with the antigen in vitro, the MCs (examined with the phase-contrast microscope) swell, discharge their granules and become vacuolated. These changes are similar to those undergone by MCs during anaphylaxis in vivo. The temperature optimum of the reaction is between 36°C and 42°C. At temperatures above 45°C, or below 26°C, the process is completely blocked. Treatment with 1-fluoro-2-4-dinitrobenzol, zinc chloride and iodoacetic acid likewise block this reaction. "These observations speak in favor of the assumption that the mastocyte changes, induced by anaphylaxis, result from a cell-damaging antigen-antibody reaction within the cells themselves."

Keller & Schwarz-Speck D25,586/61: "Rabbit anti-rat serum produces in vitro characteristic morphological changes in rat mast cells isolated from the peritoneal cavity. The changes are temperature-dependent and are prevented by substances which inhibit enzyme action. Removal of complement also prevents these alterations. Isolated mast cells from rats are not passively sensitized by incubation with rabbit anti-ovalbumin serum."

Yamura & Watanabe D58,429/61: The isolated peritoneal MCs of the rat discharge their granules and histamine, following in vitro exposure to an antigen against which they have been immunized in vivo.

Keller & Beeger D25,638/61: Rat peritoneal MCs, sensitized with horse serum or ovalbumen, discharge their granules upon contact with the antigen, while this is not the case with MCs of nonsensitized controls.

Keller D26,836/62: When isolated rat peritoneal MCs are incubated with anti-rat serum, anti-rat-γ-globulin, or anti-rat-albumin, the greatest histamine release is obtained by the γ-globulin serum. Total anti-rat serum is less effective while anti-rat-albumin is ineffective.

Keller D27,706/62: A critical review of the literature leads to the conclusion that "it appears that mast-cell damage occurring in anaphylaxis is due to an antigen-antibody reaction on the surface of cells. This reaction is dependent on temperature, *p*H value and ionic strength, requires complement and may be inhibited by a number of substances having enzyme-inhibiting properties."

Burnet D33,851/62: In a strain of mice in which an auto-immune type of hemolytic anemia develops spontaneously, the thymus is enlarged and incomplete lymph follicles, as well as plasma cells and MCs, accumulate in its medullary portion.

Shelley & Caro D36,685/62: When the blood of ovalbumen-sensitized rabbits is exposed to ovalbumen in vitro, the basophils show explosive degranulation. A similar response is obtained by reinjection of the antigen in vivo. Apparently, "the basophil is a key target cell in the immediate type of hypersensitivity. Just as the mast cell, it releases its granules of histamine-heparin complex and this thus appears to be the cellular basis for the prime cardinal sign of anaphylaxis. It becomes evident that the functional status of the 'MB (mastocyte-basophil)' system at any given time determines the potential for anaphylaxis."

Gözsy & Kátó D36,811/62: After depletion of the MCs by 48/80 or polymixin in rats sensitized by horse serum, only mild anaphylactic shock can be produced by the re-injection of the antigen. It is thought that antibody formation occurs within the MCs and is, hence, impeded after degranulation of the latter.

Kátó & Gözsy D36,810/62: As judged by observation with the "transparent skin" technique, the MCs of the rat disintegrate during anaphylactic challenge and it is thought that the antigen-antibody reaction occurs within the MCs. [The six-line report gives no details (*H.S.*).]

Kátó & Gözsy D30,617/62; *Gözsy & Kátó* D56,953/62: In rats, sensitized by horse serum with pertussis vaccine i.p., anaphylactic shock is produced by horse serum i.v. given a few days later. The resulting MC discharge in the paws, abdominal skin, and mesentery is much greater in rats that die from anaphylactic shock than in survivors.

Austen & Humphrey D44,506/62: Rabbit anti-rat ϒ-globulin consistently released histamine from normal rat mesentery or from peritoneal MCs. Under these conditions, the MCs "bubble" as seen under the phase microscope due to the appearance and disappearance of vacuoles.

Johnson D39,569/62: As judged by observations on allergic patients "there is no definite correlation of presence of mast cells in the nasal smear with positive scratch skin test reaction to food, nor with a history of food allergy".

Keller & Mühlethaler D58,042/62: Normal rat peritoneal MCs, exposed for only 1–2 minutes to rabbit anti-rat serum, exhibit an anaphylactic granule discharge verifiable with the electron-microscope. There is first a swelling of the cytoplasm, which pushes the granules apart, and then disruption of the cell and granule membranes.

Mota G12,259/62: In mice and rats passive anaphylaxis is unaccompanied by MC damage or histamine release and thereby differs from active anaphylaxis. Pretreatment with *Bordetella pertussis* enhances MC damage and histamine release in active but not in passive anaphylaxis of rats and mice. Even injections of soluble antigen-antibody complexes do not reproduce the MC-damage and histamine release found in active anaphylaxis in these species. "It is suggested that the mast cell damage and histamine release in active anaphylaxis of rats and mice is due to non-precipitating antibodies of an unknown nature and that anaphylaxis in passively sensitized rats and mice is the consequence of interaction of antigen with precipitating antibodies which do not lead to mast cell damage or histamine release in these species."

Csaba et al. D79,388/62: MCs are produced in vitro within the explanted thymus of x-irradiated or albumin-immunized rats, especially if the medium contains heparin. Some MCs also appear under these conditions in explanted lymph nodes, but not in splenic tissue which produces only plasma cells. It is concluded "that the thymus is principally involved in states where the correlation between the tissues is disturbed: it produces acid mucopolysaccharides and mast cells. The spleen, on the other hand, has an important function in states of tissue immunity; it produces immune substances and plasma cells."

Csaba et al. E36,438/63: During immunization with ovalbumen, rat thymus reacts with an increased production of plasma cells and MCs.

Briggs E21,583/63: The granuloma-pouch technique was used to study the reactions of the connective-tissue MCs in the mouse during allergic reactions. MC-degranulation was observed following challenge in mice actively or passively immunized against *Trichinella spiralis*. On the other hand, "mice infected with *Trichinella* and sensitive to homologous antigens were not markedly reactive to heterologous somatic antigens from *Strongyloides ratti* and *Nippostrongylus braziliensis*."

Humphrey et al. D68,120/63: "The addition of antigen to rat mesentery or peritoneal mast cells from actively sensitized rats did not produce histamine release even though the donor animals had high levels of circulating antibody and exhibited anaphylactic shock with each intravenous booster dose of alum-precipitated antigen. The finding that these tissue or cell preparations from actively sensitized rats reacted with anti-RGG (anti-rat γ-globulin) indicated that either the cells did not carry γ-globulin identical with the antibody in their circulation or that the antibody was biologically inert in terms of releasing histamine after interaction with antigen."

Keller E36,439/63: "Cytolysis of normal isolated peritoneal mast cells of albino rats by rabbit anti-rat globulin serum occurs only if active complement is present."

Keller E32,257/63: During anaphylaxis, lysophosphatides are formed in the rat MCs.

Keller & Sorkin E31,032/63: Isolated rat peritoneal MCs were incubated with antibodies. "The results demonstrate that mast cells, liver, spleen, lymph node and red blood cells of the albino rat treated in vitro with rabbit antiserum against human serum albumin are capable of specifically absorbing ^{131}I–HSa." Apparently MCs can absorb antibody but they share this property with many other cells.

Keller & Beeger D39,842/63: The release of histamine by specific antibody from isolated rat peritoneal MCs has been used to investigate the effect of various peptidase substrates and inhibitors on anaphylaxis. No slow-reacting substance was detected in this system. Histamine release "is inhibited by some chymotrypsin substrates and inhibitors, but not by substrates of trypsin, carboxypeptidase or leucine aminopeptidase, nor by soya bean trypsin inhibitor. Acetylated esters of phenylalanine and tryptophan, which are typical chymotrypsin substrates, inhibit best; non-acetylated esters of aromatic amino acids which are effective inhibitors of the anaphylactic release of histamine in the guinea-pig, act spontaneously as histamine liberators in the rat. Toxic organophosphorus compounds DFP and 'Paraoxon' are inhibitory; TEPP is ineffective. All these inhibitors were effective only if present when the antibody was added. This indicates that these substrates and inhibitors are acting on an antigen-antibody activated step. Collectively, the data suggest that activation of a chymotrypsin-like enzyme is a necessary condition for the anaphylactic release of histamine from mast cells of the rat".

Keller & Schwarz D58,842/63: Isolated rat peritoneal MCs discharge their granules under the influence of anti-rat rabbit serum, even in the presence of antisera to phosphatidase A from bee venom and to bovine α-chymotrypsin. From this it can not be concluded, however, that these enzymes are not involved in the discharge of MCs, because the antisera may be species specific and, hence, ineffective in inactivating the corresponding enzymes of the rat.

Keller & Sorkin E37,372/63: Comparative studies on the in-vitro and in-vivo discharge of MCs in sensitized rats following treatment with antigen suggest fundamental differences in the mechanism of discharge in vitro and in vivo. It is thought that this may depend upon the presence of a special MC-discharging antibody.

Niebauer D58,906/63: On the basis of an extensive literature survey, the theory is formulated that the MCs participate in allergic reactions in that physiologically active products (heparin, serotonin, histamine) are formed and stored in MCs for release during anaphylaxis. "Probably the MCs do not participate in the specific phenomena of allergy, but they play an important role in the development of manifest allergic phenomena."

Cricchi G3,043/63: During anaphylactic shock, the MCs in the choroid membrane of the guinea-pig eye discharge their granules.

Einbinder et al. G5,491/63: No significant disruption or degranulation of MCs was found in the various tissues of mice exposed to fatal anaphylaxis.

White et al. E22,503/63: Using a modification of the fluorescent antibody technique, it has been shown that globulin from the serum of a variety of animal species can be taken up on murine lingual MCs in vitro. Thus, the MCs are rendered brilliantly fluorescent when treated with guinea-pig serum plus fluorescein-labeled rabbit anti-guinea-pig globulin, or with human serum plus fluorescein-labeled rabbit anti-human globulin, etc.

McCamish & Benedict E85,501/63: In mice, actively sensitized to egg white, intradermal challenge with the antigen develops a local immediate-type hypersensitivity reaction with intense, topical MC degranulation.

Liacopoulos et al. E27,304/63: It is calculated "that several units of antigen-antibody complexes are necessary to deplete a mast cell." Earlier observations (*Paton* D39,576/58) suggested that "in the guinea-pig, a molecule of 48/80, which is a potent histamine liberator, releases only 10 to 50 molecules of histamine."

Mota E36,462/63: In addition to the usual serum-precipitating antibody, the immunized rat produces a thermolabile "mast cell sensitizing antibody." The latter sensitizes rat tissues in such a way that subsequent contact with antigen causes MC disruption and histamine release. When this antibody is injected into rat skin, it produces, on later contact with antigen, a passive cutaneous anaphylaxis that differs from a similar reaction induced by precipitating antibody, but resembles the allergic reaction induced in man with the so-called reagin or skin-sensitizing antibody.

Mota E22,516/63; D58,285/63: Excellent up-to-date reviews on the role of the MC in anaphylaxis.

Lagunoff & Benditt D58,280/63: Two proteolytic enzymes (MC-chymase and MC-tryptase) have been demonstrated in isolated rat peritoneal MC granules. The possibility that these enzymes may play a role in allergic reactions is considered.

Mota G5,487/63: Serum taken from rats sensitized with antigen plus *Bordetella pertussis* may passively sensitize rat MCs so that later contact with antigen results in damage to these cells and histamine release. This activity cannot be attributed to the usual serum precipitating antibodies since serum containing a very high level of these antibodies may not show this activity, while serum with negligible amounts of precipitating antibodies can be highly efficient in sensitizing rat MCs. "It is concluded that the anaphylactic release of histamine in rats is produced by a particular type of antibody different from the usual serum precipitating antibody, and which we call mast cell lytic antibody".

Perera & Mongar E27,299/63: Inhibition of chymotrypsin-like enzyme does not inhibit the histamine release that normally occurs from sensitized rat peritoneal MCs during anaphylaxis in vitro. "It is concluded that the active chymotrypsin-like enzyme in these cells is not involved in the anaphylactic reaction."

Mongar & Perera G9,089/64: In isolated rat peritoneal MCs, sensitized to horse serum (with the aid of *Hemophilus pertussis* vaccine), oxygen consumption is not increased when an anaphylactoid reaction is elicited, even under conditions of reduced oxygen tension and in glucose-free media. Apparently, in the rat peritoneal MCs, "oxygen is not a rate-determining factor in the reactions which follow the union of antigen with cell-bound antibody and lead to histamine release".

Claudatus et al. E56,463/64: Anti-rat MC-serum causes disruption of rat peritoneal MCs in vitro and, when given intraperitoneally, also in vivo.

Einbinder et al. G18,460/64: In mice, in which an anaphylactic shock was elicited by sensitization and subsequent challenge with horse serum, the organs showing the greatest number of MCs were not necessarily those exhibiting the most severe pathologic changes (e.g., thrombus formation). Furthermore, no characteristic changes in MC-number or morphology was detectable in various organs as a consequence of anaphylactic shock. "None of the results obtained support the view that mast cells play a critical role in allergic phenomena in mice."

Keller G18,239/64: Anaphylaxis in vitro has been investigated in a system consisting of rat peritoneal MCs and an anti-rat γ-globulin from rabbit serum. From these studies "it is concluded that a proesterase, present in complement, is the key to the reaction whereby pharmacologically-active agents are released from the mast cell."

West F13,144/64: In different species and different sites of the body, the MCs may or may not show degranulation during anaphylaxis. For example, in the cat, the cutaneous MCs show no disruption during anaphylactic shock. "These observations may be directly relevant to anaphylaxis in man and illustrate that histamine is not always the released agent which causes the damage. Other substances, such as bradykinin or slow-reacting substance, may be much more important."

Riley F9,669/64: Excellent summary of present concepts concerning the relationship of MCs to anaphylaxis.

Parish E4,391/64: Anaphylaxis and anaphylactoid reactions in several species are accompanied by shedding of MC granules. Yet, rats and mice passively sensitized by antibody from the same species or from rabbits, may become anaphylactically sensitive to challenge though the MCs remain intact. Furthermore, when nearly all MCs are discharged by 48/80, rats may remain as susceptible to anaphylaxis as control animals similarly sensitized but not treated by 48/80. "It is concluded from these and other experiments, that substances liberated from mast cells may intensify the changes occurring in anaphylaxis but are not necessary to initiate them."

Fisher & Fisher D19,392/64: Contrary to earlier reports, depletion of tissue MCs by 48/80 in donor and/or recipient skin failed to influence the survival rate of skin homografts in rats.

Keller D19,391/64: Isolated rat peritoneal MCs liberate 80 per cent of their histamine when placed in contact with an anti-rat γ-globulin fraction of rabbits. The response is attributed to the liberation of a nonspecific chymotrypsin-like esterase and peptidase through the antigen-antibody interaction. Prior to incubation, this system contains lecithin but not lysolecithin while, following cell disruption, lysolecithin appears. It is assumed that complement activation must precede cytolysis and that mere combination of antigen and antibody does not suffice to initiate this process.

ALLERGY + VARIOUS AGENTS

Stuart D2,340/51; D15,089/52: MCs are normally sparse in the rabbit, plentiful in the guinea-pig and dog, and extremely numerous in mice. In each of these species, the tissues most affected by anaphylaxis (produced by ovalbumen) are those richest in MCs regardless of the MC population in the rest of the body. In the reacting tissues, the MCs show degranulation during anaphylaxis. This reaction is inhibited by *antihistaminics*. "These correlations suggest that the mast cells act as a defense mechanism against alterations induced by anaphylaxis."

Wegelius et al. D27,732/55: Rabbit-anti-hamster-serum causes degranulation of the MCs in the cheek pouch of the hamster, as judged by in vivo observation after staining with toluidine blue. If the *antihistaminic,* Anthisan, is injected into the cheek pouch 5 minutes before the immune serum, the MCs remain intact.

Mota & Vugman D27,087/56: In guinea-pigs sensitized with ovalbumen, reinjection of the antigen causes intense degranulation of the pulmonary MCs. This change is not prevented by pretreatment with an *antihistaminic* such as chlorprophenpyridamine.

Inderbitzin & Craps C38,962/57: In rats, passive cutaneous allergy of the immediate type is induced by intracutaneous injection of globulins from ovalbumen-immunized rabbits, followed 3 hours later by the same antigen i.v. Pontamine is added to test vascular permeability. Under these conditions, there is only very moderate histamine, 5–HT and MC-granule discharge, irrespective of the ensuing anaphylactic reaction and increased vascular permeability.

The response is not blocked by pretreatment with *BOL 148* and *pyrilamine maleate,* although the former blocks the increased vascular permeability caused by 5–HT injection, and the latter that caused by histamine. It is concluded that passive cutaneous anaphylaxis "cannot be explained only with an action of chemical mediators (histamine, 5-hydroxtryptamine) which are set free from the tissues in the process of this reaction."

Mota D27,088/57: In rats, anaphylactic shock elicited with horse serum as an antigen — unlike anaphylotoxin — produces MC disruption in the snout, tongue, and ears. The plasma histamine reaches a maximum about 5 minutes after injection of the antigen. The mesenteric MCs of the sensitized rat are also disrupted upon incubation with antigen in vitro. *Antihistamines* protect the rat against anaphylactic shock, but not against MC disruption. Pretreatment with *48/80* protects against anaphylactic shock and the rise in plasma histamine. "Probably nearly all the histamine liberated in anaphylaxis in rats comes from the mast cells."

Högberg & Uvnäs D26,477/58: *Allicin* (an enzyme inhibitor from garlic) prevents the degranulation of rat peritoneal MCs which is otherwise produced by antigen-antibody reaction, 48/80, ascaris extract, or lecithinase A. Glutathione in excess reverses this blockade of degranulation.

Mota D26,425/58; D26,755/59: When minced lung tissue or a piece of mesentery from a sensitized guinea-pig is incubated with antigen, MC-degranulation ensues within 15 seconds. The MC alterations are clearly different here from those induced by a histamine-discharger (octylamine), which causes fusion and clumping of the granules without degranulation. Furthermore, the MC alterations produced by anaphylaxis, unlike those caused by the histamine-releaser, are prevented by *heating* or *cooling* the tissue, *lack of calcium, iodoacetate,* and *phenol.* There is a close parallelism between the effect of these agents on MCs and on histamine release. "Since mast cell alterations are produced by the action of the antigen both in vivo [*Mota & Vugman* D27,087/56; *Mota* D27,088/57] and in vitro, it seems probable that the mast cells contain antibody and play an important role in anaphylaxis . . . . The morphological alterations induced by octylamine suggest that this base combines directly with the metachromatic material in the granules, and in doing so produces a complete disorganization of the granular structure with subsequent histamine release. A similar mechanism of action was postulated by MacIntosh [D27,093/56] . . . It is suggested that most of the histamine released in anaphylaxis comes from the mast cells and that these cells may be concerned with the uptake of antibodies."

Mota et al. D30,208/60: "In rats and guinea-pigs both mast cell damage and histamine release in anaphylaxis were inhibited by pyridine, nicotinamide, diethylnicotinamide, nicotinic acid, isonicotinic acid, and isonicotinic acid hydrazide, which are known to be *inhibitors of diphosphopyridine nucleotidases.* On the other hand these compounds potentiated histamine release and mast cell damage by compound 48/80 in guinea-pigs although inhibiting the same phenomena in rats." Apparently, in the rat, the mechanism of histamine release by 48/80 and antigen is more closely related than in the guinea-pig.

Mota & Ishii D26,569/60: In-vitro observations on the skin and mesentery of rats sensitized by various antigens reveals that the subsequent induction of an anaphylactic reaction by exposure of the tissue to the antigen induces MC damage with histamine release. Both these phenomena are inhibited by various *metabolic inhibitors, antipyretics, lack of calcium* in the medium, and previous *heating* of the tissue to 45°C. Contrary to earlier observations on guinea-pigs, the MC damage produced by antigen in sensitized rats is morphologically similar to that induced by 48/80, both agents causing extrusion of granules. Since, furthermore, both antigen (after sensitization) and histamine liberators can be blocked by the same agents as regards their actions upon MCs and histamine release, "It is suggested that in rats the histamine-releasing mechanism of the antigen-antibody reaction in anaphylaxis is very similar to that of compound 48/80."

Draper & Smith D26,649/61: In rats, whose peritoneal MCs are disrupted by 20 ml of *distilled water* i.p., the subsequent induction of a passive antigen-antibody reaction (rabbit-anti-ovalbumen antiserum i.p., followed 3 hours later by crystalline ovalbumen i.v.) no longer produces the usual increase in vascular permeability (judged by the intraperitoneal leakage of intravenously injected Evans blue). Essentially similar results are obtained when the skin is used as the site of the antigen-antibody reaction, or when *anti-mast cell serum or 48/80* are used instead of distilled water to disrupt the MCs. "The present results indicate that the mast cells may be of primary importance in initiating the inflammatory response accompanying antigen-antibody reactions."

Boréus D12,234/61: In guinea-pigs sensitized with crystalline ovalbumen, intra-arterial challenge with the antigen produces extensive MC disruption in the nasal mucosa. This depletion remains at the original low level for 3 weeks, then the MC count begins to rise but does not reach normal values until the 7th week. Neither *ACTH* nor *cortisone* (given in high doses) prevent this MC-disruption or the associated anaphylactic reaction.

Keller D39,722/61: The liberation of histamine from rat peritoneal MCs, which normally occurs during the anaphylactic reaction to anti-rat γ-globulin is inhibited in vitro by the administration of *peptidase substrates and inhibitors*. It is concluded that some chymotrypsin-like proteolytic enzyme participates in the anaphylactic degranulation of MCs in the rat.

Keller D39,671/61; D39,659/62: "Investigations designed to give an insight into the process of anaphylactic reaction have been performed on isolated mast cells sensitized in vivo and in vitro by fixation of anti-human gamma globulin. The reaction observed in these mast cells after adding the antigen depends on temperature and requires complement. It is inhibited by substances such as *di-isopropylfluorophosphate* and *epsilon amino caproic acid*."

Gözsy & Kátó D36,811/62: In rats, sensitized by horse serum, only mild anaphylactic shock can be produced by the reinjection of the antigen after depletion of the MCs by *48/80* or *polymyxin*. Presumably, antibody formation occurs within the MCs; hence, it is impeded after degranulation of the latter.

Keller E38,771/63: The anaphylactic release of histamine from isolated rat peritoneal MCs is inhibited by *various substances*. This inhibition does not run parallel with the histochemically demonstrable chymotrypsin-type esterase present in the MCs.

DIET

(Cf. also VITAMINS, LIPIDS and other dietary constituents under DRUGS)

Several investigators believed to have induced important changes in the MC system by diets of varying protein, lipid, and carbohydrate content, but the results were inconsistent. Starvation likewise fails to produce any pronounced and reproducible change in the MC population.

On the other hand, in rats kept on a low calcium and vitamin-D deficient diet, a large number of MCs appears along the endosteum without any corresponding increase in the MC population of other tissues.

In rats on a magnesium-deficient diet, the characteristic vasodilatation in the skin is associated with a degranulation of the cutaneous MCs and an increase in urinary and plasma histamine levels. In chronic magnesium deficiency, the MCs disappear from certain regions and form compact cell nests at other places. Eventually, a considerable number of these rats develop thymomas.

VARIOUS COMPLEX DIETS

Hardy & Wesbrook D28,474/1895: In the intestinal tract MCs are much more numerous in carnivores than in herbivores; hence, experiments were performed on rats to determine the effect of *meat* diet upon the MC population. In rats fed exclusively on "fresh flesh from the butcher," MCs became numerous and particularly rich in granules. Some of these MCs "were found thrust between the cells of the entodermic epithelium."

Nagayo D26,871/28: In rats kept on cow's *milk* there is a noteworthy increase in the MC population of the peritoneum.

de Giorgi-Ferrari D39,835/33: The mesenteric MCs of the rat increase in size and number if the animals are fed diets rich in *proteins or glucose*. Fasting has an inverse effect.

Vezzini D39,606/33: The MC count of the mesentery and small intestine rises in rats kept on a pure *meat* or *sugar* diet, but remains normal during fasting. Conversely, the number of disintegrating MCs rises on the meat diet and during fasting in comparison with the control values of animals kept on a normal mixed diet.

Hoepke & Westenhoeffer 66,679/35: Hedgehogs which after hibernation were kept on different *mixed diets*, showed no evident changes in their mesenteric MCs which could be referred to the type of nutrition received.

Kelsall & Crabb D26,076/59, *pp. 73,113*: Discussion.

Ahlqvist D26,622/60: During the development of hepatic cirrhosis in rats fed a *low-protein-high-fat diet,* the number of hepatic MCs decreases somewhat in the first two months (prior to the development of cirrhosis) but later, as the cirrhosis develops, the MC count rises above normal.

Haikonen & Räsänen G1,314/63: The dietary *fat* content appears to have no influence upon the gastric and intestinal MCs of the rat.

Räsänen G19,874/64: *Food intake* causes MC degranulation in the glandular stomach of the rat.

Thompson et al. F3,698/64: In dogs, heparin i.v. inhibits the increase in gastric secretion normally elicited by food ingestion. The gastric MCs are viewed as the source of the histamine that stimulates gastric secretion and it is postulated that heparin may bind this histamine. "A *meat* meal causes degranulation of significant number of gastric mast cells. This degranulation is prevented by i.v. heparin and may be the mechanism for heparin inhibition of gastric secretion."

STARVATION

Hardy & Wesbrook D28,474/1895: In starving rats the intestinal MCs tend to disappear.

Nagayo D26,871/28: During inanition, the MCs of the peritoneal fluid and tissues greatly increase in the rat and many MC granules are eliminated through the epithelium of the intestinal tract.

Vezzini D39,606/33: The MC count of the mesentery and small intestine rises in rats kept on a pure meat or sugar diet, but remains normal during fasting. Conversely, the number of disintegrating MCs rises on the meat diet and during fasting in comparison with the control values of animals kept on a normal mixed diet.

Kelsall & Crabb D26,640/52: Starvation does not alter the MC population of the thymus, despite the development of intense thymic atrophy.

Devitt et al. B84,254/53: Starvation produces an increase in the mesenteric MCs of the rat, without altering the percentage of degenerative types.

Arvy D26,724/55, *p. 78*: Discussion.

Bottiglioni et al. G18,905/57: During starvation, the MC population of the skin increases in the rat.

Constantinides & Rutherdale C56,628/57: Fasting fails to affect the cardiac MC count in the rat.

Kelsall & Crabb D26,076/59, *p. 63*: Discussion.

Blomquist & Fock D69,669/63: One day of fasting causes no significant change in the MC population of various tissues in the rat.

CALCIUM

Shipley et al. D33,700/22: In rats, on a low-calcium and vitamin-D deficient diet, "cells evidently derived from the fixed tissues with large basophilic granulations were numerous in the immediate vicinity of the trabeculae." [As judged by the histologic picture, these cells appear to have been MCs (*H.S.*).]

Urist & McLean D30,209/57: In rats kept on a low-calcium and vitamin-D deficient diet, a large number of MCs appear along the endosteum, but there is no corresponding increase in the MC population of the mesentery, perivascular connective tissue, or synovial membranes. The accumulation of MCs in the bone marrow can be abolished by treatment with large doses of vitamin-D, whereas parathyroid hormone, even in doses causing osteitis fibrosa, does not diminish the number of bone marrow MCs.

Cass et al. C54,014/58: In confirmation of earlier observations it is found that rats, kept on a special calcium-deficient diet, develop an unusually large number of MCs in the bone marrow. This is accompanied by an increase in the histamine and 5–HT content of the bone-marrow tissue.

MAGNESIUM

Bélanger et al. D26,328/57: In rats kept on a magnesium-deficient diet, the characteristic vasodilatation is associated with a degranulation and marked polymorphism of the cutaneous MCs. Here, magnesium deficiency might either act upon the skin through histamine discharge from the MCs, or the MC-discharge may be secondary to the hyperemia and cutaneous edema characteristic of magnesium deprivation.

Bois et al. C86,523/60; D5,409/61: In rats, kept on a magnesium-deficient diet, the subcutaneous MC population decreases. The decrease is accentuated by pretreatment with 48/80 and is thought to result from a defective cell regeneration. The peripheral vasodilatation, which is an early sign of magnesium deficiency, is absent in rats pretreated with 48/80.

Bois et al. D64,014/63: The cutaneous MC-discharge with vasodilatation that develops in magnesium-deficient rats is associated with considerable increase in urinary and plasma histamine levels.

Bois D33,692/63: During prolonged magnesium deficiency, the MC count in the tongue and subcutaneous connective tissue of the rat decreases. After 60 days, isolated clusters of MCs appear in abnormal distribution within the central zone of the tongue. Urinary histamine excretion and the peripheral vasodilatation characteristic of Mg deficiency showed no obvious relationship to the MC count.

Bois F979/64: In rats kept on a magnesium-deficient diet, the peripheral edema with erythema is associated with MC degranulation and a distribution of the MCs which disappear from certain regions and form compact cell nests at other places. Prolonged treatment with such magnesium deficient diets leads to the formation of thymomas and it is thought that MCs may originate in the thymus

NERVOUS STIMULI

Our extensive search of the literature failed to reveal any observation concerning significant and reproducible changes in the MCs that could be ascribed to purely nervous stimuli. This is all the more remarkable since calcification of the autonomic nerves can be induced through neurotropic calciphylaxis and calcergy by various MC-dischargers (aluminum dextran, 48/80, polymyxin) as well as by histamine. Furthermore, MCs are numerous in certain parts of the central nervous system (e.g., the olfactory lobe of the dog and hedgehog) and in the connective tissue of peripheral nerves. Intimate anatomical relations have been observed, also, between the terminal reticulum of cutaneous nerves and MC-like elements in the skin.

Unpublished observations of our group showed that, in rats, transection of the spinal cord, or of the motor and sensory nerves of an extremity, causes no pronounced and specific change in the MCs of the denervated regions beyond those that could be ascribed to the stress of the intervention. The anaphylactoid inflammation induced by ovalbumen or dextran was slightly increased in rats subjected to such interventions, perhaps owing to the hyperemia of denervation. Further studies along these lines would certainly be desirable.

Review: *Baglioni* C16,539/54, *p. 200*

SEX AND REPRODUCTION

There is no constant and significant *sex-dependent* difference in the MC population of various organs. There are, however, cyclic variations in the MC count of the sex organs — particularly the uterus — in animals and man.

During *pregnancy,* the MC count of the uterus is allegedly increased in certain animal species but apparently decreased in women and in hamsters.

During *lactation,* the uterus, vagina, and mammary gland of the dog have been claimed to be unusually rich in MCs.

SEX

Consolandi & Briziarelli B84,591/52: There is no significant sex difference in the MC population of the human hypophysis.

Kelsall & Crabb D28,690/53: There is no significant sex difference in the MC population of the sublingual glands in the hamster.

Constantinides & Rutherdale C2,644/54; C56,628/57: There is no significant sex difference in the cardiac MC population of the rat.

Cairns & Constantinides C3,038/54: Among non-atherosclerotic patients, who die of various causes, females have a higher myocardial MC-count than males. No such sex difference is observed among senile non-atherosclerotics.

Olivi C14,795/55: MCs are numerous in the mammary glands of male or female mice.

Simpson & Hayashi D26,645/60: In the mesentery of the cancer-resistant C57BL strain of mice, the perivascular MCs and those in the adjacent fatty tissue, increase with age in both sexes, but those in the membranous portions of the mesentery are little affected by age. In the cancer-susceptible BALB/c-mice, on the other hand, the greatest increase occurs in the membranous mesentery. Males of this strain also show marked elevations with age in the perivascular and fatty tissues, but females show slight changes here. In the skin of the C57BL-males, the MCs increase considerably with age, but they decline slightly in females. No change occurs with age in the whole skin of either males or females of the BALB/c-strain, but females regularly show one and one-half times as high a count as males. "Irregularities of the responses to age and sex factors by mast cells in different tissues make it clear that the number of mast cells is determined, at least in part, by local factors."

Mikhail & Miller-Milinska D11,944/64: No statistically significant variations could be found in the MC population of the human skin in relation to age or sex.

SEXUAL CYCLE

Tinel & Vimeux D33,688/52: In the cow, ewe, and woman, there are cyclic variations in the MC count of the uterus, with a peak during the folliculoid phase.

Baglioni C16,539/54, *p. 189*: Discussion.

Westin C11,073/55: On a single transverse section of the mouse uterus usually 5–7 MCs can be counted during all phases of the cycle, except diestrus, during which only about one MC per section is detectable.

Zachariae et al. C57,334/58: In the rabbit basophils migrate from the blood into the genital organs (primarily the ovaries) at ovulation. A large number of them accumulates around ovulating follicles and fresh corpora lutea. [In the tissues, it is difficult to distinguish these basophils from MCs (*H.S.*).]

Iversen C90,461/60: In the myometrium of the human cervix uteri, MCs are most plentiful during the secretory phase of the cycle.

Vara D39,825/62: The MCs of the human endometrium undergo cyclic variations with a discharge of their granules just premenstrually and a gradual regeneration during the rest of the cycle. It is assumed that the MCs may play a role in making menstrual blood uncoagulable.

Bassett D69,353/63: Observations on various animal species indicate "that mast cells are not necessary for the production of increased amounts of ground substance under conditions of connective-tissue modification in oestrus and pregnancy. Fibroblasts alone must be capable of making all the constituents of connective tissue as in many of these pelvic and genital connective tissues both in the inactive state and when modified by pregnancy and oestrus they are the only cells present in significant numbers."

Harvey G13,574/64: In the hamster uterus, the MC density is greatest on the day after estrus.

Likar & Likar G5,081/64: In the uterus of the cow, MCs are found just below the epithelium, around the uterine glands, the myometrium and the perimetrium. Their number increases during proestrus and estrus parallel with the histochemically-demonstrable hyaluronate.

Likar et al. G19,263/64: In the bovine endometrium, the MC count increases from metestrus through diestrus to proestrus. At the height of estrus there are many MCs and they show intense degranulation. Biochemically and histochemically estimations of hyaluronic acid and total acid mucopolysaccharides showed variations which roughly paralleled the MC counts throughout the cycle. "The results of this investigation support the concept that mast cells participate in the production of hyaluronic acid."

PREGNANCY

Berka D27,512/11: MCs are constantly present in the stroma of the mammary glands of women but their number increases during pregnancy.

Huguenin D29,587/12: In the human uterus, the number of MCs is diminished during pregnancy and the puerperium.

Asplund & Holmgren B17,599/47: During pregnancy the so-called "specific cells" (which contain metachromatic granules but are not considered to be MCs) in the human uterus are decreased in number.

Castiglioni D39,812/48: MCs are especially numerous in the pituitary of pregnant women.

Wimsatt D27,404/49: Numerous MCs are found in the myometrium of the pregnant bat (*Myotis lucifugus*).

Brusa D39,831/49: In the uterus of the normal prepubertal mouse there are only few MCs and their number is not altered by treatment with LH or folliculoids. On the other hand, during pregnancy and lactation the uterine MC count increases considerably.

Consolandi & Briziarelli B84,591/52: Certain variations in the MC population of the human hypophysis are allegedly characteristic of pregnancy.

Kelsall & Crabb D26,640/52: Pregnancy does not influence the thymic MC count of the hamster.

Padawer & Gordon B83,891/53: Pregnancy does not alter the MC population of the rat's peritoneum.

Baglioni C16,539/54, *p. 191*: Discussion.

Padawer & Gordon C18,005/56: The MC concentration is decreased but their absolute count is increased in the peritoneal fluid of the rat during pregnancy. This is ascribed to an increase in the peritoneal fluid content.

Nepriakhin D26,879/56: The MC count in the uterus and mammary gland is considerably increased during pregnancy in the dog; but there also appears to be an increased MC-density in other organs throughout the body.

Iversen C90,461/60: The MC count in the human cervix uteri declines during pregnancy.

Csaba et al. C98,159/60: The MC population of the rat thymus is greatly increased during pregnancy.

Voutsa et al. D69,713/63: In the human uterine cervix, MCs predominate around the blood vessels. Their number decreases in the gravid uterus at term.

Bassett D69,353/63: Observations on various animal species indicate "that mast cells are not necessary for the production of increased amounts of ground substance under conditions of connective tissue modification in oestrus and pregnancy. Fibroblasts alone must be capable of making all the constituents of connective tissue as in many of these pelvic and genital connective tissues both in the inactive state and when modified by pregnancy and oestrus they are the only cells present in significant numbers."

Harvey G13,574/64: During pregnancy, the MC-density in the uterus decreases in the hamster.

LACTATION

Michaelis D27,584/1898: During lactation, MCs are demonstrable in the mammary gland of the mouse, but not in that of the guinea-pig.

Huguenin D29,587/12: The MC count of the human uterus declines during the puerperium.

Brusa D39,831/49: In the uterus of the normal prepubertal mouse there are only few MCs and their number is not altered by treatment with LH or folliculoids. On the other hand, during pregnancy and lactation the uterine MC count increases considerably.

Kelsall & Crabb D26,640/52: Lactation does not influence the MC count of the thymus in the hamster.

Arvy & Quivy D27,966/55: In lactating dogs, the uterus and vagina are extraordinarily rich in MCs.

Nepriakhin D26,879/56: During lactation, the mammary gland of the dog contains an unusually large number of MCs.

AGE

(Cf. also EMBRYOLOGY)

The MC-system is fully developed at birth in most species and does not undergo any striking changes with increasing age, although a slight drop has been noted in the skin and heart in men approaching senility.

In the rat, the percentage of abnormally-shaped peritoneal MCs increases with age and when deformed by centrifugation, they return more slowly to their original spherical shape than those of young animals.

In the myometrium of the human cervix uteri, the MC count apparently decreases during the post-menopausal period.

Rosenheim D26,865/1886: The connective tissue of various peripheral nerves of man is rich in MCs, though not before the fifth year of life. Their number greatly increases in old age.

Browicz E25,818/1890: MCs are not found in the heart of new-born babies and are rare in infants, but increase in number as the individual reaches maturity.

Münchheimer A47,205/1895: MCs are present in the testis of the adult man, pig, and cattle, but absent during the first weeks of life. In man, numerous MCs were found in testicular tissue between the age of 2–78 years.

Audry D27,885/1896: MCs are plentiful in the skin of the new-born, particularly around the hair follicles.

Sabrazès & Husnot D27,507/07: MCs are present in the human adrenal gland from embryonic age to senility. They are especially plentiful in senile individuals with arteriosclerosis.

Greggio D31,536/11: In the sclerotic ovaries of old women, the MCs tend to become elongated and show signs of dissolution, but their absolute number is increased, especially within the loose connective tissue.

Barbano D29,284/12: In the human thymus, MCs appear to develop from cells with eosinophilic granulations in the course of involution.

Brack D26,821/25: Both in the penis and in the nipples of children, the MC count declines at puberty. However, no such age-dependence in MC count is found in the gastro-intestinal tract. In the interstitial tissue of the lung and testis, MCs are very scarce in children and much more numerous in adults.

Webb D26,822/34: In the peritoneum "there is proportionately more fluid within the body cavity of the young rat than in the adult, whereas the number of cells [MCs] per cubic millimeter is less", hence, the apparent increase in MCs between birth and sexual maturity may be due to concentration without any change in total number.

Webb D30,627/35: Between the 5th day before and the 19th day after birth the number of MCs per standard area increases ten times in the dermis of the rat. After that, no pronounced change is noted up to the 50th day.

Bates D26,774/35: The number of subcutaneous MCs in the rat is highest during the first few weeks of life and falls gradually until the end of the second month. Thereafter, the MC population remains steady up to one and one-half years of age. The mean diameter of the individual MC is about 8μ at birth and grows to approximately 24μ at one and one-half years of age.

Ducci D39,802/46: A comparatively large number of MCs is present in the synovial membranes of man from infancy to adulthood; only with highly advanced age does their number diminish.

Hellström & Holmgren D39,611/47: Quantitative analysis of the MC count in human skin and heart tissue shows a gradual drop between birth and senility.

Asplund & Holmgren B17,599/47: In the normal and pregnant human, uterine mucosa cells with occasional metachromatic granules (called "specific cells") are found. "These cells are neither mast cells nor apparently plasma-mast cells. The 'specific' cells are met more frequently during the secretion phase. After the cessation of menstruation, they seem to disappear from the mucous membrane. As the cells are only met during the fertile age, it is assumed that they have a function associated with the functioning uterine mucous membrane." The cells should also not be confused with the metachromatic granule-containing myometrial cells found in pregnant rats and mice immediately under the placental insertion. The specific cells are not so localized.

Hellström & Holmgren D25,620/50: With advancing age the MC population of the human skin constantly decreases up to the age of 80 years. In the heart, only few MCs are detectable before the age of two years. Then, their number rises sharply for a period and, later, continues to fall steadily until the age of 80 years. Only in the atria is the decrease with

age not statistically significant. "The decimation of the mastocyte system is interpreted as resulting from general senile decay."

Compton B90,594/52: MCs are exceedingly scarce in the connective tissue of the newborn hamster. They are hardly recognizable before the third post-natal day.

Consolandi & Briziarelli B84,591/52: In the human hypophysis, MCs appear during the first months of extra-uterine life and increase in number after the age of 20–30 years. Thereafter, the hypophyseal MC-population remains fairly constant.

Kelsall & Crabb D26,640/52: No age difference in the thymic MC count could be detected among 38–387-day-old hamsters, although the thymi of the older animals were considerably reduced in size.

Kelsall & Crabb D28,690/53: Age does not appear to influence the MC population in the sublingual glands of the hamster.

Riley & West B96,668/53: The MC and histamine content of the lung (cattle, man, and cat), liver capsule (cattle) and skin (cat) is much lower in the young than in adult animals.

Dunn D27,626/54: In aged mice, the number of MCs increases in various tissues and iron-containing phagocytes are frequently found in the vicinity of the MCs.

Constantinides & Cairns D26,732/54: Young and old, non-atherosclerotic persons have essentially the same cardiac MC count.

Constantinides & Rutherdale C2,644/54: In the rat, there is a significant progressive diminution in the MC count of the heart with aging.

Cairns & Constantinides C3,038/54: Young adult and non-atherosclerotic, senile individuals have approximately the same number of MCs in the myocardium. On the other hand, in senile atherosclerotics, this number is considerably below normal, irrespective of the immediate cause of death.

Arvy & Quivy D27,966/55: In senile dogs, there are very few MCs in the uterus and vagina.

Sundberg D27,403/55: In general, the MC count in the inferior vena cava, subclavia, and external iliac vein decreases with age in man. Unlike in young individuals, the MC count of the aorta is significantly higher than in the vena cava of aged people. However, in view of the great individual variations, these findings must be interpreted with care.

Padawer & Gordon C21,135/56: The peritoneal MC population and the percentage of abnormally shaped cells increases with age in the rat. "The study of mast cells may afford important clues as to the physiologic processes involved in ageing."

Nepriakhin D26,879/56: The MCs of old people and old dogs may contain a yellow, natural pigment of their own, readily visible on unstained sections under ordinary light.

Niccoli-Vallesi D39,807/56–57: In the skin of the external auditory meatus of man, very few MCs are seen during embryonic life, but their number increases and reaches a maximum in senility.

West & Parratt C45,206/57: "Two days after weaning, the histamine and 5–HT levels for abdominal skin, ears and dorsal skin of the foot are about twice those found in unweaned litter-mate rats; yet mast cells in these regions are not increased in number or altered in appearance. The exact cause of these increases is still unknown, though it may be simply related to the stress involved in weaning, since the return to normal levels is complete in the next six days."

Guidotti D65,255/57: Following radiosulfur administration, the autoradiographically-determined S^{35}-uptake of the cutaneous MCs in the rat reaches the same maximum level, but the rate of exchange is higher in younger than in older animals.

Parratt & West C37,857/57: At the time of weaning, there is a pronounced, temporary increase in the 5–HT and histamine content of the rat skin, which does not occur in non-weaned controls of the same age. This increase lasts only a few days and its cause is still unknown, though it has been related to the "stress involved in weaning." There is no change in the number or appearance of MCs during this period. The observation shows a relative independence of skin histamine and 5–HT from the local MCs.

Constantinides & Rutherdale C56,628/57: The cardiac MC count of the rat decreases with age in both sexes.

Sumi C60,846/58: In the human bone marrow, the MCs are increased in senility.

Pomerance D33,710/58: The periarterial MC count is not significantly affected by age in man.

Padawer et al. D29,151/58; D26,629/60; D26,628/61: When rat peritoneal MCs are deformed by centrifugation "mast cells of young rats behave as if invested with an elastic envelope" and rapidly return to their original spherical shape, while those of older rats are much slower in reverting to their normal shape and indeed, non-spherical peritoneal MCs are not uncommon even in untreated old rats.

Carranza & Cabrini D65,112/59: Observations on rats "revealed an increase in the number of mast cells from 3 days to one month in skin and oral and nasal mucosae, which coincides with connective tissue maturation, and suggests a relation between this and mast cells. After reaching the higher values at one month of age, the number of mast cells diminished gradually in skin, as shown by previous workers [*Hellström & Holmgren* D39,611/47]. This reduction is more evident, however, in oral mucosa. Nasal mucosa, on the other hand, seems to increase continuously its content of mast cells, but absolute numbers of mast cells found in nasal mucosa are very low and their counting difficult".

Dixon D65,094/59: Observations on rats show that "in skin, mast-cell count and histamine content are closely correlated between 18½ days gestation and 7 days post-partum".

Marx et al. C80,411/60: With advancing age, the MCs become more numerous in the lung and thymus and, to a lesser degree, in the kidney of the rat. The heparin content of the thymus and, to a lesser extent, of the lung also rose with advancing age.

Spicer C92,580/60: In aged mice, the number of MCs increases in various tissues and iron-containing phagocytes are frequently found in the vicinity of the MCs.

Csaba D2,230/60: In the human thymus, MCs and metachromatically-staining thymocytes (presumed to be precursors of MCs) are demonstrable from birth to 81 years of age.

Csaba et al. C98,159/60: In the rat thymus, MCs appear at about the 18th day of fetal life, reach a maximum in animals weighing 50–150 gm and decline again at 250 gm. Roughly parallel with the development of MCs is that of thymocytes with metachromatic granules.

Iversen C90,461/60: In the myometrium of the human cervix uteri, the MC count decreases considerably during the postmenopausal period.

Simpson & Hayashi D26,645/60: In the mesentery of the cancer-resistant C57BL strain of mice, the perivascular MCs and those in the adjacent fatty tissue, increase with age in both sexes but those of the membranous portions of the mesentery are little affected by age. In the cancer-susceptible BALB/c-mice, on the other hand, the greatest increase occurs in the membranous mesentery. Males of this strain also show marked elevations with age in the perivascular and fatty tissues, but females show slight changes here. In the skin of the C57BL-males, the MCs increase considerably with age, but decline slightly in females. No change occurs with age in the whole skin of either males or females of the BALB/c-strain, but females regularly show one and one-half times as high counts as males. "Irregularities of the responses to age and sex factors by mast cells in different tissues make it clear that the number of mast cells is determined, at least in part, by local factors."

Csaba et al. D33,082/61: Following thymus involution owing to advanced age, as well as after thymectomy, the MC count in the lymph nodes of the rat increases. It is assumed that the lymph nodes may take over the supposed MC-producing ability of the thymus.

Pepler & Meyer D26,748/61: No correlation could be established between age and coronary MC counts in a large series of European and Bantu subjects.

Glick & Pothapragada D2,215/61: In a series of 30–120-day-old rats, the succinic dehydrogenase activity of the peritoneal MCs did not appear to be influenced by age.

Nozaka & Simpson D63,181/62: In man, the MC count in the submucosa and muscularis of the pyloric portion of the stomach gradually increases with age. In the cervix the increase ends abruptly at middle age and then declines.

Allen E94,053/62: Mitoses in the peritoneal MCs of the rat decrease with advancing age from 10 to 120 days.

Simpson D58,271/63: Careful review of the literature leads to the conclusion that "considering the diversity of the observations mentioned, it seems clear that generalizations on the changes of mast cells with age are unjustified. Under normal physiological conditions, each tissue or organ must have within itself the chief determinants of its mast cell population."

Boseila D58,293/63: Discussion.

Padawer D58,275/63: Discussion.

Guidotti & Spinelli-Ressi G11,021/64: The incorporation of labeled sulfate in vitro into peritoneal MCs is faster in young than in adult rats. This difference is ascribed to changes characteristic of senescence.

Mikhail & Miller-Milinska D11,944/64: No statistically significant variation could be found in the MC population of the human skin in relation to age or sex.

HIBERNATION, SEASONAL VARIATIONS

In the bat, hedgehog, frog, and other hibernating animals, the MC count of various tissues is increased during the winter season and in general the blood-clotting time shows parallel variations. These observations have been taken to support the view that heparin produced by the MCs helps to prevent thrombosis during hibernation when the circulation is slow.

Reviews: *Baglioni* C16,539/54, *p. 209*
Arvy D26,724/55, *p. 78*
Fulton et al. C35,831/57
Kelsall & Crabb D26,076/59, *pp. 64, 79*
Keller C91,531/60
Smith D63,031/63

Ballowitz D27,586/1891: MCs are plentiful in various tissues of the bat (*Vesperugo noctula K. et BLAS.*). In the spring, at the end of the hibernation period, when the animals are greatly emaciated as the result of a 5–6 months fast, the MC count is moderately decreased in the hibernating gland and in the intestinal tract, but their density is essentially normal in the testis, tongue, and other organs.

Peter D29,160/35: In the hedgehog, the thymic MCs greatly increase in number during the beginning of hibernation and then discharge their granules, gradually disappearing as the winter season progresses.

Härmä & Suomalainen B65,284/51: The MC population increases both during true hibernation and in the course of artificial "hibernation", induced by insulin in hedgehogs.

Suomalainen & Härmä D30,082/51: The MC population of the small intestine and bronchi is increased during hibernation in the hedgehog. Perhaps increased heparin production by these MCs accounts for the absence of thromboses, despite the greatly reduced pulse rate during hibernation.

Suomalainen & Lehto B89,504/52: In the hedgehog, the MC count in the small intestine and bronchioles rises concurrently with the blood clotting time during hibernation. It is assumed that the delay in blood clotting, characteristic of hibernation, is due to an increased secretion of heparin.

Suomalainen C852/53–54: MCs are particularly numerous in the peribronchial and intestinal connective tissue of the hedgehog, especially during hibernation.

Smith et al. D67,482/54: The MC count in the duodenum of the bat increases during the winter season as well as upon exposure to cold during the summer. In summer bats the MC count is low and it can be lowered artificially during the winter by exposure to heat. The blood-clotting time shows parallel variations. "The mast cell changes suggest that the alterations in clotting time are determined at least in part by alterations in the availability of heparin to the circulation".

Veil E24,154/56: Definite seasonal variations are noted in the MCs of the scales in the carp.

Hjelmman D39,689/56: In the frog, artificial hibernation, induced by exposure to cold, greatly increases the cardiac MC count.

Veil E62,531/57: The MCs in the scales of various fish are subject to seasonal variations reaching a maximum between October and February, and almost disappearing in April.

Allara C68,999/59: In the hedgehog (*Erinaceus europaeus*) there are numerous MCs in the stroma of the thymus under normal conditions but their number diminishes sharply during hibernation, induced by exposure to cold during the fall.

Kelly et al. E43,287/61: In a series of 29 post-hibernation, horned lizards (*Phrynosoma cornutum*), the mean blood-basophil count was only about 8 per cent of the leukocytes. Mast cells were not especially numerous in the tissues and were entirely absent from the peritoneal fluid. It is possible that the higher counts reported by earlier investigators may have been due to seasonal variations.

Sacerdote D33,407/62: In the pelvic gland (a male accessory organ) of *Triturus cristatus,* numerous stromal MCs develop at the height of sexual activity.

HEREDITY

There are no significant racial variations in the MC count of Caucasians, Negroes, Chinese, Indians, and Malayans. Occasionally high MC counts common in Africans may be due to nutritional factors or parasitic infestations.

An unusually large number of pericapillary MCs was noted in the "hairless" strain of rats. In comparison with guinea-pigs, dogs, rats, and mice, comparatively few MCs are found in rabbits, but this may be partly due to genetically determined differences in staining ability.

Pigmented MCs are found in the skin of "naked" and "crinkled" mice, in close proximity to the growing hair follicles which contain similar pigments. A considerable accumulation of MCs is also seen in the fat depots of mice with the hereditary obese-hyperglycemic syndrome.

MAN

Staemmler D26,807/21; *Wöringer* D26,819/55: The cutaneous MC population is not significantly different in Negroes and Caucasians; hence, pigment formation does not depend upon the MCs.

Fernex D26,721/59: The cardiac MC count is approximately three times higher in Africans than in Europeans. It remains questionable, however, whether this is a true racial difference or the consequence of the infections and nutritional deficiencies so common among Africans.

Fernex E20,417/60: In cases of serous myocarditis there is often a large accumulation of MCs. This was more evident in Africans than in Europeans and may be due to a nutritional factor.

Fernex D26,839/61; D26,660/61; D39,603/61: Although the myocardial MC count is much higher in Africans than in Europeans, the cutaneous MC counts are not strikingly different.

Pepler & Meyer D26,748/61: The MC concentration of the coronary arteries is not significantly different in Europeans and Bantus.

Ali G14,207/64: The nasopharyngeal mucosa of man has a particularly dense MC population, but no racial differences have been observed in a comparative study on Chinese, Indians, Malayans, and Europeans.

Mikhail & Miller-Milinska D11,944/64: No significant difference in the cutaneous MC population was found between Negroes and Caucasians.

ANIMALS

(Cf. also COMPARATIVE ANATOMY)

Heller D26,810/04: In the "hairless rat", an extraordinarily large number of MCs accumulates around the capillaries in the vicinity of the cyst-like deformed hair roots.

Selye A57,745/44: Topical application of estradiol to the skin of the hairless mouse induces a nonpitting cutaneous edema with mucin accumulation. Although, in this work, no metachromatic dyes were used, the resulting changes were compared with scleredema adultorum (Buschke) and the possible participation of MCs should be considered.

Stuart D15,089/52: MCs are normally sparse in the rabbit, plentiful in the guinea-pig and dog, and extremely numerous in mice.

Nay D65,634/56: "In the skin of Naked, Crinkled, and occasionally, normal mice, the mast cell granules, or whole mast cells, located in subdermal connective tissue, become pigmented, the colour being the same as the colour of the hair of the animal in question. In the skin of Crinkled mice, which have little hair growth, a great number of pigmented mast cells accumulate in the subdermal connective tissue. The pigmented mast cell granules in Naked and Crinkled mice are engulfed by the growing hair follicle, and accumulated in the dermal papilla. After the formation of pigment in the hair the dermal papilla appears depleted of pigmented granules. It is suggested that mast cells in the mouse are concerned in pigment formation".

Padawer D30,194/57: "There are about 3½ per cent mast cells in the peritoneal fluid of a 200 gm rat of the Long-Evans strain, but about 7 to 12 per cent in samples from the Sprague-Dawley strain."

Simpson & Hayashi D26,645/60: In the mesentery of the cancer-resistant C57BL strain of mice, the perivascular MCs and those in the adjacent fatty tissue increase with age in both sexes, but those in the membranous portions of the mesentery are little affected by age. In the cancer-susceptible BALB/c-mice, on the other hand, the greatest increase occurs in the membranous mesentery. Males of this strain also show elevations with age in the perivascular and fatty tissues, but females show slight changes here. In the skin of the C57BL-males, the MCs increase considerably with age, but decline slightly in females. No change with age occurs in the whole skin of either males or females of the BALB/c-strain, but females regularly show one and one-half times as high counts as males.

Fernex & Fernex D39,820/62: In mice with various experimental helminthic diseases, the cutaneous MC number increases sharply and at the same time there is blood eosinophilia. It is thought that the increased number of MCs in the connective tissue of Africans (frequently associated with blood eosinophilia) may result from helminthic infections.

Hellman et al. E22,484/63: The MCs of the mouse were examined in the epididymal and subcutaneous adipose tissues. "Both with the obesity induced by goldthioglucose and that associated with the American variety of the obese-hyperglycemic syndrome there was a considerable accumulation of mast cells in the fat depots. While the relative number of mast cells was calculated as 3 per 100 epididymal fat cells in the lean controls, it was more than 50 for the obese-hyperglycemic animals. . . . The greatly increased mast cell content of the adipose tissue in obesity would be consistent with previous work on the rat, in which it was suggested that the lipase activity of the adipose tissue is concerned with accumulation of fat in depots."

Täljedal & Hellman D5,553/63: In hereditary obese mice, the adipose tissue contains many MCs but not as many as in other forms of obesity.

7

Diseases

MASTOCYTOSES IN MAN

THE term "mastocytosis" is currently used to designate the entire class of morbid conditions characterized by the abundant proliferation of MCs. Most commonly mastocytosis affects the skin but often it also involves many internal organs, thus constituting a systemic disease. Urticaria pigmentosa is the usual cutaneous variant of mastocytosis in man, but this term could not be used to designate those forms which are unaccompanied by pigmentation or even by any other characteristic skin lesion.

Reviews:

Little D39,673/05–06
Pelagatti G2,957/09
Finnerud E35,353/23
Schäfer D26,711/27–28
Le Cars D39,796/30
Chimi D39,797/31
Ormsby & Montgomery E37,428/48
Chaves D39,789/49
Baglioni C16,539/54
Degos D27,649/55
Nickel D27,886/57
Herzberg D39,565/59
Allegra D27,514/60
Stutzman et al. C95,789/60
Bigelow D26,847/61
Braun-Falco & Jung D39,567/61
Sagher & Even-Paz D9,772/61
Stutzman & Urbach D14,152/61
Bermejo D47,515/62
el-Mofty et al. D56,904/62
Fernex D39,200/62
Franzen E44,409/62
Grüneberg D30,668/62
Remy D31,528/57; D32,662/62
Szweda et al. D20,223/62
Anonymous D69,591/63
Caplan D55,590/63
Degos D58,430/63
Demis E24,240/63
Mutter et al. E36,471/63
Anonymous F614/64
Braunsteiner G10,415/64

HISTORY

The typical form of mastocytosis as it occurs in man, was first described by Nettleship in 1869 and quite independently rediscovered by Tilbury Fox in 1875. The name "urticaria pigmentosa" was suggested by Sangster in 1878 and the cardinal role played by the MC in the development of this lesion was first demonstrated by Unna in 1887. After this the various clinical features of this disease and the essential identity of the seemingly distinct adult and infantile types were soon recognized by numerous clinicians.

Sézary and associates were apparently the first to suggest the terms "mastocytoma" for single nodules and "mastocytosis" to include all variants of MC proliferation. Sézary also described as mastocytomas certain cutaneous mast-cell tumors of the dog which appeared to behave in a malignant fashion since the lymph nodes, spleen and liver were also affected.

Reviews: *Little* D39,673/05–06
Bendel & Race E20,636/63

Nettleship & Tay D27,987/1869: First description of a disease which was apparently urticaria pigmentosa but has not yet been so designated.

Fox G18,411/1875: Rediscovery of urticaria pigmentosa under the name of "xanthelasmoïdea."

Thin D39,839/1877: Early clinical report.

Sangster D39,840/1878: First use of the term "urticaria pigmentosa" for the description of "an anomalous mottled rash, accompanied by pruritus, factitious urticaria and pigmentation."

Hoggan & Hoggan D33,721/1883: Description and illustration of the histologic appearance of the skin in urticaria pigmentosa. The affected regions are infiltrated with "swollen cells" which are obviously MCs.

Unna D39,515/1887: First description of MCs as the characteristic cells in urticaria pigmentosa. Unlike in his first publication of 1887, in which he considered the MCs in urticaria pigmentosa as "emigrated wandering cells," Unna (D31,522/1887) subsequently assumed that these cells are formed locally by transformation of fibroblasts.

Little D39,673/05–06: First detailed clinical description of urticaria pigmentosa.

Finnerud E35,353/23: Clinical studies on urticaria pigmentosa (nodular type) with a summary of the early literature.

Touraine et al. D39,649/33: Clinical observations suggest that the spleen and bone marrow are involved in urticaria pigmentosa. First use of the term "reticulose mastocytaire".

Sézary D26,804/36: The term "mastocytoma" is suggested to designate localized MC-tumors of man, irrespective of whether they are pigmented or not.

Ellis D27,355/49: First detailed autopsy report of a fatal case of urticaria pigmentosa. In a one-year-old Negro child, MC-infiltrations were seen in the skin, liver, spleen, lymph nodes, periadrenal fat, kidney, and the endosteal surface of bones. There was hepatosplenomegaly and diarrhea.

Sagher et al. D10,437/52: First demonstration of skeletal lesions in patients with urticaria pigmentosa.

CASE REPORTS

Hallopeau & Teisseire G1,485/05
MacMaster E37,983/05
Lieberthal E38,338/05
Beatty E37,982/06
Mewborn E38,149/06
Vörner G1,238/06
Stainer E37,379/06
van der Hoop E37,992/07
Crocker E37,597/07
MacLeod E37,596/07
Fox E37,441/07
Adamson E37,591/08; E38,164/08
Bowen E38,156/08
Kanitz E37,951/08
Jackson E38,157/08
Hutchinson E38,161/08
Savill D34,031/08
Bonnet E39,410/08
Little E37,594/08; E53,067/08
Bunch E37,600/09; E37,592/09
Schwartz E38,146/09
Meachen E38,166/09
Pautrier & Fernet E24,203/09
Nicolas & Moutot E39,356/09
Ercoli G2,956/09
Lapowski E38,145/09
Kanitz D32,277/10
Montagnon D38,347/10
Hyde E38,154/10
Fox E38,155/10
Little D52,641/10
Bizzozero E37,588/11
Bunch E37,431/11
Rott E37,999/11
Gottheil E38,147/11
Fox E38,148/11
Little E52,371/11; E51,343/11; E37,381/11
Dubreuilh E37,598/12
Lancashire E37,584/12
Hartzell E38,009/12
Boas G1,236/12
Rasch G1,237/12
Fox E38,008/12
Knowles E38,158/13
Heath E37,436/13
Meachen E37,582/13
Hartzell E38,131/13
Foerster & Baer E38,138/13
Spangenthal E37,995/13
Heller D32,024/13
Semon E37,587/13
Adamson D71,842/14
Trimble E38,132/14
Bechet E38,136/14
Jadassohn E38,017/14

Adler G2,051/14
Whitehouse E37,991/15
Comby E38,000/15
Davis E37,989/15
Stelwagon E37,988/15
Shaffner E37,990/15
Bang D45,271/16
Whitehouse E38,150/16
Dore D29,282/16
Fordyce E38,139/16
Bechet E38,133/16
Trimble E38,135/16
Tièche E37,994/16
Shelmire E37,585/16
Kingsbury E38,140/16
Cassar E37,583/16
Little D71,210/16
Stillians E38,134/16
Sibley E37,586/16
Hartzell E38,143/17
Fordyce E38,142/17
Ormsby E38,144/17
Pusey E38,141/17
Mackey E38,006/18
Heidingsfeld E38,004/18; E38,005/18
Lieberthal E38,003/18
Hartzell E38,001/18
Ormsby E38,007/18
Goldenberg E38,002/18
Harris E38,014/19; E38,015/19
Bunch D71,208/19
Zeisler E38,010/19
Ormsby & Mitchell E38,012/19
Wise E38,011/19; E38,013/19
Oliver E38,162/20
Fordyce E38,163/20
Wise E37,993/20
Olson E37,384/21
Abramowitz E37,986/21
Beatty E37,593/21
Eliascheff E37,599/21
Milian & Périn E43,369/21
Fox E37,590/21
Clark E37,984/21
Wise E37,985/21
Mandel E72,211/21
Rostenberg E38,165/22
Michelson E38,160/22
Gager E38,159/22
Parounagian E37,996/23
Crawford E37,589/23
Ormsby & Mitchell E25,267/23
Gaté & Michel D39,750/34
Gray D39,721/38
Quiroga & Helman D39,833/40
Ayres D39,581/42
Carrera & Seoane D39,805/45
Camaño et al. D39,804/45
Bolgert & le Sourd D39,719/50
Torres D39,814/51
Texier D39,655/53
Gaté et al. D39,643/54
Becker D39,619/54
Post 39,632/56
Marten D39,706/57
Rider et al. E35,352/57
Degos & Guilaine E31,480/62
Warin & Hughes E23,545/63
Manfredi et al. E28,481/63
Grüneberg E30,063/63

CLASSIFICATION AND TERMINOLOGY

Many forms of mastocytosis have been described as separate entities on the basis of their predominant manifestations and it has often been attempted to classify these into logically structured systems which would comprise all variants with as little overlap as possible. However, transitional types between these variants are so common as to greatly limit the value of any strict categorization. For example, the juvenile and adult, benign and malignant, pigmented, and non-pigmented, uni- and multinodular pairs of groups, all tend to overlap so that the same case may fit equally well into two or more categories. Hence, in the following pages, we shall not attempt to systematize the manifold types of mastocytosis, but merely to group similar cases under headings which emphasize their salient characteristic features. It must be understood however, that the most prominent manifestation of one type — that according to which it is listed — may also occur as a more incidental feature in cases mentioned under another heading.

Still, to obtain a general overview of the principal forms, we shall list them here by way of an introduction arranged according to the system of *Degos* (D58,430/63) which will also serve us later as a skeleton for the clinical description of these forms.

(1) Common urticaria pigmentosa
Juvenile form
Adult form

(2) Nodular and papular mastocytoses
Xanthelasmoïdea
Multinodular globular forms
Coalescent nodular form
Papular form (including the single mastocytoma nodule)

(3) Bullous mastocytoses

(4) Diffuse mastocytoses

(5) Extracutaneous or systemic mastocytoses

It would be impossible to describe the clinical features of the various types without some kind of categorization and, among the systems proposed, that just outlined appears to be most acceptable. It will be remembered, however, that other features, such as presence of hemorrhages, pigmentation, leukemia, angiomas etc., may be most characteristic in individual cases and reports published under these headings will be listed accordingly, here (without any pretense of creating non-overlapping categories) as follows:

Multinodular	Maculo-papular
Uninodular	Xanthoma-like
Diffuse	MC-nevus
Hemorrhagic	MC-reticulosis
Bullous	Leukemic form
Unpigmented	Various other forms

Systems of classification

Reviews: *Kerl* D39,694/13 *Nickel* D27,886/57
Sagher D27,978/56 *Demis* E24,240/63

Sézary D39,815/36: The following classification is recommended:

"1. Diffuse mastocytosis which causes dermographism;
2. Circumscribed mastocytosis with multiple non-pigmented tumors (mastocytomas);
3. Circumscribed mastocytosis in the form of spots or multiple pigmented tumors (urticaria pigmentosa) which merely represent pigmented mastocytomas."

[Here the term "tumor" was merely used to designate a nodule, not a true neoplasm (*H.S.*).]

Degos et al D39,586/53: The following forms of mastocytosis are distinguished: (1) Urticaria pigmentosa; (2) The multi-nodular form to which also belongs the xanthelasmoid reticulosis. There are many transitional forms between these main types.

Degos E57,261/56; D39,776/56: The mastocytoses are subdivided into urticaria pigmentosa, mastocytoma (single nodule), nodular mastocytoses, papular mastocytoses, bullous mastocytoses, and diffuse cutaneous mastocytoses.

Stutzman & Urbach D14,152/61: The following classification of the mastocytoses is proposed:

I. Cutaneous MC disease
  A. Childhood forms
    (1) Solitary mastocytoma
    (2) Bullous urticaria pigmentosa
    (3) Diffuse urticaria pigmentosa
  B. Adult forms
    (1) Diffuse urticaria pigmentosa
    (2) Telangiectasia macularis eruptiva perstans
  C. Generalized MC disease
II. Polysystemic MC disease
  A. Benign mastocytosis

B. "Malignant" mastocytosis
C. Systemic mastocytosis without skin involvement

Demis E24,240/63: The following classification is recommended:

I. Benign
A. Cutaneous
(1) Generalized — urticaria pigmentosa
(2) Isolated — mastocytoma
B. Systemic
(1) Skin, bones, liver, spleen
(2) Gastrointestinal tract
C. Splenic
II. Malignant
III. Leukemic

Caplan D55,590/63: 112 cases of urticaria pigmentosa were classified into 3 groups: (1) solitary lesions; (2) multiple lesions in infancy and early childhood; (3) multiple lesions in adults.

Multinodular

Gross D42,436/34: A patient with a solitary urticaria-pigmentosa lesion on the wrist.

Chargin & Sachs D39,556/54: The nodular form of urticaria pigmentosa occurs in about 25 per cent of the cases. [This estimate appears to be very high in comparison with that of other authors (*H.S.*).]

Gaté et al. D39,643/54: Nodular urticaria pigmentosa with intense MC-proliferation and signs suggesting beginning malignant transformation.

Degos et al. D39,578/57: Multinodular and bullous mastocytosis.

Janower D64,689/62: In a case of urticaria pigmentosa, "the mucosal folds were thickened and studded with innumerable small nodules measuring up to 4 mm in diameter. The small intestine was most involved but also the stomach and colon revealed abnormalities."

Uninodular

Sézary D26,804/36: The name "mastocytoma" is suggested for the MC tumors of man; this designation would encompass both the pigmented and the non-pigmented variant.

Scott & Lewis D39,665/52: Solitary macule.

de Graciansky et al. D39,637/54: "Mastocytome unique avec poussée bulleuse."

Chargin & Sachs D39,556/54: A 20-month-old boy with a single round, nodular plaque on the left forearm.

Gaté et al. D39,423/54: Description of a solitary mastocytoma in a 3-month-old infant.

Degos et al. D39,551/55: "Mastocytose à plaque unique du nourrisson." A case of uninodular bullous xanthelasmoid mastocytosis in a 7-month-old infant.

Szymanski & Becker D39,633/56: Solitary lesion.

Zackheim D39,653/57: Solitary urticaria pigmentosa type with local MC-accumulation in a 12-year-old boy.

Degos et al. D39,601/57: A single plaque of bullous cutaneous mastocytosis on the dorsum of the left foot in a 6-month-old child.

Marshall et al. D29,474/57: Two cases of solitary mastocytoma presenting episodes of generalized flushing. The nature of the flushing phenomenon is compared with that observed in metastasizing argentaffinoma. The question of mastocytosis in general is reviewed and a system of clinical classification and nomenclature is proposed.

Jacobs D39,638/58: Solitary lesion.

Diffuse

Hadida et al. D63,180/56: Mastocytose cutanée diffuse.

Basset & Monfort D39,540/56: A 13-month-old infant with generalized cutaneous mastocytosis and an urticaria which is exaggerated by warm baths. None of the cutaneous efflorescences exhibit signs of urticaria pigmentosa, yet, histologically, they show MC-infiltrations.

Figure 21.—Cutaneous manifestations of mastocytosis. (*Top left*) Diffuse cutaneous infiltrate and bullae in generalized MC disease. Two-year-old child with polysystemic, generalized MC disease. (*Top right*) Widespread distribution of the macular type of urticaria pigmentosa. (*Middle right*) Clear tension bullae arising spontaneously on the skin of an 8-month-old infant with bullous urticaria pigmentosa. (*Bottom left*) Scotch-grained "lichenified" skin of a youngster with generalized MC disease. (*Bottom right*) Deeply pigmented macules of the adult type of urticaria pigmentosa. [After *Stutzman & Urbach* D14,152/61. Courtesy *Pediatric Clinics of North America.*]

Hemorrhagic

Pick D33,733/1881: A persistent kind of urticaria pigmentosa with hemorrhages is described under the name of "urticaria perstans haemorrhagica."

Asboe-Hansen D39,743/50: Two cases of "urticaria pigmentosa haemorrhagica," with the accumulation of melanotic and iron pigment in the skin. The hemorrhages may have been related to heparin production by the MCs.

Hissard et al. D39,583/51: Hematodermic form.

Hissard et al. D39,769/51: A case of mastocytosis with true tissue MCs in the circulating blood. There was a tendency to the formation of hemorrhages.

Berlin D30,375/55: Urticaria pigmentosa with widespread hemorrhages.

Brodeur & Gardner C21,475/56: Urticaria pigmentosa hemorrhagica.

ten Berg & Hermans E57,228/56: A fatal case of hemorrhagic urticaria pigmentosa.

Waters & Lacson D39,669/57: A case in which there was a prolonged bleeding time, ease of bruising, and at autopsy a subcapsular hematoma of the liver with the heparin and histamine content of the liver some 100 times over normal.

Couperus D39,621/57: Urticaria pigmentosa with a pronounced hemorrhagic diathesis.

Ende & Cherniss D39,554/58: Urticaria pigmentosa with repeated spells of nosebleeding.

Davis et al. D39,697/58: Urticaria pigmentosa with repeated nosebleeding.

Herzberg D39,565/59: Studies on the blood-clotting defect in the hemorrhagic type of urticaria pigmentosa.

Kogoj C82,505/59: A hemorrhagic form of urticaria pigmentosa is described under the name "mastocytosis mucocutanea haemorrhagica."

Grüneberg D30,668/62: Hemorrhagic and telangiectatic manifestations are much more common in adults than in children suffering from mastocytosis.

Bullous

Reviews: *MacLeod* D71,212/21
Dewar & Milne D39,692/55
Grüneberg E30,064/63

Hudelo et al. D39,709/27: "Urticaire pigmentaire à forme bulleuse."

Spillmann & Weille D39,654/37: Bullous urticaria pigmentosa in an infant with hereditary syphilis.

Konrad & Winkler D26,875/53: The bullous form of urticaria pigmentosa is usually combined with other types. The vesicles contain a clear or hemorrhagic fluid and may reach a diameter of about three inches.

Robbins D26,739/54: Purely bullous urticaria pigmentosa without pigmentation. Papules are other typical manifestations of the same disease.

Obermayer & Rosman D39,608/54: A case of purely bullous urticaria pigmentosa.

Degos et al. D39,579/54: A case of "bullous mastocytosis" with urticaria pigmentosa, diffuse MC reticulosis, and a bullous eruption.

Degos et al. D39,580/54: Diffuse urticaria pigmentosa with bullous eruptions.

Degos et al. D39,551/55: Solitary mastocytosis nodule with bullous transformation in an infant.

Dewar & Milne D39,692/55: Summary of the literature and report on two additional cases of bullous urticaria pigmentosa.

Basset & Monfort D39,540/56: Bullous urticaria pigmentosa in an infant.

Couperus D39,621/57; *Thorne* D39,670/57: Bullous urticaria pigmentosa.

Degos et al. D39,578/57: "Mastocytose multinodulaire bulleuse avec poussées généralisées"—is the name given to a case of multinodular bullous mastocytosis with frequent spells of flushing and pruritus in a newborn baby.

Asboe-Hansen E99,822/62: A case of bullous diffuse nonpigmented cutaneous mastocytosis in a one-year-old girl led to the urinary excretion of considerable amounts of nonsulfated mucopolysaccharide of the hyaluronic-acid type. The patient was successfully treated with cyproheptadine.

Unpigmented

Sézary et al. D26,815/35: A case of urticaria pigmentosa without pigmentation. Mast-cell proliferation was found in the deep layers of the skin but even histologically no pigment depositions could be demonstrated.

Sézary et al. D26,806/36: There are cases of otherwise typical urticaria pigmentosa with MC proliferation in which there is no pigmentation.

Gougerot et al. D39,729/39: A case of urticaria pigmentosa which was clinically atypical (non-pigmented) but histologically typical (rich in MCs).

Ayres D39,581/42: Urticaria pigmentosa without pigmentation.

Agostini D39,788/47: "Urticaria pigmentosa sine pigmentatione."

Degos & Vissian D39,542/49: A case of urticaria pigmentosa of tumoral xanthomatous aspect without brown pigmentation. Histologically, there was no evidence of lipid storage between the MC infiltrations.

Hissard et al. D39,583/51: Unpigmented urticaria pigmentosa with skin hemorrhages.

Degos et al. D39,586/53: MC-reticulosis without pigmentation.

Robbins D26,739/54: Mastocytosis without pigmentation.

Brinkmann D33,665/59: Unpigmented urticaria pigmentosa with pachydermia and typical spells of flush syndrome but without urtication upon cutaneous irritation. In the the final stages, an MC-leukemia developed.

Remy D32,662/62: In cases of urticaria pigmentosa without pigmentation, the prognosis is usually bad.

Maculo-papular

Kerl D39,694/13; *Becker* D39,619/54: Maculo-papular urticaria pigmentosa.

Berlin D30,375/55; *Barker* D33,656/57: Maculo-papular urticaria pigmentosa with systemic manifestations.

Xanthoma-like

Gougerot et al. D39,691/31: Report of a patient with urticaria pigmentosa with typical xanthoma cells in the skin lesions.

Duperrat & de Sablet D30,628/52: In certain forms of mastocytosis, there are yellow cutaneous papules which, however, consist exclusively of MCs and contain no Sudan-stainable lipids. They are called "mastocytose xanthelasmoïde."

Mast-cell nevus

Goldsmith & Wells D39,589/52: Urticaria pigmentosa verrucosa.

Drennan & Beare D26,760/54: The solitary "mast-cell naevus" represents one type of urticaria pigmentosa. The lesions contain many amitotic and a few mitotic divisions as well as numerous eosinophils and some crystalline and amorphous eosinophilic bodies, which are presumably special forms of Charcot-Leyden crystals. Up to 1 mg per g of histamine is found in the nevus tissue.

Cid D18,597/57: Usually MC nevi develop during early infancy or even in prenatal life and rapidly involute after birth. In the present case, however, the evolution was slow and necessitated surgical removal.

Mast-cell reticulosis

Degos et al. D39,580/54: Observation of several cases of "mast cell reticulosis" without pigmentation.

Lennert D39,800/55: A case of "mastocytoide Osteomyeloreticulose" with MC proliferation and fibrosis of the spleen, liver, and bone marrow, is accompanied by osteomyelosclerosis.

Degos D39,791/55: "Réticuloses mastocytaires diffuses."

Le Coulant & Texier D63,187/56: "Réticulose mastocytaire maligne."

Loewenthal et al. D39,620/57: Urticaria pigmentosa with systemic mastocytosis.

Remy D39,664/59: MC-reticulosis is characterized by MC accumulations in the skin and various organs, urticaria pigmentosa, enlargement of the spleen, lymph nodes and liver, a flush syndrome with occasional collapse, rapid pulse, decrease in blood pressure, headache, nausea, fever, and gastrointestinal symptoms, caused by histamine discharge into the blood. As a result of hyperheparinemia there may be disturbances in blood coagulation and changes in the lipoprotein spectrum of the blood. Often, there is also osteosclerosis.

Lennert D46,521/61: The so-called MC-reticulosis is identical with the generalized form of urticaria pigmentosa.

Remy D46,809/61: Description of the clinical characteristics of MC-reticulosis.

Grüneberg D30,668/62: In cases of MC-reticulosis or mastocytic leukemia, cutaneous manifestations are usually absent.

Rupe D58,296/63: On the basis of a literature survey and a personal observation, "systemic mast cell disease" is characterized by flushing, urtication, palpitation, nausea, vomiting, diarrhea, fever, night sweats, facial edema, and occasionally peptic ulceration. Inciting causes of histamine liberation from MCs have been cold, trauma, infection, alcohol, radiation of the spleen, and retroperitoneal nodes. No manifestations have been seen that could be attributed to hyperheparinemia.

Gonnella & Lipsey E95,219/64: In a 49-year-old Negro woman with severe systemic MC disease and hepatosplenomegaly due to MC infiltrations, there was no sign of urticaria pigmentosa although she showed dermographism and multiple foci of bone absorption.

Leukemic form

Jeanselme & Touraine D39,677/13; *Touraine et al.* D39,649/33: Urticaria pigmentosa associated with a myeloid leukemia.

Waters & Lacson D39,669/57: A case of MC-leukemia with a hemorrhagic type of urticaria pigmentosa and diffuse infiltration of various organs with MCs. There was a hundredfold increase in the histamine and "heparin" content of the liver, but the blood-clotting time was normal despite a prolonged bleeding time.

Various other forms

Levi D39,848/29; D39,784/30: *Urticaria papulosa perstans con pigmentazione.*

Gaté et al. D39,587/31: A case of generalized urticaria pigmentosa which is atypical because of the *intensity of the pruritus* and the *pseudo-tumoral* development of the lesions.

Touraine & Renault D39,751/34: A case of urticaria pigmentosa which appeared in a man at the age of 26 years and lasted for 18 years without remissions. It is designated, *"forme tardive à poussée unique."*

Pautrier D39,734/39: A case of urticaria pigmentosa which started at the age of 40 years and exhibited an *angiomatous* type.

Touraine & Harliz D39,679/47: "Urticaire pigmentaire à *début fébrile.*"

Kierland & Stegmaier D39,639/50: *Large nodular* type.

Michel & Saint-Paul D39,730/50: An *atypical* pigmented urticaria in a newborn infant.

Ende & Cherniss D39,554/58: *Splenic mastocytosis* is characterized by hypersplenism, episodic flushing, hemorrhagic tendency, vomiting, and an enlarged spleen which is heavily infiltrated with MCs. In one such case, splenectomy brought about a permanent remission.

Cramer F18,664/64: *Teleangiectasia macularis eruptiva perstans* is regarded as a special, comparatively pigment-poor form of urticaria pigmentosa. Synonyms: "téléangiectasies acquises généralisées," "téléangiectasies essentielles en plaques acquises," "Urticaria pigmentosa of the Parkes Weber type."

PATHOLOGIC ANATOMY

Among the structural changes characteristic of urticaria pigmentosa, the *skin* lesions received the greatest attention because they are particularly characteristic of the disease and easily accessible to study.

The presence of numerous MCs, first described by Unna in 1887, has been amply confirmed by subsequent investigators. These cells exhibit essentially the same characteristics as normal MCs although the metachromatic granules usually do not stain as intensely and are often less numerous. The MCs may show mitotic and amitotic divisions, however, these are rare. According to a recent electron-microscopic investigation, specific granules may even be missing, but different types of granules appear following mild local irritation. These granules swell and may be discharged by treatment with 48/80. Around the MCs, numerous eosinophils and some crystalline or amorphous eosinophilic bodies (presumably special forms of Charcot-Leyden crystals) are commonly observed. There may be edema and bulla formation.

For the diagnosis of urticaria pigmentosa, it is essential to stain the sections with metachromatic dyes since it is virtually impossible to recognize the MCs as such on ordinary hematoxylin-eosin-stained preparations.

In the systemic forms of urticaria pigmentosa, the *blood and hemopoietic organs* often contain an unusually large number of MCs. In the blood, these cells may be difficult to distinguish from large blood basophils, but several workers described cases in which they exhibited the typical characteristics of tissue MCs; these are thought to be released into the blood from the affected tissues. For this reason and because the tissue MCs are often surrounded by reticular fibers, the disease has been interpreted as a reticulo-endotheliosis and designated "mast-cell reticulosis". The association of urticaria pigmentosa with basophilic leukemia and osteomyeloscelerosis is certainly too frequent to be ascribed to mere coincidence. Mast-cell infiltrations may also occur in the bone marrow, spleen, liver, and lymph nodes of patients with generalized urticaria pigmentosa and in this event the spleen and liver are usually enlarged.

The *intestinal* tract may likewise be affected. In one case, non-pigmented papular lesions were found in the buccal mucosa. Typical nodules may also be seen in the stomach, small intestine and colon.

In recent years, the *skeletal lesions* of urticaria pigmentosa have attracted great attention. Focal osteosclerosis and osteoporosis may be encountered side by side, limited to circumscribed regions or diffusely distributed throughout the skeleton. In many of these cases, there are intense MC proliferations in the bone marrow associated with fibrosis and often bone proliferation. In view of the important relationships between the MCs, calciphylaxis, and calcergy, these changes deserve special study.

Reviews: *Knowles* E37,987/15; *Hissard et al.* D10,427/50; *Brodeur & Gardner* C21,275/56; *Herzberg* D39,565/59; *Stutzman et al.* C95,789/60; *Zakon et al.* D65,525/63

Skin

Bohač D27,597/06: MCs are unusually numerous in the skin lesions of patients with urticaria pigmentosa and xeroderma pigmentosum. Allegedly, there are direct transitions between MCs and pigment cells in both these conditions, which explains the genesis of melanosis in both these dermatoses.

Ormsby & Mitchell E25,267/23: In a case of urticaria pigmentosa, there was allegedly no MC proliferation in the cutaneous lesions.

Hannay E50,591/24: In a patient with otherwise typical urticaria pigmentosa, no noteworthy increase in MC density could be observed in the lesions.

Quevedo D39,834/43: Demonstration of numerous MCs in xanthelasmoid cutaneous urticaria pigmentosa lesion of an infant.

Drennan & Beare D26,760/54: The solitary MC nevus represents one type of urticaria pigmentosa. The lesions contain many amitotic and a few mitotic divisions as well as numerous eosinophils and some crystalline and amorphous eosinophilic bodies, which are presumably special forms of Charcot-Leyden crystals. Up to 1 mg per g of histamine is found in the nevus tissue.

Brodeur & Gardner C21,475/56: Hematoxylin-eosin may not demonstrate MCs in biopsy specimens of urticaria pigmentosa. Special stains are required.

Stark et al. D28,278/56: Biopsy material from patients with MC-reticulosis often shows granulomatous formations in which spindle-shaped cells are surrounded by dense fibrillar network. These cells contain only few metachromatic granules and are regarded dedifferentiated MCs.

Hasegawa & Bluefarb C97,856/60: In a patient with urticaria pigmentosa, there was no significant difference in the histologic appearance of lesions which had, and those which had not been urticated.

Johnson & Helwig D26,652/61: On the basis of histochemical studies on solitary mastocytomas of man, it is concluded that the MCs in the lesions contain sulfated acid mucopolysaccharide (presumably heparin) and mucoproteins, but no hyaluronic acid or 5–HT. Numerous eosinophils are present during the stage of initial edema and bulla formation and the MCs are intimately associated with a large number of reticulin fibers.

Gusek G19,632/61: The electron-microscopic appearance of the MCs in the cutaneous and systemic lesions of patients with systemic mastocytosis ("mast-cell reticulosis") is distinctly abnormal. The Golgi apparatus is enlarged. There frequently exist accessory nuclei (Nebenkerne). Lamellated granules are common and some of the granules resemble zones of cytoplasm which have been described in the literature as "Viroplasm."

Orfanos & Stüttgen D32,154/62: In a patient with mastocytosis, the MCs normally contained no specific (electron-dense) granules but different types of granules appeared following different kinds of mild local stimuli. Compound 48/80 induces swelling, granulation, degranulation, and cell disintegration in successive stages. (*Fig. 6, p. 62* and *Fig. 22, p. 258.*)

Demis E24,240/63: In mastocytosis, telangiectases, sometimes with pigmentation of the trunk and especially of the chest, are not unusual. They may be the most striking manifestation in one rare variant "telangiectasia macularis eruptiva perstans."

Ultmann et al. G19,654/64: The abnormal MCs of a patient with systemic mastocytosis contained a particularly prominent juxtanuclear Golgi zone and irregular electron-dense granules lying within lacunae.

Blood, bone marrow, lymph nodes, and liver

Groat et al. D39,568/36: Occasionally, mitoses may be found in the bone-marrow MCs of patients with urticaria pigmentosa.

Bertellotti E35,030/43: Histologic studies on the organs of a patient with systemic urticaria pigmentosa lead to the conclusion that the disease is a reticuloendotheliosis.

Hissard et al. D39,769/51: A case of mastocytosis with true tissue MCs in the circulating blood. Injection of adrenaline causes a splenic contraction which further increases the number of circulating tissue MCs.

Degos et al. D27,406/51; D30,625/52: In urticaria pigmentosa, spleen biopsies may show up to 70 per cent MCs.

Dewar & Milne D39,692/55: MC infiltrations are demonstrable in the lymph nodes of patients with urticaria pigmentosa.

Reilly et al. D10,435/55: MC proliferation may be demonstrable in liver-biopsy material in urticaria pigmentosa.

Brodeur & Gardner C21,475/56: The lymph nodes of patients with urticaria pigmentosa may contain many MCs.

Loewenthal et al. D39,620/57: Hepatosplenomegaly with diffuse MC infiltration of the spleen, liver, and bone marrow as well as effusions into the pleural and peritoneal cavities may occur in urticaria pigmentosa.

Asboe-Hansen C77,655/57: In one case of urticaria pigmentosa, the blood basophil and bone MC counts were enormously increased. This observation would suggest some close relationship between the blood basophils and the tissue MCs, but the author points out that the case is unique.

Friedman et al. D26,445/58: In a 34-year-old woman, neoplastic proliferation of tissue MC-type cells was seen in the viscera, lymph nodes, bone marrow, and peripheral blood. The case is designated as "tissue mast-cell leukemia." There were also recurrent pruritic, erythematous skin eruptions and a possible association with urticaria pigmentosa, and myeloid leukemia was considered.

Jensen & Lasser D39,704/58: Unpigmented urticaria pigmentosa associated with widespread sclerosis of the spongy parts of bone.

Lennert et al. D26,817/59: In a case of mastocytosis, the lymph nodes contained numerous MCs which could be stained with toluidine blue only at very low *p*H. Following artificial sulfation, these MCs were tingible with toluidine blue, even at very high *p*H.

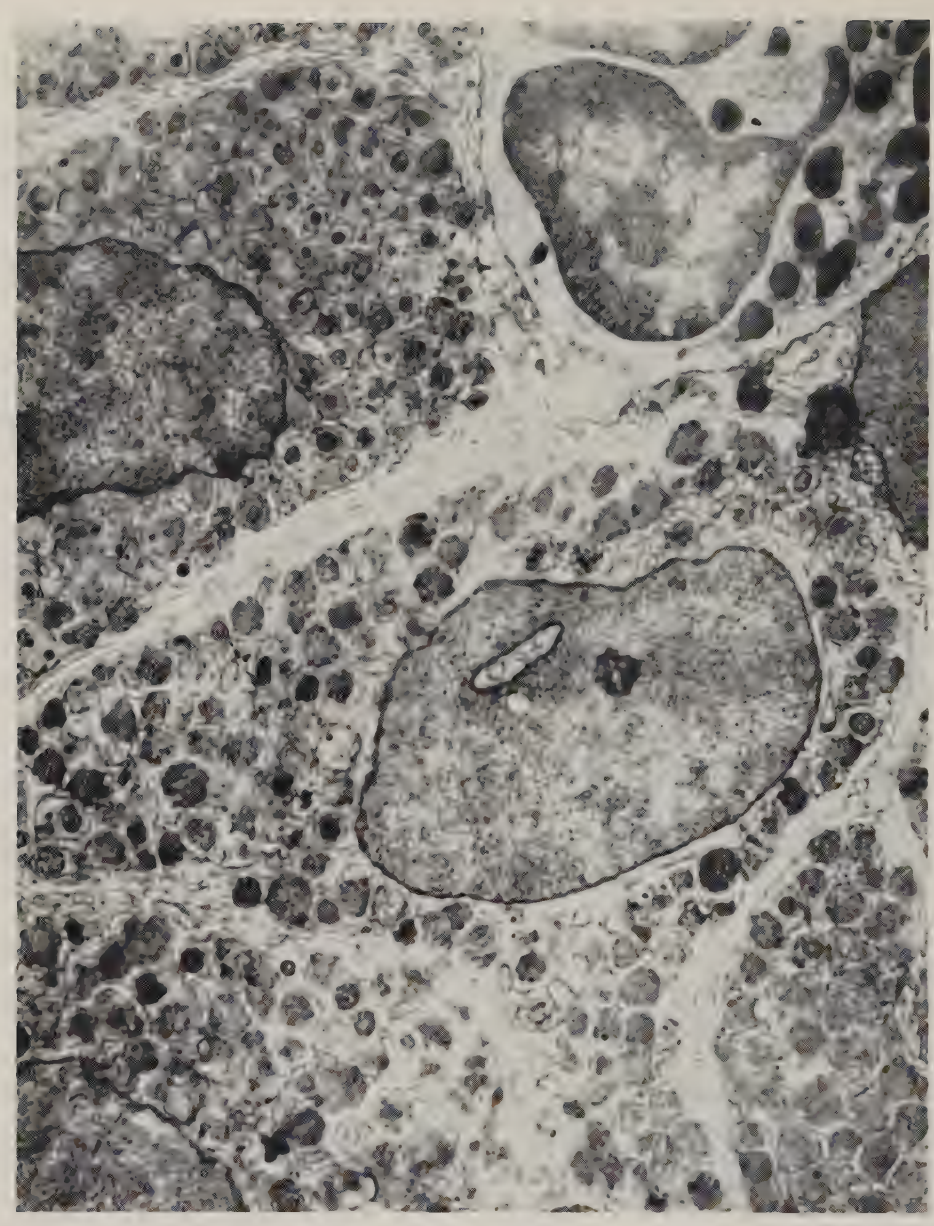

Figure 22.—Mast cells in diffuse cutaneous mastocytosis. The MCs are densely packed with specific granules, some of which coalesce (*near bottom*) while others are in the process of extrusion. For comparison, in upper right corner an eosinophil is shown with its characteristic electron-dense granules that contain inclusions. Picture taken two hours after irritation with compound 48/80. (Fixation in OsO_4. Embedding in Vestopal W subsequently treated with uranyl acetate. X 12,000.) [After *Stüttgen, unpublished.*]

Ende & Cherniss D39,554/58: In a case of splenic mastocytosis, the spleen and liver contained heavy MC infiltrations, although there were no cutaneous infiltrates. Several additional cases are cited from the literature in which typical urticaria pigmentosa was associated with a great increase in splenic MC density.

Ende & Cherniss D39,554/58: In a case of isolated splenic mastocytosis, the bone marrow exhibited no increase in basophils or tissue MCs.

Brinkman D33,665/59: A case of generalized mastocytosis with "phenomenal flushing" and shock-like spells eventually terminated in basophil leukemia. Presumably, close relationships exist between tissue MCs and blood basophils. In the bone marrow, MCs represented 90 per cent of the nucleated cells.

Boseila C68,531/59: In two cases of urticaria pigmentosa, pronounced basophilia was noted.

Havard & Scott C85,492/59: In a patient with urticaria pigmentosa and skeletal lesions, there was also splenomegaly and hepatomegaly.

Asboe-Hansen D26,742/60: In a patient with urticaria pigmentosa and generalized tissue mastocytosis, there was also basophilic leukemia, a fact which "supplies support of the modern view that the blood basophils have some relationship to the tissue mast cells."

Fisher C85,479/60: In patients with leukemia of the tissue-MC type, there may develop pruritic erythematous eruptions of the skin, similar to those of urticaria pigmentosa without MC infiltration of the affected areas. In some patients with this type of leukemia, dermal lesions were evident which, when stimulated, resulted in the formation of urticarial wheals. "Although these cases do not resemble classic urticaria pigmentosa, there appears to be sufficient similarity to suggest that perhaps tissue mast cell leukemia may represent a variation of this disorder."

Schuster D26,851/61: In urticaria pigmentosa, a discharge of tissue MCs into the blood is not observed.

Szweda et al. D20,223/62: A case of systemic mastocytosis was associated with MC-leukemia.

Remy D32,662/62: The blood count rarely shows any significant changes in cases of urticaria pigmentosa. Sometimes there is a slight normochromic anemia with normal blood-iron values. The white-cell count is somewhat variable but occasionally there is eosinophilia, leukocytosis, or leukopenia. The sternal bone marrow frequently shows hyperactivity in cases of urticaria pigmentosa, but here, the MC count is only occasionally increased although sometimes there are nodules of MCs between the marrow cells.

Cavegn F16,869/64: A case of urticaria pigmentosa with telangiectasia macularis eruptiva perstans, an increased number of blood basophils and X-ray changes suggestive of osteomyelosclerosis.

Gonnella & Lipsey E95,219/64: In a 49-year-old Negro woman with severe systemic MC disease and hepatosplenomegaly due to MC infiltrations, there was no sign of urticaria pigmentosa although she showed dermographism and multiple foci of bone absorption.

Sandler & Putschar G19,842/64: A case of urticaria pigmentosa with MC infiltration of the liver.

Intestinal tract

Leitão & Trincão D39,615/52: In a case of urticaria pigmentosa, nonpigmented papular lesions were found in the buccal mucosa, while the cutaneous infiltrations were associated with melanotic pigmentation and sclerosis.

Janower D64,689/62: In a case of urticaria pigmentosa, "the intestinal mucosa folds were thickened and studded with innumerable small nodules measuring up to 4 mm in diameter. The small intestine was most involved but also the stomach and colon revealed abnormalities."

Bones

Schwarz G9,072/01: In a case of leukemia with a greatly increased blood MC count there was osteosclerosis, but several other cases of osteosclerosis occurred in patients with leukemia, unaccompanied by an MC-increase.

Sagher et al. D10,437/52: Skeletal lesions in urticaria pigmentosa.

Clyman & Rein D39,698/52: Two cases of urticaria pigmentosa with roentgenographically demonstrable bone lesions.

Hauser D26,883/53: In urticaria pigmentosa, the MC content of the bone marrow is usually increased.

Asboe-Hansen D31,588/53: A case of urticaria pigmentosa with bone lesions.

Calnan D31,593/53: A case of urticaria pigmentosa with bone lesions.

Calnan D39,552/53: A 24-year-old female with urticaria pigmentosa and a "small, ill-defined defect in the right frontal bone, about 5 mm in diameter."

Grupper D31,576/54: Several cases of urticaria pigmentosa with bone lesions.

Bluefarb & Salk D39,514/54: Osteosclerosis in a patient with urticaria pigmentosa.

Schorr et al. D63,795/56: Two cases of generalized osteosclerosis with urticaria pigmentosa.

Sagher et al. D33,675/56: In a case of urticaria pigmentosa, massive accumulations of MCs in the bones were associated with myelofibrosis and osteosclerosis.

Deutsch et al. D28,280/56: Review of the literature and personal observations on patients with urticaria pigmentosa who showed both osteosclerosis and osteoporosis side by side.

Edelstein D31,574/56: Case of urticaria pigmentosa with periosteal thickening of the femora, humeri, and proximal ends of the radius which developed unilaterally. No anomaly was found in the rest of the skeleton.

Stark et al. D28,278/56; *Sagher* D27,978/56; *Sagher & Schorr* D28,279/56; *Zak et al.* D27,410/57; *MacDonald & Peirce* D33,106/57: Skeletal changes are quite common in urticaria pigmentosa where focal deposition of new bone occurs preferentially in the bone marrow around MC granulomas.

Efrati et al. D25,560/57: Focal osteosclerosis in the vertebrae in a woman with presumed "mast-cell leukemia."

Barker D33,656/57: A case of urticaria pigmentosa in a 58-year-old man with decalcification of the bones and a blood calcium of 16.5 mg per cent which responded well to Meticorten therapy. Several additional cases of urticaria pigmentosa with associated skeletal lesions were mentioned by discussants of this communication.

Hasselmann & Scholder-Oehmichen C47,971/57: A case of urticaria pigmentosa with bone lesions.

Beare D27,976/58: Review of urticaria pigmentosa with special reference to the associated bone lesions which are common in this disease.

Lennert & Schubert D26,816/59: Bone-marrow MCs are especially numerous in cases of mastocytosis with urticaria pigmentosa.

Jensen & Lasser D39,704/58: Case of urticaria pigmentosa with widespread osteosclerosis.

Brinkmann D33,665/59: A case of mastocytosis with pronounced osteosclerosis.

Orkin & Schwartzman D67,468/59: Rarefaction of the ischium was observed in a case of canine mastocytoma.

Bürgel & Oleck D39,675/59: A case of urticaria pigmentosa with widespread skeletal lesions.

Remy D39,664/59; *Poppel et al.* B30,192/59: In MC-reticulosis, there is often osteosclerosis.

Brogren et al. C69,050/59: Osteosclerosis is frequently seen in urticaria pigmentosa.

Havard & Scott C85,492/59: In a patient with urticaria pigmentosa and skeletal lesions, there was also splenomegaly and hepatomegaly.

Lees & Stroud E34,936/59: In a series of 32 children with urticaria pigmentosa, four showed significant bone involvement.

Lerner & Lerner E35,351/60: In a woman with urticaria pigmentosa, skeletal changes were associated with bilateral otosclerosis.

Hasegawa & Bluefarb C97,856/60: A patient with urticaria pigmentosa and bone lesions.

McKellar & Hall D26,621/60: In a case of systemic mastocytosis, there was extensive patchy osteosclerosis combined with hereditary spherocytosis.

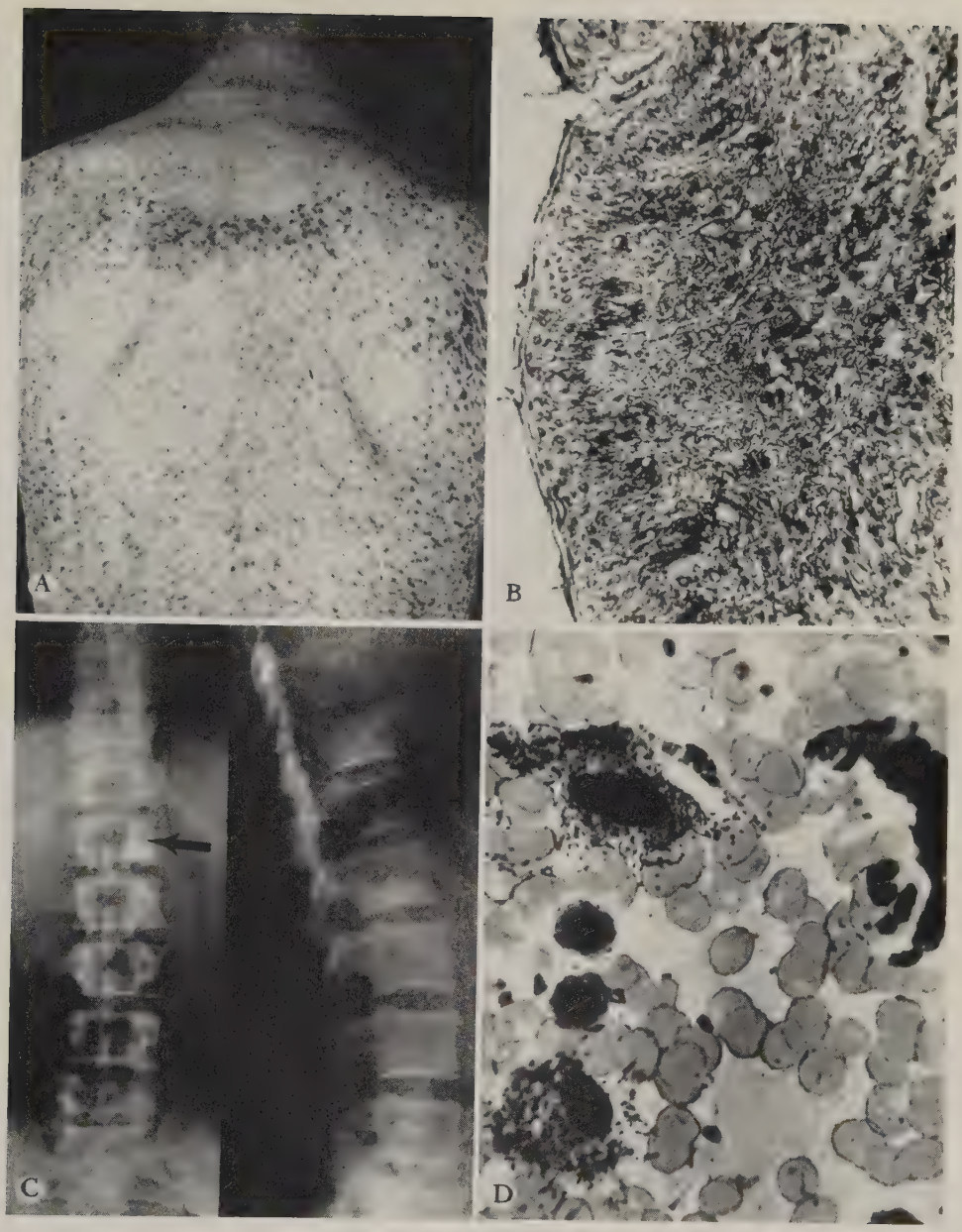

Figure 23.—Urticaria pigmentosa (mastocytosis). A: Extensive skin lesions on the back. *B*: Skin biopsy showing multitude of MCs in corium. *C*: (*Left*) Antero-posterior X-ray of dorso-lumbar spine showing coarse and dense vertical trabeculae and condensing islets in vertebral bodies (*arrow*). (*Right*) Lateral roentgenogram of dorso-lumbar spine showing essentially similar changes. *D*: Bone-marrow aspirate showing MCs with coarse granules in cytoplasm (oil immersion). [After *Poppel et al.* B30,192/59. Courtesy Yearbook Publishing Inc. and *American Journal of Radiology*.]

Bloom et al. D8,351/60: In a man with malignant systemic-MC disease, severe bone changes were associated with an increased histamine and heparin content in the mastocytoma tissue itself as well as in the blood and urine.

Sagher & Even-Paz D9,772/61: Detailed description of skeletal changes in mastocytosis.

Brinkmann D26,693/62: Osteosclerosis occurs in patients with mastocytoma.

Teichert D26,594/62: The histologic appearance of the medullary spongy bone in urticaria pigmentosa is very similar to that of the osteomyeloscleroses that are associated with certain types of leukemia and anemia.

Fernex D39,200/62: Skeletal lesions, sometimes with osteomyelosclerosis, are not uncommon in urticaria pigmentosa.

Remy D32,662/62: A survey of the literature suggests that skeletal lesions are among the most common systemic manifestations of urticaria pigmentosa.

Demis & Zimmer D58,631/63: Skeletal lesions in systemic mastocytosis.

Bank & Marks D35,275/63: Osteosclerosis with osteoporosis and spontaneous fractures or "pseudofractures" in a woman with generalized urticaria pigmentosa.

Rabinovich & Ley D66,453/63: Urticaria pigmentosa with skeletal lesions in a woman.

Mutter et al. E36,471/63: Intense skeletal lesions in a case of generalized mastocytosis.

Sirois E31,826/63: In a man with generalized mastocytosis, there was also osteosclerosis and hypocalcemia.

Bendel & Race E20,636/63: In a five-year-old girl with urticaria pigmentosa, there was osteosclerosis with histologically demonstrable MC-infiltration of the marrow and proliferation of trabecular bone.

Schorr et al. G1,315/64: In an adult male patient, progressive urticaria pigmentosa was associated with osteomyelosclerosis and occlusive panarteritis in subcutaneous nodules.

Cavegn F16,869/64: A case of urticaria pigmentosa with telangiectasia macularis eruptiva perstans, an increased number of blood basophils and x-ray changes suggestive of osteomyelosclerosis.

Gonnella & Lipsey E95,219/64: In a 49-year-old Negro woman with severe systemic MC disease and hepatosplenomegaly due to MC infiltrations, there was no sign of urticaria pigmentosa although she showed dermographism and multiple foci of bone absorption.

Ultmann et al. G19,654/64: Extensive skeletal involvement in a patient with systemic mastocytosis.

CLINICAL COURSE

As we have said before (Cf. CLASSIFICATION), the various forms of mastocytosis tend to overlap. In the following pages, we shall not attempt to deal with all the many intermediate forms but will limit ourselves to the description of the most typical variants arranged according to the system of *Degos* (D58,430/63).

(1) *Common urticaria pigmentosa.* — The typical common urticaria pigmentosa is characterized by the appearance of brownish patches irregularly distributed all over the body, although they may affect one region more than another. Their number can vary between about a dozen and several hundred. If they are very numerous, they give a "leopard skin" or "trout skin" appearance to the integument. Hyperemia may somewhat mask the pigmentation but the latter is readily detectable when the skin is viewed through a compressing plate of glass.

The incidence of common urticaria pigmentosa is greatest in children. The disease may even be present at birth, but it is not exceptional in adults and has been known to make its first appearance quite late in life. Sometimes itching dermographism and the formation of congested papules may precede pigmentation, but this is uncommon.

The characteristic papules are congested, itchy and, as a rule, there is intense dermographism. Local irritation (e.g., rubbing with a blunt instrument) can precipitate urtication and thermal stimuli, for example hot baths, may provoke a serious crisis. The provocation of urtication by friction is an important diagnostic sign, if the adjacent normal skin fails to react in the same manner; otherwise we may be dealing with simple dermographism. In the event of induced urtication, the papule becomes prominent and reddish owing to congestion; this is associated with an intense pruritus which may last several hours. The erectility of the papules is ascribed to the liberation of histamine by MCs during irritation.

Another typical manifestation of mastocytosis is the "flush-syndrome" which appears in spells, often as a consequence of thermal, mechanical or emotional stimulation. It is characterized by a suddenly developing hyperemia of the face and thorax, tachycardia, precordial pain, nausea, vomiting, headache and, in several cases, a sharp drop in blood pressure with collapse. Not infrequently, the flush is associated with fever, intestinal colic and diarrhea.

The flush may give rise to diagnostic difficulties between urticaria pigmentosa and the carcinoid syndrome, since the latter can also cause periodic flushing of the face and thorax. However, the typical flush of the carcinoid syndrome is short (generally lasting only 10 minutes or less) and usually of a bluish cyanotic hue unlike the bright red erythematous flush of mastocytosis.

In the *juvenile form,* the papules are usually quite large (2–3 cm or more in diameter), oval and frequently arranged along cutaneous folds. Their color is yellowish or light brown and they tend to be slightly elevated, very itchy and easily provoked to urtication. In rare instances, they even progress to the formation of bullae. When only a few large spots are present, they may resemble drug-induced rashes.

In the *adult form,* it is more common to find macules than papules. The individual lesions are small, brownish-purple and soft rather than pasty as in the juvenile form. These macules rarely produce pruritus (except if they are very diffuse) and they are rather stable, not very subject to sudden exacerbations. They may confluence into large reddish-brown plaques which form a transition to the diffuse mastocytosis. Hemorrhagic forms of urticaria pigmentosa are quite uncommon both in children and in adults.

(2) *Nodular and papular mastocytoses.* — The nodular forms of urticaria pigmentosa show many variants but are almost exclusively seen in infants and very young children.

The type described as xanthelasmoïdea shows the closest resemblance to common urticaria pigmentosa. The lesions are slightly prominent, oval, measuring a few centimeters in diameter. They exhibit a yellowish color and a pasty, somewhat elastic consistency. Their surface may be smooth or of a lichenoid aspect. They can be mistaken for xanthomas or "café au lait" nevi. Upon provocation, the plaques become hyperemic and swollen sometimes (especially during the first two years of life) with a tendency to form bullae.

When only one such plaque is present, it is sometimes referred to as a single cutaneous mastocytoma ("mastocytose à plaque unique"), a condition almost exclusively seen in infants. However, this distinction may be somewhat artificial since in fact here we are dealing with a single xanthelasmoïdea lesion. Actually, the

term mastocytoma should be applied only to single, very small circumscribed brownish and prominent tumors, which resemble nevus carcinomas. They are very rare in man, although they occur with comparative frequency in old dogs, as we shall see later.

The multinodular globular form is rather distinctive in its appearance, especially because it is usually unaccompanied by pigmentation ("urticaria depigmentosa"). The individual nodules measure only a few mm in diameter and are very prominent, almost hemispheric, sometimes reddish, sometimes white or yellow. Because of this unusual appearance, the condition is often not correctly diagnosed. As a rule, such lesions appear in very large numbers throughout the skin and they cannot easily be modified by friction; this further adds to the diagnostic difficulties. The nodules can proceed to the formation of bullae which eventually tend to become pale, flat and yellow with transition to the macular variety.

The coalescent nodular form consists of white or yellowish prominences which may impart a quilt-like aspect to the skin.

The *papular form,* as the name implies, consists almost exclusively of papules; these are not pigmented and may appear either in adults or in children. They exhibit the appearance of lichenoid or pseudoxanthomatous papules.

All forms of mastocytosis may be accompanied by the flush-syndrome, especially in infants, but as the child reaches the age of about two years, the flushes become rare and, eventually, disappear, simultaneously with the tendency to the formation of bullae.

(3) *Bullous mastocytoses.* — The bullous forms of urticaria pigmentosa are seen almost exclusively in children less than two years of age. However, in such very young children, the formation of bullae may accompany any form of mastocytosis, although it is most common in the nodular type and exceptional in the purely macular variety. If the dermatosis consisted only of bullae, the diagnosis would be very difficult, but this is rarely the case, since vesicle formation is superimposed upon other more typical manifestations of urticaria pigmentosa. It is possible however, that the purely bullous variant — if it exists — remains unrecognized.

The typical bulla of mastocytosis is round, pemphigoid and tensely filled with clear fluid. It may reach a diameter of about 2 cm, but tends to disappear within a few days without leaving a scar. When many bullae are present, they may imitate Dühring's disease; after they begin to regress and are transformed into scabs they strikingly resemble impetigo. In such instances, the diagnosis can be made only on the basis of coexistent typical urticaria pigmentosa lesions. Although scrapings often reveal no MCs, these can be demonstrated on biopsy specimens stained with metachromatic dyes.

(4) *Diffuse mastocytoses.* — In diffuse mastocytosis, the skin is yellowish of pasty consistency and thickened. The surface is smooth or more frequently sprinkled with small elevations consisting of minute papules which give the skin a grain-leather appearance ("peau chagrinée" of the French dermatologists). The cutaneous furrows and wrinkles (e.g., in the arm pits) become very prominent. Because of the diffuse character of the lesions, the provocation of urtication and dermographism is of little diagnostic value. The coexistence of small yellowish elevations can give the impression of pseudoxanthoma elasticum. In mild forms, the lesions may be limited to the arm pits, while in severe cases, most of the skin

becomes cross-hatched, pasty and of lichenoid appearance. The small papules and nodules penetrate deeply into the dermis and are readily eroded by rubbing. Fibrous bridges of cheloid-like appearance may also develop. Usually, pruritus is especially pronounced in these forms.

The diffuse mastocytoses are rare and have only been recognized as a form of urticaria pigmentosa during the last two decades. However, their appearance is sufficiently typical to permit diagnosis even in the absence of other characteristic signs of the disease.

(5) *Extracutaneous or systemic mastocytoses.* — As previously mentioned, systemic manifestations may accompany most of the forms of mastocytosis, although in the vast majority of the cases lesions are limited to the skin.

The morphologic changes, which are most frequently found especially in the hemopoietic organs, the intestinal tract and the skeleton, have been surveyed in the section on *Pathologic Anatomy,* so that we need not touch upon this topic here.

Incidence of findings

Demis et al. D2,184/61; *Demis* E24,240/63: Incidence of findings in 113 cases of mastocytosis:

	(%)
Flushing	36
Tachycardia	18
Headache	10
Weakness, fatigue, general malaise, weight loss	12
Gastrointestinal symptoms	23
Duodenal ulcer	4
Respiratory distress	6
Skin lesions (urticaria pigmentosa)	99
Hepatomegaly	12
Splenomegaly	11
Osseus lesions	9

Flush-syndrome

Bory D39,624/27: Urticaria pigmentosa with severe flush-syndrome which can be precipitated by the application of carbon dioxide snow. Under the influence of cold there appeared, within a few minutes, intense hyperemia of the face and thorax with dyspnea, precordial pain, fainting, nausea and tachycardia. Adrenaline brought improvement.

Touraine & Harliz D39,679/47: Attacks of flush-syndrome, fever and nausea in urticaria pigmentosa.

Hissard et al. D39,583/51: 50-year-old patient with urticaria pigmentosa. Sudden nocturnal attacks of pruritus, tachycardia, precordial pain, and shivering appear, usually lasting 15 to 30 minutes.

Dewar & Milne D39,692/55: Spells of cyanosis and convulsions in a child with urticaria pigmentosa.

Ende & Cherniss D39,554/58: 35-year-old man with the typical flush-syndrome of urticaria pigmentosa and a splenic tumor but no cutaneous manifestations.

Herxheimer E57,641/58: A man of 49 years of age, who has had widespread urticaria pigmentosa as long as he can remember. During the last ten years he has had "attacks of flushing of the skin, headache and nasal obstruction. The flush, which may be accompanied by feeling faint, is most intense on the face, less on the trunk and arms, and least on the legs. The body temperature may be raised during the attack to 101–102°F. Towards the end of the attack, he sometimes feels nausea; vomiting has occurred on four occasions. In some attacks there is an urge to defecate, but no pain. In a few attacks he has lost consciousness and he

has twice been incontinent of urine. The skin lesions show no change during an attack. The attacks, which last about half an hour, occur at irregular intervals, singly, or in twos and threes within a few days. Between these bouts he is free for 1–8 weeks (average two weeks). Attacks are not brought on by alcohol or aspirin, by baths or skin friction and no precipitating factors have been discovered."

Brinkmann D33,655/59: In a case of systemic mastocytosis, "phenomenal flushing" of several hours duration accompanied by sudden drop in blood pressure, shock, tachycardia, hypersecretion of the stomach, urticaria, and headache in which these symptoms are ascribed to sudden histamine liberation. At the same time, there was heparin production as judged by delayed blood coagulation.

Herzberg D39,565/59: Severe flush-syndrome crises appear following baths in a child with urticaria pigmentosa.

Remy D39,664/59: Female patient with typical attacks of flush-syndrome but no cutaneous manifestations of urticaria pigmentosa. She had a splenic tumor and slight liver enlargement. Biopsy shows 2.6 per cent MCs in the spleen while the liver exhibits fibrosis without MC proliferation.

Remy D32,662/62: Detailed description of the flush-syndrome in urticaria pigmentosa. In the event of severe attacks, there is a drop in blood pressure, acceleration of the pulse, precordial pain, collapse, vomiting, fever, and occasionally intestinal and urinary incontinence. The clinical picture is that of a severe anaphylactic shock and in the occasional patient in whom the cutaneous manifestations are lacking, a differential diagnosis may be difficult.

Gastrointestinal tract

Jeanselme & Touraine D39,677/13; E21,110/19: Urticaria pigmentosa is so frequently associated with intestinal complications that it is considered as the consequence of the latter.

Sagher et al. D10,437/52: Gastric disturbances may precede the outbreak of skin lesions in urticaria pigmentosa.

Canizares D39,557/53: Case of urticaria pigmentosa with a troublesome "nervous stomach".

Bluefarb & Salk D39,514/54: In a 30-year old patient with urticaria pigmentosa, there was meteorism, constipation, intestinal cramps, and vomiting.

Robbins D26,739/54: Strong intestinal colics may complicate the course of urticaria pigmentosa.

Berlin D30,375/55; *Reilly et al.* D10,435/55: Diarrhea and voluminous stools are often associated with urticaria pigmentosa.

Deutsch et al. D28,280/56: A case of urticaria pigmentosa in which intestinal disturbances led to an appendectomy (which, of course, brought no improvement).

Zak et al. D27,410/57: Urticaria pigmentosa with a polyp in the antrum of the duodenum.

Couperus D39,621/57: A case of urticaria pigmentosa with severe intestinal hemorrhages.

Bürgel & Oleck D39,675/59: Diarrhea in urticaria pigmentosa.

Demis et al. D2,184/61; *Demis* E24,240/63: Peptic ulcers are comparatively frequent in patients with urticaria pigmentosa.

Remy D32,662/62: A case of urticaria pigmentosa with polyposis of the duodenal bulbus. In two other cases, there was pronounced gastric hyperacidity with secretory and motor disturbances of the small intestine.

Blood coagulation

Review: *Herzberg* D39,565/59

Bolgert & le Sourd D39,543/49: A 34-year-old woman with urticaria pigmentosa and a moderate disturbance of blood coagulation.

Bergström et al. D30,555/50: Description of a case of mastocytoma with hemorrhagic diathesis, presumably due to increased heparin production.

Hissard et al. D30,630/50: In a case of mastocytosis, there was an extraordinarily pronounced hemorrhagic tendency which was ascribed to the excessive formation of heparin.

Degos et al. D27,406/51: In a case of generalized mastocytosis, the blood-heparin content was not noticeably increased, but there was a slight tendency towards the formation of hemorrhages.

Leitão & Trincão D39,615/52: In a case of urticaria pigmentosa, there was an increase in blood platelets and a diminished blood-coagulation time.

Degos et al. D30,625/52: A case of generalized mastocytosis with a coagulation defect.

Berlin D30,375/55: A case of urticaria pigmentosa with multiple hemorrhages in which blood obtained by expression from injured skin lesions contained a heparin-like substance.

Deutsch et al. D28,280/56: Review of the literature and personal observations on patients with urticaria pigmentosa who showed delayed blood coagulation, presumably as a consequence of increased heparin production.

Stark et al. D28,278/56: Coagulation defects are rarely seen in urticaria pigmentosa despite presumptive evidence of an increased heparin production.

Remy D31,528/57: Hemorrhages and a demonstrable coagulation defect are common in urticaria pigmentosa.

Waters & Lacson D39,669/57: A case of MC-leukemia with a hemorrhagic type of urticaria pigmentosa and diffuse infiltration of various organs with MCs. There was a hundred-fold increase in the histamine and "heparin" content of the liver, but the blood-clotting time was normal despite a prolonged bleeding time.

Beurey et al. D26,744/59: A case of cutaneous mastocytosis with gingival and cutaneous hemorrhages.

Remy D32,662/62: An extensive survey of the literature revealed only two cases of urticaria pigmentosa with significantly prolonged bleeding-time and four in which the bleeding-time was near the upper limit of the norm. In some additional cases the prothrombin values were below normal and the Quick test was positive. Sometimes, the plasma thrombokinase decreased and the elasticity of the thrombi was diminished. In eleven cases examined by the author, the blood-thrombocyte values were slightly below normal.

Degos D58,430/63: In a large group of patients with mastocytosis, no noteworthy change in the blood-coagulation mechanism could be detected.

Chemical changes

(Cf. BIOCHEMISTRY, *p.* 301.)

DIAGNOSIS

In typical cases, the diagnosis of urticaria pigmentosa causes no difficulties because of the previously described characteristic cutaneous lesions which readily urticate upon mechanical or thermal stimulation. The chronic course of the disease, the pruritus and the frequent presence of flush-syndrome spells, further facilitate the diagnosis. In the comparatively rare cases of systemic mastocytosis, enlargement of the liver and spleen, gastrointestinal disturbances, and radiologically-detectable foci of osteoporosis and osteosclerosis are of diagnostic value.

The differential diagnosis between mastocytosis and the carcinoid syndrome may be difficult. However, in mastocytosis, the flush is red, the skin lesions urticate and show dermographism upon irritation and urinary histamine elimination is greatly increased while, in the carcinoid syndrome, the flush is cyanotic, the skin lesions pellagra-like and the characteristic urinary excretion products are 5–HT metabolites. Still, in occasional cases of carcinoid syndrome, histamine excretion may likewise be increased (especially in cases of gastric carcinoids) and then the flush is red as in urticaria pigmentosa. Both in mastocytosis and in the carcinoid syndrome, the flush is episodic but in mastocytosis it tends to last thirty minutes or more, while with carcinoids it lasts only ten minutes or less.

The following table (based largely on *Demis* E24,240/63) summarizes some of the salient characteristics of the two syndromes for comparison:

SOME TYPICAL CHARACTERISTICS OF MASTOCYTOSIS AND CARCINOIDOSIS

	Mastocytosis Syndrome	*Carcinoid Syndrome*
Symptoms	Erythematous flush (duration about 20–30 minutes)	Cyanotic flush (duration about 10 minutes)
	Telangiectases	Telangiectases
	Diffuse gastrointestinal complaints, diarrhea	Gastrointestinal complaints, diarrhea
	Pruritus	Respiratory distress
Findings	Characteristic skin lesions of urticaria pigmentosa with urtication and dermographism upon irritation	Pellagra-like skin lesions
	Foci of osteosclerosis and/or osteoporosis	Cardiac valvular disease
	Hepatosplenomegaly	Hepatic metastases
	Peptic ulcer	Connective-tissue proliferation
Primary lesion	MC proliferation	Argentaffin tumor with metastases
Characteristic chemical changes	Enzyme: histidine decarboxylase	Enzyme: 5–HT decarboxylase
	Mediator: histamine	Mediator: 5–HT
	Metabolite: 1,4-methylimidazole acetic acid (MeImAA)	Metabolite: 5–Hydroxyindole acetic acid (5–HIAA)

Reviews: *Klotz* E37,427/07
Biach E37,595/12

Decker & Luscombe D39,696/54: Discussion of relationship between urticaria pigmentosa and incontinentia pigmenti.

Kogoj C82,505/59: An extract is prepared from the skin lesions of patients with urticaria pigmentosa and its active principle, designated as "mastocytine." Intracutaneous injection of this extract produces a delayed papular form of skin reaction, reminiscent of that elicited by tuberculin, in patients with urticaria pigmentosa, but not in normal individuals or those suffering from other diseases. The reaction does not depend upon the histamine, heparin or 5–HT content of the preparation but presumably upon a specific antigen.

PROGNOSIS

When urticaria pigmentosa begins in early childhood, it tends to disappear with age but in some cases it may become chronic and last throughout life. When the disease appears in adults, remissions are rare and the disease may go on for decades with only minor fluctuations in its severity.

Generalized mastocytoses, particularly MC-leukemia, are usually fatal within a month.

Margarot & Bourgoing E37,981/21–22: Urticaria pigmentosa of 18 years' duration.

Canizares D39,557/53: A 39-year-old woman with generalized urticaria pigmentosa of 21 years' duration.

Dickison E53,143/57: Urticaria pigmentosa developing early in childhood has the best chance of a complete remission.

Remy D32,662/62: The prognosis of urticaria pigmentosa is extremely variable. When the disease begins in early childhood, it tends to disappear with age but some cases are extremely chronic and may last throughout life. When the disease appears in adults, spontaneous remissions are more exceptional. Generalized mastocytosis and particularly MC-leukemia are the forms which most frequently end in death.

Klaus & Winkelmann G18,747/62: In a series of 26 children with urticaria pigmentosa, the prognosis was, in general, very good. Six patients showed complete clearing, and 14 definite improvement. Isolated nodular lesions have a better prognosis than the maculopapular ones, especially if the onset is after the sixth month of life.

Braunsteiner G10,415/64: When urticaria pigmentosa develops in childhood, complete remissions may occur. When the disease appears during adult life, it usually goes on for years and decades with only minor variations in its severity. In rare instances, when mastocytosis becomes generalized, there is enlargement of the liver and spleen, progressive anemia and eventually fatal MC-leukemia develops.

PATHOGENESIS

Nothing is known about the mechanism conducive to MC proliferation although it has been considered as possibly related to the phagocytosis of heparin or similar polysaccharides. In any event, most of the manifestations of mastocytosis can be explained as a consequence of the liberation by the proliferating MCs of histamine, heparin, and possibly other active compounds.

Reviews: *Balbi* D39,846/49
Remy D32,662/62

Knowles E37,987/15: "A congenital abnormality of the skin has apparently been proven in cases of urticaria pigmentosa, by the finding of mast-cells in the clinically normal skin of those with this affection."

Hudelo & Cailliau D39,740/28; G6,824/28: Urticaria pigmentosa is considered to be a disease of the RES.

Sézary et al. D26,805/36: In cases of urticaria pigmentosa, MCs are most common in those regions of the skin which are affected by the disease, yet, even in otherwise healthy skin with strong dermographism, the MC number is increased though not quite to the same extent. It is postulated, therefore, that substances liberated from the MCs during friction are responsible for the factitious urticaria in these cases.

Cottenot D27,990/54: At sites where MCs accumulate, there occurs a competitive binding of thiol groups. Possibly the elimination of antityrosinase effect may be responsible for the pigmentation characteristic of urticaria pigmentosa.

Brodeur & Gardner C21,475/56: MC proliferation in urticaria pigmentosa may be a secondary phenomenon consequent upon the phagocytosis of heparin or similar compounds.

Remy D31,528/57: Review of the literature and personal observations on mastocytomas. "Many of the typical features of the disease are explainable on the basis of MC function, i.e., formation and storage of histamine and heparin. Thus, histamine is responsible for the urticarial signs, the capillary changes and the gastro-enteritic symptoms, while changes in coagulation and abnormalities of lipoprotein metabolism are considered the consequence of hyperheparinaemia."

Remy D32,662/62: A survey of the literature and personal observations lead to the conclusion that most of the manifestations of mastocytosis are due to the discharge of histamine and perhaps also 5–HT and heparin from the proliferating MCs. Since granuloma formation and sclerosis are frequently seen around tissue MC accumulations in systemic mastocytosis—not only in the skin but also in the bone marrow, spleen and liver — it is assumed that MC products, probably heparin, are responsible for the connective-tissue proliferation. [It must be kept in mind, however, that the stimulation of connective-tissue proliferation by heparin has not yet been proved by convincing animal experiments (*H.S.*).]

AGENTS INFLUENCING THE MASTOCYTOSES OF MAN

In this section, we shall deal conjointly with the literature on agents having a beneficial or detrimental effect upon mastocytoses, since knowledge of both types is necessary for the proper treatment of the disease and the understanding of its pathogenesis.

There is no doubt that in many cases systemic treatment with *ACTH or glucocorticoids* results in temporary remissions of urticaria pigmentosa, but the results are inconstant. On the other hand, mastocytosis predisposes to the development of peptic ulcers (presumably owing to increased histamine production) and an increase in the blood level of glucocorticoids may enhance this process. Topical glucocorticoid treatment of the skin lesions does not have such an effect, but it is rarely beneficial.

Among the many *drugs* that have been tried, few have given encouraging results. Patients with mastocytosis are notoriously intolerant of *salicylates* and *codeine* which tend to precipitate attacks. The best therapeutic results have been obtained so far with various *antihistaminics and antiserotonins,* particularly cyproheptadine which at least temporarily combat the pruritus and urtication in most cases. Favorable results have occasionally also been achieved with *histamine liberators,* which discharge the MCs (e.g., toluidine blue, polymyxin, 48/80). Topical treatment of the lesions with *hyaluronidase* induced no obvious change. The *heparin* tolerance is not consistently altered although it might be expected that the proliferating MCs produce an excessive amount of this compound. Nevertheless, in the hemorrhagic type of urticaria pigmentosa, treatment with the heparin antagonist protamine sulfate would appear to be indicated.

X-ray treatment can cause significant remissions and should be attempted, especially in the intractable systemic forms.

Immune bodies do not appear to play a role in urticaria pigmentosa. Passive transfer of the disease with the serum of affected patients yielded negative results. Earlier reports, according to which vaccination aggravates the disease, could not be confirmed; hence, there is no reason to consider vaccination contraindicated in children with mastocytosis.

Atmospheric variations and *exposure to heat or cold* often precipitate attacks.

Pregnancy does not appear to change the course of the disease which, as previously stated, may appear at any *age* although it is much more common in infants and children than in adults, and may be present at birth.

Genetic predisposition plays an important role in mastocytosis. Many familial cases have been reported and the disease tends to develop simultaneously in siblings, especially in twins.

The fact that topical *trauma* (rubbing, scratching) can cause urtication, pruritus, and even systemic manifestations (flush, eosinophilia) hardly requires special mention: it represents one of the most characteristic diagnostic signs. It is noteworthy, however, that almost any kind of systemic *stress,* especially emotional excitement and alcoholic beverages, may bring on a flush-syndrome attack.

Excision of solitary lesions may result in a permanent remission of the mastocytosis syndrome.

There are many reports of mastocytosis in combination with *other diseases* such as syphilis, gonorrhea, polycythemia vera, or Cushing's syndrome, but we have no convincing proof of a causal relationship.

ACTH and corticoids

Grupper & de Brux D14,290/52: Cortisone did not prove useful in the treatment of urticaria pigmentosa.

Robbins D26,739/54: In an infant with a bullous urticaria pigmentosa, ACTH treatment was successful.

Urbach et al. D39,652/54: Desoxycorticosterone treatment resulted in a considerable improvement in a patient with urticaria pigmentosa. At the same time, the initially high blood heparin level decreased.

Szymanski & Becker D39,633/56: Neo-Cortef ointment is allegedly beneficial in the treatment of urticaria pigmentosa.

Barker D33,656/57: A case of urticaria pigmentosa in a 58-year-old man with decalcification of the bones and a blood calcium of 16.5 mg per cent which responded well to Meticorten.

Efrati et al. D25,560/57: In a case of MC-leukemia, treatment with antiphlogistic corticoids depressed the blood MC values but the general condition of the patient was not much influenced.

Bloom et al. D27,896/58: Topical treatment with cortisone did not significantly improve the skin lesions of urticaria pigmentosa although it did induce some local MC destruction.

Davis et al. D39,697/58: Treatment with ACTH and glucocorticoids had only a limited effect in a patient with urticaria pigmentosa.

Friedman et al. D26,445/58: Cortisone treatment may be dangerous in mastocytosis because it may accentuate the already existing tendency of peptic ulcer formation.

Brinkmann D33,665/59: In a case of mastocytosis with greatly increased urinary histamine excretion, triamcinolone treatment produced no noteworthy remission.

Stutzman et al. C95,789/60: In a case of systemic MC disease, cortisol and prednisone produced no clinical improvement, although heparinemia developed, suggesting MC disintegration.

Braunsteiner G10,415/64: Although cortisone may give temporary relief in patients with mastocytosis, its systemic use is contraindicated because of the danger of peptic-ulcer formation for which these patients are predisposed.

Other hormones

Grupper & de Brux D14,290/52: Thyroid extract and adrenaline do not influence the course of urticaria pigmentosa.

Drugs

Salicylic acid derivatives

Hamrin D39,668/57: A woman with urticaria pigmentosa was severely hypersensitive to acetylsalicylic acid.

Brogren et al. C69,050/59: "One patient showed severe intolerance to acetylsalicylic acid and developed shock, erythema, gastric hypersecretion and increased histaminuria after a small test dose."

Sutter et al. D63,193/62: Acetylsalicylic acid produces generalized flushing in patients with urticaria pigmentosa.

Rabinovich & Ley D66,453/63: Aspirin-precipitated attacks in a woman with urticaria pigmentosa.

Antihistaminics, antiserotonins

Warin D30,600/50: Several antihistaminics and antiserotonins exert beneficial effects in urticaria pigmentosa, although their action is only suppressive and not curative.

Drennan & Beare D92,234/51: Antihistaminics (e.g., Anthisan) failed to control the urticarial manifestations in urticaria pigmentosa.

Grupper & de Brux D14,290/52: Antihistaminics given systemically or topically failed to affect the lesions of urticaria pigmentosa.

Davis et al. D39,697/58: Treatment with the antihistaminic chlorpheniramine had only a limited effect in a patient with urticaria pigmentosa.

Brinkmann D33,665/59: In a case of mastocytosis, with intense histaminuria, treatment with antihistaminics produced no noteworthy remission.

Grupper D33,727/61: Considerable improvement is obtained in patients with urticaria pigmentosa by the antihistaminic and antiserotonin agent, cyproheptadine.

Asboe-Hansen E99,822/62: A case of bullous diffuse nonpigmented cutaneous mastocytosis in a one-year-old girl led to the urinary excretion of considerable amounts of nonsulfated mucopolysaccharide of the hyaluronic-acid type. The patient was successfully treated with cyproheptadine.

Remy D32,662/62: There is no causal or even highly effective symptomatic treatment for mastocytosis. Antihistaminics may relieve the itching and urtication but their value is limited. The skin should be protected against scratching, temperature variations, and other local irritating stimuli.

Degos D58,430/63: Cyproheptadine exerts a beneficial though transitory effect upon pruritus, urtication, and the flushes of urticaria pigmentosa.

Histamine-liberators

Drennan & Beare D92,234/51: Toluidine blue i.v. failed to control the urticarial manifestations in urticaria pigmentosa.

Lorincz E56,912/52: Pruritus and dermographism diminished in urticaria pigmentosa under the influence of toluidine-blue treatment.

Bluefarb & Salk D39,514/54: Toluidine-blue treatment of mastocytosis yielded disappointing results.

Asboe-Hansen D26,742/60: In a patient with urticaria pigmentosa and generalized mastocytosis, the histamine liberator substance, polymyxin B, brought about a partial or complete degranulation of mast cells, a subsidence of the skin urtication, a decrease in liver size and of ascites, and a considerable increase in the count of basophil blood leukocytes. This rise may be explained by leukocytic phagocytosis of mast-cell, granule material.

Sutter et al. D63,193/62: Polymyxin produces generalized flushing in patients with urticaria pigmentosa.

Orfanos & Stüttgen D32,154/62: Excellent description and illustration of electron-microscopic changes induced by 48/80 in the MCs of a patient with mastocytosis. (*Fig. 6, p. 62.*)

Orfanos & Stüttgen E37,429/63: Topical treatment with 48/80 causes first granule formation in immature human cutaneous mastocytoma cells but this is followed by degranulation. It is considered that 48/80 acts primarily on granule formation and that the liberation of the granules is secondary as judged by electron-microscopic studies.

Hyaluronidase

Degos et al. D31,651/52: Following injection of hyaluronidase into the skin lesions of urticaria pigmentosa, no obvious change was noted.

Cordero G1,709/54: Neither testicular nor bacterial hyaluronidase caused depolymerization of the mucopolysaccharides in the MCs of a human mastocytoma.

Heparin, antiheparins

Grüneberg et al. D39,626/55: The heparin tolerance was not altered in a case of urticaria pigmentosa.

Gulden & Niebauer D31,594/56: Intracutaneous injection of heparin induces a local hypersensitivity reaction in urticaria pigmentosa. Glucosaminehydrochloride (possibly a heparin precursor) is even more effective in this respect. Protamine sulfate, a heparin antagonist, causes bleaching of the urticaria pigmentosa areas if directly injected into them.

Bădănoiu et al. G18,749/61–62: In urticaria pigmentosa, injection of heparin into the skin causes storage of granules by macrophages owing to their "heparinopektic" property.

Braunsteiner G10,415/64: In hemorrhagic forms of mastocytosis, protamine-sulfate treatment may be indicated in view of the probable pathogenic role of heparin.

Codeine

Sutter et al. D63,193/62: Codeine produces generalized flushing in patients with urticaria pigmentosa.

Rabinovich & Ley D66,453/63: Codeine precipitated attacks in a woman with urticaria pigmentosa.

Novocain

Grupper & de Brux D14,290/52: Infiltration of cutaneous urticaria pigmentosa lesions with novocain prevents the urtication normally induced by rubbing the skin.

Other drugs

Demis & Zimmer D58,631/63; *Braunsteiner* G10,415/64: *α-Methyldopa,* an antidecarboxylase, does not diminish histaminuria in mastocytosis patients and has no therapeutic value. [This is understandable since α-methyldopa does not interfere with the decarboxylation of histidine (and, hence, the formation of histamine) in mastocytoma tissue (*H.S.*).]

Stutzman et al. C95,789/60: In a case of systemic MC disease, *carcinolytics* such as nitrogen mustard, induced temporary improvements without histaminemia, histaminuria, or increased excretion of 5-HT metabolites.

Ionizing rays

Jacob E37,998/07: A case of urticaria pigmentosa successfully treated by x-rays.

Jeanselme & Touraine E21,110/19: A case of urticaria pigmentosa with hypertrophy of the liver and splenomegaly which showed considerable improvement following x-irradiation.

Degos D58,430/63: X-ray treatment can cause significant remissions in patients with systemic mastocytosis.

Immune bodies

Melczer D39,674/54: Passive transfer experiments yielded no evidence in favor of the allergic theory of urticaria pigmentosa.

Degos & Touraine D26,820/60: Earlier reports, according to which vaccination may elicit urticaria pigmentosa or at least aggravate the cause of the disease, could not be confirmed. Hence, there is no reason to consider vaccination contra-indicated in patients with mastocytosis.

Temperature, climate

Bory D39,624/27: By freezing individual cutaneous lesions in urticaria pigmentosa, these can be caused to disappear, but if many of them are treated at the same time, a general "nitritoid crisis" with collapse may occur.

Pratt D39,672/45: 20-year-old woman with urticaria pigmentosa in whom the skin lesions become itchy, red and elevated upon exposure to cold.

Becker D39,619/54: Atmospheric variations may elicit attacks in mastocytosis.

Berlin D30,375/55: Changes in the weather and temperature variations tend to aggravate urticaria pigmentosa.

Herzberg D39,565/59: In cases of urticaria pigmentosa, a hot bath may lead to loss of consciousness and shock-like conditions, presumably as a consequence of histamine liberation.

Remy D32,662/62: Atmospheric variations, such as an influx of polar air, may bring about an attack in urticaria pigmentosa.

Pregnancy

Rollier D33,730/60: In a woman with diffuse cutaneous mastocytosis, pregnancy did not change the course of the disease

Age

Swoboda D31,857/05: Urticaria pigmentosa in a newborn baby.

Fabry E38,151/12: Congenital urticaria pigmentosa in a boy.

Riehl D72,670/13: Urticaria pigmentosa and syphilis in a newborn infant.

Pernet D71,209/16; E38,153/16: In a male child, urticaria pigmentosa was evident at birth. The condition is considered to be congenital in this case.

Thibierge & Boutelier E38,016/20: Urticaria pigmentosa in a seven-month-old girl.

Finnerud E35,353/23: An extensive review of the literature on urticaria pigmentosa shows that the disease may appear immediately after birth or late in life.

Pautrier D39,734/39: A case of urticaria pigmentosa which started at the age of 40 and exhibited an angiomatous aspect.

Degos & Bellone D39,745/47: Six cases of urticaria pigmentosa which first appeared at ages varying between 20 and 52 years.

Blechmann et al. D39,794/48: Urticaria pigmentosa in a newborn infant.

Dugois D39,741/48: Development of urticaria pigmentosa in a 36-year-old woman. Although the clinical course is typical, histologically no MCs could be demonstrated in the lesions.

Krementchousky D39,737/48; *Michel* D39,736/48; *Tzanck & Civatte* D39,732/49; *Pellerat & Jeantet* D39,731/49; *Prosser-Thomas & Rook* D39,749/50; *Bondet & Bourgeois* D39,718/50: Cases of urticaria pigmentosa appearing in adults.

Chatard & Cau D26,811/59: A case of urticaria pigmentosa with generalized vasomotor disturbances in a six-month-old infant.

Walker C91,546/60: Widespread urticaria pigmentosa with episodes of flushing, which appeared almost immediately after birth in a baby.

Fernex D39,200/62: Urticaria pigmentosa is not uncommon in adults.

Ehmann D39,810/62: Congenital MC-reticulosis, with cutaneous urticaria pigmentosa, enlargement of the liver, spleen and lymph nodes as well as thrombocytopenia.

Demis E24,240/63: The age distribution of mastocytosis in two large groups of patients has been summarized as follows:

	286 Cases, 1925		*140 Cases, 1961*	
Age	Number	%	Number	%
0–5	192	67	65	46
5–20	43	15	13	9
20–50	46	16	35	25
50+	5	2	27	20

Genetics

Touraine D39,735/48: Urticaria pigmentosa in three members of the same family, with a review of similar familial cases.

Leitão & Trincão D39,615/52: A case of urticaria pigmentosa in a newborn baby whose brother showed identical lesions. Several additional cases among brothers are quoted from the literature.

Melczer D39,674/54: On the basis of a literature review, urticaria pigmentosa is considered to be a genetically transmitted systemic disease.

Burks & Chernosky D39,622/57: Nodular urticaria pigmentosa of the vulva in siblings.

Frain-Bell D39,663/58: Urticaria pigmentosa in identical 5-month-old twin girls.

Jacobs D39,638/58: Solitary lesions of urticaria pigmentosa in a mother and her daughter.

Kibel & Kingsley D65,189/63: A case of mastocytosis in an African Negro.

Caplan D55,590/63: An instance of urticaria pigmentosa in mother and daughter.

Gross & Hashimoto D18,541/64: Urticaria pigmentosa in four individuals of two families (mother and daughter, and father and daughter). The hereditary pattern seems to be that of an incompletely penetrant autosomal dominance.

Trauma

Jadassohn D33,673/33: Two otherwise equal cutaneous effluorescences in a patient with urticaria pigmentosa were examined histologically; one was not irritated, the other irritated mechanically by rubbing and scratching. Only in the latter was there a pronounced increase in tissue eosinophils.

Wöringer & Bendoraitis D39,733/49: Urticaria pigmentosa in which the skin lesions are readily provoked by mechanical irritation.

Braun-Falco & Jung D39,567/61: Following rubbing of the skin, signs of increased heparin, histamine and 5–HT production are obtained in a case of cutaneous mastocytosis.

Bădănoiu et al. G18,749/61–62: In patients with urticaria pigmentosa, topical trauma causes release of the MC-granules.

Stress

Marten D39,706/57: In a child with urticaria pigmentosa, every emotional excitement elicited a flush syndrome. "A visit to the barber always brings on one of these attacks."

Davis et al. D39,697/58: Every kind of stress situation, as well as alcoholic beverages and strongly spiced foods, tend to bring on flush-syndrome attacks in patients with urticaria pigmentosa.

Excision of lesions

Ende & Cherniss D39,554/58: Splenic mastocytosis is characterized by hypersplenism, episodic flushing, hemorrhagic tendency, vomiting and an enlarged spleen which is heavily infiltrated with MCs. In one such case, splenectomy brought about a permanent remission.

Bloom et al. D27,896/58: Acute spontaneous histamine shocks developed in an infant with urticaria pigmentosa. These disappeared after removal of two big mastocytoma-like formations.

Diseases

[Cf. also MAST-CELL CHANGES IN VARIOUS DISEASES (*p.* 281), other than mastocytosis.]

Spillmann & Weille D39,654/37: Bullous urticaria pigmentosa in a child with hereditary *syphilis.* Attention is called to the fact that this combination is not uncommon.

Cordonnier D61,079/46: Following severe cranial trauma, urticaria pigmentosa and *Cushing's syndrome* developed conjointly.

Ellis D27,355/49: A woman with *gonococcic* cervicitis delivered a baby with congenital urticaria pigmentosa. Innumerable MCs were found in the infant in many portions of the body, particularly in the vicinity of many chronic infections. "These facts may be related and it can be postulated that this infant's congenital lesions might be the result of a localized demand for heparin due to the adjacent cervicitis."

Duperrat & Grupper D39,544/51; *Grupper & de Brux* D14,290/52: The mothers of newborn babies with urticaria pigmentosa frequently exhibit gonococcal cervicitis.

Grupper D31,576/54: Urticaria pigmentosa has repeatedly been observed in the newborn infants of mothers with gonococcal cervicitis.

Degos D27,649/55: Urticaria pigmentosa in the lactating infant has repeatedly been noted in mothers who suffered from gonococcal uterine cervicitis during pregnancy. It is emphasized that various infections and intoxications of the mother may play a role in the development of mastocytosis in their newborn infants.

Bowdler & Tullett D39,625/60: Urticaria pigmentosa and *polycythaemia vera* occurred simultaneously in a patient. "The possibility is considered that the occurrence of the two conditions in one patient may be due to a stimulus or related stimuli of the kind postulated for the myeloproliferative disorders, acting both on the tissue mast cells and on the bone-marrow simultaneously."

Brink & Marshall D70,852/63: A case of urticaria pigmentosa combined with polycythemia rubra vera, portal hypertension, and portal venous thrombosis. The combination of mastocytosis with increased myelopoiesis is thought to add weight to the unitary theory of diseases of the reticuloendothelial and hemopoietic system.

Weidman & Franks E22,563/63: A case of urticaria pigmentosa combined with *Hodgkin's disease.* The association may have been coincidental.

MASTOCYTOMAS IN ANIMALS

In animals, typical urticaria pigmentosa does not occur as a spontaneous disease nor has it ever been reproduced experimentally. However, mastocytomas, often described as "mast-cell sarcomas," do develop with comparative frequency especially in old *dogs.* Boxer dogs appear to be particularly predisposed but there is no striking sex difference in the incidence of these tumors. Canine mastocytomas tend to become invasive and metastasizing; they have often been successfully transplanted.

Several breeds of *mice* develop transplantable and often metastasizing mastocytomas, some of which contain enormous amounts of heparin, histamine, and 5–HT.

The mastocytoma tissue of the dog and mouse can be cultured in vitro and lends itself well for electron microscopy as well as for studies on the biochemistry of MC-tissue.

Mastocytomas have also been reported in the *cat, cattle, horse,* and *ferret.*

Review: *Schauer* E4,510/64

Dog

Murray D31,527/08: Description of a "mast-cell sarcoma" in the hind leg of a dog.

Chambers B21,637/31: Among 16 malignant tumors in dogs, 3 proved to be MC-sarcomas.

Bloom D10,421/42: The term "mastocytoma" is proposed for a hitherto undescribed primary subepithelial neoplasm, occurring spontaneously in dogs.

Mulligan D39,723/48: Detailed description of MC-sarcomas in the dog.

Hauser D10,422/48: MC-tumors of the dog often contain (in addition to MCs) numerous eosinophils and small hemorrhagic foci.

Rubarth D50,784/49: Brief description of mastocytomas in dogs.

Nielsen D31,566/52: In the dog, mastocytomas are usually poorly demarcated skin tumors occurring primarily in the thighs and the external genitalia.

MacDougall D29,156/54: Three specimens of dog mastocytoma tissue grew well in tissue culture.

Baglioni C16,539/54: Discussion.

Bloom et al. D26,753/55: First electron-microscopic study of canine mastocytoma cells.

Stünzi C14,513/55: A review of the literature and canine mastocytomas.

Brodey C32,742/56: Mastocytoma of the scrotum in a ten-year-old Boston terrier which also had a seminoma and a Sertoli cell tumor.

Larsson E81,440/56: Canine mastocytomas avidly take up radiosulfur as shown by autoradiography

Köhler C21,325/56: Twenty-six cases of mastocytomas in dogs at various points of the skin surface.

Bloom et al. C12,081/56: Extensive electron-microscopic studies on mastocytomas of dogs succeeded in clearly identifying cytoplasmic protrusions at the periphery of the cells (which often contain vacuoles), granules, mitochrondria, a Golgi apparatus, the nucleus, and the nuclear membrane. The mitochondria are quite distinct from the secretion granules and no transformation of the former into the latter has been seen.

Larsson D10,423/56: In a series of 266 cutaneous tumors of dogs, 35 instances of mastocytoma were noted. The sex distribution was equal but predominance among boxer dogs was conspicuous.

Larsson D50,351/57: Discussion.

Larsson E88,145/57: Mastocytomas are particularly common in old boxer dogs. The incidence is approximately equal in both sexes.

Weiss G17,190/57: A case of "aleukemic mast-cell leukosis" in a 5-year-old boxer dog. In addition to cutaneous mastocytomas and MC infiltrations in the liver, spleen, and lymph nodes, there was leukocytosis, but the basophil count in the blood was not increased. "Aleukemic mast-cell leukosis" is considered to be the systemic counterpart of the localized cutaneous mastocytoma.

Bloom et al. D39,809/58: Among 27,278 licensed dogs in Stockholm, "sixty cases of mastocytoma were found and, of these, forty-nine were in boxers. Sex distribution proved equal. The mean age for boxers with mastocytoma is 6.62 $\pm$ 0.40 years."

Nielsen & Cole D67,466/58: "In the pathological collection studied, mastocytomas comprised 20 per cent of the cutaneous neoplasms of dogs. This tumor rarely occurs in other species. The mastocytomas invaded locally, metastasized, recurred following surgical excision, and were, therefore, classified as true neoplasms. They had a tendency to erosion, grew without demarcation, and had a site preference for the external genitalia (15 per cent) and hindquarters. The Boston Terrier exhibited a marked predisposition, and the Boxer a lesser

breed predisposition for this tumor. Males and females were affected with equal frequency. Most mastocytomas occurred after the age of 6 years. 28% were malignant, 17% recurred between two weeks and one year, and 16% metastasized to inguinal nodes, spleen, liver, and sublumbar nodes. Multiple occurrence was present in 21%. In no instance did internal mastocytomas occur in the absence of cutaneous tumors. Microscopically, the mastocytoma was characterized by a diffuse proliferation of freely situated round cells of uniform size and shape." The report is based on the observation of one hundred canine mastocytomas.

West C64,139/58; *Head* D27,975/58: Discussion.

Williams et al. D26,619/59: A dog "mast-cell sarcoma," has been grown in tissue culture for 50 passages over a period of two years. The cells grew in a fibroblastic pattern but contained mitochondria, metachromatic MC-granules, and lipid droplets. The number of metachromatic granules increases when heparin is added to the medium while sudanophilic granules become more numerous in media containing stearic acid. Even the original tumor contained but little histamine, presumably owing to dedifferentiation.

Orkin & Schwartzman D67,468/59: General review of canine mastocytomas.

Orkin & Schwartzman C70,193/59: Rarefaction of bones may occur in connection with mastocytomas in the dog.

Lombard & Moloney D63,184/59: A spontaneous MC-sarcoma of the dog has been transferred by s.c. injection of ultrafiltrates. Heterotransplants in rats, mice, guinea-pigs, hamsters, and cats were unsuccessful.

Bloom E22,677/60: In mastocytomas of the dog and mouse crystalloid, inclusion bodies were found which may be related to virus or be products of virus activity.

Epstein & Martin E75,754/63: Description of two cutaneous mastocytomas in mongrel dogs, aged 5 and 7 years respectively.

Ende & Auditore F5,869/64; F6,349/64: In a dog having an MC-sarcoma with multiple metastases, minute doses (35 μg/kg) of 48/80 produced a lowering of the prothrombin consumption and a prolonged increase in blood-coagulation time with intense fibrinolytic activity.

Crespi & Celestino E38,732/64: Description of a canine mastocytoma in which two types of MCs can be distinguished: (1) small cells giving a positive Adams' paradimethylaminobenzoaldehyde (DMAB) reaction, and (2) large alcian-blue positive cells. The small DMAB-positive elements are alcian-blue negative. DMAB-positivity presumably indicates the presence of the 5–HT precursor tryptophan or possibly neuraminic acid both of which react positively with DMAB.

Mouse

Deringer D10,425/47: "Gross and microscopic observations of five cases of mast-cell neoplasia occurring in reciprocal F_1 hybrid mice of strains A and L are reported." The MC-proliferations were particularly conspicuous in the spleen and various portions of the gastro-intestinal tract.

Bali & Furth D10,424/49: In the Ak-strain of mice, there occurs a transplantable splenic tumor with neoplastic cells resembling epithelium and presumed to be derivatives of reticulum cells. These tumors, both spontaneous and transplanted, are very rich in MCs although the MCs are not related to the neoplastic cells. Among other forms of tumors in mice, luteomas contain MCs, while granulosa-cell tumors, pulmonary adenomas, breast cancers and malignant lymphomas, do not contain them.

Dunn D27,626/54: Brief review on mouse mastocytomas.

Baglioni C16,539/54: Discussion.

Dunn & Potter D27,625/57: A mastocytoma was found in a male mouse of the DBAf/2 strain which was repeatedly painted with methylcholanthrene at various sites. The tumor apparently arose from two subcutaneous points and proved to be transplantable in the same strain both in solid and in ascites forms. There were "hematoidin crystals and unusual birefringent yellow globules in necrotic areas of the tumor. This may indicate that the mast cell has a function related to the formation of bile pigments from hemoglobin."

Furth et al. C40,976/57: A subcutaneous mastocytoma was found in a 500-day-old mouse of the LAF_1 strain which contained enormous amounts of histamine, heparin and 5–HT. Its cells are typical metachromatic MCs and the tumor can be transplanted.

Ono et al. D27,408/59: Two transplantable strains of mastocytomas are known, both of which originated in mice as solid tumors and are transplantable in the strain of origin. One of these is invasive and grows rapidly (*Dunn & Potter* D27,625/57), the other grows

slowly, does not metastasize readily and produces as much or more heparin, histamine and 5–HT as any known mammalian tissue.

Green & Day D26,854/60: "During culture in vitro of an ascitic mast-cell tumor of the mouse, P–815, three strains have been developed, two of which were obtained by a cloning-technique. One of these pure strains is near diploid, the other tetraploid. All strains maintain their intracellular levels of heparin, histamine, and 5-hydroxytryptamine in culture." Strains vary in their capacity to incorporate S^{35}-sulfate and glucosamine-1-C^{14}, into heparin, but in all cases, the amounts of heparin, 5–HT and histamine are higher in culture than when the same strain of cells is grown in the mouse. The half-life of heparin in MCs is about one and one-half days.

Gottlieb et al. D26,743/61: The granules of the transplantable mastocytomas of mice do not stain readily with the usual methods, but they can be demonstrated with the Bismarck-brown technique.

Day & Green D39,523/62: An MC-tumor of the mouse has been grown and maintained in tissue culture for nearly four years during which time its cells have continued to synthesize histamine, 5–HT, and heparin.

Mengel D58,283/63: The various sublines of mouse mastocytoma P–815 vary considerably as regards metachromasia and other morphologic characteristics with repeated transfers.

Bloom D58,274/63: Detailed description of electron microscopy of Furth mastocytomas.

Dunn & Andervont E29,999/63: Description of spontaneous mastocytomas in the wild mouse.

Rask-Nielsen & Christensen D64,074/63; *Christensen et al.* D64,073/63: "The origin and general morphology of a transplantable murine mast cell neoplasm are described. The primary tumor arose in a 26-month-old female (CBA X DBA/2)F_1 mouse that at the age of 4 months had been inoculated subcutaneously with leukemic tissue from a transplantable plasma-cell leukemia." Electron-microscopic studies on this MC-tumor revealed "a well-developed Golgi region; numerous ribosomes, free or attached to membranes; a highly organized endoplasmic reticulum; a smooth membrane-like inner surface in the lacunae, which lodged the mast cell granules; mast cell granules located in the outer zone of the cytoplasm in most cells, but occasionally occupying the entire cell body and appearing as loose curls with all transitional stages to condensed, homogeneous material; long, slender protrusions projecting from the cell surface. From previous and present investigations, it is suggested that there may be a direct connection from the interior of the mast cell through the channels of the endoplasmic reticulum to the lacunae, and from the lacunae during the release of the mast cell granules to the extracellular space. This system may reflect the synthesis of the tumor mast cell granules."

Karzel G9,337/64: In mice inoculated with P–815 mastocytoma tissue, various organs exhibit a greatly increased 5–HT content.

Other animals

Sabrazès & Lafon D27,301/08: Description of a tumor, which formed as a result of a traumatic injury in the upper lip of a *horse*. The neoplasm consists almost exclusively of MCs and eosinophils and contains a yellow pigment, which gives a mild Prussian-blue reaction.

Symmers & Thomson D66,474/53: Description of a *ferret* with multiple spontaneous basi-squamo-sebaceous tumors of the skin and tumor-like cutaneous MC-accumulations.

Baglioni C16,539/54, *p. 195 ff.*: Review of MC-tumors *in various species.*

Head D27,975/58; *West* C64,139/58: Description of spontaneous cutaneous mastocytomas in *cattle.*

Dodd D19,424/64: Description of a mastocytoma which developed in the tongue of a *calf.*

Seawright & Grono G2,729/64: "A case of malignant mast cell tumor in a 9-year-old male *cat* is described. Skin, spleen and liver were especially affected. Death resulted from a perforating duodenal ulcer."

Trautwein & Stöber D97,999/in press: Mastocytosis (MC-reticulosis) can occur in *cattle* as a spontaneous disease. It is characterized by infiltration with MCs and reticular fibers in the skin, lungs, skeletal musculature, and by basophilic leukemia. The infiltrates exhibit a yellowish-green color and, in addition to MCs, contain many eosinophils.

AGENTS INFLUENCING THE MASTOCYTOMAS OF ANIMALS

Glucocorticoids tend to inhibit the growth of canine and murine mastocytomas. *Histamine liberators* yielded somewhat conflicting results but, according to several investigators, they discharge the granules and histamine (probably also 5–HT and heparin) from murine mastocytomas.

Reserpine releases 5–HT from murine mastocytoma tissue, but its effect has not yet been extensively investigated.

Murine mastocytomas undergo involution under the influence of the carcinolytic substance, *cyclophosphamide* and the glutamine antagonist *DON*. *Myleran,* an alkylating agent, causes chromosomal anomalies in murine mastocytoma cells, while *protamine* allegedly induces vesicular transformation of the granules and *phospholipase A* produces degranulation. However, some of these findings have not yet been confirmed and little attention has been given to the effect of other agents upon animal mastocytomas.

Corticoids

Bloom B69,764/52: Cortisone caused rapid regression of a malignant mastocytoma in a dog. Microscopically, the MCs developed cytoplasmic vacuolization, conglomeration, and altered staining reaction of the metachromatic granules, disappearance of many fine granules, disruption of the cell membrane, and cellular destruction. The therapeutic effect was long lasting, but eventually a small nodule reappeared.

Brodey et al. B95,502/53: Following cortisone treatment, marked tumor involution was noted in three cases of canine MC-sarcoma. However, in each instance, cessation of therapy was followed by marked increase in tumor size.

Larsson E88,145/57: Cortisone has little effect upon the development of canine mastocytomas.

Sjoerdsma et al. C48,610/58: Cortisone decreases the histamine- and 5-HT-content of mouse mastocytoma tissue.

Bloom E22,677/60: The growth of mouse mastocytomas is inhibited by cortisone treatment.

Green & Day D58,290/63: "Cortisone inhibited the growth of these (murine mastocytoma) cells without influencing the synthesis of heparin, histamine, or 5-hydroxytryptamine."

Folliculoids

Iversen et al. G10,503/64: Treatment with an estrogen (Diprovex Leo, chemical name not given) causes light and electron-microscopic changes in a transplantable mouse mastocytoma in vivo.

Histamine liberators

Sjoerdsma et al. C48,610/58: 48/80 has no effect upon the 5–HT content of mouse mastocytoma tissue.

Day & Green D41,586/62: 48/80 releases both 5–HT and histamine from murine neoplastic MCs in vitro.

Fredholm E32,253/63: 48/80 as well as phospholipase-A cause MC-degranulation and decreased oxygen consumption in the P–815 mouse mastocytoma.

Green & Day D58,290/63: Polymyxin B releases histamine, and 48/80 releases both histamine and 5–HT from murine mastocytomas.

Ende & Auditore F5,869/64; F6,349/64: In a dog having an MC-sarcoma with multiple metastases, minute doses (35 μg/kg) of 48/80 produced a lowering of the prothrombin consumption and a prolonged increase in blood-coagulation time with intense fibrinolytic activity.

Reserpine

Sjoerdsma et al. C48,610/58: Reserpine markedly decreases the 5–HT content of mouse mastocytoma tissue.

Green & Day D58,290/63; *Day & Green* D41,586/62: Reserpine releases 5–HT from murine mastocytoma cells.

Carcinolytic agents

Mengel & Kelly D26,448/61; D2,746/61: In mice bearing P–815 ascites MC-neoplasms, the carcinolytic substance, cyclophosphamide, causes involution of the tumors and simultaneously an increase in the otherwise low percentage of cells that contain metachromatic granules. The metachromasia of the MCs increased concomitantly with a rise in 5–HT content, while the histamine content of the cells remained unchanged. The urinary excretion of 5-hydroxy-indoleacetic acid and 5–HT was enhanced. The induction of a dissociation in the 5–HT and histamine content of the tumor indicates that all the 5–HT cannot be present as a heparinate in these MC-tumors. Another possibility is that the tumor contains several cell populations in terms of 5–HT and histamine storage and that cyclophosphamide may have damaged predominantly one cell type.

DON

Potter E90,592/59: P–815 mastocytomas of the mouse show growth inhibition upon treatment with the glutamine antagonist, DON (6-diazo-5-oxo-L-norleucine). However, in the course of treatment, resistance of the tumor cells to DON may develop.

Myleran

Biesele E25,803/63: Treatment with alkylating agents such as Myleran, causes chromosomal anomalies in the cells of murine mastocytomas in vitro.

Podophyllum

Batz et al. D18,542/64: "Two podophyllum preparations with spindle poison activity, were tested for their effect on ^{3}H thymidine incorporation into P–815 mastocytoma cells in vitro. Concentrations which inhibited cell multiplication completely did not affect DNA-synthesis as measured by thymidine incorporation."

Protamine sulfate

Sellyei & David E30,333/63: Electron-microscopic studies on Furth's mastocytoma revealed that the specific granules arise from the ground substance and the canaliculi of the endoplasmatic reticulum. The shrinking of the granules and their vesicular transformation were interpreted as secretory phenomenon. These changes were further enhanced by treatment with protamine sulfate.

Phospholipase A

Fredholm E32,253/63: Phospholipase A produces MC-degranulation and decreased oxygen consumption in the P–815 mouse mastocytoma.

Iproniazid

Sjoerdsma et al. C48,610/58: Iproniazid has no effect upon the 5–HT content of mouse mastocytoma tissue.

Thymectomy

McEntegart et al. E27,610/63: "C3H mice thymectomised within 24 hours of birth became susceptible to the P–815 mast-cell tumor which will normally grow only in DBA/2 mice and a few F 1 hybrids of DBA/2. The tumor in the thymectomised C3H animals showed more necrosis than in the normal DBA/2 host."

Auxin

Karzel F15,956/64: The 5–HT content of murine mastocytoma cells can be diminished in vitro by the addition of auxin to the culture medium.

THE MAST CELLS IN VARIOUS DISEASES

Local increases in MC density have been found in a great variety of *dermatoses,* especially those associated with inflammation, edema, itching, or eosinophilic infiltration. In general, the MC count runs parallel with the histamine content of the affected regions. In *alopecia areata*, the bald areas are particularly rich in MCs and upon intravenous infusion of 48/80 these regions urticate first. Furthermore, there is diffuse metachromasia of the dermis, both in the affected and in the nonaffected areas.

In *psoriasis* an increase in MC density, especially around the sebaceous glands, is especially prominent and is believed to play a pathogenic role.

The presence of numerous MCs in the cutaneous lesions of *xeroderma pigmentosum, pigmented scars, "melanoderma of vagabonds," and other pigmented dermatoses,* raises the possibility of some connection between pigment binding and MC activity. This view appears to receive further support from the observation of mastocytoses with hemosiderosis and melanosis in the surroundings of *varicose veins.* Mastopexis may play a role here. However, other forms of pigmentation (e.g., Addison's disease, hemochromatosis, racial pigmentation) are unaccompanied by an increase in cutaneous MC density.

In *keloids* there may be many or few MCs, presumably depending upon the stage in the development of the lesion and upon constitutional factors. Negroes, who are notoriously susceptible to keloid formation, are alleged to have a high cutaneous MC count.

The preferential arrangement of MCs around small blood vessels and their ability to produce heparin, has stimulated much research on the possible role of these cells in *cardiovascular disease,* particularly in relation to inflammation, sclerosis and blood clotting.

The presence of diffuse metachromasia in many *atheromatous lesions* raised the possibility that the local heparin concentration may be increased. Subsequent investigations suggested that the MC count in the myocardium of senile atherosclerotics is considerably below normal, implying that, here, a lack of heparin may be responsible for the frequency of coronary thrombosis. However, these findings have not been uniformly confirmed; indeed, some authors report an increased number of MCs around atheromatous coronary arteries. Hence, no definite statement can be made as yet concerning the possible participation of MCs in the genesis of atheromatosis.

In the *obliterative angiopathies* MC proliferation has been noted in the vessel walls but, since the number of MCs tends to increase in various forms of chronic inflammation, this response cannot be considered to be specific. As we shall see later, the MC count also increases in the walls of the rabbit ear-vein following the injection of thrombosing and sclerosing materials.

A local increase in MCs has also been found in *serous myocarditis* and *endomyocardial fibrosis,* especially in the type that is common in Africa. It was assumed that, here, the MCs render the cardiac connective tissue particularly subject to inflammation and sclerosis.

Often, though by no means always, there is MC proliferation in the connective tissue around inflammatory and neoplastic *diseases of the kidney and urinary passages.*

Considerable attention has been given to the MCs in *gastrointestinal disease.*

In the vicinity of gastric and duodenal ulcers, as well as in gastritis and ulcerative colitis, the number of MCs often increases, but here again, there are great individual variations.

Among the *diseases of the respiratory tract,* topical increases in MC density have been reported in nasal, laryngeal, and aural polyps, allergic rhinitis, habitual epistaxis, and mastoiditis. In asthmatic patients the number of peribronchial MCs is decreased and those present tend to discharge their granules.

Among the *ocular diseases* an increase in the local MC count has been observed especially in connection with various forms of inflammation and glaucoma.

Several *blood dyscrasias* (e.g., leukemia, agranulocytosis, panmyelopathy, pernicious and iron-deficiency anemia) are often associated with an increased bone-marrow MC count. Mastocytosis in the hemopoietic tissue tends to be especially pronounced in chronic anemias (hypo- or aplastic, more rarely pseudo-aplastic) and in agranulocytosis. This fact is noteworthy since these diseases, like mastocytomas, may lead to osteomyelosclerosis.

A variety of *infections* causes MC proliferation in the affected tissues, for example, in lymphadenitis, tonsillitis, gingivitis, cystitis, mastitis, as well as in the lesions of syphilis, tuberculosis, and leprosy. However, these changes are variable and presumably dependent upon the stage and severity of the disease. Interestingly, *parasitic infestations* conducive to eosinophilia tend to produce a particularly pronounced mastocytosis.

Endocrine diseases are rarely associated with any consistent changes in MC number or morphology, although an increase in the dermal MC population has been reported in myxedema. In Addison's disease — unlike in urticaria pigmentosa and some other forms of pigmentation — the skin is not particularly rich in MCs. In diabetic glomerulosclerosis, the hyaluronic acid of the dermal connective tissue allegedly may show a "monstrous increase" concurrently with MC degranulation. It was suggested that this may be the result of a deranged carbohydrate metabolism affecting polysaccharide production by MCs.

Ever since Ehrlich reported in 1879 that the stroma of human carcinomas is rich in MCs, considerable attention has been given to the possible role of these cells in *neoplasia.* Although there are many exceptions, it may be said that, in general, there tends to be an increase in the MC count of the connective tissue in and around various tumors, not only in man but also in animals. This is rarely the case within the tumor parenchyma. On the other hand, most of the spontaneous and transplanted animal tumors studied were associated with a decrease in the number and a degranulation of the MCs. In any event, the findings of different authors are so contradictory that no definite conclusion can be made concerning the behavior of MCs in neoplasia. It appears likely that the observed MC changes in the connective tissue in and around tumors are due to reactive inflammation and connective-tissue proliferation as such, and not to any specific effect of the neoplastic cells. On the other hand — as we have stated before (*p.* 147) — there can be little doubt that various carcinogens, applied to the skin of susceptible animals, can cause a local MC proliferation especially during the preneoplastic stage.

In view of the many similarities between the *carcinoid* syndrome and mastocytosis, it is noteworthy that metachromatic granules have been demonstrated in carcinoids of the human appendix. Furthermore, MCs are allegedly plentiful in the skin and the fibrotic endocardium of patients with a carcinoid syndrome.

Rheumatoid arthritis is not associated with any consistent change in the MCs, while in rheumatic fever the cardiac MC count may be doubled.

In *Waldenström's macroglobulinemia,* the bone-marrow and lymph-node MC count rises considerably in some patients but not in others.

Among the *nervous diseases,* MC proliferation is seen in the connective tissue of the peripheral nerves in chronic neuritis and in Recklinghausen's disease. In human brain tissue, MCs occur only under pathologic conditions around foci of sclerosis or inflammation.

Intense MC proliferations have been seen in *lymphedema.* Allegedly, here, MC products may participate in the causation of water accumulation, but it is equally possible that the edema furnishes a stimulus for MC proliferation.

Among the spontaneous *diseases of animals,* MC infiltrations have been noted in the muscular dystrophy of the mouse and hamster as well as in the obese-hyperglycemic mouse. In old arteriosclerotic rats the cardiac MCs allegedly undergo degeneration.

In *conclusion,* it may be said that the enormous amount of work designed to detect characteristic MC changes in diseases other than the mastocytoses and mastocytomas, revealed no consistent characteristic change. Considerable alterations (increases or decreases) in the MC density undoubtedly occur as a consequence of inflammation and sclerosis in the surroundings of diverse specific morbid processes and the direction of the change appears to depend mainly upon the intensity and chronicity of the lesions. Only in certain blood dyscrasias (anemias, leukemias) and in Waldenström's macroglobulinemia is there a fairly constant increase in bone-marrow and lymph-node MCs, but even in this respect there are many exceptions.

Reviews: *Audry* D27,714/1896; *Calleja* D39,609/1896; *Serrão* C8,615/53; *Asboe-Hansen* D27,999/54; *Baglioni* C16,539/54, *pp. 162, 181*; *Smith* D63,031/63

DERMATOSES

Audry D27,714/1896: Description of the MCs in various dermatoses.

Bäumer D27,593/1896: A local increase in MCs has been found in various skin diseases (e.g., milium with comedos, onychogryposis, Verruca mollis, and cutaneous carcinomas).

Bender E25,130/1900: The cutaneous MC population is frequently increased in patients with dermatitis exfoliativa.

Westberg C97,252/01: MC increase in the skin of a woman with scleroderma.

Heller D26,810/04: The cutaneous MC population is increased in a great variety of cutaneous diseases both in human and in animal pathology.

Rheindorf D33,731/05: MCs are common in nevi and freckles; here, certain cells contain both metachromatic and pigment granules.

Bohač D27,597/06: MCs are unusually numerous in the skin lesions of patients with urticaria pigmentosa and xeroderma pigmentosum. Allegedly, there are direct transitions between MCs and pigment cells in both these conditions, which explains the genesis of melanosis in these dermatoses.

Pültz D30,085/12: In the cutaneous vesicles produced in man by the local application of croton oil, as well as in cutaneous vesicles occurring in the course of various diseases, numerous MCs and eosinophils are simultaneously present. Some relation between eosinophils and MCs is, hence, suspected.

Klausner & Kreibich D27,434/13: Numerous MCs are found in a variety of vesicle-forming dermatoses, particularly in erythema exudativum due to miliaria crystallina, prurigo agria Hebrae, scabies, herpes zoster, and various types of hypersensitivity reactions, particularly hypersensitivity to tuberculin.

Sézary et al. D10,612/36: In a patient with symmetrical lipomatosis and dermographism but no urticaria pigmentosa, the cutaneous MC count was considerably increased, though not quite as much as in the lesions of urticaria pigmentosa.

Michels C72,066/38, *pp. 344–6*: Discussion.

Asboe-Hansen D26,785/50: An extensive study on a large number of dermatoses shows that in general, MCs are most plentiful in those lesions in which there is edema with accumulation of mucopolysaccharides, particularly hyaluronic acid, in the skin. These changes are most prominent in the itching dermatoses such as neurodermatitis circumscripta, urticaria pigmentosa, urticaria factitia, chronic urticaria, Besnier's prurigo, lichen planus, and contact dermatitis.

Moursund & Hirschmann G12,247/51: In a patient with telangiectasia macularis eruptiva, skin biopsies revealed the presence of numerous MCs, "which seemed to support the diagnosis of urticaria pigmentosa, or, as designated by Parkes Weber, 'telangiectasia macularis eruptiva perstans,' an adult type of urticari pigmentosa."

Prakken & Woerdeman D26,813/52: In the skin of patients suffering from a variety of dermatoses, eosinophilia was always connected with an increased number of MCs. However, cutaneous mastocytosis may occur without accompanying eosinophilia.

Hauser D26,883/53: There was an increased bone-marrow MC count in patients with lymphatic leukemia affecting the skin, mycosis fungoides, erythroderma, reticulum-cell sarcoma of the skin, and acrodermatitis chronica atrophicans.

Messerschmitt D26,705/54: Occasionally, marked increases in the bone-marrow MC count are found in patients with cancer or lupus erythematodes.

Woringer D26,819/55: In many dermatoses associated with hyperpigmentation (urticaria pigmentosa, pigmented scars, "melanoderma of vagabonds," seborrheic warts, malignant lentigo, posteczematous pigmentations, circumscribed lichenification with pigmentation) the MC density in the pigmented areas is increased. In other forms of pigmentation (Addison's disease, hemochromatosis, pigmentation due to ACTH treatment or exposure to heat, vitiligo, racial pigmentation), the hyperpigmented skin contains a normal number of MCs. In ulcers due to varicose veins, topical mastocytosis is often accompanied by both hemosiderosis and melanosis. It is probable, therefore, that at least in many types of pigmentation, the MCs play an important role.

Lindemayr & Santler D26,876/55: In two cases of eosinophilic granuloma of the bone, there was distinct diffuse metachromasia in the affected regions.

Asboe-Hansen & Kaalund-Jorgensen C25,899/56: In a patient with generalized mastocytosis and urticaria pigmentosa, disseminated xanthomas appeared, but their relationship to the MC proliferation could not be proved. There was marked hyperglobulinemia but no definite anomaly in serum lipids or heparin values and the clotting time and prothrombin index were normal.

Wegelius & Wahlberg D63,170/57: In a patient with scleroderma with cardiac sclerosis and mucinous edema, the MC count in the myocardium was high and possibly related to the sclerotic changes.

Levi et al. D26,473/59: In various forms of pruritus, skin eczema, and skin infections, the number of the cutaneous MCs is not significantly altered, while a mild augmentation occurs in urticaria and an enormous increase in urticaria pigmentosa. The histamine content of the skin runs roughly parallel to the MC count in all these conditions. The blood basophils appear to be diminished in urticaria.

Wiedmann & Niebauer C67,755/59: In patients with various forms of chronic eczema, the MCs of the affected skin are unusually numerous and rich in granules. The granules are discharged under the influence of Largactil and Phenergan.

Juhlin & Shelley D81,021/61: In patients with cold urticaria, unlike in normal controls, the cutaneous MCs show degranulation (punch biopsies) upon contact with cold. The same is true when blood basophils are chilled in vitro. It is assumed that "in acquired essential cold urticaria, the local and systemic signs are due to histamine release from the mast cell of the skin and basophilic granulocyte of the blood."

Giacometti et al. E35,787/63: In alopecia areata there is intense metachromasia of the dermis both in the affected and in the nonaffected areas. At the same time, the dermal connective tissue stains intensely with Hale's stain. The author believes that alopecia areata is a disease of the whole dermal connective tissue in which MCs play an important part.

Juhlin E35,093/63: In patients with alopecia areata, the bald areas are particularly rich in MCs. Upon intravenous infusion of 48/80, urticaria first appears in these bald areas.

Asboe-Hansen G13,573/64: General review of the cutaneous MC changes seen in various dermatoses.

Calnan E51,853/64: Review of the literature and personal observations suggesting that "chronic 'ordinary' type urticaria may depend on a varying susceptibility of the mast cell to histamine releasing agents, rather than on the presence or absence of specific inducing substance."

Szabó & Mészáros F14,221/64: In psoriasis (as in some other inflammatory diseases of the skin) the cutaneous MC density is increased. This is more evident in acute than in chronic cases and most pronounced in the vicinity of sweat glands. There is a positive correlation between the density of MCs around sweat glands and the amount of acid mucopolysaccharide contained in the sweat-gland lumina. It is assumed that the MCs play a role in the pathogenesis of psoriasis and they may also participate in sweat secretion.

Grin et al. F16,754/64: On the basis of indirect evidence, it is assumed that excessive 5–HT production (possibly by MCs) plays an important part in the pathogenesis of scleroderma. The anti-5–HT substance, Deserol, gives satisfactory therapeutic results.

Lindner G20,218/64: In a dog with chronic dermatitis and a melanosarcoma of the leg, the MCs showed a "vesicular type of secretion" with the formation of large bulli on the cell surface. To a lesser extent, similar surface-vesicle formation was observed in dogs and cats suffering from dermatitis, but not in normal animals.

Mikhail & Miller-Milinska D11,944/64: Comparative studies on the cutaneous MC count in 17 dermatoses.

KELOIDS

Audry D27,885/1896: In cicatricial keloids of man, MCs are not particularly numerous.

Pautrier & Woringer D27,883/31: In keloids, MCs are numerous and the tissue calcium content is about 3–4 times that of normal connective tissue.

Asboe-Hansen D26,785/50: MCs and metachromatic ground substances are plentiful, especially in recent keloids.

Degos et al. D27,406/51: In a case of generalized mastocytosis, a decubitus-like ulcer appeared in the gluteal region and gave rise to the local development of keloid-like dense connective tissue.

Baglioni C16,539/54, *pp. 223, 225*: Discussion.

Calonius & Jäämeri D26,777/61: In a series of 22 operatively-removed keloids, the total MC count was not higher than in ordinary scars. Most of the MCs were in the peripheral younger portions of the keloids. The number of MCs within the keloid tissue increased with advancing age and diffuse metachromasia of the ground substance was most common wherever the MC count was highest.

Fernex D26,660/61: Negroes are known to be particularly susceptible to the development of keloids after skin wounds. Furthermore, various types of "idiopathic myocarditis" are commonly observed among African natives. Since the MC count both in the heart and in the skin is much higher in Negroes than in Europeans, the question is raised whether these cells might not play a role in the development of inflammation and keloid formation.

CARDIOVASCULAR DISEASES

Atherosclerosis

Sabrazès & Husnot D27,507/07: In senile individuals with arteriosclerosis, the MC count in the frequently sclerotic adrenal glands is unusually high.

Faber D29,294/49: "On the basis of the literature, it is shown that the organism contains a number of extracellular cholesterol deposits and that these are always to be found in tissues which beforehand contain substances that can be stained metachromatically. It is, therefore, possible that these substances are responsible for the depositions of cholesterol. In the human aorta, one finds an increasing content of sulfate as a measure of the metachromatically stainable carbohydrate-sulfuric acid esters with advancing age. Higher values are found in cases of hypertension and in most cases of syphilitic aortitis, corresponding to the increased cholesterol contents. The sulfate content of the xanthomatous aorta is normal."

[The possibility that the metachromatic material may be heparin is considered but a relationship to MCs is not specifically discussed (*H.S.*).]

Cairns & Constantinides C3,038/54: Young adults and nonatherosclerotic senile individuals have approximately the same number of MCs in the myocardium. On the other hand, in senile atherosclerotics, this number is considerably below normal, irrespective of the immediate cause of death.

Constantinides & Cairns D26,732/54: The cardiac MC count of atherosclerotic senile individuals was lower than that of nonatherosclerotic young adults.

Baglioni C16,539/54, *pp. 167, 186*: Discussion.

Lino & Salvatore G18,901/55: In patients with atherosclerosis, the cardiac MC count is significantly subnormal. At the same time, the blood level of metachromatic substances diminishes. "The authors suggest the hypothesis of a direct relation between mast cell rate, blood concentration of metachromatic substances and atherosclerosis."

Díaz & Guedes E56,717/57: The MC count and diffuse metachromasia in the arterial wall and periarterial connective tissue of the kidneys are increased in subjects who died of nephrogenic hypertension.

Pollak D26,440/57: Numerous observations in the literature suggest that MCs may participate in the pathogenesis of atherosclerosis, presumably by regulating lipid metabolism. For example, in an extensive study on the MCs of human blood vessels, the highest counts were observed in patients whose blood plasma was milky at autopsy. It was suggested that perhaps MCs are attracted by lipoproteins carried into the vessel wall by blood plasma insudate. This view finds support in experiments on rats, showing that fat i.p. increases MC density and causes degranulation (*Shoulders & Meng* D27,067/57). Upon intracorneal injection of serum lipoprotein fractions to dogs, MCs appeared in the edematous tissues where normally none are found (*Waters* D27,068/56). "Heparin carried and released by tissue mast cells might serve to break down lipoproteins into soluble protein and insoluble lipids. The presence of mast cells in edematous tissues and their absence in atheromatous plaques possibly implicates these cells as participants in atherogenesis."

Paterson & Mills C71,884/58: In 67 consecutive autopsies, "no relationship has been found to exist between the number of mast cells and the degrees of atherosclerosis. However, significant reduction in the number of these cells was apparent in cases with complications such as thrombosis, infarction, and acute coronary insufficiency, compared with the number in cases without these complications."

Pomerance D33,710/58: In patients who died of coronary occlusion, the number of MCs around the coronary arteries was increased in proportion to the severity of the atheromatosis. "It is postulated that the increase in perivascular mast cells is due to inhibition of the normal mechanism of heparin release."

Lempert et al. D26,747/61: The validity of the earlier work of Constantinides et al. concerning an increased number of MCs around the coronary arteries in patients with atherosclerosis is questioned because he used aqueous formalin as a fixative. From a new investigation of this problem, "it is concluded that the estimation of the number of mast cells in the myocardium is unreliable, even in specimens fixed in alcoholic formalin. Secondly, it appears that no correlation exists between the number of mast cells counted in a single specimen and the apparent degree of atherosclerosis."

Fernex D26,839/61: The MC count in the heart (and to a lesser extent in the skin) is diminished in patients with coronary sclerosis, renal disease, hypertension, and a high blood cholesterol, that is, conditions frequently associated with cardiac infarcts. On the other hand, an increased MC count is found in patients with a low blood cholesterol and a considerable resistance against myocardial infarction, such as are found among Africans.

Jennings et al. D58,288/63: "In man, there are relatively more mast cells in the adventitia of arteries with atherosclerotic lesions than in normal vessels, but this reaction is more likely to follow than to precede the development of disease. Neither an increase nor decrease of cells was found in the coronary vessels of those racially predisposed to coronary atherosclerosis compared with the vessels of those with a lesser racial predisposition. Perhaps the most interesting finding to emerge from the numerical studies of mast cells has been that in man, a general decrease of these cells takes place in many tissues with advancing age."

Benditt & Lagunoff E580/63: "No obvious, interpretable relationship between mast cells and atherosclerosis or coronary thrombosis has emerged thus far." In general, MC

proliferation in connective tissue is viewed as the result of nonspecific, chronic local injury.

Obliterating arteritis

Battezzati B64,180/50: In thromboangiitis obliterans, numerous MCs appear within the walls of the affected arteries.

Candiani D39,604/53: In patients with obliterative angiopathies conducive to gangrene, MCs are often found in the intima and media of large muscular arteries where they are normally not present. Sometimes, they occur also in thrombi during organization. There appears to be an inverse relationship between diffuse metachromasia and the number of MCs. There is no significant difference between MC behavior and the nature of the vascular process that leads to gangrene. "Wherever there is formation of new connective tissue and new blood vessels, there MCs originate or at least appear during one phase of the process." The MCs may exert an antitoxic function.

Hjelmman E20,253/56: In various forms of obliterating vascular diseases of man, the MC count in the vascular wall increases. This response is considered to be a defense reaction against further clotting.

Hjelmman D39,689/56: In endarteritis obliterans, the MC count in the adventitia of the arteries and veins of the affected limbs is greatly increased.

Thromboses, varices

Audry D27,885/1896: In varicose ulcers with venous stasis, MCs are comparatively rare.

Cottenot D27,990/54; *Woringer* D26,819/55: In the surroundings of varicose ulcers, both hemosiderin and melanin pigment tend to be associated with an increased number of MCs.

Hjelmman E20,254/56; D39,689/56: In the hemorrhoidal veins of man, the MC count is greatly increased, especially if there is an associated thrombosis.

Pepler & Meyer D26,748/61: In a series of nine patients with cerebral vascular thrombosis, five showed a very significant increase in the coronary MC concentration. "It is postulated that the increase of coronary mast cells is a manifestation of a general systemic reaction to thrombosis in any part of the body. The significance of this increase is not known."

De la Pava & Pickren E90,345/62: In patients with thrombosis, the cutaneous MC count is diminished, presumably a reflection of low heparin production.

Myocarditis, endomyocardial fibrosis

Fernex E20,417/60; D39,603/61: In serous myocarditis of the type common in Africa, the myocardial MC population is greatly increased and production of histamine and heparin by the MCs is assumed to play a part in the subsequent development of sclerosis. In Senegal Negroes, the cardiac MC population is diminished in arteriosclerosis, particularly in obliterative atherosclerosis, which is especially rare in Africa. "The paucity of mastcells is considered to be a factor predisposing to coronary thrombosis, assuming that the mastcell through its function as heparinocyte prevents vascular alterations."

Fernex G10,072/64: There is an increase in cardiac MC density in patients with carcinoid or endomyocardial fibrosis due to helminthiasis. It is assumed that the MCs render the cardiac connective tissue particularly subject to inflammation and connective-tissue proliferation in both these diseases.

RENAL DISEASES (INCLUDING DISEASES OF THE URINARY PASSAGES)

Prior & Sesenna D27,080/53–54: In a large series of patients with cancer or sclerosis of the neck of the urinary bladder, the number of MCs in the stroma was extremely variable and no definite relationship could be established between MC morphology or number and the degree of malignancy.

Schlich & Piccaluga D65,256/56: In patients with nephrosclerosis, the MCs become very polymorph, which is considered an indication of increased cellular activity, perhaps related to connective-tissue formation.

Macaluso & Salerno D26,435/60: The MC population around the renal pelvis of man is particularly dense in patients who died from various chronic, inflammatory renal diseases and nephrosclerosis. Conversely, the MCs are scarce or even absent in this region in patients with acute nephritis or degenerative renal diseases.

Macaluso D26,436/60: In patients with various types of primary and metastatic renal neoplasms, the MC population in the vicinity of the tumors was extremely variable. However, in general the MCs were numerous in the stroma around the tumors, wherever the connective tissue was rich in fibrils and contained lymphocytic and histiocytic infiltrations. Comparatively few or no MCs were found in metastatic tumors. Yet, the author concludes that the MCs play an important role in the stroma reaction of the host against the tumor.

Pavone-Macaluso D26,615/60: While under normal conditions the kidney contains only a few MCs, their number is increased around inflammatory foci, tumors (especially primary neoplasms of the kidney), but not in nephrosis. Particularly numerous MCs were found in pyelonephritis and chronic glomerulonephritis.

Rebuck et al. D58,294/63: In patients with interstitial cystitis, the basophil and MC-number is increased not only in the bladder but also at the site of "skin window tests."

GASTROINTESTINAL DISEASES

Peptic ulcer

Quensel D39,827/28: In the vicinity of gastric ulcers, the number of MCs is increased both in the submucosa and in the hypertrophic muscles.

Quensel D26,221/33: In the sclerotic tissue within the crater of gastric ulcers, MCs are absent or scarce while they are more numerous at the borderline which demarcates the ulcer from the healthy tissue where they occur in association with round-cell infiltrations.

Vallone D26,432/44; *Janes & McDonald* B32,304/48; *Squartini et al.* D30,195/56: In the vicinity of peptic ulcers, the MC population tends to increase considerably in man.

Corbetta D26,439/51–52: MCs are most numerous in acute, less in chronic gastric ulcers, and least numerous in gastric cancer. It is thought that the MCs participate in tissue repair, primarily through their influence upon the development of the ground substance.

Squartini et al. D30,649/56: In the normal duodenum of man, the MC count corresponds to 2.85 per 0.04 mm^2. More or less considerable increases are seen in peptic ulcer, carcinoma, and sarcoma, simultaneously with an increase in diffuse stroma metachromasia.

Räsänen D27,066/58: No significant change in the gastric MC population was found in patients with peptic ulcer.

Sundberg & Siurala D26,634/59: A moderate increase in the gastric MC count is noted in patients with duodenal ulcer and gastric ulcer.

Hiatt & Katz D25,019/62: An increase in MC concentration was observed in the muscularis in patients with peptic ulcers.

Gastritis

Vallone D26,432/44; *Corbetta* D26,439/51–52: In cases of acute or chronic gastritis, there is often a marked increase in the local MC population.

Siurala & Sundberg D27,075/58: While the mean MC count in the human gastric mucosa (obtained by suction biopsy) was 79 $\pm$ 8.6/mm^2, it rose to 125 $\pm$ 24.1 in superficial gastritis and to 153 $\pm$ 18.3 in atrophic gastritis.

Ulcerative colitis

McGovern & Archer D39,717/57: It is assumed, on the basis of histologic studies on rather indirect evidence, that "augmented barrages of nervous impulses during stress may give rise to excessive production of acetylcholine in the colon, which then reacts with the tissue mast cells, causing the phenomenon of 'histamine-release'."

McAuley & Sommers D33,728/61: In ulcerative colitis, the inflammatory exudate of the colonic wall is unusually rich in MCs. "Mast cell secretions would likely exaggerate and prolong the exudative inflammatory reaction in persons with nonspecific ulcerative colitis."

Hiatt & Katz D25,019/62: An increase in the MC population of the muscularis of the intestine was seen in patients with regional ileitis, ulcerative colitis, and spastic colitis. No comparable increases were seen in the muscularis of patients with inflammatory conditions or postirradiation fibrosis of the intestine.

Rebuck et al. D58,294/63: In patients with ulcerative colitis, the accumulation of basophils (MCs?) in "skin windows" is augmented.

DISEASES OF THE RESPIRATORY TRACT

Hirschmann D27,099/01: MCs are numerous in the stroma of the larynx of patients with laryngitis. Here, the MCs (basophils?) are sometimes seen in the process of emigration through the vascular wall into the connective tissue.

Baglioni & Leonardelli D33,714/56: MCs are plentiful in nasal, laryngeal, and aural polyps; their number parallels the amount of argyrophil fiber tissue.

De Vincentiis & Bernicchi C68,645/58: In patients with allergic rhinitis, unusually large numbers of MCs accumulate in the submucosa of the turbinates.

Cattaneo D26,725/59: MCs are particularly numerous in the nasal mucosa and submucosa of patients with habitual epistaxis.

Salvato C73,693/59: The peribronchial connective tissue of man is particularly rich in MCs and these show intense degranulation during attacks of bronchial asthma. It may be assumed that, by virtue of their heparin, histamine, and hyaluronic acid content, these cells play an important role in the pathogenesis of hyperergic tissue reactivity.

Hussarek & Neuhold D26,850/60: In chronic rhinitis with polyp-like mucous membrane proliferations, the MC population of the nasal mucosa was greatly increased, while this was not the case in chronic rhinitis without such proliferative changes. In patients with acute vasomotor spasms of the nasal mucosa, the MC count decreased below normal. This decrease may be related to histamine discharge and the production of local acute inflammatory changes.

Salvato D10,341/61; D27,641/62: In asthmatic patients, the number of peribronchial MCs is subnormal and most of them discharge their granules.

Holler E2,351/63: Extensive clinical observations suggest that asthma is a disease of adaptation in which deranged secretion of corticoids and abnormal MC reactions play a decisive role.

Palva & Palva D68,123/63: MCs are present in the inflamed tissue and the aural discharge of patients with mastoiditis.

Hlaváček & Lojda D68,124/63: The MCs in the turbinates and maxillary sinuses of patients with allergic rhinitis are usually diminished in number, especially during the acute stages of the disease.

Parish et al. G16,492/64: In "cot-death" (a fatal asphyctic condition that develops in the sleeping infant following aspiration of stomach contents containing cow's milk) there was no striking change in the pulmonary MCs that might suggest an anaphylactic reaction.

OCULAR DISEASES

Holmgren & Stenbeck D26,779/40: The MC count in the cornea increases during various diseases such as ulcus serpens and iridocyclitis. Occasionally, the MC count of the eye is also augmented in glaucoma.

Zollinger D26,862/49: In the iris and ciliary body of the human eye, the MC count is increased in various forms of chronic inflammation such as chronic iridocyclitis, secondary glaucoma, and old perforating wounds. On the other hand, comparatively few MCs are found in fresh perforated wounds, simple glaucoma, or senile cataract. The MC count was variable in the case of intraocular tumors with papilledema. Especially high MC counts are found occasionally with retinal gliomas and melanomas of the choroid. In the latter case, sometimes the infiltrate consists exclusively of MCs.

Günther D65,225/56: Detailed description of the MC concentration in the human eye as influenced by ocular diseases. The MC count is generally increased in most types of chronic inflammation but diminished in acute suppurating infections and after thrombosis of the central vein.

Vannas D26,763/59: In simple glaucoma, the MC population of the eye is slightly, but not significantly, elevated. In closed-angle glaucoma, there is decrease in the ocular MC population during the severe, acute attack, while in the chronic congestive phase there is a significant increase. Especially-high MC counts were noted in inflammatory secondary glaucoma as in chronic inflammation in general.

Titschack D26,861/60: In patients with melanomas of the eye, the MC count in the ciliary body was usually high, but comparatively few MCs were found in the immediate vicinity of the tumor itself.

Gemolotto & Patrone D64,690/61: The ocular MCs of man are diminished in cases of blue sclera and increased in absolute glaucoma, but the changes are not very conspicuous.

BLOOD DYSCRASIAS

Undritz D30,200/46: The MC content of the bone marrow is increased in certain forms of leukemia, agranulocytosis, and panmyelopathy.

Kabelitz D33,664/49: The sternal bone-marrow MC population is increased in patients with pernicious or iron-deficiency anemia.

Bergström et al. D30,555/50: In a case of pronounced hemorrhagic diathesis of unknown origin, blood-coagulation time was prolonged and the bone-marrow MC count greatly increased. The hemorrhage could be checked by protamine and was ascribed to hyperheparinemia.

Bremy C72,062/50: Proliferation of bone-marrow MCs is noted in 20 cases of "aregenerative anemias" and is regarded as "a partial reaction of the bone marrow to the influence of allergic-anaphylactic processes." This increase in bone-marrow MCs is often associated with reticulosis of the marrow elements.

Herpels D26,783/51: It is exceptional to find a high MC count in the human bone marrow except in cases of panmyelophthisis, aplastic anemia, or lymphatic leukemia. Description of a syndrome of hypersplenism (with hypochrome anemia, leukopenia, hemorrhagic diathesis, and infantilism) in which the bone MC count is unusually high without any accompanying hyperheparinemia.

Fadem D26,720/51: In a series of 2,800 human bone marrows, only seven were found to contain MCs and these suffered from Hodgkins' disease, lymphatic leukemia, prostatic carcinoma, atypical aplastic anemia, or thrombocytopenic purpura. In the latter case, the appearance of MCs was associated with the development of numerous immature megakaryocytes in the bone marrow.

Rohr D27,402/52: Intense proliferation of bone-marrow MCs is seen, particularly in chronic anemia (hypo- or aplastic, more rarely pseudo-aplastic) and in granulocytosis.

Hauser D26,883/53: In various forms of aplastic anemia, the bone MC count is increased.

Paniagua et al. D39,785/53: In chronic, unlike in acute aplastic anemia, the MC count of the bone marrow is increased.

Johnstone C11,069/54: Bone marrow MCs could be found in 30 percent of a series of 139 patients taken at random. Their proliferation appears to be enhanced by anemia and splenomegaly due to various causes.

Meneghini D39,813/54: In a patient with pernicious anemia, decreased blood-coagulation time, and a hemorrhagic tendency, there was marked proliferation of MCs in the bone marrow. Treatment with vitamin B_{12} caused a remission of the anemia, with disappearance of the excess medullary MCs.

Ziliotto & Pellegrini D27,056/56: In patients with reticulum-cell tumors, hepatic cirrhosis with venous stasis, and splenectomy because of Banti's disease, the MCs undergo striking changes which led to the conclusion that one function of the MCs may be "to exert a plastic effect upon the reticulum."

Sumi C60,846/58: MCs in the bone marrow of man are augmented in aplastic anemia, Werlhof's purpura, and Banti's disease. Also, data concerning bone marrow MCs in other conditions.

Csaba D2,230/60: Particularly-numerous MCs were found in the thymus of children who died of myeloid leukemia or agranulocytosis.

Brinkmann D26,693/62: The MC population of the human bone marrow is most frequently increased in various forms of aplastic anemia and panmyelophthisis.

Fernex D66,465/62: In tropical eosinophilia, there is mastocytosis of the skin.

Prager & Bearden E90,981/62: The MC count in the mesentery of mice, which developed leukemia, is greatly increased.

INFECTIONS

Lymphadenitis

Cazal D26,655/55: The MC count of the human lymph nodes increases under the influence of various bacterial infections.

Lennert et al. D26,817/59: Numerous MCs are found in human lymph nodes affected by various forms of "nonspecific" lymphadenitis.

Lennert & Illert D26,831/59: In a series of patients suffering from various lymph-node diseases, the highest number of MCs were found in the lymph nodes affected by filariasis and, here, the mastocytosis was associated with eosinophilia. The lymph-node MC population is also high in various types of "nonspecific lymphadenitis" and to a lesser extent in lymph-node tuberculosis and sarcoidosis. The lymphadenitis of cat-scratch disease (Masshoff disease) is not associated with an increase in MCs.

Tonsillitis

Sussmann D27,432/11: MCs are frequently seen in hypertrophic or inflamed adenoids and tonsils of man.

Scevola D27,701/38: The local MC count is very high in individuals with tonsillar hypertrophy and tonsillitis.

Miskolczy-Fodor D31,580/50: In various forms of tonsillitis, the MCs disappear during the acute stage while their number is increased during the chronic stage.

Filipo & Bernicchi D84,681/57: MC proliferations are seen in the human tonsil, especially in cases of chronic inflammation with sclerosis.

Drabe D26,852/61: In the human tonsil, MCs are particularly plentiful during chronic inflammation, even when inflammatory processes are not longer demonstrable, and lymphatic tissue is replaced by scars. It is concluded that "the tissue mastocytes probably promote the formation of new connective tissue through the production of acid mucopolysaccharides."

Gingivitis

Stella D63,057/55: A considerable number of MCs is found in the connective tissue of the human gingiva, but some are present also in the epithelium under normal conditions. The MC count of the gingiva increases under the influence of various inflammatory processes, but degranulation is seen in pregnancy gingivitis.

Takeda D63,362/58: In patients with suppurating alveolar gingivitis, the MCs in the gums are increased in number and are abnormal in shape.

Vidal E22,485/63: MCs are always numerous in dental granulomas.

Mastitis

Higuchi D26,227/30: In chronic inflammation of the mammary gland with pronounced fibrosis, there is a diminution, while in chronic cystic mastitis there is an augmentation of the MC population.

Quensel D26,221/33: In chronic mastitis with or without cyst formation, the MC population of the mammary gland remains essentially normal.

Syphilis

Audry D27,885/1896: In syphilitic lesions of man, MCs are plentiful.

Athias & França D27,513/01: MCs are found along the blood vessels of the brain in a patient with general paresis. No such cells have been found in this location in the brains of normal individuals.

Michels & Globus D27,401/29: Transitional types between the plasma cell and the MC are described as "plasmamastcells" in syphylitic perivascular infiltrates of the central nervous system in man.

Tuberculosis

Bergonzini D27,587/1891: MCs are numerous in tubercles of the human skin.

Audry D27,885/1896: In man, MCs are frequently plentiful in tuberculous lesions.

Wolff D27,718/02: Vitally-tingible MCs can be found in tuberculous exudates.

Pellegrini & Ziliotto D65,521/58: MCs accumulate in large numbers in the vicinity of extrapulmonary tuberculomas as well as in foreign-body granulomas of man. Later, in the sclerotic change, they disappear.

Leprosy

Marie-Suzanne & Noel D26,736/48: The granuloma of tuberculoid leprosy contains numerous eosinophils and MCs.

Gupta & Ghosh D39,828/63: The cutaneous MCs in leprosy, as well as in many other dermatoses of man and in the normal mesentery of the guinea-pig, show acid-fast granules, demonstrable with the Fite-Faraco modification of Ziehl-Neelsen stain. These granules, which were first thought to be partially digested mycobacteria of leprosy, are apparently normal MC constituents.

Kátó & Gözsy D66,168/65: The MC count increases around s.c. murine leprosy granulomas, reaches a peak after 40 days, and then decreases as the resistance of the host breaks down. India ink i.v. accumulates at the sites of infection when the MC disruption is maximal, "thus suggesting that the natural defense mechanism is well functioning and it is maintained by mediators of mast cell origin: histamine and serotonin." Antileprosy drugs, which retard granuloma formation, also impede the decline of local mastocytosis.

Malaria

Cottini D39,837/47: In a woman who developed circumscribed pigmented urticaria in the course of malaria, numerous MCs and pigment cells were seen in the lesions. The case is considered to be a transitional type between urticaria pigmentosa and the so-called "infectious" urticarias.

Fernex D26,721/59: In the chick infected with *Plasmodium gallinaceum,* as well as in the monkey infected with *Plasmodium cynomolgi,* the resulting experimental malaria is not accompanied by any change in the cardiac MCs.

Various

Wolff D27,646/04: In a very unusual case of pleuritis of unknown origin but unconnected with leukemia, the MC count was about 10 per cent.

Leuchs E38,234/04: MCs are frequently demonstrable in purulent exudates of patients with various forms of infection.

Schuh D27,589/11: MCs are almost always demonstrable in the purulent discharge of gonorrheic patients.

Smirnowa-Zamkowa D31,602/26: Very large numbers of MCs are found in various organs (particularly in the inflammatory infiltrates) of patients with scarlet fever. This mastocytosis is so intense that it is considered to be a characteristic feature of the disease.

Argaud & Pesqué 90,375/29: The human thymus normally contains very few MCs, but their number increases considerably in bronchopneumonia and diphtheria.

Vallone D26,432/44–45: In pneumonia and bronchopneumonia, it is rare to find MCs mixed with the inflammatory exudate where they are assumed to migrate by ameboid motion.

Janes & McDonald B32,304/48: In various forms of chronic inflammation including tuberculosis, the synovial MCs of man are increased in number.

Messerschmitt D26,636/55: The MC count on bone-marrow smears is frequently increased in patients with various chronic infections.

Dunn & Montgomery D99,754/57: The MCs immediately below the uterine cervical epithelium of women show no noteworthy change in acute or chronic inflammation or squamous metaplasia. In leukoplakia and especially in cervical carcinoma there is a considerable increase in the topical MC population.

Fernex D26,660/61: An increased cardiac MC count is often associated with serous myocarditis, while this is not the case with other forms of myocarditis. Curiously, in the uremic serous myocarditis, MCs are scanty while they are particularly numerous in various forms of "idiopathic myocarditis" common in Africa.

Brinkmann D26,693/62: The MC population of the human bone marrow is increased in various chronic infections.

PARASITIC INFESTATIONS

Gherardini D39,596/1898: MCs are plentiful in the bovine liver but their number is further increased in echinococcus infection.

Fernex & Bèzes D39,821/62: A strong hyperplasia of the cutaneous MC system (associated with blood eosinophilia) "is observed in relation with filariasis and bilharsiasis and tropical eosinophilia in Africans as well as in Europeans . . . In tropical regions, helminthic diseases may be considered as the most frequent etiological factor for mastocytosis."

ENDOCRINE DISEASES

Hypothyroidism

Asboe-Hansen D26,784/50; B60,602/50; B60,548/50; B60,604/51: In myxedema, including circumscribed and thyrotoxic myxedema, there is accumulation of hyaluronic acid and of large MCs in the dermal connective tissue.

Baglioni C16,539/54, *p. 201*: Discussion.

Ziliotto & Pellegrini D12,772/56: In the thyroid tissue of patients with hypothyroid goiter, MCs are allegedly absent; in hyperthyroid goiters, MCs are numerous but they discharge their granules. The MCs are assumed to detoxify abnormal thyroid products.

Beber et al. C85,594/60: Very few MCs were found in the placenta of a woman who received desiccated thyroid because of hypothyroidism.

Hyperthyroidism

Ekman & Naumann B4,771/45: No MCs could be demonstrated in the thyroid glands (normal or Graves' disease) of man following fixation in 4 per cent lead acetate and staining with toluidine blue.

Asboe-Hansen D26,784/50: In thyrotoxicosis, there is usually no demonstrable hyaluronic acid in the dermal connective tissue and only few, small MCs.

Asboe-Hansen C1,756/54: The skin of patients with malignant exophthalmos contains an unusually large number of MCs.

Hypocorticoidism

Woringer D26,819/55: In Addison's disease, the pigmented skin is not particularly rich in MCs. Hence, hyperpigmentation is not necessarily associated with mastocytosis.

Diabetes

Cottenot D26,657/55: In diabetes with renal glomerulosclerosis, "there exists a monstrous increase in the hyaluronic acid content of the dermal connective tissue, accompanied by a very marked degranulation of mastocytes." Since at the same time, certain abnormal carbohydrates were detected in the urine, it was thought that in diabetes with renal disease, there is a special derangement of carbohydrate metabolism which is closely linked with the production of polysaccharides by the MCs.

Pomerance D33,710/58: In diabetic patients with coronary disease, the number of MCs around the coronary arteries is even more markedly increased than in nondiabetic patients with coronary occlusion.

VARIOUS TUMORS

Reviews: *Michels* C72,066/38 *pp. 344–6*; *Holmgren & Wohlfart* B41,911/47; *Serrão* C8,615/53; *Baglioni* C16,539/54 *pp. 194, 203*; *Dunn* D27,626/54; *De Palo & Papadia* C9,397/55

Tumors in man

Waldeyer A6,120/1875: First description — under the name of "Plasmazellen" — of what we now call "MCs," in human carcinoma tissue.

Ehrlich D27,092/1879: MCs are numerous in the stroma of carcinomas in man.

Stintzing D31,578/1889: *Corbetta* D26,439/51; *Serrão* C8,615/53: The effect of gastric cancer upon the local MC population appears to be variable; there may be an increase or a decrease.

Bergonzini D27,587/1891: Many MCs were found in the stroma of various tumors, especially in a uterine fibromyoma and in a lipoma.

Audry D27,885/1896: Numerous MCs are found in various forms of epitheliomas in man.

Rheindorf D33,731/05: In melanosarcomas, MCs are common and certain cells contain both pigment and metachromatic granules.

Fromme D26,217/06: The accumulation of MCs around certain primary carcinomas and their lymphatic metastases in man is attributed to a "positive chemotaxis of these cells which may have the function of detoxifying noxious substances produced by the tumors."

Bonney D28,388/08: MCs are frequently found in the neighborhood of carcinomas but it is not certain that their number is actually increased above normal.

Greggio D31,536/11: In the connective tissue of various tumors of man, the MC population is extremely variable; an increase is by no means the rule.

Huguenin D39,690/11: MCs are found in the loose connective tissue of the uterus, particularly in the vicinity of myomas in women.

Huguenin D29,587/12: In uterine myomas, there are regions with numerous MCs while at other places plasmocytes predominate.

Weill D26,215/19: In a case of melanosarcoma, metastases in organs normally poor in MCs (heart, muscles, thyroid, liver) contained few MCs. In the lymph nodes, the metastases were surrounded by numerous MCs, allegedly because the lymphocytes can give rise to MCs under the influence of stimulation by the neoplastic cells.

Weill D27,097/19: Numerous MCs are found in the stroma of squamous epithelial carcinomas of the human cervix uteri. They are thought to arise partly from lymphoid cells.

Regaud & Lacassagne D26,872/22: Many MCs are found in the connective tissue stroma of various carcinomas of man. These have previously been thought to be "eosinophils with round nuclei" because, using bad fixatives, the granules take up eosin.

Brack D26,821/25: MCs are often quite numerous in the connective-tissue capsule around carcinomas and sarcomas, but not within the tumerous substance itself.

Quensel D39,827/28: The MC population is increased in gastric carcinomas.

Kückens D30,204/28: MCs are plentiful in a stroma of mammary glands affected by cystic fibrosis or tumors.

Pettinari D30,642/29: In human cancers of various types, there is no MC proliferation comparable to that seen in experimental tar cancers.

Higuchi D26,227/30: In women with carcinomas of the mammary gland, the MCs become particularly numerous along the borderline between the normal and neoplastic tissue.

Austoni D27,062/32: In women with mammary carcinomas, MCs are comparatively numerous in the regional lymph nodes that contain metastases.

Quensel D26,221/33: In gastric carcinomas, MCs are scarce within the neoplasm itself but more numerous in its surroundings. In mammary carcinomas, few MCs occur within the stroma of the neoplasm, while they are more numerous in the surroundings of these tumors.

Güttner D26,843/42: No obvious increase in MC density could be found in human lymph nodes that contained carcinoma metastases.

Baglioni D26,894/44: The connective-tissue stroma of various spontaneous tumors of man is especially rich in MCs.

Sylvén D30,594/45: Studies on the variety of human tumors suggest that "all growing tumor vegetations constantly contain high molecular ester sulphuric acids in their cell territories." They also contain numerous MCs which may account for the formation of metachromatic high-molecular sulfuric-acid esters. However, "the old misleading term, mucus," should be abandoned.

Janes & McDonald B32,304/48: MCs are much more frequent in non-cancerous lesions of the stomach and duodenum than in cancer of the stomach. On the other hand, unusually large numbers of MCs were found in lymph nodes involved by carcinoma.

Kabelitz D33,664/49: The MC population in the sternal bone marrow of patients with gastric carcinomas is often increased.

Consolandi D39,591/49: MCs and free metachromatic material are plentiful in patients with cystosarcoma phylloides of the nipple. Here, the entire process of mucoid formation in the neoplasms may result from MC activity.

Miskolczy-Fodor D31,580/50: In malignant growths of the tonsillar region, MCs are scarce.

Bruni et al. D30,647/50: In 75 patients with gastric carcinomas, MCs and free metachromatic material were constantly found in the stroma. Mast-cell products and particularly heparin-like substances may play a role in the development of the stroma reaction.

Bruni & Olivi D39,592/51: In tumors of the human parotid gland, MCs are less numerous than in the normal parotid gland; at the same time, diffuse metachromasia may become intense, presumably owing to a degranulation of MCs.

Bruni & Caschera D30,634/52: Around gastric carcinomas, the connective tissue contains an abnormally large number of MCs. The increase in their number is attributed to invasion by malignant cells and regarded as a secondary response.

Prior D39,610/53: In prostatic adenomas and carcinomas, the MC population is subject to great individual variations. No definite relationship exists between the malignancy of the tumor and the MC count.

von Numers & Fortelius D67,345/53: MCs are often found in the papilli of serous cystic adenomas of the ovary. Here, they lie within the epithelium and may contribute to the metachromatic content of the cysts.

Bruni & Caschera D39,618/53: The MC count was low in lymph nodes with metastases of various human neoplasms. This finding is viewed as evidence against the hypothesis that MCs exert a defensive function against tumor growth. Yet, the peritumoral hyaline connective tissue often stains metachromatically, a fact which suggests that mucopolysaccharides enter into the composition of the so-called "hyaline."

Jernstrom D28,481/54: An unusually large number of MCs was found in a synovial sarcoma of the pharynx in a young man.

De Palo & Papadia C9,397/55: In women with carcinoma of the uterine cervix, the MC population of the regional lymph nodes increases, especially during the period of most active neoplastic proliferation.

Cazal D26,655/55: The MC count in the lymph nodes increases under the influence of various tumor metastases and in lymphogranulomatosis.

Messerschmitt D26,636/55: Various types of malignant tumors tend to increase the bone-marrow MC population.

Mondina E54,833/56: The MCs are especially dense in hemorrhagic uterine fibromyomas.

Blomquist D27,524/56: MCs are normally present in the stroma and capsule of the human thyroid; their number is greatly increased in goitrous and other adenomatous glands.

Squartini et al. D30,649/56; D30,195/56: In the normal duodenum of man, the MC count corresponds to 2.85 per 0.04 mm^2. More or less considerable decreases are seen in peptic ulcer, carcinoma, and sarcoma, simultaneously with an increase in diffuse stroma metachromasia.

Dunn & Montgomery D99,754/57: The MCs immediately below the uterine cervical epithelium of women show no noteworthy change in acute or chronic inflammation or squamous metaplasia. In leukoplakia and especially in cervical carcinoma there is a considerable increase in the topical MC population.

Lascano D33,682/58: Extensive studies on human tumors showed that, in general, these contain only as many and usually less MCs than the surrounding tissues. "Only basal cell carcinoma of the skin has a greater number of mast cells than the normal skin has. The tumorous stroma, especially that of malignant tumors, is not a very favorable field for the development of mast cells."

Räsänen D27,066/58: No significant changes were found in the gastric-MC population of patients with gastric carcinomas.

Titschack D39,667/59: In a variety of basal-cell carcinomas of the eyelid skin, the number of MCs decreased within the stroma with increasing malignancy.

Lennert & Illert D26,831/59: The MC count is comparatively low in the lymph nodes of patients suffering from lymphogranulomatosis, lymphosarcoma, lymphadenosis, carcinoma metastasis in lymph nodes, and reticulum-cell sarcoma.

Sundberg & Siurala D26,634/59: In patients with gastric carcinoma, the gastric-MC count is considerably increased. However, a similar increase is seen with atrophic gastritis which occurred in every case of gastric cancer. The local mastocytosis is, therefore, presumably due to the atrophic gastritis and not to the cancer itself.

Macaluso D26,436/60: MCs are numerous in the stroma of various forms of renal tumors.

Csaba D2,230/60: In patients who died from various types of tumors, the MC population in the thymus was essentially normal.

Cawley & Hoch-Ligeti D26,653/61: Numerous MCs were seen in a great variety of cutaneous tumors, the highest counts being observed in nevus, basal-cell carcinoma, malignant melanoma, and keloid tissue, but in general they were limited to the stroma of the neoplasms.

Orlandi D26,658/61: The connective tissue surrounding laryngeal carcinomas is especially rich in MCs, while in the interior of the neoplasm, these cells are rare.

Spaziante & Giani E98,826/61: In the proliferating stromal connective tissue of hypertrophic prostates there are many MCs as well as diffuse metachromasia.

Orlandi D33,261/62: In various types of neoplasms situated in the tonsils or rhinopharynx of man, MCs were commonly found in the stroma, but their number was not definitely increased nor were there any abnormal forms demonstrable.

Baroni & Casella G19,160/63: In giant-cell epulis, the MC count is unusually high. This is considered evidence of the neoplastic nature of this growth.

Majewski et al. E20,009/63: In the stroma of human mammary carcinomas, there are many MCs and much free metachromatic substance. "The authors suppose that in the protoplasm of the fibroblasts and mast cells there arises a substance that may be the forerunner of the acid mucopolysaccharides of the connective tissue's ground substance."

Giani D18,251/64: In a variety of human tumors, MC density and diffuse connective metachromasia are greatest in the best-vascularized areas.

Tumors in animals

Sabrazès et al. D27,505/08: Nodular infiltration with MCs occurred in the spleen of a cat with a melanoma of the eyelid.

Bali D26,611/49: A study of numerous mouse neoplasms showed few or no MCs in granuloma tumors, adenomas of the ovary, carcinomas, and sarcomas of different sorts, and leukemias, while a luteoma and a splenic reticulo-endothelioma contained unusually large numbers of them.

Hilliard & Nash D63,183/51: Following i.p. injection of malignant or normal human cells, or even mouse tissue, the MCs disappeared from the peritoneal fluid of the mouse.

Köksal C1,302/53: MCs are especially numerous around necrotic parts of transplanted tumors.

Kelsall & Crabb D28,690/53: Transplants of various sarcomas and carcinomas caused no change in the MC population of the sublingual glands in the hamster.

Wada et al. D6,659/55: In rats bearing transplants of Yoshida sarcoma or Takeda sarcoma, there is an inverse relationship between the number of MCs and the proliferation of tumor cells.

Asboe-Hansen et al. C61,920/57: From four to six days after injection of Rous sarcoma virus into the pectoral muscles of 2-month-old Brown-Leghorn fowls, MCs and diffuse metachromatic substance appeared around the transplants. Some of the tumor cells also showed diffuse metachromasia with toluidine blue.

Stolk C61,615/58: In the precancerous skin of the lizard *Lacerta agilis,* the MCs accumulate and exhibit a golden-brown fluorescence in ultraviolet light, but only after treatment with formalin. It is thought that, just as in the precancerous mouse skin, the transformation of 5-HT into a fluorescent β-carboline by the action of formaldehyde is responsible for this phenomenon.

Scott et al. D63,179/58: Transplantation of a rat sarcoma or injection of a polypeptide fraction from this tumor, causes a reduction in the number of MCs in the rat mesentery. "The disruption of mast cells prior to and following tumor implantation increased tumor growth. The administration of 5-HT and/or histamine to rats also increased tumor growth."

Asboe-Hansen & Levi D78,274/59: "In early stages of Rous's fowl sarcoma I, S^{35}-labeled sulfate was incorporated in the numerous mast cells and the surrounding metachromatic extracellular substance. In later stages, nongranulated cells with a metachromatic cytoplasm in the sarcoma cell area took up S^{35}."

Stolk D39,817/60: "The cutaneous mast cells of the precancerous skin (carcinoma planocellulare) in the lizard *Lacerta agilis,* showed a positive leucine aminopeptidase activity." These MCs in the stroma of spontaneous tumors show degranulation upon treatment with distilled water.

Csaba et al. C98,159/60: The MC population of thymus in rats with Guérin tumor and mice with Ehrlich ascites tumor transplants is greatly increased.

Csaba et al. D2,228/60: In mice inoculated with Ehrlich ascites tumor, injection of heat-treated (non-metachromatic) heparin into the thymus produces local MC formation. In itself, intrathymic injection of this material is ineffective.

Simpson & Hayashi D26,645/60: In the mesentery of the cancer-resistant C57BL strain of mice, the perivascular MCs and those in the adjacent fatty tissue, increased with age in both sexes but those in the membranous portions of the mesentery were little affected by age. In the cancer-susceptible BALB/c mice, on the other hand, the greatest increase occurred in the membranous mesentery.

Stolk D26,444/61: MCs are numerous in the precancerous skin of the lizard *Lacerta agilis,* during the development of carcinoma planocellulare.

Goldie et al. D22,813/62: Viable tumor cells i.p. (kind not stated), cause irreversible disappearance of peritoneal MCs in the mouse, even if the tumors subsequently regress. Killed tumor cells are ineffective.

Simpson et al. D61,512/62: In C3H mice, which developed mammary cancers as a result of the milk agent, numerous MCs developed around the proliferating ducts. "Hence, with a totally different carcinogenic agent, the milk factor, and a different tissue, the mammary gland, there is again evidence that 'preneoplastic' proliferation of epithelium is associated with local increase of mast cells."

Scott D58,287/63: Rats bearing subcutaneous fibrosarcomas, exhibited intense fragmentation of their mesenteric MCs. Similar results were obtained with tumor extracts. At the same time, there was discharge of 5-HT and histamine and, since both these substances cause retention of radioactive iodide ("iodide trapping") in various organs, "the release of their [MCs] stores of histamine and 5-HT explains the iodide trapping syndrome seen in cancer." Polymyxin, 48/80, reserpine, and distilled water likewise reproduced the iodide trapping syndrome and all of this has been considered to support the view that this syndrome depends upon MC discharge. [Unfortunately, controls with stressors have not been performed (*H.S.*).]

Dunn D58,297/63: Numerous MCs were found in a hepatoma of a mouse which also had a Leydig-cell tumor.

CARCINOIDS

Tavares & Ribeiro D39,612/49: Cells with metachromatic granules are demonstrable in carcinoids of the human appendix. There may be transitional types between carcinoid cells and MCs.

MacDonald & Robbins D63,175/57: The cardiac lesions in patients with a carcinoid syndrome are quite characteristic. There is "a peculiar fibrous tissue, devoid of elastic fibers, present upon relatively intact endocardium, and large numbers of tissue mast cells are present in the affected valvular endocardium and in contiguous fibrous tissue."

Steiner D12,749/61: A large number of MCs can be demonstrated in the skin of a patient with the carcinoid syndrome by alcian blue preceded by oxidation with potassium permanganate. "Mastocytosis is a clinical parallel to carcinoidosis with hyperproduction of histamine in the former and of serotonin in the latter. The relatively high incidence of mast cells in the telangiectatic skin of carcinoid, at least in the case here reported, adds a further link to the chain of pathogenic relationships between mastocytosis and carcinoid."

Fernex G10,072/64: There is an increase in cardiac MC density in patients with carcinoid or endomyocardial fibrosis due to helminthiasis. It is assumed that the MCs render the cardiac connective tissue particularly subject to inflammation and connective-tissue proliferation in both these diseases.

RHEUMATOID ARTHRITIS, RHEUMATIC FEVER, AND OTHER COLLAGENOSES

Ducci D39,802/46: Arthritis caused by pyogenic microorganisms, unlike the rheumatoid type, is associated with a diminution of the articular MCs.

Hamilton & Syverton D27,526/50: Almost twice the normal number of MCs are found in the hearts of patients with rheumatic fever. In addition, there is much diffuse metachromasia in the connective tissue of such patients and metachromatic granules are also seen in cells with Anitschkow nuclei. Such cells are considered to be modified MCs. "This suggests that degranulation of tissue mast cells with liberation of highly reactive acid mucopolysaccharide, such as heparin, may reflect participation by the host in the pathogenesis of the focal rheumatic process."

Asboe-Hansen B60,604/51: MCs are especially common in various connective-tissues-collagen diseases, including lupus erythematosus.

Nigro D35,450/59: In rheumatoid arthritis and rheumatic fever, the periarticular MCs exhibit degranulation. [The evidence for this statement is very indirect (*H.S.*).]

McCrea D33,729/61: In the bone marrow of patients with rheumatoid arthritis and anemia, MCs were found only in about 50 per cent of the cases and there was no constant relationship between their presence and the response of the anemia to i.v. iron therapy.

Nigro & Pavesio D35,454/62: On the basis of very indirect evidence, the authors assume that the function of the MCs is disturbed in rheumatic fever.

Morozova G9,435/63: The number of MCs in the alveolar septa of the lung is increased in patients with rheumatic fever.

Burns et al. D54,172/63: Biopsies taken from patients with rheumatoid arthritis showed no anomalies in the mast cells or any other histologic feature of the skin.

MACROGLOBULINEMIA (WALDENSTRÖM)

Tischendorf & Hartmann D39,646/50: A case of macroglobulinemia (Waldenström) in which intense MC hyperplasia in the bone marrow was held responsible for the hemorrhagic tendency.

Lennert D63,796/55: In Waldenström's macroglobulinemia, the bone marrow usually contains large numbers of MCs in addition to the small lymphocytes and plasmacells characteristic of this disease.

Jim & Steinkamp C42,786/56: In cases of macroglobulinemia, MC hyperplasia of the bone marrow and lymph nodes may occur but is by no means constant.

Oettgen & Quitmann D39,688/56: MC proliferation is not always evident in Waldenström's macroglobulinemia and its specificity is doubtful since it is also found in other forms of anemia.

Kappeler et al. D39,705/58: A case of macroglobulinemia combined with mastocytosis.

Lennert & Schubert D26,816/59: Tissue MCs are regularly present in the bone marrow of man, irrespective of the terminal disease, but they are especially numerous in cases of panmyelophthisis, lymphadenosis, morbus Waldenström, and mastocytoma.

Lennert & Illert D26,831/59: In macroglobulinemia of Waldenström, the lymph nodes are rich in MCs.

Brinkmann D26,693/62: The bone-marrow MC population is often increased in the macroglobulinemia of Waldenström.

Le Beux & Ganter E22,489/63: In Waldenström's macroglobulinemia, the lymph nodes are characteristically infiltrated by plasma cells, reticulum cells, and MCs.

NERVOUS DISEASES

Rosenheim D26,865/1886: The MC population of the connective tissue in the peripheral nerves is considerably increased in chronic neuritis and other conditions that cause degenerative changes in the nerves.

Neumann D29,310/1890: MCs occur in the human brain under pathologic conditions, for example, in the vicinity of apoplectic cysts or thrombosis and in the foci of multiple sclerosis.

Greggio D31,536/11: In a patient with Recklinghausen's disease, MCs were particularly numerous in the nerve fibromas.

Cornil & Michon D27,444/24: Particularly numerous MCs are found in tissue affected by neurofibromatosis of Recklinghausen. "Either the MCs represent a defense reaction elicited by the tumor or they are part of the special inflammatory process characteristic of this disease."

Michels C72,066/38, *pp. 344–6:* Discussion.

LYMPHEDEMA

Michels C72,066/38, *pp. 344–6:* Discussion.

Ehrich et al. D26,791/49: Microscopic examination of a human scrotum amputated because of elephantiasis, showed numerous "heparinocytes" around lymph and blood vessels. One hundred and twenty-six mg of purified heparin per kg of wet tissue were obtained. Based on the purified material, the scrotum contained at least 16,380 I.U. of activity per kg of fresh tissue. These findings are further evidence that MCs are sources of heparin. They also explain the absence of thrombosis in elephantiasis.

Fernex & Sarasin D39,822/62: Elephantiasis, as a late complication of *Wuchereria bancrofti* and other filarial infections, produces intense cutaneous MC proliferations in the affected regions. "We may conclude that the large population of mast cells of the normal genital skin and breast, increased by helminthic infections, may be the local substratum which makes possible the development of tumorous elephantiasis of scrotum, vulva and breast in cases of filarial infections involving lymphatic vessels."

VARIOUS OTHER DISEASES

Greggio D31,536/11: Certain systemic diseases appear to affect the MC population of the human *ovary* but the observations were not sufficiently numerous to arrive at any generalization.

Vallone D26,432/44–45: Extensive studies on patients who died from various diseases, show that variations in the MC population occur in numerous morbid processes. Yet, curiously, the conclusion is reached that "the possibility that the mastocytes may participate in any pathologic process may be excluded; in fact, it may be said that the mastocytes can exist only in a normal milieu."

Sylvén D33,704/46: Investigations on normal and *pathologic human uteri* showed that "the young growing stroma is poor in mast cells, while on the other hand, older and more highly differentiated stroma connective tissue contains a larger number of mast cells." Diffuse metachromatic staining of the stroma was also most evident in the growing regions.

Baar & Bickel G8,963/52: *Lignac-Fanconi disease* (cystine storage disease with amino-aciduria) may be associated with the presence of numerous MCs within the renal parenchyma.

Consolandi & Briziarelli B84,591/52: Allegedly, characteristic variations in the MC population of the human hypophysis occur during *various* debilitating diseases.

Williams D27,399/52: A systematic study of bone-marrow MCs in man with *various* diseases showed considerable variations but it was not possible to relate them to any particular group of diseases.

Cazal D25,410/55: In a patient with *thrombocytopenia* associated with hypoplasia of the bone marrow, there was a great increase in the MC population of the bone marrow. The author believes that mastocytosis in the bone marrow is a sign of irritation or chronic inflammation.

Lennert D39,800/55: A case of *"mastocytoide osteomyeloreticulose"* with MC proliferation and fibrosis of the spleen, liver, and bone marrow, is accompanied by osteomyelosclerosis.

Danilova D39,771/58: On the basis of histologic studies on the MCs of patients who died from *various* diseases, the author comes to the conclusion that these cells play an important part in the regulation of ground-substance formation.

Togawa D39,528/60–61: Very few MCs are found in the stroma of the healthy human liver but their number is greatly increased in chronic viral *hepatitis,* especially when combined with cirrhosis.

Fiocca & Baroni G19,159/63: In proliferative *"displastic endometriopathies",* the MC count in the uterine stroma is greatly increased, while in the secretory displastic endometriopathies, it is decreased.

Norris et al D68,628/63: "There is no appreciable decrease in the number of mast cells between the fourth through the ninth hours after *death.*"

Teodori et al. G19,161/63: In *Ehlers-Danlos syndrome,* the dermal MCs are often extraordinarily numerous. It is assumed that they may participate in the basic connective-tissue derangement.

Rebuck et al. D58,294/63: "In *Hurler's disease,* the presence of unusual intercellular materials (chondroitin sulfuric acid B and/or heparin monosulfuric acid) leads not only to their ingestion by the histiocytes with the formation of quasimastcells, but, in addition, an unexpected, undue migration of basophilic granulocytes ensues."

DISEASES OF ANIMALS (excluding TUMORS for which cf. *p.* 296.)

Muscular dystrophy in the mouse and hamster

Nixon et al. G7,817/62: In hamsters with a necrotizing (presumably hereditary) myopathy, the muscular lesions were characterized by infiltration with MCs.

Walker & O'Steen D66,467/63: "Using thymidine-H^3 incorporation as a criterion of cell division, mast cells in adult mice show a very low rate of proliferation which may increase sporadically in dystrophic mice." The observations were made on the skin and tongue.

Bois G1,472/64: In the muscles of mice with hereditary muscular dystrophy, the MC counts are above normal.

Walker D19,393/64: In young mice with muscular dystrophy, there was no significant difference in the frequency of MCs in skin, tongue, or muscle when compared to normal littermates. Hence, the increased frequency of MCs reported in adult dystrophic mice is considered to be secondary to the disease and not a causal factor.

Adiposity in the mouse

Hellman E22,484/63: The MCs of the mouse were examined in the epididymal and subcutaneous adipose tissues. "Both with the obesity induced by goldthioglucose and that associated with the American variety of the obese-hyperglycemic syndrome, there was a considerable accumulation of mast cells in the fat depots. While the relative number of mast cells was calculated as 3 per 100 epididymal fat cells in the lean controls, it was more than 50 for the obese-hyperglycemic animals . . . . The greatly increased mast cell content of the adipose tissue in obesity would be consistent with previous work on the rat, in which it was suggested that the lipase activity of the adipose tissue is concerned with accumulation of fat in depots."

Arteriosclerosis in the rat

Wexler D45,267/64: In old breeder rats, the development of arteriosclerotic lesions is associated with a corresponding diminution and degeneration of the cardiac MCs whose granules tend to become orthochromatic. Virgin rats which do not develop arteriosclerosis fail to exhibit such MC changes. [The statistical significance of the variations has not been calculated (*H.S.*).]

8

Biochemistry

THE MCS contain so many biologically-active compounds that they may be regarded as veritable first-aid kits distributed throughout the body. Located at strategic points they release their potent components into the surrounding tissues or the blood stream to satisfy diverse local or systemic requirements.

Among the most intensely studied and, as far as we know, the most important components of the MCS are heparin, histamine, 5–HT, and a great variety of enzymes. The MC granules also tend to attract a variety of metals (iron, calcium, zinc, etc.) and presumably certain organic substances which reach them from the blood and tissue fluids and become bound to them ("mastopexis") without representing products of their own synthetic activity. It is well to distinguish, therefore, between those products that are made by the MCS and those that are merely stored by them; while all these compounds are MC constituents, only the former can be called MC products.

In this chapter, we shall deal with all those constituents of MCS that have been identified by chemical means — irrespective of whether they are endogenous products of these cells or not — since in many instances it is impossible to ascertain whether a constituent was actually made by the MC or merely ingested by it. Indeed, there is reason to believe that a given compound can be both synthesized by the MC and taken up into its cytoplasm from the surroundings. To obtain a good overview of the field, the biochemistry of normal and morbid MCS, as well as the chemical changes induced in them by diverse experimental procedures, will be discussed conjointly.

HEPARIN AND RELATED MUCOPOLYSACCHARIDES

[Cf. also THEORIES (*p.* 365) for interpretation of MC-heparin determinations.]

It was the great merit of Jorpes and his coworkers to have first shown that there is a good correlation between the MC density in various *normal tissues* of different animal species and their heparin content. Subsequent work revealed that granules and heparin are simultaneously discharged from the hepatic MCS of the dog during peptone shock. Finally, the chemical properties of MC granules (including their ability to stain metachromatically with basic analine dyes) proved to be virtually identical with those of heparin. Hence, it was concluded that the metachromatic substance is actually heparin; indeed, there is reason to believe that the MCS are the only source of heparin in the animal organism.

Heparin could be prepared from *normal* MCS and it is estimated that they store approximately $30\mu g/mm^3$ of tissue and that each individual MC contains

about 20$\mu\mu$g. The polysaccharide fraction of rat and mouse peritoneal MCs is said to contain 80–100 per cent heparin but no hyaluronic acid.

Isolated mast cell granules can be obtained from tissues rich in MCs by various techniques of differential centrifugation. Early investigations suggested that heparin is contained in the microsome fraction of the intergranular cytoplasm but recent studies indicate that it is located within the metachromatic granules themselves while the mitochondria are devoid of it.

In *human mastocytoses,* stimulation of the skin lesions may cause an increase in blood heparin but this was not consistently found to be the case. Occasionally, large amounts of heparin could be demonstrated in the skin lesions of urticaria pigmentosa. The variability of these findings led to the assumption that heparin may be present here in the form of an inactive precursor which requires activation (or the removal of an inhibitor) before it can interfere with blood coagulation. Metachromatic material is sometimes demonstrable in the urine of patients with mastocytosis but some investigators believe this to be chondroitin sulfate rather than heparin or uroheparin.

Animal mastocytomas, such as occur in dogs and mice, sometimes contain extraordinarily large amounts of heparin and heparin precursors. The sulfuric acid groups of this material can be labeled with S^{35} and this reaction is accelerated by the addition of DPN in vitro. The soluble fraction of murine MC tumors catalyzes the incorporation of inorganic sulfate into heparin but only in the presence of ATP. Labeled glucose and sulfate are converted by murine MC tumor slices into a mucopolysaccharide indistinguishable from heparin. However, in addition to heparin, murine mastocytomas possess glucosamine- and galactosamine-containing polysaccharides of different sulfate content.

The heparin concentration of MCs has also been investigated *following experimental interventions* which affect these cells. The most important outcome of this line of investigation was to show that various stimuli (peptone shock, treatment with histamine-dischargers) which liberate the metachromatic granules from MCs, simultaneously release heparin into the circulation. However, such a parallelism between MC discharge and heparin liberation does not occur uniformly in all species; furthermore, heparin and histamine are not always released together. For example, in rats treated with 48/80, almost all the histamine but only about 50 per cent of the heparin is discharged from the skin; the blood-clotting time remains normal, and no metachromatic material appears in the urine. It was assumed that some of the heparin may be disposed of by the tissues at the site of its liberation, or that the MCs contain an inactive precursor of heparin which would be activated by chemical extraction but not by a simple in-vivo destruction of the granules. Following its injection into connective tissue, heparin is phagocytosed by fibroblasts and macrophages which then assume an MC-like appearance. It is possible, therefore, that MCs can not only produce heparin but also store preformed heparin when it is brought in contact with them (cf. *p.* 184).

Several investigations have shown the possibility of *histamine and 5–HT binding by heparin* in vitro. Heparin has a greater affinity for histamine than 5–HT. Only 4 mg of heparin are required to bind 1 mg of histamine but 15 mg of heparin are necessary to bind 1 mg of 5–HT. According to recent investigations, zinc is necessary as a bridge between heparin and histamine for such complex formation. Histamine heparinate (assumed to be the usual storage form of histamine in MCs) has

no anticoagulant properties. If, under certain conditions, heparin were released in this bound form, this could explain the often-observed and much-discussed dissociation between MC discharge and diminished blood coagulability.

Reviews: *Jorpes* D44,643/46
Asboe-Hansen D27,999/54
Baglioni C16,539/54, *pp. 158, 163, 185, 210*
Studer C6,137/54
Riley C9,303/55; C70,315/59, *pp. 28, 137*
Arvy D65,673/56
Brodeur & Gardner C21,475/56
Fulton et al. C35,831/57
Anonymous E4,459/59
West C64,139/58; D65,259/59
Anonymous D29,286/60
Macaluso & Pasqualino D5,225/60
Jaques D26,299/61
Smith D63,031/63
Benditt & Lagunoff G10,074/64

IN NORMAL TISSUES

Charles & Scott D31,555/33: "The presence of a blood anticoagulant, presumably heparin, has been demonstrated in various tissues. It was found in greatest quantities in muscle, liver and lung. Much smaller quantities were obtained from heart, thymus, spleen, and blood. Dog liver contains approximately twice as much heparin as does beef liver." A relationship to MCs is not yet suspected.

Holmgren & Wilander D26,887/37; *Jorpes et al.* D26,888/37; *Jorpes* D27,887/38: Comparative estimations of the MC-density and the heparin content in the liver, spleen, and the lung of the cow, calf, sheep, pig, horse, dog, rabbit, and the rat show a remarkable parallelism between metachromatic granule and heparin content. The chemical properties of the MC granule and of heparin are likewise virtually identical and, hence, it is concluded that the metachromatic substance is actually heparin.

Jorpes D26,965/39: MCs are thought to contain heparin because of their metachromatically-staining granules, the good correlation between MC count and heparin content in various tissues and the fact that heparin- and MC-discharge occur concurrently during peptone shock in the dog.

Snellman et al. D27,734/48: Potassium thiocyanate is especially effective in extracting heparin and metachromatic material from the MCs of ox liver, skin, and other tissues.

Veil & Quivy D10,146/50: The scales of the carp contain numerous MCs and considerable amounts of heparin can be extracted from them.

Sundberg et al. D26,731/54: Hyaluronidase does not alter the granules in the MCs of Wharton's jelly. Aqueous extract of umbilical cord and of placenta have anticoagulant activity. "The initial antithrombic substance was not, however, neutralized with dilutions of protamine that were adequate to neutralize equally antithrombic solutions of heparin."

Parratt & West C19,991/56: In various tissues of the rat (ear, skin, spleen), the heparin content remarkably parallels MC density.

Freeman et al. D29,475/56: MC counts and heparin determinations were performed on various organs of rats and rabbits. Only in a few instances did these two determinations follow a similar trend.

Mergenthaler & Paff D27,407/56: The heparin content of the peritoneal fluid in the rat is approximately 9 times that of blood. This is additional proof in favor of the heparin production by MCs, which are likewise numerous in rat peritoneal fluid.

Padawer D30,194/57: Rat peritoneal fluid will clot readily if contaminated with tissue juices, despite its richness in MCs. It is possible, however, that the MC polysaccharides are not released and physiologically available to interfere with coagulation under these conditions.

Marx et al. C28,984/57: Tissue heparin contents and MC counts were determined on liver, lung, intestine, kidney, spleen, and thymus of male rats and rabbits. "In most instances, distribution of heparin and mast cells did not follow the same pattern. Rat organs showed higher heparin values, but lower mast cell numbers than the corresponding rabbit tissues."

Parekh & Glick D27,898/62: Procedure for the analysis of heparin by azure-A binding in the peritoneal MCs of the rat.

Jorpes E4,171/63: Personal studies and a review of the literature lead to the conclusion that "the mast cells are evidently the only source of heparin, which is stored as metachromatic granules." However, heparin is not only stored but also synthesized by the MCs, since labeled sulfate is incorporated into MC-heparin.

IN NORMAL MAST CELLS

Benditt et al. D31,573/56: On the basis of estimations on isolated rat peritoneal MCs, it is concluded that these cells contain approximately 30 μg of heparin per mm^3 of tissue.

Schiller & Dorfman D63,194/59: Isolation of heparin from normal rat peritoneal MCs.

Bloom E22,677/60: In MCs of the rat or mouse peritoneum, isolated by density-gradient centrifugation, "heparin was found to be the major mucopolysaccharide present in these cells and an estimate of the amount of this substance in individual cells gave values around 20 $\mu\mu$g." The yield of polysaccharide from MC tumors was about 1 mg/g wet tissue, but in addition to heparin they also contained other mucopolysaccharides.

Bloom & Ringertz D39,808/61: The polysaccharide fraction of rat and mouse peritoneal MCs is said to contain 80–100 per cent heparin and no hyaluronic acid.

Schiller D58,281/63: Heparin has been isolated from normal rat peritoneal MCs and from rat skin.

ISOLATED MAST-CELL GRANULES

Julén et al. D26,818/50: On the basis of cytologic studies and differential centrifugation of suspensions of ox liver-capsule MCs, it is concluded that the large MC granules do not contain heparin but presumably protein, lipids, and enzymes. They are basophilic. The easily water-soluble metachromatic and oxyphilic anticoagulant is thought to be located in the intergranular cytoplasm, "and is provisionally regarded as a microsome structure." The anticoagulant is thought to be present as a heparin-protein complex.

Snellman et al. D27,963/51: The native heparin-containing compound was extracted from the hepatic capsule MCs of the ox. The lipoprotein part, associated with the carbohydrate moiety, was further analyzed as to its chemical composition. On the basis of indirect evidence, it is assumed that the whole heparin complex is produced in the intergranular cytoplasm of MCs.

Sylvén D31,551/51: Separation by ultracentrifugation of various fractions from ox-liver capsules (which are rich in MCs) suggests that heparin is contained in a nonsedimentable solute in the final supernate, presumably dissolved from the microsome fraction.

Köksal B93,664/53: Comparatively large amounts of heparin-like anticoagulant can be extracted from isolated subcutaneous MC granules of normal mice.

Sylvén C77,656/57: Detailed investigations on the cytoplasmic constituents of tissue MCs by the freeze-vacuum dehydration technique and carefully-controlled differential centrifugation method, led to the view that native heparin material is located as part of the microsomal substance within the intergranular compartment that surrounds the basophilic granules. The fractions, showing metachromasia, are those that contain heparin but they are eosinophilic, perhaps because they are attached to basic protein.

Hagen et al. C70,407/59: Electron-microscopic studies of mouse mastocytoma cells, combined with ultra-centrifugation and biochemical as well as bioassay analysis of its particles, led to the conclusion that "histamine, heparin and 5-hydroxytryptamine are contained within specific granules which are clearly separable from mitochondria and other intracellular organelles."

Hagen D2,370/61: Excellent review concerning evidence obtained by electron microscopy and differential centrifugation showing that the MC granules contain heparin, histamine, and 5-HT but are devoid of such characteristic mitochondrial enzymes as fumarase, amine oxidase, and succinic dehydrogenase. The reverse is true of mitochondria.

IN HUMAN MASTOCYTOSES

Asboe-Hansen D39,743/50: Two cases of urticaria pigmentosa haemorrhagica, with the accumulation of melanotic and iron pigment in the skin. The hemorrhages may have been related to heparin production by MCs.

Caccialanza & Campani D39,701/51: A heparin-like anticoagulant is present in the MCs of urticaria-pigmentosa skin. However, unlike "complete heparin," this substance does not inhibit hyaluronidase.

Drennan D26,722/51: In urticaria pigmentosa, the MCs contain considerable amounts of heparin monosulfate which they rapidly discharge upon stimulation of the lesions. In normal tissues of man and rat, many of the MCs contain heparin at a higher level of esterification than the monosulfate and it is thought that in urticaria, full development of heparin

is prevented by the continuous stimulation to which the MCs are subjected. Since edema produced in various ways elicits MC degranulation, "it is concluded that in urticaria pigmentosa, local tissue oedema provides the stimulus for mast cell secretion."

Sagher et al. D10,437/52: Cantharidin blisters prepared over normal and affected areas of the skin in urticaria pigmentosa showed no essential difference as regards their heparin content.

Konrad & Winkler D26,875/53: In a case of bullous urticaria pigmentosa, the cutaneous vesicles contained an anticlotting substance, presumably heparin.

Cordero G1,709/54: In a case of urticaria pigmentosa, no anticoagulant activity could be demonstrated either in the blood or in the skin.

Urbach et al. D39,652/54: Mechanical stimulation of the skin lesions in a patient with urticaria pigmentosa resulted in an increase of blood heparin. This increase could be largely suppressed by desoxycorticosterone treatment.

Drennan & Beare D26,760/54: Large amounts of heparin were found in a solitary MC nevus.

Cornbleet D26,740/54: "Two biopsy specimens, taken at different times from one patient with the acquired form of urticaria pigmentosa, yielded extracts incapable of prolonging the coagulation time of blood. The coagulation time of the patient's blood, after rubbing a large area of his skin with the production of whealing, was not longer than that of the sample drawn before rubbing. The conclusion seems warranted that heparin (or similar substances) in the mast cells of the lesions is in a form needing activation or that an inactivating substance interferes with its blood-anticoagulating action."

Urbach et al. D39,716/55: "An increase in the titrable heparinoid activity of serum has been demonstrated in six of eight patients with urticaria pigmentosa following brisk generalized rubbing with a towel."

Waters & Lacson D39,669/57: A case of MC-leukemia with a hemorrhagic type of urticaria pigmentosa and diffuse infiltration of various organs with MCs. There was a hundredfold increase in the histamine and "heparin" content of the liver, but the blood-clotting time was normal, despite a prolonged bleeding time.

Loewenthal et al. D39,620/57: Hepatosplenomegaly with diffuse MC-infiltration of the spleen, liver, and bone marrow as well as effusions into the pleural and peritoneal cavities may occur in urticaria pigmentosa.

Gardner & Tice C52,326/58: The liver and spleen of a child with urticaria pigmentosa contained large amounts of a substance resembling mucoitin sulfuric acid (possibly heparin).

Ende & Cherniss D39,554/58: In a case of isolated splenic mastocytosis, the heparin content of the spleen was increased.

Herzberg D39,565/59: Discussion.

Meneghini & Levi D27,702/60: In the skin lesions of patients with urticaria pigmentosa, there is no increased heparin activity, although the histamine content is greatly augmented and proportional to the local MC count.

Bloom et al. D8,351/60: In a man with malignant systemic MC disease, severe bone changes were associated with an increased histamine and heparin content in the mastocytoma tissue itself, as well as in the blood and urine.

Vilanova et al. D26,651/61: In a 9-month-old child with nodular urticaria pigmentosa, biopsy produced very severe bleeding which was due to the presence in the blood of a heparin-like anticoagulant factor.

Stüttgen et al. D26,860/62: An antithrombin substance could be demonstrated in the skin and the cutaneous vesicular fluid of patients with mastocytosis.

Fernex D39,200/62: The heparin content of the skin is greatly increased in urticaria pigmentosa.

Mutter et al. E36,471/63: In a case of generalized mastocytosis the urine contained a fraction, presumably corresponding to heparin sulfate.

Asboe-Hansen & Clausen E37,788/64; F16,673/64: Paper-electrophoresis of urinary concentrates from patients with urticaria pigmentosa revealed the presence of chondroitin sulfate and a chemically-changed (depolymerized?) hyaluronic acid, but no heparin.

Piper & Würbach F10,290/64: The urinary elimination of metachromatic material (toluidine-blue test) is greatly increased in patients with urticaria pigmentosa. Chromatographic studies suggest that the eliminated material is chondroitin sulfate rather than heparin or uroheparin.

IN ANIMAL MASTOCYTOMAS

Oliver et al. D26,764/47: In spontaneous mastocytomas of dogs, "the heparin content was large (50 times that of dog liver) in the growth with mature cells and only moderate (1.7 times) in that with immature cells. Since there may be a great amount of greyish particulate matter (or fine-stained granules) in a tumor of relatively low heparin content, it is suggested that this material represents an early or precursor phase in the development of heparin."

Asboe-Hansen B85,960/53: Histochemical studies in mice treated with 9,10-dimethyl-1,2-benzanthracene showed that "the granules of the connective tissue mast cells contain a sulfuric mucopolysaccharide. This substance is closely related to heparin and hyaluronic acid without being identical with either. Stripping-film autoradiography of connective tissue in experimental skin tumors in mice injected intraperitoneally with S^{35} using sodium sulfate as carrier, showed that the majority of the mast cells take up sulfur."

Cass et al. D26,776/54: Large amounts of both histamine and heparin are found in mastocytomas of dogs.

Magnusson & Larsson D26,475/55: Heparin has been obtained from a dog mastocytoma and it was shown that the sulfuric-acid groups of this heparin can be labelled with S^{35}.

West C19,992/56: Mastocytomas of dogs are very rich in heparin.

Korn E90,065/58: "1 gm of wet weight mouse mast cell tumor contains 1–2 mg of heparin determined by metachromatic and carbazole assays."

Korn D65,340/58: Slices of mouse mastocytoma "were incubated with either C^{14}-glucose or S^{35}-sulfate, and heparin of relatively high purity isolated."

Ono et al. D27,408/59: The transplantable mastocytomas of LAF_1 mice contain as much or more histamine, heparin, and 5–HT as any mammalian tissues so far examined.

Korn D63,167/59: In mouse mastocytomas, "most of the heparin is contained in particles which are sedimented by centrifuging at 10,000 × g for 10 minutes." Heparin could be released from these particles by any of several mild procedures. No evidence was found for the existence of a firmly-bound heparin-protein complex.

Korn D39,642/59: "It has been demonstrated that C^{14}-glucose and S^{35}-sulfate are converted by mouse mast cell tumor slices into a mucopolysaccharide indistinguishable from heparin."

Korn D65,268/59: "The soluble fraction of [murine] mast cell tumors catalyzes the incorporation of inorganic sulfate into heparin. This reaction has an absolute requirement for adenosine triphosphate, and phosphoadenosylphosphosulfate has been implicated as an intermediate."

Padawer D30,206/59: Since the granules of some mouse mastocytoma cells do, while others do not, stain metachromatically, "one should be cautious in equating them to each other or to normal mast cells in biochemical or physiological studies."

Rodén & Dorfman D65,652/59: Heparin and a fraction with low sulfur content, similar to heparin monosulfuric acid, has been extracted from the Furth type of mouse mastocytoma.

Day & Green C66,290/59: Murine neoplastic MCs maintain their intracellular levels of heparin in tissue culture.

Spolter & Marx D65,505/60: Paper-chromatographic analysis of mouse mastocytoma heparin, in comparison with heparins of other sources.

Ringertz D63,189/60: "Polysaccharides prepared from two mast cell tumors in mice were fractionated by chromatography on ECTEOLA cellulose. Both tumors contained heparin and also large quantities of other polysaccharides."

Ringertz E22,676/60: Transplantable mouse mastocytomas contain, in addition to heparin, a series of glucosamine- and galactosamine-containing polysaccharides of different sulfate content.

Ringertz & Bloom D39,806/61: In dog mastocytomas, about 70 per cent of the polysaccharide fraction is heparin, while the remainder is a nonsulfated fraction containing both glucosamine and galactosamine.

Mengel & Trier D3,888/61: The P–815 MC-ascites tumor of the mouse is rich in histamine and heparin. By in-vitro cloning, it is possible to develop morphologically-recognizable stable sublines of this tumor with differential levels of 5–HT and histamine.

Green & Day D58,290/63: The heparin in murine neoplastic MCs maintained in vitro has an infrared spectrum different from that of bovine heparin.

Green D69,722/63: "Thus the major portion of the ^{35}S-heparin is catabolized by the cells to dialyzable material and, in addition, a small portion, representing only one of the components of intracellular heparin, is eliminated into the medium. This latter component, which is nitrogen-rich, may be heparin in association with the cytoplasmic granules, which appear to be extruded from normal mast cells."

Spolter et al. D62,371/63: The incorporation of S^{35}-sulfate into heparin precursors of mouse MC-tumor homogenates is accelerated by the addition of DPN in vitro.

Green et al. E20,594/63: Separation of sulfomucopolysaccharides from murine mastocytomas.

Ringertz D58,282/63: "The polysaccharide content of normal and neoplastic mast cells was studied with biochemical techniques. Normal mast cells from mice and rats were found to contain heparin, but no other acid polysaccharides. Solid mast cell tumors of mice, in addition to heparin, housed chondroitin sulphate-like polysaccharides. An ascites subline of the Furth tumor contained only very small amounts of galactosamine-containing polysaccharides. It therefore cannot be excluded that the chondroitin sulphate found in the solid tumors derived from non-neoplastic connective tissue cells present in the solid tumor, but not in the ascites subline. Two dog mastocytomas were found to contain heparin and some non-sulphated polysaccharide material."

Silbert E32,901/63: Demonstration of the incorporation of ^{14}C and ^{3}H from nucleotide sugars into a polysaccharide in the presence of a cell-free preparation from mouse MC tumors leads to the suggestion that the resulting unusual polysaccharide may be a precursor of heparin.

Rice et al. F5,316/64: By ultracentrifugal separation, subcellular fractions can be obtained from murine mastocytomas which are capable of incorporating sulfate into heparin.

IN OTHER DISEASES

Ehrich et al. D26,791/49: Microscopic examinations of a human scrotum, amputated because of *elephantiasis,* showed numerous heparinocytes around lymph and blood vessels. One hundred and twenty-six mg of purified heparin per kg of wet tissue were obtained. Based on the purified material, the scrotum contained at least 16,380 I.U. of activity per kg of fresh tissue. These findings are further evidence that MCs are sources of heparin. They also explain the absence of thrombosis in elephantiasis.

Hjelmman E20,253/56: In various forms of *obliterating vascular diseases* of man, the MC count in the vascular wall increases. The response is considered to be a defense reaction against further clotting.

FOLLOWING EXPERIMENTAL INTERVENTIONS

Jaques & Waters B40,648/41: By means of the protamine titration procedure, it is shown that, during anaphylactic shock, the dog liberates large quantities of heparin into the blood, that this heparinemia does not occur in hepatectomized dogs, and that concurrently with shock symptoms in the normal animal, the heparin and MC content of the liver decreases acutely.

Frick B62,124/50: Following i.p. injection of heparin, the mesenteric MCs store metachromatic granules while similar treatment with thrombokinase causes MC-discharge, accompanied by urinary excretion of a metachromatic substance, presumably heparin.

Lecomte & Baeckeland B93,844/53; *Baeckeland & Lecomte* D27,995/53: Serial biopsies of the liver, performed during the development of peptone shock in the dog, showed no histologically-demonstrable change in the MCs, although pronounced heparinemia developed. These findings are in contradiction to earlier observations of Wilander (D29,595/38), but the authors do not deny the possibility of heparin production by MCs, they merely insist that the liberation of heparin need not be accompanied by morphologically-detectable MC-alterations.

Fulton & Maynard D27,953/53: Following disruption of MCs in cortisone-injected hamsters, the blood coagulation time was actually shortened during the first two weeks but increased above normal after the 21st day. "This might indicate a delay between the time of disruption of mast cells and the appearance of a significant increase in circulating anticoagulants."

Turchini & van Kien D26,718/53: Heparin can be demonstrated in the MCs both of the rat and the mouse. During peptone and anaphylactic shock, heparin and MC granules are concurrently discharged.

Mota et al. D26,758/54: Shock induced by i.v. injection of peptone in the dog, is associated with depletion of the MCs in the liver, tongue, spleen, mesentery, lung, and other organs. The few remaining intracellular granules tend to lose their metachromasia. The concomitant decrease in blood pressure and blood coagulability is ascribed to degranulation of the MCs, "mast cells of other organs also present alterations, suggesting that in the dog, heparin and histamine might originate from other organs besides the liver."

Riley et al. D27,737/55: Following repeated i.p. injections of 48/80, wide-spread MC degranulation occurred in the subcutis of the rat with almost complete loss of its histamine content, while the heparin content of the skin decreased only by 50 per cent and even this loss was unaccompanied by any sign of heparin release: the clotting time remained normal and no metachromatic material appeared in the urine. As judged by the literature, some heparin may be disposed of locally by macrophages, some may adhere to adjacent connective-tissue fibrils or cells, and some may be bound by the basic histamine liberator itself. Perhaps "the function of heparin may be concerned rather with events in the tissues than with the coagulability of the circulating blood."

Parratt & West C19,991/56: When the MCs of the ear are destroyed by repeated i.p. injections of 48/80, the heparin content of the ear drops sharply, while that of the spleen (which contains virtually no MCs) remains unchanged.

Hjelmman & Wegelius E20,252/56: The cardiac MCs increase in number both in the toad (*Bufo bufo*) and in the frog (*Rana temporaria*) upon exposure to low surrounding temperatures. On the other hand, the hepatic MC count rises only in the toad and not in the frog, upon exposure to cold. The mastocytosis is interpreted as a defensive measure against threatening blood coagulation.

Lacaz et al. C33,366/57: CCl_4-intoxication increases the heparin content of the rat liver simultaneously with a local mastocytosis.

Braunsteiner et al. D27,986/57: Massive degranulation of MCs induced by histamine-liberator diaminodecan i.v. in the rat, is not accompanied by any change in blood coagulation time. Either MCs contain an inactive precursor of heparin (which would be activated by chemical extraction but not by a simple in-vivo destruction of the granules) or heparin in the rat may be bound to a carrier which antagonizes its effect upon blood clotting. [However, in some species, MC discharge is associated with delayed blood coagulability, e.g., in the dog after peptone shock (*H.S.*).]

Guimaraes & Taylor D26,762/57: In rats treated with radioactive gold, the bone-marrow MCs are increased in number and size. The possibility is considered that the post-irradiation syndrome of prolonged blood-clotting time, with increased heparin production, may be related to this change in the bone-marrow MC population.

Marx et al. D26,895/60: Hypophysectomy caused a significant elevation of the mast-cell numbers in liver, lung, and kidney, but not in the spleen. The thymus showed a trend toward increased values. "The heparin contents of the organs examined were not significantly modified by the operation; the kidneys exhibited a trend toward higher values."

Archer D26,441/61: When the isolated peritoneal MCs of the rat are disrupted by freezing and thawing, 48/80, distilled water, an antigen-antibody mixture consisting of human erythrocytes and fresh rat antiserum, or by mechanical trauma, heparin is liberated into the medium only in case the disruption is induced by the freezing-thawing technique. Microscopic examination showed that, although the MCs were disrupted with all the techniques used, the granules themselves underwent disruption only following treatment by repeated freezing-thawing. "It may be concluded that the antithrombin present in rat mast cells is not released into the surrounding solution following disruption of these cells in vitro unless the granules are also disrupted. This is in contrast to the results with histamine, which is known to be released from disrupted rat mast cells even though the granules remain intact".

Riley D26,692/62: 48/80 activates the connective tissue of the rat in the immediate vicinity of its injection. "The fixed mesenchymal cells become plump, granular, basophilic, and finally amoeboid until the affected area comes to resemble a vigorously growing tissue-culture." This local response can be reproduced when a mixture of histamine and heparin is injected directly into the peritoneal cavity or subcutaneous tissue of rat or mouse. Moreover, it can even develop in animals which have been freshly killed just prior to the injection. Since it is known that metachromatic material, discharged by mastocytes under the influence of 48/80, is subsequently ingested by fibroblasts, the theory is formulated that histamine facilitates the

entry of heparin or mast-cell granules into the mesenchymal cell, which then forms fresh mucopolysaccharide of its own. This response may have a defensive value in inflammation."

Baeckeland D30,918/62: If heparinized plasma is placed in contact with rat peritoneal MCs in vitro, the latter do not degranulate but they lose their granules and their nucleus disintegrates upon the addition of thrombin. It is concluded that the MCs undergo degranulation during blood coagulation which is additional evidence of their participation in this process.

West D33,712/62: Only in the dog is MC degranulation (induced by 48/80 or peptone) associated with a sufficient heparin discharge to render the blood incoagulable. "Where does the released heparin disappear to in the rat?" Presumably some of it is disposed of locally by macrophages ingested by connective-tissue cells and bound to the histamine liberator itself. Apparently, both histamine and 5–HT act primarily on connective tissue, stimulating the phagocytosis and digestion of metachromatic material released by nearby MCs. The fibroblasts are thereby stimulated to produce mucopolysaccharides and thus assist in the formation of extracellular ground substance. In the rat, "intense activity in the mesenchyme may be produced locally by injecting a mixture of histamine and heparin but not by histamine alone. Wound healing, as measured by tensile strength, is stimulated by locally administered heparin which, among other things, may neutralize the action of local adrenal corticoids."

HISTAMINE AND 5–HT BINDING BY HEPARIN

Parrot & Laborde B74,584/51: Addition of heparin to a histamine solution diminishes the biologic activity of the latter. Dialysis shows a quantitative binding of the two compounds.

Werle & Amann D26,786/55; C18,291/56: On the basis of chemical and physicochemical studies concerning the behavior of MC granules, it is concluded that the "histamine of the mastocytes and, hence, by far the major portion of tissue histamine, is present in the form of a heparinate."

Amann & Werle D31,582/56: In-vitro experiments show that heparin binds histamine and other di- and poly-amines. It is postulated that in the MCs, histamine is present as a heparinate and that histamine-dischargers act upon MCs by replacing histamine in its combination with heparin.

Bloom et al. D39,809/58: On the basis of a literature survey and personal observations, it is concluded that "heparin and histamine may form a complex in which histamine preserves its physiological effects while heparin loses its effect on the coagulation of blood."

Paton D39,576/58: Review of the literature concerning the manner in which histamine is bound in the tissues. It has been thought to be bound: (1) by peptide linkage from which it can be detached by proteolytic enzymes; (2) by an ionic bond with a tissue acid such as heparin, nucleic acid, or ATP but neither of the theories has been definitely proven.

Keller D55,000/58: Displacement and dialysis tests show that the affinity of histamine to heparin is greater than that of 5–HT to heparin; approximately 4 mg of heparin are required to bind 1 mg histamine, and 15 mg heparin to bind 1 mg of 5–HT. Histamine, and particularly 5–HT, are loosely bound to heparin, which would explain that minor changes in the surroundings such as freezing and thawing, or hypo- and hypertonic solutions liberate these amines. The repeatedly-observed anti-allergic effect of heparin might also find its explanation in this phenomenon.

Kerp & Steinhaeuser E24,263/61: Chemical studies revealed that heparin can bind histamine even at a near physiological *p*H in the presence of zinc which acts as a bridge between the two organic compounds.

Schauer & Eder D30,202/62: Histochemical studies on rat MCs suggest that the granules contain a "salt-like heparin-histamine union."

HISTAMINE AND RELATED COMPOUNDS

[Cf. also THEORIES (*p.* 366) for interpretation of MC-histamine determinations.]

Riley and West were the first to note that a striking parallelism exists between the histamine and MC content of various *normal tissues* in many species. They found, furthermore, that MC tumors are exceptionally rich in histamine, and that histamine-liberators which deplete the MCs also diminish tissue histamine. Still,

there are exceptions. Hog pyloric submucosa contains about four times as much histamine as could be accounted for by its MC population. In the rat, the fundic region of the stomach and the duodenum are rich in histamine and yet poor in MCs. Even in species whose MCs contain 5–HT in addition to histamine, the two compounds do not always run parallel. In the rat, histamine and MCs are concentrated in the inner layer of the skin, whereas 5–HT is chiefly in the outer layer. Similarly, the skin of the footpads contains fewer MCs and less histamine but more 5–HT than the dorsal skin. In fetal rat tissues, histamine appears before MCs. According to prevalent contemporary opinion, it may be concluded that most but not all of the body's histamine is in MCs.

Studies on isolated *normal mast cells* confirmed their high histamine content. It is estimated that individual MCs contain approximately 7–32 $\mu\mu$g of free histamine base.

In relatively pure fractions of *isolated mast cell granules*, obtained by differential centrifugation of rat subcutaneous tissue, the histamine content was so high as to account for most of the base in the subcutis. This observation has been confirmed on other species and it could be shown that upon destruction by various means, the isolated MC granules release their histamine. Electron-microscopic studies also support the assumption that histamine (like heparin and 5–HT) is contained within the specific granules which are clearly separable from mitochondria and other intracellular organelles by ultracentrifugation.

In *human mastocytoses,* the specific skin lesions are very rich in histamine; simultaneously the concentration of histamine in the blood and urine may be considerably elevated. In the skin lesions of some patients with urticaria pigmentosa, as much as 2 mg/g of histamine were found, as compared with 5.3–18.4 μg/g in normal skin. In one patient as much as 600 μg of histamine were found in a 24-hour urine collection. Radioactive histidine is transformed to histamine by homogenates of urticaria pigmentosa skin as a consequence of histidine-decarboxylase activity.

In *animal mastocytomas* (dog and mouse), the histamine concentration is likewise very high; in one canine mastocytoma it reached 1290 μg/g, the highest concentration ever described for a tissue. Upon incubation with radioactive histidine, canine mastocytoma tissue synthesizes histamine through histidine-decarboxylase activity. This is additional evidence that MCs can not only store but can also form histamine. Murine MC-leukemia cells maintain their high histamine content even in tissue culture.

Following *experimental interventions,* which discharge the granules from the MCs, the histamine is also released. This parallelism between the discharge of granules and histamine from MCs is found not only after treatment with ovomucoid, dextran or 48/80 in the rat skin, but also during peptone shock in the liver and tongue of the dog. Anaphylactic histamine liberation, following antigen-antibody reaction in vitro, often likewise corresponds quite closely to the MC depletion in various organs.

Yet, as we have said, not only the MCs contain histamine; there is also a relatively high concentration of *histamine in the leukocytes and platelets* of various species. The platelets appear to contain much histamine only in the rabbit but the basophil leukocytes are rich in histamine in most vertebrates, including man. The eosinophils and neutrophils do not appear to contain appreciable amounts of this amine.

We have already alluded to the decarboxylation of histidine and there is considerable evidence of *histamine synthesis by* MCs. Apparently, virtually the whole histidine-decarboxylase activity is concentrated in the MCs.

Reviews: *Asboe-Hansen* D27,999/54
Feldberg D31,609/54
Riley C53/54; C9,303/55; D30,582/56; D30,562/56; C70,315/59
Paton D39,572/55; D27,354/57 *pp. 283, 316*
Blaschko C34,533/56
Brodeur & Gardner C21,475/56
Fulton et al. C35,831/57
Padawer D30,194/57
Kelsall & Crabb D26,076/59, *pp. 123, 139*
West D65,259/59
Macaluso & Pasqualino D5,225/60
Hagen D68,493/62
Smith D63,031/63
Benditt & Lagunoff G10,074/64
Code et al. G18,722/64

IN NORMAL TISSUES

Cazal D39,786/42: First suggestion of some relationship between histamine and MCs.

Riley & West D39,656/52; B96,668/53: A strong positive correlation is found between the histamine and MC content of various organs. Mast cells are especially numerous in the liver capsule of ox and sheep and in ox pleura, all of which are especially rich in histamine. Adult organs, rich in MCs, yield higher values for histamine than immature organs which are poor in MCs. Mast-cell tumors are exceptionally rich in histamine. Treatment with histamine-liberators, which deplete the MCs, also diminish the histamine content of tissues.

Graham et al. D26,780/55; *Boréus & Chakravarty* D26,646/60: Histologic study of various nerves from cattle, cat, rabbit, rat, and guinea-pig show a striking correlation between the MC count and the histamine content. "The results support the view that the main part — if not all — of the histamine is present not in the nerve fibers but in the mast cells." It is calculated that, if all the histamine in the nerve tissue is stored in the MCs, each cell contains approximately 30 $\mu\mu$g of the amine (*Torp* D27,063/61). This figure is in good agreement with values for the histamine content of MCs in other tissues.

Benditt et al. C13,402/55: There is an excellent correlation between the MC count and histamine content in various tissues of the rat. Furthermore, during the anaphylactoid inflammation, the discharge of MC granules parallels the loss of tissue histamine.

Arvy & Quivy D27,872/55: In the dog, the esophagus and colon are relatively poor in MCs while the stomach and duodenum contain many of them. This distribution roughly parallels the histamine content of these intestinal segments and constitutes additional proof of the presence of histamine in MCs.

Riley & West C29,554/56: MCs are numerous in the abdominal skin of the guinea-pig, rabbit, dog, cat, mouse, rat, and man. The histamine content of various skin layers is roughly parallel with the regional MC density.

West C19,992/56: The histamine and MC content of various organs in several species show a surprising degree of parallelism. The results of these "studies leave no doubt that the mast cell is exceptionally rich in histamine and that in many instances the total histamine content of an organ can be accounted for in this way."

Parratt & West C19,991/56: In various tissues of the rat (ear, skin from various regions, spleen) the histamine concentration remarkably parallels the MC density.

Riley & West D27,968/56: Although in most locations the MC and histamine content of tissues, including the hog pyloric submucosa, run parallel, this is not true of the mucosa in this species. (Cf. also *Paton* D39,576/58.) Here, the histamine content is about four times that accountable for by the MC population. "We have a good reason for believing that the histamine in the submucosa is due to its high content of mast cells; hence, it is clear that something other than mast cells must be binding the histamine in the mucosa." Perhaps here, the histamine is bound to the metachromatically-staining mucus.

Parratt & West C26,727/56: "When rat's skin is scraped to separate the subcutaneous layers completely from the outer epithelium, the major portion of the mast cells and histamine are removed with the inner scrapings. However, the 5–HT content of the outer epithelium greatly exceeds that of the scrapings, so that mast cells do not appear to be the only source of 5–HT in the skin of the rat. Similarly, in the feet, the skin of the pads contains fewer mast cells and less histamine than the dorsal skin but its 5–HT content is higher."

Mota et al. C31,032/56: Comparative determinations of the MC count and histamine content in various tissues of the rat show a positive correlation between them at most sites. However, the relatively high histamine values were obtained for the fundic region of the stomach and duodenum and medium value for the ileum, although only very few MCs were detected in these regions.

Parratt & West C37,857/57: Comparative MC counts and determinations of histamine and 5–HT (bioassay, chromatography) revealed that 5–HT is associated with MCs in the rat and mouse, but not in the guinea-pig, dog, man, rabbit, cow, hamster, and cat. In the rat, more than half of the total 5–HT of the body is in the skin, but only part of this is within the MCs. In the rat, histamine and MCs are concentrated in the inner layers of the skin and footpads where 5–HT is chiefly in the outer layers.

Ende & Cherniss C55,644/58: In the human spleen, there is a good correlation between MC density and histamine content, but no correlation with 5–HT could be demonstrated.

Gamble & Stempak D26,648/61: In the rat fetus, MCs appear in the subcutis at about the 15th day of gestation and in the liver as well as throughout the connective tissue, including the mesentery; they can be demonstrated during the next few days. Blood MCs were not seen in any of the fetuses. Although other investigators stated that histamine appears in the rat fetus much before MCs are demonstrable, the present observations do not support such a view. "It is equally clear, however, that histamine is first present in rat foetal tissues some four to five days before mast cells may be recognized there and that the source of this histamine, while still unknown, is in cells other than mast cells."

Dunér & Pernow E4,176/63: Review of the literature shows that in mammals most, though not all, the histamine is derived from MCs.

Demis E24,240/63: The histamine pathway of histidine metabolism may be summarized as follows (numbers in parentheses indicate the approximate per cent of exogenous histamine excreted in the urine of man as a metabolite):

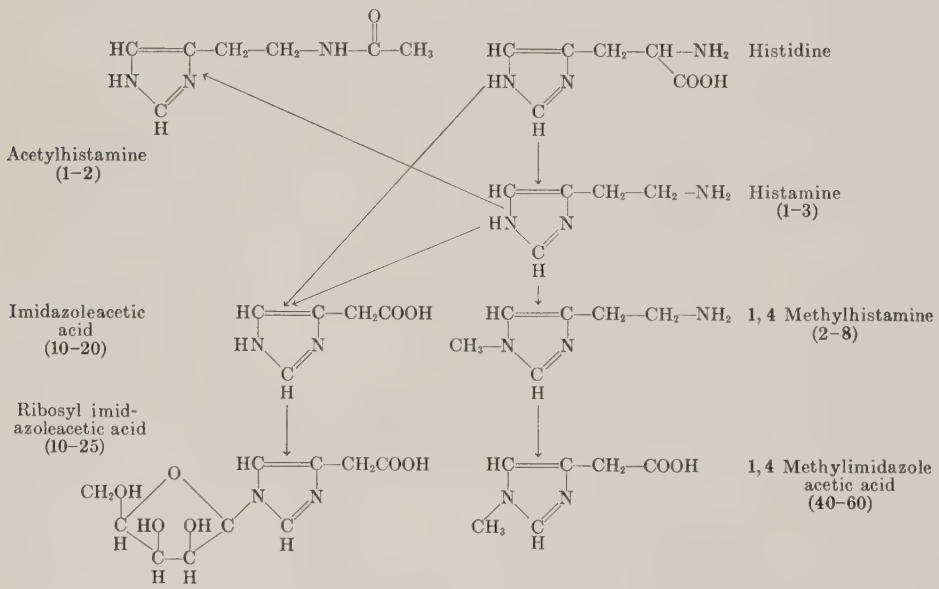

Walter Reed Army Institute of Research

Gróf et al. G17,921/64: In the eyes of cattle the greatest MC concentrations are found in the conjunctiva, the optic nerve, and the ocular muscles. The sclera, iris, ciliary body, and choroid contained less MCs, while the cornea, lens and retina were completely free of them. The histamine content of these tissues paralleled their MC concentration.

Zachariae F10,412/64: In human embryos "skin histamine rose with increasing fetal age. The appearance of identifiable mast cells coincided with the presence of larger amounts of cell-bound histamine in skin."

IN NORMAL MAST CELLS

Riley & West D39,662/53: The liver capsule of the ox, sheep, and cow as well as ox pleura, are very rich in MCs and histamine.

Graham et al. D26,780/55: Comparative enumeration of MCs and histamine determinations in dog skin, lung, liver, muscle, and kidney, as well as in beef liver parenchyma and capsule, exhibit a positive relationship between these two parameters. The amount of histamine found per mast cell varied from 7 $\mu\mu$g in dog skin to 32 $\mu\mu$g in beef liver capsule; i.e., roughly from 3×10^{10} to 15×10^{10} molecules of histamine per cell.

Benditt et al. C9,838/55: Histamine, 5–HT, and heparin could be demonstrated in purified MCs from peritoneal washings of rats, both by biossay and by chromatography.

Benditt et al. D31,573/56: On the basis of estimations on isolated rat peritoneal MCs, it is concluded that these contain approximately 11 μg. of histamine (free base) per mm^3.

Keller D27,073/57: "In mast cells isolated from the abdominal cavity of rats and concentrated, histamine and 5-hydroxytryptamine were identified by tests with isolated organs and paper chromatography."

Boréus & Chakravarty D26,646/60: Guinea-pig MCs contain from 21 to 34 $\mu\mu$g of histamine base/cell.

Bray & Van Arsdel D26,900/61: "Qualitative variations in response of these mast cells to different releasers suggested that mechanisms of histamine release very considerably among the chemical agents now being investigated." It is calculated that each peritoneal MC contains 29 $\mu\mu$g of histamine.

Moran et al. D33,693/62:

Content of 5–HT and histamine in rat peritoneal cell suspension and in rat mast cells

	5–HT μg/rat n = 82	5–HT μg/10^6 mast cells n = 37	Hist. μg/rat n = 82	Hist. μg/10^6 mast cells n = 37	Ratio Hist: 5–HT n = 82
Mean ± standard error	1.09 ± 0.17	1.34 ± 0.20	22.3 ± 1.2	31.5 ± 1.9	42.4 ± 3.4
Range	0.05–8.38	0.22–5.70	3.5–46.8	12.2–58.9	3.3–170.3

Humphrey et al. D68,120/63: Rat MCs contain from 10 to 20 $\mu\mu$g of histamine/cell.

HISTAMINE CONTENT OF ISOLATED MC GRANULES

Mota et al. D27,632/54: Earlier observers suggested that histamine is bound to the mitochondrial fraction of the liver. By differential centrifugation of rat subcutaneous tissue, a relatively pure fraction of MC granules could be obtained and the major amount of histamine was present in these granules, from which it could be released by heating in an acid medium or by 48/80. "It is, therefore, probable that the higher histamine concentration of the mitochondrial fraction of dog liver might be due, at least in part, to its contamination with mast cell granules."

Grossberg & Garcia-Arocha D28,699/54; *Hagen* D26,567/54: A suspension in isotonic sucrose solution of the large granule fraction (containing the MC granules) of dog-liver homogenate contains much histamine which it releases when diluted with distilled water.

West D31,552/55: Histamine is located in the granules of isolated mouse subcutaneous-tissue MCs. Treatment with 48/80 and other histamine-liberators released most of the histamine from the granules into the supernatant. The MCs contain histamine.

Paton D39,576/58: It is quite possible that histamine is not located within the MCs themselves but around them. "Indeed, if the histamine content outside the mast cells bore some definite relation to the number of mast cells present, it would be very difficult indeed to distinguish the two sources of histamine by methods in use thus far."

Hagen et al. C70,407/59; *Hagen* D2,370/61: Electron-microscopic studies of mouse mastocytoma cells, combined with ultracentrifugation and biochemical as well as bioassay analysis of its particles, led to the conclusion that, histamine, heparin, and 5–HT are contained within specific granules, which are clearly separable from mitochondria and other

intracellular organelles. The granules are devoid of such characteristic mitochondrial enzymes as fumarase, amine oxidase, and succinic dehydrogenase, while the reverse is true of mitochondria.

Kahlson et al. E39,145/63: The histamine-forming capacity of the rapidly-multiplying cells in Ehrlich ascites tumors is very considerable but only a portion of the histamine thus formed comes from peritoneal MCs. Apparently, rapidly-multiplying tissues in general possess a high histamine-forming capacity.

IN HUMAN MASTOCYTOSES

Riley & West D39,656/52: The skin of patients with urticaria pigmentosa is unusually rich in histamine.

Riley B86,264/53: Large amounts of histamine were found in mastocytomas of children.

Drennan & Beare D26,760/54: Large amounts of histamine were found in a solitary MC nevus.

Grüneberg et al. D39,626/55: The histamine content in skin vesicles, produced by freezing, is greatly augmented in urticaria pigmentosa.

Waters & Lacson D39,669/57: A case of MC leukemia with a hemorrhagic type of urticaria pigmentosa and diffuse infiltration of various organs with MCs. There was a hundred-fold increase in the histamine and "heparin" content of the liver, but the blood-clotting time was normal despite a prolonged bleeding time.

Gardner & Tice C52,326/58: In the liver and spleen of a child with urticaria pigmentosa, "histamine was present in the tissue in several hundred times the normal concentration" but no 5–HT could be detected. "Our studies suggest that the decarboxylation of 5-hydroxytryptophan to serotonin does not take place in the human mast cell. Instead, the accumulation of compounds such as 5-hydroxytryptophan, kynurenine or hydroxylated kynurenine may take place. There was no increase in xanthine oxidase activity."

Davis et al. D39,697/58: In a patient with urticaria pigmentosa, the skin histamine was greatly increased.

Ende & Cherniss D39,554/58: The histamine content of the spleen was increased in a case of isolated splenic mastocytosis.

Schultz et al. G11,135/59: The blood histamine level may be elevated in mastocytosis.

Herzberg D39,565/59: Discussion.

Brogren et al. C69,050/59: In urticaria pigmentosa, excessive histaminuria is commonly found.

Meneghini & Levi D27,702/60: In the skin lesions of patients with urticaria pigmentosa, there is no increased heparin activity, although the histamine content is greatly augmented and proportional to the local MC count.

Bloom et al. D8,351/60: In a man with malignant systemic MC disease, severe bone changes were associated with an increased histamine and heparin content in the mastocytoma tissue itself, as well as in the blood and urine.

Bloom E22,677/60: In a patient with a mastocytoma, 600 μg of histamine were found in a 24-hour urine collection which is allegedly "a higher level than any previously reported in the literature."

Lindell et al. D26,738/61: In two cases of urticaria pigmentosa, the MC-containing skin specimens were shown to form radioactive histamine from added C^{14}-L-histidine. "The findings indicate that the mast cells in man not only store but also form histamine."

Demis et al. D2,184/61: In urticaria pigmentosa, the urinary excretion of free histamine increases, while that of 5–HIAA remains normal.

Demis et al. G11,134/61: It was thought that the accumulation of histamine in mastocytoma lesions may be due to some disturbance in the degradation of this compound. However, radioactive histamine injected intradermally in patients with mastocytosis and in healthy controls revealed no significant abnormality in the plasma clearance of total radioactivity. Presumably, the derangement is due to an overproduction of histamine rather than to some interference with its degradation. Detection of the specific histamine metabolite 1,4-methylimidazole acetic acid (MeImAA) in the urine of patients with mastocytosis also indicates histamine overproduction.

Demis & Brown E35,082/61: The administration of histidine-C^{14} to patients with urticaria pigmentosa resulted in essentially no radioactivity in the urinary histamine or histamine metabolites within the first five hours, despite increased urinary excretion of free histamine

by these patients. It is concluded that histidine degradation is not significantly influenced by urticaria pigmentosa although the skin lesions contain an increased amount of histidine decarboxylase, as much histidine decarboxylase activity as uninvolved skin.

Birt et al. D65,257/61: Radioactive histidine is transformed into histamine by homogenates of urticaria pigmentosa skin lesions, presumably as a consequence of an increased histidine-decarboxylase activity.

Fernex D39,200/62: The histamine content of the skin is greatly increased in urticaria pigmentosa.

Oates et al. G11,136/62: Using a fluorometric method of assay, it could be shown that histaminuria is increased in patients with mastocytosis.

Sutter et al. D63,193/62: Histaminuria is increased in mastocytosis, especially under the influence of treatment with codeine or polymyxin.

el-Mofty et al. D56,904/62: The histamine content of the blood was greatly increased in several cases of urticaria pigmentosa.

Demis & Zimmer D58,631/63: The urinary excretion of histamine is increased in urticaria pigmentosa. α-Methyldopa does not prevent this histaminuria because the compound does not block the conversion of histidine to histamine, which in mastocytosis depends on a specific histidine decarboxylase.

Mutter et al. E36,471/63. In a case of generalized mastocytosis, the serum histamine was increased 80-fold.

Zachariae D69,687/63: In three cases of urticaria pigmentosa, the skin histamine values were extremely high, up to 2 mg/g, as compared with the normal values of 5.3–18.4 μg/g.

Demis E24,240/63: The fact that the blood histamine is not regularly elevated in patients with mastocytosis is presumably a consequence of the transient character of the rises in blood histamine. The urinary histamine elimination is a better indication of increased histamine production in mastocytosis, but it also fluctuates and there are cases without histaminuria. The highest values were found during attacks of flush syndrome.

Code et al. G18,722/64: Discussion.

Ultmann et al. G19,654/64: The blood and tissue histamine content was greatly increased in a patient with systemic mastocytosis. The increase was most pronounced in the greatly enlarged spleen.

IN ANIMAL MASTOCYTOMAS

Riley & West D39,662/53: Dog MC tumors are very rich in histamine.

Cass et al. D26,776/54; D39,658/54: Large amounts of both histamine and heparin are found in mastocytomas of dogs.

Riley & West D27,968/56: The highest histamine content ever described for a tissue so far recorded is that of MC tumor from a dog, which contained 1290 μg/g of histamine.

West C19,992/56: Mastocytomas of dogs are very rich in histamine.

Larsson E47,930/57: Canine mastocytomas are very rich in histamine, containing up to 903 μg/g of wet tumor tissue. The blood histamine is not markedly elevated but under the influence of 48/80 it rises much higher in mastocytoma-bearing than in normal dogs. The histamine content of the mastocytoma tissue itself, on the other hand, is not significantly affected by 48/80.

Sjoerdsma et al. C35,838/57: The mouse mastocytoma P–815 contains large amounts of histamine and 5–HT, while a dog mastocytoma and the skin of a patient with urticaria pigmentosa contained high amounts of histamine but only negligible quantities of 5–HT. Furthermore, patients with urticaria pigmentosa excrete normal amounts of 5–HIAA while patients with carcinoid tumors and mice with mastocytomas exhibit a high urinary elimination of 5–HIAA. Evidently, there is a marked species variation in the histamine and 5–HT production by MCs.

Cass et al. C54,014/58: Murine mastocytoma tissue is very rich in histamine.

Lindell et al. D65,656/59: As judged by incubation with radioactive histidine, a canine mastocytoma contained large amounts of histidine decarboxylase and was capable of synthesizing histamine. "This is considered additional evidence that mast cells form histamine and not merely store it."

Ono et al. D27,408/59: The transplantable mastocytomas of LAF_1 mice contain as much or more histamine, heparin, and 5–HT as any mammalian tissues so far examined.

Schindler et al. C68,305/59: A technique for the continuous in-vitro culture of cells of the P–815 MC-leukemia of the mouse is described. Under suitable conditions, the cells maintain their high 5–HT and histamine content as well as their neoplastic infectivity.

Day & Green C66,290/59; D41,586/62: Two lines of neoplastic murine MCs showed wide fluctuations in their histamine and 5–HT content over a two-year period, whether grown in culture or in the mouse. Supplementing the culture medium with tryptophan, 5-hydroxytryptophan, histidine, and some other substances did not influence the levels of amines in the MCs.

Day & Green D39,829/60: "Neoplastic murine mast cells (P–815) in culture not only took up and converted histidine and 5-hydroxytryptophane (5-HTP) to the corresponding amines, but were able to concentrate histamine and 5-hydroxytryptamine (5-HT) from the medium. Both amines were more rapidly taken up by a diploid strain than by a tetraploid strain. Imipramine (Tofranil) decreased the uptake of the amines by the cells. High levels of 5–HT in the medium reduced the amount of histamine and 5–HTP taken up by the cells. On the other hand, the uptake of 5–HT was not influenced by high levels of histamine, 5–HTP, or histidine. Similarly, histamine did not influence the uptake of either amino acid, nor could an antagonism be shown between the two amino acids in their uptake by the cells."

Green & Day D29,594/61: Two strains of the mouse mastocytoma (P–815) in tissue culture, maintained for more than two years their capacity to take up and to decarboxylate histidine and 5–HTP to their respective amines. The cells are also able to concentrate within their bodies preformed histamine, 5–HT and, to a lesser extent, 3-hydroxytryptamine and tryptamine. Upon incubation with tryptophan, the cells produce 5–HTP and 5–HT but only small amounts of 5–HIAA. No evidence could be obtained that either endogenous or exogenous histamine is further metabolized.

Mengel & Trier D3,888/61: The P–815 MC ascites tumor of the mouse is rich in histamine and heparin. By in-vitro cloning, it is possible to develop morphologically-recognizable stable sublines of this tumor with differential levels of 5–HT and histamine.

Mengel & Kelly D26,448/61: In mice bearing P–815 ascites MC-neoplasms, the carcinolytic substance, cyclophosphamide, causes involution of the tumors and simultaneously an increase in the otherwise low percentage of cells that contain metachromatic granules. The metachromasia of the MCs increased concomitantly with a rise in 5–HT content, while the histamine content of the cells remained unchanged. The urinary excretion of 5–HIAA and 5–HT was enhanced. The induction of a dissociation in the 5–HT and histamine content of the tumor indicates that all the 5–HT cannot be present as a heparinate in these MC tumors. Another possibility is that the tumor contains several cell populations in terms of 5–HT and histamine storage and that cyclophosphamide may have damaged predominantly one cell type.

Day & Green D39,523/62: By the use of C^{14} it has been possible to show that endogenous 5–HT and histamine are more rapidly metabolized by neoplastic murine MCs than are exogenous 5–HT and histamine. "Two pools for amines are postulated: one, containing endogenous amines and a mechanism for the elimination of the amines, is of only limited accessibility to the exogenous amines, most of which are held in a separate pool."

Green et al. D47,977/62: Histamine is demonstrated in the cells of murine mastocytomas.

Stüttgen et al. D26,860/62: Using high-tension electrophoresis and pharmacologic assays, histamine could be demonstrated in mastocytoma tissue. In such extracts, there is also an activator of histamine oxidation.

Gróf & Kelényi G17,922/63: In Furth's transplantable murine mastocytoma tissue the histamine content varies between 120 and 1114 μg/g. The other organs of tumorous mice showed no increase in histamine concentration.

Mengel D58,283/63: The histamine content of the mouse mastocytoma P–815 varies considerably in its sublines with repeated transfer.

Green & Day D58,290/63: Cortisone inhibited the growth of (murine mastocytoma) cells without influencing the synthesis of heparin, histamine, or 5–HT. Reserpine released 5–HT from these cells, polymyxin B released histamine, and 48/80 released both amines.

Furano & Green G18,219/64: About 60 percent of radioactive histamine added to murine neoplastic MCs is taken up by the large particle fraction of their granules, while only 25 per cent is present in the soluble cytoplasmic material. After incubation with nonradioactive histamine, only 9.1–21 per cent of the radioactive histamine enters the large

particle fraction, while more than 60 per cent remains in the soluble cytoplasmic material. Radioactive histamine is lost much more rapidly from cells in which the bulk of the radioactive histamine is located in the soluble cytoplasmic material than from cells in which most of the radioactive histamine is in a large particle fraction; thus, there appears to be an association between the subcellular distribution of radioactive histamine and the rate at which this amine is lost from the cell.

Day & Stockbridge G20,741/64: Neoplastic murine MCs take up C^{14}-labeled 5–HT and histamine from the medium. This response is influenced by a variety of drugs. "In general, any antagonist which inhibited uptake of 5-hydroxytryptamine had little effect on uptake of histamine, and vice versa."

Zachariae F10,402/64: In a transplantable murine mastocytoma, the histamine content was 11797 μg/g of dried and defatted tissue. The skin was also rich in histamine, while other organs (liver, spleen, ovary) contained essentially normal amounts.

FOLLOWING EXPERIMENTAL INTERVENTIONS

Fawcett D28,375/54: 48/80 i.p. releases both the granules and the histamine from the local MCs of the rat. However, if the MCs have been destroyed by a previous i.p. injection of distilled water several days earlier, then 48/80 no longer caused histamine release. "These observations strongly support the thesis that MCs are unusually rich in histamine which is released under experimental conditions which cause them to discharge granules."

Fawcett D26,771/54: Following i.p. injection of distilled water or 48/80 into the peritoneum of the rat, the peritoneal MCs discharge their granules and histamine into the surrounding fluid. "It is concluded that mast cells in the rat are extraordinarily rich in histamine which is liberated under conditions which cause mast cells to release their granules."

Benditt et al. B91,948/54: Ovomucoid is thought to produce an anaphylactoid inflammation in rats as the result of histamine discharge from the MCs in the shock organs.

Mota et al. D26,758/54: Shock, induced by i.p. injection of peptone in the dog, is associated with depletion of the MCs in the liver, tongue, spleen, mesentery, lung, and other organs. The few remaining intracellular granules tend to lose their metachromasia. The concomitant decrease in blood pressure and blood coagulability is ascribed to degranulation of the MCs and suggests that "mast cells of other organs also prevent alterations, suggesting that, in the dog, heparin and histamine might originate from other organs besides the liver."

Braun-Falco D26,884/55: Distilled water or 48/80 i.p. increases the histamine content of the peritoneal fluid in the rat proportionately to the local MC discharge thus obtained.

Riley & West C14,427/55: Following acute or chronic treatment with 48/80 i.p. or into the artery supplying one ear, there is a degranulation of the directly-affected MCs and, to a lesser extent, also of those at a distance from the application of the histamine-liberators. "In every experiment, a close correlation was observed between the fall and subsequent recovery of the tissue histamine on the one hand and the disruption and restoration of the mast cells on the other."

Rowley & Benditt C15,372/56: Edema produced in the rat paw by topical injection of such MC-damaging agents as ovomucoid, dextran, 48/80, or testicular extract, is partially inhibited by dibenamine (a 5–HT antagonist), but not by pyrilamine (a histamine antagonist). It is completely inhibited by treatment with both these drugs. The MC damage, produced by the above-mentioned MC-dischargers, is not prevented by the drugs which inhibit their edematogenic action. "The observations are consistent with the hypothesis that agents which damage mast cells, 'release' both 5-hydroxytryptamine and histamine and that, in the rat, the edema associated with mast cell damage is mediated largely by 5-hydroxytryptamine."

Mota el al. C18,184/56: In the dog, peptone injection causes a pronounced diminution in the histamine content of the liver and tongue, simultaneously with the MC degranulation that occurs in these organs. Apparently, not only heparin but histamine also is discharged during peptone shock from the MCs of the dog.

Parratt & West C19,991/56: When most of the MCs in the rat's ear are disrupted by repeated i.p. injections of 48/80, the histamine content of the ear drops considerably while that of the spleen (where MCs are absent) remains virtually unchanged.

Parratt & West C26,727/56: In the rat, 48/80 and egg white produce anaphylactoid inflammation with MC discharge and the release of histamine plus 5–HT. Rats pretreated with 48/80 no longer respond to egg white with an anaphylactoid inflammation, presumably

because of the preceding depletion in histamine and 5–HT. Reserpine, which also depletes the skin of 5–HT, does not markedly affect its histamine content and produces no edema. After reserpine, egg white also fails to produce edema, although histamine is released. "Hence, both histamine and 5–HT need to be released to produce edema. This suggests that 5–HT is one of the mediators of the reaction of the skin to egg white."

Mota et al. C31,032/56: In rats, treatment with 48/80 greatly reduced the histamine content of tissues rich in MCs, but the treatment did not reduce the histamine in the wall of the fundic region of the stomach, duodenum, ileum, and liver, which contain few MCs. It was concluded that "the histamine of the mast cells is very susceptible to 48/80 and that its inability to release the histamine of some tissues is due to the fact that in these, the histamine is not of mast cell origin."

Keller & Burkard C29,951/56: 48/80 i.p. and distilled water produce a local MC discharge in the rat which corresponds in degree to the intensity of the resulting local MC degranulation.

Eisen et al. C26,528/56: Following X-irradiation, there is a rapid decrease in skin histamine accompanied by significant damage to the cutaneous MCs. On the other hand, the concurrent decrease in the histamine content of the stomach and jejunum is not associated with MC degeneration. "It is suggested that the fall in skin histamine is attributable to the concurrent degeneration of subcutaneous mast cells, but that the depletion of histamine in the alimentary canal is largely independent of changes in the mast cells."

Högberg et al. D26,423/56–57: 48/80, an extract from jellyfish (*Cyanea capillata*), and the eelworm of swine (*Ascaris lumbricoides*) are highly effective both in causing disruption of mesenteric rat MCs in vitro and in inducing a histamine discharge from the perfused cat's paw. An extract from hip seed blocks both the MC-disrupting and the histamine-liberating effect of these compounds.

Lacaz et al. C33,366/57: CCl_4-intoxication increased the histamine content of the rat liver simultaneously with the development of a local mastocytosis.

Keller C54,750/57: "Injections of distilled water, trypsin, dextran, peptone and application of tourniquets to rats gave a reaction similar to that obtained by the injection of rabbit serum containing antibodies against the connective tissue of rats; subsequently, the histamine excretion was increased in most cases; the tissue mast cells, in contrast to controls, displayed qualitatively similar alterations in all types of shock. These observations indicate a connection between the damage to, or destruction of, mast cells and histamine liberation in albino rats."

Mota D26,425/58: When minced lung tissue or a piece of mesentery from a sensitized guinea-pig is incubated with antigen, there ensues degranulation of MCs and reduction in their number within 15 seconds. These MC alterations are clearly different from those induced by a histamine-discharger (octylamine), which are characterized by fusion and clumping of the granules without degranulation. Furthermore, the MC alterations produced by anaphylaxis, unlike those caused by the histamine releaser are prevented by heating the tissue at 45°C, by lack of calcium, as well as by iodoacetate and phenol. There is a close parallelism between the effect of these agents on MCs and on histamine release. "Since mast cell alterations are produced by the action of the antigen, both in vivo [*Mota & Vugman* D27,087/56; *Mota* D27,088/57] and in vitro, it seems probable that the mast cells contain antibody and play an important role in anaphylaxis."

Paton D39,576/58: In the rat mesentery, some MCs resist 48/80 completely even when very high doses are given. "Further, it is interesting that if the administration of a histamine liberator is continued, restitution of some of the mast cell population occurs even during the continued presence of the drug."

Boréus & Chakravarty D26,646/60: The anaphylactic histamine liberation following antigen-antibody reaction in vitro corresponds quite closely to the MC depletion in various organs increasing in the following order: trachea, uterus, nasal mucosa, aorta. On the assumption that all the histamine is located in the MCs, it is calculated that each cell in these organs of the guinea pig contains 25–34 $\mu\mu$g of histamine base and releases 12–17 $\mu\mu$g in the course of anaphylaxis.

Smith D58,273/63: Protamine sulfate can liberate histamine from rat peritoneal MCs, even following repeated injections when no visible change occurs any more in the cells. "Thus, secretion by the mast cell does not require cell disruption and death as much of the literature indicates but is merocrine in nature."

HISTAMINE IN LEUKOCYTES AND PLATELETS

Eckert & Tötterman D28,660/50: Contrary to earlier claims, a review of the literature, and personal observations, lead to the conclusion that available evidence "speaks against the assumption that histamine is an essential part of the eosinophil granules."

Graham et al. D28,268/52: The basophils of normal and leukemic human blood are especially rich in histamine.

Code D28,281/52: In the blood of most species, including man, the granular leukocytes are the main source of histamine. "Part or all of the histamine apparently originates with the cells of the blood in the bone marrow so that they carry it with them when they leave but by what means it enters them or is synthetized by them is not known." Still, there is no constant correlation between the total number or the number of any one member of the granular series and the histamine content of the blood. The earlier concept that the eosinophil is the carrier of histamine is still not definitely rejected, however, despite this lack of correlation. "If eosinophils are the 'trucks' that carry histamine in the blood stream they are not always 'loaded.' "

Ehrich D26,427/53: The histamine content of the blood is well correlated with the number of circulating MCs (basophils), but not with that of eosinophils or neutrophils. This could be confirmed on the blood of cats, guinea-pigs, rabbits, and man as well as on the blood of leukemic patients. "These observations are in keeping with the view that blood and tissue mast cells are functionally the same."

Schayer & Kobayashi D30,376/56: The rabbit is the only species known to contain high concentration of histamine in the blood platelets (*Code* D28,281/52). Furthermore, "rabbit platelets decarboxylate C^{14} L-histidine and bind the resulting C^{14} histamine in stable condition." [This is of special interest since the rabbit is also unique in having particularly few MCs (*H.S.*).]

HISTAMINE SYNTHESIS BY MAST CELLS

Schayer D27,727/56: "Suspensions of the cells of rat peritoneal fluid have a marked ability to decarboxylate C^{14} L-histidine and bind the resulting histamine in stable form. The evidence is strong that this activity is due almost entirely to mast cells . . . Disruption of the mast cells results in a considerable loss in histamine forming activity."

Sjoerdsma et al. C48,610/58: Histidine administration does not change the 5–HT content of mouse mastocytoma tissue.

Rothschild & Schayer C76,258/59: It could be demonstrated that the histidine-decarboxylase activity in the peritoneal fluid of rats is almost entirely associated with the MCs. This is of interest since histidine-decarboxylase plays an important role in the production of histamine in vivo.

Lindell et al. D26,738/61: In two cases of urticaria pigmentosa, the MC-containing skin specimens were shown to form radioactive histamine from added C^{14}-L-histidine. "The findings indicate that the mast cells in man not only store but also form histamine."

Green & Day D29,594/61: Two strains of the mouse mastocytoma (P–815) in tissue culture, maintained for more than two years their capacity to take up and to decarboxylate histidine and 5–HTP to their respective amines. The cells are also able to concentrate within their bodies preformed histamine, 5–HT and, to a lesser extent, 3-hydroxytryptamine and tryptamine. Upon incubation with tryptophan, the cells produce 5–HTP and 5–HT but only small amounts of 5–HIAA. No evidence could be obtained that either endogenous or exogenous histamine is further metabolized.

Day & Green D41,586/62: Neoplastic murine MCs concentrate histidine when the latter is added to the culture medium.

Kahlson et al. D17,638/64: The histamine-forming capacity (HFC) of rats was studied during anaphylactic shock elicited by sensitization with egg white and *Haemophilus pertussis* vaccine, the results being expressed in terms of C^{14} histamine formed in vitro from C^{14} histidine by a given amount of tissue. It was concluded "that there is no correlation between elevation of HFC in anaphylaxis and the number of mast cells in the tissues investigated." For example, the HFC of skin rich in MCs was not significantly altered in anaphylaxis.

5–HT AND RELATED COMPOUNDS

[Cf. also THEORIES (*p.* 366) for interpretation of MC–5–HT determinations.]

In *normal tissues* of the rat and mouse there exists a good correlation between MC counts and 5–HT content but this is not the case in the guinea-pig, dog, rabbit, cow, hamster, cat, and man. In the rat, more than half of the total 5–HT of the body is in the skin, but even in this species only part of it is within the MCs.

Normal mast cells, isolated from the peritoneal cavity of the rat, are estimated to contain about 0.7 $\mu g/mm^3$ of 5–HT.

Electron-microscopic studies revealed that 5–HT is contained in *isolated mast-cell granules* that can be clearly separated from mitochondria and other intracellular organelles by density gradient ultracentrifugation.

The specific lesions in *human mastocytoses* contain little or no 5–HT despite their high histamine and heparin content. Apparently, decarboxylation of 5–HTP to 5–HT does not take place in human MCs to any appreciable extent. Accordingly, the 5–HT, 5–HTP, and 5–HIAA content of the blood and urine remain within essentially normal limits in the mastocytoses of man (unlike in the carcinoid syndrome).

Among the *animal mastocytomas,* those of the dog and cow contain no excessive amounts of 5–HT while those of the mouse are rich in this compound. Neoplastic murine MCs can even convert 5–HTP to 5–HT in vitro. Upon incubation with tryptophan, the cells produce 5–HTP and 5–HT but only small amounts of 5–HIAA. Neoplastic murine MCs also take up 5–HT from the culture medium in vitro.

Following *experimental interventions* which discharge the MCs, 5–HT is released together with the granules in those species (e.g., rat) which store 5–HT in their MCs. Furthermore, in the mouse, painting of the skin with certain carcinogens which increase the local MC population is associated with a corresponding rise in the topical 5–HT concentration.

As judged by experiments with radioactive 5–HTP, there occurs some synthesis of *5–HT in platelets.* This observation led to the assumption of some close relationship between MCs and platelets.

In the preceding pages we have already touched upon evidence suggesting *5–HT synthesis by mast cells.* Homogenates of murine mastocytomas contain a 5–HTP-decarboxylase as well as dopa-decarboxylase, but as judged by ultracentrifugation, both enzymes are located in the non-particulate cytoplasm. Murine neoplastic MCs can also take up tryptamine, tryptophan, and 3-hydroxytryptamine from the culture medium in vitro.

Reviews:
Arvy D65,673/56
Fulton et al. C35,831/57
Padawer D30,194/57
Crabb C53,755/58
Kelsall & Crabb D26,076/59 *p. 133*
Sjoerdsma D30,551/59
Macaluso & Pasqualino D5,225/60
Smith D63,031/63
Benditt & Lagunoff G10,074/64

IN NORMAL TISSUES

Keller D27,073/57: "In mast cells isolated from the abdominal cavity of rats and concentrated, histamine and 5-hydroxytryptamine were identified by tests with isolated organs and paper chromatography."

Parratt & West C37,857/57; C37,858/57: Comparative MC counts and determinations of histamine and 5-HT (bioassay, chromatography) revealed that 5-HT is associated with MCs

in the rat and mouse, but not in the guinea-pig, dog, man, rabbit, cow, hamster, and cat. In the rat, more than half of the total 5-HT of the body is in the skin, but only part of it is within the MCs. In the rat, histamine and MCs are concentrated in the inner layer of the skin, whereas 5-HT is chiefly in the outer layer. The same is true within the footpads of the rat which contain much 5-HT but little histamine and few MCs.

Ende & Cherniss C55,644/58: In the human spleen, there is a good correlation between MC density and histamine content, but no correlation with 5-HT could be demonstrated.

IN NORMAL MAST CELLS

Benditt et al. C9,838/55: By direct analysis of relatively-pure rat peritoneal MC populations, their 5-HT content has been determined to be 0.7 $\mu g/mm^3$.

Moran et al. D33,693/62: Discussion.

IN ISOLATED MAST-CELL GRANULES

Hagen et al. C70,407/59; *Hagen* D2,370/61: Electron-microscopic studies of mouse mastocytoma cells, combined with ultracentrifugation and biochemical as well as bioassay analysis of its particles, led to the conclusion that, "histamine, heparin and 5-hydroxytryptamine are contained within specific granules, which are clearly separable from mitochondria and other intracellular organelles."

IN HUMAN MASTOCYTOSES

West C45,485/57; *Parratt & West* C37,857/57: Unlike carcinoids, MC tumors of man as well as MC-containing nodules in Shorthorn heifers, do not contain raised 5-HT levels.

Sjoerdsma et al. C35,838/57: Only traces of 5-HT can be found in human mastocytosis lesions.

Gardner & Tice C52,326/58: In the liver and spleen of a child with urticaria pigmentosa, "histamine was present in the tissue in several hundred times the normal concentration" yet no 5–HT could be detected. Apparently the decarboxylation of 5–HTP to 5–HT does not take place in human MCs. Instead, the accumulation of compounds such as 5–HTP, kynurenine, or hydroxylated kynurenine may take place. There was no increase in xanthine oxidase activity.

Ende & Cherniss D39,554/58: In a case of splenic mastocytosis, there was no evidence of an increased 5–HIAA excretion in the urine.

Herzberg D39,565/59: Discussion.

Brogren et al. C69,050/59: Although patients with urticaria pigmentosa show histaminuria, the 5–HT and 5–HIAA content of the urine is not increased.

Birt & Nickerson G11,133/59: 5–HT may occur in mastocytosis lesions and the urinary excretion of 5–HIAA may be slightly increased in patients with mastocytosis.

Lees & Stroud E34,936/59: The 5–HIAA content of the urine was normal in a case of urticaria pigmentosa.

Baer & Witten G11,137/59–60: The urinary 5–HT and 5–HIAA excretion is usually unchanged in mastocytosis.

Hasegawa & Bluefarb C97,856/60: There was no increase in the urinary 5–HT or 5–HIAA content in a patient with urticaria pigmentosa.

Demis et al. D2,184/61: In urticaria pigmentosa, the urinary excretion of free histamine increases, while that of 5–HIAA remains normal.

Stüttgen et al. D26,860/62: In skin extract and the fluid of vesicles of patients with mastocytosis, 5–HT could not be demonstrated as such, but 5–HTP was present.

Szweda et al. D20,223/62: Patients with mastocytosis may have a slightly increased urinary excretion of 5–HIAA.

Sturm & Stüttgen D21,093/62: In mastocytosis and urticaria pigmentosa, the skin and the contents of cutaneous vesicles were shown to contain increased amounts of histamine, tryptophan, 5–HTP, and glutamic acid. 5–HT, on the other hand, could not be demonstrated. The 5–HIAA elimination in the urine was normal. The 5–HTP storage in the MC-rich cutaneous lesions was considered as a possible reserve for the subsequent formation of 5–HT.

Enerbäck D39,849/63: "Mast cells occurring in human carcinoid tumors exhibit histochemical reactions suggesting that they contain serotonin." The so-called enterochromaffin reactions shown by enterochromaffin cells and carcinoid cells after fixation in formalin are most probably elicited by a reaction between formalin and serotonin. "It remains to be seen

whether carcinoids containing mast cells with positive enterochromaffin reactions constitute a special type of tumour or if all carcinoids normally contain such mast cells."

Zakon et al. D65,525/63: No 5–HIAA could be found in the urine of a patient with urticaria pigmentosa.

Demis E24,240/63: The blood and urinary concentrations of 5–HT and 5–HIAA are within normal limits in mastocytosis.

Mutter et al. E36,471/63: In a case of generalized mastocytosis, the serum 5–HT content was decreased but the urinary 5–HIAA level was normal.

Rabinovich & Ley D66,453/63: In a woman with classical urticaria pigmentosa, there was no demonstrable increase in the urinary excretion of 5–HIAA.

Ultmann et al. G19,654/64: In a patient with systemic mastocytosis, no 5–HT could be demonstrated in the blood, and the urine and tissues contained normal amounts of this compound. The 5–HTP activity of the enlarged spleen was subnormal.

IN ANIMAL MASTOCYTOMAS

Parratt & West C37,857/57: Mastocytomas in the dog and cow do not contain excessive amounts of 5–HT.

Sjoerdsma et al. C35,838/57: The mouse mastocytoma P–815 contains large amounts of histamine and 5–HT, while a dog mastocytoma (and the skin of a patient with urticaria pigmentosa) contained only high amounts of histamine but negligible quantities of 5–HT. Furthermore, patients with urticaria pigmentosa excrete normal amounts of 5–HIAA, while patients with carcinoid tumors and mice with mastocytomas exhibit a high urinary-elimination of 5–HIAA. Evidently, there is a marked species variation in the histamine and 5–HT production of MCs.

Weissbach et al. C50,586/58: Large amounts of 5–HT can be demonstrated in mouse mastocytomas by precipitation of the tissue protein with zinc hydroxide, followed by direct fluorometric measurement of 5–HT.

Cass et al. C54,014/58: In mice bearing a transplantable mastocytoma, the tumor tissue was found to be very rich both in 5–HT and in histamine.

Schindler C71,500/58: The conversion of C^{14} tryptophan to 5–HT by neoplastic mouse MCs in culture has been described. The labeled 5–HT formed was identified by paper chromatography and by recrystallization with carrier 5–HT. The results indicate that in MCs, free tryptophan is the major, if not the sole, precursor of 5–HT. In preliminary experiments, this conversion was demonstrated in cell-free homogenates of MC tumors.

Meier C67,864/59: "Eight canine mastocytomas revealed only negligible quantities of 5–HT, averaging 0.49 μg/g dry weight, although histochemically large amounts of indol compounds could be demonstrated."

Ono et al. D27,408/59: The transplantable mastocytomas of LAF_1 mice contain as much or more histamine, heparin, and 5–HT as any mammalian tissues so far examined.

Schindler et al. C68,305/59: A technique for the continuous in-vitro culture of cells of the P–815 MC-leukemia of the mouse is described. Under suitable conditions, the cells maintain their high 5–HT and histamine content as well as their neoplastic infectivity.

Day & Green C66,290/59; D41,586/62: Two lines of neoplastic murine MCs showed wide fluctuations in their histamine and 5–HT content over a two-year period whether grown in culture or in the mouse. Supplementing the culture medium with tryptophan, 5–HTP, histidine, and some other substances, did not influence the levels of amines in the MCs.

Day & Green D39,829/60: Neoplastic murine P–815 MCs in culture took up and converted histidine and 5–HTP to the corresponding amines. They also concentrated histamine and 5–HT from the medium. "Both amines were more rapidly taken up by a diploid strain than by a tetraploid strain. Imipramine (Tofranil) decreased the uptake of the amines by the cells. High levels of 5–HT in the medium reduced the amount of histamine and 5–HTP taken up by the cells. On the other hand, the uptake of 5–HT was not influenced by high levels of histamine, 5–HTP, or histidine. Similarly, histamine did not influence the uptake of either amino acid, nor could an antagonism be shown between the two amino acids in their uptake by the cells."

Green & Day D29,594/61: Two strains of the mouse mastocytoma (P–815) in tissue culture, maintained for more than two years their capacity to take up and to decarboxylate histidine and 5–HTP to their respective amines. The cells are also able to concentrate within their bodies preformed histamine, 5–HT and, to a lesser extent, 3-hydroxytryptamine and

tryptamine. Upon incubation with tryptophan, the cells produce 5–HTP and 5–HT, but only small amounts of 5–HIAA. No evidence could be obtained that either endogenous or exogenous histamine is further metabolized.

Mengel & Kelly D26,448/61: In mice bearing P–815 ascites MC-neoplasms, the carcinolytic substance cyclophosphamide causes involution of the tumors and simultaneously an increase in the otherwise low percentage of cells that contain metachromatic granules. The metachromasia of the MCs increased concomitantly with a rise in 5–HT content, while the histamine content of the cells remained unchanged. The urinary excretion of 5–HIAA and 5–HT was enhanced. The induction of a dissociation in the 5–HT and histamine content of the tumor indicates that all the 5–HT cannot be present as a heparinate in these MC tumors. Another possibility is that the tumor contains several cell populations in terms of 5–HT and histamine storage and that cyclophosphamide may have damaged predominantly one cell type.

Rice & Mitchener D2,299/61: Contrary to earlier investigators who found no 5–HT in mastocytomas of the dog (*Parratt & West* C37,857/57; *Sjoerdsma* D30,551/59), histochemical methods (fluorescence after acid-formalin fixation with positive ferric-ferricyanide and diazosafranin reactions) give "strong presumptive evidence of the occurrence of 5-hydroxytryptamine in the mast cells of this tumor."

Day & Green D41,587/62: Neoplastic murine MCs take up 5–HT from the culture medium in vitro.

Green et al. D47,977/62: 5–HT is demonstrated in the cells of murine mastocytomas.

Day & Green D39,523/62; *Green & Furano* D39,524/62: In studies with C^{14}-marked metabolities, it could be shown that the turnover rate of endogenous 5–HT and histamine in murine mastocytoma cultures is more rapid than that of exogenous 5–HT and histamine. "It is suggested that the endogenous amines are held in a pool separate from the exogenous amines and that the accessibility of the exogenous amines to the pool for endogenous amines is a function of the levels of endogenous amines already existing in the pool."

Mengel D58,283/63: The 5–HT content of mouse mastocytoma P–815 varies considerably in its sublines with repeated transfer.

Green & Day D58,290/63: Metabolic studies on 5–HTP in murine neoplastic MCs.

Hagen D46,595/63–64: Murine mastocytoma ascites cells decarboxylate m-tyrosine about twice as rapidly as o-tyrosine or DOPA. Hydroxylated tryptophan derivatives were decarboxylated much more slowly than hydroxylated phenylalanine derivatives. "Competition experiments indicate that a single enzyme effects the decarboxylation of all these hydroxylated amino acids."

FOLLOWING EXPERIMENTAL INTERVENTIONS

Rowley & Benditt C15,372/56: Edema produced in the rat paw by topical injection of such MC-damaging agents as ovomucoid, dextran, 48/80, or testicular extract is partially inhibited by dibenamine (a 5–HT antagonist), but not by pyrilamine (a histamine antagonist). It is completely inhibited by combined treatment with both these drugs. The MC damage, produced by the above-mentioned MC-dischargers, is not prevented by the drugs which inhibit their edematogenic action. "The observations are consistent with the hypothesis that agents which damage mast cells, 'release' both 5-hydroxytryptamine and histamine and that in the rat the edema associated with mast cell damage is mediated largely by 5-hydroxytryptamine."

Bhattacharya & Lewis C19,581/56: From comparative histologic and biochemical studies "it is concluded that the 5–HT released by histamine liberators, like the released histamine and heparin, originates in the mast cells and is released from them."

Parratt & West C26,727/56: "When rat's skin is scraped to separate the subcutaneous layers completely from the outer epithelium, the major portion of the mast cells and histamine are removed with the inner scrapings. However, the 5–HT content of the outer epithelium greatly exceeds that of the scrapings, so that mast cells do not appear to be the only source of 5–HT in the skin of the rat. Similarly, in the feet, the skin of the pads contains fewer mast cells and less histamine than the dorsal skin but its 5–HT content is higher." Compound 48/80 and egg white produce anaphylactoid inflammation with MC discharge and the release of histamine plus 5–HT; rats pretreated with 48/80 no longer respond to egg white with an anaphylactoid inflammation presumably because of the preceding depletion in histamine and 5–HT. Reserpine, which also depletes the skin of 5–HT, does not markedly affect its histamine content and produces no edema. After reserpine, egg white also fails to produce edema,

although histamine is released. "Hence, both histamine and 5–HT need to be released to produce edema. This suggests that 5–HT is one of the mediators of the reaction of the skin to egg white."

Parratt & West C37,858/57: In the rat, the histamine content of various tissues runs parallel with the density of the MC population but this is not true of 5–HT. Furthermore, polymyxin can deplete the rat skin of its histamine content with little effect on 5–HT, while reserpine depletes 5–HT with little effect on histamine.

West C45,485/57: 5–HT is not concentrated in the MCs of the guinea pig, dog, man, cow, horse, rabbit, ox, hog, hamster, or cat. It may be partly associated with the MCs of the rat and mouse. The skin of the rat contains more than half of the total 5–HT in the body. This can be depleted by treatment with reserpine. On the other hand, the rat skin can be depleted of its histamine by treatment with polymyxin B.

Cass et al. C54,014/58: Painting of the skin with the carcinogen 9:10-dimethyl-1:2-benzanthracene resulted in a considerable increase in the local MC population within the dermis of the mouse. This was accompanied by a substantial increase in the 5–HT content of precancerous skin. In mice bearing a transplantable mastocytoma, the tumor tissue was found to be very rich in both 5–HT and histamine.

Riley C69,692/58: Painting of the skin with 9:10-dimethyl-1:2-benzanthracene in acetone causes a marked increase in the MC population of the dermis in the mouse. If such skin is treated with formaldehyde, there appears a brown fluorescent pigment which, judged by direct bioasay and paper-chromatography has been identified as the β-carboline of 5–HT.

Coupland & Riley D26,772/60: The MCs that develop in the dermis, following painting with 9:10-dimethyl-1:2-benzanthracene in the mouse, are very rich in 5–HT (demonstrated histochemically).

Carlini et al. F22,986/64: 5–HT is rapidly discharged from murine mastocytoma cells in vitro by chlorpromazine and repletion is also rapid. A slower time course of action is seen with reserpine. Presumably, the two drugs act through different mechanisms.

5–HT IN PLATELETS

Udenfriend & Weissbach B91,942/54: Blood platelets are very rich in 5–HT. After administration of radioactive 5–HTP, 5–HT is synthesized and incorporated into newly-formed platelets.

Benditt et al. C9,838/55: The demonstration of 5–HT in MCs suggests some relationship between these cells and the blood platelets.

5–HT SYNTHESIS BY MAST CELLS

Lagunoff et al. C33,258/57: A brief abstract suggesting, on the basis of in-vitro experiments, that the MCs of the rat can form 5–HT from 5–HTP.

Sjoerdsma et al. C48,610/58: Following 5–HTP administration, a significant elevation of 5–HTP was observed in murine MC-tumor tissue.

Hagen & Lee D27,085/58: Homogenates of mouse mastocytomas contain dopa-decarboxylase, histidine-decarboxylase, and 5–HTP-decarboxylase. By differential centrifugation all these enzymes were found to be located in the non-particulate cytoplasm. Dopamine was not detected. It is concluded that the MCs have the power of synthesizing both histamine and 5–HT.

Lagunoff & Benditt C68,450/59: 5–HTP-decarboxylase could be demonstrated in the isolated peritoneal MCs of the rat. The presence of this enzyme suggests that the MCs of the rat can synthesize 5–HT.

Day & Green D41,587/62: Neoplastic murine MCs take up tryptamine, tryptophan, and 3-hydroxytyramine from the culture medium in vitro.

SLOW-REACTING SUBSTANCE (SRS)

Review: *Benditt & Lagunoff* G10,074/64

Uvnäs & Thon D26,067/59: When isolated peritoneal MCs are exposed to histamine-discharging agents, SRS (slow reacting substance, that causes smooth muscle contraction) leaves the cells in amounts roughly proportional to the intensity of the histamine discharge. Apparently, the SRS originates in MCs.

Chakravarty et al. D26,476/59: In the perfused cat-paw preparation, "nonspecific enzyme inhibitors such as polysaccharides and 'polysalicylic acid,' and SH-blocking agents — such as allicin and iodoacetate — blocked the release of both histamine and 'SRS.' Heating of the paws to 45°C for 15 min. had the same blocking effect. The observations support the hypothesis that 48/80 releases histamine in the cat paw by activating an enzymatic mechanism and that 'SRS' is a product of the same or a similar mechanism."

Boréus & Chakravarty C86,027/59: When an anaphylaxis is produced in vitro in isolated guinea-pig tissues, histamine and slow reacting substance (SRS) are liberated in amounts proportional to the MC population of the region in question. Blocking of histamine and SRS production by enzyme inhibitors also prevents MC degranulation. "It is suggested that the tissue mast cells may be the common source of both histamine and 'SRS' in anaphylactic reaction."

Uvnäs D25,283/61: Considerable evidence has accumulated to suggest that SRS is released conjointly with histamine from the MCs.

Archer D26,443/61: When the isolated peritoneal MCs of the rat are treated in vitro with 48/80 in the presence of rat plasma, 5–HT or a similar substance (tested on the isolated rat uterus) is released. On the basis of bioassays, this substance is thought to be identical with SRS. Under similar circumstances SRS-like material was also released from MCs by mechanical disruption, distilled water, an extract of rat spleen, dextran, and human erythrocytes added to rat antiserum, all of which are known to disrupt MCs.

Uvnäs & Thon D26,478/61: In reviewing the possibility of SRS production by MCs, it is stated that "improved extraction procedures (to be published) have now enabled us to definitely establish the origin of this smooth-muscle-stimulating principle from such cells." [No experimental evidence in support of this statement is given, however, in the present communication. (*H.S.*).]

Uvnäs D64,029/63: SRS is released simultaneously with histamine from isolated rat MCs and perfused cat paws under the influence of 48/80. The SRS from these sources is identical or closely related with that released from sensitized guinea-pig lungs by antigen.

Änggård et al. D32,256/63: SRS principles are discharged from rat and cat MCs by 48/80.

ENZYMES

The histochemistry of MC enzymes has already been discussed (*p.* 50); hence, here we shall limit ourselves to conventional chemical studies.

Several investigators have confirmed the presence of trypsin-like proteolytic activity in MCs. It has been suggested that there may be two distinct enzymes of this type, "mast cell chymase" and "mast cell tryptase." In addition, MCs have been claimed to contain fibrinolysin (plasmin), hydroxylases, β-glucuronidase, dehydrogenase, esterases, monoamine-oxidase, diaphorase, lysolecithin, phosphatidase, phosphatase, ATP-ase, and a hyaluronidase inhibitor.

Reviews: *Smith* D63,031/63
Ende et al. F6,607/64

PROTEASES IN GENERAL

Lutzner F5,054/64: Alkaline protease could be demonstrated in isolated rat MC granules.

TRYPSIN, CHYMOTRYPSIN, MC CHYMASE

Benditt D28,269/56: An enzyme "with some properties resembling chymotrypsin" has been demonstrated in homogenates of rat feet-skin (which is rich in MCs), as well as in purified MCs isolated from the rat peritoneal cavity.

Schauer D39,984/62: Aminopeptidase activity is less pronounced in mouse mastocytomas than in normal MCs.

Lagunoff & Benditt D58,280/63: Isolated peritoneal MC granules contain a proteolytic enzyme which hydrolyzes casein, albumin, and insulin. It is named "mast-cell chymase." In addition to MC chymase, isolated peritoneal MC granules of the rat contain a second enzyme

which is homospecific for trypsin. If this second enzyme is separable from the chymase activity, it is proposed that it be called "mast-cell tryptase."

Perera & Mongar E27,298/63: A chymotrypsin-like enzyme was found in rat peritoneal MCs in fully activated form. "Since these cells retain their histamine intact it seems clear that the active chymotrypsin-like enzyme in the cells does not function as a histamine releaser."

Keller E29,395/63: "The influence of a number of inhibitors on the esterase, leucine aminopeptidase and adenosin triphosphatase of isolated rat mast cells has been investigated. The results support the assumption that the unspecific esterase is a chymotrypsin-like enzyme."

Änggård et al. D32,256/63: The chymotrypsin-like enzyme is discharged from cat and rat MCs by 48/80.

Mongar & Perera E32,256/63: The presence of a chymotrypsin-like enzyme in rat MCs is confirmed.

FIBRINOLYSIN (PLASMIN)

Ende & Auditore G4,543/61; D26,826/61: Dog mastocytomas contain a proteolytic substance that lyses heated bovine fibrin plates.

Ende & Auditore D43,914/61: Considerable fibrinolytic activity has been found in the capsule of human liver, which is rich in MCs.

Kwaan G17,226/64: Rat connective tissue and peritoneal MCs contain little fibrinolytic activity (plasminogen activator) as judged by histochemical studies although they do contain definite proteolytic activity. There is a close correlation between the localization of plasminogen activator and the presence of small blood vessels which are often surrounded by MCs. However, plasminogen activator is concentrated around small vessels, independently of the presence or absence of MCs. It is considered unlikely therefore, that the MCs provide the vessels with fibrinolytic enzyme and the high fibrinolytic activity of certain tissues rich in MCs is more probably due to the fact that MCs in small blood vessels rich in plasminogen activator occur together in tissues.

HYDROXYLASES

Jordon & Hartman G6,549/62: "A H_2O homogenate of the solid Furth mouse mastocytoma enzymatically hydroxylates C^{14}-phenylserine (PS) to p-hydroxyphenylserine (POPS) but not C^{14}-phenylalanine, nor does it decarboxylate the latter or PS." The author assumes "the identity of the enzyme with phenylalanine hydroxylase."

Levine et al. F5,784/64: Murine mastocytoma cells can hydroxylate tryptophan and phenylalanine in vitro.

Levine et al. D17,991/64: In canine mastocytomas, hydroxylation of tryptophan to 5-hydroxyindoles and of phenylalanine to tyrosine can be observed. This is apparently the first demonstration of tyrosine synthesis in a mammalian tissue other than liver.

β-GLUCURONIDASE

Lutzner F5,054/64: β-glucuronidase could be demonstrated in isolated rat MC granules.

HYALURONIDASE

Glick & Sylvén B59,009/51: A good deal of evidence suggests "that the native heparin-lipoprotein compound obtained from tissues rich in mast cells is a hyaluronidase inhibitor. It is possible that this, or part of this, heparin compound is responsible for the nonspecific hyaluronidase inhibition given by serum."

Glick et al. D39,641/58: A heat-stable hyaluronidase inhibitor could be demonstrated in isolated rat peritoneal MCs.

DEHYDROGENASES

Glick & Pothapragada D2,215/61: The isolated rat peritoneal MCs are rich in succinic dehydrogenase activity.

Schauer D39,984/62: Dehydrogenase activity is very intense in mouse mastocytomas.

ESTERASES, TAME-ase

Ende & Auditore G4,543/61: A dog MC tumor hydrolyzes p-toluenesulphonyl arginine methyl ester (TAME), while five other types of dog tumors failed to exhibit this effect.

Ende & Auditore D39,511/62: Tissues from a human spleen, with an unusual number of MCs, split TAME at a remarkable rate. Normal human spleens contain few MCs and do not hydrolyze TAME. Canine MC tumors split TAME at a much lower rate. Bovine liver capsule, with high populations of MCs, does not split TAME at an appreciable rate.

Schauer D39,984/62: Nonspecific esterase activity is hardly demonstrable in normal MCs, but very intense in mouse mastocytomas.

Katayama & Ende F4,764/64: Demonstration of ATEE and TAME-esterases in human splenic mastocytosis cells.

MONOAMINE OXIDASE

Schauer D39,984/62: Monoamine oxidase is demonstrable in mouse mastocytomas.

DIAPHORASE

Schauer D39,984/62: DPN diaphorase activity is present in mouse mastocytomas.

PHOSPHATIDASE, LYSOLECITHIN

Keller D60,849/62: Normal rat peritoneal MCs contain much lecithin and little lysolecithin, while the reverse is true of MCs degranulated by 48/80 or anaphylaxis. It is assumed that, during MC degranulation, lecithin is transformed into lysolecithin.

Keller E32,257/63: During anaphylaxis, lysophosphatides are formed in the rat MCs.

Änggård et al. D32,256/63: A phosphatidase-A-like enzyme is discharged from cat and rat MCs by 48/80.

PHOSPHATASE, ATP-ase

Lennert & Schubert D33,718/61: Adenosinetriphosphatase (ATP-ase) is present in the blood basophils and tissue MCs of human bone marrow.

Schauer D39,984/62: Phosphatase and ATP-ase activity are less intense in mouse mastocytomas than in normal MCs.

DECARBOXYLASES

Hagen & Lee D27,085/58: Murine MCs contain an enzyme capable of converting 5–HTP to 5–HT.

Lindell et al. D65,656/59: As judged by incubation with radioactive histidine, a canine mastocytoma contained large amounts of histidine-decarboxylase and was capable of synthesizing histamine. "This is considered additional evidence that mast cells form histamine and not merely store it."

Hagen et al. D63,087/60: Mouse mastocytomas contain dopa and histidine-decarboxylase, but no detectable cysteic-acid-decarboxylases or glutamic-acid-decarboxylases.

Birt et al. D65,257/61: Evidence of the presence of both histidine-decarboxylase and 5–HTP-decarboxylase has been investigated in a solitary urticaria pigmentosa lesion removed from the thigh of a two-year-old boy. Although an active histidine-decarboxylase was found, no 5–HTP-decarboxylase activity could be detected. "This result supports the previously held opinion that human mast cells lack the capacity to synthesize serotonin."

Weissbach et al. D33,695/61: Histidine-decarboxylating enzymes have been demonstrated in extracts of mouse mastocytoma tissue.

Demis et al. G11,134/61: Homogenates of mastocytosis skin lesions were incubated with radioactive 5–HTP and dopa. There was no significant formation either of 5–HT or dopamine under incubation conditions which allowed formation of significant quantities of histamine. Since such homogenates are highly active in decarboxylating histidine, it seems unlikely that a general amino-acid-decarboxylase is active in human MCs. Here, the characteristic enzyme seems to be a specific histidine-decarboxylase.

Lindell et al. D26,738/61: The histidine-decarboxylase activity of the skin lesions in mastocytosis is apparently increased, since studies with radioactive histidine show that homogenates of such skin lesions transform the compound into histamine.

Day & Green D41,586/62: Mastocytoma-tissue cultures contain a decarboxylase capable of converting 5–HTP to 5–HT.

Aures et al. G7,584/62; *Aures & Clark* E27,333/63: Histidine-decarboxylase prepared from mouse mastocytoma tissue was inhibited by several enzyme inhibitors. The strongest inhibitor tested to date was 3-hydroxy-4-bromobenzyloxamine, H_2PO_4.

Werle et al. E28,902/63: Mouse mastocytoma tissue is rich in histidine-decarboxylase.

Schayer D58,278/63: Review of the literature and personal observations lead to the conclusion that MCs "are the only mammalian cells in which the presence of histidine-decarboxylase has been demonstrated rigorously."

Demis E24,240/63: Homogenates of the skin lesions from patients with cutaneous mastocytosis were incubated with radioactive histidine and shown to form significant quantities of histamine, presumably under the influence of a decarboxylase. This enzyme tissue appears to be a specific histidine-decarboxylase since α-methyl dopa — a known inhibitor of general mammalian decarboxylase — failed to produce significant inhibition of histamine formation in homogenates of human mastocytosis tissue.

Aures & Clark D18,341/64: Demonstration of histidine decarboxylase in murine mastocytoma cells using a rotating diffusion chamber for $C^{14}O_2$.

Ultmann et al. G19,654/64: The enlarged spleen of a patient with systemic MC disease contained a greatly-increased amount of histidine-decarboxylase activity.

VARIOUS OTHER COMPOUNDS

CEREBROSIDES

Green et al. D47,977/62: Cerebroside is demonstrated in the cells of murine mastocytomas.

LECITHIN

Keller D60,849/62: Normal rat peritoneal MCs contain much lecithin and little lysolecithin, while the reverse is true of MCs degranulated by 48/80 or anaphylaxis. It is assumed that, during MC degranulation, lecithin is transformed into lysolecithin. Cephalin could not be identified in normal degranulated rat peritoneal MCs.

PHOSPHATIDYL CHOLINE

Änggård et al. D32,256/63: Phosphatidyl and phosphatidyl choline are discharged by 48/80 in cat and rat MCs.

NUCLEOTIDES, ATP

Korn D66,466/59: Derivatives of adenine, guanine, cytosine, and uracil could be chromatographically separated from an extract of murine mastocytoma.

Pasternak D67,481/60: "The high speed supernatant fraction of P–815 mast cell tumor, grown in solid or ascitic form, catalyzes the synthesis of 3'-phosphoadenosine 5'-phosphosulfate from adenosine triphosphate and sulfate."

Ringertz D67,467/60: In-vitro studies of the "supernatant fractions" of murine mastocytomas, revealed that "adenosine-5'-phosphosulphate (APS) synthesized by the carbodiimide method, was found to be an intermediate in the sulphation of mast cell tumor polysaccharides. Adenosine-3'-phosphate, -5'-phosphosulphate (PAPS, "active sulphate") was identified as a reaction product from the phosphorylation of APS by an APS-kinase present in the tumour."

Green et al. D47,977/62: ATP is demonstrated in the cells of murine mastocytomas.

Witthaus E38,878/63: "The free nucleotides of the P–815 mastocytoma cultured in vitro were determined with the aid of anionic exchange chromatography. The tumour cells contain the mono-, di- and triphosphates of adenosine, guanosin, cytidine and uridine and uridine diphosphate derivatives."

Batz et al. D18,542/64: "Two podophyllum preparations with spindle poison activity, were tested for their effect on ^{3}H-thymidine incorporation into P–815 mastocytoma cells in vitro. Concentrations which inhibited cell multiplication completely did not affect DNA-synthesis as measured by thymidine incorporation."

NEURAMINIC ACID

Green et al. D47,977/62: Neuraminic acid is not demonstrable in the cells of murine mastocytomas.

IMIDAZOLACETIC ACID

Hanson D39,623/57: In two cases of urticaria pigmentosa, the urinary elimination of imidazolacetic acid was greatly increased (in one case up to 2,600 μg per 24 hours).

CYSTEIC ACID

Green et al. D47,977/62: Cysteic acid is demonstrated in the cells of murine mastocytomas.

TAURINE

Green et al. D47,977/62: Taurine is demonstrated in the cells of murine mastocytomas.

CHONDROITIN SULFATE

Rodén & Dorfman D65,652/59: Chondroitin sulfuric acid A and/or C has been extracted from the Furth type of mouse mastocytoma.

Jorpes E4,171/63: A review of the literature shows that MC tumors contain only traces of chondroitin sulfuric acid which are probably derived from the connective tissue of the stoma elements.

Asboe-Hansen & Clausen F16,673/64: Paper-electrophoresis of urinary concentrates from patients with urticaria pigmentosa revealed the presence of chondroitin sulfate and a chemically-changed (depolymerized?) hyaluronic acid, but no heparin.

DOPA

Day & Green D41,586/62: α-Methyldopa inhibits the uptake and decarboxylation of 5–HTP, but not of histidine, by neoplastic murine MCs in vitro.

Green & Day D58,290/63: Studies on dopa metabolism in murine neoplastic MCs in vitro.

Smith D63,031/63: Discussion of the presence of dopamine in MCs.

HYALURONIC ACID

(Cf. GROUND SUBSTANCE AND HYALURONIC ACID FORMATION, *p.* 372.)

HEXOSAMINE

Benditt et al. D31,573/56: On the basis of estimations of isolated rat peritoneal MCs, it is concluded that these contain approximately 11 μg of hexosamine per mm^3.

Parekh & Glick D27,898/62: Technique for the analysis of hexosamine by Exley's method in the peritoneal MCs of the rat.

LIPIDS

Herzberg D39,565/59: Discussion of blood lipids.

Fernex D39,200/62: The blood cholesterol drops in urticaria pigmentosa, presumably the result of increased heparin formation.

Bank & Marks D35,275/63: Pronounced steatorrhea in a woman with generalized urticaria pigmentosa was unaccompanied by any increase in the intestinal MC population.

Änggård et al. D32,256/63: Unsaturated fatty acids are discharged from cat and rat MCs by 48/80.

AMYLOID

Rukavina et al. E36,437/57: Simultaneous occurrence of urticaria pigmentosa and primary systemic amyloidosis in a patient suggests that the MCs may participate in the production of amyloid.

CALCIUM

Hissard et al. D39,769/51: A case of urticaria pigmentosa with hemorrhagic tendencies in which the blood calcium is 15 mg per cent.

Sirois E31,826/63: In a man with generalized mastocytosis, there was also osteosclerosis and hypocalcemia.

Bank & Marks D35,275/63: In a woman with generalized urticaria pigmentosa, steatorrhea, and bone lesions, the blood calcium was so low that tetany could be prevented only by the administration of vitamin D_2.

ZINC

Kerp & Steinhaeuser E24,263/61: Chemical studies revealed that heparin can bind histamine even at a near-physiological *p*H in the presence of zinc which acts as a bridge between the two organic compounds.

Kerp E32,807/63: Apparently histamine is stored within MCs in the form of ternary heparin-zinc-histamine complexes, because there are great quantities of zinc besides histamine and heparin in the granules of MCs. This view is further substantiated by experiments in vitro which showed "that great quantities of histamine may be bound by heparin at physiological *p*H in presence of zinc."

IRON

Bank & Marks D35,275/63: In a woman with urticaria pigmentosa, bone lesions, and steatorrhea, the serum iron content was low and eventually severe anemia developed.

6

The Blood Basophil

MONOGRAPHS AND REVIEWS ON BLOOD BASOPHILS IN GENERAL

MONOGRAPHS and reviews which deal with the morphology, physiology, and pathology of the blood basophils in general, are merely listed here in chronologic order:

Graham G3,076/20
Jolly D51,788/23
**Boseila* C68,531/59
Braunsteiner D59,693/59
Fredricks & Moloney D84,020/59
Braunsteiner & Zucker-Franklin E55,512/62
Padawer G5,248/63
**Shelley* G18,654/64

HISTORY

It was in 1879, two years after the discovery of the MCs, that Ehrlich first noticed the presence of cells with metachromatic granules in circulating blood. These he called "blood mast-cells," and with singular insight he immediately recognized that, unlike the ordinary MCs which arise locally in connective tissue, those of the blood are derived from the bone marrow.

In 1898, Ehrlich and Lazarus observed that in chronic myeloid leukemia the basophil count is usually increased, thereby demonstrating the participation of this cell in a naturally-occurring disease of man. This finding was subsequently confirmed by numerous other investigators who also showed that in some instances basophilic leukemia may assume the aspect of a separate disease entity.

It was not until some seventy years after the discovery of the "blood mast-cell" that its high histamine and heparin content was noted, thus further emphasizing the close relationship between this blood-borne element and its sessile counterpart, the tissue MC.

At present, much of the work in this field is concerned with the elucidation of the part played by basophils in allergic phenomena and the regulation of lipid metabolism. The changes in basophil count that occur under the influence of spontaneous diseases or experimental procedures are also under active study.

As we look back upon the historic development of our knowledge on basophils, it is striking that although these cells possess essentially the same properties as tissue MCs, our understanding of them lagged behind that of the MCs in almost every respect. This is because the blood contains so few basophils that only modern techniques for their concentration and isolation permitted the study of these elusive cells.

Ehrlich D27,092/1879: Cells with metachromatic granulations appear not only in tissues but also in the circulating blood. These are described as "blood mast-cells" and are thought to be derived from the bone marrow.

Ehrlich & Lazarus D50,996/1898: First observation of the fact that, in chronic myeloid leukemia, the blood-basophil count is usually increased.

Levaditi G18,721/01: Confirmation of earlier observations concerning the development of basophilia in chronic myeloid leukemia.

Wolff E48,694/03; G17,715/04: Early description of human blood basophils.

Pappenheim G19,254/05: Detailed description and lithographic illustration of human basophils.

Türk G19,257/05: Early description of blood basophils for which the term "Mastzellen" should be reserved.

Graham et al. D28,268/52; C9,304/55: First demonstration of a high histamine content in blood basophils.

Behrens & Taubert D30,378/52: Evidence suggesting that the basophils are rich in heparin-like material.

HISTOLOGY

The blood basophil resembles the tissue MC in many respects, especially in that they both contain metachromatic granules which are rich in histamine and heparin. However, the basophil is usually smaller, measuring only about 10 μ in diameter and its granules are more water-soluble. The nucleus is rather polymorph and often exhibits a characteristic "S"-shape with two or more constrictions which give it a lobulated appearance similar to that of other polymorphonuclear leukocytes. The chromatin network is somewhat looser than in eosinophils and there are no nucleoli.

In man, the basophils represent less than 0.5 percent of all leukocytes and, hence, various special techniques had to be devised to obtain statistically-significant counts. For example, it is possible to concentrate the leukocytes by filtration in a liquid fixative or by differential centrifugation which separates them from the heavier erythrocytes. Counting (in specially-constructed chambers) can also be facilitated by procedures which destroy nuclear staining without affecting that of the metachromatic granules.

Histochemical studies suggested that the metachromatic granules contain heparin, but the presence of hyaluronic and chondroitin-sulfuric acids has not yet been definitely demonstrated. There is also some difference of opinion concerning the glycogen content of basophils, but it has been suggested that in these cells it is loosely attached to heparin.

The electron microscope revealed allegedly-characteristic lammellae in the bone-marrow basophils of the guinea-pig, but comparatively little is known as yet about the ultrastructure of blood basophils.

As viewed with the phase-contrast microscope, the human basophil possesses only a sluggish motility in which the nucleus leads the forward movements. The granules are nonrefractile and, upon vital staining with neutral red, they assume a pale pink or brick-red color. The mitochondria are scarce, nonrefractile, and not stainable.

Little is known about the histophysiology of the basophil beyond the fact that it is of myeloid origin and tends to discharge its granules under the influence of histamine liberators and various allergic reactions. After glucocorticoid-induced basopenia, regeneration is slow, suggesting gradual neoformation from the bone marrow rather than immediate regranulation.

GENERALITIES, CLASSIFICATION, TERMINOLOGY

Arneth D63,797/20: Like the polynuclear leukocytes, the human MCs can be classified into four groups ("Arneth count") according to the structure of their nucleus.

Michels C72,066/38: The terms "basophil," "blood mast cell," and "mast leukocyte" are synonymous.

Ferràta & Storti E2,368/46: MCs can be distinguished from blood basophils on morphologic grounds. The basophil is usually smaller than the MC and unlike the latter it possesses a lobulated nucleus. The granules are soluble in water and methyl alcohol and do not give the characteristic Hale reaction of ordinary tissue MCs. Also unlike the MCs, the basophils are usually PAS-negative. Occasionally, some of the basophil-cell granules are sudan-B positive.

Undritz B56,478/50: The metachromatic granules of the blood basophils can best be demonstrated by staining with toluidine-blue or the Pappenheim technique, but they are washed out if the simple Giemsa stain is used.

Dantchev D53,654/52: In certain cases of basophilic leukemia there are basophils which also contain eosinophilic granulations ("eosinobasophils") which suggests a close relationship between eosinophils and basophils.

Osgood et al. D62,861/54: In man, the life span of blood basophils (like that of eosinophils) has been estimated to be about 8–12 days.

Maximow & Bloom C50,889/57: In human blood, the basophils represent only about 0.5 per cent of the total number of leukocytes. On dry-smear preparations they measure about 10 μ in diameter. The nucleus is elongated and often bent in the form of an "S" provided with two or more constrictions. The chromatin network is somewhat looser and less tingible than in eosinophils and there are no nucleoli. In the living cell, the granules have a low refractive index. In man, their substance is water-soluble but they can readily be demonstrated in dry smears or sections, fixed in alcohol, as round metachromatic bodies. Supravital staining with neutral red imparts a dark-red color to the granules.

Thonnard-Neumann C59,519/58: Three forms of blood basophils are distinguished in man according to the distribution of the granules: (1) Only in the periphery of the cytoplasm; (2) in the periphery and, to a lesser extent, in the nuclear region; (3) diffusely throughout the cytoplasm covering the nucleus.

Boseila C68,531/59: In the fixed stage, mammalian basophils exhibit a certain polymorphism of the nucleus which is often S-shaped, oxyphilia of the cytoplasm, and basophilia with metachromasia of the specific granules. Although even in his earliest publications Ehrlich emphasized the water-solubility of the granules, disregard of this fact has led to many errors of interpretation. The following technique is preferred: "Alcoholic fixatives and staining solutions are generally recommended. The author used to fix air-dried blood and bone-marrow smears in absolute methanol for 10–20 minutes. For staining, a 1% toluidine blue solution in 60% alcohol was used for 30–60 minutes, followed by 30 seconds' rinsing in 50% alcohol, then drying. Whereas the granules stain purple red, the nucleus as well as the nuclei of other leucocytes stain faintly blue, a contrast that makes it easy to identify the basophils even when using a low magnification. For human blood, containing few basophils, a thick smear is recommended."

Juhlin E99,930/63: "According to size, staining properties and location of the granules, the basophils were divided into 18 groups to establish a basophil differential. The mean basophil differential in various disorders studied did not vary as compared to that in healthy subjects."

Juhlin E98,089/63: In patients suffering from various diseases, no correlation was found between the percentage of basophils in blood and bone marrow.

ISOLATION, FIXATION, COUNTING

Alder D27,431/22–23: The mean number of basophils in human blood is 35 cells/cm^3, which corresponds to 0.45 per cent of the leukocytes.

Moore & James D27,613/53: A method for the differentiation and enumeration of basophils in a counting chamber. The mean basophil count per mm^3 was found to be 46.7 in men and 46 in women. The difference was not statistically significant.

Boseila C68,531/59; D78,510/59: In man, the average basophil count is 38.3 $\pm$ 2.4/mm^3 while in the rabbit it is 516.4 $\pm$ 10.8/mm^3 of blood.

Juhlin & Shelley D51,133/61: A simple plastic-tube centrifugation method is described for the fractional harvesting of viable leukocytes from 10 ml of human blood. The leukocytes, being lighter than the erythrocytes, can be concentrated ten-thousand-fold.

Piette & Piette E89,770/62: Following a critical evaluation of current methods for the counting of basophils, a new technique is described: Staining is performed in a relatively

anhydrous medium, this being followed by dilution in saline solution which destroys nuclear staining without affecting that of the metachromatic granules. After this, counting in a Nageotte chamber is comparatively easy.

Shelley & Juhlin D41,202/62: A simple method is described for the rapid liquid fixation, concentration, and staining of blood basophils in man and experimental animals.

Shelley D58,295/63: Two methods for the isolation of basophil leukocytes are described, one being based on filtration in a liquid fixative, the other on centrifugation.

HISTOCHEMISTRY

Heparin, hyaluronic acid, chondroitin sulfuric acid

Laves & Thoma D31,583/50; G18,725/50: Histochemical studies on the basophils of rabbits and guinea-pigs suggest the presence of a heparin-like polysulfuric-acid ester in the basophilic granules.

Astaldi et al. D39,707/53: In the basophils of a case of basophilic leukemia, a hyaluronic acid has been identified with histochemical techniques.

Turchini & van Kien D88,984/55: Heparin, and perhaps also hyaluronic acid, is present in human basophils as judged by histochemical observations.

Piette & Piette D78,336/56: In normal man, a larger number of blood basophils stains metachromatically than with the PAS-procedure. Stainability with PAS is abolished by amylase. The difference in the stainability of the granules is ascribed to varying concentrations of heparin (perhaps also chondroitin sulfuric acid) and glycogen.

Glycogen

Wislocki et al. D28,970/49; Smith D85,923/49: Using the PAS-reaction and saliva digestion, human basophils are found to contain glycogen.

Astaldi et al. D39,707/53: Earlier findings concerning the glycogen content of blood basophils could not be confirmed.

Piette & Piette D78,336/56: In the basophils, glycogen is allegedly present in weak combination with heparin.

Peroxydase

Graham G3,076/20: Unlike the other granulocytes, the basophils are often peroxydase-negative.

Lennert & Schubert D33,718/61: Unlike MCs, the blood basophils are peroxydase-positive.

Phosphatase

Wachstein G18,688/46: The cytoplasm or basophils is devoid of alkaline phosphatase demonstrable by the Gomori method.

Gomori B73,271/52: No alkaline phosphatase could be demonstrated in basophils by the Gomori method.

Various other compounds

Laves & Thoma D31,583/50: Histochemical studies on the basophils of the rabbit suggest the presence of ribonucleic acid in these specific granules.

Amann & Wolff E35,029/56: Histochemical demonstration of copper and zinc in the basophil leukocytes of man.

Ackerman D58,292/63: Extensive histochemical studies on the basophils of the rabbit, guinea-pig, and man, with special emphasis upon protein, nucleic acid, glycoprotein, mucopolysaccharide, lipid, and enzyme content.

ELECTRON-MICROSCOPY

Winqvist E43,466/60: The electron-microscopy of the guinea-pig bone-marrow basophils is described. A characteristic feature is the lamellated structure of the basophil granules which have a slight resemblance to the concentric lamellae of cat eosinophils but, unlike the latter, they are not concentric but parallel in arrangement. Some earlier investigators reported a similar structure, while others found only homogeneous granules or reticular tissue and, presumably, fixation plays an important role here.

Winqvist D58,291/63: Electron-microscopic studies revealed that the granules of the guinea-pig basophils have a very specific ultrastructure with complex lamellation. Experiments, designed to liberate histamine, did not result in any change in the appearance of the basophilic granules. (*Figs. 24–27, pp. 336, 338, 340* and *344.*)

VITAL AND SUPRAVITAL STAINING

Sabin G16,025/23: First systematic studies on living human basophils.

Michels C72,066/38: Review of early literature on the vital and supravital staining of basophils.

PHASE-CONTRAST MICROSCOPY

Ackerman & Bellios D20,145/55: Phase-contrast microscope studies on the morphology of the living human basophil in "vital films" led to the conclusion that this is the smallest of the granulocytes (10–15μ) with a sluggish motility. While in other granulocytes, cytoplasmic pseudopodia lead the forward movements, in basophils the nucleus is in the lead. In living preparations, the nucleus is band-shaped or bilobed with a dense and irregular chromatin pattern and a thin nuclear membrane. The granules are non-refractile, oval, spherical, or irregular in shape. Their size varies between 0.3 and 0.8μ. They stain pale pink or brick red with neutral red. Mitochondria are scarce, non-refractile, and not stainable. They are usually scattered diffusely throughout the cytoplasm, ovoid in shape and measuring 0.2–0.3μ in diameter.

HISTOPHYSIOLOGY

Ferràta & Golinelli D59,519/10; *Maximow* D29,280/13; *Downey* D27,880/14: Histologic studies suggest that the blood basophil is of myeloid origin, thus confirming Ehrlich's earliest hypothesis.

Boseila C59,059/58: Following cortisone-induced basopenia in the rabbit, the basophils do not attain the control values until after about two weeks. This suggests that regeneration occurs as a result of slow neoformation of basophils from the bone marrow rather than of immediate regranulation.

EMBRYOLOGY

In man, basophils first appear in the blood at about the third month of embryonic development, together with other types of granulocytes. They develop from promyelocytes by the gradual accumulation of metachromatic granules and segmentation of the nucleus.

Saeki D78,337/52: The development of blood basophils is followed in liver smears of 6–10-week-old human embryos from the promyelocyte to a segmented cell.

Dantchev D53,654/52: During the course of differentation, the metachromatic granules of the blood basophils increase gradually until they prevail.

Arey E4,225/54: In man, basophils first appear in the blood of 3-month-old embryos simultaneously with other types of granulocytes. Postnatally, the red marrow eventually serves as the only source of basophils.

COMPARATIVE ANATOMY

Cells which possibly correspond to basophils have been observed in the blood of invertebrates and they are apparently present in all vertebrates, although their number is subject to great variations. In many, though by no means in all species, there exists an interesting inverse relationship between the tissue-MC density and the blood-basophil count. For example, in the rabbit and in many birds and lizards, the basophil count is unusually high (10–40 per cent), while tissue MCs are sparse. Conversely, in the guinea-pig, cat, rat, man, and in fish, basophils are rare (0.1–0.7 per cent) while tissue MCs are plentiful.

Betances G11,140/21: Basophils are present in the blood of *Astacus*.

Zotta D27,503/22: Blood basophils are found in various insects such as *Carausius morosus, Truxalis nasuta,* various locusts, *Mantis religiosa, Philium sp.*, and *Cyphocrania gigas* (in *Orthoptera*, 10–13 per cent).

Undritz 98,255/46; B56,478/50: Blood basophils have been found even in invertebrates (e.g., butterflies) as well as in most of the lower vertebrates examined.

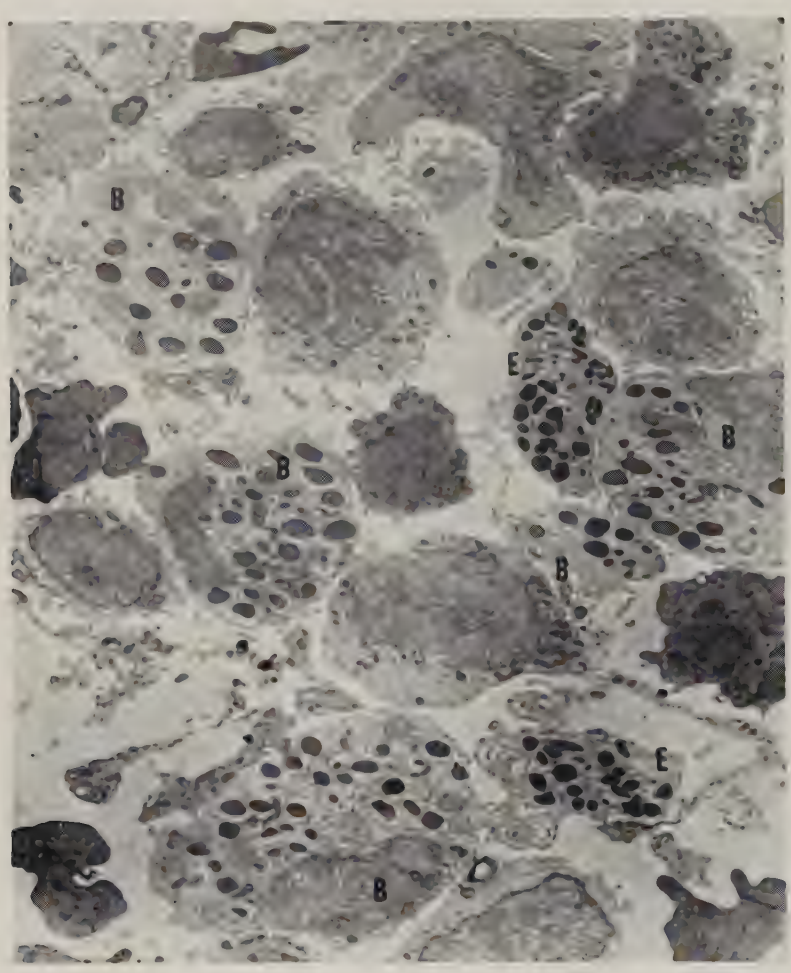

Figure 24.—Section of guinea-pig bone marrow with experimentally-increased number of basophils (B) *and eosinophils* (E). (Dalton's chrome-osmium fixative. Methacrylate. No stain. X 4,200. Siemens' Elmiscope I.) [After *Winqvist,* unpublished.]

Maximow & Bloom C50,889/57: In the guinea-pig, the granules of basophil leukocytes are large, oval, and soluble in water. They stain only faintly. In the dog, the granules are fine and assembled in a small compact group. In the cat, rat, and mouse, basophils seem to be absent from the blood under normal conditions.

Boseila C68,531/59: There exists an interesting inverse relationship between the tissue-MC density and the blood basophil count in various species as visualized by the following table:

Occurrence of blood and tissue mast cells in different animals

	Blood mast cells (Basophil leukocytes)	Tissue mast cells
Mammals:		
Man	0.35–0.5%	many
Rabbit	4.0–12.0%	comparatively few
Guinea-pig	0.7%	many (body wall and omentum)
Dog	0.7%	many (liver)
Cat	0.1%	very many (lymph nodes)
Rat and Mouse	0.5%	extraordinarily numerous (peritoneal and cavity)
Lower vertebrates:		
Birds	17.0–23.0%	sparse
Lizards	41.0%	extremely numerous
Frogs	5.0–23.0%	extremely numerous
Fish	rare	massive aggregations (mesentery and peritoneum)

Kelly et al. E43,287/61: In a series of 29 post-hibernation, horned lizards (*Phrynosoma cornutum*), the mean blood-basophil count was only about 8 per cent of the leukocytes. Mast cells were not especially numerous in the tissues and were entirely absent from the peritoneal fluid. It is possible that the higher counts reported by earlier investigators may have been due to seasonal variations.

AGENTS INFLUENCING THE BLOOD BASOPHILS
(Cf. also DISEASES, *p.* 351)

ACTH, glucocorticoids, and exposure to *stress* cause basopenia simultaneously with eosinopenia. The same has been claimed for *thyroxin,* but this has been challenged. Acute treatment with *heparin* is said to induce basophilia, while the longer-lasting effect of depot heparin results in delayed basopenia, which reaches its lowest point only after a few days.

Several *histamine-liberators* and particularly compound 48/80 have been shown to induce basopenia in vivo and degranulation of isolated basophils in vitro.

Basopenia has also been produced by *colchicine, rattlesnake venom,* and various *other drugs,* but since all severe stressors decrease the basophil count, the specificity of drug actions is difficult to ascertain in this respect.

Various *allergic reactions* to vaccines, sera, and other antigens are associated with basophilia and eosinophilia. This may be accompanied by a decrease in blood-clotting time and a rise in the histamine content of the bone marrow, possibly owing to the formation of heparin and histamine by basophils. On the other hand, during anaphylactic shock there is a brief but pronounced basopenia, and the basophils of sensitized individuals discharge their granules in vitro upon the addition of the appropriate antigen to the suspension medium. In fact, such in-vitro tests may have diagnostic value in the detection of hypersensitivity.

Alimentary *hyperlipemia* is frequently associated with degranulation of the blood basophils. This response has been considered to be of adaptive value since heparin exerts a blood-lipid clearing effect.

No significant *diurnal variations* or *sex differences* in the basophil count have been observed although, in women, certain fluctuations do allegedly occur depending upon the *menstrual cycle.* During *pregnancy,* basopenia has been observed both in rabbits and in women. *Age* does not significantly affect the blood-basophil count.

HORMONES

Review: *Boseila* D58,293/63

ACTH, glucocorticoids

Code et al. D30,193/54; *James et al.* D27,395/55: Cortisone causes basopenia simultaneously with eosinopenia in healthy human beings. This suggests a relationship between basophils and eosinophils.

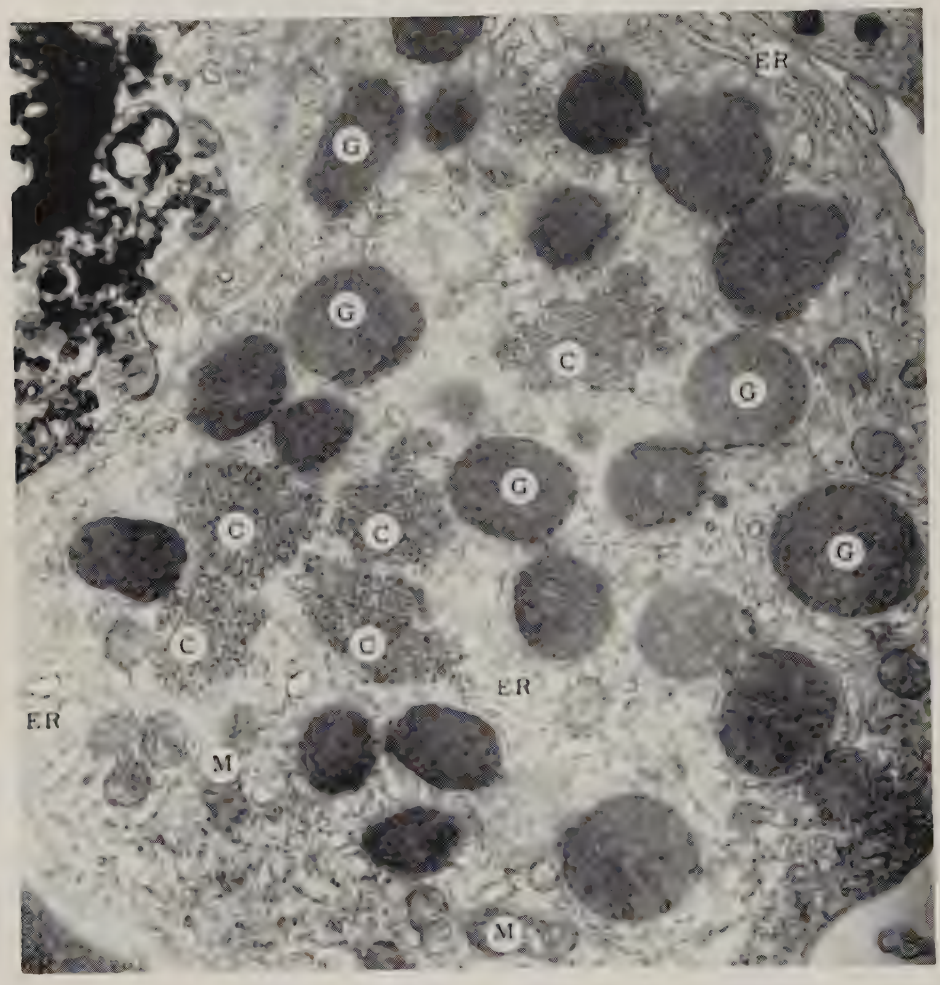

Figure 25.—Basophilic myelocyte of guinea-pig in mitosis. Specific granules (*G*), endoplasmic reticulum (*ER*), mitochondria (*M*), chromosomes (*C*). (One per cent OsO_4 buffered to *p*H 8.5 Epon. Uranyl acetate. X 15,000. Siemens' Elmiscope I.) [After *Winqvist,* unpublished.]

Code & Mitchell C34,861/57: The basophil and eosinophil count was decreased under the influence of cortisone in the dog, guinea-pig, and man. In the dog and man, the blood-histamine content was also diminished, but in the guinea-pig this change was inconstant.

Braunsteiner & Thumb C62,702/58; C89,221/58: Cortisone and other glucocorticoids produce basopenia in man.

Boseila & Uhrbrand E45,649/58: ACTH causes a basopenia in man, although it is less marked than the eosinopenia.

Thonnard-Neumann C59,519/58: ACTH causes a parallel decrease in basophils and eosinophils in women.

Boseila C60,944/58; C59,059/58; C68,531/59: ACTH i.m. produces significant basopenia within four hours in the rabbit. The count returns to normal within 24 hours. Prolonged treatment with ACTH s.c. causes a steady basopenia. Cortisone also induces basopenia in the rabbit.

Hecker et al. E94,745/60: Prednisone causes basopenia in man.

Braunsteiner et al. E52,570/60: Treatment with ACTH in various glucocorticoids causes basopenia in man.

Juhlin D65,336/63: Following ACTH treatment, there is an initial eosinopenia within the first four hours, followed by a less pronounced basopenia in man. There is no increase in degranulation of basophils during treatment. The percentage of bone-marrow basophils does not decrease. Essentially similar results were obtained by treatment with prednisone, but in two patients treated with very large doses of this steroid, the bone-marrow basophils decreased considerably.

Juhlin D62,609/63: ACTH causes basopenia as well as eosinopenia in patients with ulcerative colitis.

TSH, thyroid hormones

Camerada & Leo D20,047/55: Thyroxin i.m. causes eosinopenia and basopenia in man.

Boseila & Moltke C59,062/58: In rabbits, daily i.m. injections of thyroxin induce a steady and linear increase in basophils which continues for two days after interruption of treatment. The discrepancy between these findings and the results of earlier investigators may be due to differences in dosage and in the animal species used. As judged by studies with I^{131}, the thyroxin-induced basophilia is associated with a decrease in thyroid activity and may be the result of decreased TSH-production.

Boseila C68,531/59: Thyroxin produces basophilia in the rabbit, parallel to a decrease in the rate of thyroid function as reflected in the reduction of radioactive iodine in their plasma.

Cavazzuti et al. C73,006/59: Both in the hyperthyroid patient and in the rabbit, treatment with the antithyroid drug 1-methyl-2-mercaptoimidazole increases the basophil count. Conversely TSH or thyroxin causes basopenia in hypothyroid patients and in the rabbit.

Boseila et al. C76,463/59: D-thyroxin causes basophilia without any significant change in the number of circulating eosinophils or the total leukocyte count in man. The serum-PBI does not rise significantly. Conversely, L-thyroxin induces only slight changes in the basophil count and a significant rise in serum-PBI. Possibly, the basophils are "controlled by a balance action of circulating thyrotrophic and thyroid hormones."

Sex hormones

Thonnard-Neumann C59,519/58: Treatment with estradiol benzoate increases the mean basophil count in women. However, following prolonged estrogen treatment, a reversed effect may be seen.

Potuzhek et al. E53,262/59: Estrogens and androgens cause no significant change in the basophils of women, while progesterone causes a probably significant but slight basophilia.

Thumb et al. C73,066/59: Mild eosinopenia is occasionally seen following treatment of women with progesterone.

Other hormones and tissue extracts

Pröscher D27,970/09: In the rabbit, carcinoma extract i.v. induces intense blood basophilia.

Braunsteiner & Thumb C89,221/58: Adrenaline caused no significant change in the basophil count in man.

Yanagihara C58,484/58: Insulin causes a parallel decrease in basophils and eosinophils in the rabbit.

Ricci et al. D66,411/63: Insulin causes basopenia simultaneously with eosinopenia in diabetis mellitus.

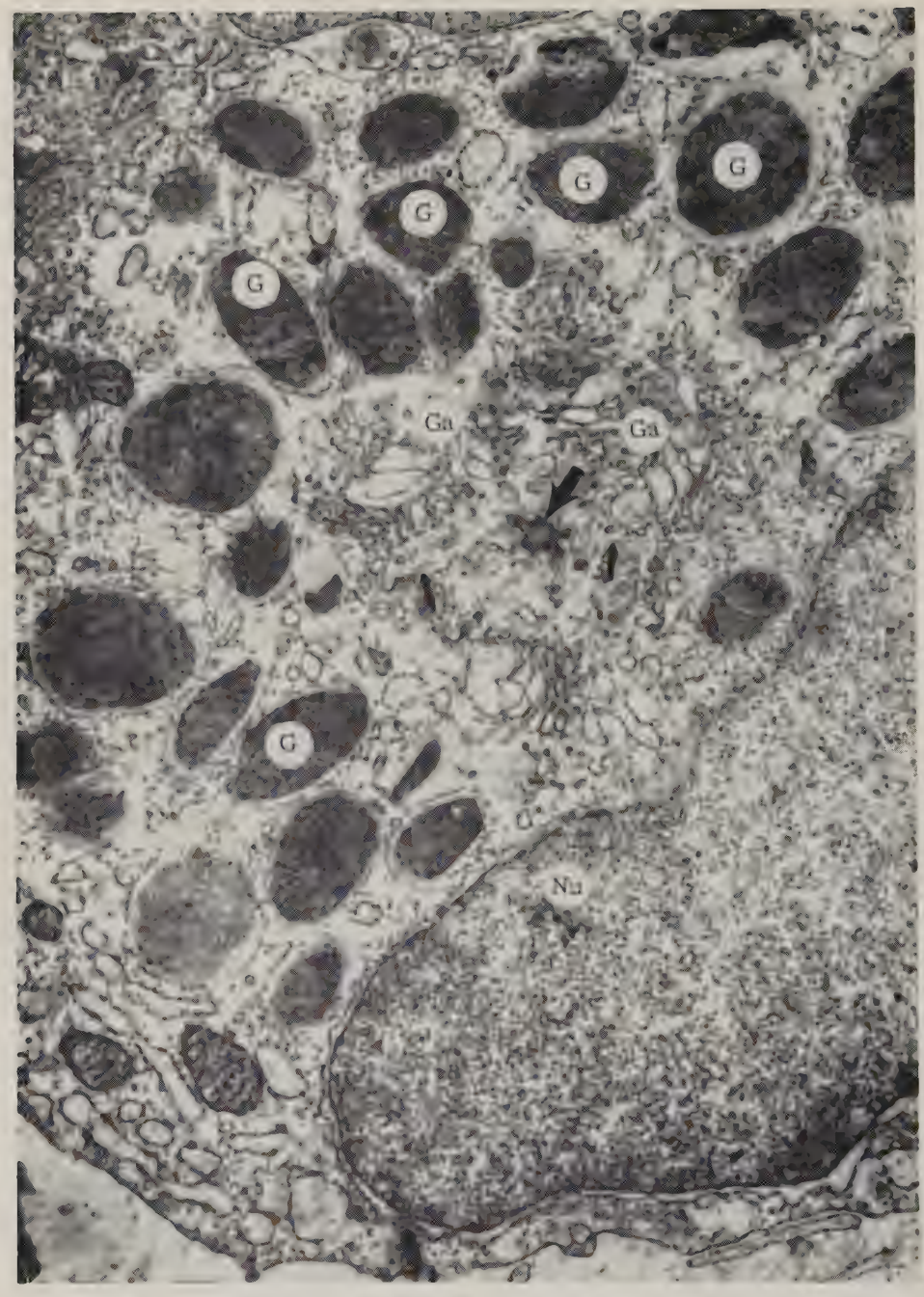

Figure 26.—Basophilic myelocyte of guinea-pig with one of the centrioles (large arrow). Note microtubules (*small arrows*) radiating from the centriole and subdividing the Golgi apparatus (*Ga*) into sector-like compartments. Basophilic granules (*G*) are situated around the Golgi apparatus near nucleus (*Nu*). (One per cent OsO_4 buffered to *p*H 8.5. Epon. Lead acetate. X 24,000. Siemens' Elmiscope I.) [After *Winqvist,* unpublished.]

DRUGS

Mast-cell products, mast-cell dischargers

Angeli et al. E94,909/55: Heparin i.v. produces basophilia and eosinopenia which last only a few hours.

Magni & Parmigiani D13,214/56: Heparin causes basophilia and eosinophilia in man.

Braunsteiner & Thumb C62,702/58; C89,221/58: Treatment with depot heparin produces a delayed basopenia in man which reaches its lowest point after 6–10 days.

Boseila C68,531/59: Heparin decreases the basophil count of the rabbit, but 5–HT causes a slight basophilia.

Marks et al. D82,448/59: 48/80 i.v. causes basopenia owing to degranulation of the basophils in the rabbit and chicken.

Hunt et al. D46,575/61: Following 48/80 i.v., the basophils of the rabbit decrease rapidly, while those in the spleen and subcutaneous connective tissue increase. Repeated injections of 48/80 caused proliferation of basophilic myelocytes in the bone marrow.

Shelley & Juhlin D80,542/62: 48/80 as well as several other histamine-liberators induce degranulation of human basophil leukocytes in vitro.

Shibata et al. E44,169/62: 48/80 produces a shock-like condition with basopenia in the rabbit. This was unaccompanied by basophil degranulation, blood-histamine concentration, or any change in blood coagulability. Histamine also causes basopenia in the rabbit.

Other drugs

Schmauch D76,213/1899: In the rabbit, *pyrodin* (1-acetyl-2-phenylhydrazine) produced intense basophilia. [This frequently-quoted paper reports only a single observation on one rabbit (*H.S.*).]

Lignac G18,730/32: In the mouse, *benzene* treatment causes myeloid leukemia and, in some cases, typical basophilic leukemia.

Plimpton D76,318/40: *Ventriculin* (a powdered, defatted hog gastric-tissue preparation) produces accumulation of basophils and MCs at subcutaneous injection sites in the guinea-pig. Since basophil myelocytes also appeared in the exudate, it was assumed that the basophils came from the bone marrow.

Marks et al. D82,448/59: Chronic treatment with *colchicine* s.c. induces pronounced blood basophilia in the rabbit. Conversely, *rattlesnake* (Crotalus atrox) *venom* i.v. causes complete disappearance of the basophils from the blood of rabbits.

Lindner D86,255/59: *Eckstein et al.* C98,735/60: In the rat, *phenylbutazone* s.c. or i.m. causes local accumulation of acid mucopolysaccharides and "mastocytoid" cellforms as well as blood basophilia.

Shelley & Juhlin D80,542/62: *Lecithinase A* has been found to induce a notable "melting" (granulolysis) in human basophils in vitro.

Marks & Oberer D31,908/62: In rabbits treated with the venom of *Crotalus atrox,* a biphasic basopenic response develops for which the lecithinase-A content of this snake venom may give a satisfactory explanation.

Shelley E35,090/63: "Twenty-five healthy male volunteers received *novobiocin* orally for 15 days. One-third of these subjects showed an increase in the percentage of circulating basophils which was interpreted as an immune response. Later challenge of one of these subjects with novobiocin caused a reactive basophilia within 24 hours."

STRESSORS, PHYSICAL AGENTS

Ringoen D27,892/23: Review on the production of basophilia by various bacterial toxins.

Casey D30,614/29; D30,613/28: In rabbits which became moribund as a result of various infections or transplantation of tumors, the basophil count showed a pronounced premortal drop. Antemortem basopenia is considered an index of low resistance.

Morelle D27,509/31: Shock produced by the intravenous injection of various toxic metallic sulfur compounds causes basopenia in the rabbit.

Moloney & Lange G18,692/54: Among atom-bomb survivors, basophilia was often the earliest sign of a developing leukemia.

Craddock et al. G17,986/55: The depression of leukopoiesis following X-irradiation does not affect the basophils selectively in the dog.

Spode D16,626/57: Various stressors such as parenterally administered foreign proteins, ultraviolet rays, strong visible light, induce mild initial basopenia followed by intense basophilia and a secondary basopenia in the rabbit. These reactions, which are associated with similar variations in the pseudo-eosinophil count of the blood, are ascribed to nonspecific stress.

Braunsteiner & Thumb C89,221/58; *Braunsteiner et al.* E52,570/60: Following massive X-irradiation, the basophils drop sharply in man, but in the personnel of an X-ray department, a moderate basophilia was noted.

Braunsteiner & Thumb C62,702/58: Various stressors induce basopenia in man.

Mitchell D92,371/58: In children with various acute diseases such as lobar pneumonia, rheumatic fever, or anaphylactoid purpura, "the number of circulating basophils was always low in the acute stage and high during the stage of recovery. These are regarded as nonspecific changes in response to the stress of the acute disease."

Fredricks & Moloney D84,020/59: "There is suggestive evidence that the basophilopenia in cases of infection, neoplasia, tissue necrosis and acute anemia is analogous to the eosinophilopenia of the 'stress reaction' mediated via the adrenal glands; however, it must be admitted that this has not been unequivocally established, and other mechanisms may play a role in controlling the levels of circulating basophils."

Thonnard-Neumann E93,067/61: A review of the literature shows that various stressors (as treatment with glucocorticoids or ACTH) cause basopenia which "may, therefore, be considered as manifestations of the adaptation syndrome, brought about by the activation of adrenal gluco-corticosteroids through release of ACTH."

Rorsman E41,991/62: Moderate exercise does not influence the basophil level in man.

Asano et al. D55,974/62: Cigarette smoking causes eosinopenia, basopenia, and increased urinary catecholamine excretion. "Thus the authors' results imply that tobacco smoking is one of the stressors in daily life."

Norins & Gould F7,147/64: Rabbit basophils stained with neutral red and then exposed to white light, exhibit signs of serious damage which can be prevented by the interposition of a neutral red filter between the light source and the stained cells. The possible interference of such photodynamic effects with the evaluation of basophil-depletion tests is emphasized.

ALLERGY

Melnikova D66,284/10: Intravenous administration of smallpox vaccine increases the blood-basophil count of the rabbit.

Schlecht D28,465/10: In the guinea-pig, diphtheria serum or ordinary horse serum s.c. produces a marked increase in basophils, often associated with eosinophilia.

Ringoen D27,892/23: Review of the literature on the production of basophilia by various antigens.

Thoma & Wiercinski E50,870/50: In guinea-pigs, daily i.p. injections of bovine serum cause intense blood and bone-marrow basophilia (as previously shown by Schlecht). The response is more pronounced in females than in males and is accompanied by a parallel increase in prothrombin time. The prolongation of blood clotting is ascribed to heparin derived from the blood basophils.

Baer & Yanowitz G18,943/52: In blister fluid from allergic patients in whom a patch test was produced by salicylic acid, permanent-wave lotion, or nickel sulfate, as well as in poison ivy dermatitis, the basophil content of the exudate is unusually high. The mononuclear cell count is also high in the allergic eczematous contact-type of reaction, while primary irritants cause a predominantly polymorphonuclear response.

Braunsteiner & Thumb C89,221/58: In patients with diverse allergic reactions, basophilia is inconstantly observed and not clearly correlated with the eosinophilia.

Braunsteiner et al. E52,570/60: In three cases of hay fever, the basophil count was significantly increased.

Winqvist D39,532/60: By daily s.c. injections of horse serum, the average number of basophils in guinea-pigs could be increased from 43 to more than 800/mm^3 of blood and from 15,000 to about 145,000/mm^3 of bone marrow.

Chan & Yoffey D39,533/60: In guinea-pigs receiving horse serum daily s.c., the bone-marrow basophils were increased to nearly nine times their normal level, but gradually diminished both during and after the treatment.

Rorsman D39,534/61: Allergen i.v. in sensitized rabbits produces a short but severe decrease in basophils, neutrophils, and eosinophils. The basophils do not decrease selectively during allergic reactions in rabbits as they do in many cases of urticaria in man.

Albanus & Winqvist D91,881/61: Daily s.c. injections of horse plasma causes intense basophilia and a rise in the histamine content of the bone marrow in guinea-pigs. No correlation was found between histamine content and the number of eosinophils.

Shelley & Juhlin D61,814/61: Patients with a history of pencillin anaphylaxis show degranulation of the basophils when these cells are placed in contact with penicillin in vitro. The response may be demonstrable even after penicillin had not been administered for months or even years. In this manner, it is possible to recognize penicillin-sensitive patients. In other forms of allergy, similar basophil degranulation has been obtained in vitro by exposure to the corresponding antigens. It is "suggested that the basophil is the central cell of the anaphylactic state."

Rorsman D39,534/61; D32,191/62; D39,535/62: The basophils are decreased in guinea-pigs and rabbits during anaphylaxis, and in patients with urticaria. "It appears reasonable to suppose that basophil leucocytes, like tissue mast cells, are of importance in certain urticarial conditions and in anaphylactic reactions."

Osada & Ogawa E48,023/62: Repeated i.p. injection of sterile horse serum causes local accumulation of numerous basophils and eosinophils. It was concluded that the basophils, like the eosinophils, participate in antigen-antibody reactions.

Klopstock et al. G17,219/62: The observations of Shelley and Juhlin on the in-vitro degranulation of basophils, placed in contact with antigens to which the patients are hypersensitive, have been confirmed with two simplified test procedures.

Wolf-Jürgensen G17,220/62: An increased number of eosinophils and basophils was found in the exudate in experimental contact allergy, using 2,4-dinitrochlorobenzene as a sensitizing agent and the Rebuck skin-window technique. In nonallergic inflammation, only few basophils and eosinophils were found under similar conditions.

Juhlin & Westphal G18,748/62: In a case of milk allergy, there was marked basopenia unaccompanied by any significant changes in the number of total white cells, eosinophils, and thrombocytes.

Shelley E52,331/62; D62,401/63: In rabbits sensitized by various antigens, re-exposure to the sensitizing antigen produces basophil degranulation both in vivo and in vitro. Heparin does not interfere with this reaction in vitro, but oxalate does, "indicating a presumed need for calcium." In man, contact allergens such as poison-ivy extract or paraphenylenediamine, have also shown positive reactions in sensitized patients. "Apparently the basophil reaction detects circulating antibody in any allergy." An indirect basophil-degranulation test for allergy to penicillin and other drugs is described. It requires one drop each of the patient's serum, of the penicillin solution, and of rabbit leukocytes (buffy coat containing test basophils). A positive test consists in the degranulation of the basophils. Positive results have also been obtained using the appropriate antigens with the serum of patients sensitive to sulfonamides, local anesthetics, and other drugs.

Fregert & Rorsman E35,551/63: The exudates of cantharidin blisters at sites of intradermal test reactions to nickel, cobalt, and chromate showed an increased number of blood basophils in patients allergic to these metals. The basophilia was higher in exudates from bullae at the site of test reactions than in exudates produced by cantharidin on otherwise normal skin.

Sidi et al. E51,719/63: The observations of Shelley on the in-vitro degranulation of basophils of allergic patients upon contact with the appropriate allergen, have been confirmed in patients with various drug allergies, particularly penicillin sensitivity.

Hu et al. E33,665/63: Using the Rebuck skin-window technique, it was found that suspensions of a strain of staphylococci produced a higher incidence of local basophilic and/or eosinophilic response in patients with furunculosis than in normal controls. A purified polysaccharide antigen prepared from the same strain of staphylococci failed to elicit such a reaction. "It is proposed that possibly the basophilic and eosinophilic response following exposure of skin to staphylococci represents one manifestation of hypersensitivity reaction to the organisms."

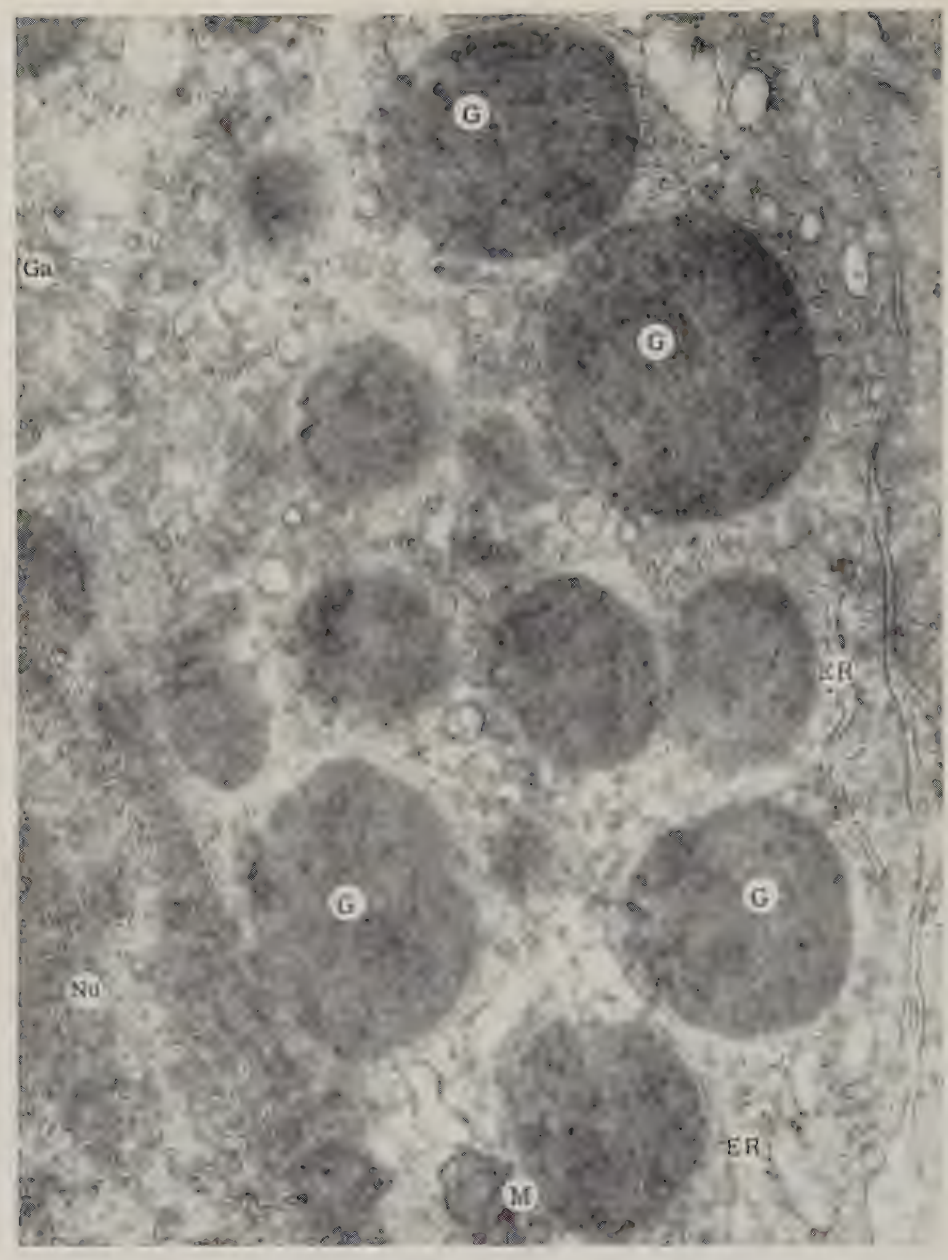

Figure 27.—Basophilic myelocyte of guinea-pig showing lamellated and periodic ultrastructure of the basophilic granules (G). (One percent OsO_4 buffered to *p*H 8.5. Epon. Lead acetate. X 33,000. Siemens' Elmiscope I.) [After *Winqvist,* unpublished.]

Aspegren et al. E28,353/63: An increased number of basophils can be demonstrated in the exudate of a nonvesicular allergic patch test in which a bulla was formed by the application of cantharidin. Although this local basophilia is not absolutely specific for allergic eczematous contact dermatitis, it is useful in differentiating allergic from primary irritant dermatitis.

Aspegren et al. D92,280/63: Vesicles and bullae, produced by contact allergens in sensitive patients, contain many more basophils than those elicited by primary toxic irritants. It is thought that the accumulation of basophils may be related to the immunological reaction.

Aspegren et al. E50,794/64: Bullae, produced by the application of cantharidin to the area where a skin reaction is elicited by old tuberculin, contained more basophils than bullae similarly produced in normal skin.

Keller D51,806/64: Early experiments showed that heat-aggregated human γ-globulin completely inhibits the immune reaction in an in-vitro system consisting of isolated rat peritoneal MCS, rabbit anti-rat γ-globulin serum, and heat-labile serum factors. After washing away the aggregated human γ-globulin, the addition of anti-rat γ-globulin and heat-labile serum factors allows cytolysis to proceed. It was assumed that this reaction cannot take place in the presence of aggregated human γ-globulin because the available complement is exhausted. Aggregated bovine γ-globulin did not have such an inhibitory effect.

Katz et al. F8,694/64: The indirect basophil-degranulation test (Shelley) was found highly efficient in detecting penicillin hypersensitivity in man.

Friedlaender & Friedlaender G18,240/64: Systematic studies were conducted on basophil degranulation induced by the addition of antigen to sera of patients or animals known to be sensitive to ragweed pollen or penicillin. Unfortunately, nonspecific alterations in basophils interfered with efforts to quantitate the response. However, "while the results with ragweed-sensitive sera suggest a possible specificity directed toward a fraction of the ragweed antigen, total correlation with clinical sensitivity and reaginic antibody was not found. Many technical and theoretical problems require solution before the specificity of the basophil degranulation phenomenon can be confidently related to antigen-antibody reaction."

Juhlin F16,723/64: The observations of Shelley on the in-vitro degranulation of blood basophils of allergic patients upon contact with the appropriate allergen, have again been confirmed in patients with various drug allergies, particularly penicillin sensitivity.

Schönherr & Herrmann F22,262/64: In one of two patients with cold urticaria, basophil degranulation could be demonstrated with a modified Shelley-Juhlin technique in vitro.

DIET

Braunsteiner & Thumb C89,221/58; C62,702/58: No significant change in the basophil count was observed in man after a high-fat meal.

Shelley & Juhlin D39,536/61: In man, alimentary lipemia is associated with degranulation of the basophils. This is regarded as the mechanism for the physiological release of heparin and, hence, of importance in the clearing action.

Rorsman E41,991/62: Food intake does not influence the basophil level in man.

Shelley & Caro D36,685/62: Oral lipid administration inhibits anaphylaxis in both guinea-pigs and rabbits (*Jaques* C89,858/59); this desensitization is ascribed to the degranulation of basophils that occurs during lipemia and anaphylactic challenge.

Shelley E52,331/62: High-fat diets cause degranulation of basophils in man, while carbohydrate and protein feedings are without this effect. Presumably, the basophil plays a role in regulating lipemia through the release of heparin.

Braunsteiner & Thumb G14,691/63: During alimentary hyperlipemia, the basophils discharge their granules in man.

DIURNAL AND SEASONAL VARIATIONS, HIBERNATION

Suomalainen & Granström C29,531/55: In the hamster, during hibernation there is leukopenia, eosinopenia, and lymphopenia, but the basophil count is essentially normal. The changes are considered to be manifestations of the general adaptation syndrome.

Boseila C68,531/59: The basophil count shows slight diurnal variations with elevations in the afternoon, both in the rabbit and in man.

Rorsman E41,991/62: The basophil count showed no significant variations between 8 a.m. and 6 p.m. in man.

Ogawa E63,367/63: Both basophils and eosinophils reach higher values in the blood of man during the summer than in winter.

SEX, CYCLE, PREGNANCY

Thonnard-Neumann D20,120/51: In normal pregnancy, the basophil count is usually low, while in threatened abortion it rises above normal.

Moore & James D27,613/53: No significant sex difference in the basophil count could be found in man.

Angeli et al. D69,546/55: In men, the blood-basophil count does not change with advancing age, while in women it diminishes after the menopause.

Zachariae et al. C57,334/58: In the rabbit, basophils migrate from the blood into the genital organs (primarily the ovaries) at ovulation. A large number of them accumulates around ovulating follicles and fresh corpora lutea. [In the tissues, it is difficult to distinguish these basophils from MCs (*H.S.*).]

Thonnard-Neumann C59,519/58: In women there are cyclic variations in the basophil count with a maximum at the time of menstrual bleeding.

Thumb et al. C73,066/59: Pronounced basopenia, unaccompanied by eosinopenia, is observed in women during pregnancy.

Potuzhek et al. E53,262/59; *Boseila* D78,510/59: No significant variations in the basophil count were observed in women during the menstrual cycle. On the other hand, during pregnancy, there is pronounced basopenia.

Boseila C68,531/59: The average basophil count in the rabbit blood is somewhat higher in females than in males. Cyclic changes are observed in the basophils of women in correspondence with the menstrual cycle. Basopenia is noted during pregnancy in the rabbit. After copulation and artificial sexual stimulation, conducive to ovulation and pseudo-pregnancy, there is likewise a decrease in the basophil count of the rabbit. At the same time, basophils accumulate within the blood vessels of the ovaries and oviducts.

Rorsman E41,991/62: In man there is no significant sex difference in the basophil count.

Thonnard-Neumann G15,063/63: In young adult women, the mean basophil count is higher than in males of the same age group, but the reverse is true in older men and women. In sexually-mature female rabbits, the average basophil count is higher than in immature females or mature and immature males.

AGE

Angeli et al. D69,546/55: In men, the blood basophil count does not change with advancing age, while in women it diminishes after the menopause.

James et al. D27,395/55; *Mitchell* D92,371/58: The basophil count in children is essentially the same as in adults.

Braunsteiner & Thumb C89,221/58: No correlation could be found between the basophil count and the age or the blood-cholesterol content of man.

Rorsman E41,991/62: The mean basophil count rises slightly with age in man.

Thonnard-Neumann G15,063/63: The basophil count changes but little as a function of age in the rabbit and man.

BASOPHILIC LEUKEMIA

Reviews: *Joachim* D28,466/06; *Groat et al.* D39,568/36; *Chevallier & Marinone* D52,735/48; **Lennert et al.* D26,471/56; **Braunsteiner* D59,693/59

HISTORY

Levaditi G18,721/01: Detailed review of the early history of basophilic leukemia and description of a personally-observed case.

Levaditi D63,798/02: Discussion.

CASE REPORTS

Bezançon G18,727/00
Lazarus G18,728/01
Joachim D28,466/06
Tomaszewski D63,793/11
Vasaturo G18,741/52
Sabrazès D30,601/26
Massa & Marinoni G18,742/26
Tinti G11,138/26
Sarzi-Sartori G18,740/27
Elliot & Young G18,734/31
Groat et al. D39,568/36
Doan & Reinhart D26,488/41
Casey et al. D30,374/46
Chevallier & Marinone G18,724/47
Hule G18,738/50
Cattaneo G18,743/50
Chevallier & Marinone D61,697/51
Ferrara G18,735/51; G18,736/52
Natale G18,739/52
Ninni & Belloni G11,139/53
Ferrara G18,737/53
Barlas G18,731/54

CLASSIFICATION AND TERMINOLOGY

Basophilic leukemia may be more or less acute in its development, and it may or may not be associated with severe hemorrhagic diathesis, changes in blood-platelet count, urticarial eruptions, etc. There are many transitions between the typical basophilic leukemia and the chronic myeloid leukemia with comparatively moderate predominance of blood basophils. Indeed, there are even "aleukemic" forms in which the basophil count is normal and yet the myeloid tissue infiltrates are rich in basophils and their precursors. All these differences have been used as a basis of classification, but there are so many intermediate forms between the various prototypes that their strict categorization is impossible.

Perhaps the most fundamental classification that can be made is based on the separation of urticaria pigmentosa with secondary massive basophil invasion into the blood, from primary basophilic leukemia, since in the first case the blood basophils are predominantly of histogenous origin, in the second of myelogenous origin. Yet, even here, there are probably transitional cases; besides, it is difficult to trace the source of a blood basophil with certainty.

In any event, in this section, we shall deal only with basophilic leukemia unassociated with urticaria pigmentosa since the latter condition has already been dealt with in a separate chapter.

Massa & Marinoni G18,742/26: In a case of basophilic leukemia there was a marked increase in blood-platelet count with urticarial eruptions.

Tötterman D39,744/48: "Cases of acute myeloid leukemia with low platelet counts and severe hemorrhagic diathesis are often combined with a low number of basophils. Cases of chronic myeloid leukemia with pronounced basophilia do not show greater tendencies towards hemorrhages than do cases without basophilia."

Chevallier & Marinone D52,735/48: The basophilic leukemias are subdivided into: (1) typical, (2) attenuated, and (3) temporary forms. The first are the most severe and rapidly fatal, the second show a less pronounced and less stable basophilia, while in the third blood basophilia is seen only during one stage of the disease either as a transformation of a myeloid leukemia into the basophil type or vice versa. However, admittedly, many transitional forms occur between these main types.

Hule G18,738/50: A case of "aleukemic" basophilic leukemia with fatal ending within three weeks.

Chevallier & Marinone D61,697/51: An acute form of basophilic leukemia is described as "leucose aiguë à basoblastes."

Astaldi et al. D39,707/53: A case of basophilic leukemia with a pronounced hemorrhagic tendency.

Lennert et al. D26,471/56: The following classification of basophil leukemias is recommended:

(1) *Primary mast-cell leukemia*—This is usually characterized by a rapid progress with fatal outcome between 4 days and 5 months after diagnosis. The basophil count is very high, up to 80 per cent, but in the case of aleukemic forms it may remain low, and yet, the diagnosis leaves no doubt because of the presence of immature basophils in the sternal bone-marrow biopsies which clearly show the transition to myeloblast leukemia. This connection is further supported by the frequent appearance of ulcerations in the oral mucosa and the relatively strong and early lymph-node enlargement, as well as the comparative resistance to X-ray therapy.

(2) *Secondary mast-cell leukemia*—This form usually represents the final stage of a chronic myeloid leukemia. In all pertinent cases, death occurred within 2 months after the appearance of blood basophilia. Only in one case (a 5-month-old infant) did an acute myelosis develop into basophil leukemia after one week of observation.

(3) *Mild temporary mast-cell leukemia*—This group comprises cases in which it is doubtful whether they should be considered basophil leukemias or ordinary myeloid leukemias, because the blood-basophil content is only moderately and often temporarily increased.

Remy D32,662/62: It is difficult to differentiate those basophilic leukemias that are essentially chronic myeloid leukemias with predominance of blood basophils, from those that represent "mast-cell reticuloses" developing on the basis of a systemic urticaria pigmentosa. In both types, leukemic infiltrates can occur in the spleen, liver, lymph nodes, and bone marrow, with generalized organ fibrosis and a predominance of basophil or MC-like cells in the infiltrations.

PATHOLOGIC ANATOMY

The most outstanding structural characteristic of basophilic leukemia is the presence in the blood of an unusually large number of basophils in various stages of maturation. This feature is missing only in the very rare "aleukemic" forms. The blood also may contain megakaryocytes and the platelet count is frequently increased.

In addition, myeloid infiltrates with a great predominance of immature basophils and sometimes megakaryocytes are noted in the bone marrow, liver, spleen, lymph nodes, kidney, and various other tissues. These infiltrates give rise to varying degrees of fibrosis.

The hemorrhagic tendency noted in some cases has been ascribed to heparin liberation from the proliferating basophils.

Bezançon G18,727/00: In a case of basophilic leukemia, the spleen weighs 2.9 kg, and infiltrations with myeloid tissue were noted in the spleen, lymph nodes, thymus, and lung.

Bigart D30,637/02: In a case of "mast-cell leukemia" there was hepatic cirrhosis, suggesting a relationship between the two diseases.

Joachim D28,466/06: In two cases of basophilic leukemia, the basophil count was above 50 per cent and in one of these it eventually rose to 83.2 per cent. Leukemic infiltrates with numerous basophils were seen in the bone marrow, spleen, lymph nodes, and other organs.

Sabrazès D30,601/26; D27,634/26: A case of basophilic leukemia in which blood basophils were seen to differentiate from hemohistioblasts. The basophil count varied between 2 and 22 per cent.

Massa & Marinoni G18,742/26: In a case of basophilic leukemia there was a marked increase in blood-platelet count with urticarial eruptions.

Forkner G16,566/38: In basophilic leukemia, the mature basophils are often sparsely populated by small granules and many immature forms appear in the blood.

Calamari G18,726/47: A case of basophilic leukemia in which the initial basophil count of 27.4 per cent regressed to 6 per cent.

Dantchev D53,654/52: In certain cases of basophilic leukemia, there are basophils which also contain eosinophilic granulations ("eosinobasophils"); this suggests a close relationship between eosinophils and basophils.

Moloney & Lange G18,692/54: Chronic myeloid leukemia is often associated with basophilia.

Lennert et al. D26,471/56: A 16-year-old boy developed marked leukocytosis with up to 15 per cent basophils. He died as the result of an MC-leukemia five years later. There was marked intra- and extramedullary myelopoiesis with numerous basophils and pronounced fibrosis in the liver, spleen, and lymph nodes as well as in the bone marrow. In the spleen, there were many Gandy-Gamna corpuscles with typical iron and calcium incrustations. The case probably represents an osteomyeloreticulosis in which the basophils are thought to be responsible for the fibrosis in the hemopoietic organs. A review of the literature reveals several cases of basophilic leukemia in which the platelet and megakaryocyte count of the blood was increased.

Rondanelli et al. D33,212/62: Extensive histochemical studies on the basophils in a case of basophilic leukemia.

CLINICAL COURSE, PROGNOSIS

The so-called "primary basophilic leukemia" is usually characterized by very rapid progress with fatal outcome within a few weeks or months after the patient seeks medical advice. Secondary basophilic leukemia develops as the last stage of a chronic myeloid leukemia, and although here the final outcome is likewise always fatal, the disease progresses somewhat more slowly. In either case, the clinical course is essentially that of a malignant myeloid leukemia and, hence, it need not be discussed here at length.

Chevallier & Marinone D52,735/48; *Remy* D32,662/62: The larger the number of basophils and the more stable the basophilia, the more severe is the prognosis of a myeloid leukemia.

DIAGNOSIS

The diagnosis of basophilic leukemia rarely causes any difficulty because of the presence of immature basophils and sometimes numerous megakaryocytes and platelets in the blood. In the case of chronic myeloid leukemia associated with blood basophilia, it has been accepted somewhat arbitrarily that, unless at least 20 per cent of the circulating white cells are basophils, we should not speak of basophilic leukemia. Even in the exceptional aleukemic forms, the presence of numerous immature basophils in bone-marrow biopsies rarely leaves any doubt about the diagnosis.

Forkner E4,337/38: An increase in basophils is so common in chronic myeloid leukemia that it constitutes an important differential diagnostic point between this disease and "leukemoid states."

Doan & Reinhart D26,488/41: The transition between myeloid leukemia and typical basophil leukemia is gradual. Some investigators considered a blood count with 20 per cent basophils to be sufficient for the diagnosis of true basophil leukemia, but it may be more conservative not to include cases unless one-third of all leukocytes are basophils.

Chevallier & Marinone D52,735/48: Review of all cases of basophilic leukemia published prior to 1948. In order to make the diagnosis, the basophil count must not only steadily remain high, but immature forms of basophils must be demonstrable in the blood.

Remy D32,662/62: It is difficult to differentiate those basophilic leukemias that are essentially chronic myeloid leukemias with predominance of basophils, from those forms that represent "mast-cell reticuloses" developing on the basis of a systemic urticaria pigmentosa. In both types, leukemic infiltrates can occur in the spleen, liver, lymph nodes, and bone marrow, with generalized organ fibrosis and a predominance of basophil or MC-like cells in the infiltrations.

ETIOLOGY AND PATHOGENESIS

Nothing is known about the etiology of basophilic leukemia. According to prevalent opinion, leukemias are of viral origin and it is possible that this applies also to basophilic leukemia, but no specific information is available on this point.

Regarding the pathogenesis of the disease, it seems well established that in the "primary form" of basophilic leukemia and in that developing on the basis of a chronic myeloid leukemia, the hemopoietic tissue of the bone marrow is the primary source of the blood basophils. On the other hand, when a basophilic leukemia develops in urticaria pigmentosa, the blood basophils may arise from proliferating tissue MCs which eventually invade the blood. However, since here the bone marrow is often also the site of intense basophil proliferation, we cannot exclude the possibility of a systemic MC disease in which the proliferation of tissue MCs is associated with a concurrent excess production of basophils in the bone marrow and the myeloid-tissue infiltrates.

Bezançon G18,727/00: The leukemic infiltrates in the spleen and liver of patients with basophilic leukemia may be metastatic (Ehrlich's theory) or due to a reactivation of the embryological hemopoietic function outside the bone marrow (Dominici's theory).

Remy D32,662/62: Basophilic leukemia may develop either owing to onesided overactivity of the bone marrow as in the myeloid leukemias with predominant basophil production, or on the basis of a "mast-cell reticulosis" such as occurs in the systemic forms of urticaria pigmentosa in which the tissue MCs invade the blood.

AGENTS INFLUENCING BASOPHILIC LEUKEMIA

Here, as in the section on mastocytoses, we shall deal conjointly with the literature on agents having a beneficial or detrimental effect upon the disease, since knowledge of both types is necessary for the proper treatment of basophilic leukemia and the understanding of its pathogenesis.

X-irradiation is of little value in the treatment of basophilic leukemias; occasionally, it may cause a temporary remission, but this is never of long duration and sometimes it may even aggravate the patient's condition. The X-ray sensitivity of the basophils is essentially the same as that of other white cells, and in leukemic patients treated with X-rays or P^{32} the decline in the total leukocyte count is proportional to that of the blood basophils. Among the victims of *atomic bombs,* blood basophilia was often the first indication of an incipient leukemia. *Myleran, Aminopterin* and *glucocorticoid* treatment likewise resulted only in slight temporary remissions, if any.

Ionizing rays

Tomaszewski D63,793/11: In a patient with MC-leukemia, X-irradiation produced very unfavorable results.

Sabrazès G16,740/25: Even when X-rays induce remissions in chronic myeloid leukemia and the blood count returns toward normal, basophilia persists.

Sabrazès D30,601/26: A case of X-ray-resistant myeloid leukemia in which there were unusually large basophils in the circulating blood, giving the impression of tissue MCs.

Sabrazès D27,634/26: In a case of MC-leukemia, X-irradiation caused temporary remission.

Barlas G18,731/54: In a patient with acute basophilic leukemia, X-irradiation caused only a temporary decrease in the basophil count.

Fredricks & Moloney D84,020/59: Treatment with P^{32} or X-rays causes a decrease in the absolute basophil count which roughly parallels the decline in the total leukocytes. There is no indication of any special radio-resistance of the basophils. A review of the literature reveals numerous cases in which the blood-basophil count actually rose following X-ray therapy. In a personally-observed case, X-irradiation caused pronounced absolute leukopenia with marked relative basophilia.

Other agents

Chevallier & Marinone D61,697/51: *Aminopterin* treatment caused only a slight remission in the course of an acute basophilic leukemia.

Kelemen & Bikich G16,012/56: In patients with basophil leukemia, *ACTH and cortisone* produce only mild decreases in the basophil count.

Efrati et al. D25,560/57: In a woman with presumed "mast-cell leukemia" who succumbed from massive gastrointestinal hemorrhage following *cortisone* treatment, the morphologic features of the MCs in the peripheral blood, spleen, bone marrow, and other tissues, are described at length. Mitotic figures in MCs were rare and the cells are thought to develop from reticulum cells of the spleen and from fibroblasts.

Fredricks & Moloney D84,020/59: In patients with chronic myeloid leukemia and an increased blood-basophil count, treatment with the alkylating agent *Myleran* (1:4 dimethanesulphonyl-oxybutane) caused a reduction in the absolute basophil count which roughly paralleled the decline in the total white-cell count.

THE BASOPHILS IN VARIOUS DISEASES

As previously stated, apart from *primary basophilic leukemia* and *systemic urticaria pigmentosa,* the blood basophils are most constantly and markedly increased in *chronic myeloid leukemia.* This fact had been noted at the turn of the century by Ehrlich and his students Lazarus and Levaditi; it has since been amply confirmed by many others. Indeed, some investigators claimed that sooner or later in the course of chronic myeloid leukemia, the basophil count is always raised up to 5–20 per cent, yet it is perhaps somewhat arbitrary to accept the suggestion of some hematologists not to speak of a basophilic leukemia unless 20–30 per cent of the total leukocyte count corresponds to basophils. Occasionally, basophilia also occurs in *acute myeloid leukemias,* but these are more commonly associated with basopenia or a normal basophil count.

Among *other blood dyscrasias,* more or less pronounced basophilia has been noted in chronic secondary anemias, polycythemia vera, hemolytic icterus, acute thrombopenia of immunologic origin, iron-deficiency anemias, "toxic" anemias of long standing, as well as in neutrophilic leukocytosis and leukemoid reactions associated with infection, neoplasia, tissue necrosis, etc. In chronic lymphatic leukemia and pernicious anemia, the blood-basophil count is normal or subnormal.

Among the *dermatoses,* urticaria pigmentosa is most commonly associated with basophilic leukemia, as previously stated. On the other hand, during attacks of common urticaria of allergic or unknown origin, basopenia develops. No consistent change is seen in most of the other dermatoses.

There is a concensus that in *myxedema* the basophil count is increased, while in *thyrotoxicosis* it is decreased. Suitable therapy restores the basophil count towards normal in both these conditions.

Data concerning the basophil count in *diabetes mellitus* are conflicting. Some investigators report increased, others normal or decreased values.

Nephrosis is frequently associated with basophilia, which regresses following thyroid therapy.

In *hepatic cirrhosis,* early investigators reported a considerably-raised basophil count, but this has not been confirmed.

In *asthma,* the basophil count may be normal or high, perhaps depending upon its cause.

Diverse *allergic reactions* may cause a basophilia which is not always associated with eosinophilia. However, basopenia has also been reported, for example, in a case of milk allergy, and it is possible that these differences are due to the time at which blood counts were made; in general, the basophil count tends to drop during an attack and rise to or above normal afterwards. In allergic exudative dermatoses, large numbers of basophils tend to migrate into the inflammatory fluid. The basophil

count in artificially-produced "skin windows" or cantharidin blisters may even be of diagnostic value in allergic states.

In various other *acute diseases* such as severe infections and myocardial infarction, there is basopenia at the height of the disease with basophilia during recovery. These changes were ascribed respectively to the alarm reaction and stage of resistance of the *general adaptation syndrome*. A similar acute drop in blood basophils has been noted in animals exposed to the stress of infections or tumor transplants.

Myeloid leukemia

Ehrlich & Lazarus D50 996/1898; *Levaditi* G18,721/01: In chronic myeloid leukemia, the blood basophil count is increased.

Alder D27,431/22–23: In myeloid leukemia, the basophil count is always raised, sometimes up to 20 per cent of the total leukocyte count.

Forkner G16,566/38: In chronic myeloid leukemia, the basophils may contain only few and small granules.

Holmgren & Wohlfart D28,677/41: In chronic myeloid leukemia, the basophil count is almost always increased 10–18.5 per cent. The highest basophil count was 24,300/mm^3. A basophil count of 4–5 per cent or more is "almost pathognomonic for myeloid leukemia."

Casey et al. D30,374/46: In six cases of neutrophilic leukemia, the basophils outnumbered the neutrophils only during the five weeks prior to death. "There is no evidence at present that basophilic leukemia ever occurs except as a terminal phase of neutrophilic leukemia."

James et al. D27,395/55: Pronounced basophilia may occur in chronic myeloid leukemia.

Lennert et al. D26,471/56: Chronic myeloid leukemias are always accompanied by basophilia.

Braunsteiner & Thumb C89,221/58: Pronounced blood basophilia may occur not only in chronic, but also in acute myeloid leukemias.

Fredricks & Moloney D84,020/59: "A marked relative and absolute increase of basophils was always found in chronic myelogenous leukemia. Moderate relative and absolute increases of basophils usually occurred in myeloid metaplasias (including polycythemia vera with leukocytosis). In some cases of iron-deficiency, hemolytic and toxic anemias of long standing there may be moderate increases of blood basophils." Pronounced relative and absolute decreases of basophils occurred in all cases of neutrophilic leukocytosis and leukemoid reactions, associated with infection, neoplasia, tissue necrosis, or acute anemia. In chronic lymphatic leukemia, monocytic leukemia, and acute leukemia there is almost always an absolute decrease in basophils.

Other blood dyscrasias

Alder D27,431/22–23: Slight rises in the basophil count are observed in connection with various types of chronic secondary anemias. In pernicious anemia, the basophil count is usually normal or subnormal. In two cases of polycythemia, the basophil count was raised to almost ten times the normal level. In a series of 22 patients with hemolytic icterus, the basophil count was raised to almost three times the normal level. In lymphatic leukemias, the absolute basophil count tends to rise although the percentage of basophils among the total leukocyte population drops.

Holmgren & Wohlfart D28,677/41: In polycythemia, there is a slight increase in the basophil count.

Braunsteiner & Thumb C89,221/58; C62,702/58: In a case of polycythemia vera there was marked basophilia. In acute thrombopenia of immunologic origin, blood basophilia has repeatedly been observed.

Fredricks & Moloney D84,020/59: Basophilia is sometimes associated with polycythemia vera. A review of the literature shows that, in pernicious anemia, the basophil count is normal although it may be raised slightly in chronic hemolytic iron deficiency and "toxic anemias."

Dermatoses

Klausner & Kreibich G8,896/09: The basophil count of the blood and of skin vesicles is high in a variety of itching dermatoses.

Rorsman D96,270/57: During attacks of urticaria, basopenia develops.

Rorsman & Rosengren E88,078/58; *Rorsman* E41,623/58: A marked decrease in basophils was found in a series of patients with urticaria. In some instances, the basophils disappeared completely but occasionally the basophil count was normal. Following attacks, the basopenia disappears within a few days. In general there is parallelism between the basophil count and the blood-histamine content. However, there are exceptions with normal or even increased basophil and histamine values. The blood basophil count was not significantly changed in patients with atopic dermatitis.

Rorsman E40,272/58: In patients with non-erythrodermic psoriasis and atopic dermatitis, the basophil count was normal.

Bersani D82,695/59: In urticaria of unknown origin, basopenia tends to develop.

Langhof et al. D16,751/61: In a patient with psoriasis pustulosa (Hallopeau), increased emigration of basophils into the skin could be demonstrated with the Rebuck test only during the stage of pustule formation.

Rorsman D39,084/62: The basophil count in a large series of patients with urticaria of unknown origin was significantly below normal. On the other hand, in cold urticaria the basophils were normal, in dermographism slightly decreased, in pressure urticaria markedly decreased. As a rule, basopenia in urticaria disappears shortly after the symptoms cease.

Rorsman D32,191/62: The basophils are decreased in guinea-pigs and rabbits during anaphylaxis, and in patients with urticaria. "It appears reasonable to suppose that basophil leucocytes, like tissue mast cells, are of importance in certain urticarial conditions and in anaphylactic reactions."

Shelley E52,331/62: In atopic dermatitis, it has been possible regularly to detect the significant allergens, since these cause basophil degranulation in vitro when added to the patient's basophils.

Juhlin E99,930/63: The blood basophil content of cantharidin blisters was increased in patients with exfoliative erythroderma, allergic contact dermatitis, nummular eczema, chronic eczematous dermatitis, eczema of the hands and/or feet, psoriasis, and atopic dermatitis. Bullous lesions after insect bites and in patients with drug eruptions, pemphigus, and Behcet's syndrome contained more than ten times the normal percentage of basophils. No correlation was found between the basophil count in blood or bone marrow and in inflammatory exudate. The literature on the basophil content of experimentally-produced skin exudates is reviewed, and the specificity of basophilia in exudates, as a test for allergic reactions, is discussed.

Aspegren et al. E97,750/63: Basophilia was commonly observed in the skin lesions of allergic eczematous contact dermatitis, in erythema exudativum multiforme, and in drug eruptions, but not in eczematous dermatitis of unknown, presumably non-allergic origin nor in psoriasis, pustulosis palmoplantaris, herpes zoster, or in nummular eczema. "The occurrence of basophilia in the skin in many cases with dermatoses of proved or suspected allergic origin and its absence in diseases with a more obscure immunologic background suggests that local basophilia is more common in dermatoses of allergic origin. The absence of local basophilia does not, however, exclude the possibility of the skin inflammation being allergic."

Thyroid disease

Turin 34,610/10; *Braunsteiner & Thumb* C62,702/58; G14,691/63; *Mitchell* D92,371/58; *Anbo* D9,261/59; *Cavazzuti et al.* C73,006/59; *Tedeschi et al.* C70 550/59; *Braunsteiner et al.* C65,755/59; E52,570/60; *el-Din et al.* D96,623/61; *Ishibe* E64,005/62; *Juhlin* E26,200/63: In myxedema, there is an increased, and in thyrotoxicosis a decreased basophil count in man.

Inagaki C54,042/56; C45,593/57: In almost all cases of thyrotoxicosis, the absolute basophil count is markedly decreased. Under the influence of methylthiouracil therapy it increases further. In myxedema, the basophil count is increased but drops following treatment with thyroxin or desiccated thyroid.

Hecker et al. E94,745/60: In hypothyroidism, there is a pronounced increase in blood basophils which vanishes upon administration of substitution therapy. In hyperthyroidism there is a pronounced diminution of basophils which can be restored to, or above normal, by antithyroid treatment.

Diabetes

Braunsteiner & Thumb C89,221/58; C62,702/58; G14,691/63: *Braunsteiner et al.* E52,570/60: In diabetes mellitus, the basophil count is usually high.

Tedeschi et al. C70,550/59; *Juhlin* E26,200/63: In diabetic patients well controlled with insulin, the basophil and eosinophil counts are normal.

Engleson & Lindberg D54,609/62: In diabetes with vascular complications, the blood content in heparinoid substances is reduced, but the number of basophils is unchanged.

Nephrosis

Inagaki C54,042/56; C45,593/57: In nephrosis, the basophil count is increased but treatment with desiccated thyroid causes a rise.

Braunsteiner & Thumb C89,221/58; C62,702/58; *Braunsteiner et al.* E52,570/60; *el-Din et al.* D96,623/61: Basophilia is frequently observed in lipid nephrosis.

Hepatic cirrhosis, hepatitis

Rubinato D28,463/07: In patients with hepatic cirrhosis, the basophil count is only irregularly and slightly raised.

Braunsteiner et al. E52,570/60: No increase in basophils was observed in patients with hepatic cirrhosis.

Canestri E61,236/62: In children with acute hepatitis, the blood-basophil count is increased.

Asthma

Rorsman E40,272/58; E41,623/58; *Tedeschi et al.* C70,550/59; *Ricci & Lombardi* E40,138/61; *Juhlin* E26,200/63: In patients with bronchial asthma, the basophil count is usually within normal limits.

Braunsteiner et al. E52,570/60: In allergic asthma, the basophil count was significantly increased.

Ricci & Lombardi E40,138/61: In the allergic forms of asthma, the basophil count is usually increased.

Allergic diseases

(Cf. DERMATOSES, *p.* 352, ASTHMA, *p.* 354, ALLERGY, *p.* 342.)

Infections

Pröscher D27,970/09: Following inoculation with *smallpox virus,* there develops intense blood basophilia in the rabbit.

Bunting G16,739/21: In *influenza,* "eosinophils and basophils are either absent from the circulation or present in very small numbers."

Bunting & Thewlis G18,416/26: Slight elevations of the relative basophil count may be observed in *smallpox, chickenpox, scarlet fever, measles, and mumps.*

Mitchell D92,371/58: In children with various acute diseases, such as *lobar pneumonia,* and *rheumatic fever,* and as in *anaphylactoid purpura,* there was basopenia at the height of the disease with basophilia during recovery. These changes were ascribed to nonspecific stress.

Anbo D9,261/59: During the febrile stage of *scarlet fever* the basophil count drops, but then increases to or above normal at about the 15th day. A similar biophysic reaction was observed in *measles, rubeola, rheumatic fever,* and *typhoid fever.*

Saito D31,873/62: In various acute *infections,* there is basopenia which vanishes as the condition of the patient improves and subsequently may even increase above normal.

Tumors

Casey D30,613/28; D30,614/29: In rabbits which become moribund as a result of various infections or transplantation of tumors, the blood-basophil count showed a pronounced premortal drop. Ante-mortem basopenia is considered an index of low resistance.

Jacquet E24,358/63: In rats bearing transplants of the rat uterine epithelioma of Guérin, the number of blood basophils is increased.

Other diseases

Reviews: *Canon* D27,645/1892
Tedeschi et al. C70,550/59
Thonnard-Neumann E93,067/61

Thonnard-Neumann D20,120/51; G9,153/54: Mild basophilia is seen in women with various *menstrual disorders.* Among five children with *cryptorchidism,* four showed varying degrees of basophilia.

Braunsteiner et al. E52,570/60: In two cases of *adrenogenital syndrome,* the basophil count was above normal. In seven cases of *Cushing's disease,* there was marked basopenia which may have diagnostic value.

Priest et al. E43,293/60: As judged by observations with the Rebuck skin-window technique, in most patients with *ulcerative colitis* the exudates contain an excessive number of basophilic leukocytes.

Boseila & Toone E40,872/61: The mean basophil count in patients with long-standing *rheumatoid arthritis* is significantly subnormal. The possibility is considered that the basophil changes may reflect anomalies in mucopolysaccharide production during the development of rheumatoid arthritis.

Juhlin D62,609/63: In *ulcerative colitis,* the basophil count is slightly above normal.

Juhlin E71,741/63: In acute bleeding *peptic ulcers* verified by X-rays, the basophil count was decreased and the cells showed signs of degranulation.

Juhlin E26,200/63: Normal basophil counts are found in *essential hypertension.* In patients with *myocardial infarction,* there is basopenia and degranulation of basophils, especially two or three days after the attack. A similar delayed basopenia occurs after corticoid treatment. "This means that the basophil decrease is probably due to the stress reaction produced by the infarction."

Rebuck et al. D58,294/63: Using the skin-window technique, excessive basophil migration into the exudate was found in eight of nine patients with *interstitial cystitis (Hunter's ulcer).* Urinary bladder biopsies in this group likewise revealed an increase in the "basophil-mast cell complex" within the bladder wall. "In *Hurler's disease,* the presence of unusual intercellular materials (chondroitin sulfuric acid B and/or heparin monosulfuric acid) leads not only to their ingestion by the histiocytes with the formation of quasi-mast cells, but, in addition, an unexpected, undue migration of basophilic granulocytes ensues." In patients with *ulcerative colitis,* the cutaneous exudate also contains an unusually large number of basophils. At the same time, metachromatic cells ("basophil-mast cell complex") are present in excessive amounts in the colonic and dermal lesions of the natural disease process.

BASOPHILIC LEUKEMIA IN ANIMALS

Spontaneous basophilic leukemia is very exceptional in animals, although one case has been observed in a cat, and a condition resembling basophilic leukemia has been produced experimentally in the mouse.

Lillie G18,729/31: Observation of a spontaneous basophilic leukemia in a cat.

Lignac G18,730/32: In the mouse, benzene treatment causes myeloid leukemia and, in some cases, typical basophilic leukemia.

Weiss G17,190/57. A case of "aleukemic mast-cell leukosis" in a 5-year-old boxer dog. In addition to cutaneous mastocytomas and MC infiltrations in the liver, spleen, and lymph nodes, there was leukocytosis, but the basophil count in the blood was not increased. "Aleukemic mast-cell leukosis" is considered to be the systemic counterpart of the localized cutaneous mastocytoma.

Lucke G20,416/64: Report on basophilic leukemia in a twelve-year-old cat with a review of four previously described cases.

Trautwein & Stöber D97,999/in press: Mastocytosis (MC-reticulosis) can occur in cattle as a spontaneous disease. It is characterized by infiltration with MCs and reticular fibers in the skin, lungs, skeletal musculature, and basophilic leukemia. The infiltrates exhibit a yellowish green color and, in addition to MCs, contain many eosinophils.

BIOCHEMISTRY

(Cf. also HISTOCHEMISTRY, *p.* 334)

Data concerning the chemical composition of blood basophils as judged by conventional chemical techniques are necessarily indirect, because of the difficulty of obtaining large samples of these cells, uncontaminated by other elements. It

seems to be rather convincingly established, however, that blood or blood concentrates rich in basophils have a very high heparin and histamine content.

Review: *Valentine* B61,807/51

HEPARIN

Thoma & Wiercinski E50,870/50: In guinea-pigs, daily i.p. injections of bovine serum cause intense blood and bone-marrow basophilia accompanied by a parallel increase in prothrombin time. The prolongation of blood clotting is ascribed to heparin derived from the blood basophils.

Laves & Thoma G18,725/50: Using various substrate-specific enzyme systems, it is noted that the basophils of man and the rabbit contain heparin-like, large molecular polysaccharides.

Behrens & Taubert D30,378/52; *Martin & Roka* D26,751/53: Human blood basophils are rich in heparin or, at least, some closely-related material.

Turchini & van Kien D88,984/55: Basophils are claimed to produce heparin and this synthesis is disturbed in disease so that precursor substances are liberated which are necessary for the elimination of toxic products.

HISTAMINE

Code A9,199/37: In various species, the granular leukocytes (separated by centrifugation) are found to be especially rich in histamine. Indirect evidence suggests that the eosinophils may carry most of this substance, but the basophils have not been separately studied.

Code & Macdonald A14,572/37: The blood-histamine content is considerably raised in patients with leukemia. [No mention is made of any possible associated basophilia (*H.S.*).]

Thiersch G18,799/47: Report on the histaminase content of the blood in chronic myeloid leukemia.

Shimkin et al. B49,546/49: In chronic myeloid leukemia, the blood histamine is considerably raised and roughly proportional to the white cell count. [Basophil counts have not been reported (*H.S.*).]

Pearce & Valentine B53,380/50: In chronic myeloid leukemia, the blood histamine is markedly elevated but the urinary histamine excretion remains normal.

Shimkin & Bierman B53,091/50: In chronic myeloid leukemia, the blood histamine is raised up to 2,300 μg/100 ml in comparison with 2–8.5 μg/100 ml in normal blood. [No mention of the blood basophil counts (*H.S.*).]

Valentine et al. G18,804/50; D39,647/55: The basophils are rich in histamine and there is a good correlation between blood-histamine concentration and basophilia in various leukemic and leukemoid reactions.

Graham et al. D28,268/52; C9,304/55: About half the histamine of normal blood is in the basophils, one-third in the eosinophils, and the remaining one-sixth in all other blood cells combined. The platelets contain only about 3 per cent of the total blood histamine.

Ehrich D26,427/53: Basophils, like MCs, are very rich in histamine.

Code & Mitchell C34,861/57: In the dog, nearly all the blood histamine is carried by the eosinophils, while in the guinea-pig and man both eosinophils and basophils contain histamine. In man, most of it is associated with the basophils, indeed, sometimes human eosinophils contain no histamine.

Mitchell & Cass C66,822/59: In children, the amount of histamine in the blood is closely related to the number of circulating basophils and there is little or no histamine in the plasma. 5–HT is contained predominantly in the platelets.

Albanus & Winqvist D91,881/61: Daily s.c. injections of horse plasma causes intense basophilia and a rise in the histamine content of the bone marrow in guinea-pigs. No correlation was found between histamine content and the number of eosinophils.

Hartman et al. E98,125/61: Basophils from the buffy coat of patients with myelogenous leukemia contain histidine decarboxylase, since they are capable of transforming C^{14}-histidine into C^{14}-histamine under sterile conditions.

Lindell et al. D41,119/61: Upon addition of C^{14}-histidine in vitro to blood samples of patients with myelogenous leukemia or urticaria pigmentosa, the degree of histamine formation was proportional to the number of mature basophils. It is concluded that the basophils not only contain, but also synthesize histamine.

Code et al. G18,722/64: Unlike in urticaria pigmentosa, the urinary excretion of histamine is usually not raised in patients with basophilic leukemia, although the histamine content of the blood and bone marrow are enormously increased. Apparently, here, histamine is strongly bound to the basophils and thus prevented from being excreted. Yet, these cells die and eventually must release their histamine but perhaps they carry it to the lung or gut and thus permit its elimination, bypassing urinary excretion.

THEORIES

(Cf. also Relationship of Basophils and Mast Cells to Blood Eosinophils, *p.* 364, Histochemistry, *p.* 334, and Biochemistry, *p.* 355.)

The blood basophil resembles the tissue MC in its ability to produce *heparin* and *histamine.* (This fact has been well substantiated by data discussed in previous chapters.) There is also good evidence in support of the view that—again, like the tissue MCs—the blood basophils participate in *anaphylaxis* by discharging their granules as a response to antigen-antibody reactions. However, the nature of this participation is not yet clearly understood and it remains questionable whether all forms of allergic reactions affect the basophils.

Through the discharge of heparin, the basophils might also participate in the regulation of the *blood-lipid* level, but little is known about the importance of this mechanism in physiology and pathology. Numerous other theories have been formulated, but these are not sufficiently supported by evidence to deserve detailed discussion.

ALLERGY

Saito D31,873/62: On the basis of indirect evidence, derived from interpretation of blood counts in various infections, immune diseases, and collagen diseases, it is assumed that the basophil plays an important part in immunity.

Shelley E52,331/62: In rabbits sensitized by various antigens, re-exposure to the same antigen produces basophil degranulation both in vivo and in vitro. Heparin does not interfere with this reaction in vitro, but oxalate does, "indicating a presumed need for calcium." In man, contact allergens such as poison-ivy extract or paraphenylenediamine, have also shown positive reactions in sensitized patients. "Apparently the basophil reaction detects circulating antibody in any allergy."

Shelley G18,654/64: "Although normally not seen in the skin, basophils regularly accumulate at inflammatory sites of allergic origin. Such a dermal migration is entirely characteristic and diagnostic for allergic contact dermatitis, as well as the tuberculin type hypersensitivity response. It does not occur in simple toxic inflammatory responses."

LIPID METABOLISM

Braunsteiner & Thumb C62,702/58: Basophilia is noted in various conditions conducive to lipemia, such as diabetes, myxedema, acute thrombopenia, and lipid nephrosis. Conversely, in hyperthyroidism there is basopenia. It is assumed that the basophils play an important role in the degradation of macromolecular serum lipoproteins.

Shelley E52,331/62: High-fat diets cause degranulation of basophils in man, while carbohydrate and protein feedings are without this effect. Presumably, the basophil plays a role in regulating lipemia through the release of heparin.

OTHER THEORIES

Ringoen D27,892/23: The accumulation of basophils around an area of egg-white injection is allegedly due to chemotaxis, and the basophils are thought to phagocytose polymorphonuclear leukocytes.

Michels C72,066/38: Review of various old theories concerning the function of basophils, regarding them as developmental stages of MCs, immature eosinophils, lymphocytes, having undergone mucoid degeneration, etc.

Miale D24,134/58: In this currently much-used 735-page textbook of hematology, only a paragraph of nine lines is devoted to the basophils; this includes the statement that "their functional importance is probably minor."

10

Theories

EVER since Ehrlich discovered the MC in 1878, its function has been the topic of intense speculation. It will be remembered that Ehrlich called these cells "Mastzellen" (well-fed cells) because their cytoplasm is stuffed full with large metachromatic granules which were believed in turn to provide vital nourishment to the surrounding connective tissue. By 1938, Michels could enumerate 25 hypotheses of MC function. In the following pages we shall have to discuss more than 30 that are currently attracting interest, but we will not elaborate on many additional concepts incidentally quoted in the preceding chapters.

For general orientation, it may be said by way of an introduction, that there is excellent evidence in support of the view that the MCs are closely related to the *blood basophils* and there also appear to exist interesting relationships between these cells and *eosinophil leukocytes,* although their nature has not yet been elucidated.

The MCs undoubtedly contain and produce *heparin, histamine,* a variety of *enzymes* and, at least in certain species, *5-HT*. Perhaps they also secrete *SRS* and *catecholamines*. Through their active constituents the MCs can undoubtedly modify local reactions to injury by influencing *vasoconstriction, capillary permeability,* and the *blood-clotting* mechanism. In this manner, the MCs play a vital role in *inflammation, connective-tissue proliferation, thrombosis, edema* formation, and certain *anaphylactic and anaphylactoid reactions*. Through the production of heparin, they probably also affect *lipid metabolism*.

Recent observations on *calciphylaxis and calcergy* have shown that MC granules possess an extraordinary affinity for certain metals, including calcium, iron, and zinc: presumably, they can bind and localize blood-borne elements through the phenomenon of *"mastopexis"*. These studies revealed, furthermore, that under certain conditions, MC-dischargers (e.g., polymyxin, 48/80) can produce selective calcification of the autonomic nervous system and it is tempting to speculate upon the possible role that MC products may exert upon *nervous* tissue under normal and morbid conditions.

Reviews:
Lehner D27,094/24
**Michels* C72,066/38 *p. 310*
Baglioni C16,539/54 *p. 161*
Arvy D26,724/55 *p. 85*
**Kelsall & Crabb* D26,076/59 *p. 57*
Lindholm C70,944/59
**West* D33,712/62

RELATION OF BLOOD BASOPHILS TO MAST CELLS

Ever since the discovery of the MCs and blood basophils, the relationship between them has been the subject of a debate which still goes on today. The chief

arguments in support of the view that tissue MCs and blood basophils are *essentially identical* or, at least, closely related cell types are:

(1) Both contain metachromatic basophilic granules.

(2) It is highly probable that both contain heparin and histamine.

(3) Urticaria pigmentosa, a disease due to tissue-MC proliferation, is frequently accompanied by blood basophilia and sometimes by basophilic leukemia.

(4) There exists a curious inverse relationship between the tissue-MC density and the blood basophil count in various species. In the rabbit, as in birds, blood basophils are numerous and tissue MCs sparse, while the reverse is true of man, guinea-pig, dog, cat, rat, and mouse. It has been thought, therefore, that the basophils may compensate for a deficiency in MCs.

(5) Although there are some morphologic differences between typical MCs and basophils, many transitional stages between the two types can be observed.

(6) In lower vertebrates, migration of basophils into tissues is commonly seen and the two types are virtually indistinguishable by morphologic criteria.

(7) Under suitable conditions, degranulation of both tissue MCs and blood basophils can be obtained by MC-dischargers, anaphylactic reactions, stress, and glucocorticoids.

(8) When isolated cells of a transplantable murine mastocytoma are injected i.v., MC-leukemia develops.

On the other hand, there are good reasons to consider the blood basophils as *essentially different* from the tissue MCs:

(1) In most species, including man, the intimate structure of the blood basophil differs from that of the tissue MC. The basophil is smaller, round, and possesses a lobulated nucleus, while the MC is larger, often equipped with long pseudopodia, and has a roundish or ovoid nucleus. The two types also differ in their electron-microscopic structure and in the solubility of their metachromatic granules.

(2) There is good evidence that in mammals during postnatal life blood basophils arise only from hemopoietic tissue, while tissue MCs are formed in connective tissue either through the division of parent MCs or by metaplasia from fibroblasts or histiocytes. However, in lower animals as well as in embryonic mammals, basophils arising in the bone marrow can apparently migrate into tissues and become indistinguishable from ordinary MCs.

(3) The tissue MCs are usually not influenced by systemic diseases which considerably alter the blood-basophil count; this is particularly true in certain basophilic leukemias. Conversely, the cutaneous MC proliferation in urticaria pigmentosa is only occasionally associated with blood basophilia.

(4) Unlike the tissue MCs, the blood basophils are sometimes peroxidase-positive.

(5) Unlike the tissue MCs, the blood basophils are capable of intense ameboid motility.

In *summary,* it may be said that tissue MCs and blood basophils show a striking similarity in most of their structural and chemical characteristics; they certainly resemble each other more than any other cell. They also tend to respond to various stimuli in a similar manner, although this is not always the case. Of course, the medium influences the structure and reactivity of a cell. The same fibroblast will take on different shapes in a tendon, in loose connective tissue, and in an inflammatory granuloma. The same histiocyte will have strikingly dissimilar

characteristics depending upon the material it ingests. Even the shape of neoplastic cells differs when they grow as solid tumors or as ascites tumors. Until further evidence is forthcoming, it seems reasonable to assume, therefore, that the blood basophil represents the circulating form of the MC system.

Reviews: *Michels* C72,066/38 *pp. 246, 326*; *Baglioni* C16,539/54 *pp. 223, 224*; *Arvy* D26,724/55 *p. 75*; *Kelsall & Crabb* D26,076/59; *Riley* C70,315/59; *Hittmair* D39,841/60; *Quattrin* E22,504/63

Milchner D29,581/1899. In basophilic leukemia, the basophils may emigrate into ascitic fluid. Because of their metachromatic granules, these cells must be regarded as MCs but their lobulated nucleus differentiates them from oridinary tissue MCs.

Wolff D27,646/04: MCs are derived from basophils because they are so frequently observed in the surroundings of blood vessels. Allegedly, basophils can occasionally be seen during the process of migration through the vessel wall.

Weidenreich D27,422/08: The blood basophils — which in agreement with Maximow's suggestion should be called "mastleucocytes" — are essentially different from MCs. Although the former can emigrate into the tissues, they retain the characteristics of blood basophils.

Maximow B79,779/07: In the rabbit, which has many blood basophils, connective-tissue MCs are scarce. In the skin, MCs appear to develop from lymphocytoid wandering cells, beginning at the 22nd day of embryonic life, while basophils develop from mast myelocytes in the bone marrow at approximately the same period. However, it is still impossible to decide whether the two types of cells are derivatives of a common precursor.

Pappenheim D27,984/09: Extensive theoretical discussion on the morphology of leukocytes in various species with some remarks concerning the relationship between the basophils and MCs.

Pappenheim & Szécsi D30,558/12; *Szécsi* D27,413/12: MCs arise locally in connective tissue and are much larger than blood basophils, thus representing a special cell type.

Jordan & Flippin D27,962/13: True MCs are found in the blood of the box turtle (*Cistudo carolina*) and in other *Chelonia*.

Maximow D29,280/13: In man and various animals species, the MCs can be clearly differentiated from blood basophils by their size, shape, the structure of the nucleus, and the staining characteristics of the granules. However, intermediate types exist and in certain species, a distinction between the two forms is impossible. In the embryo, they both arise from lymphocytoid precursors. "In any event, in the adult organism the two forms of mast cells represent two distinct cell lines which are no longer genetically related to each other; also they do not originate from any common cell type. Only in the rat does one find possible intermediate types between young mast cells and mast myelocytes in the bone marrow."

Downey D27,429/15: The MCs of the blood and bone marrow in guinea-pigs differ from hematogenous MCs of other animals, both in staining reactions and in structure. "However, they resemble mast cells more than any other type of granulocyte, and consequently they must be classified as mast cells of a distinctive type ('guinea pig type,' according to Weidenreich)."

Herzog D26,808/16: On the basis of morphologic studies, it is assumed that the so-called mast myelocytes, mast leukocytes (blood basophils), and tissue MCs, are all but different forms of the same cell type.

Laguesse D27,510/19: The blood basophils are considered to be derivatives of bone-marrow MCs.

Staemmler D26,807/21: The tissue MCs are usually not influenced by systemic diseases (including certain basophilic leukemias) which cause considerable changes in blood-basophil counts.

Lauda & Flaum D26,828/29; *Schürer* D40,720/46: Large MCs of the "Kugelhaufen" type are found in the blood of the vena cava, the mesenteric veins, the heart, and the serous membranes (peritoneum, pleura, pericardium) but never in the venous blood of the tail in rats. It is assumed that they enter the blood through the lymph spaces of the peritoneal cavity and are derived from the serous membranes and the bone marrow.

Michels C72,066/38: During early embryonic development, there is no obvious difference between MCs and basophils, since both take origin from a common mesenchymal

cell, the "resting wandering cell of Saxer." In mammals, MCs are still histogenous while basophils are myelogenous. A review of the literature shows that most investigators tend to admit that in lower vertebrates myelogenous basophils can leave the blood stream and transform themselves into tissue MCs which morphologically resemble those of mammals. However, the contention of some investigators that the reverse process also occurs, namely that tissue MCs may migrate into the blood, is not considered to be sufficiently substantiated. [Yet, an invasion of cutaneous MCs into the blood appears to occur in certain forms of urticaria pigmentosa (*H.S.*).]

Doan & Reinhart D26,488/41: As judged by their histologic characteristics, the basophils of blood and tissue are distinct entities.

Moeschlin D30,597/41; *Undritz* D30,200/46; 98,255/46: The tissue basophils of the bone marrow are designated as "basophils with insoluble granulation" because their granules, unlike those of blood basophils, are insoluble in methyl alcohol. The young stages of the bone-marrow MC contain large nuclei, the mature stages small round nuclei, and their granules are oxidase-negative, while the blood basophils possess bizarre segmented nuclei and their granules are partly oxidase-positive. Tissue MCs may enter the blood stream in the human embryo as well as in the adult rat or mouse, but they are not found in the blood of adult man.

Ferràta & Storti E2,368/46: MCs can be distinguished from blood basophils on morphologic grounds. The size of the basophil is usually smaller than that of the MC and, unlike the latter, it possesses a lobulated nucleus. The granules are soluble in water and methyl alcohol and do not give the characteristic Hale reaction of ordinary tissue MCs. Also, unlike the MCs, the basophils are usually PAS-negative.

Liebman D61,516/47: "It is generally agreed that in the lower vertebrates the tissue mast cells originate from those of the blood: the mast leucocytes or basophils. As for the mammals, the majority of hematologists maintain — largely on the basis of the solubility of the cellular inclusions — that each represents a distinct cell type.

"In rodents and some other groups, however, a separation of mast leucocytes from mast-cells is difficult and a migration of the former into the tissues has been repeatedly observed; in inflammation this seems to be of general occurrence. There are also claims that forms intermediate between the two kinds are encountered. The numerical correlation between the blood elements and those of the tissues, observed in mammals, adds further support to the idea that here too both kinds are genetically related. And, finally, our own observations on the variations of invertebrate trephocytes and their inclusions, depending on the surroundings, make it very doubtful whether the argument of variability can be applied against a unitarian conception of the mammalian mast-cell. Consequently, both the tissue mast-cells and those of the blood will be considered as representing variants of a single type throughout the entire vertebrate section."

Marinone D26,632/47: In cases of myeloid leukemia, the large basophilic granules of the basophils are most soluble in water. It appears that solubility in water is a sign of maturation of MC granules.

Bremy C72,062/50: There is no doubt that, in the adult human being, the MCs differ from the blood basophils both as regards their structure and their origin, since the latter are much smaller and originate in the myeloid tissue. However, both phylogenetically and ontogenetically the earliest differentiation of MCs and blood basophils is from the same type of mesenchyma and, thus, as regards their primary origin, the two cell types are comparable. The possibility of a functional homology is also considered.

Behrens & Taubert D30,378/52: Demonstration of a metachromatic anticoagulant material, presumably heparin, in the blood basophils of the horse.

Graham et al. D28,268/52: The basophils of normal and leukemic human blood are especially rich in histamine.

Martin & Roka D26,751/53: A heparin-like substance could be demonstrated in the basophils of a patient with blood-MC leukemia.

Ehrich D26,427/53: The histamine content of the blood is well correlated with the number of circulating MCs (basophils), but not with that of eosinophils or neutrophils. This could be confirmed on the blood of cats, guinea-pigs, rabbits, and man, as well as on the blood of leukemic patients. "These observations are in keeping with the view that blood and tissue mast cells are functionally the same."

Speirs C3,414/55: Although MCs arise in connective tissue while blood basophils are formed in the hemopoietic organs and later retain the characteristic leukocyte-type of nucleus and high ameboid motility, the two cell types are similar in many respects; both contain metachromatic granules, large amounts of histamine and heparin, and both allegedly disintegrate under the influence of systemic stress or glucocorticoids.

Lennert et al. D26,471/56: A case of basophilic leukemia with tissue mastocytosis.

Asboe-Hansen & Kaalund-Jorgensen C25,899/56: In a case of urticaria pigmentosa with tissue mastocytosis, there was also intense blood basophilia which is thought to support the assumption that, in the blood and tissues, we are dealing with the same cell type.

Braunsteiner & Pakesch D30,632/57: The electron-microscopic structure of blood basophils differs rather essentially from that of tissue MCs.

Padawer D30,194/57: While tissue MCs have a round vesicular nucleus, basophilic leukocytes contain the polymorph nucleus typical of leukocytes. In the rat, MCs are numerous while basophilic leukocytes are rare, the reverse being true of the rabbit. "Thus there are good grounds for considering 'tissue' mast cells as distinct entities."

Fulton et al. C35,831/57: Ehrlich and many others referred to basophilic leukocytes as "blood mast cells" and there are many reasons to believe that the two are merely different forms of the same basic type. In many lower vertebrates, blood MCs appear to leave the blood and become transformed into tissue MCs. Furthermore, an inverse relationship appears to exist between them in that fish have many tissue MCs and practically no blood basophils, essentially the same being true of the cat, mouse, hamster, and rat. Conversely, in the rabbit most MCs are in the blood, but the horned toad and certain turtles have numerous MCs both in the blood and in tissues. Yet, many workers do not agree that blood and tissue MCs are similar.

Braunsteiner et al. D27,986/57: Since, according to the literature, both blood basophils and MCs are rich in heparin and histamine and since both these cell types contain granules which are metachromatic, like heparin, they are considered to be intimately related.

Beare D27,976/58: In several instances, urticaria pigmentosa was associated with MC-leukemia.

Boseila C68,531/59: On the basis of extensive systematic studies, and an exhaustive review of the literature, "the author concludes that the basophils are probably the circulating members of the mast system representing a mobile source of mucopolysaccharide and histamine." They are also thought to compensate for tissue MCs when special generalized requirements for MC products arise.

Ono et al. D27,408/59: When isolated cells of the transplantable mastocytoma of LAF_1 mice are injected i.v. into animals of the same strain, MC-leukemia results. In association with hepatomegaly and splenomegaly, infiltration of the spinal cord and ganglia frequently caused paralysis of the hind legs, but pulmonary metastases were rare and the lymph nodes were not enlarged. In a few cases, the skull was infiltrated and small subcutaneous tumor nodules were quite common. In the blood, the MCs tend to round off and to become less granulated than tissue MCs. "These and other observations suggest the essential identity of blood and tissue mast cells and suggest that mast cells are an independent cell type with primary residence in tissues outside the hemopoietic organs."

Braunsteiner D59,693/59: A review of the literature on the relationship between MCs and basophils shows that the two forms are closely related if not identical.

Brinkmann D33,665/59: A case of generalized mastocytosis with "phenomenal flushing" and shock-like spells eventually terminated in basophil leukemia. Presumably, close relatonships exist between tissue MCs and blood basophils.

Fisher C85,479/60: A survey of literature and personal observations lead to the conclusion that the blood MCs or "basophils" and the tissue MCs are closely related.

Asboe-Hansen D26,742/60: In a patient with urticaria pigmentosa, in generalized tissue mastocytosis there was also basophilic leukemia, a fact which "supplies support of the modern view that blood basophils have some relationship to the tissue mast cells."

Winqvist D39,532/60; *Chan & Yoffey* D39,533/60: Allergic sensitization of the guinea-pig is followed by an enormous increase in the number of basophil leukocytes in the blood as well as in the bone marrow.

Lennert & Schubert D33,718/61: As judged by human bone-marrow specimens, the granules of blood basophils are water-soluble but not methanol-soluble. Thereby, they differ in principle from the granules of the tissue MCs. Furthermore, at *p*H 2.6, the basophils

are much more readily stainable with toluidine blue than are the tissue MCs. Sudan black stains the basophils but not the tissue MCs. Peroxydase is regularly demonstrable in basophils but not in tissue MCs. It is concluded that "the blood and tissue mast cells of man are indubitably two separate cell strains; they undoubtedly show a striking cytochemical similarity but the granules of the blood mast cells are water-soluble and peroxydase-positive whereby they differ from the tissue mast cells."

Amann & Martin D26,616/61: In a patient with MC-leukemia, it was possible to extract from the basophils a heparin-like substance which inhibited several phases of blood coagulation like heparin, and stained metachomatically with toluidine blue.

Szweda et al. D20,223/62: A case of systemic mastocytosis was associated with MC-leukemia.

Niebauer D58,906/63: MCs and basophils differ in many morphologic and cytochemical characteristics. They probably also develop from different precursors and should be strictly distinguished from each other.

RELATION OF BLOOD EOSINOPHILS TO MAST CELLS

Some close interdependence of MCs and eosinophils is suggested by the fact that the two cell types often (though not always) show parallel fluctuations, for example, in inflammatory exudates, around necrotic foci, and in the skin of patients suffering from various dermatoses including urticaria pigmentosa. Since MCs and basophils produce histamine while eosinophils allegedly inactivate this substance, it has been assumed that eosinophils are attracted by degranulating MCs and basophils to neutralize their products.

Pültz D30,085/12: In the fluid of cutaneous vesicles produced in man by the local application of croton oil, as well as in cutaneous vesicles occurring in the course of various diseases, numerous MCs and eosinophils are simultaneously present. Some relation between eosinophils and MCs is, hence, suspected.

Kovács & Juhász C70,358/52: An antihistaminic effect can be demonstrated in suspensions of eosinophil leukocytes from animals and man. Presumably, the eosinophils can antagonize blood histamine.

Dantchev D53,654/52: In certain cases of basophilic leukemia there are basophils which also contain eosinophilic granulations ("eosinobasophils") which suggests a close relationship between eosinophils and basophils.

Hillebrecht G9,243/52: In various psychiatric and ovarian disorders there is "some correlation" between the number of eosinophils and basophils.

Prakken & Woerdeman D26,813/52: In the skin of patients suffering from a variety of dermatoses, eosinophilia was always connected with an increased number of MCs. However, cutaneous mastocytosis may occur without accompanying eosinophilia.

Vercauteren D27,722/53: On the basis of studies with isolated blood-eosinophil granules, it is concluded that these contain an antihistaminic and presumably participate in the detoxification of histamine in vivo.

Baglioni C16,539/54 *pp. 161, 181:* Discussion.

Riley C9,303/55: Discussion.

Hamerston et al. E92,384/56: In a series of institutionalized patients with convulsive disorders, a statistically-significant correlation was noted between blood basophils and eosinophils.

Code & Mitchell C34,861/57: In the dog, nearly all the blood histamine is carried by the eosinophils, while in the guinea-pig and man both eosinophils and basophils contain histamine, in man most of it being associated with the basophils. Indeed, in man, sometimes the eosinophils contain no histamine.

West C64,139/58: Eosinophils tend to accumulate near disintegrating MCs, for example, urticaria pigmentosa after X-irradiation or in dog mastocytomas after treatment with histamine-liberators. Eosinophils used to be considered as the chief source of histamine, but perhaps they are more concerned with detoxification of histamine.

Fernex D66,465/62: "Mast cells in connective tissues and eosinophils in blood and tissues are intimately related: histamine is produced by mast cells, has a strong eosinotactic activity, and probably stimulates eosinopoiesis."

Aschkenasy D68,599/62: Based on morphologic considerations, it is assumed that eosinophils are attracted by degranulating MCs in order to phagocytose histamine and perhaps also other MC products.

Juhlin E26,200/63: A review of the literature shows that a correlation between circulating eosinophils and basophils has been reported by some investigators (*Code et al.* D30,193/54; *Hamerston et al.* E92,384/56; *Kovács* E98,657/61; *Rorsman & Rosengren* E88,078/58) while others failed to find any such parallelism (*Angeli et al.* E41,475/55; *Boseila & Uhrbrand* E45,649/58; *Braunsteiner & Thumb* C89,221/58; *Braunsteiner et al.* E52,570/60; *Mitchell* D92,371/58; *Shelley* E52,331/62). Since the basophils produce histamine and the eosinophils are alleged to neutralize histamine, according to some investigators (*Archer et al.* D37,484/62; *Kovács & Juhász* C70,358/52; *Vercauteren* D27,722/53) a correlation between these two cell types is to be expected under certain circumstances.

Orfanos & Stüttgen E37,429/63: Electron-microscopic studies on human mastocytoma tissue, topically treated with 48/80, indicate that the degranulation of the MCs is associated with a "cytotactic" attraction and subsequent degranulation of eosinophils.

HEPARIN

[Cf. HISTOCHEMISTRY (*p.* 45), BIOCHEMISTRY (*p.* 301), AGENTS AFFECTING MAST CELLS (*p.* 132) for pertinent original articles.]

It may be taken as a well-established fact today that the MCs contain heparin. Most of the evidence in support of this view has been discussed in other sections, hence, it will suffice here to summarize the salient points:

1. There exists a good correlation between the MC density in various normal tissues of different animal species and their heparin content.
2. Heparin can be prepared from isolated MCs.
3. Heparin can be prepared from isolated MC granules.
4. Morbid MC-proliferations (mastocytoses, mastocytomas) are extraordinarily rich in heparin.
5. The chemical properties of MC-granules (including their ability to stain metachromatically with basic analine dyes) are virtually identical with those of heparin.

There is still some controversy about the question whether MCs synthesize all the heparin made in the body or whether they ingest some of it ready-made. When heparin is brought in contact with tissues it is undoubtedly phagocytosed by fibroblasts and histiocytes which then assume an MC-like appearance, being studded with metachromatic granules. However, it remains questionable whether these cells are true MCs. In any event, labeled-sulfate is incorporated into MC-heparin, an observation suggesting that the cells are capable of synthesizing this compound.

There is also good evidence to show that MCs can release stored heparin into the blood. During peptone shock, heparin and MC granules are simultaneously discharged from the hepatic MCs. Furthermore, in certain types of mastocytoses and mastocytomas, irritation of the lesions induces a decrease in the coagulability of the blood with some increase in its heparin content. This may be accompanied by the urinary excretion of heparin or, at least, of some heparin-like metachromatic material. All these observations are consonant with the view that the MCs not only store but also synthesize and discharge heparin.

HISTAMINE

[Cf. HISTOCHEMISTRY (*p.* 45), BIOCHEMISTRY (*p.* 301), AGENTS AFFECTING MAST CELLS (*p.* 132) for pertinent original articles.]

While according to predominant contemporary opinion, all the heparin produced in the body arises from MCs, it is probable that histamine is synthesized not only by these cells but also in other tissues. Still, it may be taken as well established that the MCs can produce, store, and discharge large amounts of histamine because:

1. There exists a striking parallelism between the histamine and MC content of the various normal tissues.
2. Isolated MCs are rich in histamine.
3. Isolated MC granules are rich in histamine.
4. Morbid MC-proliferations (mastocytoses, mastocytomas) often contain abundant amounts of histamine.
5. Upon irritation, mastocytosis and mastocytoma lesions discharge histamine into the blood and the urine may contain histamine and histamine metabolites.
6. Virtually the whole histidine-decarboxylase activity of the body is concentrated in MCs and radioactive histidine can be converted to histamine by tissue rich in MCs (as well as by isolated MCs) in vitro.
7. Various experimental interventions which discharge the granules from the MCs also release their histamine.

On the other hand, histamine is also present in leukocytes and platelets as well as in certain tissues poor in MCs, hence, the compound does not appear to be derived exclusively from the MCs.

On the basis of rather indirect evidence, it has been assumed that vacuolization of MCs is related to histamine discharge, while complete lysis of the granules is an indication of heparin secretion. It has also been claimed that the discharge of histamine does not necessarily require cell disruption. However, these views require further confirmation.

Hill C64,094/58: On the basis of histologic observations, it is assumed that vacuolization of MCs is related to histamine discharge, complete lysis of the granules to the secretion of heparin, and excretion of granules after intracellular loss of their tingibility to the production of ground substances, particularly mucopolysaccharides of the hyaluronic acid type.

Smith C54,403/58: While i.p. injection of such histamine-liberators as stilbamidine, d-tubocurarine, 48/80, and distilled water cause mesenteric MC disruption simultaneously with histamine discharge in the rat, the i.p. injection of toluidine blue or protamine sulfate may result in a similar histamine discharge without any microscopically-visible change in the mesenteric MCs. Indeed, repeated injection of the latter substances at intervals of from 20 minutes to 24 hours results in repeated histamine discharges which are still unaccompanied by morphologic evidence of MC disruption. "It is concluded that secretion by the mast cell does not require cell disruption and death as much of the literature indicates but is merocrine in nature."

5-HT AND RELATED COMPOUNDS

[Cf. also HISTOCHEMISTRY (*p.* 45), BIOCHEMISTRY (*p.* 301), and AGENTS INFLUENCING THE MAST CELLS (*p.* 132).]

There is convincing evidence to show that the MCs of some, though not all species, do synthesize, store, and discharge 5–HT:

1. In normal tissues of the rat and mouse, there exists a good correlation between MC counts and 5–HT content, but this is not the case in numerous other species examined, including man.
2. Isolated normal MCs of the rat are rich in 5–HT.
3. Isolated MC granules of the rat are rich in 5–HT.
4. The specific lesions of human mastocytoses as those of canine and bovine mastocytomas contain little or no 5–HT although they are rich in histamine and heparin. On the other hand, murine mastocytomas are rich in 5–HT.
5. Following the experimental interventions which discharge the MCs, 5–HT is released together with the granules in the rat. Furthermore, in the mouse, painting of the skin with carcinogens, which increase the local MC population, is associated with a corresponding rise in the topical 5–HT concentration.
6. Homogenates of murine mastocytomas contain a 5–HTP decarboxylase, capable of synthesizing 5–HT from 5–HTP. However, apparently the blood platelets are likewise capable of such synthesis and the argrentaffin cells, rather than the MCs, appear to be the main source of 5–HT in most species, including man.

SLOW-REACTING SUBSTANCE (SRS)

[Cf. also *p.* 324.]

SRS is apparently liberated simultaneously with histamine from MCs; for example, in anaphylaxis and after treatment by 48/80 and other agents known to disrupt MCs.

HYALURONIC ACID

[Cf. also GROUND SUBSTANCE AND HYALURONIC ACID PRODUCTION (*p.* 372).]

It has been suggested that the MCs also produce hyaluronic acid and thereby influence the production of ground substance. However, as we have seen elsewhere, recent investigations have given very little support to this concept.

MUCIN

Since the secretory products of various mucinous glands and MC granules stain almost identically with metachromatic dyes, a relationship of the latter to mucins has long been suspected. Indeed, it has been suggested that the MCs may contribute to the secretion of mucin by glandular cells and that granule formation in tissue MCs and blood basophils constitutes some kind of "mucoid degeneration." The MCs were also thought to contribute to synovial mucin. However, the term "mucin" is difficult to define. Staining with mucicarmine is not a safe diagnostic criterion since heparin also takes up this dye. What the histologist considers mucin appears to correspond chemically to acid mucopolysaccharides, high-molecular esters of sulfuric acid, which are demonstrable both in MCs and in the cells of mucinous glands.

Reviews: *Kelsall & Crabb* D26,076/59, *p. 106*
Arvy D26,724/55, *pp. 64, 65*

Raudnitz D28,536/1883: MCs are considered to be "mucinously degenerated cells."

Hoyer D28,275/1890: Using a variety of metachromatic dyes, the staining of MCs in the tongue, salivary glands, larynx, and intestinal tract of various animal species "exhibit

granules whose tinctorial properties are completely identical with those of mucin-containing glandular elements." It is true that the staining of MC granules resists decoloration in alcohol better than the mucin of intestinal epithelia, but this is no fundamental difference, because even the mucin in the goblet cells of intestinal epithelia and in the tubules of the snail foot can resist decoloration by alcohol or dilute acids for dyes, while concentrated acids decolorize the MC granules as well. "The more compact the examined mucinous mass, the more its behaviour resembles that of mast cell granules." Still, the author does not maintain that the identity of mucin and mast cell granules has been definitely proved. He refers to correspondence with Ehrlich who insists on the special nature of the MC granule which he often finds to have "crystalline aspect" and "is very resistant to water in which mucin swells considerably."

Unna D27,089/1891: On the basis of their tinctorial properties, the MC granules are considered to consist of mucin.

Harris D26,716/00: MCs are thought to secrete mucin and since they frequently discharge their granules in infected tissue, they "may elaborate some substance which is bactericidal."

Pappenheim D31,529/04: MCs are considered to arise from mucoid degeneration of nongranulated precursors.

Clowes & Owen D28,257/04: "Since mast cells [in the rat's tongue] take polychrome methylene blue much more readily than does mucin, and exhibit a blue color with acids and a red with alkalis, whilst mucin is red with acids and decolorized with alkalis, also since the globules of mucin are far more soluble in alkaline solutions than are the mast-cell granules, it may be concluded that they differ very materially in chemical constitution."

Schaffer D30,589/07: The granules in the subcutaneous MCs of the rat stain like mucin with some but not with all dyes, which speaks against their mucinous nature.

Schwenter-Trachsler D27,711/08: On the basis of their staining reactions, MC granules must be clearly differentiated from mucin.

Pröscher D27,970/09: The metachromatic granules in basophils and MCs are considered to result from "mucoid degeneration."

Staemmler D26,807/21: On the basis of extensive histologic studies in man, the conclusion is reached that "the mastocytes are unicellular glandular organs of the connective tissue, whose function it is to form the mucin necessary for the production of the intercellular ground substance." The fact that fetal connective tissue contains more "mucin" than that of the adult, is explained by the assumption that during fetal life, fibroblasts may be capable of producing this material. It is also emphasized that, although the ground substance of the adult does not stain like "mucin," this material can be demonstrated in it by chemical means and besides, the histologic concept of mucin is rather vague and there may be several variants of it. [It must be kept in mind that, at the time of these studies, hyaluronic acid had not yet been discovered (*H.S.*).]

Wermel & Sassuchin D39,520/28: Mucin was originally defined as "a viscous thread-forming slippery fluid which upon addition of acetic acid forms a fibrous precipitate of characteristic aspect." It was at first thought to be a protein but is now classed as a mucoprotein. The only characteristic feature of epithelial mucin is the presence of mucoitin-sulfuric-acid and a high-molecular esterified sulfuric acid. The mucus of goblet cells and salivary glands may now be defined as: "an epithelial-secretion product containing mucoitin-sulfuric-acid as its only characteristic constituent". The staining with mucicarmine depends upon the formation of a bond between the aluminum carminate of the mucicarmine solution and mucoitin-sulfuric-acid. However, tingibility with mucicarmine is by no means characteristic for mucins; they stain even more easily with metachromatic dyes. For the staining of MCs, the mucicarmine method is of no practical value. Although heparin stains with mucicarmine and a mucicarmine-positive halo develops around MCs, the granules themselves are difficult to demonstrate with this technique *(Sylvén D31,570/39)*. Other investigators likewise found mucicarmine to stain MCs only superficially and not very intensely.

Sylvén D31,570/39: Attention is called to the fact that the mucicarmine method should not be considered as the only specific mucin stain; most mucinous substances stain even better with metachromatic dyes. There appear to be close relationships between epithelial and connective-tissue mucins, both of which are presumably high-molecular polysaccharide ester sulfates. The accumulation of metachromatic "mucin" in the surroundings of carcinoma tissue is probably largely due to the local MCs.

Sylvén D30,594/45: Studies on many human tumors suggest "that all growing tumor vegetations constantly contain high molecular ester sulphuric acids in their cell territories." They also contain numerous MCs which may account for the formation of metachromatic high-molecular sulfuric acid esters. However, "the old misleading term mucus" should be abandoned.

Oria D26,726/45: Because of their mucoid-staining reactions and frequent occurrence in the oro-pharyngeal mucous membranes and in the stroma of muciparous glands, it is assumed that MCs may participate in the production of glandular mucinous secretions.

Ducci D39,802/46: A comparatively large number of MCs in the synovial membranes of man suggests that these cells participate in synovial mucin formation.

Asplund & Holmgren B17,599/47: "In the normal and pregnant uterine, mucous membrane cells with occasional metachromatic granulations (called by the authors 'specific cells') are found. These cells are neither mast cells nor apparently plasma-mast cells. The 'specific' cells are met more frequently during the secretion phase. After the cessation of menstruation, they seem to disappear from the mucous membrane. As the cells are only met during the fertile age, it is assumed that, "in view of its tinctorial properties, the substance in question will probably consist of high molecular ester sulphuric acids."

Urtubey D27,059/48: Because of the mucin-like histochemical reactions given by MC granules, these cells are assumed to have the physiologic role of producing mucin and consequently are designated as myxoblasts.

Janes & McDonald B32,304/48: Since synovial membranes contain numerous MCs and these appear to discharge their granules into the synovia, "it is suggested that mast cells of the synovial membrane, through their secretion of heparin, may play a part in keeping hemarthrosis fluid." In agreement with this view, fluid blood taken from a case of hemarthrosis formed a coagulum upon the addition of protamine which is known to annul the action of heparin.

Kelsall & Crabb D28,690/53: MCs are more numerous in the sublingual glands (mucous) than in the submaxillary or parotid glands (chiefly serous) of the hamster. "The number, position and extrusion of granules of mast cells in the sublingual gland suggest that these cells may provide mucopolysaccharides for mucous alveolar cells."

Gomori D33,670/54: "Mucin in the tinctorial sense of the word, is covered chemically by the term acid mucopolysaccharide. Certain substances, sometimes called mucoid, morphologically indistinguishable from stainable mucin, are not demonstrated by the regular techniques. In all likelihood, they are neutral mucopolysaccharides, since they can be made stainable by esterification with sulfuric acid or by the oxidative creation of carboxylic groups in them." These are physicochemical differences between various types of mucin but as judged by their staining reactions, the MC-granules contain compounds of this type.

Kelsall & Crabb D26,076/59, *pp. 94, 207, 209:* MCs may furnish mucinous substances to lubricate serous and synovial cavities.

CATECHOLAMINES (ADRENALINE, NORADRENALINE)

Certain chromaffin cells have been demonstrated in human skin; their close relationship to unmyelinated nerve fibers and smooth-muscle cells suggested that they might release some neurohumoral substances. Since some of these cells also contain metachromatic granules, a relationship to MCs has been suspected. Ordinary MCs, which exhibit no chromaffin reaction, have been found in sympathetic as well as in cerebrospinal nerves but there is no reason to believe that they secrete catecholamines.

Burch & Phillips C64,614/58: Certain chromaffin-reacting cells can be demonstrated in the human digital skin. Initially, differentiation of these special stains from MCs was difficult because they appeared to stain similarly. However, with special methods, it can be shown that the chromaffin granules are not in MCs.

Rhodin et al. D39,527/59: Electron-microscopic observations on the so-called chromaffin cells of human skin suggest that they contain granules "that chemically and structurally are closer related to the chromaffin granules of the adrenal medullary head cells than to the granules of the mast cells." The close relationship of these cells to unmyelinated nerve fibers

and smooth-muscle cells suggest that they may "release some substance into the smooth muscle cell by impulses through the nerve fiber."

Phillips et al. C91,246/60: Electron-microscopic studies suggest that there are at least two types of MCs in the human skin and gastric mucosa: one shows "peculiar, rolled, laminated scroll forms," while the other is an elongated cell with granules showing an amorphous architecture. The latter cells appear to be identical with the chromaffin cells as seen on light microscopy and are thought to contain adrenaline and noradrenaline.

Phillips et al. D26,570/60: In the human skin, there are cells which in many respects resemble MCs but contain chromaffin granules, while the ordinary MCs are devoid of them.

Gamble & Goldby D2,298/61: In the sural and caudal nerves of the rat, MCs are frequently found within the endoneurium, perineurium, and epineurium. In smaller numbers, MCs are also present in the guinea-pig sural nerve and in the splanchnic nerves of the rat and man, often in contact with small blood vessels. These cells do not exhibit a chromaffin reaction after treatment with Orth's fluid. From one to eight days after transection of the nerves, the MCs become more numerous and many of them shed their granules. Intense MC proliferation was seen, however, only several months after nervous injury, "thus, while mast cell hyperplasia is marked in conditions of fibroplasia, the latter usually appears first."

Coupland & Heath D2,439/61: Contrary to earlier claims (*Adams-Ray & Nordenstam* D26,474/56; *Burch & Phillips* C64,614/58), chromaffin cells have not been observed in human skin. "It would be theoretically possible for the bases, adrenaline and noradrenaline to be ionically bound to the highly acid molecule of heparin polysulphuric acid . . . . All these reactions are, however, negative in man and at present there is no histochemical evidence for the localization of catechol amines in human skin."

PIGMENTS

The accumulation of melanin in the lesions of urticaria pigmentosa has long suggested some relationship between MCs and pigment deposition. In nevi, freckles, and melanosarcomas, there are "pigment mast cells" which contain both metachromatic and pigment granules. An unusually large number of MCs has also been noted in acanthosis nigricans and xeroderma pigmentosum; indeed, allegedly there even exist direct transitional forms between MCs and pigment cells in both these diseases. A certain parallelism between local mastocytosis and hyperpigmentation also exists in various other spontaneous and experimentally-produced pigmented dermatoses. All these findings suggest some relationship between MCs and melanin production.

In view of recent work on the binding of blood-borne particles by MC granules through mastopexis and the demonstration of dopa decarboxylase in MCs, the possible participation of these cells in pigmentation deserves further study.

Bäumer D27,593/1896: Review of early literature on the relationship between the MCs and pigmentation including the alleged observation of pigment granules within MCs.

Rheindorf D33,731/05: In nevi, freckles, and melanosarcomas, MCs are very numerous and certain cells designated as "pigment mast cells" contain both metachromatic and pigment granules. It is assumed that MCs can be transformed into chromatophores. [In the discussion of this thesis Pappenheim rejects this interpretation although he admits that metachromatic and pigment granules may coexist in the same cell (*H.S.*).]

Staffel D27,427/06: In patients with nevi acanthosis nigricans, xeroderma pigmentosum, transformation of MC granules into melanin has been observed and, hence, "mastocytes are pigment-forming cells."

Bohač D27,597/06: MCs are unusually numerous in the skin lesions of patients with urticaria pigmentosa and xeroderma pigmentosum. Allegedly, there are direct transitions between MCs and pigment cells in both these conditions which explains the genesis of melanosis in these dermatoses.

Sabrazès & Lafon D27,301/08: A yellow pigment which gives a mild Prussian blue reaction is noted in a mastocytoma of the lip in a horse.

Staffel D33,661/08: The MCs in human skin may contain pigment granules and presumably participate in pigment formation.

Meirowsky D27,981/08: On the basis of histologic observations, it is assumed that MCs can be transformed into pigment cells.

Jacobi D27,436/14: Following a review of the older literature on the relationship between MCs and pigment cells, pigmentation associated with vitiligo, pigmented nevi, and exposure to ultraviolet light was examined in man. Mast cells were common in the vicinity of the pigmented regions but pigment granules in MCs, or metachromatic granules in pigment cells, have not been found.

Lipschütz D28,696/23–24: Chronic tar painting of the skin often leads to local mastocytosis combined with melanosis or even to mastocytoma and melanoma formation in the mouse.

Lehner D27,094/24, *p. 149:* Discussion.

Borrel D26,868/28: If whole mounts of the skin that covers the mammary gland in black mice are stained with metachromatic dyes, it is easy to see "the evident transformation of sub-epidermal mastocytes with violet granulations into the pigment cells of Langerhans." The same phenomenon can be demonstrated in the pigment cells of *Helobdella stagnalis* and in those of embryonic black chicks.

Cottenot D27,990/54; *Woringer* D26,819/55: The MCs may play an important role in cutaneous pigmentation since their number is increased in many dermatoses associated with hyperpigmentation. It is thought that the action of tyrosinase is normally inhibited by SH-groups and that the MCs may use up the available SH for the synthesis of sulfated mucopolysaccharides, thereby removing a natural inhibitor of melanogenesis from tyrosinase. In discussing these findings, Jausion pointed out that there is considerable chemical evidence of a possible transition from porphyrins to melanins and that, hence, the coexistence of hemosiderosis and melanosis in the vicinity of varicose ulcers might not be coincidental and that both types of pigmentation might be influenced by the local accumulation of MCs.

Paschoud D26,812/54: Repeated s.c. injection of heparin or glucosamine (unlike glucuronic acid and NaCl solutions) causes dark pigmentation with melanophore formation and the appearance of MC-like cells with metachromatic granules, both in grey rabbits and in man. In the rabbit, heparin and glucosamine also produces a local blackening of the hair. It is presumably the glucosamine and not the glucuronic-acid compound of heparin that is responsible for these changes and glucosamine plays a role both in the formation of MCs and in melanin formation.

Nay D65,634/56: "In the skin of naked, crinkled, and occasionally, normal mice, the mast cell granules, or whole mast cells, located in subdermal connective tissue, become pigmented, the colour being the same as the colour of the hair of the animal in question. In the skin of crinkled mice, which have little hair growth, a great number of pigmented mast cell granules in naked and crinkled mice are engulfed by the growing hair follicle, and accumulated in the dermal papilla. After the formation of pigment in the hair, the dermal papilla appears depleted of pigmented granules. It is suggested that mast cells in the mouse are concerned in pigment formation."

Dunn & Potter D27,625/57: A mastocytoma was found in a male mouse of DBAf/2 strain which was repeatedly painted with methylcholanthrene at various sites. The tumor arose apparently from two subcutaneous points and proved to be transplantable in the same strain, both in solid and in ascites forms. There were "hematoidin crystals and unusual birefringent yellow globules in necrotic areas of the tumor. This may indicate that the mast cell has a function related to the formation of bile pigments from hemoglobin."

Quevedo et al. D27,069/58: Distilled water s.c. causes local depletion of MCs in the mouse, and even 14 days later the injected skin area is devoid of these cells. Yet, growth and pigmentation of hair occurred in normal fashion in the complete absence of local MCs. "Contrary to previous reports, it is concluded that mast cells neither elaborate melanin pigment nor contribute to the melanogenic activity of melanocytes within hair follicles." In a variety of genotypes of mice, with different hair growth and pigmentation, no striking MC anomaly and particularly no intermediate types between MCs and melanocytes could be observed.

Hagen C66,315/59: Mouse mastocytomas contain histidine, 5–HTP decarboxylases, and a highly active dopa-decarboxylase. Yet, they contain no dopamine, although they are rich in histamine and 5–HT. Whereas dopamine is readily oxidized by dopamine oxidase, 5–HT is not. Nor is histamine appreciably metabolized by any of the mastocytoma enzymes. "Thus, the absence of dopamine and the presence of large amounts of 5–HT and histamine

can be explained by the ability of mastocytoma amine-oxidases to rapidly destroy the dopamine without metabolizing the 5–HT or histamine."

Lennert & Illert D26,831/59: In lipomelanotic reticulocytosis, there is a considerable increase in the MC population of the lymph nodes. This fact, and the common occurrence of simultaneous mastocytosis and pigmentation in various conditions including urticaria pigmentosa, suggests some relationship between melanin formation and the MCs, however "present knowledge does not permit us to assume a definite connection between hyperpigmentation and mastocytosis."

Coupland & Heath D26,426/60; D2,439/61: Nuclear-fast red is said to stain dopamine granules selectively and human cutaneous MCs give a positive reaction with this dye. Melanin is capable of chelating iron and, therefore, of giving a positive Turnbull's blue reaction in MCs.

VARIOUS OTHER COMPOUNDS

[Cf. also (*p.* 45.)]

Among other compounds alleged to be present in MCs are: cerebrosides, lecithin, phosphatidyl choline, nucleotides, ATP, neuraminic acid, imidazole acetic acid, cysteic acid, taurine, chondroitin sulfate, DOPA, hyaluronic acid, hexosamine, lipids, calcium, zinc, and iron.

CONNECTIVE TISSUE AND NUTRITION

Various investigators assumed on theoretic grounds that the function of MCs is to promote the nutrition of connective tissue.

When heparin acts on collagen solutions, threads are formed which exhibit the characteristic periodic cross-striation of collagen fibrils. Furthermore, addition of MCs to cultures of fibroblasts appears to favor the formation of silver-staining (reticular?) fibers near the growing fibroblasts. Such observations suggested that MCs may participate in the *formation of collagenous and argyrophilic fibers.*

In patients with basophilic leukemia, the affected tissues (e.g., bone marrow, liver, spleen, lymph nodes) frequently show a sclerosis attributed to mucopolysaccharide production by the MCs. However, depletion of the MCs by 48/80 does not significantly inhibit the formation of collagen under the influence of subcutaneously-injected irritating substances or the tensile strength of experimentally-produced wounds.

Recent work on *calciphylaxis and calcergy* (*p.* 393) clearly indicates that under certain conditions MCs can stimulate connective-tissue proliferation and sclerosis through the attraction from the blood of various metals particularly calcium. Yet, the importance of this process in human physiology and pathology remains to be demonstrated.

The MCs have been implicated also in the formation of *ground substance and hyaluronic acid.* The density of MCs in joint capsules and the occasional demonstration of metachromatic granules within the synovial fluid led to the hypothesis that these cells may elaborate mucin and ground substance. Diffuse metachromasia of the ground substance is often seen in dermatoses, in which MCs are numerous. However, the production of hyaluronic acid by MCs has never been definitely proved.

It has been assumed that the MCs can stimulate *wound healing,* presumably through the formation of heparin. However, the induction of connective-tissue formation by heparin has not been convincingly demonstrated. It is true that MCs sometimes proliferate in healing wounds, but this is not always the case and there is no proof that these cells play a causal role in scar formation. After transection

of nerves, the MCs become more numerous but since this is preceded by fibroplasia, it cannot be regarded as its cause.

Trephocytosis has been defined as a transfer of foodstuffs from one cell to another. Through the production of heparin and histamine, the MCs may provide nutrient materials to adjacent fibroblasts.

The frequent concentration of MCs around *inflammatory* foci led to the concept that these cells may have a defensive function against inflammatory irritants including microbes, allergens, thermal injuries, and even tumors. The fact that such agents cause MC degranulation, especially during the acute stage of inflammation, suggests that the released histamine may play an important part in the associated vasodilatation and edema. Yet, degranulation of the MCs by 48/80 does not significantly and constantly influence the inflammatory reaction elicited by various irritants.

Thus, we may conclude that despite considerable work on the role of MCs in fibrillogenesis, the formation of ground substance and hyaluronic acid, wound healing, "trephocytosis," and inflammation has not yet been clearly elucidated. It is highly probable that a discharge of histamine and, in some species, 5–HT from irritated MCs, assists in the formation of an acute inflammatory edema; we shall have more to say about this in discussing anaphylactic and anaphylactoid inflammation. The discharge of heparin may play a role in preventing local thrombosis at sites of injury, although it is not yet clear whether heparin also influences connective-tissue formation. In any event, inflammation and connective-tissue proliferation can proceed in an essentially normal manner after the depletion of the MC population by histamine-dischargers, hence these processes are not wholly dependent upon the presence of a normal MC population.

Westphal A8,394/1880; *Rosenheim* D26,865/1886; *Ballowitz* D27,586/1891; *Ranvier* D31,524/1891; *Bäumer* D27,593/1896; *Stassano & Haas* D33,741/1900; *Greggio* D31,536/11: Various investigators assumed, on theoretic grounds, that the function of MCs is to promote the nutrition of connective tissue.

Fibrillogenesis

Bensley D42,231/49: A hyaluronidase-containing testicular extract causes local degranulation of MCs in the skin of the rat and mouse. By the fourth day, there was evidence of new fiber formation around active fibroblasts and the MCs began to reappear. The possible participation of MCs in collagen formation is considered.

Morrione D27,615/52: When heparin acts on solutions of collagen, fibrils are formed, which at least in certain segments "showed a distinct periodicity of approximately 640 Å." These heparin-precipitated fibers give typical staining reactions of collagen with Masson's trichrome and van Gieson's stains. Some of the fibers were argyrophilic, but most of them did not stain with Laidlaw's reticulum stain. "It is postulated that mast cells, by virtue of the heparin which they produce, may play a role in the formation of collagen." Heparin concentrations of 1:80,000 suffice for collagen-fiber formation in vitro.

MacDougall D29,156/54: Using MCs from dog mastocytomas, it was found that: "the addition of mast cells to a culture of fibroblasts appeared to favour the formation of silver staining fibres near the growing fibroblasts. Such fibre formation was not seen in control cultures of fibroblasts alone. However, similar fibre formation could be induced by the addition of critical concentrations of a simple extract of a mast-cell tumor to the basic medium in which the fibroblasts were growing. This supports the idea that in vivo, mast cells and fibroblasts may likewise interact in the production of fibres."

Reilly et al. D10,435/55: Acid solutions of collagen can be made to precipitate out collagen fibers by the addition of heparin. The resulting fibers not only stain like collagen but also show the characteristic electron-microscopic periodicity. It is assumed that the fibrosis

(e.g., in the liver), that is characteristic of urticaria pigmentosa, is due to this collagen-forming effect of the heparin produced by the MCs.

Sundberg et al. D26,731/55: Not only the MCs but even fibroblasts of Wharton's jelly contain metachromatic granules. It is doubtful whether such cells could be regarded as MCs.

Lennert et al. D26,471/56: In a patient with basophilic leukemia and tissue mastocytosis, there was pronounced sclerosis of the liver, spleen, lymph nodes, and bone marrow. This effect is attributed to mucopolysaccharide production by the MCs.

Rondez & Rüttner D27,391/59: If the eventrated mesentery of the mouse is brought in contact with quartz-, corundum-, or coal-dust, an immediate MC degranulation is observed. "There is no reason to connect mast-cell degranulation with fibrogenetic processes, which are observed at a much later stage."

Fisher C85,479/60: Depletion of the MCs by pretreatment with 48/80 does not significantly inhibit the formation of collagen under the influence of subcutaneously-injected carrageenin; furthermore, both connective tissue and amorphous ground substance appear in the embryo before MCs are detectable.

Smyth & Gum D4,499/61: On theoretic grounds, it is assumed that the MCs participate in the formation of connective tissue, particularly inflammatory granulomas and scar tissue.

Fisher & Hellstrom D6,683/61: MC depletion by 48/80 "failed to influence tensile strength, rate of wound contraction or qualitative aspects of wound healing in these animals. These findings appear to minimize the role of the tissue mast cell in fibrillogenesis in this species."

Fernex G9,088/63: A review of the literature and personal observations suggest that, under various experimental and clinical conditions, proliferation of MCs is associated with increased fibroplasia, including scleroderma and endomyocardial fibrosis.

Orfanos & Stüttgen E37,429/63: Electron-microscopic studies on human mastocytoma tissue, topically treated with 48/80, indicate that the degranulation of the MCs is associated with a "cytotactic" attraction and subsequent degranulation of eosinophils, as well as stimulation of the adjacent connective tissues in which new collagen protofibrils are formed intracellularly. Subsequently, these fibril precursors come to lie extracellularly and several of them unite to form permanent collagen fibrils.

Ground substance and hyaluronic acid formation

Reviews:
- *Asboe-Hansen* B50,548/60; B60,-602/50; B60,604/51
- *Studer* C6,137/54
- *Wegelius & Asboe-Hansen* C29,-551/56
- *Fulton et al.* C35,831/57
- *West* C64,139/58
- *Kelsall & Crabb* D26,076/59, *pp. 61, 205*

Bensley D28,924/34: By treatment with dilute acids or alkalis, the ground substance of connective tissue may be made to stain metachromatically with toluidine blue. [It remains to be seen whether this normally "masked" metachromasia is in any way related to MC granules (*H.S.*).]

Bachman et al. 31,404/35: Chronic heavy overdosage with estriol produces intense gelatinous edema and hyperemia in the sex skin of the rhesus monkey. [The possible participation of MCs in this response has not been investigated (*H.S.*).]

Caselli D26,830/45: While the cutaneous MCs of the rabbit are destroyed by hyaluronic acid, those of man are not. Hence, the assumption that the MC granules contain hyaluronic acid and are important for the formation of ground substance, while possibly valid for the rabbit, cannot be extended to man.

Asboe-Hansen B60,550/50; D26,785/50: The fact that MCs and metachromatic ground substances (hyaluronic acid) are most plentiful in those dermatoses in which MCs are numerous, is cited as evidence supporting the concept that the MC produces hyaluronic acid for the synthesis of ground-substance constituents.

Asboe-Hansen D26,784/50: "Influenced by hormones, the mast cells secrete the mesenchymal mucopolysaccharide, hyaluronic acid, perhaps by way of a precursor resembling heparin."

Campani D27,609/51: On the basis of purely theoretic considerations, it is assumed that MCs are less likely to produce hyaluronic acid than they are to transform it and other components of the ground substance into "substances not yet well defined," e.g., heparin.

Asboe-Hansen B74,068/52: MCs are considered to produce hyaluronic acid, hence, their suppression by cortisone may be important in the anti-inflammatory effect of this hormone.

Compton B90,594/52: "Hamster mast cell granules do not include hyaluronic acid; they remain metachromatic after hydrolysis of the sections with hyaluronidase."

Schallock D39,666/54: Morphologic observations lead to the concept that MCs may participate in the formation of ground substance.

Baglioni C16,539/54, *p. 160*: Discussion on the relationship between MCs and hyaluronidase activity.

Holczinger & Dévényi D39,763/55: During the healing of cutaneous wounds in rats, the local MC population shows no obvious variations, and the different localization of ground substance and MCs led to the conclusion that the latter are not responsible for the production of ground substance. Very small doses of heparin neutralize the ground-substance-depolymerizing action of hyaluronidase, which "suggests that the mast cells, in their capacity of heparin producers, act as hyaluronidase inhibitors in the evolution of granulation tissue."

McGovern D26,767/56: The endothelium of the peritoneum, pleura, and blood vessels have a very similar structure. There is a surface layer of argyrophilic protein material and argyrophylic cement lines separating the individual endothelial cells. Underneath the epithelium and closely attached to it are the MCs. When the peritoneum of the rat is mildly irritated by topical application of 1 per cent acetic acid or 48/80, there is an increased production of the surface protein film and imbibition with metachromatic substance of both the cement lines and the surface film, this being associated with degranulation of the subendothelial MCs. The so-called stigmata or stomata, which were thought to appear on the borderline between endothelial cells, are actually bubbles of metachromatic material which have an argyrophilic outline. "It is postulated that capillary permeability is partly due to a spreading factor, produced by mast cells, which acts on the surface protein layer of the endothelium."

Taylor & Saunders D27,882/56: As judged by histologic observations on connective-tissue formation around gelfoam pledgets, subcutaneously implanted into rats, it was concluded that there is no reason to think that MCs are concerned in the formation of ground substance.

Szirmai C43,968/57: The large amount of gelatinous ground substance that is found in the rooster's comb and the sex skin of the monkey may be related to the activity of local MCs.

Schoenberg & Moore D27,894/58: In man, metachromatic ground substance appears in Wharton's jelly, before any MCs are demonstrable. Furthermore, the potentially-metachromatic material (made metachromatic by sulfation) in the intercellular spaces, differs from the potentially-metachromatic substrate of immature MCs in that it is sensitive to β-glucuronidase. "It seems more reasonable that the fibroblasts are the synthesizing cells of the connective-tissue polysaccharides."

Hill C64,094/58: On histologic evidence it is assumed that vacuolization of MCs is related to histamine discharge, complete lysis of the granules to the secretion of heparin, and excretion of granules after intracellular loss of their tingibility to the production of ground substances, particularly mucopolysaccharides of the hyaluronic acid type.

Danilova D39,771/58: On the basis of histologic studies on the MCs of patients who died from various diseases, the author concludes that these cells play an important part in the regulation of ground-substance formation.

Kraft & Kirsner D33,708/60: Since MCs produce heparin, histamine, hyaluronic acid, and 5–HT, it is postulated that "mastocytes play an important role in the production and maintenance of connective-tissue ground substance throughout the alimentary canal, as elsewhere in the body."

Bloom & Ringertz D39,808/61: The polysaccharide fraction of rat and mouse peritoneal MCs is said to contain 80–100 per cent heparin and no hyaluronic acid.

Asboe-Hansen E99,822/62: A case of bullous diffuse nonpigmented cutaneous mastocytosis in a one-year-old girl led to the urinary excretion of considerable amounts of nonsulfated mucopolysaccharide of the hyaluronic-acid type. The patient was successfully treated with cyproheptadine.

Jorpes E4,171/63: Although it has been claimed that MCs synthesize hyaluronic acid, "this claim can now be refuted. There is no hyaluronic acid in the mast cells, only heparin and a small amount of a monosulfated polysaccharide, which is not chondroitin sulfuric acid."

Bassett D69,353/63: Observations on various animal species indicate "that mast cells are not necessary for the production of increased amounts of ground substance under conditions of connective-tissue modification in oestrus and pregnancy. Fibroblasts alone must be capable of making all the constituents of connective tissue as in many of these pelvic and genital connective tissues both in the inactive state and when modified by pregnancy and oestrus, they are the only cells present in significant numbers."

Asboe-Hansen & Clausen F16,673/64: Paper electrophoresis of urinary concentrates from patients with urticaria pigmentosa revealed the presence of chondroitin sulfate and a chemically-changed (depolymerized?) hyaluronic acid.

Asboe-Hansen & Clausen E37,788/64: In a patient with urticaria pigmentosa, paper electrophoresis revealed two bands with mobilities like those of hyaluronic acid and chondroitin sulfuric acid. Polymyxin-B treatment changed the electrophoretic pattern.

Likar et al. G19,263/64: In the bovine endometrium, biochemical and histochemical estimations of hyaluronic acid and total acid mucopolysaccharides showed variations which roughly paralleled the MC- counts throughout the cycle. "The results of this investigation support the concept that mast cells participate in the production of hyaluronic acid."

Wound healing

McCleery et al. D39,636/49: In the dog, wound healing following the application of cutaneous burns, is greatly accelerated by the local application of heparin. [No special mention is made of MCs (*H.S.*).]

Perez-Tamayo & Ihnen D28,955/53: Wound healing is delayed in rats kept on a protein-deficient diet but can be improved by methionine supplements. Metachromatic material appears during the initial stages of wound-healing but — contrary to Sylvén (D26,048/41) — no decrease in MCs was found at the time when metachromasia became apparent. Hence it is thought unlikely that the MCs are implicated in wound healing.

Holczinger & Dévényi D39,763/55: During the healing of cutaneous wounds in rats, the local MC population shows no obvious variations, and the different localization of ground substance and MCs led to the conclusion that the latter are not responsible for the production of ground substance.

Boyd & Smith D65,097/59: Morphologic studies on the healing of linear skin wounds in rats suggest some relationship between MC degranulation and wound healing, but the evidence is very indirect.

Fiore-Donati & Moltke C88,372/60: In rats with linear cutaneous wounds, reserpine, and, to a lesser degree, 5–HT, cause a significant decrease in the tensile strength of the wounds without any marked change in the MC morphology. Conversely, polymyxin, which produces intense MC degranulation, induced no significant decrease in tensile strength. "It is concluded that the decrease in tensile strength of healing wounds induced by 5–HT and reserpine is probably not mediated by the tissue mast cell."

Drabe D26,852/61: In the human tonsil, MCs are particularly plentiful during chronic inflammation and even when inflammatory processes are no longer demonstrable, but lymphatic tissue is replaced by scar tissue. It is concluded that "the tissue mastocytes probably promote the formation of new connective tissue through the production of acid mucopolysaccharides."

Gamble & Goldby D2,298/61: In the sural and caudal nerves of the rat, MCs are frequently found within the endoneurium, perineurium, and epineurium. From one to eight days after transection of the nerves, the MCs become more numerous and many of them shed their granules. Intense MC proliferation was seen, however, only several months after nervous injury, "thus, while mast cell hyperplasia is marked in conditions of fibroplasia, the latter usually appears first."

Smith D39,764/61: MCs are apparently not required for the production of mucopolysaccharides during the avascular healing of corneal wounds in the rat.

West D33,712/62: Apparently, both histamine and 5–HT act primarily on connective tissue, stimulating the phagocytosis and digestion of metachromatic material released by nearby MCs. The fibroblasts are thereby stimulated to produce mucopolysaccharides and thus assist in the formation of extracellular ground substance. In the rat, "intense activity in the mesenchyme may be produced locally by injecting a mixture of histamine and heparin but not by histamine alone. Wound healing as measured by tensile strength is stimulated by locally administered heparin which, among other things, may neutralise the action of local adrenal corticoids."

Reynolds et al. D64,852/63: During wound healing, following the excision of skin flaps, the number and granularity of the MCs is increased at first and declines after the tenth day towards normal. "The mast cell is suggested as a mediator to peripheral tissue of the presence and activity of the wound."

Smith D63,031/63: Discussion.

Trephocytosis

Riley D58,277/63: Trephocytosis is the transfer of foodstuffs from one cell to another. This process is common in invertebrates and "the mast cells among the vertebrate leukocytes, reveal the closest possible resemblance to the invertebrate type" (*Liebman* D61,516/47). This theory has recently been revived and extended by several investigators (*Kelsall & Crabb* D26,076/59; *Dougherty & Schneebeli* D61,515/58; *Burton* D26,702/60; *Riley* D58,277/63). Both histamine and heparin may participate in this process of trephocytosis and "we thus can visualize rupture of the mast cell as being followed by two successive waves of discharge: first, a rapid and widely-spreading zone of histamine; second, a more sluggish discharge of heparin or heparin-containing granules. The first, histamine, activates nearby connective-tissue cells to receive and digest the heparin that follows. The histamine, of course, also acts as a vaso-dilator of the small blood vessels, so that plasma colloids leak into the injured zone."

Inflammation

Metchnikoff B64,274/1892: MCs are thought to play an important role in inflammation in that they help the removal of toxin.

Calleja D39,609/1896; *Fahr* D29,298/05; *Fromme* D26,217/06; *Cajal* D27,596/06; *Sabrazès & Lafon* D27,301/08: The frequent concentration of MCs around inflammatory foci led to the concept that these cells have a defensive function against phlogistic irritants, including tumors.

Maximow B79,776/04: Unlike the clasmatocytes (histiocytes), the MCs "undergo exclusively regressive changes in inflammation." They discharge their granules and eventually become exhausted but never participate actively in phagocytosis or defense, as judged by observations in rats in which inflammation is produced by the subcutaneous implantation of celloidin capsules.

Tanon D27,445/09: MCs are unusually abundant in the immediate vicinity of vaccination pustules and, allegedly, the potency of the vaccine is roughly parallel to the number of MCs. Hence, the latter are assumed to "produce a specific secretion related to defense."

Michels C72,066/38, *pp. 291, 319:* Discussion.

Scevola D27,705/38; D27,701/38: The great accumulation of MCs frequently seen in inflamed tonsils is taken to indicate a defensive function of these cells. This view received further support from observations in rats in which thermal (thermocautery) and chemical ($NaOH$, $AgNO_3$) burns were produced in the palato-pharyngeal region because, here again, the local MC count was increased.

Riley & West C14,427/55: In rats in which an intense MC degranulation was obtained in the mesentery owing to the intraperitoneal administration of 48/80, the regional fibroblasts swell and show increased cytoplasmic basophilia. At the same time, the tissue is impregnated with protein-rich edema fluid which may be due to the release of histamine. "If so, it might indicate a physiological role for histamine in the inflammatory reaction."

McGovern D27,739/57: When local inflammation is produced in the hind paw of the rat by ethyl-chloride spray or the injection of ethanolamine, the local MCs discharge their granules. When the MCs are previously depleted by 48/80, the inflammatory edema is lessened but leukocytic migration into the tissue is hastened. Local injection of heparin does not influence the edema but retards the migration of leukocytes. It is concluded that the MCs may play a role in regulating inflammation.

Asboe-Hansen & Wegelius C73,310/57: While MCs undoubtedly can produce histamine they may avert at least one of its effects, namely, the edema because, "in their bodies the mast cells contain oedema substances, but also substances which can organize oedema." [However, these conclusions are based on rather indirect evidence (*H.S.*).]

Takeda C60,734/58: In view of the intense MC discharge that occurs during inflammation of the skin following topical application of NaOH, it is assumed that these elements play an important role in the mechanism of inflammation.

Kelsall & Crabb D26,076/59, *p. 179:* Discussion.

Fisher & Paar C94,668/60: The production of an inflammatory granuloma by the subcutaneous injection of carrageenin in the rat was not influenced by the previous depletion of the animal's MCs by 48/80.

Sheldon & Bauer C96,633/60: Discharge of MCs by 48/80 and inhibition of discharge by alloxan-induced diabetes interferes with the local development of inflammation and host resistance to subcutaneously-inoculated Rhizopus oryzae in the rat. "It is concluded that a function of the tissue mast cells in the normal rat is the rapid initiation of acute inflammation at the site of injury and that degranulation of these cells prior to infection somewhat delays the inflammatory response and, therefore, slightly diminishes host resistance. Furthermore, a severe metabolic disorder such as acute alloxan diabetes with acidosis, inhibits the normal function of the tissue mast cells, delays and decreases inflammation, and in this manner contributes to the greatly increased susceptibility of the host to infection."

Macaluso & Pasqualino D5,225/60: Discussion.

Ferluga et al. D68,157/63: In rats bearing a granuloma pouch induced with croton oil, pretreatment with epsilon-amino-caproic acid reduced the inflammation parallel to an inhibition of MC disruption. It is concluded that the MCs may play a role in inflammation and that epsilon-amino-caproic acid protects them from disruption.

Csaba et al. E26,735/63: The antiphlogistic effect of cortisone is associated with an initial increase followed by a decrease in the thymic MCs of the rat. These findings are thought to confirm the view that the MCs play a part in inflammation. [However, the evidence for this assumption is quite indirect (*H.S.*).]

Schayer D58,278/63: Glucocorticoids suppress the rate of synthesis of new histamine, perhaps by an inhibition of the transport of L-histidine into MCs in which decarboxylation of the product occurs. At least part of the anti-inflammatory corticoid action may be due to the effect of these compounds upon MCs and histamine formation.

Fernex G10,072/64: There is an increase in cardiac MC density in patients with carcinoid or endomyocardial fibrosis due to helminthiasis. It is assumed that the MCs render the cardiac connective tissue particularly subject to inflammation and connective-tissue proliferation in both these diseases.

Schauer F10,764/64: Review of the participation of MCs in acute inflammation through the liberation of vasoactive and edematogenic substances.

Parish E4,391/64: The pharmacologic substances released by MCs "are mediators of changes occurring in inflammation, thus the mast cell provides a reserve of material readily available in any sudden physiological stress or damage to the tissues."

TUMORS

As we have stated elsewhere, MCs are frequently plentiful in the stroma of spontaneous tumors and chronic treatment with various carcinogens can produce local mastocytosis, especially in the preneoplastic stage. These observations have raised the suspicion that MCs may play a part in defense against neoplasia, but conclusive evidence of this is still lacking.

Reviews:
- *Michels* C72,066/38, *p. 320*
- *Studer* C6,137/54
- *Boréus* E27,559/61
- *Mongar & Schild* D22,507/62
- *Giertz* E20,161/63
- *Klein* E26,609/63
- *Claudatus et al.* E56,463/64

IMMUNITY, ANAPHYLAXIS

It is now almost generally agreed that the MCs play an important role in anaphylaxis. The main arguments in favor of this view are that:

1. During anaphylactic shock both heparin and histamine are released into the blood simultaneously with the degranulation of MCs.
2. The prolongation of blood-clotting time characteristic of anaphylactic shock (especially in the dog) is duplicated by heparin.
3. Many of the other manifestations of anaphylaxis are reproduced by histamine.

Curiously, chemical histamine liberators can release histamine from isolated MC granules, while anaphylaxis requires an intact living cell on which antigen and antibody can interact. It is thought that this interaction causes a transient activation of an intracellular heat-labile, calcium-requiring enzyme system which is responsible for the release of histamine and perhaps also of other substances that may determine the general symptomatology of anaphylaxis in various species. A special type of lytic antibody may also be involved in the discharge of histamine from MCs during anaphylaxis.

Among the substances suspected to play a role in anaphylaxis — in addition to heparin and histamine — are 5–HT and the slow-reacting substance SRS–A; all of these compounds are probably derived from MCs. Thus, among the principles believed to be implicated in the development of anaphylaxis, only bradykinin (a nonapeptide generated in plasma) has not been found to be linked with MCs.

It had been shown long ago by Bordet and others that, when serum is incubated with antigen-antibody complexes (or with such high-molecular substances as agar, starch, and insulin) it acquires the property of producing an anaphylaxis-like syndrome in the guinea-pig, allegedly owing to the formation of an "anaphylatoxin". In some models of anaphylaxis, serum complement facilitates the enzymatic release of histamine from MCs: this is of interest because complement was once thought to play a part in the formation of anaphylatoxin.

All these facts suggest that the MCs play an important part in certain forms of anaphylaxis; however, their role need not necessarily be an indispensable one: in some species (e.g., the mouse) fatal anaphylactic shock may develop without any detectable MC involvement.

ANAPHYLACTOID INFLAMMATION

In the rat, and to a lesser extent in several other species, parenteral administration of certain MC dischargers (e.g., ovalbumen, ovomucoid, dextran, dextrin) produces an anaphylactoid inflammation. This is characterized by acute edema and hyperemia of the acral regions, particularly the snout, ears, and the perianal skin. A good deal of evidence has accumulated in support of the view that the *mast cells play a causal role* in the production of this response:

1. There exists a good correlation between the localization of the MC discharge and of anaphylactoid inflammation in various tissues of several species following treatment with diverse MC dischargers.
2. There exists a good correlation between the histamine and 5–HT discharge from various tissues and the localization of anaphylactoid inflammation.
3. Intense pretreatment with MC-dischargers, 5–HT- and histamine-antagonists prevents the production of anaphylactoid inflammation.

On the other hand, certain data are *not entirely consonant with this interpretation*:

1. Repeated administration of comparatively small doses of 48/80 or polymyxin can continue to cause an anaphylactoid inflammation despite histamine depletion in the anaphylactoid shock organs.
2. With moderate doses of MC-dischargers, damage to the MCs may be slight and follow the appearance of inflammatory edema which suggests

that MC degranulation may be secondary to the inflammatory infiltration of the shock organs.

3. After virtually complete MC disruption by one anaphylactoidogenic agent, another may still produce an anaphylactoid inflammation which is preventable by 5–HT antagonists. From this, it has been concluded that 5–HT is important for the production of this reaction but it does not necessarily come from MCs (although it may still come from degranulated MCs).
4. Systemic treatment with 5–HT produces only a mild anaphylactoid inflammation and histamine is quite ineffective in this respect. It must be kept in mind, however, that, during anaphylactoid inflammation, large amounts of these amines are probably released selectively in the shock organs; perhaps similar concentrations of 5–HT and histamine cannot be achieved by systemic treatment with these compounds. Topical administration of minute doses of either histamine or 5–HT does induce anaphylactoid inflammation in the shock organs.
5. Isolated peritoneal MCs of the rat release their granules and histamine after treatment with 48/80 or polymyxin but not upon exposure to dextran or ovomucoid. This implies that only certain MC-dischargers act directly upon the peritoneal MCs of the rat. However, anaphylactoid inflammation is produced only by certain organotropic MC-dischargers which act selectively upon the acral MCs in the shock organs, not upon those in the peritoneum. When directly introduced into these shock organs, all MC-dischargers produce intense local inflammation.

In conclusion, it may be said that considerable evidence supports the view that only agents which can cause selective MC discharge in the anaphylactoid shock organs (associated with a topical discharge of histamine and 5–HT) produce an anaphylactoid inflammation. It is possible, however, that minute doses of anaphylactoidogenic agents can elicit this response even without visibly affecting the MCs or, at least, before the metachromatic granules are discharged from the shock organs. This may imply that: (1) the granule discharge is secondary to the inflammatory response or (2) the mediators (histamine, 5–HT) may be effective even in small concentrations which can leave the cells prior to the discharge of visible granules.

Selye 38,798/37: First description of an anaphylactoid inflammation. In the rat, egg white i.p. produces hyperemia and edema of the lips, ears, tongue, paws, and clitoris. The phenomenon diminishes in intensity after repeated daily injections. Pretreatment with a stressor (formaldehyde injections) abolishes anaphylactoid reactivity while adrenalectomy aggravates it. Apparently, there exists some relationship between the adrenals and inflammation. [The possible role of the histamine discharge during stress is considered only on the basis of theoretic considerations without offering experimental proof (*H.S.*).]

Feldberg & Talesnik D27,605/53: Reactions similar to, if not identical with, the typical anaphylactoid inflammation induced by ovalbumen, have also been elicited in rats by 48/80 and exposure to light after photosensitization with hematoporphyrin. Following repeated treatment with 48/80, the histamine content of the skin and many other organs is depleted, but that of the stomach and duodenum remains unchanged. In such histamine-depleted rats, 48/80, egg white, or exposure to light after sensitization with hematoporphyrin, produced no anaphylactoid inflammation. This resistance is ascribed to histamine depletion. [No mention is made of the MCs as the possible source of histamine outside of the gastric and duodenal wall (*H.S.*).]

Feldberg D31,609/54: In the guinea-pig, treatment with histamine-liberators produces no visible edema. But if pontamine-blue is injected together with 48/80 intravenously, bluing is most intense around the mouth, the base of the ears, the submental region, the nipples, and the perineum. It was "found that the regional pattern of bluing was, with one exception (the distal parts of the legs), directly related to the histamine content of the skin." Essentially similar findings were made during typical edematous anaphylactoid inflammation in the dog and rat.

Benditt et al. B91,948/54: An anaphylactoid inflammation produced by ovomucoid i.v. is associated with edema in those acral regions in which MCs are most plentiful, and it is associated with MC degranulation. Since ovomucoid, like 48/80, releases histamine, it is thought that "ovomucoid may produce its action by damaging mast cells" and that histamine liberation may play a role as a mediator here.

Benditt et al. C13,402/55: During the anaphylactoid inflammation induced by ovomucoid i.v. in the rat, the MC discharge in the shock organs roughly parallels the edema and the local discharge of histamine. These observations were confirmed in vitro on isolated rat-paw skin exposed to ovomucoid. The findings "lend support to the hypothesis that ovomucoid, in causing mast-cell disruption releases histamine and that histamine presumably causes the vascular hyperemia and increased permeability." After repeated i.v. injection of 3 mg ovomucoid (the minimum amount capable of producing a just-maximal skin edema) the histamine content of the shock organs drops sharply after the first injection with only small further decreases after subsequent injections; yet, the edema is not reduced after the first injection, despite the low concentration of tissue histamine. "This raises the question of whether histamine is the sole or perhaps even the main mediator of this injury response."

Riley & West D39,574/55: In the rat and, to a lesser extent, in the mouse, the MC and histamine depletion of the ears and subcutaneous connective tissue induced by 48/80, are accompanied by more or less typical manifestations of anaphylactoid inflammation.

McGovern D31,617/55: Numerous MCs can be found beneath the endothelium of blood vessels in man. A few hours after death, the MC granules disappear and bubbles of metachromatic material seep through the endothelium, causing the surface protein layer and intercellular cement lines to spread. This change is reproduced by histamine-releasing agents that cause an anaphylactoid inflammation. "Neither histamine nor heparin separately or combined causes any anaphylactoid inflammation in the rat, so that it seems that mast cells must produce a further substance which changes the consistency of the surface protein film of endothelial surfaces and alters their permeability. Mast cells are very scanty around small blood vessels in the brain and choroid plexus of both rats and humans. Nor can they be found in the leptomeninges. This may be a factor in maintaining the blood brain barrier."

MacIntosh C24,237/56: Stilbamidine, pentamidine, and related diamidines, are widely used in Africa for their trypanocidal properties. They can produce interesting side effects in man when given intravenously. One author, for example, observed "a severe but transient fall in blood pressure . . . a curious puffy suffusion of the face and eyelids . . . and itching, generalized and often very pronounced, the grotesque antics of the patient, trying to scratch every part of his body simultaneously, being a source of great amusement to his companions" (*Lourie* D33,694/42). According to MacIntosh "there seems to be no doubt that these side-effects are due to histamine release."

Jasmin C24,745/56: The degranulation of the MCs in the shock organs (e.g., after 48/80 or dextran) is considered to be the cause of anaphylactoid inflammation in the rat.

Asboe-Hansen & Wegelius C25,969/56: In-vivo observations on the cheek pouch of the hamster indicate that 5–HT i.p. produces pronounced degranulation of the MCs concurrent with the development of a typical edema and cyanosis of the snout and paws; that is, an anaphylactoid inflammation.

Parratt & West C37,858/57: Following repeated injections of polymyxin, cutaneous vasodilatation continues to occur even when the skin is virtually depleted of its histamine content.

West & Parratt C45,206/57: Anaphylactoid inflammation, produced by ovalbumen i.p., causes a decrease of both 5–HT and histamine with moderate MC damage in the shock organs. To test if 5–HT is essential for the production of anaphylactoid inflammation, rats received 48/80 to disrupt the cutaneous MCs and deplete the histamine and 5–HT levels: then, they were given egg white. No edema was noted, and assays indicated that no histamine

or 5–HT was released by the egg white. If the rats were pretreated with reserpine, again no edema developed from the injection of egg white, though histamine was still released. "It is clear that 5–HT is needed for the production of edema by egg white. Histamine must certainly play a part, but the more important amine is 5–HT, being about 200 times as active as histamine in producing this local vascular injury. The two amines acting together do in fact produce the vascular response." Dextran-induced anaphylactoid inflammation is also greatly reduced or prevented by pretreatment with 48/80 or reserpine. "There is thus no doubt that 5–HT now takes its place alongside histamine as a possible mediator of the response to inflammation or injury in certain sites of the body of the rat."

Parratt & West C56,384/57; *West* C45,485/57: In rats in which an anaphylactoid inflammation was produced by dextran or egg white (i.p. or locally), MC degranulation was very slight and, hence, it was concluded that "mast cell damage need not occur before the edema reaction can proceed." Furthermore, when rats are made refractory to dextran, there is only slight MC damage and, if the animals are left for a few days without injection, recovery of the anaphylactoid inflammation follows closely the recovery of the tissue amines. Furthermore, when the majority of the MCs are disrupted by polymyxin, the edema reaction is still maximal when other agents are used. The anaphylactoid inflammation is attributed mainly to the release of 5–HT since it can be prevented by 5–HT antagonists, but the source of this 5–HT does not appear to be in the MCs.

Selye & Bois C23,958/57: Following repeated s.c. injections of 5–HT, there develops an anaphylactoid inflammation in the rat which differs from the classical form (induced by ovalbumen or dextran) in that it takes several days to develop, consists more of hyperemia than of edema, affects the paws more than the snout and is frequently associated with gastric ulcers. Though evident in the intact rat, it is even more pronounced in adrenalectomized animals maintained on desoxycorticosterone and almost absent in those maintained on cortisol. One mg of 5–HT per day suffices to elicit an anaphylactoid inflammation but gastric ulcers are more evident with higher doses. Single doses of up to 32 mg (in the paper mg is mistyped as μg) per 100 g body weight are tolerated.

Adamkiewicz & Langlois C51,916/58: Treatment of rats with an antihistaminic (Phenergan) or prolonged pretreatment with 48/80 inhibits the anaphylactoid inflammation normally produced by dextran as well as the sensitizing effect which insulin exerts upon this reaction. However, systemic administration of histamine, serotonin, or heparin does not restore the ability to develop an anaphylactoid inflammation under these conditions. Histamine, 5–HT and heparin are also unable to imitate the sensitizing effect of insulin in normal rats.

Lagunoff & Benditt D26,708/60: Peritoneal MCs of the rat, isolated on a Millipore filter, release their granules and histamine under the influence of 48/80 or polymyxin but not upon treatment with dextran or ovomucoid. It is concluded that "four agents which in vivo appear to have similar activities have been found by means of in vitro analysis to operate by at least two different mechanisms." [It will be kept in mind, however, that dextran and ovomucoid produce the selectively "acral type" of anaphylactoid inflammation in vivo, while 48/80 and polymyxin cause much more generalized cutaneous responses so that these agents differ also in vivo (*H.S.*).]

Zbinden D501/60: A review of the literature and personal observations suggest that, in the anaphylactoid reaction of the rat, 5–HT plays a more important role than histamine.

Eder & Schauer D33,687/61: During the anaphylactoid inflammation, the MCs of the rat discharge their metachromatic granules as well as several histochemically-demonstrable enzymes.

Selye et al. D26,792/62: Various mastocalciphylactic reactions as well as anaphylactoid inflammations that are preventable by pretreatment with histamine-liberators are also blocked by cyproheptadine, an antihistamine and anti-5–HT agent.

Kátó & Gözsy D30,619/62: Neither i.v. nor i.p. injection of dextran in doses conducive to strong anaphylactoid inflammation produces any discharge of MCs even in the shock organs themselves, "thus suggesting that liberation of loose binding histamine and serotonin from the mast cells is not involved in the dextran induced acute inflammatory reaction." [It is difficult to explain this paradoxical finding, especially since under the same conditions the authors did observe MC disruption in rats in which an anaphylactoid inflammation was produced by similar treatment with 48/80 (*H.S.*).]

Benditt et al. D58,279/63: Review of the evidence in support of the hypothesis that 5–HT, liberated from MCs, plays an important role in the anaphylactoid inflammation.

Gözsy & Kátó E37,126/63: "In the rat, intravenous injection of minute amounts (7.9 mg/kg) of dextran induced edema formation of the same intensity as high doses (300–600 mg/kg). With the high doses, mast-cell disruption (histamine and serotonin release), vasodilatation, hypothermia, hypotension, hemoconcentration and edema occurred. Since minute doses of dextran induced only vasodilatation and edema formation, this response is considered as the pure anaphylactoid reaction. The syndrome provoked by high doses is a consequence of conditions created by the physical presence of large quantities of dextran in the blood, rather than an integral part of the proper anaphylactoid sequence. Minute doses of dextran induced edema without mast-cell disruption, hypothermia, hypotension or hemoconcentration, thus showing that the dextran response in the rat is mediated by factors other than histamine and serotonin of mast-cell origin."

DEFENSE

(For Phagocytosis cf. HISTOPHYSIOLOGY, *p.* 82.)

Ever since their discovery, the MCs were thought to play some role in defensive and adaptive phenomena. There was much speculation about the special nutritive, antibacterial, antitoxic, or even antineoplastic function of materials discharged with the metachromatic granules. But evidence in favor of these views was derived mainly from the accumulation or discharge of MCs in the vicinity of morbid foci.

When fibroblasts ingest exogenous metachromatic polysaccharides, they assume the aspect of MCs; this fact led to the suggestion that the same mechanism may induce a neoformation of MCs. Thus, the MCs would be scavengers (somewhat comparable to the reticuloendothelial cells) which, through a process of "micellophagosis," would absorb polysaccharides released endogenously under stressful conditions.

Through the production of edema by the release of histamine or 5–HT, the MCs were thought to protect tissues by diluting potentially-toxic foreign materials, for example, in anaphylactic inflammation. Undoubtedly, the release of vasoactive substances from MCs participates in various types of inflammatory responses. The production by MCs of heparin, histamine, 5–HT, SRS, a great variety of enzymes, and numerous other substances has been discussed in other sections; suffice it to point out here that all these compounds probably fulfill important roles both in topical and in systemic defense reactions.

Reviews: *Asboe-Hansen* D27,999/54
Kelsall & Crabb D26,076/59, *p.* 94

Harris D26,716/00: MCs are thought to secrete mucin and since they frequently discharge their granules in infected tissue they "may elaborate some substance which is bactericidal."

Argaud & Pesqué 90,375/29: On the basis of purely theoretical arguments it is postulated that the development of numerous MCs within the thymus during diphtheria and bronchopneumonia is an expression of an "antitoxic function."

Sylvén & Larsson D26,612/48: Following a single painting of the mouse skin with benzene, phenol, or naphthalene, local MC depletion ensues. This effect is not obtained by phenanthrene, 20-methylcholanthrene, ethanol, or acetone. It is concluded that "the reaction of the mast cell granular substance is induced by such hydrocarbons and derivants as require ethereal sulfate and/or glucuronic acid for their elimination. Consequently, the granular substance of mast cells is supposed to participate in protective reactions."

Balázs & Holmgren D30,635/49: "Sulfomucopolysaccharides (sodium heparinate and the sodium salt of agar acid) suppress the growth of cells from methyl cholanthrene tumors in the rat in vitro." In vivo, these same substances diminish mortality in mice inoculated with Ehrlich's carcinoma. The possibility that sulfomucopolysaccharides of MCs may enhance resistance to tumors is discussed.

Bremy C72,062/50: The primary function of MCs is thought to be defense, since they accumulate in the vicinity of tumors and inflammations and obviously participate in allergic phenomenon.

Benditt B95,916/54: Mainly on the basis of the response of rat MCs to mechanical and chemical trauma, it is concluded that in physiology and pathology: "regulated release of histamine from or by mast cells is an important factor in controlling vascular tone and permeability; regulated release of heparin and/or related substances controls local thrombus formation and, through the 'clearing-factor' mechanism, controls lipid transport."

Higginbotham & Dougherty D33,668/55: Heparin, agar-agar, and other macromolecules s.c., readily form azure-staining granules in fibroblasts of the mouse. Following shedding of MC granules under the influence of stressors and after injection of isolated MC granules, these are likewise taken up by fibroblasts. "It is evident that fibroblasts can absorb polysaccharides released endogenously under stressful conditions as well as administered substances of this type. It is suggested that this process (micellophagosis) plays a role in detoxification by absorption and intracellular degradation of conjugates of polysaccharides with noxious agents. This concept re-emphasizes Ehrlich's suggestion that mast cells are scavengers."

Bartoli D27,055/55–56: On the basis of purely morphologic observations, the theory is formulated that the MCs absorb various substances useful in tissue defense and thus represent "a system of alarm" of the organism against the action of various abnormal stimuli.

Piccinelli C28,175/56: MCs are claimed to exert a "non-specific detoxifying action" because CCl_4-inhalation causes MC degranulation in the rat. [It is not clear, however, why the author draws this conclusion from such observations (*H.S.*).]

Perry D30,574/56: "Releasable histamine is located in mast cells and is only present in quantity in the skins of the mouse, rat and cat." These three species "cannot (or can only with difficulty) produce fixed antibody in the skin in response to an antigenic stimulus. They may not, therefore, depend so much upon antibodies for defense, as upon a very active phagocytosis and on large quantities of releasable histamine. This histamine, when released, promotes a violent oedema which dilutes and washes out foreign material."

Calzavara et al. D13,495/60: Following X-irradiation, as after extensive skin burns, the peritoneal MCs of the rat undergo a biphasic reaction of degranulation followed by regranulation. This response is considered to be nonspecific and an expression of a defense against injury.

LeBlanc et al. D87,634/60: In fishermen, used to cold water, the pressor response to cold is diminished and pain is less easily induced by immersion into cold water than in control individuals. "Skin biopsies showed no difference in skin thickness or cell size but there was a significantly greater number of mast cells in the fishermen's skin. The difference between the fishermen and the control subjects may be related to repeated cold exposure."

Higginbotham G7,638/62: Heparin can inhibit the systemic lethal effects of Russell's Viper venom (RVV). "Mast cell response may therefore be an important factor in local resistance to RVV."

Riley D26,692/62: 48/80 activates the connective tissue of the rat in the immediate vicinity of its injection. "The fixed mesenchymal cells become plump, granular, basophilic, and finally amoeboid until the affected area comes to resemble a vigorously growing tissue-culture." This local response can be reproduced when a mixture of histamine and heparin is injected directly into the peritoneal cavity or subcutaneous tissue of rat or mouse. Moreover, it can even develop in animals which have been freshly killed just prior to the injection. Since it is known that metachromatic material, discharged by MCs under the influence of 48/80, is subsequently ingested by fibroblasts, the theory is formulated that "histamine facilitates the entry of heparin or mast-cell granules into the mesenchymal cell, which then forms fresh mucopolysaccharide of its own." This response may have a defensive value in inflammation.

Csaba et al. D79,388/62: MCs are produced in vitro within the explanted thymus of X-irradiated or of albumin-immunized rats, especially if the medium contains heparin. Some MCs also appear under these conditions in explanted lymph nodes, but not in splenic tissue. On the other hand, the spleen produces plasma cells. It is concluded that "the thymus is principally involved in states where the correlation between the tissues is disturbed: it produces acid mucopolysaccharides and mast cells. The spleen, on the other hand, has an important function in states of tissue immunity: it produces immune substances and plasma cells."

Csaba E36,438/63: The increase in the thymic MC population induced by stress or cortisone is regarded as a defense reaction related to the increased production of mucopolysaccharides.

Kátó & Gözsy D66,168/65: The MC count increases around subcutaneous murine leprosy granulomas, reaching a peak after 40 days and then decreasing as the resistance of the host breaks down. India ink (i.v.) accumulates at the sites of infection when the MC disruption is maximal, "thus suggesting that the natural defence mechanism is well functioning and it is maintained by mediators of mast cell origin: histamine and serotonin." Antileprosy drugs, which retard granuloma formation, also impede the decline of local mastocytosis.

STRESS

The data quoted in the preceding section have already suggested some MC participation in stress responses. This function may be important in the regulation of the microcirculation, and in the mediation of the stress response from the site of injury to distant organs. The fact that the most diverse physical and chemical injuries produce MC degranulation has also often been cited as evidence of a nonspecific reaction to local stressors. Indeed, according to many investigators, even systemic stress results in widespread MC degranulation.

Fulton et al. C35,831/57: On the basis of an extensive review of the literature, it is concluded that the MCs presumably play "an important role in adjustment of microcirculation to the needs of tissue cells, especially during trauma or stress."

West C64,139/58: Review of literature and extensive personal study led to the belief "that mast cells act as part of the defense mechanism of the body whereby they react quickly to any kind of cell injury. The local action of the released amines results in the formation of oedema fluid, which assists in the removal of foreign materials and floods the tissues with protein-rich fluid ready for the job of repair."

Hill & Pospíšil C73,689/59: The pronounced changes obtained in the mesenteric and omental MCs of the rat by intramuscular injection of formalin suggest that these elements play an important role during stress.

Hill & Pospíšil C99,519/60: It is assumed that the MCs play an important role in stress. A single intramuscular injection of 0.3 ml of 4 per cent formaldehyde per 100 g rat, produces cyclic alterations in the mesenteric MCs with an initial shrinking and lysis of the granules followed by a secondary phase of swelling with granule discharge.

Kádas & Virág D26,824/61: Sudden death induced in dogs and hare by a shot through the medulla oblongata is normally followed by degranulation of the mesenteric MCs and an increase in the heparin content of the blood. These changes can be prevented by "inactivating the pituitary-adrenal-cortical system through barbiturate (Evipan) anesthesia." These observations were thought to indicate that the MC system plays an important part in stress and that the MCs are under the control of a "neuroendocrine system" (*Kádas et al.* D26,825/61). [This blocking effect of the barbiturate is undoubtedly of interest if confirmed, but the present experimental series gives no evidence in support of the view that the inhibition is due to an inactivation of the pituitary-adrenal system (*H.S.*).]

Parish E4,391/64: The pharmacologic substances released by MCs "are mediators of changes occurring in inflammation, thus the mast cell provides a reserve of material readily available in any sudden physiological stress or damage to the tissues."

BLOOD VESSELS, EDEMA

Because of the well-known tendency of MCs to arrange themselves in close contact with the walls of small blood vessels, they have long been suspected of playing an important part in the regulation of microcirculation. This view received further support from the subsequent observation that several strongly-vasoactive substances (histamine, 5–HT, SRS) are produced by MCs; these compounds could hardly fail to influence vasomotion and capillary permeability. Through their effect upon smooth muscle, the vasoactive amines of MCs probably also play a part in the regulation of the blood pressure.

We have no definite proof of bradykinin production by MCs, but there is some reason to believe that these cells can release an enzyme which forms bradykinin (or some similar potent vasodilator which increases capillary permeability) from a plasma globulin.

A considerable literature has accumulated concerning the possible role of MCs in the pathogenesis of thrombo-embolic diseases and arteriosclerosis. Heparin is suspected to play the principal role here by decreasing blood coagulability, clearing the blood of lipids and decreasing platelet adhesiveness and blood viscosity. Undoubtedly, metachromatic material often accumulates in and around atheromatous lesions. Yet, further work will be necessary to substantiate the part played by MCs in such vascular diseases.

General

Nepriakhin D26,879/56: Because of the close relationship between MCs and vessels, these cells which frequently reach the endothelial surface are considered to play an important role in the exchange of materials between vessels and tissues. Indeed, it is assumed on morphologic grounds that MCs can transform themselves into endothelial cells, and vice versa.

Blood pressure, vasoconstriction

Keller D26,882/56; C34,639/57: In rats rendered hypersensitive by desoxycorticosterone (following conditioning with unilateral nephrectomy and 1 per cent NaCl as a drinking fluid), a single s.c. injection of heparin suffices to produce a long-lasting reduction in blood pressure. "After rendering functionally ineffective the mast cell system of hypertensive animals by intraperitoneal injection of distilled water or of histamine liberator 48/80, the reduction in blood pressure caused by heparin is not initially modified, but its duration is substantially shortened." These experiments suggest that, in an indirect manner, the MCs may participate in the regulation of blood pressure, at least under certain conditions.

Schayer E37,862/64: On purely theoretic grounds it is assumed that "in vivo mobilization of histamine may be capable of explaining the microcirculatory aspects of post-exercise hyperemia."

Capillary permeability, edema

Wegelius & Asboe-Hansen C29,551/56: "The authors advance the view that the mast cells contain and are able to release mucopolysaccharide material to the intercellular substance in response to tissue oedema. Free water in the tissues may be bound and converted into mucinous substance."

Asboe-Hansen & Wegelius C29,324/56: A great variety of nonspecific damaging agents, which cause tissue edema (histamine, histamine-liberators, trauma, or injections of water) lead to disruption of the MCs in the cheek pouch of the hamster. "The degranulation is interpreted as a response to increased tissue fluid, which in turn may be due to increased capillary permeability. The mucopolysaccharide-containing granular substance of the mast cells may bind extracellular water and thus maintain the gel structure of the connective-tissue ground substance. This view unites the results of previous experiments on the relation of the mast cells to histamine as well as to tissue mucopolysaccharides."

McGovern D26,767/56: The endothelium of the peritoneum, pleura, and blood vessels have a very similar structure. There is a surface layer of argyrophilic protein material and argyrophilic cement lines separate the individual endothelial cells. Underneath the epithelium and closely attached to it are the MCs. When the peritoneum of the rat is mildly irritated by topical application of 1 per cent acetic acid or 48/80, there is an increased production of the surface protein film and imbibition with metachromatic substance of both the cement lines and the surface film, this being associated with degranulation of the subendothelial MCs. The so-called stigmata or stomata, which were thought to appear on the borderline between endothelial cells, are actually bubbles of metachromatic material which have an argyrophilic outline. "It is postulated that capillary permeability is partly due to a spreading factor, produced by mast cells, which acts on the surface protein layer of the endothelium."

McGovern D28,556/56: Various compounds which produce MC disruption increase capillary permeability, presumably by altering the metachromatic surface cement-film of the

vascular endothelium. No such effect is exhibited by heparin or histamine. "These facts naturally lead to the postulate that mast cells produce, in addition to other substances, a permeability factor which alters the consistency of the cement film covering edothelial surfaces."

Asboe-Hansen & Wegelius C73,310/57: "In their bodies the mast cells contain oedema substances, but also substances which can organize oedema." [However, only very indirect evidence is available in support of this concept. While MC degranulation is usually accompanied by edema, it is difficult to determine whether the degranulation of the cells is the cause or the result of water accumulation (*H.S.*).]

Curran D27,624/57: "Acid mucopolysaccharides are present in and around capillary endothelium in a variety of human and mouse tissues. The most sensitive method for their demonstration is autoradiography after the use of radioactive sulphate in vitro or in vivo, but they can often be stained" (e.g., metachromatically with thionine or cresyl violet). "McGovern [D28,931/55; D26,767/56; D28,556/56; D27,739/57] believes that this substance may be heparin liberated from mast cells, but it appears equally possible for it to be elaborated directly by the endothelium." This material is especially plentiful in regenerating tissue and the stroma of tumors, but above all, in fields of osteogenesis.

West C64,139/58; *Crabb* C53,754/58; *Kelsall & Crabb* D26,076/59, *p. 157:* Reviews on the role of MCs in the regulation of capillary permeability and edema formation.

Craps D27,704/60: Brief review of the evidence suggesting the participation of MCs in various vascular reactions and edema formation.

West D33,712/62: Histamine released from MCs in the rat may cause the appearance in lymph of an enzyme capable of producing bradykinin from a plasma globulin and bradykinin possesses a potent vasodilator effect, increases capillary permeability, causes local accumulation of leukocytes and produces pain.

Thromboembolic disease

Battezzatti D31,581/51: A large number of MCs is found in the walls of arteries affected by thromboangiitis. At the same time, there is an increase in the bone-marrow MC population of the affected limbs. It is thought that perhaps the MCs combat thromboangiitis by producing heparin.

McGovern D28,931/55: In the rat, various forms of mechanical or chemical injury to blood vessels stimulate the endothelium to produce material similar to intercellular cement. "At the same time, a metachromatic substance thought to contain heparin diffuses through the endothelium. This unites with the newly formed granular cement, which then coalesces to form a film on the endothelial surface. The metachromatic component is not a product of endothelial cells but probably comes from mast cells. Either inadequate heparin production or defects in the vehicle, the cement film, predisposes to thrombus formation." Similar changes have been seen in injured vascular endothelium of man.

Pettersson & Hjelmman G15,429/64: Around veins in which thrombosis was produced by sclerosing agents in rabbits, the MC density increases. At the same time, many of the surrounding fibrocytes become laden with metachromatic granules. These findings suggest some relationship between blood clotting and MC activity.

Arteriosclerosis

(Cf. also LIPID METABOLISM, *p.* 398.)

Schultz D29,296/22: The connective-tissue ground substance of blood vessel walls normally contains a metachromatically-staining mucoid substance. The intensity of metachromasia (e.g., for cresyl violet) increases in various types of experimental and clinical arteriosclerosis. It is assumed that the metachromatic substance attracts calcium and lipids, thereby predisposing for the development of arteriosclerosis. This metachromatic material may be derived from degenerating elastic fibers. [No special mention is made of its possible derivation from MCs (*H.S.*).]

Faber D29,294/49: Metachromatic material accumulates in the arterial wall during various forms of experimental and clinical atherosclerosis (*Rinehart & Greenberg* D29,295/51). Furthermore, extracellular cholesterol tends to accumulate, especially in tissues which stain metachromatically with toluidine blue (e.g., cartilage, arcus senilis cornae, inflammatory tissue, aorta). [These observations as well as the increase in blood heparinoid substances, observed in human atherosclerosis (*Nikkilä & Majanen* D26,329/52) suggest that

some relationship exists between this disease and the MCs which are principally involved in the production of metachromatic substances including heparin (*H.S.*).]

Constantinides B81,085/53: The rabbit is very sensitive, while the rat is extremely resistant to cholesterol atherosclerosis. Heparin inhibits atherosclerosis in the cholesterol-fed rabbit. While the various tissues of the rat are rich in MCs, only a few of these cells are found in the skin, skeletal muscle, heart, and intestine of the rabbit, although its other organs are virtually free of them. In view of these findings it is assumed that the rabbit may be atherosclerosis-susceptible because of the poor development of its MC system.

Studer C6,137/54: Brief discussion of participation of MCs and heparin in arteriosclerosis.

Lino & Salvatore G18,901/55: In patients with atherosclerosis, the cardiac MC count is significantly subnormal. At the same time, the blood level of metachromatic substances diminishes. "The authors suggest the hypothesis of a direct relation between mastcell rate, blood concentration of metachromatic substances and atherosclerosis."

Fodor & Lojda D65,270/56: Following feeding of fat, the MCs of the rat peritoneum show only minor degrees of degranulation unless protamine i.v. is simultaneously administered. Protamine in itself has little effect. It is assumed that protamine neutralizes the released heparin and, hence, calls for more heparin discharge from MCs to clear the blood of chilomicrons. Such a clearing mechanism may play an important part in the pathogenesis of atherosclerosis.

Padawer D30,194/57: Discussion.

Marx et al. C28,984/57: "More heparin was found in the tissues of the rat than in the tissues of the rabbit. As the former species exhibits greater resistance to hyperlipemia and atherosclerosis, the observations agree with the theory that the heparin content of the tissues may be one of the factors which contribute to this resistance."

Pollak D26,440/57: Numerous observations in the literature suggest that MCs may participate in the pathogenesis of atheroscolerosis, presumably by regulating lipid metabolism. For example, in an extensive study of the MCs of human blood vessels, the highest counts were observed in patients whose blood plasma was milky at autopsy. It was suggested that perhaps MCs are attracted by lipoproteins carried into the vessel wall by blood plasma insudate. This view finds support in: "Heparin carried and released by tissue mast cells might serve to break down lipoproteins into soluble protein and insoluble lipids. The presence of mast cells in edematous tissues and their absence in atheromatous plaques possibly implicate these cells as participants in atherogenesis."

Paterson & Mills C71,884/58: In 67 consecutive autopsies, "no relationship has been found to exist between the number of mast cells and the degree of atherosclerosis. However, a significant reduction in the number of these cells was apparent in cases with complications such as thrombosis, infarction, and acute coronary insufficiency compared with the number in cases without these complications."

Pomerance D33,710/58: The number of MCs around the coronary arteries is considerably increased in patients with coronary occlusion. "It is postulated that the increase in perivascular mast cells is due to inhibition of the normal mechanism of heparin release." This does not contradict earlier finds of a decrease in MCs in the myocardium at a distance from the atheromatous vessels.

Bersohn C51,282/58: Theoretical considerations lead to the conclusion that the MCs play an important role in the pathogenesis of atherosclerosis by liberating heparin, which notoriously acts as a clearing factor for blood lipids, decreases platelet adhesiveness and blood viscosity, and prevents blood clotting. Since it has been shown (*Bélanger et al.* D26,-328/57) that magnesium deficiency decreases the MC population of the rat, it is concluded that "magnesium deficiency may be linked with mast cells and heparin production, dietary atherogenic factors, stress and shock."

Watson D26,643/61: The myocardial MC population of the rat is not influenced when intense hypercholesterolemia and organ lipidosis are produced by lipogenic dietary regime. Furthermore, depletion of tissue MCs by 48/80 does not affect recovery from such a state. "The myocardial mast cell is probably not involved in the early stages of vascular lipid infiltration."

Douglas et al. G9,087/62: Prolonged treatment with 48/80 causes disappearance of the cutaneous and peritoneal MCs and an increase in the lipoprotein-lipase activity of the

aorta and subcutaneous tissue in rats. "It is postulated that there is a system which regulates lipase activity of the tissues through the mast cells."

Douglas et al. G9,086/62: After prolonged treatment with 48/80, "the aorta and coronary arteries revealed no atherosclerotic changes even in those animals (rats) receiving an excess of cholesterol in the diet, although they were hypercholesterolemic and showed accumulation of lipids in tissues as well as fatty liver."

Wexler D45,267/64: In old breeder rats, the development of arteriosclerotic lesions is associated with a corresponding diminution and degeneration of the cardiac MCs whose granules tend to become orthochromatic. Virgin rats which do not develop arteriosclerosis fail to exhibit such MC changes. [The statistical significance of the variations has not been calculated (*H.S.*).]

Douglas et al. E42,119/64: In rats chronically treated with 48/80 or a high-cholesterol diet, widespread MC degranulation occurs in combination with certain changes in the mucopolysaccharides of the aorta, the connective tissue, and the blood. "It is concluded that the mast cells probably intervene as an adaptive factor in the physiology of the arterial wall."

NERVOUS FUNCTION

Although the peripheral nerves and ganglia of various mammals contain some MCs, none are found, as a rule, in the brain and spinal cord. However, in some animals such as the dog and hedgehog, an extraordinarily large number of MCs occurs in the olfactory bulb and tract, an observation which led to the assumption that, here, the MCs may play some physiologic role in relation to olfaction.

In the human skin, there are cells with metachromatic granules which also give positive reactions for noradrenaline. They are located in close association with the terminal reticulum of the vegetative nerves and hence it was assumed that these are modified MCs which play a role in the humoral transmission of nervous impulses.

With MC dischargers or histamine itself, it is possible to induce selective calcification of the autonomic nervous system by certain calciphylactic and calcergic techniques. These observations also suggest that MC products can affect the nervous system. The effect of 5–HT upon cerebral metabolism is well established, but none of the observations just surveyed furnished definite proof that the MCs are specifically involved in the function of the nervous system.

Torsegno D39,799/35; D39,595/35: The presence of numerous MCs in the olfactory bulb and tract of the dog and hedgehog suggests that these cells may play a physiologic role in relation to olfaction.

Hermann D30,199/52: In human sympathetic ganglia, MCs are scarce and often missing. Their number varies greatly in ganglia of different regions but nowhere are they in such intimate contact with nerve cells as to justify the assumption of their participation in nervous transmission.

Niebauer & Wiedmann D39,678/58: In the human skin, MCs or at least similarly-staining cells, are frequently found in close contact with nervous elements. These pictures suggest a neurohumoral function.

Wiedmann & Niebauer C67,755/59: Both metachromatic cells (MCs?) and cells which give positive reactions for noradrenaline are found in close association with the terminal reticulum of the vegetative nerves along the cutaneous vessels of man. It is assumed that the MCs plays a role in the humoral transmission of nervous impulses.

Wiedmann C99,174/60: The so-called "neurohumoral" cells of the skin contain metachromatic granules which are discharged during inflammations.

Kádas & Virág D26,824/61: Sudden death induced in dogs and hare by a shot through the medulla oblongata is normally followed by degranulation of the mesenteric MCs and an increase in the heparin content of the blood. These changes can be prevented by "inactivating the pituitary-adrenal-cortical system through barbiturate (Evipan) anesthaesia." These observations are thought to indicate that the MC system plays an important part in stress and that MCs are under the control of a "neuro-endocrine system" (*Kádas et al.* D26,825/61).

Niebauer D12,405/61: On the basis of a review of the literature it is concluded that the most important function of MCs is "the regulation of neurovegetative functions."

Stach D39,563/61: Spreads of the musculo-cutaneous tissue of rats can be vitally stained with methylene blue to demonstrate simultaneously the terminal reticulum of vegetative nerves and the MC. A definite topographic relationship between these structures suggests a functional participation of MCs in nerve actions.

Hiatt & Katz D25,019/62: Among a variety of gastrointestinal diseases, "the only conditions which demonstrate a definite increase above control values were peptic ulcer, regional ileitis, ulcerative colitis and spastic colitis. These diseases all bear the label 'psychosomatic' and it thus may be possible that the mast cell is in some way involved in the 'psychosomatic' process."

Kátó et al. D30,616/62: A striking correlation has been established between the psychotrophic effect of various drugs and their ability to influence anaphylactoid inflammation. [Although the authors cautiously avoided drawing any far-reaching theoretic conclusions from this observation, it is tempting to think of some possible connection between this effect and the liberation during the anaphylactoid inflammation of 5–HT by the MCs, since 5–HT certainly plays an important part in cerebral metabolism. Yet, the possible influence of the stressor action of "psychotrophic" drugs must also be considered since stress notoriously inhibits anaphylactoid inflammation (*H.S.*).]

Mosinger et al. D59,136/62: MCs are particularly numerous in the skin and exhibit close morphologic relations to nerve endings.

Wiedmann D60,447/63: The Langerhans' cells of the epidermis, Riehl's dendrite cells on the internal surface of the epidermis, and the so-called neurohormonal cells of the skin are morphologically indistinguishable, although they differ in their function and histochemical properties. The neurohumoral cells are metachromatic. The cells of Langerhans and Riehl appear to participate in pigment metabolism.

Ehrenbrand D19,113/64: In the paraganglion caroticum of the calf, there are unusually many MCs, the granule content of which varies greatly. Masses of MCs are found within the myelinated nerves in the immediate vicinity of the carotid body. This anatomic arrangement suggests close correlations between MCs and the nervous system.

Selye et al. G11,123/64: In rats simultaneously given lead acetate i.v. and histamine s.c., successive calcium deposition occurs in various parts of the autonomic nervous system. This "neurotropic mastocalcergy" can be inhibited by pretreatment with various MC-dischargers (48/80, polymyxin, chlorpromazine); MC components (histamine, 5–HT) are drugs known to inhibit the pharmacologic action of such MC components (cyproheptadine, neo-antergan). "This prophylactic effect appears to be largely specific to compounds related to mast-cell activity since it was not shared by various other drugs and stressors tested." Little is known as yet about the participation of the MCs in nervous functions, but the fact that under certain conditions MC products can produce selective lesions in the nervous system suggests that this may be a fruitful field for further study. (*Fig. 18, p. 194.*)

RELATIONSHIP TO JUXTAGLOMERULAR APPARATUS

The epithelioid cells of the juxtaglomerular apparatus contain granules which, under certain conditions, stain metachromatically. These elements have been thought to be modified MCs, especially since they allegedly discharge their granules under the influence of dextran and ovomucoid, as MCs do. However, the juxtaglomerular cells do not stain metachromatically under usual conditions, and not all investigators agree that they discharge their granules under the influence of MC-dischargers. Therefore, the relationship of these cells to MCs remains problematic.

Harada D27,441/54: The epithelioid cells of the juxtaglomerular apparatus contain granules which stain metachromatically with methyl violet, crystal violet, and dahlia violet.

Corbascio D27,440/60: The cells of the juxtaglomerular apparatus of the rat kidney have many characteristics in common with MCs. Their granules stain metachromatically with certain dyes to which MC granules react in the same manner. Furthermore, the granules of the juxtaglomerular cells are discharged under the influence of dextran or ovomucoid as are those of the MCs. "The presence of mast-cell-like elements at the vascular pole of the kidney glomerulus is stressed in view of their possible role in the functional activity of the nephron, owing to the fact that degranulation of these cells is capable of releasing anticoagulant and

vasoactive substances like heparin, histamine, and serotonin proximal to one of the most important circulatory districts of the body."

Demopoulos et al. D26,565/61: After fixation in strong oxidants such as potassium dichromate, the cell of the juxtaglomerular apparatus can stain metachromatically; hence, they have been likened to MCs (*Corbascio* D27,440/60). However, these cells, unlike the MCs, do not discharge their granules under the influence of 48/80 or dextran, nor do they stain metachromatically under ordinary conditions, as MCs, and hence, they are not considered to be MCs.

TEMPERATURE REGULATION

Various MC-dischargers cause hypothermia, but there is little evidence that MCs participate in the physiologic regulation of body temperature.

LeBlanc D39,725/59: Chlorpromazine i.p. causes disruption of the peritoneal MCs in the rat and this effect is prevented by KCN simultaneously with the hypothermic effect of chlorpromazine. The experiments are thought to suggest "a possible relationship between mast cell disruption and hypothermia caused by chlorpromazine."

Jamieson & van den Brenk D8,004/61: Hypothermia caused by 48/80 in rats appears to result from histamine and 5–HT liberation by ruptured MCs and is antagonized by a specific antihistamine (mepyramine) and by LSD without the prevention of MC rupture. However, hypothermia caused by chlorpromazine and related phenothiazines, which also rupture MCs, is based on a different mechanism in that: (1) the hypothermia is not antagonized by mepyramine; (2) the hypothermia can be dissociated from histamine release by prior treatment with 48/80; and (3) LSD abolishes the hypothermic activity of chlorpromazine but not its MC-disrupting action. The earlier observation (*LeBlanc* C55,959/58) that cyanide causes a reduction of both chlorpromazine hypothermia and MC disruption, was not confirmed.

Hecht & Gloxhuber D55,529/62: I.p. administration of various insoluble particulate substances, histamine-liberators, and especially 48/80, causes temporary hypothermia in the rat. It is assumed that the peritoneal MCs participate in temperature regulation in the rat.

HAIR GROWTH

The stromal papillae and the growing epithelia of rat-hair roots contain large amounts of metachromatic material, especially at times when hair growth is rapid. The same is true of human hair, particularly in the region of the mons pubis, where MCs may also be found in the papillae. During spontaneous hair cycles, the MC-, 5–HT- and histamine-content of the rat skin increases concurrently. All these facts suggested some MC-participation in hair growth.

Sylvén D29,140/50: With the freeze-vacuum dehydration technique, considerable amounts of metachromatic material can be demonstrated in the stromal papillae and the rapidly-growing epithelia of rat hair roots. "This material is associated with periods of intense proliferation of hair epithelia, and is most likely supplied via the stromal matrix. The pronounced alcohol stability of the staining reaction is regarded as indicative of polysaccharide ester sulfate, but analytical evidence is still lacking." Mast cells have not been observed in the rat hair papillae but occur occasionally in those of man [and of rat bristles (*H.S.*)].

Montagna et al. D28,552/51: In the normal human skin of the mons pubis, intense metachromasia is observed in the papillae of growing hair follicles and the cells of the external sheath. The adjacent MCs stain similarly, but no topographic relationship between these and the diffuse metachromasia is noted. "Metachromasia here described is visualized at acid *p*H and resists extraction in alcohol. The metachromasia in the hair papilla and in the external sheath is not abolished by testicular hyaluronidase, and may represent chondroitin sulfate B."

Moretti et al. D27,515/62: The MC-, 5–HT-, and histamine-content of the skin is said to vary in the course of spontaneous and provoked hair cycles in the rat. However, in this brief abstract, quantitative results are not given.

Moretti et al. D64,379/63: An unusually large number of MCs appears in the skin of rats during the first days of a spontaneous hair cycle concurrently with a rise in skin histamine. "It seems possible that histamine, perhaps also liberated from the mast cells, may in part be responsible for 'triggering' the mechanism of the hair-growth cycle in the rat."

GROWTH, CELL PROLIFERATION

In rapidly-growing embryonic tissues, granulomas, the stroma of tumors, and regenerating epithelium, there is diffuse metachromasia throughout the ground substance of connective tissue. This has been assumed to depend upon the presence of heparin, presumably derived from MCs. These findings may imply that heparin stimulates growth, but several other observations show that heparin inhibits mitosis. Actual growth stimulation by treatment with this substance has been clearly demonstrated only in frog tadpoles.

Zakrzewski D31,586/32: Addition of heparin to sarcoma cells in tissue culture retards their growth.

Holmgren D27,890/39: In young embryos of various species, amorphous metachromatic substance is seen in diverse, rapidly-growing tissues. This substance may be heparin and, since heparin stimulates the growth of frog tadpoles, the possibility is considered that heparin may be a general growth-stimulating substance. [Although no specific reference is made to the MCs, the concept implies that these cells participate in growth promotion since they manufacture heparin (*H.S.*).]

Holmgren D28,926/40: Studies on embryos of man, rat, and guinea-pig indicate that metachromatic ground substances in connective tissue is particularly prominent at places where growth of the adjacent epithelial structures is most intense. "It is of course difficult to decide whether the chromotrope substance induces the growth or is itself a consequence of it." Although other investigators maintained that this diffuse metachromasia is derived from the MCs, this could not be demonstrated in the present experiments. Yet, it is assumed that the metachromasia probably corresponds, at least in part, to heparin.

Sylvén D26,048/41: Diffuse metachromatic staining is especially evident in various types of rapidly-growing tissues (embryonic tissues, granuloma, regenerating epithelium). It is thought that the MCs discharge their granules into those tissues in which growth proceeds most actively and that this process may have physiologic significance. No evidence could be found in support of the old theory that the appearance of metachromatic mucinous substance in tissues is a sign of "mucinous degeneration."

Sylvén D31,569/49: In the stroma underneath growing normal or cancerous epithelia, metachromatic polysaccharide ester sulfates appear. "Present results indicate the existence of very close functional interactions between growing epithelia and stroma, probably aiming at the supply of raw-materials for epithelial growth. The transfer of high-molecular ester sulphates to the cytoplasm of epithelia is an expression of such a stroma function." Attention is called to the fact that MCs also contain enzymes such as alkaline phosphatase which may participate in growth processes and that "the volutin granules in yeast do present an alcohol-resistant metachromasia, and thus the presence of ES (high-molecular polysaccharide ester sulphates) has to be postulated."

Sylvén D29,140/50: Considerable amounts of metachromatic material can be demonstrated in the stromal papilla and the rapidly growing epithelia of rat-hair roots.

Paff et al. D28,673/52: When heparin is added to embryonic chick heart cultures, mitosis is inhibited in the outgrowing fibroblasts. This antimitotic effect is attributed to an interference by heparin with the metabolism of nucleoproteins. At the same time, the fibroblasts phagocytose metachromatic heparin granules. "As evidence that heparin inhibition of mitosis may act in the intact animal, we offer the observation that when pieces of mast cell tumors are grown in tissue culture, only mast cells grow [*Paff et al.* D26,765/47]. This despite the fact that the tumor contains other cell types. Since mast cells produce heparin or a precursor, it seems that the explanation for the phenomenon may also lie in Roth's [D30,-553/52] observation that heparin inhibits ribonuclease."

Studer C6,137/54: Brief discussion of literature on role of heparin as a growth inhibitor.

Arvy D26,724/55, *p. 74:* Discussion of interrelation between MCs and growth.

Kelsall & Crabb D26,076/59, *p. 95:* Discussion.

Csaba et al. C98,159/60: Since the MC population of the thymus is greatly increased during active growth after tumor transplantation and in pregnancy, it is assumed that these cells are in some manner related to active cell proliferation in the body.

CALCIUM METABOLISM AND OSTEOGENESIS

In the course of the past few years, two newly-observed biologic reactions, calciphylaxis and calcergy, made it possible to study a hitherto unsuspected role of the MC as a metal-binder. Apparently, discharged MC granules can furnish the organic matrix necessary for the binding of various metal salts and particularly those of calcium.

Calciphylaxis is a phenomenon which can induce selective calcification in various organs. It is brought about by pretreatment with a systemic calcifying compound, e.g., parathyroid hormone or vitamin-D derivatives (the "sensitizer"), followed after a time interval (the "critical period") by an eliciting agent (the "challenger").

Calcergy differs from calciphylaxis in that it is produced without previous sensitization, by parenteral administration of so-called direct calcifiers or "calcergens." Most calciphylactic challengers and calcergens are metallic compounds, but, while all calcergens so far tested are also active as challengers, the reverse is not necessarily true. For example, lead acetate, indium chloride, and lanthanum chloride are calcergens in that they cause topical tissue calcification at the site of injection even without any previous sensitization, but they are also challengers in that their calcifying potency is greatly enhanced if they are given to animals previously sensitized by parathyroid hormone or vitamin-D derivatives. On the other hand, ferric chloride, chromic chloride, and aluminum chloride produce calcification only after sensitization, hence, they are calciphylactic challengers but not calcergens.

Through their MC-discharging effect, histamine-liberators play an important role in the mechanism of certain calciphylactic and calcergic syndromes. For example, in rats sensitized by dihydrotachysterol (DHT) and subsequently given $FeCl_3$ i.v., topical calcification of the skin can be produced at sites where histamine-liberators (polymyxin, 48/80, viomycin) are injected. Histochemical studies have shown that, here, the discharged MC granules bind the blood-borne iron which, after calciphylactic sensitization, secondarily attracts calcium salts. Finally, the calcified MC granules disintegrate and release their mineral deposits which then become attached to adjacent connective-tissue fibers. This phenomenon has been designated as *"mastocalciphylaxis."*

If a calcergen, for example lead acetate, is injected intravenously, a subsequent subcutaneous injection of histamine-liberators produces topical calcinosis even without any previous calciphylactic sensitization. Here, the blood-borne lead becomes bound to the discharged MC granules and, being a calcergen, it secondarily attracts calcium salts even without any calciphylactic sensitization. In such cases, we speak of *"mastocalcergy."*

Histochemical methods have made it possible to follow the morphogenesis of mastocalciphylaxis and mastocalcergy step by step. Using appropriate methods for the detection of MC degranulation (metachromatic dyes), the attraction to the granules of blood-borne iron (Prussian-blue reaction), lead (sodium-rhodizonate technique), calcium (chloranilic-acid technique) or phosphate and carbonate (von Kóssa reaction) can be readily visualized.

If MC-dischargers are administered systemically to suitably-prepared animals, calcification will ensue wherever MC degranulation is particularly pronounced. Thus, under these conditions, dextran or egg white, which discharge the MCs predominantly in the anaphylactoid shock organs, induce these to undergo selective

calcification. Depending upon their particular organotropism (that is, their ability to induce MC discharge predominantly in one or the other region) other MC-dischargers may produce calcification in the esophagus, the nuchal musculature, or more or less diffusely throughout the skin.

A particularly striking example of such selective organotropism is furnished by the *neurotropic forms* of mastocalciphylaxis and mastocalcergy which induce selective calcification in the autonomic nervous system. Calcification in the vagus and throughout the sympathetic nerves has been obtained, for example after calciphylactic sensitization by aluminum dextran i.v. or, without calciphylactic sensitization, by lead acetate i.v. followed by polymyxin or 48/80 s.c. The former experiment represents an instance of neurotropic calciphylaxis, the latter of neurotropic calcergy. It is interesting that, in neurotropic calcergy, histamine can replace the MC-dischargers in eliciting autonomic nerve calcification after pretreatment with lead acetate i.v., while 5–HT and heparin are inactive in this respect. On the other hand, the topical mastocalciphylaxis induced by MC-dischargers s.c. in animals pretreated with lead acetate i.v., can be duplicated both by histamine and by 5–HT s.c., but not by heparin s.c.

This outline will suffice as an introduction to the original articles that describe the participation of MCs and MC products in various forms of experimental soft-tissue calcification. Much further work will be required to elucidate the intimate mechanism of these reactions, but it is already evident that through mastopexis (the potent binding effect that MC products can exert upon various blood-borne compounds, particularly metals) the MCs are capable of influencing mineral deposition in various organs with great selectivity.

There are a few *other observations suggesting a relationship between* MCs *and calcium*: In keloids containing numerous MCs, the tissue calcium is often considerably raised. Toluidine blue inhibits the metastatic calcification normally produced by parathyroid hormone in the rat and this augmentation can, in turn, be blocked by heparin. Calcium ions appear to be indispensable for the release of histamine by anaphylaxis or 48/80. Both mucopolysaccharides and iron are demonstrable by histochemical techniques in certain forms of spontaneous calcification.

The MCs may even participate in *osteogenesis*. In fields of active new-bone formation, acid mucopolysaccharides are plentiful around capillary endothelia; they can often be stained by metachromatic dyes and are believed to be derived from MCs. In rats kept on a low calcium and vitamin-D deficient diet, a large number of MCs appear along the endosteum and this mastocytosis can be abolished by treatment with large doses of vitamin-D (cf. EFFECT OF DIET ON MAST CELLS, *p.* 237).

Calciphylaxis

Selye D15,540/62, *pp. 16, 448; Gabbiani et al.* D64,692/64: In calciphylactically-sensitized rats, treatment with polymyxin results in the precipitation of calcific material around many cutaneous MC granules. If certain iron compounds (e.g., Fe-Dex) are injected i.v., simultaneously with the polymyxin administration, iron becomes fixed in the vicinity of the discharged MCs and, secondarily, appears to attract calcium from the blood stream. If calciphylactically-sensitized rats are treated with iron preparations in which the metal is combined with a *mast-cell discharger* that produces a typical anaphylactoid inflammation (e.g., ferric dextrin or thorium dextrin), the anaphylactoid shock organs (lips, ears, tongue, paws) become heavily calcified. Apparently, in all these instances, MC discharge helps to localize metals in certain regions selectively.

Selye et al. D15,688/62: In rats sensitized for calciphylaxis with DHT, *distilled water* s.c. produces no local calcinosis, unless the animals simultaneously receive small amounts of ferric dextran i.v. This action of water appears to depend upon its MC-depleting potency since near-isotonic solutions of NaCl or glucose have little or no calcium-precipitating effect under similar circumstances, while highly hypertonic solutions of these same compounds are virtually as effective as distilled water (presumably because, like the latter, they discharge MCs, but isotonic solutions do not). Apparently, the ability of discharged MC granules to attract calcium salts is greatly enhanced, if they are first incrusted by blood-borne iron, which acts as a calcium trap.

Selye D15,540/62; E24,150/64: Mastocalciphylaxis is interpreted as a phenomenon in which MC degranulation, induced following suitable sensitization, causes the attraction of various *blood-borne metals* to discharged MC granules. (*Fig. 28.*)

Selye D59,442/63: In rats calciphylactically sensitized with DHT, *thorium-dextrin* i.v. produces MC degranulation and calcification predominantly around the shoulder and hip joints

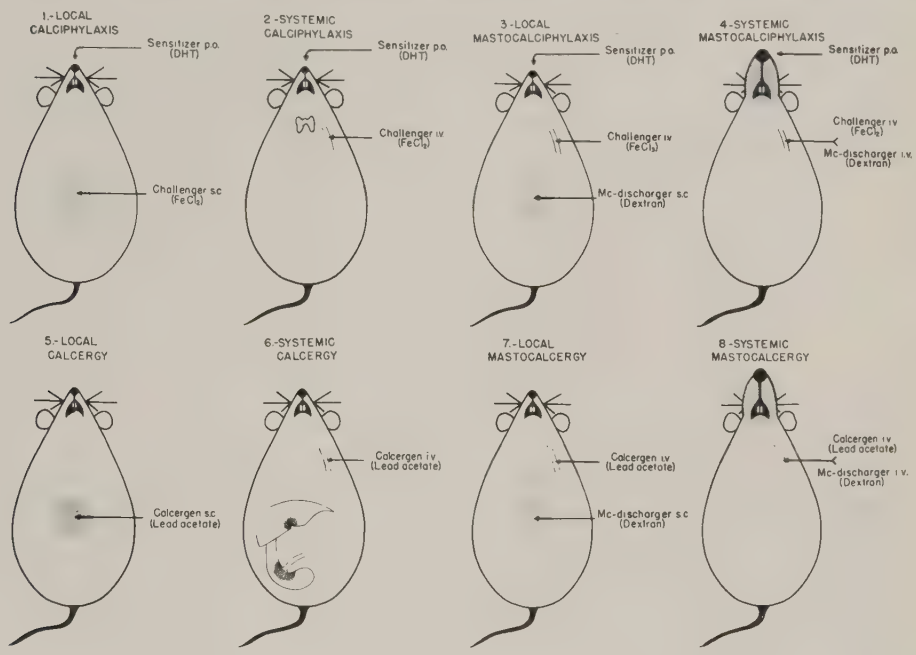

Figure 28.—Schematic representation of the various forms of calciphylaxis and calcergy. [After *Selye* E24,150/64.]

in the rat. It is assumed that here the discharged MC granules participate in the localization of first thorium, then calcium salts.

Selye et al. D58,540/63: In rats calciphylactically sensitized with DHT, *aluminum dextran* produces calcification in the autonomic nervous system and in the anaphylactoid shock organs. Aluminum dextran is an MC-discharger which produces an anaphylactoid reaction in non-sensitized animals; hence it is assumed that this calcifying syndrome is, at least in part, also dependent upon MC degranulation.

Selye et al. D40,219/63: Large calcified skin plaques are produced if rats, pretreated with dihydrotachysterol (DHT) p.o., are calciphylactically challenged through the infiltration of a tissue area with dilute solutions of *ferric dextran* s.c. A variety of agents such as distilled water, mechanical trauma, formaldehyde, croton oil, or histamine-liberators (48/80, polymyxin), selectively inhibits this skin calcification at the point where they are applied within the challenged area. As judged by histologic studies, this anticalciphylactic effect appears to

be one of the most sensitive indicators of local stress. It is accompanied by changes in the MCs, and in the distribution of the challenger (here iron). Irrespective of the nature of the topical protective agent, the histologic structure of the skin in and around the treated area was always essentially the same in that three distinct zones could be distinguished: (1) An unprotected peripheral zone is massively calcified and exhibits the characteristics just described. In addition, here, the MCs show degranulation and a diffuse metachromasia appears in the calcified and partly necrotic connective tissue. Iron deposition is extracellular and forms a faint, more or less homogenous, Prussian-blue positive incrustation of the calcified areas. (2) An intermediate zone, just inside the calcified periphery, shows little or no calcification but fairly numerous histiocytes replete with Prussian-blue-positive iron granules. Here, there is little or no metachromatic material or iron in the extracellular space. (3) A central, protected zone without calcification or any other obvious evidence of tissue damage. In this region there are almost no MCs or iron-containing phagocytes, but diffuse metachromasia and ferrification are likewise absent (*Figs. 9, 10,* and *11, pp. 176, 177, 178*).

Selye et al. D15,989/63; E24,147/64: In rats sensitized for mastocalciphylaxis by pretreatment with DHT and subsequent injection of *ferric dextran i.v.*, subcutaneous administration of polymyxin, 48/80, or stilbamidine produces topical calcinosis, presumably owing to the fixation of iron and then of calcium salts on the discharged MC granules.

Selye et al. E24,138/64; E24,139/64: "Mastocalciphylaxis ensues when a DHT-sensitized animal is given a metallic challenger (e.g., $FeCl_3$) intravenously and, simultaneously, a mast-cell discharger (e.g., polymyxin) subcutaneously. Here, the mast-cell discharger elicits a *chain reaction* resulting in topical calcification at the site of injection although the challenger is given systemically. Histochemical studies make it probable that this chain reaction evolves in four stages: 1) Liberation of metachromatic granules; 2) the metachromatic material attracts iron; 3) the fixed iron in turn attracts calcium, phosphate and probably carbonate; 4) the calcium precipitate becomes attached to the adjacent connective-tissue fibers." (*Plates I* and *II.*)

Caruso G11,119/64: In rats pretreated with DHT p.o. and $FeCl_3$ i.v., dextran or polymyxin produce much more intense calcification if injected into the *lips* (where MCs are numerous) than if introduced into subcutaneous connective tissue (where MCs are less numerous). Apparently, "soft-tissue calcification is directly proportional to the regional density of tissue mast cells and their granule discharge."

Veilleux D55,007/64: In rats calciphylactically sensitized with DHT, the calcification of the anaphylactoid shock organs normally induced by the injection of ferric dextrin i.v. is *suppressed* by the injection of dextran i.p. one hour prior to the ferric dextrin. Histochemical studies indicate that in the latter case the iron does not reach the shock organs and, presumably, that is why calcification fails to occur. [Although the author does not say so, the prevention of iron deposition may well be related to the previous discharge of the MCs in the shock organs induced by dextran pretreatment (*H.S.*).]

Selye et al. E24,102/64: In rats calciphylactically sensitized with *parathyroid extract* (just as in those pretreated with DHT), subsequent systemic treatment with various MC-dischargers produces calcification in different organs, presumably as a result of MC-discharge and a subsequent attraction of calcium salts.

Calcergy

Selye et al. D25,659/63: A widespread osteomyelosclerosis can be produced in the rat by repeated injections of lead acetate i.v. The response is associated with the appearance of "basophilic bone granules" and numerous MCs in and around the newly-formed bone trabeculae (*Figs. 19* and *20, pp. 198, 200*). This is of interest because basophil proliferation also occurs in certain forms of osteomyelosclerosis in man.

Selye et al. E24,136/64; *Selye & Gabbiani* E24,133/64: Mastocalcergy is produced by lead acetate i.v. followed immediately by polymyxin s.c. The MCs in the treated area first show degranulation without any mineralization, but this is soon followed by lead uptake on the MC granules with secondary attraction of calcium (chloranilic acid reaction), phosphate, and possibly carbonate (von Kóssa reaction). Finally, the discharged and calcified MC granules disintegrate into a dust-like fine precipitate which is transferred to the circumjacent collagen fibers where it initiates an intense process of mineralization, eventually leading to the complete petrification of the polymyxin-injected area. "Apparently, in addition to its already well established functions of histamine, heparin and serotonin production, the mast cell also plays a role in mineralization." (*Plate IV.*)

Selye et al. G11,123/64: The fact that neurotropic mastocalcergy depends upon treatment with various MC-dischargers or MC products in combination with a calcergen, likewise suggests that the MCs can regulate selective organ calcification. (*Fig. 18, p. 194.*)

Selye et al. G11,107/64: When mastocalcergy is produced by the intravenous injection of lead acetate followed by a subcutaneous injection of polymyxin in the rat, there is a topical discharge of MC granules followed by their calcification. This whole reaction proceeds also if the PMX-treated skin area is *transplanted* into an unpretreated control rat. Apparently, the whole complex mechanism necessary for the development of mastocalcergy is fully determined at the injection site within a few hours.

Dieudonné E24,129/64: Following subcutaneous injection of polymyxin (without pretreatment), the discharged granules of the topical MCs begin to calcify within five hours and, subsequently, calcium salts can be histochemically demonstrated also in cutaneous muscle and subcutaneous nerves. This confirms the other observation that *polymyxin can act as a calcergen* without calciphylactic or calcergic sensitization (*Selye* D15,540/62).

Selye & Tuchweber G11,117/65: In rats pretreated with lead acetate i.v., *topical* connective-tissue calcification can be produced at sites where minute doses of various MC-dischargers (48/80, PMX, ovalbumen, viomycin, stilbamidine, trypsin) or MC components (heparin, 5–HT) are injected.

Caruso E24,145/65: In rats given lead acetate i.v., subcutaneous injection of dextran or polymyxin into the *lips*, which have a dense MC population, causes much more calcification than if the same amount is injected hypodermically on the back, where MCs are much less numerous. Apparently, the MCs play an important part in this form of calcergy.

Selye et al. G11,118/65; G11,121/64; *Jahnke* G11,103/65: In rats given lead acetate i.v., the *topical* connective-tissue calcification produced by minute doses of various MC components (histamine, 5–HT) or MC-dischargers (48/80, polymyxin) can be *inhibited* by large doses of any one among these compounds. The protective effect of the MC-dischargers could be due to the unavailability of normal MCs at the time of subsequent treatment with other MC-dischargers but the mechanism, through which histamine, 5–HT, and adrenaline offer protection, is not yet clear. (*Fig. 15, p. 188.*)

Other observations suggesting a relationship between mast cells and calcium

Pautrier & Woringer D27,883/31: In keloids, MCs are numerous and the tissue calcium content is about three–four times that of normal connective tissue.

Baker et al. B85,053/53: Contrary to previous observations showing that in-vitro calcification is inhibited by toluidine blue, in-vivo i.p. injection of toluidine blue inhibits the metastatic calcification normally produced by parathyroid hormone in the rat. This augmentation of the parathyroid hormone effect is in turn blocked by heparin.

Chakravarty C83,831/60: As judged by in-vitro studies, calcium ions are indispensable for the release of histamine by anaphylaxis or 48/80 in the guinea-pig and rat. [However, the possible participation of MCs was not investigated (*H.S.*).]

Johnson et al. F2,277/64: Histochemical studies on cutaneous calcification in man indicate the presence of mucopolysaccharides and iron in the mineralizing tissue. The authors conclude "that elaboration of acid mucopolysaccharides plays an intermediate role in the pathogenesis of calcification by its ability to bind calcium or by the initial binding of iron and its replacement by calcium."

Osteogenesis

Curran D27,624/57: "Acid mucopolysaccharides are present in and around capillary endothelium in a variety of human and mouse tissues. The most sensitive method for their demonstration is autoradiography after the use of radioactive sulphate in vitro or in vivo, but they can often be stained" (e.g., metachromatically with thionine or cresyl violet). "McGovern [D28,931/55; D26,767/56; D28,556/56; D27,739/57] believes that this substance may be heparin liberated from mast cells, but it appears equally possible for it to be elaborated directly by the endothelium." This material is especially plentiful in regenerating tissue, tumor, stroma and, above all, in fields of osteogenesis.

Beare D27,976/58: Review of urticaria pigmentosa with special reference to the bone lesions which are common in this disease.

LIPID METABOLISM
(Cf. also BLOOD VESSELS, *p.* 387.)

Heparin has definitely been shown to possess a lipid-clearing activity and to counteract alimentary lipemia. Since heparin is produced by MCs, it is reasonable to assume that it must play some part in the regulation of lipid metabolism. Some relationship between MCs and fat metabolism is also suggested by the observation that MCs are often numerous in the vicinity of lipophages and adipose tissue. It has been postulated, furthermore, that heparin of MC-origin may be involved in the pathogenesis of atheromatosis (*p.*), but definite proof in support of this view is still lacking.

Ciaccio D26,438/13: Lipids cannot be demonstrated in normal MCs by the usual techniques but they appear in MCs situated within chronically-inflamed tissues, both in man and in animals. They are designated as "Mastlipoidzellen."

Hahn D39,584/43: Heparin i.v. abolishes alimentary lipemia in the dog.

Levy & Swank D39,635/53: During shock due to anaphylaxis or to the injection of certain histamine-liberators, heparin may appear in the blood and alimentary hyperlipemia may disappear, but the two changes do not necessarily coincide in time. "Possibly alternate pathways exist, independently of heparin, for lipemia clearing to occur."

Baratta et al. G1,475/53: In rats kept on a high cholesterol diet, the peritoneal MCs show a pronounced initial rise during the first week followed by a drop below control values, after 15–65 days. It is suggested that the initial rise in MC count reflects an increased demand for heparin to metabolize the excess cholesterol, while the secondary decrease indicates an exhaustion of the heparin-forming mechanism.

Asboe-Hansen D27,999/54: Discussion.

Havel & Boyle D26,429/54: During anaphylactoid reactions produced in dogs by stilbamadine, 48/80, or peptone, the endogenous heparinemia is regularly accompanied by the appearance in the plasma of lipemia-clearing factor identical with that produced by heparin injection. Apparently, the MC granules liberated during anaphylactoid shock can liberate a substance which, like heparin, is effective in this respect.

Waters D27,068/56: Upon intracorneal injection of serum lipoprotein fractions to dogs, MCs appeared in the edematous tissues where normally none are found.

Shoulders & Meng D27,067/57: In rats, fat i.p. increases MC density and causes degranulation.

West C64,139/58: Discussion of relationship between MCs and "lipid-clearing factor."

Douglas et al. G9,087/62: Prolonged treatment with 48/80 causes disappearance of the cutaneous and peritoneal MCs and an increase in the lipoprotein-lipase activity of the aorta and subcutaneous tissue in rats. "It is postulated that there is a system which regulates lipase activity of the tissues through the mast cells."

Fábry et al. E45,801/62: Review of literature concerning the effect of high-fat diets on the MCs.

Spicer D58,289/63: MCs are particularly numerous in the vicinity of siderophages and lipophages in various tissues (lymph nodes, uterus, mammary gland, stomach, and intestine) of various species (mouse, rat, hamster, guinea-pig, rabbit).

Jennings et al. D58,288/63: "Attempts so far made to connect the mast cells with fat transport have for the most part depended on finding differences in them by the light microscope under different conditions of fat metabolism. Changes in number and in cell morphology have been sought. Autoradiographic differences in the uptake from labelled sulphate of sulphur–35, which is incorporated into the mast cell heparin, have also been looked for. Another approach has been to look for changes in the ability of rats to deal with hypercholesterolaemia after depletion of their mast cells by 48/80. A survey of this work leads to the conclusion that there is as yet no satisfactory evidence of a connection between the mast cells and fat transport. This well may be because the methods so far used are unsuitable and, in particular, insufficiently sensitive to enable such a connection to be detected."

Hellman et al. E22,484/63: The MCs of the mouse were examined in the epididymal and subcutaneous adipose tissues. "Both with the obesity induced by goldthioglucose and that

associated with the American variety of the obese-hyperglycemic syndrome there was a considerable accumulation of mast cells in the fat depots. While the relative number of mast cells was calculated as 3 per 100 epididymal fat cells in the lean controls, it was more than 50 for the obese-hyperglycemic animals. . . . The greatly increased mast cell content of the adipose tissue in obesity would be consistent with previous work on the rat, in which it was suggested that the lipase activity of the adipose tissue is concerned with accumulation of fat in depots."

Haikonen & Räsänen G1,314/63: Dexamethasone discharges the gastric and intestinal MCs, and at the same time increases the hypercholesterolemia induced by high fat diets. "It is suggested that a factor activating the clearing factor is mobilised into the organism from the mucosal mast cells in the gastrointestinal tract and that this activating factor is absent after mast-cell degranulation, resulting in alimentary cholesterolemia."

ENDOCRINE FUNCTION

The MCs may be regarded as endocrine cells, since they secrete products which act in minute amounts not only locally but also upon distant organs reached through the blood stream. However, there is little evidence to support the view that MCs regulate the function of classical endocrine glands such as the hypophysis.

Prus D31,542/1895; *Cajal* D31,538/1896; *Greggio* D31,536/11; *Staemmler* D26,-807/21; *Lehner* D27,094/24: The concept that MCs are mononuclear glands that secrete into the connective tissue has been propounded on the basis of morphologic evidence.

Consolandi & Briziarelli B84,591/52: On the basis of morphologic studies on the human hypophysis, it is postulated that MCs can regulate the distribution of colloid granules and thereby hypophyseal hormone secretion, through a process which is designated as "normatoneurocrinia mastocitaria."

Fulton et al. C35,831/57: "Present evidence indicates that mast cells may be unicellular endocrines which produce heparin, hyaluronic acid, histamine, and serotonin (5-hydroxytryptamine), and may thus react as part of the mesenchymal system in time of stress."

RETICULOENDOTHELIAL SYSTEM (RES)

(Cf. also *Phagocytosis* in section on HISTOPHYSIOLOGY, *p.* 82.)

There is reason to believe that histamine increases the phagocytic power of RES cells. Indeed, under the influence of topical treatment with histamine, the endothelia of small vessels become phagocytic as if they were transformed into RES cells. Those who believe that MCs result from the ingestion of heparin by fibroblasts would even rank the MCs themselves among the RES cells; this view appears to receive some support from the fact that, in the dog, the hepatic MCs are located along the walls of the sinusoids just as the Kupffer cells are. However, as we have said elsewhere, it is most probable that heparin is predominantly, if not exclusively, synthesized by the MCs and does not reach them ready-made from the outside.

More direct evidence of a relationship between MCs and the RES is obtained from experiments in which colloidal carbon or iron is administered i.v. concurrently with an MC-discharger. Here, the blood-borne particles precipitate in the immediate vicinity of MCs wherever the latter discharge their granules. In discussing calciphylaxis and calcergy, we have already mentioned similar instances of mastopexis in which calcium salts are thus localized around degranulating MCs. Cyproheptadine (an antihistamine and anti-5–HT agent) prevents all these forms of mastopexis without influencing MC discharge. Hence, it acts presumably by blocking the effect of MC products.

Törö D33,638/42: If histamine is applied to the shaved skin of the rat, there is local storage of carbon particles in the endothelium of the small vessels. Hence, the ink granules are taken up by the pericytes. The regional MCs "first disappear and later reappear without

granules. Sometimes they are laden with India Ink. Since, in the rat, the MCs form a perivascular sheath and undergo pronounced changes, they may play an important role in vascular function. We did not succeed in obtaining a clear picture of this process."

Antalóczy D26,874/55: Following a review of the literature concerning the relationships between the MCs and the RES, the former are considered to be essentially heparin-storing RES cells, although it is admitted that they may also synthesize heparin. It had previously been shown that heparin inhibits the phagocytic power of RES and that is probably why MCs normally do not phagocytose.

Selye et al. D24,159/63: If the MC-discharger, polymyxin, is given s.c., simultaneously with India ink i.v., the carbon particles localize particularly in a halo around the polymyxin injection site, "perhaps because mastocyte material can fix blood-borne particles by increasing the adhesiveness of tissue." If the polymyxin is given somewhat prior to the India ink, there is no local fixation of carbon in the subcutis, but numerous pulmonary capillaries are occluded by thrombi which contain aggregates of India ink. Here, the discharged MC granules may have already been carried from the polymyxin injection site to the pulmonary circulation by the time the India ink was introduced into the circulation. It is perhaps for this reason that the carbon particles are fixed in the lung. Ferric oxide saccharate (Fe–OS) i.v. acts essentially like India ink in this experimental arrangement. Repeated i.v. injections of Fe–OS produce heavy iron precipitation in the choledochus and duodenum; this results in extreme dilatation of the bile ducts and duodenal ulcer-formation in the heavily-ferrified areas. Here again, the iron particles precipitate predominantly in the immediate vicinity of the MCs which are particularly numerous in the extrahepatic bile ducts and duodenum of the rat. Pretreatment with a MC-discharger protects against these effects of Fe–OS. These models show how through mastopexis the MCs can participate in the localization of pathogens, drugs, and particularly pigments. (*Fig. 14, p.* 182.)

Gabbiani & Nielsen G11,130/64: In rats given ferric dextran i.v., polymyxin s.c. causes local iron fixation in the discharged MC granules with subsequent anaphylactoid inflammation. Cyproheptadine prevents the mastopexis of iron without influencing MC discharge. (*Plate V.*)

ENZYMES

(Cf. also HISTOCHEMISTRY, *p.* 50 and BIOCHEMISTRY, *p.* 325.)

The presence in MCs of numerous enzymes has been clearly demonstrated both by histochemical and by conventional chemical means. These enzymes may not only regulate the activities of the MCs themselves but also affect adjacent tissues; yet up to now, the role of enzymes after they are released from the MCs has received little attention.

Paton D39,576/58: Attention is called to the fact that in addition to heparin, histamine, and 5–HT, the MCs also contain phosphatase, succinoxidase, phosphoramidase, histidine decarboxylase, and an enzyme-resembling chymotrypsin. "It is therefore misleading to think of the mast cells solely as reservoirs of histamine and heparin. Indeed, the possibility cannot be excluded yet that their histamine content is incidental to some other more important function."

Benditt & Arase D26,709/59: The peritoneal MCs of the rat contain an enzyme which hydrolyzes 3-chloroacetoxy-2-naphthoic acid anilide, which possesses properties similar to those of chymotrypsin. "This constituent of mast cells must rank in functional importance with heparin, histamine, and the other potent agents now identified in these cells."

Benditt & Lagunoff G10,074/64: Discussion.

GASTRIC SECRETION

The MC population of the gastric mucosa is comparatively dense and it is tempting to speculate on the part these cells may play in stimulating gastric secretion through the liberation of histamine. The increase in gastric secretion induced by ACTH, glucocorticoids, and 48/80 has been thought to result from the MC-degranulating action of these agents.

Kraft & Kirsner D33,708/60: "The possible role of mast cells in gastric secretion must be considered in view of their high histamine content and proximity to gastric parietal cells."

Räsänen D33,725/61: Since ACTH causes degranulation of the gastric MCs in intact but not in adrenalectomized rats, it is assumed that the stimulating effect of ACTH and glucocorticoids upon gastric secretion is mediated by histamine discharge from the gastric MCs.

Räsänen E94,505/61: On the basis of morphologic studies concerning the degranulation and regranulation of MCs under various conditions, it is assumed that the MCs play an important part in regulating the secretory function of the stomach.

Räsänen E22,623/63: Heparin liberated from degranulating MCs is considered to be a factor in reducing mitotic frequency in the gastric mucosa of rats exposed to stress, ACTH, or glucocorticoids.

Thompson et al. E39,861/63: 48/80 and many other gastric secretory stimulants (except exogenous histamine) caused degranulation of the gastric MCs, simultaneously with a decrease in their total count. This degranulation and loss of gastric MCs was prevented by heparin i.v., which also inhibits the secretagogue effect. It is postulated that the local MCs may be responsible for gastric secretion.

Thompson et al. F3,698/64: In dogs, heparin i.v. inhibits the increase in gastric secretion normally elicited by food ingestion. The gastric MCs are viewed as the source of the histamine that stimulates gastric secretion and it is postulated that heparin may bind this histamine. "A meat meal causes degranulation of significant number of gastric mast cells. This degranulation is prevented by i.v. heparin and may be the mechanism for heparin inhibition of gastric secretion."

Zeppa et al. F14,725/64: Gastrin causes histamine release from rat peritoneal MCs in vitro. It is assumed "that histamine release by gastrin is of sufficient magnitude to be involved in the mechanism of gastric secretion."

SWEAT SECRETION

Although MCs tend to accumulate in the vicinity of sweat glands, there is no reason to believe that they affect the secretion of the latter.

Szabó & Mészáros F14,221/64: In psoriasis, as in some other inflammatory diseases of the skin, the cutaneous MC density is increased. This increase is more evident in acute than in chronic cases of psoriasis and is most pronounced in the vicinity of sweat glands. There is a positive correlation between the density of MCs around sweat glands and the amount of acid mucopolysaccharide contained in the sweat-gland lumina. It is assumed that the MCs play a role in the pathogenesis of psoriasis and they may also participate in sweat secretion.

VARIOUS OTHER THEORIES

The possibility that MCs may specifically affect other functions (iron metabolism, hemopoiesis, the sexual cycle, aging, hibernation, tissue respiration, hyaline metabolism, the Shwartzman-Sanarelli phenomenon, *pH*-regulation, vitamin metabolism, and intestinal activity) has been considered, but there is far too little evidence in support of these theories to warrant their detailed evaluation at present.

Various — Iron metabolism

Spicer D58,289/63: MCs are particularly numerous in the vicinity of siderophages and lipophages in various tissue (lymph nodes, uterus, mammary gland, stomach, and intestine) of various species (mouse, rat, hamster, guinea-pig, rabbit).

Hemopoiesis

Messerschmitt D26,636/55: Since the bone-marrow MCs are frequently increased in patients following repeated hemorrhages, the possibility is considered that there may be some relationship between MCs and hemopoiesis.

Sexual cycle

Vara D39,825/62: The MCs of the human endometrium undergo cyclic variations, with a discharge of their granules just premenstrually and a gradual regeneration during the rest of the cycle. It is assumed that the MCs may play a role in making menstrual blood uncoagulable.

Aging

Spicer C92,580/60: MCs and siderophages are increased in the lymph-node hili of aged mice (*Dunn* D27,626/54). Siderosis, with increased lipofuscins in macrophages, closely associated with MC accumulation, has also been seen in other tissues of aged mice.

Guidotti & Spinelli-Ressi G11,021/64: The incorporation of labeled sulfate in vitro into peritoneal MCs is faster in young than in adult rats. This difference is ascribed to changes characteristic of senescence.

Hibernation

Michels D65,511/23: MCs disappear from the digestive tract of certain animals during hibernation. Therefore, they may be correlated with nutrition.

Tissue respiration

Michels D65,511/23: Since MCs are frequently grouped near capillaries, they may be correlated with the respiratory processes.

Hyaline metabolism

Luchsinger y Centeno D30,203/27: Numerous MCs are found in hyalinized portions of human mammary glands. It is postulated that the MCs may play a part in the removal of hyalin.

The Shwartzman-Sanarelli phenomenon

Gustafson & Cronberg D61,874/63: Topical treatment with bacterial endotoxins causes little, if any, MC degranulation in the peritoneum of the rat and hamster, or in the cheek pouch of the hamster. Topical disruption of the MCs by distilled water fails to prevent the local production of a Shwartzman phenomenon by bacterial endotoxins. "It is concluded that mast cell alterations do not seem to be an essential or a primary effect in endotoxin reactions."

Intestinal activity

Astaldi et al. G19,343/64: As judged by biopsy specimens, MCs are constantly present in the submucosa of the human jejunum, while in the tunica propria they lose their granules and may no longer be demonstrable during digestion. It is assumed that the MCs participate in the regulation of intestinal activity.

p*H regulation*

Caselli & Schumacher D33,666/58: The metachromatic staining ability of heparin solutions and of rat peritoneal MCs is blocked by various basic proteins. Mast-cell granules do not stain even orthochromatically at a neutral *p*H with basic dyes after such exposure. Apparently, the acid polysaccharides of heparin and of MC granules form complexes with the proteins and such complex formation is held responsible for the well-known "disappearance of MCs" in edema, inflammation, and various intoxications. It is thought that the MCs may exert a buffer effect with regards to the tissue concentration in electro-positive substances.

Vitamin metabolism

Tuma D27,638/28: The MCs of rats kept on a diet deficient in several vitamins, show severe structural alterations. "It must be assumed that the mastocytes of the rat probably play an important role in the metabolism of vitamins and, indeed, may act as depots for these substances in the organism."

11

Overview

Now that we have carefully analyzed the entire world literature concerned with the MCs ever since their discovery about a century ago, it is tempting to sketch a brief overview of this vast field that has been reported at such length in the 402 pages of text and 82 pages of bibliography of this monograph. How can we define this cell? What are its chief structural and chemical characteristics? What might be its role in health and disease? What have we learned about ways to influence it at will?

As far as it is possible to define a constantly changing biologic structure such as a cell, we consider the MC to be a connective-tissue element which possesses cytoplasmic granules that stain metachromatically under ordinary conditions. Thus, we separate the MC from epithelial elements containing metachromatically staining granules of mucus and even from the closely related blood basophils which are myelogenous. Yet, by specifying that the staining must occur only under "ordinary conditions," we include immature neoplastic and discharged true MCs even if their metachromasia is abolished under the influence of unusual circumstances. On the other hand, our definition excludes cells which merely phagocytose metachromatic foreign material or become metachromatic as a result of abnormal histochemical manipulations.

The MC is a protean cell which exhibits great variations in form, depending upon species differences in its development and upon adaptive responses to its surroundings: it can be small or large, packed with granules or completely degranulated, round, oval, fusiform and indeed, in certain species, it may develop long branching pseudopodia which give it a glia- or nerve-cell-like appearance.

The main function of the MC appears to be the production of heparin, histamine and, at least in certain species, of 5–HT. The cell also produces a great variety of enzymes which can be demonstrated by histochemical and conventional chemical methods. Several of these enzymes are undoubtedly concerned with the internal function of the MC itself — such as the synthesis and discharge of biologically active compounds — but there is reason to suspect that at least some of the MC-enzymes are elaborated in order to influence adjacent tissues.

More recently, we have learned that, through the process of "mastopexis" or "mastocytopexis," the MCs can fix blood-borne substances such as calcium, phosphorus, etc. This process is particularly evident in calciphylaxis and calcergy.

Evidently, the MC is a pluripotent cell, a kind of "emergency kit" which contains a number of compounds that tissues may need, especially in regions exposed to local stress. Thus, under the influence of nonspecific local stressors, the MCs may help to produce an inflammatory edema which dilutes, quarantines, and eventually inactivates the irritant. Histamine liberation may play a role here by

promoting edema formation, improving the local blood supply and, perhaps, even by enhancing the topical fixation, phagocytosis, and subsequent detoxification of blood-borne substances. 5–HT may act in a rather similar manner, whereas heparin would help to prevent blood-clotting. For technical reasons, the intracellular synthesis of hyaluronic acid is more difficult to prove, but if this compound is manufactured by MCs, it may assist in the production of the connective tissue necessary for granuloma formation and wound healing.

From what we have said, it is already evident that the MCs are called upon to play important roles in health and disease. The most characteristic morbid lesions that can be traced to MCs are the mastocytoses of man and the mastocytomas of animals. Important changes in the MC-population have also been noted in various dermatoses, collagenoses, allergies, and anaphylactic reactions both in man and experimental animals; however, here, it is difficult to decide whether the observed MC-changes are the cause or the result of the morbid lesions.

Despite its somewhat different morphologic structure and its myelogenous origin, the blood basophil resembles the MC in many respects, especially in that it forms metachromatic granules which apparently contain heparin and histamine. Hence, what we have said about tissue MCs is largely applicable also to blood basophils. In pathology, the importance of these "blood mast cells" is especially evident in the various forms of basophil leukemias but they probably also play a decisive part in certain allergic reactions.

A great deal of evidence has accumulated concerning the ability of various agents to discharge MCs (e.g., histamine dischargers), to prevent this discharge, or to block the effect of the discharge by neutralizing the action of certain MC products (e.g., antiheparins, antihistaminics, antiserotonins).

It must be admitted that we are still far from having solved the famous "riddle of the mast cells." Indeed, we are just beginning to have enough well-established facts to start planned systematic work without having to rely too much upon chance observations. For this purpose, we must build upon what is already known and create easy access to it. This is what we have attempted to do in this book, through the "analytico-synthetic style" which facilitates fact-finding and strictly separates the objective, concise reports of previously published data from the authors' evaluation of them. In guiding our own experimental work, we have found this form of literature survey very helpful and it is hoped that others will also derive benefit from it.

BIBLIOGRAPHY

Bibliography

Abramovitz, ?: Urticaria pigmentosa. *A.M.A. Arch. Derm. Syph. (Chic.),* **3,** 331 (1921). [E37986

Ackerman, G. A.: Cytochemical properties of the blood basophilic granulocyte. *Ann. N. Y. Acad. Sci.,* **103,** 376 (1963). [D58292

—— and **Bellios, N. C.:** A study of the morphology of the living cells of blood and bone marrow in vital films with the phase contrast microscope. I. Normal blood and bone marrow. *Blood,* **10,** 3 (1955). [D20145

Adamkiewicz, V. W. and **Langlois Y. L.:** Insulin, mast cell components and "anaphylactoid" reaction. *Canad. J. Biochem.,* **36,** 483 (1958). [C51916

Adams, J. P. and **Paff, G. H.:** The peritoneal mast cell as a contributor to hemoconia. *Anat. Rec.,* **144,** 19 (1962). [D33746

Adams-Ray J.: Mast cells and monoamines. *Experientia (Basel),* **20,** 80 (1964). [E37378

—— and **Nordenstam, H.:** Un système de cellules chromaffines dans la peau humaine. *Lyon chir.,* **52,** 125 (1956). [D26474

Adamson, H. G.: Case of urticaria pigmentosa. *Proc. Roy. Soc. Med.,* **1,** 63 (1908). [E38164

——: Urticaria pigmentosa. *Brit. J. Derm.,* **20,** 127 (1908). [E37591

——: Generalized lentiginous pigmentation in an adult; (?) adult urticaria pigmentosa. *Proc. Roy. Soc. Med.,* **7,** 104 (1914). [D71842

Adler, F. S.: Über pigmentierte Urticaria. *Dermat. Ztschr.,* **21,** 761 (1914). [G2051

Agostini, A.: La mastocitosi cutanea e una reticolo-istiocitosi? Considerazioni istologico-cliniche a proposito di un caso di Urticaria pigmentosa sine pigmentatione. *Dermosifilografo,* **22,** 151 (1947). [D39788

Ahlqvist, J.: Liver mast cell counts during development of cirrhosis of the liver in rats on a low protein, high fat diet. *Acta path. microbiol. scand.,* sup. 142, **50,** 1 (1960). [D26622

Albanus, L. and **Winqvist, G.:** Basophils, eosinophils and histamine in the bone marrow of the guinea pig. *Acta haemat. (Basel),* **26,** 365 (1961). [D91881

Alder, A.: Über klinisches Verhalten und diagnostische Bedeutung der basophilen Leukozyten. (Mastzellen). *Folia haemat.,* **28,** 249 (1922–23). [D27431

Alfejew, S.: Die embryonale Histogenese der Zellformen des lockeren Bindegewebes der Säugetiere. *Folia haemat.,* **30,** 111 (1924). [D27415

Al-Hussaini, A. H., *cf.* al-Hussaini, A. H. [D27614

Ali, M. Y.: Distribution of mast cells in the mucous membrane of the human nasopharynx. *Experientia (Basel),* **20,** 254 (1964). [G14207

Allara, E.: Le mastzellen nel timo del riccio ibernante. *Boll. Soc. ital. Biol. sper.,* **35,** 264 (1959). [C68999

Allegra, F.: Le mastocitosi dell' uomo. *Arch. ital. Derm.,* **30,** 238 (1960). [D27514

Allen, A. M.: Two methods for coloring mast cells of mammalian tissues. *Amer. J. clin. Path.,* **33,** 461 (1960). [D92603

——: The occurrence and demonstration of spontaneous and experimentally-induced mitosis in mast cells of the rat. *Thesis, University of Wisconsin* (1961). [D61513

——: Mitosis in mast cells of a rat. *Anat. Rec.* **139,** 13 (1961). [D61514

——: Mitosis and binucleation in mast cells of the rat. *J. nat. Cancer Inst.,* **28,** 1125 (1962). [E94053

——: Deoxyribonucleic acid synthesis and mitosis in mast cells of the rat. *Lab. Invest.,* **2,** 188 (1962). [D26855

Alnikow, G. P.: On the role of basophils in physiological conditions. [Russian text]. *Probl. Gemat.,* **7,** 33 (1962). [D7621

Alonzo, M. and **Cilento, A.:** Sulla reazione mesenchimale provocata negli apparati digerente ed urinario dalla somministrazione di cortisonici. *G. ital. Chir.,* **16,** 985 (1960). [D26832

Amann, R.: Zur Physiologie und Biochemie der Mastzellen. *Arch. klin. exp. Dermat.,* **213,** 565 (1961). [D12406

——: Histochemischer Schwermetallnachweis in Blut- und Gewebsmastzellen, *Proc. 8th Congr. Europ. Soc. Haematol.,* Part 1, sect. 18 (1962). [E37264

—— and **Martin, H.:** Blutmastzellen und Heparin. *Acta haemat.,* **25,** 209 (1961). [D26616

—— and **Werle, E.**: Über Komplexe von Heparin mit Histamin und anderen Di- und Polyaminen. *Klin. Wchnschr.*, **34**, 207 (1956). [D31582
—— and **Wolff, H. P.**: Schwermetalle in Leukocyten. *Ztschr. gesamt. exp. Med.*, **127**, 281 (1956). [E35029
Anbo, F.: Clinical and experimental studies on the basophilic leucocyte in peripheral blood. [Japanese text]. *Fukuota Acta med.*, **50**, 2884 (1959). [D9261
Angeli, G., Tedeschi, G. and **Cavazzuti, F.**: Studio sul comportamento dei basofili ematici in soggetti di età avanzata. *Acta geront. (Milano)*, **5**, 28 (1955). [D69546
——; ——, and ——: Il tasso dei basofili del sangue periferico nel soggeto normale, valuto con un nuovo metodo di conta diretta. *Progr. med. (Napoli)*, **10**, 742 (1955). [E41475
——; —— and ——: Sulle variazioni del tasso dei leucociti basofili del sangue periferico dopo somministrazione de eparina. *Minerva med.*, **46**, 752 (1955). [E94909
——; —— and ——: I granulociti basofili intervengono nel metabolismo dei mucopolisaccaridi. *Comm. Congr. Ital. Mal. Ricambio, Milano* (1958). [G17550
Änggård, E., Bergzvist, U., Högberg, B., Johansson, K., Thon, I. L., and **Uvnäs, B.** Biologically active principles occurring on histamine release from cat paw, guinea pig lung and isolated rat mast cells. *Acta physiol. scand.*, **59**, 97 (1963). [D32256
Anonymous: Mast cells. *Brit. med. J.*, July 28, 219 (1956). [C20841
——: A guide to the literature on heparin and anticoagulant therapy in thrombosis. I. Covering the period up to July 1, 1958. Stockholm: *Nordiska Bokhandeln* (1959). [E4459
——: Blood coagulation. Modern concepts of the mechanism of haemostasis. *Vet. Rec.*, **72**, 450 (1960). [D29286
——: Urticaria pigmentosa: systemic mastocytosis. *J. Amer. med. Ass.*, **184**, 1037 (1963). [D69591
——: Unmasking of the mast cell. *J. Amer. med. Ass.*, **187**, 362 (1964). [F614
Antalóczy, Z.: Ueber die retikulo-endothelialen Beziehungen der Mastzellen. *Ztschr. gesamt. inn. Med.*, **10**, 443 (1955). [D26874
Antweiler, H.: Mastzellen und Histamin nach Injektion von Staubsuspensionen. *Arch. Gewerbepathol. Gewerbehyg.*, **16**, 607 (1959). [D33672
——: Eine einfache Methode zur Herstellung von tierischen Häutchenpräparaten für physiologisch-pharmakologische Untersuchungen und zur Mikroskopie (Mastzelldarstellung). *Arzneimittel-Forschg.*, **11**, 323 (1961). [D39651
——: Phenylbutazon, Mastzellen und Histaminfreisetzung, *Zschr. gesamt. exp. Med.*, **136**, 42-51 (1962). [D39512
——: Resistenzzunahme von Mastzellen gegenüber dem Histamin-liberator 48/80 durch Polyvinylpyridin-N-Oxid. *Naturwschft.*, **50**, 234 (1963). [D64030
—— and **Hirsch, E.**: Zur Frage einer akuten Mastzellschädigung und Histaminfreisetzung durch Endotoxine. *Naunyn-Schmiedeberg's Arch. exp. Pathol. Pharmak.*, **241**, 213 (1961). [D26707
Archer, G. T.: Release of histamine from mast cells by tissue extracts. *Nature (Lond.)*, **182**, 726 (1958). [D27393
——: The release of histamine from the mast cells of the rat. *Austral. J. exp. Biol. med. Sci.*, **37**, 383 (1959). [D26626
——: Release of histamine from rat mast cells by blood treated with dextran. *Nature (Lond.)*, **184**, 1151 (1959). [C78034
——: Release of histamine from mast cells by antigen-antibody reactions in vitro. *Austral. J. exp. Biol. med. Sci.*, **38**, 147 (1960). [D26625
——: Release of heparin from the mast cells of the rat. *Nature (Lond.)*, **191**, 90 (1961). [D26441
——: Release of 5-hydroxytryptamine from rat mast cells in vitro. *Nature (Lond.)*, **190**, 350 (1961). [D26443
——: The immediate and delayed skin reaction. *Australian J. Dermat.*, **6**, 5 (1961). [D16849
Archer, R. K., Feldberg, W., and **Kovacs, B. A.**: Antihistamine activity in extracts of horse eosinophils. *Brit. J. Pharmacol.*, **18**, 101 (1962). [D37484
Arey, L. B.: *Developmental Anatomy*. Philadelphia & London: W. B. Saunders Co., 6th Ed. (1954). [E4225
Argaud, R., and **Pesqué, M.**: Sur la pullulation des mastzellen dans le thymus des diphtériques. *Compt. rend. Soc. biol. (Paris)*, **100**, 833 (1929). [90375
Arneth, F.: Ueber das Mastzellenblutbild. *Berl. klin. Wchnschr.*, **57**, 109 (1920). [D63797
Arnold, J.: Ueber die Granula der oesinophilen Zellen und der Mastzellen. *Ztrbl. allg. Pathol. pathol. Anat.*, **24**, 673 (1913). [D29582
——: Ueber Granula-Färbung lebender und überlebender Gewebe. *Virchows Arch. pathol. Anat.*, **159**, 101 (1900). [D30521

——: Weitere Mitteilungen über vitale und supravitale Granulafärbung (Epithelien, Endothelien, Bindegewebszellen, Mastzellen, Leukocyten, Gefässe, glatte Muskelfasern). *Anat. Anzgr.*, **24**, 1 (1903). [D30522

——: Zur Morphologie und Biologie der Mastzellen, Leukozyten und Lymphozyten. *Münch. med. Wchnschr.*, **53**, 585 (1906). [D27305

Arsdel, P. P. Van, and **Bray, R. E.:** On the release of histamine from rat peritoneal mast cell by compound 48/80: effects of metabolic inhibitors. *J. Pharmacol. exp. Ther.*, **133**, 319 (1961). [D26617

Arvy, L.: Les labrocytes (Mastzellen). *Rev. Hémat.*, **10**, 55 (1955). [D26724

——: Effect of injections of oestrogen on the mast cells of the white mouse. *Nature (Lond.)*, **175**, 506 (1955). [C9738

——: Caractères histologiques et réactions des labrocytes linguaux chez Rana esculenta. Modifications de ces éléments sous l'action d'un libérateur d'histamine. *C. R. Soc. Biol. (Paris)*, **149**, 528 (1955). [D65694

——: Particularités histologiques des labrocytes chez quelques batraciens. *C. R. Ass. Anat., 42nd Meet. Paris, July 1955*, p. 217 (1956). [C41778

——: Les labrocytes, l'héparine et l'histamine. *Ann. biol.*, **32**, 169 (1956). [D65673

——: Comparaison des actions du chlorure de sinoménine et d'un dérivé de la méthylamine sur les labrocytes chez le rat. *C. R. Acad. Sci. (Paris)*, **243**, 1442 (1956). [C41782

——: Action de doses répétées d'un dérivé de la méthylamine sur la richesse du tissu conjonctif et des ganglions lymphatiques en labrocytes chez le rat. *C. R. Soc. biol. (Paris)*, **150**, 2071 (1956). [D27873

——: Histogénèse et répartition des labrocytes chez le rat. *C. R. Ass. Anat., 43rd Meet., Lisbon Mar. 1956*, p. 165 (1957). [C41780

——: Les labrocytes chez Protopterus annectens Owen. *C. R. Ass. Anat.*, **44**, 100 (1958). [D65058

——: Les ganglions lymphatiques et les libérateurs d'histamine. *C. R. Ass. Anat.*, **44**, 107 (1958). [D65087

——: Etude comparée des labrocytes chez les téléostéens, les batraciens, les reptiles et les mammifères. *C. R. 8e Congr. Soc. europ. Hémat., Vienne 1961*, p. 86 (1962). [E37387

——: Les variations expérimentales et physiopathologiques des labrocytes. *C. R. 8e Congr. Soc. europ. Hémat., Vienne 1961*, p. 86a (1962). [E25129

——, **Boiffard, J. A.,** and **Gabe, M.:** Augmentation du nombre des labrocytes dans les organes hématopoiétiques de la souris après irradiation par les rayons X. *C. R. Soc. Biol. (Paris)*, **232**, 1022 (1951). [B62607

——, ——, and ——: Déterminisme de la labrocytose provoquée par les rayons X dans les organes lymphoïdes de la souris. *C. R. Soc. Biol. (Paris)*, **146**, 1537 (1952). [D26834

——, ——, and ——: Action des rayons X sur les labrocytes chez la souris et le rat albinos. *Rev. Hémat.*, **9**, 454 (1954). [D26704

——, ——, and ——: Action des irradiations localisées par les rayons X émis sous une tension de 15kV sur les labrocytes chez la souris albinos. *C. R. Soc. Biol. (Paris)*, **148**, 1189 (1954). [D26833

——, **Debray, C.,** and **Gabe, M.:** Action de la thiourée sur l'appareil digestif du rat albinos. *Arch. Mal. Appar. dig.*, **39**, 942 (1950). [D31614

——, and **Gabe, M.:** Les modifications de l'hématopoïèse du rat albinos au cours de l'intoxication alloxannique aigüe. *Rev. Hémat.*, **4**, 519 (1949). [B44853

——, and ——: Augmentation du nombre des labrocytes chez le rat albinos après administration de thiourée. *Experientia (Basel)*, **6**, 23 (1950). [B50130

——, **Halpern, B. N.,** and **Neveu, T.:** Modifications morphologiques des labrocytes et corrélations avec la mise en liberté de l'histamine endogène après injection d'une butylamine substitutive (1935L) douée de propriétés histamino-libératrices chez le rat. *C. R. Soc. Biol. (Paris)*, **150**, 2074 (1956). [C41781

——, and **Quivy, D.:** Données sur la répartition des labrocytes chez le chien. *C. R. Ass. Anat.*, **42**, 234 (1955). [D27966

——, and ——: Taux des labrocytes linguaux et coagulabilité sanguine chez le chien au cours de divers chocs. *C. R. Soc. Biol. (Paris)*, **149**, 481 (1955). [D99937

——, and ——: Relation entre la richesse en labrocytes et la teneur en histamine des divers segments du tube digestif chez le chien. *C. R. Soc. Biol. (Paris)*, **149**, 658 (1955). [D27872

Asano, M., Ogawa S., and **Hirokawa, A.:** Influence of tobacco smoking on circulating leucocytes. *Bull. Inst. Public Health*, **11**, 68 (1962). [D55974

Asboe-Hansen, G.: La 'mastzelle' facteur important dans la formation de la substance

fondamentale conjonctive et de la synovie. *Bull. Histol. Techn. micr.,* **27,** 5 (1950). [B60548

——: The intercellular substance of the connective tissue in myxedema. *J. invest. Dermat.,* **15,** 25 (1950). [B60602

——: The origin of synovial mucin. Ehrlich's mast cell: secretory element of the connective tissue. *Ann. rheum. Dis.,* **9,** 149 (1950). [B60550

——: Urticaria pigmentosa haemorrhagica. *Acta derm.-venereol. (Stockh.),* **30,** 159 (1950). [D39743

——: The variability in the hyaluronic acid content of the dermal connective tissue under the influence of thyroid hormone. *Acta derm.-venereol. (Stockh.),* **30,** 221 (1950). [D26784

——: Effect of the adrenocorticotropic hormone of the pituitary on mesenchymal tissues. *Scand. J. clin. Lab. Invest.,* **2,** 271 (1950). [B59548

——: A survey of the normal and pathological occurrence of mucinous substance and mast cells in the dermal connective tissue in man. *Acta derm.-venereol. (Stockh.),* **30,** 338 (1950). [D26785

——: *Om Bindevaevets Mucinse Substanser.* Copenhagen: Rosenkilde & Baggers (1951). [B60604

——: The mast cell an object of cortisone action on connective tissue. *Proc. Soc. exp. Biol. (N.Y.),* **80,** 677 (1952). [B74068

——: Urticaria pigmentosa with bone lesions. *Acta derm.-venereol. (Stockh.),* **33,** 471 (1953). [D31588

——: Autoradiography of mast cells in experimental skin tumors of mice injected with radioactive sulfur (S^{35}), *Cancer Res.,* **13,** 587 (1953). [B85960

——: Autoradiographic evidence of cortisone action on mast cells in experimental skin tumors. *Cancer Res.,* **14,** 94 (1954). [B91127

——: Hormonal effects on connective tissues. In: *Connective tissues. Trans. 5th Conf., Princeton Feb. 1954.* New York: Josiah Macy Jr. Found., p. 123 (1954). [C1756

——: The mast cell. *Int. Rev. Cytol.,* **3,** 399 (1954). [D27999

——: On the structure and functions of the mast cell. In: *Connective tissue. A symposium.* Charles C Thomas Publ., Springfield, p. 12 (1957). [C77655

——: Endocrine control of connective tissue. *Am. J. Med.,* **26,** 470 (1959). [C65350

——: Urticaria pigmentosa with generalized tissue mastocytosis and blood basophilia. *A.M.A. Arch. Dermat.,* **81,** 198 (1960). [D26742

——: Mechanism of steroid inhibition of connective tissue growth. In: *Mills et al., Inflammation and diseases of connective tissue.* Philadelphia, London: W. B. Saunders Co., p. 460 (1961). [D7843

——: Bullous diffuse mastocytosis with urinary hyaluronate excretion. Treatment with cyproheptadine. *Acta derm.-venereol. (Stockh.),* **42,** 211 (1962). [E99822

——: Urticaria pigmentosa and generalized mastocytosis. *A.M.A. Arch. Dermat.,* **83,** 893 (1961). [D26650

——: Connective tissue. *Ann. Rev. Physiol.,* **25,** 41 (1963). [G2134

——: Dermatologic aspects of mast cell activity. *Dermatologica (Basel),* **128,** 51 (1964). [G13573

——, and **Clausen, J.**: Urinary excretion of acid mucopolysaccharides in twelve cases of mastocytosis (urticaria pigmentosa). *J. invest. Derm.,* **42,** 81 (1964). [F16673

——, and ——: Mastocytosis (urticaria pigmentosa) with urinary excretion of hyaluronic acid and chondroitin sulfuric acid. Changes induced by polymyxin B. *Amer. J. Med.,* **36,** 144 (1964). [E37788

——, and **Glick, D.**: Influence of various agents on mast cells isolated from rat peritoneal fluid. *Proc. Soc. exp. Biol. (N.Y.),* **98,** 458 (1958). [C56235

——, and **Iversen, K.**: Influence of thyrotrophic hormone on connective tissue. Pathogenetic significance of mucopolysaccharides in experimental exophthalmos. *Acta endocr. (Kbh.),* **8,** 90 (1951). [B62207

——, and **Kaalund-Jorgensen, O.**: Systemic mast cell disease involving skin, liver, bone marrow and blood, associated with disseminated xanthomata. *Acta haematol. (Basel),* **16,** 273 (1956). [C25899

——, and **Levi, H.**: S^{35} autoradiographic studies on sulfomucopolysaccharides in the connective tissue of induced skin tumors in mice and Rous's fowl sarcoma I. *Lab. Invest.,* **8,** 251 (1959). [D78274

——, and ——: Mitotic division of tissue mast cells as indicated by the uptake of tritiated thymidine. *Acta path. microbiol. scand.,* **56,** 241 (1962). [D39755

——, ——, and **Wegelius, O.**: Mast cells and intercellular mucopolysaccharides in Rous fowl sarcoma I. *Cancer Res.,* **17,** 792 (1957). [C61920

——, and **Wegelius, O.**: Serotonin and connective tissue. *Nature (Lond.)*, **178**, 262 (1956). [C25969
——, and ——: Histamine and mast cells. Studies on living connective tissue in the hamster cheek pouch. *Acta physiol. scand.*, **37**, 350 (1956). [C29324
——, and ——: Mast cells and histamine. *Acta derm.-venereol. (Stockh.)*, **2**, 164 (1957). [C73310
——, and **Zachariae, L.**: Mast-cell changes induced by hydrocortisone acetate in experimental skin papillomas in mice. *Acta path. microbiol. scand.*, **37**, 145 (1955). [C10677
Aschkenasy, A.: Quelques données récentes sur le rôle physiologique des éosinophiles. *Bull. Soc. Pathol. exot.*, **55**, 499 (1962). [D68599
Aspegren, N., Fregert S., and **Rorsman, H.**: Basophil leukocytes in lesions of various dermatoses. *Acta derm.-venerol. (Stockh.)*. **43**, 544 (1963). [E97750
——, ——, and ——: Basophil leukocytes in non-vesicular allergic patch, test reactions. *J. invest. Derm.*, **41**, 107 (1963). [E28353
——, ——, and ——: Basophil leukocytes in allergic eczematous contact dermatitis. *Int. Arch. Allergy*, **23**, 150 (1963). [D92280
——, ——, and ——: Basophil leukocytes at sites of intracutaneous tuberculin test reactions. *Int. Arch. Allergy*, **24**, 95 (1964). [E50794
Asplund, J., Borell, U., and **Holmgren, H.**: Untersuchungen über die Speicherung des Heparins im Tierorganismus sowie über seine Resorptionsmöglichkeiten in Darm und Placenta. *Ztschr. mikros. anat. Forschg.*, **46**, 16 (1939). [D28695
——, ——, and ——: In der Uteruswand während der Gravidität auftretende metachromatisch granulierte Zelleverbände und ihre Stellung zur 'Glandula myometralis'. *Ztschr. mikros. anat. Forschg.*, **48**, 478 (1940). [D15852
——, and **Holmgren, H.**: On the occurrence of metachromatically granulated cells in the mucous membrane of the human uterus. *Acta anat. (Basel)*, **3**, 312 (1947). [B17599
Astaldi, G., Airo R., and **Conrad, M. C.**: Ricerche sulle mastcellule della mucosa digiunale umana ottenuta mediante biopsia in soggetti normali. I. Sulla frequenza e sulla distribuzione. *Boll. Soc. ital. Biol. sper.*, **40**, 334 (1964). [G18060
——, ——, and ——: Ricerche sulle mastcellule della mucosa digiunale umana ottenuta mediante biopsia in soggetti normali. II. Aspetti morfologico-funzionali. *Boll. Soc. ital. Biol. sper.*, **40**, 700 (1964). [G19343
——, **Rondanelli, E. G.**, and **Bernardelli, E.**: Recherches cytochimiques sur la moëlle osseuse et le sang d'une leucémie à basocytes. *Rev. Hémat.*, **8**, 105 (1953). [D39707
——, ——, and ——: Ricerche istochimiche sul contenuto dei granuli della mastcellule del midollo osseo umano. *Haematologie*, **38**, 967 (1954). [D39597
Athias, ?., and **França C.**: Sur la présence de "mastzellen" dans les vaisseaux corticaux, chez un paralytique général. *C. R. Soc. Biol. (Paris)*, **53**, 457 (1901). [D27513
Audry, C.: Sur les cellules isoplastiques (mastzellen). *Ann. Derm. Syph. (Paris)*, **7**, 9 (1896). [D27885
——: Über Mastzellen. *Monatsh. prakt. Derm.*, **22**, 393 (1896). [D27714
Aures, D., and **Clark, W. G.**: Inhibition of histidine decarboxylase of mouse mast cell tumor. *Biochem. Pharmacol.*, **12**, sup., 40 (1963). [E27333
——, and ——: A rotating diffusion chamber for $C^{14}O_2$ determination as applied to inhibitor studies on mouse mast cell tumor distidine decarboxylase. *Analyt. Biochem.*, **9**, 35 (1964). [D18341
——, **Hartman, W. J.**, and **Clark, W. G.**: Purification and properties of specific L-histidine decarboxylase. *Fed. Proc.*, **21**, 269 (1962). [G7584
Austen, K. F., and **Humphrey, J. H.**: Mechanism of the anaphylactic release of histamine and slow reacting substance. In: *Mechanism of Cell and Tissue Damage Produced by Immune Reactions.* Basel, Stuttgart: Benno Schwabe & Co. p. 93 (1962). [D44506
Austoni, B.: Sulle reazioni preneoplastiche delle linfoghiandole regionali durante lo sviluppo del carcinoma mammario. *Tumori*, **18**, 31 (1932). [D27062
Aykroyd, O. E., and **Zuckerman, S.**: Factors in sexual-skin oedema. *J. Physiol. (Lond.)*, **94**, 13 (1938). [73722
Ayres, S.: Urticaria pigmentosa. *A.M.A. Arch. Derm. Syph. (Chic.)*, **45**, 187 (1942). [D39581
Azevedo Correia Trincão, R. de, *cf.* Trincão, R. de A.C. [D26962
Baar, H. S., and **Bickel, H.**: Morbid anatomy, histology and pathogenesis of Lignac-Fanconi disease, (Cystine storage disease with aminoaciduria). *Acta paediat. (Uppsala)*, **42**, sup. 90, 171 (1952). [G8963
Bachman, C., Collip, J. B., and **Selye, H.**: The effects of prolonged eostriol administration upon the sex skin of Macaca mulatta. *Proc. Roy. Soc.*, **117**, 16 (1935). [31404

——, ——, and ——: Further studies of sex skin reactions in Macaca mulatta. *Proc. Soc. exp. Biol. (N.Y.),* **33,** 549 (1936). [66256

Bădănoiu, A., Fulga, E., and **Gogoneata, V.:** Einige Beobachtungen über die Reaktionsbereitschaft der Mastzellen bei Urticaria pigmentosa. *Ztrbl. Haut- u. Geschl.-Krht.,* **111,** 295 (1961–62). [G18749

Baeckeland, E.: Influence d'implantats sanguins et fibrineux sur le nombre des mastocytes et tactisme de ces cellules. *C. R. Soc. Biol. (Paris),* **144,** 1005 (1950). [D27744

——: Evolution des mastocytes dans la peau du cobaye à la suite d'implantations sanguines et fibrineuses. *C.R. Soc. Biol. (Paris),* **144,** 1007 (1950). [D27745

——: Modifications morphologiques des mastocytes en raport avec les processus de coagulation. *C.R. Soc. Biol. (Paris),* **156,** 525 (1962). [D30918

——: Culture de mastocytes normaux de mammifères. *C.R. Soc. Biol. (Paris),* **157,** 1819 (1963). [G1481

——: Influence inhibitrice des mastocytes sur la culture de cellules péritonéales libres. *C.R. Soc. Biol. (Paris),* **157,** 1842 (1963). [G2967

——: Effets des ions SO_4^{2-} sur la survie de mastocytes non tumoraux en culture. *C.R. Soc. Biol. (Paris),* **157,** 2342 (1963). [G4532

——: Effets du dextran et du polyvinylpyrrolidone sur les mastocytes normaux cultivés in vitro. *C. R. Soc. Biol. (Paris),* **158,** 904 (1964). [E65987

——, and **Lecomte, J.:** Absence de modifications des mastocytes hépatiques durant le choc peptonique. *C.R. Soc. Biol. (Paris),* **147,** 927 (1953). [D27995

Baer, R. L., and **Yanowitz, M.:** Differential cell counts in the blister fluid of allergic eczematous and irritant bullous lesions. *J. Allergy,* **23,** 95 (1952). [G18943

Baglioni, T.: Studio sulle Mastzellen con particolare riguardo ai sarcomi sperimentali da 3,4-benzopirene. *Tumori,* **30,** 34 (1944). [D26894

——: Ulteriori rilievi sul comportamento delle Mastzellen del ratto. *Tumori,* **38,** 267 (1952). [D28698

——: Le Mastzellen in condizioni normali e patologiche. Problemi ed acquisizioni. *Atti Soc. ital. Sci. vet.,* **8,** 145 (1954). [C16539

——, and **Leonardelli, G. B.:** Le "Mastzellen" nelle rinosinusiti croniche iperplastiche polipoidi. *Arch. ital. Otol.,* **67,** 214 (1956). [D33714

——, and **Lorenzoni, L.:** Le mastzellen nell' adenocarcinoma di Walker nel corso di trattamento con estrogeni. *Tumori,* **41,** 709 (1955). [C15454

Baker, B. L.: Mast cells of the omentum in relation to states of adrenocortical deficiency and excess. *Ann. N.Y. Acad. Sci.,* **56,** 684 (1953–54). [B84820.

——, **Ingle, D. J.,** and **Li, C. H.:** The histology of the lymphoid organs of rats treated with adrenocorticotropin. *Amer. J. Anat.,* **88,** 313 (1951). [B63170

Baker, R., Reaven, G., and **Sawyer, J.:** Effect of toluidine blue on metastatic calcification. *Proc. Soc. Exper. Biol. (N.Y.),* **83,** 281 (1953). [B85053

Baker, S. B. de C., Golberg, L., Martin, L. E., and **Smith, J. P.:** Tissue changes following injection of iron-dextran complex. *J. Path. Bact.,* **82,** 453 (1961). [D14284

Balázs, A., and **Holmgren, H.:** Effect of sulfomucopolysaccharides on growth of tumor tissue. *Proc. Soc. exp. Biol. (N.Y.),* **72,** 142 (1949). [D30635

Balbi, E.: Ricerche intorno alla patogenesi dell'urticaria pigmentosa. *G. ital. Derm. Sif.,* **90,** 82 (1949). [D39846

Bali, T.: Mast cells in neoplasm. *Cancer Res.,* **9,** 553 (1949). [D26611

——, and **Furth, J.:** A transplantable splenic tumor rich in mast cells. Observations on mast cells in varied neoplasms. *Amer. J. Path.,* **25,** 605 (1949). [D10424

Ballantyne, E. N.: Differentiation of plasma cells from mast cells in the intestinal mucosa of the white rat. *Canad. med. Ass. J.,* **21,** 195 (1929). [D27060

Ballowitz, E.: Über das Vorkommen der Ehrlich'schen granulierten Zellen ('Mastzellen') bei winterschlafenden Säugetieren. *Anat. Anzg.,* **6,** 135 (1891). [D27586

Bang, H.: I Tilfaelde af Urticaria pigmentosa. *Ugeskr. Laeg.,* **78,** 1740 (1916). [D45271

Bank, O., and **de Jong, H. G. B.:** Untersuchungen über Metachromasie. *Protoplasma (Wien),* **32,** 489 (1939). [D67712

Bank, S., and **Marks, I. N.:** Malabsorption in systemic mast cell disease. *Gastroenterology,* **45,** 535 (1963). [D35275

Baratta, P. F., Mari, E., Angeli, G., and **Perlini, A.:** Comportamento delle cellule granulose basofile (Mastzellen) nella linfa peritoneale di ratti a dieta ipercolesterolica. *Haematologica,* **37,** 711 (1953). [G1475

Barbano, C.: Die normale Involution der Thymus. *Virchows Arch. pathol. Anat.,* **207,** 1 (1912). [D29284

Barbry, A., and **Langeron, L.:** Influence des fortes doses d'héparine sur la mastocy-

tose de la souris blanche. *C.R. Soc. Biol. (Paris),* **149,** 712 (1955). [D26835
Bargum, ?.: Mastzellen. In: *Ehrlich et al., Enzyklopädie der Färbelehre.* Berlin & Wien: Urban & Schwarzenberg, **2,** 789 (1903). [E20446
Barka, T., and **Anderson, P. J.:** *Histochemistry. Theory, practice, and bibliography.* New York, Evanston, London: Harper & Row, Publ. Inc., Hoeber Medical Division, 1963. [E4491
Barker, L. P.: Urticaria pigmentosa, with possible systemic manifestations. *A.M.A. Arch. Derm.,* **75,** 447 (1957). [D33656
Barlas, O: A propos d'un cas de leucémie chronique à basophiles. *Sang,* **25,** 147 (1954). [G18731
Barlow, R. M.: A tribasic stain for the granules of mast cells. *J. Path. Bact.,* **73,** 272 (1957). [D31600
Baroni, C., and **Casella, E.:** Istopatologia dell'epulide con particolare riguardo alla componente mastocitaria. *Arch. De Vecchi Anat. pat.,* **40,** 283 (1963). [G19160
Barrnett, R. J., Hagen, P., and **Lee, F. L.:** Mast-cell granules, containing 5-hydroxytryptamine, histamine and heparin, morphologically and biochemically distinct from mitochondria. *Biochem. J.,* **69,** 36 P (1958). [D27610
Bartlet, A. L., and **Lockett, M. F.:** Effect of adrenalectomy on tissue histamine in rats. *J. Physiol. (Lond.),* **147,** 51 (1959). [D27074
Bartoli, G.: Ricerche sperimentali sui mastociti 'Mastzellen'. I. Azione del glucosio sui mastociti mesenterici di topo albino. *Monit. zool. ital.,* **49,** 116 (1938). [D39605
——: Osservazioni e considerazioni sulle Mastzellen. *Riv. Anat. pat.,* **10,** 355 (1955–56). [D27055
Bartolini, G., and **Berti, P.:** Le Mastzellen nella tiroide del feto e del neonato. *Riv. Anat. pat.,* **23,** 51 (1963). [E37297
Basserman, F. J.: Über das Vorkommen von Gewebsmastzellen in Bronchialabstrichen. *Klin. Wchnschr.,* **35,** 634 (1956). [G12485
Basset, A., and **Monfort, J.:** Mastocytose généralisée (forme du nourrisson). *Bull. Soc. franç. Derm. Syph.* **63,** 393 (1956). [D39540
Bassett, E. G.: Some observations on mast cells in connective tissue. *Proc. Univ. Otago med. Sch.,* **41,** 5 (1963). [D69353
Bates, E. O.: A quantitative study and interpretation of the occurrence of basophile (mast) cells in the subcutaneous tissue of the albino rat. *Anat. Rec.,* **61,** 231 (1935). [D26774
Battezzati, M.: Sulla presenza di Mastzellen nelle pareti dei vasi arteriosi nelle tromboangioiti obliteranti periferiche. *Inform. med. (Geneva),* **4,** 235 (1950). [B64180
——: Sur la présence des Mastzellen dans la paroi des artères et dans la moelle osseuse dans les thromboangéites. *Presse méd.,* **59,** 1628 (1951). [D31581
Batz, K., Kalberer, F., and **Stähelin, H.:** Aufnahme von Thymidin durch Mastocytomzellen in vitro unter der Einwirkung von Podophyllumstoffen. *Experientia (Basel),* **20,** 524 (1964). [D18542
Bäumer, E.: Beiträge zur Histologie der Urticaria simplex und pigmentosa. *Arch. Dermat. Syph. (Berlin),* **34,** 323 (1896). [D27593
Beare, M.: Urticaria pigmentosa and allied disorders. *Brit. J. Derm.,* **70,** 418 (1958). [D27976
Beatty, W.: Urticaria pigmentosa. *Dublin J. med. Sci.,* **121,** 422 (1906). [E37982
——: A case of adult urticaria pigmentosa. *Brit. J. Derm.,* **33,** 151 (1921). [E37593
Beber, B. A., Landing, B. H., and **Sutherland, J. M.:** Mast cell content of placental tissue. *A.M.A. Arch. Path.,* **69,** 531 (1960). [C85594
Bechet, ?.: Urticaria pigmentosa. *J. cutan. Dis.,* **32,** 511 (1914). [E38136
——: Urticaria pigmentosa. *J. cutan. Dis.,* **34,** 685 (1916). [E38133
Becker, S. W.: Urticaria pigmentosa. *A.M.A. Arch. Derm. Syph. (Chic.),* **69,** 760 (1954). [D39619
Behrens, M., and **Taubert, M.:** Der Nachweis von Heparin in den basophilen Leukocyten. *Klin. Wchnschr.* **30,** 76 (1952). [D30378
Bélanger, L. F.: Autoradiographic visualization of S^{35} incorporation and turnover by the mucous glands of the gastrointestinal tract and other soft tissues of rat and hamster. *Anat. Rec.,* **118,** 755 (1954). [D65099
——, **van Erkel, G. A.,** and **Jakerow, A.:** Behavior of the dermal mast cells in magnesium-deficient rats. *Science,* **126,** 29 (1957). [D26328
Benacchio, G. B.: Gibt es bei Meerschweinchen und Kaninchen Mastmyelozyten und stammen die basophilgekörnten Blutmastzellen aus dem Knochenmark? *Folia haemat.,* **11,** 253 (1911). [D27417
Bendel, W. L., and **Race, G. J.:** Urticaria pigmentosa with bone involvement. *J. Bone Jt. Surg.,* **45–A,** 1043 (1963). [E20636
Bender, O.: Beiträge zur Histologie der Dermatitis exfoliativa nebst einer Bemer-

kung über Plasma- und Mastzellen. *Virchows Arch. pathol. Anat.,* **159,** 86 (1900). [E25130

Benditt, E. P.: The role of the mast cell in the reaction to injury. *Amer. J. Path.,* **30,** 615 (1954). [B95916

——: An enzyme in mast cells with some properties resembling chymotrypsin. *Fed. Proc.,* **15,** 507 (1956). [D28269

——: Morphology, chemistry and function of mast cells. *Ann. N.Y. Acad. Sci.,* **73,** 204 (1958). [C69702

——, and **Arase, M.:** An enzyme in mast cells with properties like chymotrypsin. *J. exp. Med.,* **110,** 451 (1959). [D26709

——, ——, and **Roeper, M. E.:** Histamine and heparin in isolated rat mast cells. *J. Histochem. Cytochem.,* **4,** 419 (1956). [D31573

——, **Bader, S., Arase, M., Corley, C.,** and **Lam, K. B.:** Relationship of mast cells and histamine to mechanism of edema production by ovomucoid in rats. *Fed. Proc. Am. Soc. exper. Biol.,* **13,** 422 (1954). [B91948

——, ——, and **Lam, K. B.:** Studies of the mechanism of acute vascular reactions to injury. I. The relationship of mast cells and histamine to the production of edema by ovomucoid in rats. *A.M.A. Arch. Path.,* **60,** 104 (1955). [C13402

——, and **French, J. E.:** Histochemistry of connective tissue: I. The use of enzymes as specific histochemical reagents. *J. Histochem. Cytochem.,* **1,** 315 (1953). [D31572

——, **Holcenberg, J.,** and **Lagunoff, D.:** The role of serotonin (5-hydroxytryptamine) in mast cells. *Ann. N.Y. Acad. Sci.,* **103,** 179 (1963). [D58279

——, and **Lagunoff, D.:** Mast cells, endothelium and myocardial infarction. In: *Henry Ford Hospital Internat. Symp., The Etiology of Myocardial Infarction.* Boston: Little, Brown & Co., p. 265 (1963). [E580

——, and ——: The mast cell: its structure and function. *Progr. Allergy,* **8,** 195 (1964). [G10074

——, **Wong, R. L., Arase, M.,** and **Roeper, E.:** 5-Hydroxytryptamine in mast cells. *Proc. Soc. exper. Biol. (N.Y.),* **90,** 303 (1955). [C9838

Bensley, S. H.: Histological studies of the reactions of cells and intercellular substances of loose connective tissue to the spreading factor of testicular extracts. *Ann. N.Y. Acad. Sci.,* **51,** 983 (1949). [D42231

——: Pinacyanol erythrosinate as a stain for mast cells. *Stain Technol.,* **27,** 269 (1952). [D28535

——: On the origin of mast cells. *Anat. Rec.,* **112,** 310 (1952). [D26489

——: On the presence, properties and distribution of the intercellular ground substance of loose connective tissue. *Anat. Rec.,* **60,** 93 (1934). [D28924

Bensley, R. R. and **Vimtrup, B.:** On the nature of the Rouget cells of capillaries. *Anat. Rec.,* **39,** 37 (1928). [D28923

Benson, W. R.: Acceleration of aging changes in the exorbital lacrimal gland of the female rat. *Amer. J. Path.,* **45,** 587 (1964). [D18867

Beraldo, W. T., Dias da Silva, W., and **Fernandez, A. D. L.:** Inhibitory effects of carbohydrates on histamine release and mast cell disruption by dextran. *Brit. J. Pharmacol.,* **19,** 405 (1962). [D39770

Berdjis, C. C.: Hypervitaminosis A and mast cells. A study of interrelationship of mast cells and vitamin A in vivo and in vitro. *Acta vitamin. (Milano),* **17,** 3 (1963). [D68096

Berg, N. O.: A histological study of masked lipids. *Acta path. microbiol. scand.,* sup. 90, (1951). [D27523

Berg, J. A. G. ten, and **Hermans, E. H.:** Un cas mortel d'urticaria pigmentosa haemorrhagica. *Méd. et Hyg. (Genève),* **9,** 68 (1956). [E57228

Bergonzini, C.: Über das Vorkommen von granulierten basophilen und acidophilen Zellen im Bindegewebe und über die Art, sie sichtbar zu machen. *Anat. Anz.,* **6,** 595 (1891). [D27587

Bergström, G., Johansson, H., and **Westin, B.:** The occurrence of mast cells in the mouse uterus in prolonged oestrogenic treatment. *Acta path. microbiol. scand.,* **42,** 198 (1958). [C53172

Bergström, I., Tomenius, J., and **Wihman, G.:** Mastceller och heparinbildning vid hemorrhagisk diates. *Nord. Med.,* **44,** 1644 (1950). [D30555

Berka, F.: Die Brustdrüse verschiedener Altersstufen und während der Schwangerschaft. *Frankfurt. Ztschr. Pathol.,* **8,** 203 (1911). [D27512

Berlin, C.: Urticaria pigmentosa as a systemic disease. *A.M.A. Arch. Derm. Syph.,* **71,** 703 (1955). [D30375

Bermejo, S. M.: Urticaria pigmentosa. *Galicia clin.,* **34,** 822 (1962). [D47515

Bersani, R. B.: The blood basophil in urticaria and other dermatoses. *Thesis, University of Zürich* (1959). [D82695

Bersohn, I.: Atherosclerosis and coronary heart disease. Possible incrimination of magnesium deficiency in their promotion. *Med. Proc.,* **4,** 62 (1958). [C51282

Bertellotti, L.: L'urticaria pigmentosa come reticolo-endoteliosi sistemica ad orientamento monomorfo. *G. ital. Derm. Sif.,* **84,** 698 (1943). [E35030

Betances, L.: Les cellules du sang de l'Astacus fluviatilis. *Arch. Anat. micr. Morph. exp.,* **18,** 1 (1921). [G11140

Beurey, J., Mougeolle, J. M., Remigy, E., and **Finale, R.:** Altération de la crase sanguine dans un cas de mastocytose cutanée. *Bull. Soc. franç. Derm. Syph.,* **66,** 359 (1959). [D26744

Beux, Y. le, and **Ganter, P.:** Etude histopathologique et cytologique de la maladie de Waldenström. (A propos de 8 cas de macroglobulinémie.) *Ann. Anat. path.,* **8,** 377 (1963). [E22489

Beylot, M., and **Baudrimont, A.:** Leçons sur les cellules conjonctives et leurs aptitudes réactionnelles. *Gaz. hebd. Sci. méd. Bordeaux,* **43,** 109 (1922). [D65654

Bezançon, F.: Sur un cas de leucémie myélogène. *Sem. méd. (Paris),* **20,** 226 (1900). [G18727

Bhatt, K. G. S., Jalota, R., and **Sanyal, R. K.:** Action of various drugs on the tissue histamine and 5-hydroxytryptamine contents of common laboratory animals. *Indian J. med. Res.,* **52,** 52 (1964). [F8369

Bhattacharya, B. K., and **Lewis, G. P.:** The release of 5-hydroxytryptamine by histamine liberators. *Brit. J. Pharmacol.,* **11,** 202 (1956). [C19581

——, and ——: The effects of reserpine and compound 48/80 on the release of amines from the mast cells of rats. *Brit. J. Pharmacol.,* **11,** 411 (1956). [C27232

Biach, M.: Zur Unterscheidung der Urticaria pigmentosa von der Urticaria xanthelasmoidea. *Arch. Dermat. Syph. (Berlin),* **111,** 619 (1912). [E37595

Biedl, A., and **Kraus, R.:** Experimentelle Studien über Anaphylaxie. *Wien. klin. Wchnschr.,* **22,** 363, 396 (1909). [D30639

Bierich, R.: Über die Beteiligung des Bindegewebes bei der experimentellen Krebsbildung. *Virchows Arch. pathol. Anat.,* **239,** 1 (1922). [D27096

Biesele, J. J.: Some morphological effects of alkylating agents. *Exp. Cell Res.,* sup. 9, 525 (1963). [E25803

Bigart, M.: Cirrhose de Hanot et leucémie à "Mastzellen". *C.R. Soc. Biol. (Paris),* **54,** 1529 (1902). [D30637

Bigelow, E. L.: Changing concepts concerning mastocytosis. *J. Pediat.,* **58,** 499 (1961). [D26847

Birt, A. R., Hagen, P., and **Zebrowski, E.:** Amino acid decarboxylases of urticaria pigmentosa mast cells. *J. invest. Derm.,* **37,** 273 (1961). [D65257

——, and **Nickerson, M.:** Generalized flushing of the skin with urticaria pigmentosa. *A.M.A. Arch. Derm.,* **80,** 311 (1959). [G11133

Bizzozero, E.: Sur l'urticaire pigmentaire (urticaria pigmentosa). *Ann. Derm. Syph. (Paris),* **2,** 385 (1911). [E37588

Blaschko, H.: Remarks on the location of histamine in mammalian tissues. In: *Histamine. Ciba Found. Symp.,* J. & A. Churchill Ltd., London, p. 381 (1956). [C34533

Blechmann, G., Tzanck, A., and **Deschamps, P.:** Cas à diagnostic: forme insolite d'urticaire pigmentaire (?) chez un nourrisson. *Arch. franç. Pédiat.,* **5,** 151 (1948). [D39794

Blomquist, H. E.: Kann eine Anhäufung von Mastzellen im Grenzgebiet der Schilddrüsenadenome beobachtet werden? *Acta path. microbiol. scand.,* **39,** 313 (1956). [D27524

——: Über die Einwirkung experimentell hervorgerufener Gastritis auf die Zahl der Mastzellen in der Submukosa des Magens. *Acta path. microbiol. scand.,* **39,** 317 (1956). [C34388

——: Kann ein in der Magenwand appliziertes, sklerosierendes Agens eine Zunahme der Mastzellenzahl der Schilddrüse verursachen? *Acta path. microbiol. scand.,* **39,** 320 (1956). [D31590

——, and **Fock, G.:** Über die Einwirkung von experimentell hervorgerufenem Ileus auf die Anzahl der Mastzellen in Magen, Darm und Harnblase bei Ratten. *Ann. Med. exp. Fenn.,* **41,** 182 (1963). [D69669

Bloom, F.: Spontaneous solitary and multiple mast cell tumors (mastocytoma) in dogs. *Arch. Path.,* **33,** 661 (1942). [D10421

——: Effect of cortisone on mast cell tumors ('mastocytoma') of the dog. *Proc. Soc. exp. Biol. (N.Y.),* **79,** 651 (1952). [B69764

Bloom, G.: Cytological changes in human tissue mast cells after cortisone treatment. *Acta morph. neerl.-scand.,* **1,** 331 (1956). [C74089

——: Studies on the cytology, cytochemistry and pathology of the mast cell. *Thesis, University of Stockholm* (1960). [E22677

Bloom, G. D.: Electron microscopy of neoplastic mast cells: a study of the mouse mastocytoma mast cell. *Ann. N.Y. Acad. Sci.,* **103,** 53 (1963). [D58274

Bloom, G., Dunér, H., Pernow, B., Winberg, J., and **Zetterström, R.:** Spontaneous histamine shocks in urticaria pigmentosa. *Acta paediat. (Uppsala),* **47,** 152 (1958). [D27896

——, **Franzén, S.,** and **Sirén, M.:** Malignant systemic mast cell disease (mastocytoma) in man. *Acta med. scand.,* **168,** 95 (1960). [D8351

——, and **Friberg, U.:** A method for the electronmicroscopy of tissue mast-cells. *Experientia (Basel),* **9,** 310 (1953). [D26647

——, ——, and **Larsson, B.:** Some observations on the fine structure of mast cells tumours (mastocytoma). *Nord. Vet.-Med.,* **8,** 43 (1956). [C12081

——, ——, ——, and **Åberg, B.:** Morphology of tissue mast-cells in dog mastocytoma and clinical chemistry of these tumours. *Acta path. microbiol. scand.,* **37,** 163 (1955). [D26753

——, and **Kelly, J. W.:** The copper phthalocyanin dye "Astrablau" and its staining properties, especially the staining of mast cells. *Ztschr. Zellforschg. mikros. Anat. Abt. Histochem.,* **2,** 48 (1960). [D65674

——, **Larsson, B.,** and **Åberg, B.:** Canine mastocytoma. *Ztrbl. Vet.-Med.,* **5,** 443 (1958). [D39809

——, ——, and **Smith, D. E.:** The reaction of peritoneal mast cells in the rat to various activators. *Acta path. microbiol. scand.,* **40,** 309 (1957). [C34040

——, and **Ringertz, N. R.:** Acid polysaccharides of peritoneal mast cells of the rat and mouse. *Arkiv Kemi,* **16,** 51 (1961). [D39808

——, and **Valmet, E.:** A density gradient centrifugation technique for large scale separation of rat peritoneal mast cells. *Acta morph. neerl.-scand.,* **3,** 229 (1961). [D67421

Bluefarb, S. M., and **Salk, M. R.:** Urticaria pigmentosa with bone lesions, gastrointestinal symptoms and splenomegaly. *A.M.A. Arch. Derm. Syph. (Chic.),* **70,** 376 (1954). [D39514

Boas, H.: Et Tilfaelde af Urticaria pigmentosa. *Hospitalstidente,* **5,** 905 (1912). [G1236

Bogowski, P.: Über experimentell erzeugte Mastozytome der Haut bei der weissen Maus. *Arch. Geschwulstforschg.,* **18,** 1 (1961). [D39513

Bohač, C.: Zur Kenntnis der Urticaria pigmentosa. *Arch. Dermat. Syph. (Berlin),* **82,** 49 (1906). [D27597

Bois, C. C. du: Granule cells in the mucosa of the pig's intestine. *Anat. Anzgr.,* **25,** 6 (1904). [D27594

Bois, P.: Effect of magnesium deficiency on mast cells and urinary histamine in rats. *Brit. J. exp. Path.,* **44,** 151 (1963). [D33692

——: Carence en magnésium et mastocytes. *Un. méd. Can.,* **93,** 209 (1964). [F979

——: Mast cells and histamine concentration in muscle and liver of dystrophic mice. *Amer. J. Physiol.,* **206,** 338 (1964). [G1472

——, **Byrne, E. H.,** and **Bélanger, L. F.:** Effect of magnesium deficiency on the regeneration of mast cells after treatment with 48/80 in rats. *Canad. J. Biochem.,* **38,** 585 (1960). [C86523

——, **Gascon, A.,** and **Beaulnes, A.:** Histamine-liberating effect of magnesium deficiency in the rat. *Nature (Lond.),* **197,** 501 (1963). [D64014

——, ——, and **Jasmin, G.:** Effects of magnesium deficiency on mast cells, histamine and serotonin content of tissues in the rat. *Proc. Canad. Fed. Biol. Soc., 4th Ann. Meet. Guelph May 1961,* **4,** 13 (1961). [D5409

Bolgert, M., and **le Sourd, M.:** Urticaire pigmentaire avec altérations hématologiques discrètes. *Bull. Soc. franç. Derm. Syph.,* **56,** 353 (1949). [D39543

——, and ——: Cas pour diagnostic. *Bull. Soc. franç. Derm. Syph.,* **57,** 341 (1950). [D39719

Bolton, L. L.: Basophile (mast) cells in the alimentary canal of salmonoid fishes. *J. Morph.,* **54,** 549 (1932). [D28256

Bonati, B., Bergamini, A., Mari, E., and **Montanari, L.:** Influenza della ipofisectomia su alcuni effetti biologici svolti dal salicilato di sodio nel ratto. *Arch. E. Maragliano Pat. Clin.,* **7,** 1035 (1952). [B88320

Bondet, P., and **Bourgeois, L.:** Urticaire pigmentaire tardive. Modifications sanguines. *Bull. Soc. franç. Derm. Syph.,* **57,** 255 (1950). [D39718

Bonnet, L. M.: Urticaire pigmentée. *Lyon méd.,* **110,** 1164 (1908). [E39410

Bonney, V.: The connective tissue in carcinoma and in certain inflammatory states that precede its onset. *Lancet,* **1,** 1389 (1908). [D28388

Bonomi, U.: Su di un metodo per mettere in evidenza le mastcellule nei tessuti. *Boll. Soc. ital. Biol. sper.,* **27,** 1282 (1951). [D92205

Boréus, L. O.: A comparison of mast-cell reactions in the rat, hamster and guinea pig. *Acta physiol. scand.,* **49,** 251 (1960). [D65098

——: Quantitative studies on the anaphylactic mast-cell reaction in vivo in the guinea-pig. *Acta physiol. scand.*, **48**, 431 (1960). [E27594
——: Further observations on anaphylactic mast cell changes in the nasal mucosa of guinea pigs in vivo. *Acta physiol. scand.*, **52**, 309 (1961). [D12234
——: A study of the anaphylactic mast-cell reaction in vivo following desensitization of sensitized guinea pigs. *Acta physiol. scand.*, **50**, 375 (1960). [D26859
——: Anafilaxi och mastceller. En *experimentell studie på marsvin*. Stockholm: Almqvist and Wiksells, p. 36, (1961). [E27559
——, and **Chakravarty, N.**: The histamine content of guinea pig mast cells. *Experientia (Basel)*, **16**, 192 (1960). [D26646
——, and ——: Tissue mast cells, histamine and 'slow reacting substance' in anaphylactic reaction in guinea pig. *Acta physiol. scand.*, **48**, 315 (1959). [C86027
Borrel, A.: Homologie des cellules pigmentaires et des mastocytes chez la souris noire. *C.R. Soc. Biol. (Paris)*, **99**, 1866 (1928). [D26868
Borrel, A., Boez, L., and **Goulon, A.**: Cancer du goudron chez la souris. *C.R. Soc. Biol. (Paris)*, **88**, 402 (1923). [D26809
Bory, L.: Urticaire pigmentaire; crises nitritoïdes occasionnées par des applications cryothérapiques. *Bull. Soc. franç. Derm. Syph.*, **34**, 75 (1927). [D39624
Boseila, A. W. A.: Influence of cortisone on the basophil granulocytes and the total white cell count in rabbit blood. *Acta endocr.*, **29**, 253 (1958). [C59059
——: Influence of corticotrophin on the circulating basophils in the rabbit. *Acta endocr.*, **29**, 355 (1958). [C60944
——: *The basophil leucocyte and its relationship to the tissue mast cell*. Copenhagen: Munksgaard (1959). [C68531
——: Hormonal influence on blood and tissue basophilic granulocytes. *Ann. N.Y. Acad. Sci.*, **103**, 394 (1963). [D58293
——, and **Moltke, E.**: Influence of L-thyroxine on the circulating basophil leukocytes in the rabbit. *Acta endocr.*, **29**, 273 (1958). [C59062
——, ——, and **Torsoe, H.**: Influence of D-thyroxine and L-thyroxine on the basophil count in the human blood. *Acta endocr.*, **32**, 284 (1959). [C76463
——, and **Toone, E. C.**: Basophil leucocytes (blood mast cells) in rheumatoid arthritis. *Acta rheum. scand.*, **7**, 183 (1961). [E40872
——, and **Uhrbrand, H.**: Basophil-eosinophil relationship in human blood. *Acta endocr. (Kbh.)*, **28**, 49 (1958). [E45649
Boström, H., Odeblad, E., and **Friberg, U.**: A qualitative and quantitative autoradiographic study on the uptake of S^{35}-labelled sodium sulphate in the skin of the adult rat. *Acta path. microbiol. scand.*, **32**, 516 (1953). [D65096
Bottiglioni, E., Galletti, G., and **Sturani, P. L.**: Il problema della inanizione acuta e cronica; ripercussioni indotte a livello dei mastociti cutanei e peritoneali e della sostanza fondamentale del connettivo; (studio sperimentale). *G. Clin. med.*, **38**, 1709 (1957). [G18905
Bowdler, A. J., and **Tullett, G. L.**: Urticaria pigmentosa and pigmentosa and polycythaemia vera. *Brit. med. J.*, **1**, 396 (1960). [D39625
Bowen, J. T.: Urticaria pigmentosa. *J. cutan. Dis.*, **26**, 177 (1908). [E38156
Boyd, J. F., and **Smith, A. N.**: The effect of histamine and a histamine-releasing agent (compound 48/80) on wound healing. *J. Path. Bact.*, **78**, 379 (1959). [D65097
Brack, E.: Über histologische Erscheinungen an der Mamma, speziell an den Mamillen, in den verschiedenen Lebensaltern. *Arch. Gynäk.*, **122**, 711 (1925). [D27435
——: Ueber Bindegewebsmastzellen im menschlichen Organismus. *Folia heamat. (Lpzg.)*, **31**, 202 (1925). [D26821
Braun-Falco, O.: Morphologische und pharmakologische Untersuchungen zur Frage der Histaminabgabe durch Mastzellen. *Arch. Dermat. Syph. (Berlin)*, **199**, 197 (1955). [D26884
——, and **Jung, J.**: Über klinische und experimentelle Beobachtungen bei einem Fall von diffuser Haut-Mastocytose. *Arch. klin. exp. Dermat.*, **213**, 639 (1961). [D39567
——, and **Salfeld, K.**: Leucine aminopeptidase activity in mast cells. *Nature (Lond.)*, **183**, 51 (1959). [D39714
Braunsteiner, H.: Mastzellen und basophile Leukozyten. In: *Physiologie und Physiopathologie der weissen Blutzellen*. Stuttgart: Georg Thieme Verlag, p. 49 (1959). [D59693
——: Das Mastocytose-Syndrom. *Dtsch. med. Wchschr.*, **89**, 573 (1964). [G10415
——, **Höfer, R., Thumb, N.**, and **Vetter, H.**: Untersuchungen über die basophilen Leukocyten bei Schilddrüsenkrankheiten. *Klin. Wchnschr.*, **37**, 250 (1959). [C65755
——, **Mitsotakis, E.**, and **Thumb, N.**: Ueber die Wirkung von Diaminodecan auf

Mastzellen und basophile Leukozyten. *Blut,* **3,** 255 (1957). [D27986
——, and **Pakesch, F.:** Elektronenmikroskopische Untersuchungen der Granula menschlicher Leukozyten. *Acta haemat. (Basel),* **17,** 136 (1957). [D30632
——, **Putushek, O.,** and **Thumb, N.:** Variations observées dans le nombre des leucocytes basophiles chez l'homme. *Rev. Hémat.,* **15,** 241 (1960). [E52570
——, and **Thumb, N.:** Über quantitative Veränderungen der basophilen Leukozyten und ihre Stoffwechselbedeutung. *Wien. Ztschr. inn. Med.,* **39,** 285 (1958). [C62702
——, and ——: Quantitative Veränderungen der Blutbasophilen und ihre klinische Bedeutung. *Acta haemat.,* **20,** 339 (1958). [C89221
——, and ——: Mastzellen, Basophile und Heparinfreisetzung. *Biblio. haemat. (Basel),* **15,** (1963). [G14691
——, and **Zucker-Franklin, D.:** *The physiology and pathology of leukocytes.* New York: Grune & Stratton, (1962). [E55512
Bray, R. E. and **Van Arsdel, P. P.:** In vitro histamine release from rat mast cells by chemical and physical agents. *Proc. Soc. exp. Biol. (N.Y.),* **106,** 255 (1961). [D26900
Bremy, P.: Die Gewebsmastzellen im menschlichen Knochenmark. *Ihre klinisch-haematologische Bedeutung bei 20 aregenerativen Anämien.* Stuttgart: Georg Thieme Verlag (1950). [C72062
Brenk, van den, H. A. S.: Observations on mast cell changes, histamine release and local tissue damage in rats following X-irradiation. *Brit. J. exp. Path.,* **39,** 356 (1958). [C59465
Briggs, N. T.: Immunological injury of mast cells in mice actively and passively sensitized to antigens from Trichinella spiralis. *J. infect. Dis.,* **113,** 22 (1963). [E21583
Brink, A. J., and **Marshall, J.:** Mastocytosis (urticaria pigmentosa) and polycythaemia rubra vera. *S. Afr. med. J.,* **37,** 1307 (1963). [D70852
Brinkmann, E.: Mastzellenreticulose (Gewebsbasophilom) mit histaminbedingtem Flush und Übergang in Gewebsbasophilen-Leukämie. *Schweiz. med. Wchnschr.,* **89,** 1046 (1959). [D33665
——: Funktionen und Krankheiten der Mastzellen. *Berl. Med.,* **13,** 229 (1962). [D26693
Brix, H.: Quantitative Untersuchungen des Mastzellengehalts funktionell unterschiedlicher belasteter normaler menschlicher Haut mit kovarianzanalytischer Auswertung. *Thesis, University of Berlin* (1963). [E39764
Brodersen, J.: Die Zellen des Unterhautbindegewebes der weissen Maus. *Ztschr. mikroskop. anat. Forschg.,* **14,** 60 (1928). [D12773
Brodeur, P. and **Gardner, L. I.:** Urticaria pigmentosa as a problem in diagnosis. Report of two cases, one with systemic involvement. *New England J. Med.,* **254,** 1165 (1956). [C21475
Brodey, R. S.: Multiple genital neoplasia (mast cell sarcoma, seminoma, and Sertoli cell tumor) in a dog. *J. Amer. vet. med. Ass.,* **128,** 450 (1956). [C32742
——, **McGrath, J. T.,** and **Martin, J. E.:** Preliminary observations on the use of cortisone in canine mast cell sarcoma. *J. Amer. Vet. med. Ass.,* **123,** 391 (1953). [B95502
Brogren, N., Duner, H., Hamrin, B., Pernow, B., Theander, G., and **Waldenström, J.:** Urticaria pigmentosa (mastocytosis). A study of nine cases with special reference to the excretion of histamine in urine. *Acta med. scand.,* **163,** 223 (1959). [C69050
Browicz, T.: O komórkach tucznych Ehrlicha. (Sur les cellules granulifères d'Ehrlich). *Bull. Acad. Sci. Cracow,* p. 195, July 1890. [E25818
Brugnatelli, E.: Cellule interstiziali secrezione interna della mammella. *Folia Gynaecol.,* **9,** 1 (1914). [46135
Bruni, C., and **Caschera, F.:** Quantità e distribuzione delle Mastzellen nel carcinoma dello stomaco. Ricerca sistemica. *Lav. Ist. Anat. Univ. Perugia,* **12,** 5 (1952). [D30634
——, and ——: Mastzellen e metacromasia stromale nelle linfoghiandole sede di metastasi neoplastiche. *Lav. Ist. Anat. Univ. Perugia,* **13,** 181 (1953). [D39618
——, and **Olivi, M.:** Per l'anatomia patologica dei tumori della regione paratidea. IX. Ricerche sistematiche sulla esistenza di Mastzellen nella parotide a proposito dei loro rapporti con le Mastzellen nelle neoplasie di questa ghiandola. *Lav. Ist. Univ. Perugia,* **10,** 73 (1951). [D39592
——, ——, and **Centonze, M.:** Le sostanze metacromatiche mesenchimali nel cancro dello stomaco. *Lav. Ist. Anat. Univ. Perugia,* **9,** 129 (1950). [D30647
Brusa, A.: Contributi sperimentali alla conoscenza del significato dei mastociti. Ricerche sull'utero dei roditori. *Biol. lat. (Milano),* **2,** 758 (1949). [D39831
Brusca, E. A.: Modificazioni tintoriali delle Mastzellen in seguito a contatto con pro-

teine basiche ed emoglobina. *Arch. De Vecchi. Anat. pat.*, **28**, 533 (1958). [D39526

——, **Gallina, F.**, and **Patrono, D.**: Effetti biologici del lisozima indipendenti dalla sua azione enzimatica. *Riv. Anat. pat.*, **16**, 493 (1959). [D27392

——, **Pasqualino, A.**, and **Allegra, L.**: Effetti biologici del lisozima indipendenti dalla sua azione enzimatica. II. Riduzione dei colloidi Rivalta-positivi negli essudati. *Riv. Anat. pat.*, **17**, 509 (1960). [G17025

Bryan, W.T.K. and **Bryan, M.**: Significance of mast cells in nasal secretions. *Trans. Amer. Acad. Ophthal. Otolaryng.*, **63**, 613 (1959). [D26624

Bujard, E.: Une coloration strictement élective des granulations basophiles des mastocytes. *Bull. Histol. Techn. micr.*, **7**, 264 (1930). [D27581

Bulmer, D.: Histochemical demonstration of a C-esterase activity in the metrial gland cells of the rat placenta. *Nature (Lond.)*, **1**, 90 (1964). [E23380

Bunch, J. L.: Urticaria pigmentosa. *Brit. J. Derm.*, **21**, 117 (1909). [E37592

——: Urticaria pigmentosa. *Brit. J. Derm.*, **21**, 219 (1909). [E37600

——: Urticaria pigmentosa. *Brit. J. Derm.*, **23**, 405 (1911). [E37431

——: Urticaria pigmentosa. *Proc. Roy. Soc. Med.*, **12**, 1 (1919). [D71208

Buño, W.: Algunas reacciones histoquímicas y funcionales de los mastocitos. *Acta physiol. lat.-amer.*, **3**, 60 (1953). [B90623

——: Acción 'in vitro' de la cortisona sobre los mastocitos de la rata. *Arch. Soc. Biol. Montevideo*, **20**, 117 (1953) [D69633

——: Los mastocitos tisulares: reacciones histoquímicas y funcionales. *An. Fac. Med. Montevideo*, **38**, 343 (1953). [B94605

——, and **Poletti, H.**: Acción local de la cortisona sobre el tejido conjuntivo en la rata. *Arch. Soc. Biol. Montevideo*, **20**, 6 (1953). [B94604

Bunting, C. H.: The leukocytic picture in influenza. *Amer. J. med. Sci.*, **162**, 1 (1921). [G16739

——, and **Thewlis, E.**: Leukocytic reactions in smallpox, chickenpox, scarlet fever, measles and mumps. *Arch. Path. Lab. Med.*, **1**, 189 (1926). [G18416

Burch, G. E., and **Phillips, J. H.**: Chromaffin reacting cells in human digital skin. *Circulat. Res.*, **6**, 416 (1958). [C64614

Bürgel, E., and **Oleck, H. G.**: Skelettveränderungen bei der Urticaria pigmentosa. *Fortschr. Röntgenstr.* **90**, 185 (1959). [D39675

Burkl, W.: Ueber Mastzellen und ihre Aufgaben. *Wien. klin. Wchnsch.*, **64**, 411 (1952). [D26896

Burks, J. W., and **Chernosky, M. E.**: Nodular urticaria pigmentosa of the vulva in siblings. *A.M.A. Arch. Derm.*, **75**, 812 (1957). [D39622

Burnet, M.: Role of the thymus and related organs in immunity. *Brit. med. J.*, Sept. 29, 807 (1962). [D33851

Burns, R. E., **Fine, G.**, and **Ensign, D. C.**: An investigation of the skin in rheumatoid arthritis. *J. Amer. med. Ass.*, **183**, 475 (1963). [D54172

Burton, A. L.: The fate of normal mast cells studied in tissue culture by means of time lapse cinephotomicrography. *Anat. Rec.*, **136**, 407 (1960). [D26702

——: Studies on living normal mast cells. *Ann. N.Y. Acad. Sci.*, **103**, 245 (1963). [D58284

——, and **Bensley, S. H.**: The finer structure of developing mast cells. *Anat. Rec.*, **130**, 280 (1958). [D33750

Caccialanza, P., and **Campani, M.**: Die Bedeutung des Heparins in seiner Beziehung zur Urticaria pigmentosa. *Hautarzt*, **2**, 356 (1951). [D39701

Cairns, A., and **Constantinides, P.**: Mast cells in human atherosclerosis. *Science*, **120**, 31 (1954). [C3038

Cajal, R. Y.: Estudios histologicos sobre los tumores epitheliales. *Rev. trimest. microg.*, **1**, 83 (1896). [D31538

Cajal, S. R.: Quelques antécédents historiques ignorés sur les Plasmazellen. *Anat. Anzgr.*, **29**, 666 (1906). [D27596

Calamari, A.: Considerazioni sulla genesi dei leucociti basofili del sangue (a proposito di un caso di mastzellenleucemia infantile). *Riv. Clin. Pediat.*, **45**, 425 (1947). [G18726

Calleja, C.: Distribución y significación de las células cebadas de Ehrlich. *Rev. trim. micrograf.*, **1**, 137 (1896). [D39609

Calnan, C. D.: Urticaria pigmentosa with bone lesions. Two cases. (Case 1) *Brit. J. Derm.*, **65**, 375 (1953). [D39552

——: Urticaria pigmentosa with bone lesions. Two cases. (Case 2) *Brit. J. Derm.*, **65**, 375 (1953). [D31593

——: Urticarial reactions. *Brit. med. J.* Sept. 12, 649 (1964). [E51853

Calonius, P. E. B.: Über das Auftreten von Mastzellen im Zahnfleisch, in Extraktionsnarben und in Bindegewebe unter Kompression. *Schweiz. Monatschr. Zahnheilk.*, **69**, 488 (1959). [D39832

——, and **Jäämeri, K. E. U.**: Mast cells in keloids. *Ann. Chir. Gynaec. Fenn.*, **50**, 9 (1961). [D26777

Calzavara, F., Corsi, M., and **Mezzanotte, S.:** Il sistema mastocitario del peritoneo del ratto dopo roentgenirradiazione e dopo scottatura. (Nota I). *Riv. Anat., Pat.,* **17,** 274 (1960). [D13495

——, ——, and ——: Il comportamento del sistema mastocitario del ratto irradiato previa iniezione endoperitoneale di antistaminici, acido ialuronico e cortisonici. (Nota II). *Riv. Anat. Pat.,* **17,** 433 (1960). [D10222

Camaño, O. A. L., Finkelberg, M. and **Sarmiento, A. S.:** Urticaria pigmentaria. *Rev. argent. Dermatosif.,* **29,** 56 (1945). [D39804

Cambel, P., Conroy, C. E., and **Sgouris, J. T.:** Gastric mast cell diapedesis in the albino rat. *Science,* **115,** 373 (1952). [D24770

Camble, P.: Siderosis and mast cell vacuolation in albino rat after toluidine blue O administration. *Fed. Proc.,* **11,** 400 (1952). [D39585

Camerada, P., and **Leo, P.:** *Rass. med. Sarda,* **6,** 163 (1955). [D20047

Cameron, D. G., and **Watson, G. M.:** Femoral bone marrow biopsy in the albino rat. *Blood,* **3,** 292 (1948). [B31287

Campani, M.: Effetto della irradiozione con alte dosi si raggi roentgen sulle cellule granulose basofile connettivali (Mastzellen). *Boll. Soc. med.-chir. Modena,* **48,** 279 (1948). [D39614

——: Differente solubilità dei granuli metacromatici delle cellule granulose basofile connettivali (Mastzellen) nell'alcool. *Rass. Biol. umana,* **4,** 12 (1949). [D39607

——: Function of mast-cells. *Lancet,* **260,** 802 (1951). [D27609

——, and **Benassi, G.:** Di alcune proprieta istochimiche dei granuli delle Mastzellen. *Boll. Soc. ital. Biol. sper.,* **26,** 231 (1950). [D5729

Campos Vidal, B. de, *cf.* Vidal, B. de C. [E22485

Candiani, G.: Il comportamento morfologico dei Mastociti dei vasi sanguini nelle angiopatic gangrenose delle estremità. *Riv. Anat. Pat.,* **7,** 459 (1953). [D39604

Canestri, G.: Il tasso dei basofili circolanti nell'epatite acuta itterigena. *Lattante,* **33,** 520 (1962). [E61236

Canizares, O.: Urticaria pigmentosa. *A.M.A. Arch. Derm. Syph. (Chic.),* **67,** 327 (1953). [D39557

Cannizzaro, C.: Le Mastzellen nella mucosa laringea e tracheale nel ratto sottoposto ad azione di vapori irritanti. *Boll. Mal. Orecch.,* **80,** 92 (1962). [D31003

Canon, P.: Über eosinophile Zellen und Mastzellen im Blute Gesunder und Kranker. *Dtsch. med. Wchenschr.,* **18,** 206 (1892). [D27645

Caplan, R. M.: The natural course of urticaria pigmentosa. *A.M.A. Arch. Derm.,* **87,** 146 (1963). [D55590

Cărbunescu, G.; Georgescu, L., and **Răşcanu, T.:** Influenta transplatelor tisulare asupra variatiilor histaminei la sobolanii albi cu tumori Guerin. Nota II. *Rev. med.-chir. Iasi,* **68,** 419 (1964). [E96976

Carlini, G. R. S., Fischer, G. A., and **Giarman, N. J.:** Differences in characteristics of release of serotonin from neoplastic mast cells in culture by reserpine and chlorpromazine. *J. Pharmacol. exp. Ther.,* **146,** 74 (1964). [F22986

Carranza, F. A., and **Cabrini, R. L.:** Mast cells in human gingiva. *Oral Surg.,* **8,** 1093 (1955). [D80527

——, and ——: Age variations in the number of mast cells in oral mucosa and skin of albino rats. *J. dent. Res.,* **38,** 631 (1959). [D65112

Carrera, J. L., and **Seoane, M.:** Observación de urticaria pigmentaria. *Rev. argent. Dermatosif.,* **29,** 206 (1945). [D39805

Carril, A. V. del, Saporiti, E. M., de Gastaldo, L., and **Suarez, A. F.:** El 'stress' quirurgico y su prevención mediante hormonas estrogenicas. *Pren. univ. (B.Aires),* **1,** 473 (1962). [G16997

Cars, M. le: L'urticaire pigmentaire. *Thèse, Université de Bordeaux* (1930). [D39796

Carter, P. B., Higginbotham, R. D., and **Dougherty, T. F.:** The local response of tissue mast cells to antigen in sensitized mice. **79,** 259 (1957). [D28263

Caruso, P. L.: Calcificazione sellettive della mucosa orale del palato e delle labra, nel corso della matocalcifilassi. *Ann. Stomat. (Roma),* **13,** 535 (1964). [G11119

——: Importanza dei mastociti nella localizazione oro-labiale delle calcificazioni nel corso della calcergia sperimentale. *Minerva stomat.,* (in press). [E24145

Carvalho, G.: Sur la labrocytose (mastzellose) chez les individus soumis au traitement antirabique. *C.R. Soc. Biol. (Paris),* **87,** 701 (1922). [D27504

Caschera, F., Paoletti, I., and **Bucciarelli, E.:** Comportamento della Mastzellen nella mamella di topi femina del BALB/c/Cb/Se substrain trattati 'per os' con quattro cancerogeni chimici. *Lav. Ist. Anat. Univ. Perugia,* **23,** 203 (1963). [E21879

Caselli, P.: L'azione di mesomucinasi sulle granulazioni specifiche dei mastociti umani. *Boll. Soc. ital. Biol. sper.,* **20,** 869 (1945). [D26830

——: Azione del solfato di protamina sulle cellule granulose basofile. *Haematologica,* **42,** 111 (1957). [D39775

——, **Brusca, E. A.,** and **Ardoine, A. L.:** Ricerche sul determinismo della inibizione della colorazione delle granulazioni specifiche delle Mastzellen prodotta da alcuni protidi. *Arch. De Vecchi Anat. pat.,* **32,** 259 (1960). [D26433

——, and **Schumacher, H.:** Die Pufferfunktion der Mastzellen gegenüber basischen Proteinen. *Ztschr. gesamt. exp. Med.,* **130,** 265 (1958). [D33666

Casey, A. E.: Basophilia as an index of resistance. *Proc. Soc. exp. Biol. N.Y.,* **26,** 670 (1928). [D30613

——: Antemortem basopenia as an index of resistance. *Proc. Soc. exp. Biol. N.Y.,* **27,** 135 (1929). [D30614

——, **Nettles, T. E.,** and **Hidden, E. H.:** Basophilic leukemia. *South. med. J. (Bgham. Ala.),* **39,** 325 (1946). [D30374

Cass, R., Head, K. W., Riley, J. F., Stroud S. W., and **West, G. B.:** Heparin and histamine in mast cell tumours. *J. Physiol. (Lond.)* **125,** 47P (1954). [D39658

——, **Marshall, P. B.,** and **Riley, J. F.:** 5-Hydroxytryptamine and histamine in mast cells of the mouse and rat. *J. Physiol. (Lond.),* **141,** 510 (1958). [C54014

——, **Riley, J. F., West, G. B., Head, K. W.,** and **Stroud, S. W.:** Heparin and histamine in mast-cell tumours from dogs. *Nature (Lond.),* **174,** 318 (1954). [D26776

Cassar, A.: Sur un cas d'urticaire pigmentaire tardive associé à un pytyriasis rosé. *Ann. Derm. Syph. (Paris),* **6,** 95 (1916). [E37583

Castiglioni, G.: Ricerche sulla metacromasia in soluzioni ossiregolatrici. Osservazioni sulla colorazione metacromatica alcuni constitenti della mucosa nasale. *Ann. biol. norm. pat.,* **3,** 30 (1947). [E26509

——: Osservazioni sulla cromotropia delle Mastzellen. Proposta di un metodo di colorazione. *Ann. biol. norm. pat.,* **3,** 71 (1947). [E26510

Castiglioni, G.: Gli elementi cromotropi dell'ipofisi. *Biol. lat. (Milano),* **1,** 195 (1948). [D39812

——: L'enzima mucinolotico in istologia. *Biol. lat. (Milano),* **2,** 585 (1949-50). [E25535

Cattaneo, I.: Ulteriore contributo ematologico e clinico alla conoscenza della mieloso cronica a granulosblasti metacromatici basofili. *Haematologica,* **34,** 837 (1950). [G18743

Cattaneo, L.: Sul ruolo delle mastcellule nella patogenesi dell'epistassi. *Arch. ital. Otol.,* **70,** 391 (1959). [D26725

Cavallero, C., and **Braccini, C.:** Cortisone e mastociti. *Boll. Soc. ital. Pat.,* **1,** 3 (1950). [B66152

——, and ——: Effect of cortisone on the mast cells of the rat. *Proc. Soc. exper. Biol. (N.Y.),* **78,** 141 (1951). [B63645

Cavazzuti, F., Tedeschi, G., and **Angeli, G.:** Rapporti tra funzionalità tiroidea e leucociti basofili. Ricerche cliniche e sperimentali. *Minerva med.,* **59,** 2352 (1959). [C73006

Cavegn, ?: Urticaria pigmentosa pt. Teleangiectasia macularis eruptiva perstans mit Osteomyelosklerose. Pityriasis versicolor. Hämosiderose der Leber. *Arch. klin. exp. Dermat.,* **219,** 1008 (1964). [F16869

Cawley, E. P., and **Hoch-Ligeti, C.:** Association of tissue mast cells and skin tumors. *A.M.A. Arch. Derm.,* **83,** 92 (1961). [D26653

——, **Mowry, R. W., Lupton, C. H.,** and **Wheeler, C. E.:** The remarkable tissue mast cells. With observations on mast cell acid polysaccharides in the cutaneous lesions of urticaria pigmentosa. *A.M.A. Arch. Derm.,* **80,** 725 (1959). [D26741

Cazal, P.: Mastocytose médullaire et aplasie. *Rev. belge Path.,* **24,** 107 (1955). [D25410

——: La mastocytose ganglionnaire. *Sang,* **26,** 585 (1955). [D26655

——: Mastocytes, mastocytoses, histamine et héparine. *Bull. Soc. Sci. Med. Biol. (Montpellier, France),* **21,** 152 (1942). [D39786

Celestino, D.: Sul peculiare comportamento dei granuli delle Mastcellule alla reazione istochimica per il triptofano. *Valsalva,* **39,** 154 (1963). [E21500

Centeno, J. Luchsinger y, *cf.* Luchsinger y Centeno, J. [D30203

Cerletti, U.: Die Mastzellen als regelmässiger Befund im Bulbus olfactorius des normalen Hundes. *Folia neuro-biol. (Lpzg.),* **5,** 718 (1911). [D27715

Chakravarty, N.: The mechanism of histamine release in anaphylactic reaction in guinea pig and rat. *Acta physiol. scand.,* **48,** 146 (1960). [C83831

——, **Högberg, B.,** and **Uvnäs, B.:** Mechanism of the release by compound

48/80 of histamine and of a lipid-soluble smooth muscle stimulating principle (SRS). *Acta physiol. scand.,* **45,** 255 (1959). [D26476

Chambers, F.: The Incidence of Cancer in the Domesticated Animals. *Vet. Rec.,* **11,** 709 (1931). [B21637

Chan, B. S. T., and **Yoffey, J.:** The basophil cells of guinea-pig bone marrow and their response to horse serum. *Immunology,* **3,** 237 (1960). [D39533

Chargin, L., and **Sachs, P. M.:** Urticaria pigmentosa appearing as a solitary nodular lesion. *A.M.A. Arch. Derm. Syph. (Chic.),* **69,** 345 (1954). [D39556

Charles, A. F., and **Scott, D. A.:** Studies on Heparin. II. Heparin in various tissues. *J. biol. Chem.,* **101,** 431 (1933). [D31555

Chatard, H. and **Cau, G.:** Mastocytose multi-nodulaire du nourrisson avec crises vaso-motrices généralisées. *Bull. Soc. franç. Derm. Syph.,* **66,** 743 (1959). [D26811

Chaves, A. R.: Urticaria pigmentar. *Gaz. méd. port.,* **2,** 942 (1949). [D39789

Chen, C. M. C., and **Chang, H. L.:** Methyl green-pyronin as a stain for mast cells in paraffin sections. *Stain Technol.,* **38,** 133 (1963). [D59711

Chevallier, P., and **Marinone, G.:** Sur un cas de leucémie myéloïde à basophiles. *Sang,* **18,** 401 (1947). [G18724

——, and ——: La leucémie à basocytes. *Sang,* **19,** 193 (1948). [D52735

——, and ——: La leucose aigüe à basoblastes. *Sang,* **22,** 374 (1951). [D61697

Chieco-Bianchi, L., Fiore-Donati, L., and **Pennelli, N.:** Mast cell reaction and 5-hydroxytryptamine content in the skin of Syrian golden hamsters painted with 9:10-dimethyl-1:2-benzanthracene. *Nature (Lond.),* **199,** 293 (1963). [E22251

Chimi, G. A.: Contribution à l'étude de l'urticaire pigmentaire (à propos d'un cas à forme tumorale). *Thèse, Université de Lyon* (1931). [D39797

Christensen, H. E., Iversen, O. H., and **Rask-Nielsen, R.:** Studies on a transplantable mastocytoma in mice. II. Electron microscopic observations. *J. nat. Cancer. Inst.,* **30,** 763 (1963) . [D64073

Chyujo, S.: On the tissue mast cells in the stomach wall of rats (Japanese text). *Acta path. jap.,* **18,** 156 (1928). [D64795

Ciaccio, C.: Ueber die Anwesenheit von lipoiden Substanzen in den Mastzellen. *Ztrbl. allg. Pathol. pathol. Anat.,* **24,** 49 (1913). [D26438

Cid, J. M.: Nevo mastocitario. *An. Cirug. (Rosario),* **22,** 75 (1957). [D18597

Clark, ?: Urticaria pigmentosa. *A.M.A Arch. Derm. Syph. (Chic.),* **3,** 869 (1921). [E37984

Claudatus, J., Hughes, N., and **Poulos, A.:** The role of mast cells in tumour invasion. *N. S. Wales State Cancer Council Publ.,* No. 10, 29, (1964). [E56463

Clowes, G. H. A., and **Owen, A. G.:** Metachromatism of mast-cell granules and mucin. *J. med. Res.,* **12,** 407 (1904). [D28257

Clyman, S. G., and **Rein, R.:** Urticaria pigmentosa associated with bone lesions. *J. invest. Derm.,* **19,** 179 (1952). [D39698

Code, C. F.: The histamine-like activity of white blood cells. *J. Physiol. (Lond.),* **90,** 485 (1937). [A9199

——: Histamine in blood. *Physiol. Rev.,* **32,** 47 (1952). [D28281

——, **Jurn, M. M.,** and **Mitchell, R. G.:** Histamine in human disease. *Proc. Mayo Clin.,* **39,** 715 (1964). [G18722

——, and **Macdonald, A. D.:** The histamine-like activity of blood. *Lancet,* Sep. 25, 730 (1937). [A14572

——, and **Mitchell, R. G.:** Histamine, eosinophils and basophils in the blood. *J. Physiol. (Lond.),* **136,** 449 (1957). [C34861

——, ——, and **Kennedy, J. C.:** The effect of cortisone on the number of circulating basophils and eosinophils: is there a relationship between these cells? *Proc. Mayo Clin.,* **29,** 200 (1954). [D30193

Coenen, H.: Die Aleuronat-Pleuritis des Kaninchens. *Virchows Arch. path. Anat.,* **163,** 84 (1901). [D29293

Cohnheim, ?: Über das Verhalten der fixen Bindegewebskörperchen bei der Entzündung. *Virchows Arch. pathol. Anat.,* **45,** 333 (1869). [D31546

Coleman, E. J., and **DeSalva, S. J.:** Mast cell response to cestode infection. *Proc. Soc. exp. Biol. (N.Y.),* **112,** 432 (1963). [D65237

Colosi, G.: Istamina e Mastzellen nel polmone di ratto 'in sopravvivenza'. *Boll. Soc. ital. Biol. sper.,* **36,** 417 (1960). [D30552

Comby, J.: Un cas d'urticaire pigmentaire infantile. *Arch. Méd. Enf.,* **18,** 370 (1915). [E38000

Compton, A. S.: A cytochemical and cytological study of the connective tissue mast cell. *Amer. J. Anat.,* **91,** 301 (1952). [B90594

Consolandi, G.: Il problema del cancro mucoso della mammella. I. Gli epiteli mucipari nelle mammella umana normale. *Lav. Ist. Anat. Univ. Perugia,* **6,** 35 (1947). [D39594

——: Il problema del cancro gelatinoso della mammella. IV. I fenomeni metacromatici connettivali e la istogenesi del cistosarcoma filloide. *Lav. Ist. Anat. Univ. Perugia,* **8**, 5 (1949). [D39591

——, and **Briziarelli, G.**: Le Mastzellen dell'ipofisi umana. *Lav. Ist. Anat. Univ. Perugia,* **12**, 21 (1952). [B84591

Constantinides, P.: Mast cells and susceptibility to experimental atherosclerosis. *Science,* **117**, 505 (1953). [B81085

——, and **Cairns, A.**: Mast cells and human atherosclerosis. *Anat. Rec.,* **118**, 290 (1954). [D26732

——, and **Rutherdale, J.**: Effects of ageing and of endocrines on the mast cells of the rat. *Anat. Rec.,* **118**, 379 (1954). [C2644

——, and——: Effects of age and endocrines on the mast cell counts of the rat myocardium. *J. Geront.,* **12**, 264 (1957). [C56628

Conte, E. del, della Sala J., and **Stux, M.**: Effect of thyroidectomy, thiourea and iodine on the dermal acid mucopolysaccharides and the mast cells in rats. *Acta endocr. (Kbh.),* **20**, 343 (1955). [D26730

——, ——, and ——: Action de la thyroïdectomie et des antithyroïdiens sur les mucopolysaccharides acides du derme et sur les labrocytes. *C.R. Soc. Biol. (Paris),* **148**, 2127 (1954). [D65692

Conte, F. P., Melville, G. S., and **Upton, A. C.**: Effects of graded doses of whole-body X irradiation on mast cells in the rat mesentery. *Amer. J. Physiol.,* **187**, 160 (1956). [C25678

Corbascio, A. N.: Action of long-chain polymers on kidney juxtaglomerular cells and connective tissue mast cells. *Circulat. Res.,* **8**, 390 (1960). [D27440

Corbetta, S.: Distribuzione numerica dei mastociti nelle malattie gastriche. *Arch. 'De Vecchi' Anat. pat.,* **17**, 31 (1951–52). [D26439

Cordero, A.: Ricerche clinico-sperimentali in un caso di 'urticaria pigmentosa.' *Minerva derm.,* **29**, 55 (1954). [G1709

Cordonnier, V.: Urticaire pigmentaire et syndrome de Cushing. *Bull. Soc. franç. Derm. Syph.,* **53**, 498 (1946). [D61079

Cornbleet, T.: Negative test for heparin in mast cells of urticaria pigmentosa. *A.M.A. Arch. Derm. Syph. (Chic.),* **70**, 347 (1954). [D26740

Cornil, L. and **Michon, P.**: Sur la présence de mastocytes dans les tumeurs cutanées de la maladie de Recklinghausen. *C.R. Soc. Biol. (Paris),* **91**, 787 (1924). [D27444

Cottenot, F.: *Contribution à l'étude de la physiologie du mastocyte.* Paris: Librairie Arnette (1954). [D27990

——: Recherches physio-pathologiques sur le mastocyte et les mucopolysaccharides de la substance fondamentale. *Ann. Méd.,* **56**, 305 (1955). [D26657

Cottini, G. B.: Persistenti pigmentazioni cutanee circoscritte da orticaria in soggetto malarico con particolare reperto istologico. *G. ital. Derm. Sif.,* **88**, 131 (1947). [D39837

Coulant, ?., Le, *cf.* Le Coulant, ?. [D63187

Couperus, M.: Case for diagnosis: Bullous pemphigoid? Bullous urticaria pigmentosa? *A.M.A. Arch. Derm.,* **75**, 762 (1957). [D39621

Coupland, R. E.: Mast cells and chromaffin cells. *Ann. N.Y. Acad. Sci.,* **103**, 139 (1963). [D58276

——, and **Heath, I. D.**: Chromaffin cells, melanophores and mast cells. *J. Endocr.,* **20**, xxvii (1960). [D26426

——, and ——: Chromaffin cells, mast cells and melanin. I.The granular cells of the skin. *J. Endocr.,* **22**, 59 (1961). [D2439

——, and ——: Chromaffin cells, mast cells and melanin. II. The chromaffin cells of the liver capsule and gut in granulates. *J. Endocr.,* **22**, 71 (1961). [D2440

——, and **Riley, J. F.**: Mast cells and 5-hydroxytryptamine in precancerous mouse skin. *Nature (Lond.),* **187**, 1128 (1960). [D26772

Crabb, E. D.: Effect of mast cell products on capillary permeability. In: *University of Colorado Studies.* Colorado: Boulder & Dewer, **4**, 1 (1958). [C53754

——: Serotonin as a mast cell product. In: *University of Colorado Studies.* Colorado: Boulder & Dewer, **4**, 36 (1958). [C53755

——, and **Kelsall, M. A.**: Mast cells and collagen in the thymus of X-irradiated hamsters. *Radiat. Res.,* **5**, 608 (1956). [D28681

——, and ——: Mast cells in endocrine glands of X-irradiated hamsters. *Anat. Rec.,* **128**, 534 (1957). [D28559

Craddock, C. G., Adams, W. S., Perry, S., Skoog, W., and **Lawrence, J. S.**: Studies of leukopoiesis; the technique of leukophoresis and the response of myeloid tissue in normal and irradiated dogs. *J. Lab. clin. Med.,* **45**, 881 (1955). [G17986

Cramer, H. J.: Teleangiectasia macularis eruptiva perstans, eine Sonderform der Urticaria pigmentosa. *Hautarzt,* **15**, 370 (1964). [F18664

Cramer, W.: The early stages of carcinogenesis by 20-methylcholanthrene in the skin of the mouse. II. Microscopic tissue changes. *J. Nat. Cancer Inst.*, **2**, 379 (1942). [D28366

——, and **Simpson, W. L.**: Mast cells in experimental skin carcinogenesis. *Cancer Res.*, **4**, 601 (1944). [D26710

Craps, L.: Contribution à la physiopathologie du mastocyte. *Arch. belges Derm.*, **16**, 346 (1960). [D27704

——: Verhalten der cutanen Mastzellen under physikalischen, chemischen, entzündlichen und allergischen Einflüssen. *Arch. klin. exp. Dermat.*, **213**, 582 (1961). [D12408

Crawford, ?.: Urticaria pigmentosa (acquired). *A.M.A. Arch. Derm. Syph. (Chic.)*, **7**, 563 (1923). [E37589

Crespi, M., and **Celestino, D.**: Sul comportamento della reazione istochimica di Adams negli elementi cellulari di un mastocitoma. *Valsalva*, **40**, 50 (1964). [E38732

Cricchi, M.: Studio delle Mastzellen nella coroide di cavia e di ratto con tecnica istologica a piatto. *G. ital. Oftal.*, **16**, 82 (1963). [D34314

——: Sul comportamento delle Mastzellen di coroide di cavia nello shock anafilattico. *G. ital. Oftal.*, **16**, 181 (1963). [G3043

Crocker, ?.: Xanthelasmoidea, or urticaria pigmentosa. *Brit. J. Derm.*, **18**, 136 (1907). [E37597

Cronberg, S.: The effect of hydrocortisone on mast cells in the peritoneal fluid and mesentery of the rat. *Acta rheum. Scand.*, **7**, 156 (1961). [D16785

——: The effect of combined administration of the histamine liberator 48/80 and hydrocortisone on the mast cells of the rat. *Acta rheum. scand.*, **7**, 174 (1961). [D22426

——, and **Nilsson, I. M.**: The effect of induced fibrinolysis and various substances on the mast cells in the peritoneal fluid and mesentery of the rat. *Acta path. microbiol. Scand.*, **60**, 156 (1964). [G10504

Csaba, G.: The human thymus gland: the problem of the thymus-mastcells. *Acta morph. Acad. Sci. hung.*, **9**, 285 (1960). [D2230

——, **Ács, T., Horváth, C.**, and **Mold, K.**: Genesis and function of mast cells. Mast cell and plasmacyte reaction to induced, homologous and heterologous tumours. *Brit. J. Cancer*, **15**, 327 (1961). [D25636

——, **Horváth, J., Ács, T.**, and **Horváth, C.**: Effect of galvanic current and X-ray-irradiation on the tissue reaction of thymus. *Acta morph. Acad. Sci. hung.*, **10**, 1 (1961). [D3199

——, and **Kapa, E.**: Uptake of heparin by cells. *Nature (Lond.)*, **187**, 711 (1960). [D63190

——, and **Kulmann, L.**: On the physiological control of connective tissue mast cells. *Acta biol. Acad. Sci. hung.*, **14**, 175 (1963). [G2694

——, and **Mold, K.**: Über die Wirkung von Hormonbehandlungen auf die Mastzellenbildung im Thymus der Ratte. *Ztschr. mikros.-anat. Forschg.*, **68**, 163 (1962). [D32196

——, **Törö, I., Ács, T., Kiss, F. I.**: The behaviour of the thymus in conditions associated with tissue proliferation. *Acta morph. Acad. Sci. hung.*, **9**, 187 (1960). [C98159

——, ——, and **Bodoky, M.**: Über die Bildung von Mastzellen im Thymus und den lymphatischen Organen. *Ztschr. mikroskop.-anat. Forschg.*, **70**, 242 (1963). [E36438

——, ——, and ——: Beziehungen zwischen der Funktion von Thymus und Nebennierenrinde und ihre Auswirkung auf den Serumspiegel der sauren Mucopolysaccharide. *Ztschr. mikro.-anat. Forschg.*, **69**, 467 (1963). [E26735

——, ——, ——, **Mold, K.**, and **Horváth, C.**: Data concerning relationship between thymus, lymph node and spleen. *Acta anat. (Basel)*, **44**, 333 (1961). [D33082

——, ——, and **Kapa, E.**: Provoked tissue reaction of the thymus in tissue culture. *Acta morph. Acad. sci. hung.*, **9**, 197 (1960). [D2227

——, ——, and ——: New contributions to the heparin-affinity of the thymus. *Acta morph. Acad. sci. hung.*, **9**, 291 (1960). [D2229

——, ——, and **Mold, K.**: Some new data concerning the functional unity of the 'lymphatic system'. *Acta anat. (Basel)*, **48**, 114 (1962). [D79388

——, ——, and **Vatai, M.**: New contributions to the heparin-affinity of the thymus. II. *Acta morph. Acad. Sci, hung.*, **9**, 297 (1960). [D2228

Curran, R. C.: The elaboration of mucopolysaccharides by vascular endothelium. *J. Path. Bact.*, **74**, 347 (1957). [D27624

Dalcq, A.: La coloration vitale au bleu de toluidine et sa manifestation métachromatique. *C.R. Soc. Biol. (Paris)*, **146**, 1408 (1952). [D31604

——, and **Massart, L.**: Aspects physicochimiques de la métachromasie in vivo au

bleu de toluidine. *C.R. Soc. Biol. (Paris),* **146,** 1436 (1952). [D30530

Danchakoff, V., *cf.* Dantsakoff, V. [D27400

Danilova, K. M.: Debatable problems of the origin and the functional significance of mast cells. (Russian text) *Arkh. Pat.,* **21,** 3 (1958). [D39771

Dantchev, D.: Particularités morphologiques dans la formation des granulocytes éosinophiles et basophiles. *Sang,* **23,** 439 (1952). [D53654

Dantsakoff, V.: Untersuchungen über die Entwicklung von Blut und Bindegewebe bei Vögeln. Das lockere Bindegewebe des Hühnchens im fetalen Leben. *Arch. mikros. Anat.,* **73,** 117 (1909). [A20391

——: The wandering cells in the loose connective tissue of the bird and their origin. *Anat. Rec.,* **10,** 483 (1916). [D27400

Dantschakoff, W., *cf.* Dantsakoff, V. [A20391

Davies, D. V.: The staining reactions of normal synovial membrane with special reference to the origin of synovial mucin. *J. Anat. (Lond.),* **77,** 160 (1943). [D26745

Davis, ?.: Lupus erythematosus treated with trichloracetic acid. *J. cutan. dis.,* **33,** 216 (1915). [E37989

Davis, M. J., Lawler, J. C., and **Higdon, R. S.:** Studies on an adult with urticaria pigmentosa. *A.M.A. Arch. Derm. Syph. (Chic.),* **77,** 224 (1958). [D39697

Dawson, A. B., and **Masur, J.:** Variations in the histological structure of the inguinal lymph nodes of the albino rat. *Anat. Rec.,* **44,** 143 (1929). [D28377

Day, S. M., and **Green, J. P.:** Levels of heparin, histamine and 5-hydroxytryptamine in neoplastic mast cells in vivo. *Fed. Proc.,* **18,** 381 (1959). [C66290

——, and ——: The uptake of amino acids and the synthesis of amines by neoplastic mast cells in culture. *J. Physiol. (Lond.),* **164,** 210 (1962). [D41586

——, and ——: The uptake of biogenic amines by neoplastic mast cells in culture. *J. Physiol. (Lond.),* **164,** 227 (1962). [D41587

——, and ——: Differences in turnover of endogenous and exogenous 5-hydroxytryptophan, 5-hydroxytryptamine, and histamine in neoplastic mast cells in culture. *Biochem. Pharmacol.,* **11,** 1043 (1962). [D39523

——, and ——: Amine metabolism in mast cells (P–815) in culture. *Pharmacologist,* **2,** 68 (1960). [D39829

Day, M., and **Stockbridge, A.:** The effects of drugs on the uptake of amines by mast cells. *Brit. J. Pharmacol.,* **23,** 405 (1964). [G20741

De Azevedo Correia Trincão, R., *cf.* Trincão, R. de A. C. [D26962

Decker, H. B., and **Luscombe, H. A.:** Urticaria pigmentosa? Incontinentia Pigmenti? (Discussion of a case described by Asboe-Hansen). *Arch. Derm. Syph.,* **70,** 675 (1954). [D39696

Degos, R.: Mastocytoses en dehors de l'urticaire pigmentaire. Réticuloses mastocytaires diffuses. *Arch. belges Derm.,* **11,** 10 (1955). [D39791

——: Urticaria pigmentaria y otros tipos de mastocitosis. *Act.dermo-sifiliogr. (Madr.),* **46,** 759 (1955). [D27649

——: Les mastocytoses. *Méd. et Hyg. (Genève),* **9,** 33 (1956). [E57261

——: Les mastocytoses. *Bull. Soc. méd. Hôp. (Paris),* **72,** 111 (1956). [D39776

——: Urticaire pigmentaire et mastocytoses. *Rev. Prat. (Paris),* **13,** 601 (1963). [D58430

——, and **Bellone, A.:** L'âge de l'urticaire pigmentaire. *Bull. Soc. franç. Derm. Syph.,* **54,** 428 (1947). [D39745

——, and **Cottenot, F.:** Physiologie du mastocyte tissulaire. Rôle de la surrénale sur le stockage mastocytaire. *Bull. Soc. franç. Derm. Syph.,* **60,** 228 (1953). [D26857

——, **Delort, J.,** and **Hewitt, J.:** Réticulose à mastocytes. Forme cutanée diffuse sans urticaire pigmentaire. *Bull. Soc. franç. Derm. Syph.,* **61,** 97 (1954). [D39580

——, ——, ——, and **Civatte, J.:** Mastocytose bulleuse. Urticaire pigmentaire, réticulose à mastocytes diffuse, éruptions bulleuses. *Bull. Soc. franç. Derm. Syph.,* **61,** 340 (1954). [D39579

——, ——, and **Ossipowski, B.:** Réticuloses à mastocytes (à propos de deux cas nouveaux). *Bull. Soc. franç. Derm. Syph.,* **60,** 156 (1953). [D39586

——, ——, and **Touraine, R.:** Mastocytose multinodulaire bulleuse avec poussées vaso-motrices généralisées (nouveau cas). *Bull. Soc. franç. Derm. Syph.,* **64,** 150 (1957). [D39578

——, ——, **Verliac, F.,** and **Civatte, J.:** Mastocytose à plaque unique du nourrisson. Poussées bulleuses locales associées à une vaso-dilatation généralisée des téguments. *Bull. Soc. franç. Derm. Syph.,* **62,** 135 (1955). [D39551

——, and **Guilaine, J.:** Mastocytose cutanée diffuse. *Bull. Soc. franç. Derm. Syph.,* **69,** 268 (1962). [E31480

——, **Hewitt, J.,** and **Mortier, M.:** Mastocytome et urticaire pigmentaire. Essai d'injections "in situ" d'hyaluronidase. *Bull. Soc. franç. Derm. Syph.,* **59,** 6 (1952). [D31651

——, **Lortat-Jacob, E., Civatte, J.,** and **Guilaine, J.:** Mastocytose à plaque "unique du pied". *Bull. Soc. franç. Derm. Syph.,* **64,** 150 (1957). [D39601

——, ——, **Hewitt, J.,** and **Ossipowski, B.:** Réticulose à mastocytes. Forme cutanée diffuse. *Bull. Soc. franç. Derm. Syph.,* **59,** 247 (1952). [D30625

——, ——, **Mallarmé, J.,** and **Sauvan, R.:** Réticulose à mastocytes. *Bull. Soc. franç. Derm. Syph.,* **58,** 435 (1951). [D27406

——, and **Touraine, R.:** Les vaccinations au cours des mastocytoses cutanées. *Bull. Soc. franç. Derm. Syph.,* **67,** 254 (1960). [D26820

——, and **Vissian, L.:** Urticaire pigmentaire à efflorescenses turgescentes généralisées et permanentes sans pigmentation (Forme tumorale d'aspect xanthomateux). *Bull. Soc. franç. Derm. Syph.,* **46,** 243 (1949). [D39542

De Graciansky, P., *cf.* Graciansky, P. de [D39637

De la Pava, S., *cf.* Pava, S. de la. [E90345

Delaunay, A.: Le mastocyte: histoire d'une cellule. *Vie méd.,* **43,** 1136, 1281 (1962). [E33429

Del Carril, A. V., et al. *cf.* Carril, A. V. del, et al. [G16997

Del Conte, E., *cf.* Conte, E. del [D26730

Demis, D. J.: The mastocytosis syndrome: clinical and biological studies. *Ann. intern. Med.,* **59,** 194 (1963). [E24240

——, and **Brown, D. D.:** Histidine metabolism in urticaria pigmentosa. *J. invest. Derm.,* **36,** 253 (1961). [E35082

——, **Walton, M. D.,** and **Higdon, R. S.:** Histaminuria in urticaria pigmentosa. A clinical study and review of recent literature with definition of the mastocytosis syndrome. *A.M.A. Arch. Derm.,* **83,** 127 (1961). [D2184

——, ——, **Wooley, D., Wilner, N.** and **McNeil, G.:** Further studies of histidine and histamine metabolism in urticaria pigmentosa. *J. invest. Derm.,* **37,** 513 (1961). [G11134

——, and **Zimmer, J. G.:** Histaminuria in mastocytosis. The effect of ∝-methyldopa on urinary excretion of free histamine. *A.M.A. Arch. intern. Med.,* **111,** 309 (1963). [D58631

Demopoulos, H., Kaley, G., and **Zweifach. B.W.:** Response of granular juxtaglomerular cells and tissue mast cells in various experimental states. *Circulat. Res.,* **9,** 845 (1961). [D26565

Dempsey, E. W., Bunting, H., and **Wislocki, G. B.:** Observations on the chemical cytology of the mammary gland. *Amer. J. Anat.,* **80–81,** 309 (1947). [D28461

De Palo, A., *cf.* Palo, A. de. [C9397

Deringer, M. K., and **Dunn, T. B.:** Mast cell neoplasia in mice. *J. Nat. Cancer Inst.,* **7,** 289 (1947). [D10425

Detrick, L. E.: Mucopolysaccarides in post-irradiation intestinal absorption studies. *Ann. N.Y. Acad. Sci.,* **106,** 636 (1963). [D63287

Deutsch, E., Ellegast, H., and **Nosko, L.:** Knochen- und Blutgerinnungsveränderungen bei Urticaria pigmentosa. *Hautarzt,* **7,** 257 (1956). [D28280

De Viñals, R. R. *cf.* Viñals, R. R. de. [D13202, D30196

Devitt, J. E., Pirozynski, W. J., and **Samuels, P. B.:** Mast cell resistance to hormonal influence. *Proc. Soc. exp. Biol. (N.Y.),* **83,** 335 (1953). [B84254

——, and **Samuels, P. B.:** The relation of the mast cell to blood coagulation theory. *Surg. Forum,* **4,** 197 (1953). [D26863

——, ——, **Pirozynski, W. J.,** and **Webster, D. R.:** Morphology of tissue mast cells: the frequency of artifacts and the influence of certain biologic agents. *Amer. J. Path.,* **30,** 391 (1954). [B96691

Dewar, W. A., and **Milne, J. A.:** Bullous urticaria pigmentosa. Summary of literature and report of two cases. *A.M.A. Arch Derm. Syph. (Chic.),* **71,** 717 (1955). [D39692

Diamant, B.: Histamine release elicited by extracts from Ascaris suis. Influence of oxygen lack and glucose. *Acta physiol. scand.,* **52,** 8 (1961). [D26421

——: Further observations on the effect of anoxia on histamine release from guinea-pig and rat lung tissue in vitro. *Acta physiol. scand.,* **56,** 1 (1962). [D33745

——, and **Uvnäs, B.:** Evidence for energy-requiring processes in histamine release and mast cell degranulation in rat tissues induced by compound 48/80. *Acta physiol. scand.,* **53,** 315 (1961). [D17009

Díaz, C. J., and **Guedes, J. R.:** Metacromasia, células cebadas e hipertensión arterial. *Rev. clin. esp.,* **64,** 364 (1957). [E56717

Dickison, G. J.: Urticaria pigmentosa with mast cell tumor (in Zackheim discussion). *A.M.A. Arch. Derm.,* **75,** 140 (1957) [E53143

Dieudonné, J. M.: Effect of cyproheptadine on a topical calcification in the rat. *Canad. J. Physiol. Pharmacol.,* **42,** 349 (1964). [E24128

——: A calcifying topical reaction to mast-cell depletors in the rat. *Experientia (Basel),* **20,** 209 (1964). [E24129

Diezel, P. B. and **Neimanis, G.:** Über Farbwertänderungen von Azofarbstoffen. Ein Beitrag zum Problem der Metachromasie. *Ztschr. Zellforschg. Abt. Histochem.,* **1,** 151 (1959). [D27958

el-Din, O. M., Gabr, M., Saadani, M., and **Sallam, F.:** Blood basophils in thyroid disorders. *J. Egypt. med. Ass.,* **44,** 300 (1961). [D96623

Dixon, J. B.: Histamine, 5-hydroxytryptamine and serum globulins in the foetal and neo-natal rat. *J. Physiol. (Lond.),* **147,** 144 (1959). [D65094

Doan, C. A., and **Reinhart, H. L.:** The basophil granulocyte, basophilcytosis, and myeloid leukemia, basophil and 'mixed granule' types; and experimental, clinical and pathological study, with the report of a new syndrome. *Amer. J. clin. Path.,* **11,** 1 (1941). [D26488

Dockrill, T. E.: Tissue mast cells in the oral cavity. *Austral. dent. J.,* **6,** 210 (1961). [G10498

Dodd, D. C.: Mastocytoma of the tongue of a calf. *Path. vet.,* **1,** 69 (1964). [D19424

Dore, S. E.: Case of urticaria pigmentosa in an adult. *Proc. Roy. Soc. Med.,* **9,** 11 (1916). [D29282

Dougherty, T. F., and **Schneebeli, G. L.:** Microcinematographic demonstration of mast cell disintegration in living isolated loose connective tissue of mice. *Fed. Proc.* **17,** 37 (1958). [D61515

Douglas, C. R., Escobar, E., Suarez, R., Cisternas, R., Guiloff, S., Arrovo, P., and **Rosenkranz, A.:** Role of the mast cells in the tissue and serum lipoprotein lipase activity of the rat. *Acta physiol. lat.-amer.,* **12,** 259 (1962). [G9087

——, **Jorquera, J. A., Parez, V., Escobar, E.,** and **Rosenkranz, A.:** Mucopolysaccharide content of the arterial wall of the rat upon emptying of the mast cells. *Acta physiol. lat.-amer.,* **14,** 37 (1964). [E42119

——, **Perelman, M., Oberti, C., Escobar, E.,** and **Talesnik, J.:** Influence of the mast cells upon the development of experimental atherosclerosis in the rat. *Acta physiol. lat.-amer.,* **12,** 271 (1962). [G9086

Downey, H.: The lymphatic tissue of the kidney of Polyodon spathula. *Folia haemat. (Lpzg.),* **8,** 415 (1909). [D27983

——: Die Entstehung von Mastzellen aus Lymphocyten und Plasmazellen. *Verhandl. anat. Gesellsch. (Jena).* **25,** 74 (1911). [D33660

——: The development of the histogenous mast cells of adult guinea pig and cat, and the structure of the histogenous mast cells of man. *Folia haemat. (Basel),* **16,** 49 (1913). [D26823

——: Heteroplastic development of eosinophil leucocytes and of hematogenous mast cells in bone marrow of guinea pig. *Anat. Rec.,* **8,** 135 (1914). [D27880

——: The origin and development of eosinophil leucocytes and of haematogenous mast cells in the bone marrow of adult guinea pig. *Folia haemat. (Lpzg.)* **19,** 148 (1915). [D27429

Drabe, J.: Über das Vorkommen und die Bedeutung der Gewebsmastzellen in menschlichen Gaumenmandeln. *Arch. Ohren, Nasen, Kehlk.-Heilk.,* **177,** 174 (1961). [D26852

Dragstedt, C. A., Wells, J. A., and **Rocha e Silva, M.:** Inhibitory effect of heparin upon histamine release by trypsin, antigen, and proteose. *Proc. Soc. Exper. Biol. (N.Y.),* **51,** 191 (1942). [A55982

Draper, L. R., and **Smith, D. E.:** A function for tissue mast cells. *Science* **134,** 842 (1961). [D26649

Dreifuss, W., and **Bloch, B.:** Über die künstliche Erzeugung von metastasierenden Mäusecarcinomen durch Bestandteile des Teerpeches. *Arch. Derm. Syph. (Berlin),* **140,** 6 (1922). [D27078

Drennan, J. M.: The mast cells in urticaria pigmentosa. *J. Path. Bact.,* **63,** 513 (1951). [D26722

——, and **Beare, M.:** Investigations in a case of urticaria pigmentosa. *Brit. J. Derm.,* **63,** 257 (1951). [D92234

——, and ——: Solitary mast-cell naevus. *J. Path. Bact.,* **68,** 354 (1954). [D26760

Dreyfus, B.: Cytologie du ganglion normal. *Thèse Université de Paris* (1940). [E57445

Drzewina, A.: Sur les mastzellen du ganglion lymphatique du Didelphys lanigera, Desmarest. *C.R. Soc. Biol. (Paris),* **55,** 832 (1903). [D27511

Du Bois, C. C., *cf.* Bois, C. C. du. [D27594

Dubreuilh, W.: Un cas d'urticaire pigmentaire. *Ann. Derm. Syph. (Paris),* **3,** 494 (1912). [E37598

Ducati, C. C.: Le Mastzellen. *Gazz. Osp. Clin.,* **26,** 1428 (1905). [D30559

Ducci, L.: Le strutture mucose della membrana sinoviale in alcune condizioni patologiche. *Arch. De Vecchi Anat. pat.,* **8,** 451 (1946). [D39802

Dugois, P.: Un cas d'urticaire pigmentaire. *Bul. Soc. franç. Derm. Syph.* **58,** 78 (1948). [D39741

Duguid, J. P., Smith, I. W., and **Wilkinson, J. F.:** Volutin production in bacterium aerogenes due to development of an acid reaction. *J. Path. Bact.,* **67,** 289 (1954). [D27621

Dunér, H. and **Pernow, B.:** Histamine. In: *Euler et al., Comparative endocrinology. II. Part 2. Tissue Hormones.* New York, London: Academic Press, p. 239 (1963). [E4176

Dunn, M. R., and **Montgomery, P. O.:** A study of the relationship of mast cells to carcinoma in situ of the uterine cervix. *Lab. Invest.,* **6,** 542 (1957). [D99754

Dunn, T. B.: Normal and pathologic anatomy of the reticular tissue in laboratory mice, with a classification and discussion of neoplasms. *J. nat. Cancer Inst.,* **14,** 1281 (1954). [D27626

——: Discussions. (Various authors: Round table discussion on mast cells and basophils.) *Ann. N.Y. Acad. Sci.,* **103,** 441 (1963). [D58297

——, and **Andervont, H. B.:** Histology of some neoplasms and non-neoplastic lesions found in wild mice maintained under laboratory conditions. *J. nat. Cancer Inst.,* **31,** 873 (1963). [E29999

——, and **Potter, M.:** A transplantable mast-cell neoplasm in the mouse. *J. nat. Cancer Inst.,* **18,** 587 (1957). [D27625

Duperrat, B., and **Grupper, C.:** Y-a-t-il un lien entre l'urticaire pigmentaire du nouveau-né et la gonococcie maternelle? *Bull. Soc. franç. Derm. Syph.,* **58,** 459 (1951). [D39544

——, and **de Sablet, ?.:** Mastocytose xanthelasmoïde. *Bull. Soc. franç. Derm.,* **59,** 250 (1952). [D30628

Duthie, E. S.: The origin, development and function of the blood cells in certain marine teleosts. Part I, Morphology. *J. Anat. (Lond.),* **73,** 396 (1939). [D27611

Dutta-Choudhuri, R., and **Roy, H.:** Effects of ionizing radiations on tissue mast cells. *Int. J. appl. Radiat.,* **4,** 268 (1958-59). [D65258

Dyrbye, M. O., Ahlquist, J., and **Wegelius, O.:** Effect of thyroxine, thyrotrophic and somatotrophic hormones on skin of dwarf mice. *Proc. Soc. exper. Biol. (N.Y.),* **102,** 417 (1959). [C77936

Ebling, H., and **Barbachan, J. J. D.:** Mast cells in the periodontal membrane of rat. *J. dent. Res.,* **42,** 890 (1963). [E20443

Eckert, D., and **Tötterman, G.:** On the histamine content of the white blood corpuscles, with special references to the eosinophils. *Scand. J. Clin. Lab. Invest.,* **2,** 58 (1950). [D28660

Eckstein, M., Lindner, J., and **von Schweinitz, H. A.:** Das Säure-Blasen-Gleichgewicht im Bindegewebe und davon abhängige Veränderungen unter dem Einfluss von 1,2-Diphenyl-3,5-dioxo-4-n-butylpyrazolidin. *Arzneimittel-Forschg.,* **10,** 902 (1960). [D98735

Edelstein, A. J.: Urticaria pigmentosa with bone changes. *A.M.A. Arch. Derm.,* **74,** 676 (1956). [D31574

Eder, M. and **Schauer, A.:** Fermenthistochemische und experimentelle Untersuchungen an Gewebsmastzellen. *Beitr. pathol. Anat.,* **124,** 251 (1961). [D33687

Efrati, P., Klajman, A., and **Spitz, H.:** Mast cell leukemia? Malignant mastocytosis with leukemia-like manifestations. *Blood,* **12,** 869 (1957). [D25560

Ehmann, B.: Die angeborene Mastzellenretikulose. *Ztschr. Kinderheilk.,* **87,** 282 (1962). [D39810

Ehrenbrand, F.: Beiträge zur Orthologie der lactierenden Milchdrüse. Teil I. *Acta histochem. (Jena),* **18,** 1 (1964). [F15603

——: Über die Mastzellen im Paraganglion caroticum des Kalbes. *Anat. Anzgr.,* **115,** 297 (1964). [D19113

Ehrich, W. E.: Histamine in mast cells. *Science,* **118,** 603 (1953). [D26427

——, **Seifter, J., Alburn, H. E.,** and **Begany, A. J.:** Heparin and heparinocytes in elephantiasis scroti. *Proc. Soc. Exper. Biol. (N.Y.),* **70,** 183 (1949). [D26791

Ehrlich, P.: Beiträge zur Kenntniss der Anilinfärbungen und ihrer Verwendung in der mikroskopischen Technik. *Arch. mikros. Anat.,* **13,** 263 (1877). [D26864

——: Beiträge zur Theorie und Praxis der histologischen Färbung. *Thesis. University of Leipzig,* 1878. [D40102

——: Beiträge zur Kenntnis der granulierten Bindegewebszellen und der eosinophilen Leukocythen. *Arch. Anat. Physiol.,* **3,** 166 (1879). [D27092

——: *Farbenanalytische Untersuchungen zur Histologie und Klinik des Blutes.* Berlin: Hirschwald, (1891). [D31521

——, and **Lazarus, A.:** *Die Anämien.* Wien: Hölder (1898). [D50996

Einbinder, J. M., Nelson, C. T., Walzer, R. A., and **Fox, C. L.:** Role of mast cells and coagulation factors in anaphylaxis in mice. *Fed. Proc.,* **22/1,** 599 (1963). [G5491

——, **Walzer, R. A.,** and **Nelson, C. T.:** The role of the mast cell in anaphylaxis in the mouse. *J. Immunol.,* **93,** 165 (1964). [G18460

Eisen, V. D., Ellis, R. E., and **Wilson, C. W. M.:** The effect of X-irradiation on tissue histamine in the rat. *J. Physiol. (Lond.),* **133,** 506 (1956). [C26528

——, and **Wilson, C. W. M.:** The effect of β-irradiation on skin histamine and vascular responses in the rat. *J. Physiol. (Lond.),* **136,** 122 (1957). [D65095

Ekman, C. A., and **Naumann, B.:** On the presence of mast cells in thyroid glands from guinea-pig and from man, under different conditions. *Acta path. microbiol. scand.* **22,** 271 (1945). [B4771

El-Din, O. M., et al., *cf.* el-Din, O. M., et al. [D96623

Eliascheff, O.: Un cas d'urticaire pigmentaire chez l'adulte. *Bull. Soc. franç. Derm. Syph.,* **28,** 17 (1921). [E37599

Elliott, A. R., and **Young, R. H.:** Myelogenous leukemia. *Med. Clin. N. Amer.,* **15,** 569 (1931). [G18734

Ellis, J. M.: Urticaria pigmentosa. A report of a case with autopsy. *A.M.A. Arch. Path.,* **48,** 426 (1949). [D27355

El-Mofty, A. M., *cf.* el-Mofty, A. M. [D56904

Ende, J., and **Auditore, J. V.:** Mast cells and fibrinolysin. *Nature (Lond.),* **189,** 593 (1961). [D26826

——, and ——: Fibrinolytic activity of human tissues and dog mast cell tumors. *Am. J. clin. Path.,* **36,** 16 (1961). [D43914

——, and ——: Proteolytic enzyme and tissue activator associated with canine mast cell tumour. *Biochem. Pharmacol.,* **8,** 152 (1961). [G4543

——, and ——: Esterolytic activity of canine and human mast cells. *Amer. J. Clin. Pathol.,* **38,** 501 (1962). [D39511

——, and ——: A fibrinolytic system in normal dogs and a dog with mast cell tumor. *Fed. Proc.,* **23/1,** 577 (1964). [F5869

——, and ——: Activation of a fibrinolytic system in a dog with mast cell tumor. *Amer. J. Physiol.,* **206,** 567 (1964). [F6349

——, and **Cherniss, E. I.:** Mast cells, histamine and serotonin. Studies of the human spleen. *Am. J. clin. Path.,* **30,** 35 (1958). [C55644

——, and ——: Splenic mastocytosis. *Blood,* **13,** 631 (1958). [D39554

——, **Katayama, Y.,** and **Auditore, J. V.:** Multiple proteolytic enzymes in the human mast cells. *Nature (Lond.),* **201,** 1197 (1964). [F6607

Endicott, K. M., and **Ott, M.:** The normal myelogram in albino rats. *Anat. Rec.* **92,** 61 (1945). [D27358

Enerbäck, L.: Serotonin in human mast cells. *Nature (Lond.),* **197,** 610 (1963). [D39849

Engelberg, H.: Plasma heparin levels in man following intravenous fat emulsions. *Proc. Soc. exp. Biol. (N.Y.),* **97,** 304 (1958). [D27081

Engelbreth-Holm, J., and **Asboe-Hansen, G.:** Effect of cortisone on skin carcinogenesis in mice. *Acta path. microbiol. scand.,* **32,** 560 (1953). [D27522

Engleson, G., and **Lindberg, T.:** Basophil leucocytes and heparinoid substances in diabetes mellitus. *Acta paediat.,* **52,** 87 (1962). [D54609

Epstein, B., and **Martin, A. A.:** Primera comprobación del mastocitoma canino. *Rev. Med. vet. (B. Aires),* **44,** 391 (1963). [E75754

Ercoli, O.: Su di un caso di urticaria pigmentosa in adulto. *G. ital. Mal. vener.,* **44,** 354 (1909). [G2956

Ernst, T.: Über die ersten Stunden der Entzündung. *Beitr. pathol. Anat. allg. Pathol.,* **75,** 229 (1926). [D26867

Erspamer, V.: 5-Hydroxytryptamine. In: *Euler et al., Comparative Endocrinology. II. Part 2. Tissue Hormone.* New York, London: Academic Press, p. 159 (1963). [E4173

Faber, M.: The human aorta. Sulfate-containing polyuronides and the deposition of cholesterol. *A.M.A. Arch. Path.,* **48,** 342 (1949). [D29294

Fabris, A.: Mastocitomi cutanei da catrame. *Pathologica,* **19,** 157 (1927). [D39684

Fabry, J.: Über Urticaria pigmentosa congenita. *Arch. Dermat. Syph. (Berlin),* **113,** 269 (1912). [E38151

Fábry, P., Braun, T., Petrásek, R., Franková, S., Masek, J., and **Fodor, J.:** Některé vlivy vysokotukových diet v experimenty na zvířeti. *Cs. Gastroent. Výž.,* **16,** 178 (1962). [E45801

Fadem, R. S.: Tissue mast cells in human bone marrow. *Blood,* **6,** 614 (1951). [D26720

Fagundes, J. J. M., *cf.* Mendes Fagundes, J. J. [D39676

Fahr, ?.: Ein Beitrag zum Studium der Mastzellen. *Virchows Arch. pathol. Anat.,* **179,** 450 (1905). [D29298

Falck, B.: Observations on the possibilities of the cellular localization of monamines by a fluorescence method. *Acta physiol. scand.,* **56,** sup. 197 (1962). [D46277

——, **Nystedt, T., Rosengren, E.,** and **Stenflo, J.:** Dopamine and mast cells in ruminants. *Acta pharmacol. (Kbh.),* **21,** 51 (1964). [G19000

Fan, J., and **Sikov, M.R.:** The effects of P32 on the mast cells in the skin of rats. *J. invest. Derm.,* **30,** 167 (1958). [D27070

Fawcett, D. W.: Cytological and pharmacological observations on the release of histamine by mast cells. *J. exp. Med.,* **100,** 217 (1954). [D26771

——: An experimental study of mast cell degranulation and regeneration. *Anat. Rec.,* **121,** 29 (1955). [D26781

Fawcett, W.: Correlated cytological and pharmacological observations on the release of histamine by mast cells. *Anat. Rec.,* **118,** 297 (1954). [D28375

Feagler, J. R., and **McManus, J. F. A.:** Extraction resistance of Sudan stained mast cells after previous acid treatment. *J. Histochem. Cytochem.,* **12,** 530 (1964). [G19927

Federici, F.: Un nuovo metodo per la colorazione specifica delle Mastzellen. *Anat. Anzgr.,* **29,** 357 (1906). [D27595

Feldberg, W.: On some physiological aspects of histamine. *J. Pharm. Pharmacol.,* **6,** 281 (1954). [D31609

——, and **Talesnik, J.:** Reduction of tissue histamine by compound 48/80. *J. Physiol. (Lond.),* **120,** 550 (1953). [D27605

Ferluga, J., Nikulin, A., and **Stern, P.:** Die antiphlogistische Wirkung der Epsilon-Amino-Kapronsäure. *Allergie u. Asthma,* **9,** 18 (1963). [D68157

Fernando, N. V. P., and **Movat, H. Z.:** The fine structure of connective tissue. III. The mast cell. *Exp. molecul. Path.,* **2,** 450 (1963). [E28375

Fernex, M.: Note sur les variations du nombre des mastocytes dans le myocarde du poulet et du singe au cours de la malaria expérimentale. *Acta trop. (Basel),* **16,** 362 (1959). [D26721

——: Contribution à l'étude physio-pathologique des mastocytes dans le myocarde. *Actualités cardiol.,* **9,** 269 (1960). [E20417

——: Répercussions phisio-pathologiques de la variation du nombre des mastocytes dans le myocarde. *Méd. Afr. noire,* **8,** 90 (1961). [D39603

——: Mast cells in the myocardium. *Acta trop. (Basel),* **18,** 177 (1961). [D26660

——: Die Mastzellenzahl in ihrer Beziehung zur Atherosklerose. *Helv. med. Acta.,* **28,** 534 (1961). [D26839

——: Eosinophilie et mastocytose. Physiopathologie des hyperéosinophilies. Etude expérimentale et clinique. *Bull. Soc. Pathol. exot.,* **55,** 508 (1962). [D66465

——: L'urticaire pigmentaire généralisée de l'adulte: une mastocytose. *Schweiz. med. Wchnschr.,* **92,** 608 (1962). [D39200

——: Mast cells and helminthic diseases. Pathogenesis of mastocytosis. Its consequences: eosinophilia and fibroplasia. *Ann. Soc. belge Med. trop.,* **43,** 325 (1963). [G9088

——: Herzläsionen bei Carcinoidsyndrom und Endomyokardfibrose. Pathogenetische Bedeutung der Mastzellen. *Cardiologia (Basel),* **44,** 157 (1964). [G10072

——, and **Bèzes, H.:** Increased number of mast cells and helminthic diseases in man. Clinical observations. *Acta trop. (Basel),* **19,** 252 (1962). [D39821

——, and **Fernex, P.:** Increased number of mast cells and helminthic diseases. Experimental mastocytosis in mice. *Acta trop. (Basel),* **19,** 248 (1962). [D39820

——, and **Sarasin, R.:** Topographical distribution of mast cells in human skin. Pathogenesis of tropical elephantiasis. *Acta trop. (Basel),* **19,** 258 (1962). [D39822

Fernö, O., Högberg, B., and **Uvnäs, B.:** The inhibitory action of a polycarboxylic acid on the disruption of mast cells and liberation of histamine produced by compound 48/80, ascaris extract, antigen-antibody reaction or phospholipase A. *Acta pharmacol. (Kbh.),* **17,** 18 (1960). [D23700

Fernström, A. I. B.: Studies on procaine allergy with reference to urticaria due to procaine penicillin treatment. *Acta derm.-venereol. (Stockh.),* **39,** 433 (1959). [D86793

Ferrara, A.: *Boll. Soc. ital. Emat.,* **1,** 1 (1951). [G18735

——: *Clin. Ter.,* **3,** 128 (1952). [G18736

——: *Boll. Soc. ital. Emat.,* **2,** 1 (1953). (as quoted in Lennertetal. D26,471.) [G18737

Ferràta, A.: Ricerche sul potere comotropo dei granuli delle mastcellule. *Haematologica,* **24,** 735 (1942). [D39598

——, and **Golinelli, A.:** Sui globuli bianchi con granulazioni basofile, *Folia clin. Chim. Micro.,* **2,** ? (1910). [D59519

——, and **Storti, E.**: *Le Malattie del Sangue.* Milano: Francesco Vallardi (1946). [E2368

Ferroni, E.: Sulla presenza e sulla distribuzione delle cosidette 'Mastzellen' nella membrana amnios. *Arch. ital. Ginec.,* **1,** 447 (1898). [D69360

Filipo, D., and **Bernicchi, L.**: Il comportamento delle Mastzellen nelle tonsilliti. *Boll. Mal. Orecch.,* **75,** 93 (1957). [D84681

Fink, A. I., and **Gay, L. N.**: A critical review of 170 cases of urticaria and anioneurotic edema followed for a period of from two to ten years. *J. Allergy,* **5,** 615 (1934). [E53861

Fink, M. S., and **Rothlauf, M. V.**: In vitro anaphylaxis in the sensitized mouse uterus. *Proc. Soc. Exper. Biol. (N.Y.),* **90,** 477 (1955). [D31599

Finnerud, C. W.: Urticaria pigmentosa (nodular type) with a summary of the literature. *A.M.A. Arch. Derm. Syph., (Chic.),* **8,** 344 (1923). [E35353

Fiocca, S., and **Baroni, C.**: Aspetti morfologici e comportamento mastociti nelle endometriopatie displastiche. *Arch. De Vecchi Anat. pat.,* **40,** 731 (1963). [G19159

Fiore-Donati, L., de Benedictis, G., Chiecobianchi, L., and **Bertaccini, G.**: Development of mast cell reaction during chemical skin carcinogenesis of mouse. *Nature (Lond.),* **193,** 287 (1962). [D26837

——, and **Moltke, E.**: Effect of reserpine, 5-hydroxytryptamine, and polymyxin B on mast cells and tensile strength of healing wounds. *Acta endocr. (Kbh.),* **34,** 430 (1960). [C88372

Fisher, E. R.: Tissue mast cells. *J. Amer. med. Ass.,* **173,** 171 (1960). [C85479

——, and **Hellstrom, H. R.**: Effect of mast cell depletion on wound healing. *J. invest. Dermat.,* **36,** 189 (1961). [D6683

——, and **Paar, J.**: Carrageenin granuloma in the guinea pig and rat. I. Effect of hydrocortisone, estradiol and mast cell depletion on its histological and histochemical features. *A.M.A. Arch. Path.,* **70,** 565 (1960). [C94668

Floderus, S.: Untersuchungen ueber den Bau der menschlichen Hypophyse mit besonderer Berücksichtigung der quantitativen mikromorphologischen Verhältnisse. *Acta path. microbiol. scand.,* sup., 53, 1 (1944). [B27201

Fodor, J., Fábry, P., and **Lojda, Z.**: High fat diet and mast cell count in rat mesenterium. *Experientia (Basel),* **14,** 184 (1958). [D33723

——, ——, and ——: Der Einfluss langfristiger Verabreichung von Diäten mit hohem Fettgehalt auf die Anzahl der Mastzellen im Mesenterium von Ratten. *Virchows Arch. pathol. Anat.,* **333,** 582 (1960). [D26899

——, and **Lojda, Z.**: On the relationship of heparinocytes to the transport of fats. *Physiol. bohemoslov.,* **5,** 275 (1956). [D65270

Foerster, ?., and **Baer, ?.**: Urticaria pigmentosa. *J. cutan. Dis.,* **31,** 436 (1913). [E38138

Foley, W. A., and **Glick, D.**: Histamine, mast, and parietal cells in stomachs of rats and effects of cortisone treatment. *Gastroenterology,* **43,** 425 (1962). [D39767

Folkman, J., Long, D. M., and **Becker, F. F.**: Growth and metastasis of tumor in organ culture. *Cancer,* **16,** 453 (1963). [D63244

Follis, R. H.: Effect of proteolytic enzymes and fixation on metachromasia of skin collagen. *Proc. Soc. exp. Biol. (N.Y.),* **76,** 272 (1951). [D25569

Fontanini, F., Marchi, O., Rivi, A., and **Signorelli, S.**: Alterazioni morfologiche indotte da alcuni farmaci nelle Mastzellen del mesentere del ratto. *Arch. E. Maragliano Pat. Clin.,* **14,** 23 (1958). [D39752

Fordyce, ?.: Urticaria pigmentosa. *J. cutan. Dis.,* **34,** 120 (1916). [E38139

——: Urticaria pigmentosa. *J. cutan. Dis.,* **35,** 543 (1917). [E38142

——: Urticaria pigmentosa (adult type). *A.M.A. Arch. Derm. Syph. (Chic.),* **2,** 264 (1920). [E38163

Forkner, C. E.: Material from lymph nodes of man. II. Studies on living and fixed cells withdrawn from lymph nodes of man. *Arch. int. Med.,* **40,** 647 (1927). [D33709

——: Blood and bone marrow cells of the domestic fowl. *J. exp. Med.,* **50,** 212 (1929). [D27716

——: Material from lymph nodes. IV. The heterology of lymphoid tissue with special reference to the monocyte-supravital studies. *J. exp. Med.,* **49,** 323 (1929). [D28957

——: Basophils and basophilic leukemia. In: *Forkner, Leukemia and Allied Disorders.* New York: Macmillan, p. 68, p. 181 (1938). [G16566

——: *Leukemia and Allied Disorders.* New York: MacMillan Co. (1938). [E4337

Foster, R. F., and **Layman, J. D.**: Generalized urticaria with electrocardiographic

changes simulating myocardial infarction. *J. Amer. med. Ass.,* **148,** 203 (1952). [E56241

Fox, C.: Urticaria pigmentosa. *Brit. J. Derm.,* **19,** 251 (1907). [E37441

Fox, G. H.: Urticaria pigmentosa. *J. cutan. Dis.,* **28,** 676 (1910). [E38155

——: Urticaria pigmentosa (?). *J. cutan. Dis.,* **29,** 495 (1911). [E38148

Fox, H.: Urticaria pigmentosa. *J. cutan.* Dis., **30,** 21 (1912). [E38008

——: Urticaria pigmentosa. *A.M.A. Arch. Derm. Syph. (Chic.),* **4,** 407 (1921). [E37590

Fox, T.: On xanthelasmoides (an undescribed eruption). *Trans. Clin. Soc. Lond.,* **8,** 53 (1875). [G18411

Frain-Bell, W.: Urticaria pigmentosa in identical twins. *Brit. J. Derm.,* **70,** 426 (1958). [D39663

Franco, E. E., and **Affonso, C.:** Sulla produzione del cancro e sul comportamento delle Mastzellen nei topi trattati col catrame. *Pathologica,* **16,** 445 (1924). [D26878

——, and ——: Le alterazioni istologiche di alcuni organi interni dei topi trattati col catrame. *Pathologica,* **18,** 8 (1926). [D39765

Franks, A. G., and **Weidman, A. I.:** Urticaria pigmentosa (associated with diffuse bone lesions). 2. Granuloma annulare (treated with intralesional injections of triamcinolone). *A.M.A. Arch. Derm.,* **83,** 1030 (1961). [D12544

Franzen, F.: Zur Pathophysiologie der endokrin-aktiven Phäochromocytome, Carcinoide und Mastocytome. *Dtsch. Arch. klin. Med.,* **207,** 571 (1962). [E44409

Fredholm, B.: Effects of histamine-liberators on neoplastic mast cells. *Biochem. Pharmacol.,* **12,** sup. 212 (1963). [E32253

——, **Högberg, B.,** and **Uvnäs, B.:** Role of phospholipase A and C in mast cell degranulation induced by non-purified Clostridium Welchii toxin. *Biochem. Pharmacol.,* **5,** 39 (1960). [D26853

Fredricks, R. E., and **Moloney, W. C.:** The basophilic granulocyte. *Blood,* **14,** 571 (1959). [D84020

Freeman, L., Marx, L., and **Marx, W.:** Tissue heparin and mast cells in rats and rabbits. *Fed. Proc.,* **15,** 255 (1956). [D29475

Fregert, S., and **Rorsman, H.:** Basophil leukocytes in intracutaneous test reactions to metals. *J. Invest. Dermat.,* **41,** 361 (1963). [E35551

French, J. E., and **Benditt, E. P.:** The histochemistry of connective tissue: II. The effect of proteins on the selective staining of mucopolysaccharides by basic dyes. *J. Histochem. Cytochem.,* **1,** 321 (1953). [D31601

Frenger, W., Scheiffarth, F., Gemählich, M., and **Eberlein, F.:** Untersuchungen über die Gewebsmastzellen bei der adrenalektomierten Ratte. *Allergie u. Asthma,* sup., 4, 311 (1961). [D25504

Friberg, U., Graf, W., and **Åberg, B.:** On the histochemistry of the mast cells. *Acta path. microbiol. scand.,* **29,** 197 (1951). [C72065

Frick, R.: Zur Physiopathologie der Mastzellen (Heparinspeicherung und -ausschüttung). *Thesis, University of Zürich* (1950). [B62124

Friedberger, E.: Weitere Untersuchungen über Eiweissanaphylaxie. IV. Mitteilg. *Ztschr. Immun.-Forschg.,* **4,** 636 (1910). [A20976

Friedlaender, S., and **Friendlaender, A. S.:** Observations on basophil degranulation as an indicator of antigen-antibody reaction. *J. Allergy,* **35,** 361 (1964). [G18240

Friedman, B. I., Will, J. J., Freiman, D. G., and **Braunstein, H.:** Tissue mast cell leukemia. *Blood,* **13,** 70 (1958). [D26445

Fromme, ?.: Demonstration ueber das Verhalten der Mastzellen beim Karzinom. *Zentralbl. Gynäk.,* **30,** 1146 (1906). [D26217

Fullmer, H. M.: Differences in mechanism in staining reactions for mast cells. *Nature (Lond.),* **183,** 1274 (1959). [D27394

Fulton, G. P., and **Maynard, F. L.:** Effect of cortisone on tissue mast cells in the hamster cheek pouch. *Proc. Soc. exp. Biol. (N.Y.),* **84,** 259 (1953). [D27953

——, ——, **Riley, J. F.,** and **West, G. B.:** Humoral aspects of tissue mast cells. *Physiol. Rev.,* **37,** 221 (1957). [C35831

——, ——, and **West, G. B.:** Tissue mast cells in the hamster. *J. Physiol. (Lond.),* **124,** 29P (1954). [D39660

Furano, A. V., and **Green, J. P.:** The compartmentation and elimination of ^{14}C histamine by neoplastic mast cells in culture. *Biochim. biophys. Acta (Amst.),* **86,** 596 (1964). [G18219

——, and ——: The uptake of biogenic amines by mast cells of the rat. *J. Physiol. (Lond.),* **170,** 263 (1964). [G4979

Furth, J., Hagen, P., and **Hirsch, E. I.:** Transplantable mastocytoma in the mouse containing histamine, heparin 5-hydroxytryptamine. *Proc. Soc. exp. Biol. (N.Y.),* **95,** 824 (1957). [C40976

Gabbiani, G.: Inibizione della calcifilassi per mezzo del metiltestosterone. *Sperimentale,* **112**, 457 (1962). [D32379
——, and **Nielsen, K.**: Anaphylactoid inflammation and mastopexis. The role of the mast cell. *A.M.A. Arch. Path.,* **78**, 626 (1964). [G11130
——, and **Rojo Ortega, J. M.**: Stress et calciphylaxie. *Path. et Biol.,* **12**, 192 (1964). [D55958
——, and **Tuchweber, B.**: The role of iron in the mechanism of experimental calcification. *J. Histochem. Cytochem.,* **2**, 799 (1963). [D63219
——, and ——: Studies on mechanism of experimental soft-tissue calcification. *Physiologist,* **7**, 137 (1964). [G11129
——, ——, and **Selye, H.**: A calciphylactic dermatosis produced by histamine liberators. *J. invest. Derm.,* **42**, 49 (1964). [D64692
Gager, ?.: Case for diagnosis: adult urticaria pigmentosa. *A.M.A. Arch. Derm Syph. (Chic.),* **6**, 123 (1922). [E38159
Gamble, H. J., and **Goldby, S.**: Mast cells in peripheral nerve trunks. *Nature (Lond.),* **189**, 766 (1961). [D2298
——, and **Stempak, J. G.**: Observations upon the mast cells of rat foetal tissues. *Experientia (Basel),* **17**, 460 (1961). [D26648
Garcia-Arocha, H.: Release of histamine and 5-hydroxytryptamine from cells of the peritoneal fluid of rats. *Canad. J. Biochem.,* **39**, 395 (1961). [C99920
Gardner, L. I., and **Tice, A. A.**: Histamine and related compounds in urticaria pigmentosa: analyses of tissues having mast-cell infiltration. *Pediatrics,* **21**, 805 (1958). [C52326
Gastreich, F.: Experimentelle Studie zur biologischen Analyse der Entzündungsvorgänge. *Langenbecks Arch. klin. Chir.,* **129**, 621 (1924). [B80067
Gaté, J., Coudert, J., and **Prunierás, M.**: Mastocytomes disséminés. *Bull. Soc. franç. Derm. Syph.,* **61**, 375 (1954). [D39643
——, **Massia, J., Treppoz, G.**, and **Charpy, J.**: Urticaire pigmentaire généralisée atypique par l'intensité du prurit et par le caractère pseudo-tumoral de la plupart des éléments. *Bull. Soc. franç. Derm. Syph.,* **38**, 126 (1931). [D39587
——, and **Michel, P. J.**: Urticaire pigmentaire. *Bull. Soc. franç. Derm. Syph.,* **41**, 1425 (1934). [D39750
——, **Terrier, H.**, and **Pruniéras, M.**: Tumeur à mastocytes chez un enfant de trois mois. *Bull. Soc. franç. Derm. Syph.,* No. 1, 57 (1954). [D39423
Gawecka, I.: Inhibitory effects of toluidine blue on mast cell disruption by pyrogen. *Biochem. Pharmacol.,* **12**, sup., 128 (1963). [E32148
Geiger, R. S., Adachi, C., and **Stone, W. G.**: Behavior and regeneration of mast cells in culture: granule formation and release. *Physiologist,* **7**, 140 (1964). [F11948
Gemählich, M., Frenger, W., and **Scheiffarth, F.**: Untersuchungen zur Morphologie der Mastzellen im Anaphylatoxinschock beim Meerschweinchen. *Int. Arch. Allergy,* **13**, 370 (1958). [D27072
Gemolotto, G., and **Patrone, C.**: Le Mastzellen in alcuni casi di patologia oculare. *Arch. Ottal.,* **65**, 289 (1961). [D64690
Geyer, G.: Histochemische Methylierung mit Methanol und Thionylchlorid. *Acta histochem. (Jena),* **14**, 284 (1962). [D59248
Gherardini, P.: Osservazioni relative alla natura e al significato patologico delle Mastzellen nei tessuti. *Policlinico,* **5**, 323 (1898). [D39596
Ghiara, G.: Ricerche biochimiche, biofisiche e istochimiche intorno al problema della metacromasia. *Ztschr. Zellforschg. Abt. Histochem.,* **1**, 274 (1959). [D27960
Giacometti, C., Rebora, A., and **Bertamino, R.**: Rilievi istochimici sul connettivo e sui mastociti del derma nell'alopecia areata. *Minerva derm.,* **38**, sup., 270 (1963). [E35787
Giani, E.: Sul comportamento della metacromasia stromale e delle Mastzellen nei tumori di origine mesenchimale. *G. ital. Chir.,* **20**, 95 (1964). [D18251
Giannico, O., and **Marrazza, P.**: L'azione della vitamina K su gli eparinociti. *Acta vitamin. (Milano),* **3**, 97 (1947). [D27648
——, and ——: Le modificazioni degli eparinociti da dicumarolo. *Clin. nuova,* **10**, 3 (1950). [B47769
Giarman, N. J., and **Potter, L. T.**: Release of serotonin by extracts of mammalian tissues. *Fed. Proc.* **17**, 371 (1958). [C51848
——, ——, and **Day, M.**: Release of 5-hydroxytryptamine and histamine from neoplastic mast cells by alkaline tissue extracts. *Experientia (Basel),* **16**, 492 (1960). [C99663
Giertz, H.: Wirkstoffbeteiligung an allergischen Reaktionen. *Int. Arch. Allergy,* **22**, 170 (1963). [E20161
Gillman, T.: Mast cell increases after calciferol intoxication and in experimental odoratism. *Acta haemat. (Basel),* **19**, 179 (1958). [C52329
——, and **Hathorn, M.**: Rates of growth and of remodelling as factors in the genesis of vascular and osseous lesions of odoratism

in rats. *J. Embryol. exp. Morph.*, **6**, 270 (1958). [C70377
Ginsburg, H.: The in vitro differentiation and culture of normal mast cells from the mouse thymus. *Ann. N.Y. Acad. Sci.*, **103**, 20 (1963). [D58272
——, and **Sachs, L.**: Formation of pure suspensions of mast cells in tissue culture by differentiation of lymphoid cells from the mouse thymus. *J. nat. Cancer Inst.*, **31**, 1 (1963). [E21572
Giorgi-Ferrari, L. de: Modificazioni di grandezza delle 'Mastzellen' di ratti variamente alimentati (1). *Monit. Zool Ital.*, sup. 44, 266 (1933). [D39835
Glenner, G. G., and **Cohen, L. A.**: Histochemical demonstration of a species-specific trypsin-like enzyme in mast cells. *Nature (Lond.)*, **185**, 846 (1960). [D26769
——, **Hopsu, V. K.**, and **Cohen, L. A.**: Histochemical demonstration of a trypsin-like esterase activity in mast cells. *J. Histochem. Cytochem.*, **10**, 109 (1962). [G5260
Glick, D., Bonting, S. L., and **Denboer, D.**: Use of density gradient for isolation of mast cells. *Proc. Soc. exp. Biol. (N.Y.)*, **92**, 375 (1956). [D26300
——, **Ottoson, R.**, and **Edmondson, P. R.**: Microdetermination of hyaluronidase and its inhibition by fractions of isolated mast cells. *J. biol. Chem.*, **233**, 1241 (1958). [D39641
——, and **Pothapragada, S.**: Succinic dehydrogenase system in isolated mast cells from the rat. *Proc. Soc. exp. Biol. (N.Y.)*, **106**, 359 (1961). [D2215
——, and **Sylvén, B.**: Evidence for the heparin nature of the nonspecific hyaluronidase inhibitor in tissue extracts and blood serum. *Science*, **113**, 388 (1951). [B59009
Godlewski, M.: Les mastocytes du tube digestif et du pancréas. *Arch. Mal. Appar. dig.*, **48**, 1187 (1959). [D26858
——: Les mastocytes du tube digestif. *C.R. Ass. Anat.*, No. 107, 299 (1960). [E51439
Goldenberg, ?.: Urticaria pigmentosa. *J. cutan. Dis.*, **36**, 188 (1918). [E38002
Goldie, H., Turner, T., Faustina, C., Davis, A., and **Greene, E.**: Inhibition by peritoneal tumor growth of mast cell invasion in the peritoneal fluid of normal mice. *Fed. Proc.*, **21**, 165 (1962). [D22813
Goldsmith, W. N., and **Wells, G. C.**: Urticaria pigmentosa verrucosa. *Brit. J. Derm.*, **64**, 200 (1952). [D39589
Goldstein, D. J.: Correlation of size of dye particle and density of substrate, with special reference to mucin staining. *Stain Technol.*, **37**, 79 (1962). [D65537
Gomarasca, P.: Intorno alla natura chimica dei granuli delle Mastzellen. *Boll. Soc. ital. Biol. sper.*, **12**, 182 (1934). [D39761
Gomori, G.: Aldehyde-fuchsin: a new stain for elastic tissue. *Amer. J. clin. Path.*, **20**, 665 (1950). [C14604
——: *Microscopic Histochemistry*. Chicago: University of Chicago Press (1952). [B73271
——: Chloroacyl esters as histochemical substrates. *J. Histochem. Cytochem.*, **1**, 469 (1953). [D28363
——: The histochemistry of mucopolysaccharides. *Brit. J. exp. Path.*, **35**, 377 (1954). [D33670
Gonnella, J. S., and **Lipsey, A. I.**: Mastocytosis manifested by hepatosplenomegaly. Report of a case. *New Engl. J. Med.*, **271**, 533 (1964). [E95219
Goth, A.: Influence of thromboplastins on histamine release from mast cells. *Fed. Proc.*, **20**, 270 (1962). [G7587
Gottheil, ?.: Urticaria pigmentosa. *J. cutan. Dis.*, **29**, 242 (1911). [E38147
Gottlieb, L. S., Robertson, R., and **Zamcheck, N.**: A method for staining mouse mastocytoma. *Am. J. Clin. Path.*, **36**, 336 (1961). [D26743
Gougerot, H., Burnier, ?., and **Eliascheff, O.**: Urticaire 'pigmentaire' avec lésions d'aspect xanthomateux. *Bull. Soc. franç. Derm. Syph.*, **38**, 607 (1931). [D39691
——, **Weill-Spire, ?.**, and **Eliascheff, O.**: Urticaire pigmentaire, atypique cliniquement non pigmentée, typique histologiquement. *Bull. Soc. franç. Derm. Syph.*, **46**, 1453 (1939). [D39729
Gözsy, B., and **Kátó, L.**: *Studies on Phagocytic Stimulation*. Montreal: Institute of Microbiol. and Hygiene, University of Montreal (1957). [C46650
——, and ——: Formation des anticorps dans le rat. *Proc. 30th Congress ACFAS Montreal*, p. 34 (1962). [D36811
——, and ——: Role of toxic factors in anaphylactic shock of rats. I. *Int. Arch. Allergy*, **21**, 138, 151 (1962). [D56953
——, and ——: Investigations into the mechanism of dextran induced edema in rats. *Canad. J. Biochem.*, **41**, 1855 (1963). [E37126
——, and ——: Effect of histamine, serotonin and catecholamine depletors on the capillaries in the rat skin. *Arch. int. Pharmacodyn.*, **148**, 243 (1964). [F6840
Graciansky, P. de, Loewe-Lyon, ?., Crupper, C., and **Taieb, R.**: Mastocytome

unique avec poussée bulleuse. *Bull. Soc. franç. Derm. Syph.*, **61**, 104 (1954). [D39637

Graham, D. T., and **Wolf, S.**: Pathogenesis of urticaria. Experimental study of life situations, emotions and cutaneous vascular reactions. *J. Amer. med. Ass.*, **143**, 1396 (1950). [E59056

Graham, G. S.: The hemic basophil. *J. exp. Med.*, **31**, 209 (1920). [G3076

Graham, H. T., Lowry, O. H., Wahl, N., and **Priebat, M. K.**: Mast cells as sources of tissue histamine. *J. exp. Med.*, **102**, 307 (1955). [D26780

——, ——, **Wheelwright, F., Lenz, M. A.**, and **Paris, H. H.**: Distribution of histamine among leukocytes and platelets. *Blood*, **10**, 467 (1955). [C9304

——, **Wheelwright, F., Parish, H. H., Marks, A. R.**, and **Lowry, O. H.**: Distribution of histamine among blood elements. *Fed. Proc.*, **11**, 350 (1952). [D28268

Grahne, B.: The mast cell count in the subepithelial tissue of the larynx, trachea and bronchi of human embryos. *Acta path. microbiol. scand.*, sup. 131, 55 (1959). [D25637

——: The mitotic regeneration of mast cells in the lower respiratory tract of human embryos. *Acta path. microbiol. scand.*, **53**, 321 (1961). [D26613

Grassi, A.: Sulla presenza di granulazioni grassose e lipoidee delle Mastzellen istiogene. *G. ital. Derm. Sif.*, **75**, 84 (1934). [D47550

Graumann, W.: Über die zelluläre Speicherung von Carboxymethylzellulose und Polychloretinphosphat. Ein Beitrag zur Kenntnis des Depotmechanismus von ACTH-Präparaten. *Ztschr. Zellforschg. mikroscop. Anat.*, **46**, 430 (1957). [D65523

Gray, A. M. H.: Urticaria pigmentosa. *Proc. Roy. Soc. Med.*, **31**, 1174 (1938). [D39721

Gray, J. H.: Preliminary note on the mast cells of the human pituitary and of the mammalian pituitary in general. *J. Anat.*, **69**, 153 (1935). [32404

Green, J. P.: Elimination and catabolism of ^{35}S-heparin by neoplastic mast cells in culture. *Biochem. Pharmacol.*, **12**, 588 (1963). [D69722

——, and **Day, M.**: Heparin, 5-hydroxytryptamine, and histamine in neoplastic mast cells. *Biochem. Pharmacol.*, **3**, 190 (1960). [D26854

——, and ——: Uptake and metabolism of amines by mast cells in culture. *Fed. Proc.*, **20**, 136 (1961). [D29594

——, and ——: Biosynthetic pathways in mastocytoma cells in culture and in vivo. *Ann. N.Y. Acad. Sci.*, **103**, 334 (1963). [D58290

——, ——, and **Robinson, J. D.**: Some acidic substances in neoplastic mast cells and in the pineal body. *Biochem. Pharmacol.*, **11**, 957 (1962). [D47977

——, and **Furano, A. V.**: Two pools for amines in neoplastic mast cells. *Biochem. Pharmacol.*, **11**, 1049 (1962). [D39524

——, **Roberts, M.**, and **Day, M.**: The sulfomucopolysaccharides from a mast cell tumor of the mouse. *Biochem. Pharmacol.*, **12**, 609 (1963). [E20594

Greggio, H.: Les cellules granuleuses (Mastzellen) dans les tissus normaux et dans certaines maladies chirurgicales. *Arch. Méd. exp.*, **23**, 323 (1911). [D31536

Grey, C. E., and **Biesele, J. J.**: Thin-section electron microscopy of circulating white blood cells. *Rev. Hémat.*, **10**, 283 (1955). [D39702

Grin, E., Salomon, T., and **Stern, P.**: Über die Behandlung einiger Erkrankungen aus dem Formenkreis der Sklerodermie und des Erythematodes chronicus mit einem Serotonin-Antagonisten. *Arch. klin. exp. Dermat.*, **219**, 527 (1964). [F16754

Groat, W. A., Wyatt, T. C., Zimmer, S. M., and **Field, R. E.**: Acute basophilic leukemia. *Amer. J. med. Sci.*, **191**, 457 (1936). [D39568

Gróf, P., Borros, B., and **Agoston, I.**: Correlation between the mast cells and histamine content of the eye in cattle. *Acta ophthal. (Kbh.)*, **42**, 38 (1964). [G17921

——, and **Kelényi, G.**: Histamine content of transplantable mastocytoma. *Acta med. Acad. Sci. hung.*, **19**, 331 (1963). [G17922

Gross, B. G., and **Hashimoto, K.**: Hereditary urticaria pigmentosa. *A.M.A. Arch. Derm.*, **90**, 401 (1964). [D18541

Gross, P.: Urticaria pigmentosa solitary lesion. *A.M.A. Arch. Derm. Syph. (Chic.)*, **29**, 451 (1934). [D42436

Grossberg, A. L., and **Garcia-Arocha, H.**: Histamine liberation in vitro and mode of binding of histamine in tissues. *Science*, **120**, 762 (1954). [D28699

Grossfeld, H.: Metachromasia in the living cell. *Proc. Soc. exp. Biol. (N.Y.)*, **86**, 81 (1954). [D26727

Gruber, G. B.: Über die Milchdrüsenschwellung bei Neugeborenen. *Ztschr. Kinderheilk.*, **30**, 336 (1921). [D27302

——: Beiträge zur Histologie und Pathologie der Mamma. *Virchows Arch. pathol. Anat.*, **248**, 397 (1924). [D27100
——: Diskussionsbemerkung. *Verhandl. Dtsch. Gesellsch. Pathol.*, **37**, 155 (1954). [D39683
Grunbaum, B. W., Geary, J. R., Grande, F., Anderson, J. T., and **Glick, D.**: Effect of dietary lipid on rat serum and liver cholesterol and tissue mast cells. *Proc. Soc. exp. Biol. (N.Y.)*, **94**, 613 (1957). [C31429
Grüneberg, T.: Die Urticaria pigmentosa (Mastocytose der Haut) als allgemeinmedizinisches Problem. *Hautarzt*, **13**, 231 (1962). [D30668
——: Mastzellretikulose. *Dermat. Wchnschr.*, **148**, 217 (1963). [E30063
——: Universelle reaktive Mastzellhyperplasie (zunächst jahrelang pemphigoides Bild). *Dermat. Wchnschr.*, **148**, 217 (1963). [E30064
——, **Kaiser, W.,** and **Müller, U.**: Zur Pathogenese der Urticaria pigmentosa (Untersuchungen bei einem Fall universeller mastzelliger Retikulose der Haut mit pemphigoiden Schüben). *Hautarzt*, **6**, 342 (1955). [D39626
Grupper, C.: Urticaria pigmentosa. *A.M.A. Arch. Derm. Syph. (Chic.)*, **69**, 109 (1954). [D31576
——: Le chlorhydrate de cypro-heptadine dans le traitement de l'urticaire pigmentaire et des mastocytoses. *Bull. Soc. franç. Derm. Syph.*, **68**, 32 (1961). [D33727
——, and **Brux, J. de**: Urticaire pigmentaire. Quelques acquisitions récentes. *Bull. Soc. franç. Derm. Syph.*, **59**, 363 (1952). [D14290
Guidotti, G.: Turnover of the sulphate groups in mast cells of young and adult rats. Quantitative autoradiographic study. *Exp. Cell Res.*, **12**, 659 (1957). [D65255
Guidotti, G. G., and **Spinelli-Ressi, F.**: Incorporation of sulfate in peritoneal mast cells isolated from young and adult rats. *Exp. Cell Res.*, **33**, 254 (1964). [G11021
Guilliermond, A., and **Mawas, ?.**: Caractères histochimiques des granulations des mastzellen et rapport de ces corps avec la volutine des protistes. *C.R. Soc. Biol. (Paris)*, **64**, 307 (1908). [D27506
Guimaraes, J. P., and **Taylor, D. M.**: Effect of radioactive colloidal gold on the mast cells of bone marrow. *Nature (Lond.)*, **179**, 914 (1957). [D26762
Guldberg, G.: Experimental researches on precancerous changes in the skin and skin cancer. *Acta path. microbiol. scand.*, sup. 8, 97; sup. 10, 38 (1931). [D28471
Gulden, K., and **Niebauer, G.**: Vorläufige Mitteilung zum Urticaria pigmentosa Problem. *Wien. klin. Wchnschr.*, **68**, 52 (1956). [D31594
Gulland, G. L.: On the granular leucocytes. *J. Physiol. (Lond.)*, **19**, 412 (1895–96). [D31619
——: Classification, origin and probable role of leucocytes, mastcells and plasmacells. *Folia haemat.*, **3**, 637 (1906). [D27428
Günther, G.: Über das Vorkommen von Gewebsmastzellen am menschlichen Auge und seiner Adnexe bei verschiedenen pathologischen Zuständen. In: *Deutsche Ophthalmologische Gesellschaft, 59. Zusammenkunft.* München: J. F. Bergmann, p. 278 (1956). [D65225
Gupta, P. C. S. and **Ghosh, S.**: Tissue mast cells. *Nature (Lond.)*, **197**, 506 (1963). [D39828
Gusek, W.: Zur Ultrastruktur und Genese von Mastzellen und Mastzellengranula. In: *Proc. Europ. Reg. Conf. on Electron Microscopy*, Delft 1960. **2**, 912 (1960). [D14871
——: Elektronenoptische Untersuchungen über die Ultrastruktur von Mastzellen. *Arch. klin. exp. Dermat.*, **213**, 573 (1961). [D12407
——: Submikroskopische Untersuchungen zur Feinstruktur aktiver Bindegewebszellen. *Thesis (Habilitationsschrift) University of Hamburg* (1960). [D39516
——: Elektronenoptische Beobachtungen an Mastzellen des Menschen bei Mastzellenretikulose. *Verhandl. 8. Kongr. Europ. Gesellsch. Hämatologie, Wien*, p. 89 (1961). [G19632
Gustafsson, B. E., and **Cronberg, S.**: Comparison of the effects of compound 48/80, protamine, and turpentine oil on mast cell degranulation. *Acta rheum. scand.*, **3**, 189 (1957). [D27895
——, and ——: The effect of hyaluronidase and toluidine blue on the mast cells in rats and hamsters. *Acta rheum. scand.*, **5**, 179 (1959). [D26757
——, and ——: The number and size of the mast cells in the mesentery and peritoneal fluid of germfree rats. *Acta rheum. scand.*, **8**, 208 (1962). [D58841
Gustafson, G. T., and **Cronberg, S.**: Effect of endotoxin on mast cells and the extension of the local Shwartzman reaction to the hamster. *Acta path. microbiol. scand.*, **59**, 21 (1963). [D61874
Güttner, H. G.: Morphologische Untersuchungen an regionären Lymphknoten bösartiger Geschwülste. *Ztschr. Krebsforschg.*, **53**, 93 (1942). [D26843

Habermann, E.: Gewinnung und pharmakologische Bedeutung einiger Komponenten des Giftes des Gasbranderregers (Clostridium welchii Typ A). *Naunyn-Schmiedeberg's Arch. exp. Pathol. Pharmak.,* **236,** 274 (1959). [D27439

Hadida, E., Beranger, J., Timsit, E., and **Streit, R.:** Mastocytose cutanée diffuse. *Bull. Soc. franç. Derm. Syph.,* **63,** 33 (1956). [D63180

Hagen, P.: The intracellular distribution of histamine in dog's liver. *Brit. J. Pharmacol.,* **9,** 100 (1954). [D26567

——: The substrate specificity of amine oxidase of mouse mastocytoma. *Fed. Proc.,* **18,** 399 (1959). [C66315

——: Biosynthesis and storage of histamine, heparin, and 5-hydroxytryptamine in the mast cell. *Canad. J. Biochem.,* **39,** 639 (1961). [D2370

——: Histamine and mast cells. In: *Proceedings of the International Union of Physiological Sciences;* Amsterdam, London, Milan, New York: Excerpta Medica Foundation, Intern. Cong. Ser., No. 47, 1/2 p. 863 (1962). [D68493

Hagen, P. B.: Mastocytoma studies. *Ann. Rep. Nat. Cancer Inst. Can.,* p. 106 (1963-64). [D46595

——, **Barrnett, R. J.,** and **Lee, F. L.:** Biochemical and electron microscopic study of particles isolated from mastocytoma cells. *J. Pharmacol. exp. Ther.,* **126,** 91 (1959). [C70407

——, and **Lee, F. L.:** Amino acid decarboxylases of mouse mast cells. *J. Physiol. (Lond.),* **143,** 7P (1958). [D27085

——, **Weiner, N., Ono, S.,** and **Lee, F. L.:** Amino acid decarboxylases of mouse mastocytoma tissue. *J. Pharmacol. exp. Ther.,* **130,** 9 (1960). [D63087

Hagihara, M.: Phase contrast microscopic and electron microcospic observation of mast cell. *Acta haemat. jap.,* **23,** 747 (1960). [D68589

Hahn, P. F.: Abolishment of alimentary lipemia following injection of heparin. *Science,* **98,** 19 (1943). [D39584

Haikonen, M., and **Räsänen, T.:** The serum cholesterol level and mucosal mast cell count in the gastrointestinal tract of rats in dexamethasoneshock. *Acta physiol. scand.,* **59,** 478 (1963). [G1314

Haitinger, M.: *Fluoreszenzmikroskopie.* Leipzig: Akademische Verlagsgesellschaft (1938). [E34499

Hale, C. W.: Histochemical demonstration of acid polysaccharides in animal tissues. *Nature (Lond.),* **157,** 802 (1946). [D33678

Hall, K.: Investigation of the presence of chromaffin cells in the uterus of the mouse. *J. Endocr.,* **28,** 223 (1964). [F1129

Hallopeau, ?., and **Teisseire, ?:** Sur un troisième cas d'urticaire pigmentée cyclique, nouvelle espèce d'angionévrose. *Bull. Soc. franç. Derm. Syph.,* **16,** 84 (1905). [G1485

Halmi, N. S., and **Davies, J.:** Comparison of aldehyde fuchsin staining, metachromasia and periodic acid-Schiff reactivity of various tissues. *J. Histochem. Cytochem.,* **1,** 447 (1953). [B87805

——, and **de Groote, J. W.:** Remarks concerning two types of basophil cells in the human adenohypophysis. *J. clin. Endocr.,* **21,** 732 (1961). [E89849

Hamerston, O., Elveback, L., Halberg, F., and **Gully, R. J.:** Correlation of absolute basophil and eosinophil counts in blood from institutionalized human subjects. *J. appl. Physiol.,* **9,** 205 (1956). [E92384

Hamilton, T. R., and **Syverton, J. T.:** Tissue mast cells with Anitschkow nuclei: investigations into cytologic bases of rheumatic processes. *Amer. J. Path.,* **26,** 705 (1950). [D27526

Hamrin, B.: Release of histamine in urticaria pigmentosa. *Lancet,* **272,** 867 (1957). [D39668

Hannay, M. G.: Case for diagnosis (? urticaria pigmentosa.) *Proc. Roy. Soc. Med.,* **17,** 63 (1924). [E50591

Hanson, A.: Zur Bestimmung von Imidazolessigsäure im Urin und ihr Vorkommen bei Urticaria pigmentosa. *Naturwschft.,* **44,** 470 (1957). [D39623

Harada, K.: Histochemical studies of the juxta glomerular apparatus. *Rev. belge Path.,* **23,** 311 (1954). [D27441

——: Selective staining of mast cell granules with chrysoidin. *Stain Technol.,* **32,** 183 (1957). [D33734

Harber, L. C., and **Witten, V.:** *Yearbook of Dermatology.* Chicago: Year Book Medical Publishers (1959/60). [G11137

Hardesty, M.: The structural basis for the response of the comb of the brown leghorn fowl to the sex hormones. *Amer. J. Anat.,* **47,** 277 (1931). [29533

Hardy, W. B., and **Wesbrook, F. F.:** The wandering cells of the alimentary canal. *J. Physiol. (Lond.),* **18,** 490 (1895). [D28474

Härmä, R., and **Suomalainen, P.:** Heparinocytes and hibernation in the hedgehog. *Acta physiol. scand.,* **24,** 90 (1951). [B65284

Harris, ?.: Urticaria pigmentosa in an adult. *J. cutan. Dis.,* **37,** 541 (1919). [E38014

——: Urticaria pigmentosa. *J. cutan. Dis.*, **37**, 625 (1919). [E38015

Harris, H. F.: Histology and microchemic reactions of some cells to anilin dyes. Identity of the plasma cell and osteoblast. Fibrous tissue a secretion of the plasma-cells. Mast-cell elaborates mucin of connective tissues. *Philad. med. J.*, **5**, 757 (1900). [D26716

Hartman, W. J., Clark, W. G., and **Cyr, S. D.**: Histidine decarboxylase activity of basophils from chronic myelogenous leukemic patients. Origin of blood histamine. *Proc. Soc. exp. Biol. (N.Y.)*, **107**, 123 (1961). [E98125

Hartzell, ?.: Urticaria pigmentosa. *J. cutan. Dis.*, **30**, 491 (1912). [E38009

——: Urticaria pigmentosa. *J. cutan. Dis.*, **31**, 117 (1913). [E38131

——: Urticaria pigmentosa. *J. cutan. Dis.*, **36**, 184 (1918). [E38001

Hartzell, M. B.: Late urticaria pigmentosa, or urticaria pigmentosa beginning after puberty. *J. cutan. Dis.*, **35**, 756 (1917). [E38143

Harvey, E. B.: Mast cell distribution in the uterus of cycling and pregnant hamsters. *Anat. Rec.*, **148**, 407 (1964). [G13574

Hasegawa, J., and **Bluefarb, S. M.**: Urticaria pigmentosa (mastocytosis). *A.M.A. Arch. intern. Med.*, **106**, 417 (1960). [C97856

Hasselmann, C. M., and **Scholder-Oemichen, C.**: Zum Problem der Urticaria pigmentosa. *Arch. klin. exp. Dermat.*, **205**, 261 (1957). [C47971

Hauser, H.: Hautwucherungen mit basophilgranulierten Zellen beim Hund. *Experientia (Basel)*, **4**, 197 (1948). [D10422

Hauser, W.: Zur Kenntnis der Gewebsmastzelle im Knochenmark unter besonderer Berücksichtigung ihres Vorkommens bei Dermatosen. *Arch. Dermat. Syph. (Berlin)*, **195**, 514 (1953). [D26883

Hausner, M. M.: Preliminary experiments on effects of chemical histamine-liberators, local edema, and 'wild vegetables' of Taiwan on the mast cells of the rat. *J. Formos. med. Ass.*, **62**, 353 (1963). [G14240

Havard, C. W. H., and **Scott, R. B.**: Urticaria pigmentosa with visceral and skeletal lesions. *Quart. J. Med.*, **28**, 459 (1959). [C85492

Havel, R. J. and **Boyle, E.**: Production of lipemia clearing factor during anaphylactoid shock. *Proc. Soc. exp. Biol. (N.Y.)*, **85**, 468 (1954). [D26429

Haverback, B. J., Wirtschafter, S. K., and **Dyce, B.**: Histamine metabolism in the malignant carcinoid syndrome. *Gastroenterology*, **42**, 776 (1962). [D34580

Head, K. W.: Cutaneous mast-cell tumours in the dog, cat and ox. *Brit. J. Derm.*, **70**, 389 (1958). [D27975

Heath, A. D.: A case for diagnosis: adult urticaria pigmentosa. *Brit. J. Derm.*, **25**, 410 (1913). [E37436

Hecht, G., and **Gloxhuber, C.**: Folgen intraperitonealer Injektionen bei Ratten. *Arch. int. Pharmacodyn.*, **140**, 655 (1962). [D55529

Hecker, E., Fromm, G. A., Bertoli, N., and **Parisier, H.**: Las variaciones de la basofila en distintos estados clinicos. I. Las afectiones tiroideas. II. El efecto de la prednisona. *Pren. méd. argent.*, **47**, 2960 (1960). [E94745

Hedbom, A., and **Snellman, O.**: Isolation and analysis of the large cytoplasmic granules of tissue mast cells. *Exp. Cell Res.*, **9**, 148 (1955). [D27627

Heidingsfeld, ?.: Urticaria pigmentosa. *J. cutan. Dis.*, **36**, 316 (1918). [E38004

——: Urticaria pigmentosa. *J. cutan. Dis.*, **36**, 316 (1918). [E38005

Heilmeyer, L., and **Regemann, H.**: *Handbuch der inneren Medizin.* Berlin, Göttingen, Heidelberg: J. Springer Verlag, 4th Ed., **2**, 488 (1951). [D7141

Heller, ?.: Urticaria pigmentosa. *Dermatologica (Basel)*, **20**, 806 (1913). [D32024

Heller, J.: Ein Beitrag zur Genese der Mastzellen der Haut. *Dtsch. med. Wchnschr.*, **30**, 507 (1904). [D26810

Hellman, B., Larsson, S., and **Westman, S.**: Mast cell content and fatty acid metabolism in the epididymal fat pad of obese mice. *Acta physiol. scand.*, **58**, 255 (1963). [E22484

Hellström, B., and **Holmgren, H.**: En kvantitativ analys av mastcellsförekomsten i hud och hjärta hos manniska. *Svenska Läk.-Tidn.*, **44**, 617 (1947). [D39611

——, and **Holmgren, H. J.**: Numerical distribution of mast cells in the human skin and heart. *Acta anat. (Basel)*, **10**, 81 (1950). [D25620

Henschen, F.: Discussion with Quensel: Some investigations concerning mast-cells. *Acta path. microbiol. scand.*, **5**, 38 (1928). [D39826

——, and **Krabbe, K.**: Discussion. *Acta path. microbiol. scand.*, **5**, 37 (1928). [D39826

Hermann, H.: Über die Bedeutung der Mastzellen in sympathischen Ganglien. *Klin. Wchnschr.*, **30**, 87 (1952). [D30199

Héroux, O.: Mast cells in the skin of the ear of the rat exposed to cold. *Canad. J. Biochem.,* **39,** 1871 (1961). [D26430

Herpels, E.: Au sujet des basophiles tissulaires dans moëlle osseuse. *Acta clin. belg.,* **6,** 134 (1951). [D26783

Herxheimer, A.: Urticaria pigmentosa with attacks of flushing. *Brit. J. Derm.,* **70,** 427 (1958). [E57641

Herzberg, J. J.: Die Störungen der Blutgerinnung und deren Bedeutung für die Pathogenese der cutanen Mastocytose. *Arch. klin. exp. Dermat.,* **208,** 559 (1959). [D39565

Herzog, E., and **Sepúlveda, H.:** Contribución al metabolismo y a las alteraciones postmortales del sistema nervioso vegetativo periférico. *Bol. Soc. Biol. (Concepción),* **14,** 55 (1940). [D69364

Herzog, G.: Experimentelle Untersuchungen über die Einheilung von Fremdkörpern. *Beitr. pathol. Anat.,* **61,** 325, 377 (1916). [D26808

Hiatt, R. B., and **Katz, L.:** Mast cells in inflammatory conditions of the gastrointestinal tract. *Amer. J. Gastroent.,* **37,** 541 (1962). [D25019

Hibbs, R. G., Burch, G. E., and **Phillips, J. H.:** Electron-microscopic observations on the human mast cell. *Amer. Heart J.,* **60,** 121 (1960). [D26893

——, **Phillips, J. H.,** and **Burch, G. E.:** Electron microscopy of human tissue mast cells. *J. Amer. med. Ass.,* **174,** 508 (1960). [D26446

Higginbotham, R. D.: Studies on the functional interrelationship of fibroblasts and ground substance mucopolysaccharides. *Ann. N.Y. Acad. Sci.,* **73,** 186 (1958). [C61457

——: Mast cells and local resistance to Russell's viper venom. *Fed. Proc.,* **21,** 279 (1962). [G7638

——: Discussions. (Various authors: Round table discussion on mast cells and basophils.) *Ann. N.Y. Acad. Sci.,* **103,** 441, (1963). [D58297

——, and **Dougherty, T. F.:** Significance of cytoplasmic inclusions in fibroblasts. *Fed. Proc.,* **14,** 72 (1955). [D33668

——, and ——: Fibroblastic participation in detoxification of the amine, 48–80, by heparin. *Fed. Proc.,* **15,** No. 1 (1956). [D39844

——, and ——: Micellophagosis and detoxification. *Res. Bull.,* **2,** 27 (1956). [C32940

——, and ——: Mechanism of heparin protection against a histamine releasor (48/80). *Proc. Soc. exp. Biol. (N.Y.),* **92,** 493 (1956). [C21716

——, and ——: Micellophagosis. *Res. Bull.,* **3,** 19 (1957). [D39843

——, ——, and **Jee, W. S. S.** Fate of shed mast cell granules. *Proc. Soc. exp. Biol. (N.Y.),* **92,** 256 (1956). [D15838

Highman, B.: Staining of mucus with buffered solutions of toluidine blue O, thionin and new methylene blue N. *Stain Technol.,* **20,** 85 (1945). [D29566

Higuchi, K.: Die Gewebsmastzellen in der Mamma. *Folia haemat.,* **41,** 401 (1930). [D26227

Hill, M.: Morphological effects of the secretion of histamine and mucopolysaccharides by mast cells. *Experientia (Basel),* **13,** 395 (1957). [D27967

——: Secretion of heparin by mast cells. *Nature (Lond.),* **180,** 654 (1957). [D26788

——: Ueber den Einfluss experimenteller Schockbedingungen auf die Mastzellen. *Acta anat. (Basel),* **35,** 118 (1958). [C64094

——, and **Pospíšil, M.:** On the relation between the secretion of the perivascular mast cells and the serumlevel of mucoproteins. *Experientia (Basel),* **15,** 267 (1959). [C73689

——, and ——: The patterns of mucopolysaccharide secretion in mast cells in the course of stress. *Acta histochem. (Jena),* **10,** 109 (1960). [C99519

——, and ——: Identity of the cortisol and heparin effects on mast cells. *Arch. int. Pharmacodyn.,* **124,** 139 (1960). [D26881

——, and **Praslička, M.:** Quantitative und qualitative Veränderungen der Milz-Mastzellen röntgenbestrahlter Mäuse. *Acta haemat.,* **19,** 278 (1958). [D26723

Hillebrecht, T.: Die basophilen Leukozyten bei Psychosen und endokrinen Störungen. *Thesis, University of Hamburg* (1952). [G9243

Hilliard, C. W., and **Nash, H. E.:** Cellular composition of the peritoneal fluid in DBA mice after intraperitoneal injection of normal or malignant human cells. *J. Lab. clin. Med.,* **38,** 846 (1951). [D63183

Hirschmann, A.: Pathologisch-anatomische Studien über acute und chronische Laryngitis nichtspecifischen Ursprungs nebst Bemerkungen über Vorkommen von Plasma- und Mastzellen. *Virchows Arch. pathol. Anat.,* **164,** 541 (1901). [D27099

Hirt, A., Sommer, H., Wimmer, K., and **Kiesselbach, A.:** Lumineszenz-mikroskopische Untersuchungen an den Mastzellen der lebenden Maus. *Anat. Anzgr.,* **87,** sup., p. (1939). [D33724

Hissard, R., Moncourier, L., and **Jacquet, J.:** Une nouvelle affection hématodermique,

la mastocytose. *C. R. Acad. Sci. (Paris),* **231,** 253 (1950). [D30630

——, ——, and ——: A propos d'un cas de mastocytose pure. Origine et évolution des mastocytes. *C.R. Acad. Sci. (Paris),* **231,** 1178 (1950). [D10427

——, ——, and ——: Sur la formation des mastocytes et l'origine de l'héparine. *Bull. Acad. nat. méd. (Paris),* **135,** 408 (1951). [B90449

——, ——, and ——: Etude d'un cas de mastocytose. *Ann. Méd.,* **52,** 583 (1951). [D39769

——, ——, and ——: Etude d'une nouvelle hématodermie: la mastocytose. *Presse méd.,* **59,** 1765 (1951). [D39583

——, ——, and ——: Répartition des basocytes et réactions de l'organisme déclenchées par l'implantation sous-cutanée d'un caillot sanguin. *Rev. Path. gén.,* No. 646, 401 (1953). [B92293

Hittmair, A.: Beitrag zur Basophilenleukämie. *Schweiz. med. Wschnschr.,* **90,** 938 (1960). [D39841

Hjelmman, G.: Über das erste Auftreten der Mastzellen in einigen Geweben und Organen bei Homoembryonen mit Berücksichtigung der Zunahme dieser Zellen während der Embryonalentwicklung. *Comm. Biol. Soc. Sci. Fenn.,* **13,** 1 (1952). [D15553

——: Kann eine Zunahme der Mastzellen in der Wand dilatierter Hämorrhoidalvenen beobachtet werden? *Comm. Biol. Soc. Sci. Fenn.,* **15**/2, 1 (1956). [E20254

——: Über die Anhäufung von Mastzellen in der Tunica adventitia und dem perivaskulären Bindegewebe bei obliterierenden Gefässkrankheiten. *Comm. Biol. Soc. Sci. Fenn.,* **15**/4, 1 (1956). [E20253

——: Beobachtungen an Mastzellen bei normalen und pathologischen Zuständen. *Anat. Anzgr.,* **102,** 396 (1956). [D39689

——, and **Pettersson, T.:** Über die Einwirkung der Hyaluronidase auf die Mastzellen und Fibrozyten des Rattenmesenteriums. *Com. Biol. Soc. Sci. Fenn.,* **15,** 1 (1955). [D39851

——, and ——: Beitrag zur Kenntnis der Einwirkung einer fraktionierten Röntgenbestrahlung auf die Mastzellen der Leber. *Com. Biol. Soc. Sci. Fenn.,* **15**/10, 1 (1955). [D39850

——, and ——: Zur Technik der Vitalfärbung von Mastzellen und Fibrozyten bei Laboratoriumsversuchstieren. *Com. Biol. Soc. Sci. Fenn.,* **15**/13, 1 (1955). [D39845

——, and **Wegelius, O.:** Über die Einwirkung einer experimentell hervorgerufenen Thrombenbildung auf die Mastzellen der Gefässwand. *Comm. Biol. Soc. Sci. Fenn.,* **15**/6, 1 (1956). [E20255

——, and ——: Über die Einwirkung niedriger Temperatur auf die Mastzellen der Herzmuskulatur und der Leber bei der Kröte und dem Frosch. *Comm. Biol. Soc. Sci. Fenn.,* **15**/9, 1 (1956). [E20252

Hlaváček, V., and **Lojda, Z.:** Mast cells in the mucous membrane of the upper respiratory tract during normal and pathological states. *Acta oto-laryng. (Stockh.),* **56,** 182 (1963). [D68124

Högberg, B., Südow, G., Thon, I. L., and **Uvnäs, B.:** The inhibitory action of a compound obtained from hip seeds (HSC) on the release of histamine and the disruption of mast cells produced by compound 48/80 and extracts from jellyfish (Cyanea capillata) and eelworm of swine (Ascaris lumbricoides). *Acta physiol. scand.,* **38,** 265 (1956-57). [D26423

——, **Thufvesson, G.,** and **Uvnäs, B.:** Histamine liberation produced in the perfused paw of the cat by 48/80 and extracts from jellyfish (Cyanea capillata) and eelworm (Ascaris lumbricoides) from swine. *Acta physiol. scand.,* **38,** 135 (1956-57). [D25640

——, and **Uvnäs, B.:** The mechanism of the disruption of mast cells produced by compound 48/80. *Acta physiol. scand.,* **41,** 345 (1957). [C47831

——, and ——: Inhibitory action of allicin on degranulation of mast cells produced by compound 48/80, histamine liberator from Ascaris, lecithinase A and antigen. *Acta physiol. scand.,* **44,** 157 (1958). [D26477

——, and ——: Further observations on the disruption of rat mesentery mast cells caused by compound 48/80, antigen-antibody reaction, lecithinase A and decylamine. *Acta physiol. scand.,* **48,** 133 (1960). [D26422

Hoepke, H., and **Westenhoeffer O.:** Neue Beobachtungen an Mastzellen. *Verhandl. naturhist.-med. Ver., Heidelberg,* **18,** 89 (1935). [66679

Hoggan, G., and **Hoggan, F. E.:** Histologisches über Urticaria pigmentosa. *Monatsh. prakt. Derm.,* **2,** 44 (1883). [D33721

Holczabek, W.: Die Mastzellen der Lunge des Menschen. *Dtsch. Ztschr. gesamt. gerichtl. Med.,* **54,** 175 (1963). [D41584

Holczinger, L., and **Dévényi, J.:** Relationship of mast cells to the ground substance

of connective tissue. *Acta morph. Acad. Sci. hung.*, **5**, 37 (1955). [D39763
Holländer, H.: Der histochemische Nachweis von Schwefelsäure-Estern mit Trypaflavin. *Ztschr. Zellforschg. Abt. Histochem.*, **3**, 387 (1964). [G10073
Holler, G.: 50 Jahre miterlebte Geschichte der Allergieforschung in Österreich. *Über unspezifische und spezifische Reaktionen des Eiweisstoffwechsels.* Wien: Wilhelm Maudrich, p. 267 (1963). [E2351
Holmgren, H.: Funktion und Chemie der Ehrlich'schen Mastzellen. *Verhandl. anat. Gesellsch. (Jena)*, **83**, Sup., p. 31 (1937). [D95345
——: Eine neue Methode zur Fixierung der Ehrlichschen Mastzellen, Mit besonderer Berücksichtigung der Chemie der Zellgranula. *Ztschr. wisschftl. Mikros.*, **55**, 419 (1938). [D29498
——: Über Vorkommen und Bedeutung der chromotropen (metachromatischen) Substanz in menschlichen Feten. *Anat. Anzg.*, **88**, 246 (1939). [D27890
——: Studien über Verbreitung und Bedeutung der chromotropen Substanz. *Ztschr. mikros.-anat. Forschg.*, **47**, 489 (1940). [D28926
——: Beitrag zur Frage der Genese der Ehrlich'schen Mastzellen. *Acta Anat. (Basel)*, **2**, 40 (1946). [93302
——, and **Rexed, B.:** Metachromatic staining of the Schwann cells in nerve regeneration. *Acta Anat. (Basel)*, **2**, 287 (1946-47). [26230
——, and **Stenbeck, A.:** Beitrag zur Kenntnis des Vorkommens von Mastzellen im menschlichen Auge bei verschiedenen pathologischen Zuständen. *Acta ophthal. (Kbh.)*, **18**, 271 (1940). [D26779
——, and **Wilander, O.:** Beitrag zur Kenntnis der Chemie und Funktion der Enrlichschen Mastzellen. *Ztschr. mikros. anat. Forschg.*, **42**, 242 (1937). [D26887
——, and **Wohlfart, G.:** Om de basofila levkocyternas diagnosticas betydelse. *Nord. Med.*, **11**, 2771 (1941). [D28677
——, and ——: Mast cells in experimental rat sarcomas. *Cancer Res.*, **7**, 686 (1947). [B41911
Hooff, A. van den: Eosinophilic cells as possible mast cell precursors. *Nature (Lond.)*, **194**, 97 (1962). [D61469
Hoop, ?. van der: Urticaria pigmentosa. *Ned. T. Geneesk.*, **41**, 515 (1907). [E37992
Hopf, E. J.: Über das Verhalten von Leukocyten und Mastzellen an Haut-Nabelschnurgrenze und Nabelschnur des Neugeborenen. *Frankfurt. Ztschr. Pathol.*, **63**, 1 (1952). [D30201
Hopsu, V. K., and **Glenner, G. G.:** A histochemical enzyme kinetic system applied to the trypsin-like amidase and esterase activity in human mast cells. *J. Cell Biol.*, **17**, 503 (1963). [D69723
Horváth, L.: A l'histologie normale des mastocytes. *Acta morph. Acad. Sci. hung.*, **2**, 35 (1952). [D27703
——: Analysis of mast cells by means of polarization microscopy. *Nature (Lond.)*, **183**, 1067 (1959). [C71332
——: Some data concerning the submicroscopic morphology of mast cells. II. *Acta morph. Acad. Sci. hung.*, **9**, 179 (1960). [C88558
Hoyer, H.: Ueber den Nachweis des Mucins in Geweben mittelst der Färbemethode. *Arch. mikros. Anat.*, **36**, 355 (1890). [D28275
Hu, F., Fosnaugh, F. R., and **Livingood, C. S.:** Human skin window studies: II. Comparison of cellular response to staphylococcus in controls and in patients with cutaneous bacterial infections. *J. invest. Dermat.*, **41**, XX 325 (1963). [E33665
Hudelo, ?, and **Cailliau, ?:** Le tissu réticuloendothélial à l'état normal et pathologique. A propos d'un cas d'urticaire pigmentaire. *Ann. Derm. Syph. (Paris)*, **9**, 19 (1928). [D39740
——, and ——: Le tissu reticulo-endothélial dans les états pathologiques. *Ann. Derm. Syph. (Paris)*, **9**, 145 (1928). [G6824
——, **Dumet, ?., Cailliau, ?.,** and **Boissau, ?.:** Un cas d'urticaire pigmentaire à forme bulleuse. *Bull. Soc. franç. Derm. Syph.*, **34**, 197 (1927). [D39709
Hughes, N. R., and **Claudatus, J.:** Action of thyroidectomy on the skin mast cell population and the peritoneal mast cell S^{35} O_4 uptake in the rat. *Endocrinology*, **71**, 840 (1962). [D40024
Huguenin, B.: Über abnorme Kernbildungen in den glatten Muskelfasern sowie über Mast- und Plasmazellen in Leiomyomen des Uterus. *Beitr. Geburtsh. Gynäk.*, **16**, 324 (1911). [D39690
——: Untersuchungen über Mastzellen. *Ztrbl. allg. Pathol. pathol. Anat.*, **23**, 441 (1912). [D29587
——: Mastzellen mit sudanophilen Granula. *Ztrbl. allg. Pathol. pathol. Anat.*, **23**, 725 (1912). [D27303
Hule, V.: Die akuten basophilen und eosinophilen Leukosen. *Sang*, **21**, 423 (1950). [G18738
Hultén J., and **Pontén, J.:** Staining of normal, atypical, and cancerous colon epithelium by ovalbuminfluoresceinisothiocyanate

at different pH levels. *Acta path. microbiol. scand.*, **60**, 1 (1964). [G2982

Humphrey, J. H., Austen, K. F. and **Rapp, H. J.**: In vitro studies of reversed anaphylaxis with rat cells. *Immunology*, **6**, 226 (1963). [D68120

——, and **Mota, I.**: The mechanism of anaphylaxis: specificity of antigen-induced mast cell damage in anaphylaxis in the guinea pig. *Immunology*, **2**, 31 (1959). [D26066

——, and **White, R. G.**: *Immunology for Students of Medicine*. Oxford: Blackwell Scientific Publications, (1963). [G13961

Hunt, T. E., and **Hunt, E. A.**: A study of the mast cells in the rat after injections of the histamine-liberator, compound 48/80. *Anat. Rec.*, **124**, 309 (1956). [D27054

——, and ——: Mitotic activity of mast cells. *Proc. Soc. exp. Biol. (N.Y.)*, **94**, 166 (1957). [D63100

——, ——, and **Curry, D.**: Basophil leucocytes and mast cells in the rabbit before and after intravenous injection of compound 48/80. *Anat. Rec.*, **140**, 123 (1961). [D46575

al-Hussaini, A. H.: On the functional morphology of the alimentary tract of some fish in relation to differences in their feeding habits: Cytology and physiology. *Quart. J. micr. Sci.*, **90**, 323 (1949). [D27614

Hussarek, M., and **Neuhold, R.**: Ueber den Mastzellengehalt der Nasenschleimhaut bei Rhinitiden verschiedener Stadien. *Arch. Ohren, Nasen, Kehlk.-Heilk.*, **176**, 433 (1960). [D26850

Hutchinson, J.: Prurigo urticans and urticaria pigmentosa as stigmatosis insectorum. *Scot. med. surg. J.*, **22**, 493 (1908). [E38161

Hyde, ?.: Urticaria pigmentosa. *J. cutan. Dis.*, **28**, 480 (1910). [E38154

Iakovleva, A. I.: The function of adipose cells in the connective tissue. *Morfologia Patomorfologia*, **40**, 70 (1954). [D25508

Imanishi, K.: Experimentelle Studien über Gewebsmastzellen an den der Mundhoehle angehoerigen Organen und ueber das Gewebe bei normaler Ratte (Japanese text). *Shika Geppo*, **17**, 1 (1937). [D63800

Inagaki, S.: Clinical studies on the relationship between thyroid function and level of circulating basophil leucocytes (Japanese text). *Acta haemat. jap.*, **19**, 662 (1956). [C54042

——: The relationship between the level of circulating basophil leucocytes and thyroid function. *Acta endocrinol.*, **26**, 477 (1957). [G45593

Inderbitzin, T., and **Craps, T.**: Le rôle de l'histamine et de la sérotonine (5-hydroxytryptamine) dans la pathogénie de l'augmentation de la perméabilité capillaire cutanée d'origine anaphylactique. *Dermatologica (Basel)*, **114**, 208 (1957). [C38962

Ishibe, T.: Endocrinological studies in patients with urogenital tumours. III. Thyroid gland and urogenital tumours. *Acta urol. (Kioto)*, **8**, 337 (1962). [E64005

Isidor, P.: Etude sur la caractérisation histologique et histochémique de l'héparine. *Bull. Micr. appl.*, **4**, 41 (1954). [D30595

Ito, T.: Studies on the tissue mast cells. *Nagoya J. med. Sci.*, **19**, 99 (1956-57). [E57790

Iversen, K., and **Asboe-Hansen, G.**: Studies on the fat-mobilizing factor of the anterior pituitary gland. Suppressive action of thyroxin. *Acta endocr. (Kbh.)*, **11**, 111 (1952). [B75178

Iversen, O. H.: Mast cells in the myometrium of the human cervix uteri, and changes caused by androgenic and estrogenic hormones. *Acta path. microbiol. scand.*, **49**, 337 (1960). [C90461

——: The influence of estrogenic and androgenic hormones on mast cells and connective tissue in uterus of guinea pig. *Acta pathol. microbiol. scand.*, **56**, 245 (1962). [D39756

——, **Christensen, H. E.**, and **Rask-Nielsen, R.**: Studies on a transplantable mastocytoma in mice. 3. Histologic and ultrastructural changes following varying doses of oestrogen. *Acta path. microbiol. scand.*, **60**, 194 (1964). [G10503

Jackson, ?.: Case of urticaria pigmentosa. *J. cutan. Dis.*, **26**, 418 (1908). [E38157

Jacob, F. H.: A case of urticaria pigmentosa treated by X-rays. *Brit. med. J.*, June 1, 1301 (1907). [E37998

Jacobi, O.: Ueber die Entstehung des Hautpigments, besonders die Rolle der Mastzellen bei der Pigmentbildung. *Folia haemat.*, **16**, 20 (1914). [D27436

Jacobs, P. H.: Urticaria pigmentosa. Solitary lesions occurring in a mother and her daughter. *A.M.A. Arch. Derm.*, **77**, 112 (1958). [D39638

Jacquet, J.: L'épithélioma atypique T 8 de Guérin chez le rat blanc. *Rev. Path. gén.*, **63**, 401 (1963). [E24358

Jadassohn, ?.: Urticaria pigmentosa adultorum. *Korresp.-Bl. schweiz. Arz.*, **44**, 1479 (1914). [E38017

Jadassohn, W.: Zur Histologie der Urticaria pigmentosa. *Arch. Derm. Syph. (Berlin)*, **167**, 704 (1933). [D33673

Jaffurs, W. J., and **Turner, T. R.:** A report of the occurrence of mast cells in atrophic type vaginal and cervical smears. *Amer. J. Med. Technol.,* **25,** 414 (1959). [D26770

——: Über die Beeinflussung experimenteller Verkalkungen durch Eisendextran. *Naunyn-Schmiedeberg's Arch. exp. Pathol. Pharmak.,* **249,** 162 (1964). [G11110

——: Calciphylaktische Reaktionen. *Dtsch. med. Wchnschr.,* No. 33, 1560 (1964). [E24144

Jahnke, V.: Beteiligung der Mastzellen bei der Erzeugung und Verhütung von Calcergie. *Ztschr. gesamt. exp. Med.,* **138,** 496 (1965). [G11103

James, G. W.; Wright, D. U.; Wilkerson, V., and **Shellenberg, R.:** Observations on the absolute basophil count in health and disease. *Clin. Res. Proc.,* **3,** 31 (1955). [D27395

Jamieson, D., and **van den Brenk, H. A. S.:** Relation of mast cell changes to hypothermia in the rat. *Biochem. Pharmacol.,* **7,** 35 (1961). [D8004

Janes, J., and **McDonald, J. R.:** Mast cells. Their distribution in various human tissues. *Arch. Path.,* **45,** 622 (1948). [B32304

Janower, M. L.: Mastocytosis of the gastrointestinal tract. Report of a case. *Acta radiol. (Stockh.),* **57,** 489 (1962). [D64689

Jaques, L. B.: Heparin and the mast cell. *Canad. J. Biochem.,* **39,** 643 (1961).[D26299 (1913). [D39677

——, and **Waters, E. T.:** The identity and origin of the anticoagulant of anaphylactic shock in the dog. *J. Physiol. (Lond.),* **99,** 454 (1941). [B40648

Jaques, R.: Acute effects of oral lipids on systemic and local cutaneous anaphylaxis. In: *Immunopathology, Ist Internat. Symp. Basel and Seelisberg 1958.* Basel and Stuttgart: Benno Schwabe & Co. Verlag, **?,** 237 (1958). [C89858

Jasmin, G.: Etude de l'inflammation anaphylactoide. *Rev. canad. Biol.,* **15,** 107 (1956). [C24745

——, and **Bois, P.:** Coloration différentielle des mastocytes chez le rat. *Rev. canad. Biol.,* **20,** 773 (1961). [D27951

——, and ——: Storage and tissue disposal of carboxymethylcellulose injected into rats. *Rev. canad. Biol.,* **20,** 819 (1961). [D63182

Jeanloz, R.: Hotchkiss reaction and structure of polysaccharides. *Science,* **111,** 289 (1950). [D26450

Jeanselme, E., and **Touraine, A.:** Urticaire pigmenté (étude de la formule sanguine). *Bull. Soc. franç. Derm. Syph.,* **24,** 426

——, and ——: Urticaire pigmentaire avec hypertrophie du foie et splénomégalie. Hématologie. Radiothérapie. *Bull. Soc. franç. Derm. Syph.,* **26,** 98 (1919). [E21110

Jennings, M. A., Florey, H. W., and **Robinson, D. S.:** Observations on the mast cells with special reference to fat transport. *Quart. J. exp. Physiol.,* **45,** 298 (1960). [D26618

——, ——, ——, and **Salaman, M. R.:** The relationship of mast cells to fat transport. *Ann. N.Y. Acad. Sci.,* **103,** 313 (1963). [D58288

Jensen, W. N., and **Lasser, E. C.:** Urticaria pigmentosa associated with widespread sclerosis of the spongiosa of bone. *Radiology,* **71,** 826 (1958). [D39704

Jernstrom, P.: Synovial sarcoma of the pharynx. *Am. J. clin. Path.,* **24,** 957 (1954). [D28481

Jim, R. T. S., and **Steinkamp, R. C.:** Macroglobulinemia and its relationship to other paraproteins. *J. Lab. clin. Med.,* **47,** 540 (1956). [C42786

Joachim, G.: Über Mastzellenleukämien. *Dtsch. Arch. klin. Med.,* **87,** 437 (1906). [D28466

Jóhannesson, T., and **Norn, S.:** The effect of morphine on the histamine contents of brain and skin in the rat. *Acta pharmacol. (Kbh.),* **20,** 158 (1963). [E33916

Johansson, H., and **Westin, B.:** The influence of testosterone and oestradiol on the occurrence of mast cells in the mouse uterus. *Acta. path. microbiol. scand.,* **40,** 413 (1957). [C37608

——, and ——: Studies on the influence of oestrogen on the mast cells in mice. *Acta path. microbiol. scand.,* **45,** 133 (1959). [C67836

Johnson, F. R., and **McMinn, R. M. H.:** Mast cells in the epithelium of the oesophagus. *Nature (Lond.),* **317,** 615 (1957). [D63535

Johnson, K. J.: Mast cells and eosinophils in food and inhalant allergy. *Ann. Allergy,* **20,** 657 (1962). [D39569

Johnson, W. C., Graham, J. H., and **Helwig, E. B.:** Histochemistry of the acid mucopolysaccharides in cutaneous calcification. *J. invest. Derm.,* **42,** 215 (1964). [F2277

——, and **Helwig, E. B.:** Solitary mastocytosis (urticaria pigmentosa). *A.M.A. Arch. Derm.,* **84,** 148 (1961). [D26652

Johnstone, J. M.: The appearance and significance of tissue mast cells in human bone marrow. *J. Clin. Path.,* **7,** 275 (1954). [C11069

——: The tissue mast cell in human bone marrow. *Amer. J. Clin. Path.,* **26,** 60 (1956). [C13670

Jolly, J.: Clasmatocytes et mastzellen, *C.R. Soc. Biol. (Paris),* **52,** 609 (1900). [D27449

——: Cellules plasmatiques, cellules d'Ehrlich et clasmatocytes. *C.R. Ass. Anat.,* **3,** 78 (1901). [D27635

Jordan, H. E.: The histology of the blood and the red bone-marrow of the leopard frog, Rana pipiens. *Amer. J. Anat.,* **25,** 437 (1919). [D27529

——: On the nature of the basophilic granulocytes of the blood and the tissues. *Anat. Rec.,* **33,** 89 (1926). [D27521

——: Comparative hematology. In: *Downey Handbook of Hematology.* New York: P. B. Hoeber, p. 11 (1938). [D27356

——, and **Flippin, J. C.:** Haematopoiesis in chelonia. *Folia haemat.,* **15,** 1 (1913). [D27962

Jordon, A. L., and **Hartman, W. J.:** Enzymatic hydroxylation of phenylserine by mouse mastocytoma homogenate. *Fed. Proc.,* **21,** 51 (1962). [G6549

Jorpes, E.: See also: Jorpes, J. E.

——: On heparin: its chemical nature and properties. *Acta med. scand.,* **88,** 427 (1936). [D26892

——: Über das Heparin und seine Anwendung als Ersatzmittel für Oxalat und Zitrat in der Klinik. *Acta med. scand.,* sup. 89, 139 (1938). [D27887

——, **Holmgren, H.,** and **Wilander, O.:** Ueber das Vorkommen von Heparin in den Gefässwänden und in den Augen. *Ztschr. mikros.-anat. Forschg.,* **42,** 279 (1937). [D26888

——, **Odeblad, E.,** and **Boström, H.:** An autoradiographic study on the uptake of S^{35}-labelled sodium sulphate in the mast cells. *Acta haemat. (Basel),* **9,** 273 (1953). [D26754

Jorpes, J. E.: The site of formation of heparin. In: *Jorpes, Heparin. Its Chemistry, Physiology, and Application in Medicine.* London: Humphrey Milford (Oxford Univ. Press), p. 30 (1939). [D26965

——: The site of formation of heparin. In: *Heparin in the Treatment of Thrombosis.* London, New York, Toronto: Oxford University Press, p. 57 (1946). [D44643

——: The origin and the physiology of heparin: the specific therapy in thrombosis. *Ann. intern. Med.,* **27,** 361 (1947). [B3995

——: Heparin. In: *Euler et al., Comparative Endocrinology, II. Part 2. Tissue Hormones.* New York, London: Academic Press, p. 112 (1963). [E4171

——, **Werner, B.,** and **Åberg, B.:** The fuchsin-sulfurous acid test after periodate oxidation of heparin and allied polysaccharides. *J. biol. Chem.,* **176,** 277 (1948). [D27623

Juhlin, L.: Studies on the basophil eosinophil leukocytes in various dermatosis. *Proc. 12th Int. Congr. Dermat.* Sept. 9–15, (1962). [G19256

——: Basophil leucocyte differential in blood and bone marrow. *Acta haemat. (Basel),* **29,** 89 (1963). [E98089

——: The basophil leukocytes in patients with bleeding peptic ulcer. *Acta med. scand.,* **174,** 43 (1963). [E71741

——: The effect of corticotrophin and corticosteroids on the basophil and eosinophil granulocytes. *Acta hemat. (Basel),* **29,** 157 (1963). [D65336

——: Basophil and eosinophil leucocytes in various internal disorders. *Acta med. scand.,* **174,** 249 (1963). [E26200

——: Basophil leukocytes in ulcerative colitis. *Acta med. scand.,* **173,** 351 (1963). [D62609

——: Reaction to infusion of a histamine liberator. *A.M.A. Arch. Derm.,* **88,** 771 (1963). [E35093

——: Basophil leukocytes in blood and inflammatory exudate. *Acta derm.-venereol. (Stockh.),* **43,** 528 (1963). [E99930

——: Nachweismethoden der medikamentösen Allergien. *Arch. klin. exp. Dermat.,* **219,** 319 (1964). [F16723

——, and **Shelley, W. B.:** Role of mast cell and basophil in cold urticaria with associated systemic reactions. *J. Amer. med. Ass.,* **177,** 371 (1961). [D81021

——, and ——: Plastic tube technic of centrifugal separation of leucocytes from human blood. *Blood,* **18,** 477 (1961). [D51133

——, and **Westphal, O.:** Degranulation of basophil leukocytes in a case of milk allergy. *Acta derm.-venereol. (Stockh.),* **42,** 273 (1962). [G18748

Julén, C., Snellman, O., and **Sylvén, B.:** Cytological and fractionation studies on the cytoplasmic constituents of tissue mast cells. *Acta physiol. scand.,* **19,** 289 (1950). [D26818

Junqueira, L. C. U., and **Beiguelman, B.:** Studies on the in vitro action of compound 48–80, a formaldehyde condensation product, on rat mast-cells, *Tex. Rep. Biol. Med.,* **13,** 69 (1955). [D26706

Kabelitz, H. J.: Morphologie und Bedeutung der Gewebsmastzellen im Sternalpunktat. *Dtsch. Arch. klin. Med.,* **194,** 499 (1949). [D33664

Kádas, L., and **Virág, L.:** Neuro-Endokrin-System und Heparinocyten. I. Heparinocyten und Blutgerinnung. *Endokrinologie,* **41,** 323 (1961). [D26824

——, ——, and **Szabó, A.:** Neuro-Endokrin-System und Heparinocyten. II. Heparinocyten-Blutgerinnungsverhältnisse nach plötzlichem Tod. *Endokrinologie,* **41,** 331 (1961). [D26825

Kahlson, G., Rosengren, E., and **Steinhardt, C.:** Histamine-forming capacity of multiplying cells. *J. Physiol. (Lond.),* **169,** 487 (1963). [E39145

——, ——, and **Thunberg, R.:** Increased rate of histamine formation in anaphylaxis. *J. Physiol. (Lond.),* **172,** 18P (1964). [D17638

Kanitz, H.: Ein Fall von Urticaria pigmentosa. *Pester med.-chir. Presse,* **44,** 1073 (1908). [E37951

——: Urticaria pigmentosa. *Pester med.-chir. Presse,* **46,** 118 (1910). [D32277

Kanthack, A. A., and **Hardy, W. B.:** The morphology and distribution of the wandering cells of mammalia. *J. Physiol.,* **17,** 81 (1894–95). [D28369

Kappeler, R., Krebs, A., and **Riva, G.:** Klinik der Makroglobulinämie Waldenström. Beschreibung von 21 Fällen und Übersicht der Literatur. *Helv. med. Acta,* **25,** 101 (1958). [D39705

Kappers, J. A., ten Kate, I. B., and **de Bruyn, H. J.:** On mast cells in the choroid plexus of the axolotl (Ambystoma mex.). *Ztschr. Zellforschg. mikros. Anat.,* **48,** 617 (1958). [D65524

Kardos, E.: Über die Entstehung der Blutmastzellen aus dem Knochenmark. *Folia haemat.,* **11,** 271 (1911). [D27980

Karzel, K.: Einfluss des Mastzellentumors P–815 der Maus auf den 5-Hydroxytryptamin-Gehalt ihrer Organe. *Med. exp. (Basel),* **10,** 115 (1964). [G9337

——: Zur Wirkung einiger neuer antidepressiv wirksamer Auxin-Derivate. *Arzneimittel Forschg.,* **14,** 561 (1964). [F15956

Katayama, Y., and **Ende, N.:** ATEE- and TAME-esterases of human mast cell. *Fed. Proc.,* **23**/1, 392 (1964). [F4764

Kátó, L., and **Gözsy, B.:** Alterations dans la morphologie des mastocytes au cours du choc anaphylactique chez le rat. *Proc. 30th Congress ACFAS Montreal,* p. 33 (1962). [D36810

——, and ——: Transparent skin technique for studying connective tissue response to injury. *Rev. canad. Biol.,* **21,** 175 (1962). [D30021

——, and ——: Les mastocytes dans le choc anaphylactique chez le rat. *C.R. Soc. Biol.,* **156,** 553 (1962). [D30617

——, and ——: Le rôle des mastocytes dans la réaction anaphylactoïde provoquée par le dextran. *J. Physiol. (Paris),* **54,** 619 (1962). [D30619

——, and ——: Mast-cell response in murine leprosy and as influenced by antileprosy drugs. *Internat. J. Lepr.,* Feb. 1965. [D66168

——, ——, **Lehmann, H. E.,** and **Ban, T. A.:** Attempt to classify psychotropic drugs, based on their affinity to mucopolysaccharides in vivo. *J. clin. exp. Psychopath.,* **23,** 75 (1962). [D30616

Katz, H. I., Glill, K. A., Baxter, D. L., Baxter, S. L., and **Moschella, S. L.:** Indirect basophil degranulation test in penicillin allergy. *J. Amer. med. Ass.,* **188,** 351 (1964). [F8694

Katzberg, A. A.: Distribution of mast cells in the lymphoid organs of the rat. *Anat. Rec.,* **118,** 393 (1954). [D28661

Kelemen, E., and **Bikich, G.:** Insufficiency of acute response of basophil and eosinophil leucocytes and of blood histamine after the administration of ACTH and cortisone in untreated myelocytic leukemia. *Acta haemat. (Basel),* **15,** 202 (1956). [G16012

Kelényi, A., and **Gógl, A.:** Electron microscopic examination of mast-cell tumours, with reference to mast-cell differentiation. *Morph. igazs. orv. Szemle,* **3**/4, 270 (1963). [G19262

Kelényi, G.: Changes in the mast cells following X-ray irradiation. *Acta morph. Acad. Sci. hung.,* **3,** 377)1953). [C12639

——: Effect of cytotoxic agents on tissue mast cells. *Acta morph. Acad. Sci. hung.,* **4,** 345 (1954). [C10851

Keller, R.: Experimentelle Untersuchungen zur blutdrucksenkenden Wirkung des Heparins. 1. Mitteilung. *Arch. int. Pharmacodyn.,* **107,** 382 (1956). [D26882

——: Experimentelle Untersuchungen zur blutdrucksenkenden Wirkung des Heparins. 2. Mitteilung. *Arch. int. Pharmacodyn.,* **110,** 300 (1957). [C34639

——: Tissue mast cells in anaphylactic shock and anaphylactoid reactions. *Int. Arch. Allergy,* **11,** 328 (1957). [C54750

——: Veränderungen an den Gewebemastzellen der Ratte im Shock. *Helv. physiol. pharmacol. Acta,* **15,** C20 (1957). [D94203

——: Histamin und 5-Hydroxytryptamin in den Gewebemastzellen der Albinoratte. *Helv. physiol. Acta,* **15,** 371 (1957). [D27073

——: Zur Bindung von Histamin und Serotonin in den Mastzellen. *Arzneimittel-Forschg.* **8**, 390 (1958). [D55000
——: Quantitative Untersuchungen zur Beziehung zwischen Mastzellveränderungen und Histaminausscheidung bei der Albinoratte. *Schweiz. Ztschr. allg. Pathol.*, **21**, 903 (1958). [C62755
——: Biochemische Eigenschaften und physiologische Bedeutung der Gewebemastzellen. *Schweiz. med. Wchnschr.*, **90**, 503 (1960). [C91531
——: Veränderungen isolierter sensibilisierter Mastzellen nach Einwirkung des Antigens in vitro. *Helv. physiol. pharmacol. Acta*, **19**, C 27 (1961). [D26631
——: Hemmung der anaphylaktischen Reaktion isolierter Gewebemastzellen durch Peptidasesubstrate und -inhibitoren. *Helv. Physiol. pharmacol. Acta*, **19**, C 79 (1961). [D39722
——: Zum Mechanismus der Mastzelldisruption. *Path. et Microbiol. (Basel)*, **24**, 932 (1961). [D39671
——: Hemmung der anaphylaktischen Reaktion isolierter Gewebemastzellen der Albinoratte durch Peptidasesubstrate und-inhibitoren sowie monobasische Fettsäuren. *Helv. physiol. pharmacol. Acta*, **20**, C32 (1962). [D39659
——: Nachweis von Lecithin bzw. Lysolecithin in Lipoidextrakten normaler bzw. anaphylaktischer Mastzellen. *Helv. physiol. pharmacol. Acta*, **20**, C 66 (1962). [D60849
——: Histochemical demonstration of non-specific esterase in mast cells of the albino rat with properties similar to mast cell enzyme activated in anaphylaxis. *Nature (Lond.)*, **196**, No. 4851, p. 281 (1962). [D33742
——: Effect of antibodies against rat γ-globulin or rat albumin on isolated peritoneal rat mast cells. *Nature (Lond.)*, **193**, 282 (1962). [D26836
——: Mast cells and anaphylaxis. *Experientia (Basel)*, **18**, 286 (1962). [D27706
——: Weitere Charakterisierung des für die Mastzelldisruption verantwortlichen Ferments. *Path. et Microbiol. (Basel)*, **25**, 569 (1962). [D58041
——: Zur funktionellen Bedeutung der Gewebemastzellen. *Schweiz. med. Wschnschr.*, **92**, 1638 (1962). [D39758
——: On the role of lysophosphatides during anaphylactic shock. *Biochem. Pharmacol.*, **12**, sup., 214 (1963). [E32257
——: Anaphylaxis in isolated rat mast cells. II. The effect of non-specific metabolic inhibitors on histamine release by antibody and on histochemical demonstration of non-specific esterase. *Int. Arch. Allergy*, **23**, 315 (1963). [E38771
——: Zur Bedeutung von Komplement bei der umgekehrten Anaphylaxie isolierter Mastzellen der Albinoratte. *Path. et Microbiol. (Basel)*, **26**, 671 (1963). [E36439
——: Zur Histochemie der Mastzellesterase. *Schweiz. med. Wchnschr.*, **93**, 1504 (1963). [E29395
——: Anaphylaxis in isolated rat mast cells. III. Localization of the chymotrypsin-type proesterase in heat-labile serum components. *Int. Arch. Allergy*, **24**, 255 (1964). [G18239
——: The effect of aggregated γ-globulins on immune cytolysis: the role of complement. *Experientia (Basel)*, **20**, 378 (1964). [D51806
——: Voraussetzungen für das Zustandekommen eines zytolysierenden Effektes durch Phosphatidas A. *Helv. physiol. pharmacol. Acta*, **22**, C76 (1964). [D17764
——, and **Beeger, I.**: Das Verhalten isolierter sensibilisierter Mastzellen nach Einwirkung des Antigens unter verschiedenen Versuchsbedingungen. *Med. exp. (Basel)*, **4**, 51 (1961). [D25638
——, and ——: Anaphylaxis in isolated rat mast cells. I. Effect of peptidase substrates and inhibitors. *Int. Arch. Allergy*, **22**, 31 (1963). [D39842
——, and **Burkard, W.**: Die Bedeutung der Gewebemastzellen für die Histaminfreisetzung. *Helv. physiol. pharmacol. Acta*, **14**, 289 (1956). [C29951
——, and **Mühlethaler, K.**: Cytologische Untersuchungen zum Verhalten isolierter Mastzellen bei der anaphylaktischen Reaktion. *Path. et Microbiol. (Basel)*, **25**, 115 (1962). [D58042
——, and **Oppliger, G. C.**: Zum Verhalten menschlicher Gewebemastzellen in vitro. *Klin. Wchnschr.*, **39**, 1028 (1961). [D27077
——, and **Schwarz, M.**: Versuch zur Charakterisierung der anaphylaktischen Reaktion isolierter Gewebemastzellen der Albinoratte mittels spezifischer Antiseren. *Path. et Microbiol. (Basel)*, **26**, 100 (1963). [D58842
——, and **Schwarz-Speck, M.**: Zum immunologischen Verhalten isolierter Mastzellen. *Internat. Arch. Allergy*, **19**, 202 (1961). [D25586
——, and ——: Zur Fixation von Antikörper an isolierten Mastzellen. *Schweiz. med. Wchnschr.*, **91**, 1196 (1961). [D26897

——, and **Sorkin, E.**: Zum Mechanismus der Cytolyse von Mastzellen bei der Antigen-Antikörper-Reaktion aktiv sensibilisierter Albinoratten I. *Helv. physiol. pharmacol. Acta,* **21**, C31 (1963). [E37372

——, and ——: Adsorption of rabbit antibody by rat tissue mast cells and other cells in vitro. *Nature (Lond.),* **199**, 709 (1963). [E31032

Kelly, J. W.: The use of metachromacy in histology cytology and histochemistry. *Acta histochem. (Jena),* **5**, sup. 1, 85 (1958). [G19255

——, and **Bloom, G.**: A quantitative spectrophotometric study of the mast cell. *Exp. Cell Res.,* **16**, 538 (1959). [G9515

——, **Boseila, A. W., Kavazos, L. F.,** and **Feagans, W. M.**: Hematology of the horned lizard, especially blood basophils and tissue mast cells. *Acta haemat. (Basel),* **26**, 378 (1961). [E43287

Kelsall, M. A.: Trephocytic activity of lymphocytes, plasmacytes and mast cells in relation to the metabolism of connective tissue. In: *Inflammation and Diseases of Connective Tissue. A Hahnemann Symposium.* Philadelphia: W. B. Saunders Co., p. 20 (1961). [D7784

——, and **Crabb, E. D.**: Increased mast cells in the thymus of X-irradiated hamsters. *Science,* **115**, 123 (1952). [D26640

——, and ——: Mast cells in sublingual gland of Syrian hamsters. *Anat. Rec.,* **115**, 331 (1953). [D28690

——, and ——: Effects of X-irradiation on mast cells and mucous secretion in Brunner's glands. *Anat. Rec.,* **118**, 393 (1954). [D39634

——, and ——: Effect of estrogen on mast cells and collagen in the mammary gland of hamsters. *Anat. Rec.,* **124**, 415 (1956). [D29289

——, and ——: Acid mucopolysaccharides (AMP) in uterus of estrogen and progesterone-treated hamsters. *Anat. Rec.,* **125**, 600 (1956). [D28657

——, and ——: Mast cells in endocrine glands of hormone-treated hamsters. *Anat. Rec.,* **127**, 426 (1957). [D30528

——, and ——: *Lymphocytes and Mast Cells.* Baltimore: Williams & Wilkins Co. (1959). [D26076

——, and **Lewis, P.**: Mast cells in the brain. *Fed. Proc.,* **23**/1, 1107 (1964). [D19437

Kerl, W.: Zur Kenntnis der pigmentierten Urtikariaformen. *Arch. Dermat. Syph. (Berlin),* **118**, 563 (1913). [D39694

Kerp, L.: Bedeutung von Zink für die Histaminspeicherung in Mastzellen. *Int. Arch. Allergy,* **22**, 112 (1963). [E32807

——, and **Steinhaeuser, G.**: Über einen ternären Heparin-Metall-Histamin-Komplex. *Klin. Wchnschr.,* **39**, 762 (1961). [E24263

Kibel, M. A., and **Kingsley, H. J.**: Mastocytosis. A report on two cases. *Cent. Afr. J. Med.,* **9**, 1 (1963). [D65189

Kierland, R. R., and **Stegmaier, O. C.**: Urticaria pigmentosa (large nodular type). *A.M.A. Arch. Derm. Syph. (Chic.),* **62**, 28 (1950). [D39639

Kim, Y. Z.: Mast cell degranulation in the rat uvea induced by histamine-liberator compound 48/80. *A.M.A. Arch. Ophthal.,* **69**, 350 (1963). [D58632

Kimura, E. T., Young P. R., and **Barlow, G. H.**: A study with low and high molecular weights of hexadimethrine bromide: an antiheparin agent. *Proc. Soc. exp. Biol. (N.Y.),* **111**, 37 (1962). [D36398

——, ——, and **Ebert, D. M.**: Further studies on hexadimethrine bromide (polybrene): an antiheparin agent. *Toxicol. appl. Pharmacol.,* **1**, 560 (1959). [C94625

——, ——, and **Richard, R. K.**: Interaction of histamine, serotinin and heparin with hexadimethrine bromide, a mast cell fragmentor. *Proc. Soc. exp. Biol. (N.Y.),* **107**, 19 (1961). [D33717

Kindwall, E. P., Boréus, L. O., and **Westerholm, B.**: Failure to show change in rat tissue histamine and serotonin after rapid decompression. *Amer. J. Physiol.,* **203**, 389 (1962). [D31658

Kingsbury, ?.: Urticaria pigmentosa. *J. cutan. Dis.,* **34**, 558 (1916). [E38140

Kiyono, K.: *Die Vitale Karminspeicherung.* Jena: Gustav Fischer Verlag (1914). [B78216

Klaus, S. N., and **Winkelmann, R. K.**: The nature of night-blue staining of rat mast cells. *J. invest. Derm.,* **33**, 225 (1959). [C80962

——, and ——: Course of urticaria pigmentosa in children. *A.M.A. Arch. Derm.,* **86**, 68 (1962). [G18747

Klausner, E., and **Kreibich, C.**: Über den Mastzellengehalt vesikulöser Hauteffloreszenzen. *Folia haemat.,* **15**, 347 (1913). [D27434

——, and ——: Über exsudative Mastzellen. *Arch. Dermat. Syph. (Berlin),* **96**, 235 (1909). [G8896

Klein, R.: Mastocytes thymiques et relations des mécanismes de défense de l'organisme avec la pathogénie des cancers. *C.R. Soc. Biol. (Paris),* **157**, 718 (1963). [E26609

Klieneberger, C.: *Die Blutmorphologie der Laboratoriumstiere.* Leipzig: Ambrosius Barth (1912). [D27442

Klopstock, A., Schwartz, J., and **Grinberg, E.:** Degranulation of basophil cells as diagnostic test in allergic states. *Israel Med. J.,* **21,** 216 (1962). [G17219

Klotz, M.: Ein Beitrag zur Kenntnis und Differential-diagnose der Urticaria pigmentosa (xanthelasmoidea, naeviformis). *Arch. Dermat. Syph. (Berlin),* **87,** 231 (1907). [E37427

Klug, H.: Zur submikroskopischen Struktur der Mastzellen des Thymus. *Acta biol. med. germanica,* **6,** 545 (1961). [D27650

Kluth, W.: Über das Vorkommen von Gewebsmastzellen im Ductus thoracicus. *Ztrbl. allg. Pathol. pathol. Anat.,* **87,** 139 (1951). [D26437

Knowles, F. C.: Urticaria pigmentosa. *J. cutan. Dis.,* **31,** 117 (1913). [E38158

——: Urticaria pigmentosa, particularly in regard to its histology. *J. cutan. Dis.,* **33,** 171 (1915). [E37987

Koenig, W.: Über die Bedeutung von Mastzellen im Benzpyren-Tumor von Ratten. *Ztschr. gesamt. exp. Med.,* **126,** 64 (1955). [D65252

Kogoj, F.: A propos d'une réaction au mastocytine. *Acta allerg. (Kbh.),* **13,** 349 (1959). [C82505

Köhler, H.: Zum sogenannten Mastozytom beim Hund. *Schweiz. Ztschr. allg. Pathol.,* **19,** 249 (1956). [C21325

Kohn, A.: Über das Pigment in der Neurohypophyse des Menschen. *Arch. mikr. Anat.,* **75,** 337 (1910). [D28271

Köksal, M.: Doku mast hücreleri hakkinda. *Acta med. turc.,* **5,** 85 (1953). [C1302

——: Extraction of a heparin-like substance from mast cell granules in mouse connective tissue. *Nature (Lond.),* **172,** 733 (1953). [B93664

Konjetzny, G. E.: *Der Magenkrebs.* Stuttgart: F. Enke (1938). [D39522

Konrad, J., and **Winkler, A.:** Zur Pathogenese der Urticaria pigmentosa im Zusammenhang mit der Mastzellenfunktion. *Hautarzt,* **4,** 119 (1953). [D26875

Korn, E. D.: Metabolism of heparin in mouse mast cell tumor. *Fed. Proc.,* **17,** 157 (1958). [E90065

——: The synthesis of heparin mouse mast cell tumor slices. *J. Amer. chem. Soc.,* **80,** 1520 (1958). [D65340

——: Observations of the use of cellulose ion exchangers for the chromatographic separation of nucleotides. *Biochim. biophys. Acta (Amst.)* **32,** 554 (1959). [D66466

——: The synthesis of heparin by slices of mouse mast cell tumor. *J. biol. Chem.,* **234,** 1321 (1959). [D39642

——: The isolation of heparin from mouse mast cell tumor. *J. biol. Chem.,* **234,** 1325 (1959). [D63167

——: The enzymatic sulfation of heparin. *J. biol. Chem.,* **234,** 1647 (1959). [D65268

Korybutt-Daszkiewicz, ?.: Ueber die Entwickelung der Nerven aus Plasmazellen beim Frosche. *Arch. mikr. Anat.,* **15,** 1 (1878). [D31544

Kovács, G. S.: A simple direct method for absolute basophil and eosinophil counts from the same blood sample. *Folia haemat. (Lpzg.).* **5,** 166 (1961). [E98657

Kovács, A., and **Juhász, E.:** Über die Antihistaminwirkung von Leukocytensuspensionen mit besonderer Berücksichtigung der eosinophilen Leukocyten. *Arch. int. Pharmacodyn.,* **88,** 383 (1952). [C70358

Krabbe, K.: Discussion. *Acta path. microbiol. scand.,* **5,** 37 (1928). [D39826

Kraft, S. C., and **Kirsner, J. B.:** Mast cells and the gastrointestinal tract. *Gastroenterology,* **39,** 764 (1960). [D33708

Kramer, H., and **Windrum, G. M.:** Metachromasia after treating tissue sections with sulphuric acid. *J. clin. Path.* **6,** 239 (1953). [D30593

——, and ——: Sulphation techniques in histochemistry with special reference to metachromasia. *J. Histochem. Cytochem.,* **2,** 196 (1954). [B93619

——, and ——: The metachromatic staining reaction. *J. Histochem. Cytochem.,* **3,** 227 (1955). [D26969

Kreibich, C.: Über die Granula der fixen Mastzellen. *Arch. Dermat. Syph. (Berlin),* **123,** 450 (1916). [D27585

Krementchousky, M.: Urticaire pigmentaire apparue à 46 ans. *Bull. Soc. franç. Derm. Syph.,* **55,** 387 (1948). [D39737

Krompecher, E.: Beiträge zur Lehre von den Plasmazellen. *Beitr. pathol. Anat.,* **24,** 163 (1898). [D28276

Kückens, H.: Über die Fibrosis mammae und die mit ihr zusammenhängenden Geschwulstbildungen. *Beitr. pathol. Anat.,* **80,** 40 (1928). [D30204

Kunz, J.: Autoradiographische Untersuchungen der Mastzellen in eisendextraninduzierten Sarkomen. *Acta biol. med. Germanica,* **13,** 233 (1964). [D42047

Kutter, D.: Beitrag zur direkten Zählung der basophilen Granulozyten. *Ärztl. Lab.,* **5,** 322 (1959). [G18816

Kwaan, H. C.: A histochemical study of fibrinolytic activity and content of protease

in mast cells. *Amer. J. clin. Path.*, **41**, 604 (1964). [G17226

Lacaz, P. S., Couceiro, A., Lopez, M. B. L., Leite, J. V. P., and **Tinoco, E. M.:** Mastzellen de Ehrlich Contribuição experimental paru o estudo de suas funções. *Rev. bras. Cirurg.*, **33**, 1 (1957). [C33366

Laguesse, E.: Sur le développement des mastzellen ou mastocytes chez le rat blanc. *C.R. Soc. Biol. (Paris)*, **82**, 1415 (1919). [D27510

Lagunoff, D., and **Benditt, E.:** A new method for study in vitro of morphologic and chemical changes in mast cells. *J. Histochem. Cytochem.*, **7**, 286 (1959). [D7116

——, and——: Mast cell degranulation and histamine release observed in a new in vitro system. *J. exp. Med.*, **112**, 571 (1960). [D26708

——, and ——: 5-Hydroxytryptophan decarboxylase activity in rat mast cells. *Amer. J. Physiol.*, **196**, 993 (1959). [C68450

——, and ——: Proteolytic enzymes of mast cells. *Ann. N.Y. Acad. Sci.*, **103**, 185 (1963). [D58280

——, **Calhoun, R.,** and **Benditt, E. P.:** Direct measurement of radioactive sulfate uptake by rat mast cells. *Proc. Soc. exp. Biol. (N.Y.)*, **104**, 575 (1960). [D26885

——, **Lam, K. B., Roeper, E.,** and **Benditt, E. P.:** 5-Hydroxytryptamine formation from 5-Hydroxytryptophan by mast cells. *Fed. Proc.*, **16**, 363 (1957). [C33258

——, **Phillips, M.,** and **Benditt, E. P.:** Histochemical demonstration of histamine. *J. Histochem. Cytochem.*, **8**, 325 (1960). [D289

——, ——, and ——: The histochemical demonstration of histamine in mast cells. *J. Histochem. Cytochem.*, **9**, 534 (1961). [D30207

Lancashire, G. H.: Urticaria pigmentosa. *Brit. J. Derm.*, **24**, 320 (1912). [E37584

Landsberger, A.: Die Wirkung von Heparinoiden auf den Ehrlich-Aszites-Tumor bei Mäusen. *Med. Welt (Stuttg.)* **?**, Nr. 22, 1222 (1963). [E31716

Landsmeer, J. M. F.: Some colloid chemical aspects of metachromasia. Influence of pH and salts on metachromatic phenomena evoked by toluidine blue in animal tissue. *Acta physiol. pharmacol. neerl.* **2**, 112 (1951). [D26778

Langhof, H., Müller, H., Wolfran, G., and **Zabel, R.:** Zur Pathogenese und Therapie der Psoriasis pustulosa vom Typ Hallopeau. *Arch. klin. u. exp. Dermat.* **212**, 438 (1961). [D16751

Lansing, A. I., and **Opdyke, D. L.:** Histological and histochemical studies of the nipples of estrogen treated guinea pigs with special reference to keratohyalin granules. *Anat. Rec.*, **107**, 379 (1950). [B60712

Lapowski, ?.: Xantoma planum universale. *J. cutan. Dis.*, **27**, 173 (1909). [E38145

Larsen, G.: The mast cells in the uveal tract of the eye and changes induced by hormones and avitaminosis-C. *Amer. J. Ophthal.*, **47**, 509 (1959). [C67769

——: Experimental uveitis. A histopathologic study with special reference to the mast cell. *Acta ophthal. (Kbh)*, **39**, 231 (1961). [D33726

Larsson, B.: Statistical analyses of cutaneous tumours in dogs, with special reference to mastocytoma. *Nord. Vet.-Med.*, **8**, 130 (1956). [D10423

——: Autoradiography of dog mastocymas. *Nord. Vet.-Med.*, **8**, 581 (1956). [E81440

——: Effects of compound 48/80 on blood pressure and plasma histamine level of normal dogs and dogs with mastocytoma. *Acta Physiol. scand.*, **38**, 12 (1957). [E47930

——: Some aspects of canine mastocytoma. *Nord. Vet.-Med.*, **9**, 241 (1957). [E88145

——: Studies on canine mastocytoma. Thesis, Univ. of Stockholm (1957). [D50351

Larsson, L. G., and **Sylvén, B.:** The mast cell reaction of mouse skin to some organic chemicals. I. Estimation of the relative number of mast cells in normal mouse skin. *Cancer Res.*, **7**, 676 (1947). [D26790

——, and ——: The mast cell reaction of mouse skin to some organic chemicals. II. The effect of common organic solvents. *Cancer Res.*, **7**, 680 (1947). [D31567

Lascano, E. F.: Mast cells in human tumors. *Cancer*, **11**, 1110 (1958). [D33682

Latta, J. S., and **Beber, C. R.:** Cells with metachromatic cytoplasmic granules in the stroma of human chorionic villi. *Science*, **117**, 498 (1953). [D26449

Lauda, E., and **Flaum, E.:** Die basophilen Kugelhaufen im Knochenmark von Ratte und Maus. *Folia haemat.*, **38**, 181 (1929). [D26828

Lavdowsky, M.: Zur Methodik der Methylenblaufärbung und über einige neue Erscheinungen des Chemotropismus. *Ztschr. wisschftl. Mikros.*, **12**, 177 (1895). [D42233

Laves, W., and **Thoma, K.:** Histoenzymatische Untersuchungen an den Mastzellen des Blutes. *Klin. Wchnschr.*, **28**, 95 (1950). [D31583

——, and ——: Histoenzymatische Untersuchungen an den Granulationen der weissen Blutkörperchen. *Virchows Arch. pathol. Anat.,* **318,** 74 (1950). [G18725

Lazarus, A.: Die myeloischen Leukämien. In: *Nothnagels Handbuch,* **8**/1, 111 (1901). [G18728

Le Beux, Y., *cf.* Beux, Y. le. [E22489

LeBlanc, J.: Effect of chlorpromazine on number of mast cells and of certain formed elements of blood. *Proc. Soc. exp. Biol. (N.Y.),* **97,** 238 (1958). [C55959

——: Effect of cyanide on some chlorpromazine responses. *Proc. Soc. exp. Biol. (N.Y.),* **100,** 635 (1959). [D39725

——: Secretion and activity of histamine and serotonin during cold adaptation. *Amer. J. Physiol.,* **204,** 520 (1963). [D58979

——: Peripheral tissue adaptation to cold. *Fed. Proc.,* **22,** 937 (1963). [E21031

——, **Hildes, J. A.,** and **Heroux, O.:** Tolerance of Gaspé fishermen to cold water. *J. appl. Physiol.,* **15,** 1031 (1960). [D87634

——, and **Rosenberg, F.:** Mast cell changes in animals exposed to cold. *Proc. Soc. exp. Biol. (N.Y.),* **96,** 234 (1957). [C42304

Le Cars, M., *cf.* Cars, M. le. [D39796

Lecomte, J., and **Baeckeland, E.:** Les mastocytes hépatiques du chien au cours du choc peptonique. *Acta haemat. (Basel),* **10,** 165 (1953). [B93844

LeCoulant, ?., and **Texier, ?.:** Un homme orange. Réticulose mastocytaire maligne. *Bull. Soc. franç. Derm. Syph.,* **63,** 492 (1956). [D63187

Leder, L. D.: Über die selektive fermentcytochemische Darstellung von neutrophilen Zellen und Gewebsmastzellen im Paraffinschnitt. *Klin. Wchnschr.,* **42,** 553 (1964). [E76509

Lees, M. H., and **Stroud, C. E.:** Bone lesions of urticaria pigmentosa in childhood. *Arch. Dis. Childh.,* **34,** 205 (1959). [E34936

Lehner, J.: Das Mastzellen-Problem und die Metachromasie-Frage. *Ergebn. Anat. Entwickl. Gesch.,* **25,** 180 (1924). [D27094

Leitão, A., and **Trincão, R.:** Observacão clínica e anatomopatológica dum caso de Urticaria pigmentar ou doença de Nettleship. *Trab. Soc. port. Derm.,* **10,** 55 (1952). [D39615

Lempert, H., Stein, A. A., and **Doyle, J. T.:** Myocardial mast cells and human atherosclerosis. *A.M.A. Arch. Path.,* **72,** 386 (1961). [D26747

Lennert, K.: Die pathologische Anatomie der Makroglobulinämie Waldenström. *Frankfurt. Ztschr. Pathol.,* **66,** 201 (1955). [D63796

——: Eine mastocytoide Osteomyeloreticulose (Mastzellen-reticulose). *Proc. 5th Congr. European Soc. Haematol.,* 573 (1955). [D39800

——: Zur Mastzellen-Pathologie. *Proc. 8th Congr. Europ. Soc. Haematol. Vienna,* **1,** 87 (1961). [D46521

——, and **Back, G.:** Eine verfeinerte Technik der Toluidinblau-pH-Reihe zur Mastzellendarstellung. *Klin. Wchnschr.,* **39,** 1026 (1961). [D27076

——, and **Illert, E.:** Die Häufigkeit der Gewebsmastzellen im Lymphknoten bei verschiedenen Erkrankungen. *Frankf. Zeitschr. Pathol.,* **70,** 121 (1959). [D26831

——, **Köster, E.,** and **Martin, H.:** Über die Mastzellenleukämie. *Acta haemat (Basel),* **16,** 255 (1956). [D26471

——, **Lennert, K.,** and **Schubert, J. C. F.:** Zur Histochemie der Gewebsmastzelle im menschlichen Lymphknoten. *Frankf. Ztschr. Pathol.,* **69,** 591 (1959). [D26817

——, and **Remmele, W.:** Karyometrische Untersuchungen an Lymphknotenzellen des Menschen. II. Mitteilg.: Basophile Stammzellen, Plasmazellen und Gewebsmastzellen. *Acta haemat. (Basel),* **21,** 139 (1959). [D65262

——, and **Schubert, J. C. F.:** Untersuchungen über die sauren Mucopolysaccharide der Gewebsmastzellen im menschlichen Knochenmark. *Frankf. Ztschr. Pathol.,* **69,** 579 (1959). [D26816

——, and ——: Zur Cytochemie der Blut- und Gewebsmastzellen. *Verh. Dtsch. Gesellsch. inn. Med., 66th Kongr. Wiesbaden 1960,* p. 1061 (1961). [D33718

Leredde, E., and **Bezançon, F.:** Principales formes cellulaires des tissus conjonctifs et du sang. *Presse méd.,* **6,** 305 (1898). [D39509

Lerner, M. R., and **Lerner, A. B.:** Urticaria pigmentosa with systemic lesions and otosclerosis. *A.M.A. Arch. Derm.,* **81,** 203 (1960). [E35351

Leuchs, J.: Über die Zellen des menschlichen Eiters und einiger seröser Exsudate. *Virchows Arch. pathol. Anat.,* **177,** 28 (1904). [E38234

Levaditi, C.: Un cas de leucémie myélogène. Considération sur la mastzellen-leucocytose et sur l'hétérochromasie des granulations leucocytaires. *J. Physiol. Path. gén.,* **3,** 424 (1901). [G18721

——: Contributions à l'étude des mastzellen et de la mastzellen-leucocytose.

Thèse. Université de Paris (1902). [D63798

Levi, I.: Osservazioni sopra un caso di urticaria papulosa perstans con pigmentazione. *G. ital. Derm. Sif.,* **70,** 1348 (1929). [D39848

——: Contributo alla conoscenza dell' urticaria papulosa perstans con pigmentazione. *Arch. ital. Derm.,* **5,** 219 (1930). [D39784

Levi, L., Meneghini, C. L., and **Rantuccio, F.:** Activité cholinéstérastique: pouvoir histaminolytique et dosage de l'histamine dans la peau de sujets sains et atteints de certaines dermatoses allergiques. Rapport histamine-mastocytes. *Acta allerg. (Kbh.),* **13,** 332 (1959). [D26473

Levine, M.: A method for staining connective tissue mast cells. *J. Lab. clin. Med.,* **14,** 172 (1928). [68868

Levine, R. J.; Lovenberg, W., and **Sjoerdsma, A.:** Hedroxylation of tryptophan and phenylalanine in neoplastic mast cells of the mouse. *Biochem. Pharmacol.,* **13,** 1283 (1964). [D17991

——, ——, and ——: Hydroxylation of tryptophan and phenylalanine by murine neoplastic mast cells. *Fed. Proc.,* **23**/1, 563 (1964). [F5784

Levy, S. W., and **Swank, R. L.:** Relationship of native heparin to clearing of alimentary lipemia. *Proc. Soc. exp. Biol. (N.Y.),* **82,** 553 (1953). [D39635

Lewis, G. P.: *5-Hydroxytryptamine. Proc. 5-Hydroxytryptamine Symposium, London Apr. 1957.* London & New York: Pergamon Press (1958). [C54180

Liacopoulos, P., Stone, S. H., and **Perramant, M. F.:** The molecular ratio between 'tissular' antibodies and released histamine during the anaphylactic reaction in isolated guinea pig lung preparations. *J. Immunol.,* **91,** 348 (1963). [E27304

Lieberthal, D.: Urticaria pigmentosa. *Illinois med. J.,* **8,** 432 (1905). [E38338

Lieberthal, ?.: Urticaria pigmentosa. *J. cutan. Dis.,* **36,** 243 (1918). [E38003

Liebman, E.: The trephocytes and their functions. *Experientia (Basel).,* **3,** 442 (1947). [D61516

Liebow, A. A., Warren, S., and **DeCoursey, E.:** Pathology of atomic bomb casualties. *Amer. J. Path.* **25,** 853 (1949). [D26782

Lignac, G. O. E.: Die Benzolleukämie bei Menschen und weissen Mäusen. *Krankh. Forschg.,* **9,** 403 (1932). [G18730

Likar, I. N., and **Likar, L. J.:** Acid mucopolysaccharides and mast cells in the bovine uterus at different stages of the sexual cycle. *Acta endocr. (Kbh.),* **46,** 493 (1964). [G5081

——, ——, and **Robinson, R. W.:** Mast cells and hyaluronic acid in the bovine endometrium. *Nature (Lond.),* **203,** 730 (1964). [G19263

Lillie, R. D.: Mast myelocyte leukemia in a cat. *Amer. J. Path.,* **7,** 713 (1931). [G18729

——: *Histopathologic Technic and Practical Histochemistry.* New York, Toronto: Blakiston Co., Inc., (1947). [B44595

——: Further exploration of the HIO_4-Schiff reaction with remarks on its significance. *Anat. Rec.,* **108,** 239 (1950). [D26787

——: The periodic acid-Schiff reaction in pathology. *Amer. J. clin. Path.,* **26,** 305 (1956). [D28666

Lindell, S. E., Rorsman, H., and **Westling, H.:** Formation of histamine in a canine mastocytoma. *Experentia (Basel),* **15,** 31 (1959). [D65656

——, ——, and ——: Histamine formation in urticaria pigmentosa. *Acta derm.-venereol. (Stockh.)* **41,** 277 (1961). [D26738

——, ——, and ——: Histamine formation in human blood. *Acta Allerg. (Kbh.)* **16**/3, 216 (1961). [D41119

Lindemayr, W., and **Santler, R.:** Über zwei Fälle von eosinophilem Granulom *Hautarzt,* **6,** 306 (1955). [D26876

Lindholm, S.: Mast cells in the wall of the alimentary canal. A quantitative study on human fetuses and man. *Acta path. microbiol. scand.,* sup. 132, 65 (1959). [C70944

——: The occurrence of connective tissue mast cells in the alimentary canal wall of hamster and rat. *Acta path. microbiol. scand.,* **48,** 328 (1960). [D26614

Lindner, D.: Zur vergleichenden Zellmorphologie des lockeren Bindegewebes. III. Das Zellbild der Subcutis des Schweines. *Ztschr. mikroskop.-anat. Forschg.,* **71,** 121 (1964). [G20217

——: Eine blasige Sekretionsform der Mastzellen. *Ztschr. mikroskop.-anat. Forschg.,* **71,** 270 (1964). [G20218

——: Experimentelle Untersuchungen zum Abbau von Polysacchariden in Lymphknoten. *Verhandl. Dtsch. Gesellsch. Pathol.,* **37,** 197 (1954). [D63794

——: Experimentelle Untersuchung über Stoffaufnahmen und Stoffumformung in retikulären Zellen unter besonderen Bedingungen. *Verhandl. Dtsch. Gesselsch. Pathol.,* **39,** 354 (1955). [G17153

——: Die Wirkung von Butazolidin auf des Bindegewebe, speziell auf die hyperergische Arthritis. *Proc. 4th Europ. Rheum. Congress, Istanbul Sept. 1959, Istanbul Press, p. 281* (1959). [D86255

——: Zur Theorie und Praxis metachromatischer Färbungen. *Ztrbl. allg. Pathol. Anat.,* **101,** 217 (1960). [D48381

——: Die Mastzellen, *Arch. klin. exp. Dermat.,* **213,** 588 (1961). [D12409

——: Die perkutane Resorption von Heparin. *Med. Klin.,* **58,** 1374 (1963). [E25941

Lino, S., and **Salvatore, V.:** Sui rapporti fra mastcellule e sostanze metacromatiche del connettivo. *Biol. lat. (Milano),* **8**/1, 776 (1955). [G18901

Lipschütz, B.: Untersuchungen über die Entstehung des experimentellen Teercarcinoms der Maus. *Ztschr. Krebsforschg.* **21,** 50 (1923–24). [D28696

Lison, L.: Etudes sur la métachromasie. Colorants métachromatiques et substances chromotropes. *Arch. Biol. (Liège),* **46,** 599 (1935). [D26967

——: La signification histochimique de la métachromasie. *C. R. Soc. Biol. (Paris),* **118,** 821 (1935). [D26856

——: Une réaction micro et histochimique des esters sulfuriques complexes, la "réaction métachromatique." *Bull. Soc. Chim. biol. (Paris),* **18,** 225 (1936). [D26729

——: *Histochimie et Cytochimie Animales. Principes et Méthodes.* Paris: Gauthier-Villard (1960). [D26968

Little E. G.: A contribution to the study of urticaria pigmentosa. *Brit. J. Derm.* **17,** 355, 393, 427 (1905), **18,** 16 (1905–06). [D39673

——: Sections from a case of urticaria pigmentosa in an adult. *Proc. Roy. Soc. Med.,* **1,** 165 (1908). [E53067

——: Urticaria pigmentosa of very exceptional severity. *Proc. Roy. Soc. Med.,* **3,** 3 (1910). [D52641

——: Urticaria pigmentosa of the macular type in an infant. *Proc. Roy. Soc. Med.,* **4,** 103 (1911). [E52371

——: Urticaria pigmentosa in an adult. *Proc. Roy. Soc. Med.,* **4,** 104 (1911). [E51343

——: Case of urticaria pigmentosa in an adult. *Proc. Roy. Soc. Med.,* **9,** 216 (1916). [D71210

Little, G.: Urticaria pigmentosa. *Brit. J. Derm.,* **23,** 184 (1911). [E37381

——: Urticaria pigmentosa. *Brit. J. Derm.,* **23,** 185 (1911). [G10414

——: Urticaria pigmentosa. *Brit. J. Derm.,* **20,** 232 (1908). [E37594

Loewenthal M., Schen, R. J., Berlin, C., and **Wechsler, L.:** Urticaria pigmentosa with systemic mast-cell disease. *A.M.A. Arch. Derm. Syph. (Chic.),* **75,** 512 (1957). [D39620

Löfgren, L.: The tissue mast cells, blood clotting time, and changes in the relative proportions of the white blood cells of guinea-pigs during histamine treatment. *Acta anat. (Basel),* **26,** 62 (1956). [E61351

Lombard, L. S., and **Moloney, J. B.:** Experimental transmission of mast cell sarcoma in dogs. *Fed. Proc.,* **18,** 490 (1959). [D63184

Lombardo, C.: Contributo alla conoscenza delle 'Mastzellen'. *Gazz. int. Med. Chir.,* **9,** 745 (1906). [D39600

Loomis, T. A.: Distribution and excretion of heparin. *Proc. Soc. exp. Biol. (N.Y.),* **106,** 490 (1961). [D63173

Lopez-Netto, J., Almeida, S. S., and **Lima, L. P. C.:** Miolograma do rato normal. *Rev. Inst.,* **8,** 41 (1949). [D27359

Lorentz, K.: Histochemische Untersuchung der Alcianblaufärbung mesenchymaler Gewebe. *Klin. Wchnschr.* **40,** 696 (1962). [D29001

Lorincz, A. S.: Urticaria pigmentosa treated with toluidine blue. *A.M.A. Arch. Derm. Syph. (Chic.),* **65,** 745 (1952). [E56912

Löwit, M.: Ueber färberische Differenzen zwischen der Mastzellengranulation und der Haemamoeba leucaemiae magna. *Beitr. pathol. Anat.,* **33,** 113, (1903). [E78718

Lucas, P. F.: Lymph node smears in the diagnosis of lymphadenopathy: a review. *Blood,* **10,** 1030 (1955). [D27726

Luchsinger y Centeno, J.: Über die cyklischen Veränderungen der weiblichen Brustdrüse. *Beitr. pathol. Anat.,* **78,** 594 (1927). [D30203

Lucke, V. M.: Basophilic (mast cell) leukaemia in the domestic cat. *J. Path. Bact.,* **88,** 596 (1964). [G20416

Lutzner, M. A.: Enzymatic specialization of organelles of blood cells, mast cells and platelets. *Fed. Proc.,* **23**/1, 441 (1964). [F5054

Macaluso, M. P.: Ricerche sulle Mastzellen in varie neoplasie, primitive e secondarie, del rene. *Arch. De Vecchi Anat. pat.,* **33,** 193 (1960). [D26436

——, and **Pasqualino, A.:** Sulla liberazione di istamina nei tessuti e sulla partecipazione delle Mastzellen alla genesi dei fenomeni

allergici, anafilattici e flogistici. *Arch. De Vecchi Anat. pat.,* **34,** 299 (1960). [D5225

——, and **Salerno, A.:** Antagonismo tra colloidi acidi e colloidi basici nei riguardi della colorabilità delle granulazioni specifiche delle Mastzellen. *Arch. De Vecchi Anat. pat.,* **33,** 117 (1960). [D26434

——, and ——: Ricerche sulle Mastzellen in varie malattie renali non neoplastiche. *Arch. De Vecchi Anat. pat.,* **33,** 181 (1960). [D26435

——, ——, and **Friscia, A.:** Ricerche sulla cosidetta degranulazione delle mastzellen prodotta da liberatori di istamina. *Boll. Soc. ital. Biol. sper.,* **37,** 21 (1961). [D33720

——, *cf.* **Pavone-Macaluso, M.** [D26615

MacDonald, F. R., and **Peirce, C. B.:** Urticaria pigmentosa, with bone lesions (Systemic mast cell disease). *J. Canad. Ass. Radiol.,* **8,** 15 (1957). [D33106

MacDonald, R. A., and **Robbins, S. L.:** Pathology of the heart in the carcinoid syndrome. *A.M.A. Arch. Path.,* **63,** 103 (1957). [D63175

MacDougall, J. D. B.: Experimental studies on neoplastic mast cells cultivated in vitro. *Verhandl. anat. Gesellsch. (Jena),* **101,** sup. 322 (1954). [D29156

MacIntosh, F. C.: Histamine and intracellular particles. In: *Histamine. Ciba Found. Symp., Physiol. Soc., Brit. Pharmacol. Soc.,* London: J. & A. Churchill Ltd., p. 20 (1956). [D30560

——: Histamine-releasing drugs. *Ann. Otol. (St-Louis),* **65,** 385 (1956). [C24237

——: Discussion with Riley. In: *Histamine. Ciba Foundation Symposium on Histamine.* London: J. & A. Churchill Ltd., p. 407 (1956). [D27093

Mackey, ?.: Urticaria pigmentosa. *J. cutan. Dis.,* **36,** 320 (1918). [E38006

MacLeod, J. M. H.: 1) Granuloma pudenti tropicum; 2) Urticaria pigmentosa. *Brit. J. Derm.,* **19,** 73 (1907). [E37596

——: Case of urticaria pigmentosa with bullous lesions. *Proc. Roy. Soc. Med.,* **14,** 17 (1921). [D71212

MacMaster, D.: A case of urticaria pigmentosa. *Australas. med. Gaz.,* **24,** 270 (1905). [E37983

McAuley, R. L., and **Sommers, S. C.:** Mast cells in nonspecific ulcerative colitis. *Amer. J. dig. Dis.,* **6,** 233 (1961). [D33728

McCamish, J., and **Benedict, A. A.:** Studies on immediate cutaneous hypersensitivity in mice. I. Active cutaneous hypersensitivity. *J. Immunol.,* **91,** 651 (1963). [E85501

McCleery, R. S., Schaffarzick, W. R., and **Light, R. A.:** An experimental study of the effect of heparin on the local pathology of burns. *Surgery,* **26,** 548 (1949). [D39636

McCrea, P. C.: Tissue mast cells in the bone marrow in rheumatoid arthritis. *Ann. rheum. Dis.,* **20,** 83 (1961). [D33729

McEntegart, M. G., Ross, P. W., and **Best, P. V.:** Growth of the mast-cell tumour P. 815 in thymecotomised mice. *Lancet,* **2,** 611 (1963). [E27610

McGovern, V. J.: Mast cells and metachromasia. *Austral. J. Sci.,* **17,** 176 (1955). [D31617

——: Reactions to injury of vascular endothelium with special reference to the problem of thrombosis. *J. Path. Bact.,* **69,** 283 (1955). [D28931

——: Mast cells and their relationship to endothelial surfaces. *J. Path. Bact.* **71,** 1 (1956). [D26767

——: The effect of antozoline (antistin) on endothelial surfaces. *J. Path. Bact.,* **72,** 143 (1956). [D28556

——: The mechanism of inflammation. *J. Path. Bact.,* **73,** 99 (1957). [D27739

——: Mast cells in photosensitivity reaction. *Nature (Lond.),* **191,** 90 (1961). [D26442

——, and **Archer, G. T.:** The pathogenesis of ulcerative colitis. *Australas. Ann. Med.,* **6,** 68 (1957). [D39717

McKellar, M., and **Hall, G. F.:** Systemic mast cell disease with hereditary spherocytosis. Report of a case. *N.Z. med. J.,* **59,** 151 (1960). [D26621

McKibben, P. S.: Mast cells in the meninges of necturus, easily mistaken for nerve cells. *Anat. Rec.,* **8,** 475 (1914). [D27954

McManus, J. F. A.: Histochemistry of connective tissue. In: *Connective Tissue in Health and Disease,* Copenhagen: Ejnar Munksgaard Publ., p. 31 (1954). [C821

Magni, A., and **Parmigiani, G.:** *Boll. Soc. med.-chir. Cremona,* **10,** 92 (1956). [D13214

Magnusson, S., and **Larsson, B.:** Uptake of ^{35}-S-labelled sulfate in the heparin of a dog mastocytoma. *Acta chem. scand.,* **9,** 534 (1955). [D26475

Majewski, C., Kubiak, E., and **Szulc, H.:** Les mucopolysaccharides acides du tissu conjonctif dans le carcinome de mammelle. *Acta histochem. (Jena),* **15,** 78 (1963). [E20009

Mandel, M.: Urticaire pigmentaire. *Bull. Soc. franç. Derm. Syph.,* **28,** 52 (1921). [E72211

Manfredi, G. C., Tedeschi, G., and **Casali, G.:** Considerazioni su di un caso di mastocitosi a chiara impronta epatodistrofica. *Minerva med.,* **54,** 2519 (1963). [E28481

Mannozzi-Torini, M.: Comportamento dei granuli delle cellule basofile connettivati dopo azione dell'enzima mucinolitico testicolare. *Boll. Soc. ital. Biol. sper.,* **17,** 153 (1942). [B39995

Manzini, C., and **Conti, G.:** Contributo allo studio della struttura istologica normale ed istofisiologica della mucosa gastrica dell'uomo. *Arch. ital. Mal. Appar. dig.,* **7,** 538 (1938). [D30664

Marchand, F.: Ueber Klasmatozyten, Mastzellen und Phagozyten des Netzes. *Verhandl. Dtsch. pathol. Gesellsch.,* **4,** 124 (1901). [B79772

——: Über die Herkunft der Lymphozyten und ihre Schicksale bei der Entzündung. *Verhandl. Dtsch. pathol. Gesellsch.,* **31,** 1 (1913). [48306

Margarot, J., and **Bourgoing, A.:** Urticaire pigmentaire existant depuis dix-huit ans. Signes de parasympathicotonie. *Bull. Soc. Sci. méd. biol. Montpellier,* **3,** 488 (1921-22). [E37981

Mari, E., and **Rizzatti, E.:** Comportamento delle cellule granulose basofile (Mastzellen od eparinociti) della linfa peritoneale di ratto dopo il trattamento con ACTH. *Atti 52 Congr. Soc. ital. med. int. Roma, Ottobre* (1951). [B85212

——, and ——: Comportamento delle cellule granulose basofile (Mastzellen) della linfa peritoneale di ratti normali e surrenectomizzati sottoposti a trattamento con salicilato di sodio. *Arch. E. Maragliano Pat. Clin.,* **6,** 1031 (1951). [B85211

Marie-Suzanne, Sr., and **Noel, R.:** Sur la présence de polynucléaires éosinophiles et de mastocytes dans les lésions cutanées de la lèpre tuberculoide. *Bull. Histol. Techn. micr.,* **25,** 5 (1948). [D26736

Marinone, G.: Sur la solubilité des granulations des mastzellen dans les leucémies myéloïdes. *Sang,* **18,** 405 (1947). [D26632

Marks, B. H., and **Oberer, D.:** Effects of snake venom on rabbit basophil leucocytes. *Biochem. Parmacol.,* **11,** 9 (1962). [D31908

——, **Sorgen, R.,** and **Ginsburg, H.:** Histamine-liberator 48/80 and basophilic leucocytes. *Biochem. Pharmacol.,* **2,** 201 (1959). [D82448

Marschalkó, T. von: Die Plasmazellen im Rhinoscleromgewebe; insbesondere über die hyaline Degeneration derselben auch bei einigen anderen pathologischen Processen. Ein Beitrag zur Kenntniss der sogenannten Russel'schen Körperchen. *Arch. Dermat. Syph. (Berlin),* **54,** 235 (1900). [D31616

Marshall, J., Walker, J., Lurie, H. I., Hansen, J. D. L., and **MacKenzie, D.:** Solitary mastocytoma and the mastocytoses. A discussion of the mastocytoses and a report of two cases of solitary mastocytoma showing an unusual phenomenon of generalized flushing. *S. Afr. med. J.,* **31,** 867 (1957). [D29474

Marten, R. H.: Urticaria pigmentosa. *Brit. J. Derm.,* **69,** 151 (1957). [D39706

Martin, H., and **Roka, L.:** Zur Frage des Heparin-Gehaltes der Blutmastzellen des Menschen. *Acta haemat (Basel)* **10,** 26 (1953). [D26751

Martinotti, G.: L'ematossilina, l'emateina ed il carminio. *Ztschr. Wisschftl. Mikros.,* **8,** 488 (1891). [D30606

Marx, L., Armstrong, C. W., Rucker, P., and **Marx, W.:** Effects of hypophysectomy on tissue mast cell numbers and heparin levels in the rat. *Amer. J. Physiol.,* **198,** 1261 (1960). [D26895

——, **Hirota, M., Printup, C. A., Warnick, M. A.,** and **Marx, W.:** Effects of exposure to 5°C and advancing age on tissue mast cells and heparin in male rats. *Amer. J. Physiol.,* **198,** 180 (1960). [C80411

Marx, W., Marx, L., Rucker, P., Ruggeri, L., and **Freeman, L.:** Tissue heparin and mast cells in rats and rabbits. *Proc. Soc. exp. Biol. (N.Y.),* **94,** 217 (1957). [C28984

Massa, M., and **Marinoni, E.:** Rilievi su una forma rara di mielosi leucemica e piastrinemica con emoistioblasti in orientamento basofilo. *Clin. med. ital.,* **57,** 487 (1926). [G18742

Matz, L. R., and **Skinner, S. L.:** Evidence against presence of chromaffin cells in human skin. *Circulat. Res.,* **11,** 418 (1962). [D33711

Maximow, A.: Ueber Klasmatocyten und Mastzellen. *Ztrbl. allg. Pathol. pathol. Anat.,* **14,** 85 (1903). [D27642

——: Über entzündliche Bindegewebsneubildung bei der weissen Ratte und die dabei auftretenden Veränderungen der Mastzellen und Fettzellen. *Beitr. pathol. Anat.,* **35,** 93 (1904). [B79776

——: Ueber die Zellformen des lockeren Bindegewebes. *Arch. mikros. Anat.,* **67,** 680 (1906). [B79778

——: Ueber die Entwicklung der Blut- und Bindegewebszellen beim Säugetierembryo. *Folia haematol.,* **4,** 611 (1907). [B79779

——: Experimentelle Untersuchungen zur postfötalen Histogenese des myeloiden Gewebes. *Zieglers Beitr.*, **41**, 122 (1907). [705

——: Untersuchungen über Blut und Bindegewebe. II. Über die Histogenese der Thymus bei Säugetieren. *Arch. mikros. Anat.*, **74**, 525 (1909). [87251

——: Untersuchungen über Blut und Bindegewebe. III. Die embryonale Histogenese des Knochenmarks der Säugetiere. *Arch. mikros. Anat.*, **76**, 84, 85 (1910). [D29301

——: Untersuchungen über Blut und Bindegewebe. VI. Über Blutmastzellen. *Arch. mikros. Anat.*, **83**, 247 (1913). [D29280

——: Bindegewebe und blutbildende Gewebe. (Lockeres ungeformtes Bindegewebe). In: *Handbuch der mikroskopischen Anatomie des Menschen. 2. Die Gewebe.* Berlin: Julius Springer, p. 260 (1927). [D28534

——, and **Bloom, W.**: *A Textbook of Histology.* Ed. 7, Philadelphia and London: W. B. Saunders Co., (1957). [C50889

Mazza, A.: Osservazioni sulle Mastcellule del ratto dopo irradiazione Roentgen. *Radioter. Radiobiol. Fis. med.*, **9**, 3 (1954). [E54977

Mazzi, V.: Prime osservazioni sui mastociti nell' encefalo di alcuni bassi vertebrati. *Monit. Zool. ital.*, **62**, 56 (1954). [D39757

Meachen, G. N.: Urticaria pigmentosa. *Brit. J. Derm.*, **21**, 349 (1909). [E38166

——: Urticaria pigmentosa. *Brit. J. Derm.*, **25**, 140 (1913). [E37582

Meggers, D. E., and **Allen, A. M.**: Feulgen reaction-Bismarck brown; a stain for mast cells in mitosis. *Stain Technol.*, **37**, 221 (1962). [D27664

Meier, H.: Serotonin (5-hydroxytryptamine) content of canine mastocytoma. *Proc. Soc. exp. Biol. (N.Y.)*, **100**, 815 (1959). [C67864

Meirowsky, E.: Zur Frage des Ursprungs der Mastzellengranulationen. *Folia haemat.*, **6**, 42 (1908). [D27981

Melczer, N.: Beiträge zur Ätiologie und Pathogenese der Urticaria pigmentosa. *Dermat. Wchnschr.*, **129**, 5 (1954). [D39674

Melnikova, G. I.: On the question of the experimental eosinophilia and basophilia of the blood. *(Russian text) Russkii Vratsch*, No. 6, 195 (1910). [D66284

Mendes Fagundes, J. J.: O problema da cromotropia da parede vascular e das Mastzellen peri-vasculares. *Amat. lusit.*, **7**, 253 (1949). [D39676

Meneghini, C. L.: Urticaire pigmentaire et héparine. Etude pathogénique. *Bull. Soc. franç. Derm. Syph.*, **56**, 405 (1949). [D39768

——: Novi orientamenti sul problema patogenetico dell'urticaria pigmentosa. *G. ital. Derm. Sif.*, **91**, 93 (1950). [D39847

——, and **Levi, L.**: Istaminemia e mastociti circolanti in alcune dermalosi allergiche. *G. ital. Derm.*, **100**, 449 (1959). [D89356

——, and ——: Osservazioni sperimentali in tema di mastociti e mastocitosi cutanee. Rapporti con istamina ed eparina. *Ann. ital. Derm. Sif.*, **15**, 220 (1960). [D27702

Meneghini, P.: Sul significato fisiopatologico della mastocitosi midollare. *Arch. E. Maragliano Pat. Clin.*, **9**, 1251 (1954). [D39813

Meng, H. C., and **Westerholm, B.**: Effect of some fat emulsions on histamine release from peritoneal mast cells of rats. *Toxicol. appl. Pharmacol.*, **5**, 71 (1963). [D39781

Mengel, C. E.: Biochemical and morphologic heterogeneity and variability of mast cell neoplasms in vivo. *Ann. N.Y. Acad. Sci.*, **103**, 225 (1963). [D58283

——, and **Kelly, M. G.**: Biochemical and morphologic changes in a mast cell tumor during treatment with cyclophosphamide. *Proc. Amer. Ass. Cancer Res.*, **3**, 250 (1961). [D2746

——, and ——: Biochemical and morphologic changes in a mast-cell neoplasm during treatment with cyclophosphamide. *Cancer Res.*, **21**, 1545 (1961). [D26448

——, and **Trier, J. D.**: Biochemical and morphologic heterogeneity of a mast cell tumor. *Fed. Proc.*, **20**, 136 (1961). [D3888

Mergenthaler, D. D., and **Paff, G. H.**: Peritoneal mast cells as a possible source of circulating heparin in the rat. *Anat. Rec.*, **126**, 165 (1956). [D27407

Messerklinger, W.: Über die Mastzellen in der Schleimhaut der oberen Luftwege. *Ztschr. Laryng. Rhinol.*, **39**, 447 (1960). [D26431

Messerschmitt, J.: Fréquence des mastzellen dans les frottis de moelle osseuse chez l'homme. *Rev. Hémat.*, **9**, 189 (1954). [D26705

——: La mastocytose médullaire dans les hémorragies répétées. *Sang*, **26**, 252 (1955). [D26636

Metchnikoff, E.: *Leçons sur la Pathologie Comparée de l'Inflammation.* Paris: G. Masson (1892). [B64274

Mewborn, ?.: A case of urticaria pigmentosa. *J. cutan. Dis.*, **24**, 331 (1906). [E38149

Miale, J. B.: *Laboratory Medicine-Hematology.* St. Louis: The C. V. Mosby Company, (1958). [D24134

Michaelis, L.: Beiträge zur Kenntniss der Milchsecretion. *Arch. mikros. Anat.,* **51,** 711 (1898). [D27584
——: Über Mastzellen. *Münch. med. Wchnschr.,* **49,** 225 (1902). [D27717
Michel, P. J.: Un cas d'urticaire pigmentaire d'apparition tardive. *Bull. Soc. franç. Derm. Syph.,* **58,** 326 (1948). [D39736
——, and **Saint-Paul, J.:** Curieuses pigmentations chez un nourrisson. Casus pro diagnosi. *Bull. Soc. franç. Derm. Syph.,* **60,** 226 (1950). [D39730
Michels, N. A.: Genèse hétéroplastique et homoplastique des labrocytes (Mastzellen) chez les vertébrés inférieurs. *C.R. Soc. Biol. (Paris),* **87,** 111 (1922). [D27501
——: Les labrocytes (Mastzellen) chez les poissons. *C.R. Soc. Biol. (Paris),* **74,** 115 (1922). [D27502
——: The mast cell in the lower vertebrates. *Cellule,* **33,** 339 (1923). [D65511
——: The plasma cell. A critical review of its morphogenesis, function and developmental capacity under normal and under abnormal conditions *A.M.A. Arch. Path.,* **11,** 775 (1931). [D28685
——: Susceptibility of the omentum of rabbits to a single erythema dose (400R) of roentgen rays. *Amer. J. Anat.,* **52,** 333 (1933). [D27955
——: The mast cells. In: *Downey, Handbook of Hematology.* New York: P. B. Hoeber Inc., **1,** 232 (1938). Reprinted: *Ann. N.Y. Acad. Sci.,* **103,** 235 (1963). [C72066
——, and **Globus, J. H.:** The so-called small round-cell infiltrations. *Anat. Rec.,* **42,** 28 (1929). [D27709
——, and ——: The so-called small round cell infiltrations. II. Syphilis and the central nervous system. *A.M.A. Arch. Path.,* **8,** 417 (1929). [D27401
Michelson, ?.: Urticaria pigmentosa. *A.M.A. Arch. Derm. Syph. (Chic.),* **6,** 644 (1922). [E38160
Mikhail, G. R., and **Miller-Milinska, A.:** Mast cell population in human skin. *J. invest. Derm.,* **43,** 249 (1964). [D11944
Milchner, R.: Ueber die Emigration von Mastzellen bei myelogener Leukämie. *Ztschr. klin. Med.,* **37,** 194 (1899). [D29581
Milian, M., and **Périn, ?.:** Présentation d'une malade atteinte d'urticaire pigmentaire. *Bull. Soc. franç. Derm. Syph.,* **28,** 126 (1921). [E43369
Mills, J., Strickland, G., and **Paterson, J. C.:** The validity of tissue mast-cell counts in postmortem material. *A.M.A. Arch. Path.,* **66,** 330 (1958). [D39712
Miskolczy-Fodor, F.: Über Mastzellen in Tonsillen unter normalen und pathologischen Verhältnissen. *Pract. oto-rhino-laryng. (Basel),* **12,** 44 (1950). [D31580
Mitchell, R. G.: Basophilic leucocytes in children in health and diseases. *Arch. Dis. Childh.,* **33,** 193 (1958). [D92371
——, and **Cass, R.:** Histamine and 5-hydroxytryptamine in the blood of infants and children. *J. clin. Invest.,* **38,** 595 (1959). [C66822
Mizuta, K.: Changes in the number or basophilic cells in peripheral blood caused by drugs affecting the anatomic or endocrine system. *J. Kurume med. Ass.,* **25,** 1163 (1962). G15673
Moeschlin, S.: Beitrag zur Morphologie der reticuloendothelialen Zellen des intravitalen Lymphknotenpunktats. *Folia haemat.,* **65,** 181 (1941). [D30597
el-Mofty, A. M., el-Komy, H. M., Abdeen, F. H., and **el-Shihi, A. W.:** Urticaria pigmentosa. Correlation of clinical, histopathological and biochemical findings. *J. Egypt. med. Ass.,* **45,** 45 (1962). [D56904
Möllendorff, W. von: Die örtliche Zellbildung in Gefässwänden und im Bindegewebe. *Münch. med. Wchnschr.,* **74,** 135 (1927). [B78338
Moloney, W. C., and **Lange, R. D.:** Cytologic and biochemical studies on the granulocytes in early leukemia among atomic bomb survivors. *Tex. Rep. Biol. Med.,* **12,** 887 (1954). [G18692
Mondina, R.: Presenza e significato delle Mastzellen nei fibromiomi dell'utero. *Ann. Ostet. Ginec.,* **78,** 437 (1956). [E54833
Mongar, J. L., and **Perera, B. A. V.:** The role of the chymotrypsinlike enzyme in rat mast cells in anaphylaxis. *Biochem. Pharmacol.,* **12,** sup., 213 (1963). [E32256
——, and ——: Oxygen consumption of isolated mast cells in the anaphylactic reaction. *Nature (Lond.),* **202,** 93 (1964). [G9089
——, and **Schild, H. O.:** Effect of antigen and organic bases on intra-cellular histamine in guinea-pig lung. *J. Physiol (Lond.)* **131,** 207 (1956). [D27601
——, and ——: Cellular mechanism in anaphylaxis. *Physiol. Rev.,* **42,** 226 (1962). [D22507
Monkhouse, F. C., and **Baker, D. G.:** Skin heparin levels and postheparin plasma clearing factor lipase levels in irradiated adrenalectomized and cortisone-treated rats. *Canad. J. Biochem.,* **41,** 1901 (1963). [E27204

Montagna, W.: *The Structure and Function of Skin.* New York: Academic Press Inc. (1956). [D61511

——: Histology and cytochemistry of human skin. XI. The distribution of B-glucuronidase. *J. biophys. biochem. Cytol.,* **3,** 343 (1957). [D28264

——, **Chase, H. B.,** and **Melaragno, H. P.:** Histology and cytochemistry of human skin. I. Metachromasia in the mons pubis. *J. nat. Cancer Inst.,* **12,** 591 (1951). [D28552

——, **Eisen, A. Z.,** and **Goldman, A. S.:** The tinctorial behavior of human mast cells. *Quart. J. micr. Sci.,* **95,** 1 (1954). [D27628

——, and **Melaragno, H. P.:** Histology and cytochemistry of human skin. III. Polymorphism and chromotropy of mast cells. *J. invest. Derm.,* **20,** 257 (1953). [D26849

——, and **Noback, C. R.:** Acid phosphatase and lipids in the cells of the rat. *Science,* **106,** 19 (1947). [D26642

——, and ——: Localization of lipids and other chemical substances in the mast cells of man and laboratory mammals. *Anat. Rec.,* **100,** 535 (1948). [D26717

Montagnon, ?.: Urticaire pigmentaire chronique. *Loire méd.,* **29,** 409 (1910). [D38347

Montgomery, P. O., Dillon, T., and **Goth, A.:** The effect of a histamine liberator (Compound 48/80) on methylcholanthrene induced skin carcinoma in mice. *Tex. Rep. Biol. Med.,* **14,** 432 (1956). [D65675

Moore, J. E., and **James, G. W.:** A simple direct method for absolute leucocyte count. *Proc. Soc. exp. Biol. (N.Y.),* **82,** 601 (1953). [D27613

Moore, R. D.: Mast cells of the human umbilical cord. *Amer. J. Path.,* **32,** 1179 (1956). [D26869

——, and **Schoenberg, M. D.:** Studies on connective tissue. I. The polysaccharides of the human umbilical cord. *A.M.A. Arch. Path.,* **64,** 39 (1957). [D30210

Moran, N. C., Uvnäs, B., and **Westerholm, B.:** Release of 5-hydroxytryptamine and histamine from rat mast cells. *Acta physiol. scand.,* **56,** 26 (1962). [D33693

——, and **Westerholm, B.:** The influence of reserpine on 5-hydroxytryptamine and histamine content of rat mast cells and of some rat tissues. *Acta physiol. scand.,* **58,** 20 (1963). [D69395

Morelle, L.: Sur le comportement des leucocytes basophiles dans certains chocs experimentaux. *C.R. Soc. Biol. (Paris),* **107,** 904 (1931). [D27509

Moretti, G., Giacometti, C., Boido, V., and **Rebora, A.:** Histamine, serotonin and mast cells in the skin of the rat during the hair cycle. *J. invest. Derm.,* **40,** 205 (1963). [D64379

——, ——, **Rossi, G.,** and **Rebora, A.:** Cutaneous histamine, 5HTA, mast cell quantitative changes and hair cycles of Wistar rats. *Excerpta med. (Amst.), Int. Congr. Ser.,* **52,** 97 (1962). [D27515

Morozova, M. M.: The histochemistry of mast cells in rheumatism. (Russian text). In: *Serov, Gistockhimia v Patologicheskoi Anatomii.* Moscow: I. M. Sechenov Medical Institute, p. 67 (1963). [G9435

Morrione, T. G.: The formation of collagen fibres by the action of heparin on soluble collagen: an electron microscope study. *J. exp. Med.,* **96,** 107 (1952). [D27615

Mosinger, M., Cartouzou, G., and **de Bisschop, G.:** Sur le syndrome général et le syndrome local dus à l'administration de fortes doses de substances cancérigènes chez le cobaye et le rat. *C.R. Soc. Biol. (Paris),* **154,** 1017 (1960). [C97657

——, **Luccioni, F., Jouglard, J. P., Duplay, J., Versino, A.,** and **de Bisschop, G.:** Corrélations neuro-cutanées et conséquences neuro-endocriniennes de l'épidermectomie et des brûlures. *Acta neuroveg. (Wien),* **24,** 250 (1962). [D59136

Mota, I.: Effect of antigen and octylamine on mast cells and histamine content of sensitized guinea-pig tissues. *J. Physiol. (Lond.),* **147,** 425 (1959). [D26755

——: A method for quantitative estimation of mast cells in the bone marrow of the rat. *Blood,* **6,** 81 (1951). [D26756

——: Action of anaphylactic shock and anaphylatoxin on mast cells and histamine in rats. *Brit. J. Pharmacol.,* **12,** 453 (1957). [D27088

——: Mast cells and anaphylaxis. *J. Physiol. (Lond.),* **140,** 6P (1958). [D26425

——: Mast cell and histamine in rat anaphylaxis: the effect of Haemophilus pertussis. *Nature (Lond.),* **182,** 1021 (1958). [C61610

——: The mechanism of action anaphylatoxin. Its effect on guinea pig mast cells. *Immunol.,* **2,** 403 (1959). [D26627

——: Mechanism of action of antigen-antibody complexes: their effect on mast cells. *Nature (Lond.),* **191,** 572 (1961). [D10505

——: Mast cell lytic antibodies. *Nature (Lond.),* **192,** 1201 (1961). [D27900

——: Failure of rat and rabbit antiserum to passively sensitize normal and pertussis-treated rats and mice so as to induce mast

cell damage and histamine release on later contact with antigen. *Immunology,* **5,** 11 (1962). [G12259

——: Mast cells and anaphylaxis. *Ann. N.Y. Acad. Sci.,* **103,** 264 (1963). [D58285

——: The behavior of mast cells in anaphylaxis. *Int. Rev. Cytol.,* **15,** 363 (1963). [E22516

——: Mast cell lytic antibody. *Fed. Proc.,* **22**/1, 559 (1963). [G5487

——: Passive cutaneous anaphylaxis induced with mast cell sensitizing antibody. The role of histamine and 5-hydroxytryptamine. *Life Sci.,* **?,** No. 12, 917 (1963). [E36462

——, **Beraldo, W. T., Ferri, A. G.,** and **Junqueira, L. C. U.:** Intracellular distribution of histamine. *Nature (Lond.),* **174,** 698 (1954). [D27632

——, ——, ——, and ——: Action of 48/80 on the mast cell population and histamine content of the wall of the gastrointestinal tract of the rat. In: *Histamine, Ciba Foundation Symposium.* London: J. & A. Churchill, p. 47 (1956). [C31032

——, ——, and **Junqueira, L. C. U.:** Protamine-like property of compounds 48/80 and stilbamidine and their action on mast cells. *Proc. Soc. exp. Biol. (N.Y.),* **83,** 455 (1953). [B85350

——, **Ferri, A. G.,** and **Junqueira, L. C. U.:** Action of peptone on the mast cells and histamine content of dog tissues. *Acta haemat. (Basel),* **15,** 409 (1956). [C18184

——, ——, and **Yoneda, S.:** The distribution of mast-cells in the digestive tract of laboratory animals: its bearings on the problem of the location of histamine in tissues. *Quart. J. micr. Sci.,* **97,** 251 (1956). [D27629

——, and **Ishii, T.:** Inhibition of mast cell disruption and histamine release in rat anaphylaxis in vitro. Comparison with compound 48/80. *Brit. J. Pharmacol.,* **15,** 82 (1960). [D26569

——, **Junqueira, L. C. U., Beraldo, W. T.,** and **Ferri, A. G.:** Action of peptone on mast cells of the dog. *Nature (Lond.),* **173,** 547 (1954). [D26758

——, and **Dias da Silva, W.:** Antigen-induced damage to isolated sensitized mast cells. *Nature (Lond.),* **186,** 245 (1960). [D26065

——, and ——: The anti-anaphylactic and histamine-releasing properties of the antihistamine. Their effect on the mast cells. *Brit. J. Pharmacol.,* **15,** 396 (1960). [D26563

——, ——, and **Fernandes, J. F.:** The inhibition of mast cell damage and histamine release in anaphylaxis by pyridine and diphosphopyridine nucleotidase inhibitors. Comparison with compound 48/80. *Brit. J. Pharmacol.,* **15,** 405 (1960). [D30208

——, and **Vugman, I.:** Action of compound 48/80 on the mast cells and histamine content of guinea-pig tissues. *Brit. J. Pharmacol.,* **11,** 304 (1956). [D26566

——, and ——: Effects of anaphylactic shock and compound 48/80 on the mast cells of the guinea-pig lung. *Nature (Lond.),* **177,** 427 (1956). [D27087

Moursund, M. P., and **Hirschmann, V. R.:** Telangiectasia macularis eruptiva perstans. Review of the literature, report of a case of the etiology and pathology of generalized telangiectasia. *A.M.A. Arch. Derm.,* **63,** 232 (1951). [G12247

Mulligan, R. M.: Neoplastic diseases of dogs. II. Mast cell sarcoma, lymphosarcoma, histiocytoma. *A.M.A. Arch. Path.,* **46,** 477 (1948). [D39723

Münchheimer, F.: Über Mastzellen im thierischen und menschlichen Hoden. *Fortschr. Med.,* **13,** 104 (1895). [A47205

Murray, J. A.: The zoological distribution of cancer. *A.R. imp. Cancer Res. Fd.,* **3,** 41 (1908). [D31527

Mutsaars, W., and **Lison, L.:** L'action antimétachromatique de la streptomycine. *Ann. Inst. Pasteur,* **78,** 262 (1950). [D26715

Mutter, R. D., Tannenbaum, M., and **Ultmann, J. E.:** Systemic mast cell disease. *Ann. intern. Med.,* **59,** 887 (1963). [E36471

Myers, D. K., Schotte, A., and **Mendel, B.:** Studies on ali-esterases and other lipid-hydrolysing enzymes: 2. Effect of heparin injection on alimentary lipemia and on plasma esterases. *Biochem. J.,* **60,** 481 (1955). [D39682

Myslivecek, J.: Influence de la thromboplastine et de la vitamine K sur les héparinocytes chez le rat. *C.R. Soc. Biol.,* **142,** 1041 (1948). [D31571

Nagayo, M.: Studien über die Gewebsmastzellen. *Ztrbl. allg. Pathol. u. pathol. Anat.,* **43,** 289 (1928). [D26871

Nakajima, Y.: Studien über Gewebsmastzellen. *Trans. jap. Path. Soc.,* **18,** 150 (1928). [D39782

Natale, P.: Su di un caso leucemia a basociti. *Haematologica,* **36,** 1243 (1952). [G18739

Nay, T.: Mast cells and hair growth in the mouse. *Austral. J. biol. Sci.,* **9,** 442 (1956). [D65634

Negri, P.: Sulla presenza e sul comportamento delle Mastzellen nella pars cavernosa

dell'uretra dell'uomo e degli animali domestici. *Sperimentale,* **95,** 539 (1941). [D31632

Nepriakhin, G. G.: About basophilic fuchsinophilic granules of nervous tissue and mast cells. *Arkh. Pat.,* **18,** 26 (1956). [D26879

——: Mast cells of the nervous system. (Russian text) *Arkh. Pat.,* **22,** 53 (1960). [D26802

Nettleship, E., and **Tay, W.:** Rare forms of urticaria. *Brit. med. J.,* **2,** 323 (1869). [D27987

Neumann, A.: Zum Wesen der Romanowsky-Nochtschen Färbung (relative Metachromasie). *Ztrbl. Bakt., I. Abt. Orig.,* **43,** 746 (1907). [D27640

Neumann, E. T., *cf.* Thonnard-Neumann, E. [D20120

Neumann, J.: Über das Vorkommen der sogenannten 'Mastzellen' bei pathologischen Veränderungen des Gehirns. *Virchows Arch. pathol. Anat.,* **122,** 378 (1890). [D29310

Niccoli-Vallesi, R., *cf.* Vallesi, R. N. [D39807, D31597

Nickel, W. R.: Urticaria pigmentosa. *A.M.A. Arch. Derm.,* **76,** 476 (1957). [D27886

Nicolas, J., and **Moutot, H.:** Urticaire pigmentaire. *Lyon méd.,* **113,** 1088 (1909). [E39356

Niebauer, G.: Der gegenwärtige Stand der Mastzell-Forschung. *Klin. Wchnschr.,* **38,** 673 (1960). [C90011

——: Die Bedeutung der Mastzellen innerhalb des neurovegetativen Systems. *Arch. klin. exp. Dermat.,* **213,** 556 (1961). [D12405

——: Morphologie und Funktion der Mastzellen bei allergischen Reaktionen. *Wien. klin. Wchnschr.,* **75,** 174 (1963). [D58906

——, and **Wiedmann, A.:** Zur Histochemie des neurovegetativen Systems der Haut. *Acta neuroveg. (Wien),* **18,** 280 (1958). [D39678

Nielsen, K.: Acid fuchsin. Unpublished. [G2900

Nielsen, S. W.: Clinical aspects of mastocytoma in dogs. Frequency, regional involvement, metastasis, recurrence, and differential clinical and pathological diagnosis. *Proc. Amer. vet. med. Ass., 89th meeting,* p. 212 (1952). [D31566

——, and **Cole, C. R.:** Canine mastocytoma. A report of one hundred cases. *Am. J. vet. Res.,* **19,** 417 (1958). [D67466

Niessing, ?., Slonimski, ?., Watzka, ?., Tonutti, E., and **Hirt, A.:** Discussions. *Anat. Anz.,* sup. 87, 104 (1938–39). [D33744

Nigro, N.: Ricerche sulla eparinemia e sulla tolleranza eparinica nella malattia reumatica dell'infanzia. *Minerva pediat.,* **11,** 115 (1959). [D35450

——, and **Pavesio, D.:** Rilievi tromboelastografici nella malattia reumatica dell' infanzia. *Minerva pediat.,* **14,** 61 (1962). [D35454

Nikkilä, E. A., and **Majanen, S.:** The blood heparinoid substances in human atherosclerosis. *Scand. J. clin. Lab. Invest.,* **4,** 204 (1952). [D26329

Nikulin, A., Ferluga, J., and **Stern, P.:** Einfluss der Menge des Gewebe-Histamins auf den Entzündungsprozess. *Acta med. iugosl.,* **16,** 187 (1962). [E24333

Ninni, M., and **Belloni, F.:** Sulla transformazione della leucemia mieloide cronica in leucemia basofila subacuta. *Haematologica,* **37,** 1455 (1953). [G11139

Nishiyama, R., Tasaka, K., and **Irino, S.:** The sites of action of some histamine-releasing substances in the dog. *Acta med. Okayama,* **11,** 133 (1957). [D31565

Nixon, C. W., Whitney, R., Baker, J. R., and **Homburger, F.:** Primary myopathy in an inbred line (B10 1.50 [Whitney]) of Syrian golden hamsters. *Fed. Proc.,* **21,** 313 (1962). [G7817

Noback, C. R., and **Montagna, W.:** Some histochemical aspects of the mast cell with special reference to alkaline phosphatase and cytochrome oxidase. *Anat. Rec.,* **96,** 279 (1946). [95640

Nordmann, O.: Beiträge zur Kenntnis und namentlich zur Färbung der Mastzellen. *Intern. Monatschr. Anat. Histol.,* **2,** 179 (1885). [D28272

Norins, A. L., Gould, W. M.: The photodynamic action of neutral red on rabbit basophils. *J. invest. Derm.,* **42,** 257 (1964). [F7147

Norris, H. T., Zamcheck, N., and **Gottlieb, L. S.:** The presence and distribution of mast cells in the human gastrointestinal tract at autopsy. *Gastroenterology,* **44,** 448 (1963). [D68628

Norton, S.: Quantitative determination of mast cell fragmentation by compound 48/80. *Brit. J. Pharmacol.,* **9,** 494 (1954). [D26564

——, and **de Beer, E. J.:** Effect of some antibiotics on rat mast cells in vitro. *Arch. int. Pharmacodyn.,* **102,** 352 (1955). [D30591

——, and ——: Action of histamine liberators and antihistamines on mast cells in vitro. *Fed. Proc.,* **14,** 374 (1955). [C5279

Nozaka, K., and **Simpson, W. L.:** Mast cells in the human pylorus and cervix. *Anat. Rec.,* **142,** 263 (1962). [D63181

Numers, C. von: The role of vitamin C in the mucopolysaccharides metabolism of the skin. Studies on free mucopolysaccharides and mast cells in the intact skin and during wound healing in normal and scorbutic guinea-pigs. *Ann. Med. exp. Fenn.,* **31,** 398 (1953). [D26635

——, and **Fortelius, P.:** Untersuchungen über den Gehalt des Tumorgewebes an freier chromotroper Substanz und Mastzellen bei verschiedenen Formen von Cystadenoma serosum ovarii. *Ann. Med. exp. Fenn.,* **31,** 133 (1953). [D67345

Oates, J. A., Marsh, E., and **Sjoerdsma, A.:** Studies on histamine in human urine using a fluorometric method of assay. *Clin. chim. Acta,* **7,** 488 (1962). [G11136

Obermayer, M. E., and **Rosman, D.:** Urticaria pigmentosa bullosa. *A.M.A. Arch. Derm. Syph. (Chic.),* **69,** 626 (1954). [D39608

Oettgen, H. F., and **Quitmann, K.:** Weitere Untersuchungen zur Morphologie der Makroglobulinämie Waldenström. *Frankf. Ztschr. Pathol.,* **67,** 599 (1956). [D39688

Ogawa, S.: On seasonal variations in circulating basophils and eosinophils. (Japanese text). *Jap. J. med. Progr.,* **50,** 320 (1963). [E63367

Oliver, ?.: Urticaria pigmentosa. *A.M.A. Arch. Derm. Syph. (Chic.),* **2,** 112 (1920). [E38162

Oliver, J., Bloom, F., and **Mangieri, C.:** On the origin of heparin. An examination of the heparin content and the specific cytoplastic particles of neoplastic mast cells. *J. exp. Med.,* **86,** 107 (1947). [D26764

Oliverio, V. T., and **Kelly, M. G.:** Some pharmacological properties of a tumor inhibitory methyl hydrazine derivative. *Proc. Amer. Ass. Cancer Res.,* **5,** 49 (1964). [F2926

Olivi, M.: Mastzellen ed epiteli mucipari nelle mammelle di topi sottoposti a stimolazione ormonale. *Lav. Ist. Anat. Univ. Perugia,* **15,** 77 (1955). [C14795

Olsen, N. S., and **Smith, R. O.:** Relationship of mast-cells and heparin to foreign proteins. *Amer. J. Physiol.,* **159,** 583 (1949). [D39507

Olson, ?.: Urticaria pigmentosa in the adult. *A.M.A. Arch. Derm. Syph. (Chic.),* **4,** 844 (1921). [E37384

Ono, S., Zompetti, L., Hagen, P., and **Furth, J.:** Relation of mastocytoma to mast cell leukemia, and of heparin, histamine and serotonin to mast cells. *Blood,* **14,** 770 (1959). [D27408

Orfanos, C., and **Stüttgen, G.:** Electronenmikroskopische Beobachtungen zur Mastzellendegranulation bei der diffusen Mastocytose des Menschen. *Arch. klin. exp. Dermat.,* **214,** 521 (1962). [D32154

——, and ——: Das Zerfallsstadium und die Folgen der Mastzelldegranulierung mit besonderer Berücksichtigung der mesenchymalen Reaktion. *Ztschr. Zellforschg. mikroskop. Anat.,* **61,** 622 (1963). [E37429

Oria, J.: Mast-células conetivas nos interstícios do epitelio glandular mucíparo. *Ann. Fac. Med. S. Paulo,* **21,** 121 (1945). [D26726

Orkin, M., and **Schwartzman, R. M.:** Cutaneous tumors. The mast cell and canine mastocytoma. *Vet. Med.,* **54,** 315 (1959). [D67468

——, and ——: Comparative study of canine and human dermatology: II. Cutaneous tumors: the mast cell and canine mastcytoma. *J. invest. Derm.,* **32,** 451 (1959). [C70193

Orlandi, G.: Osservazioni sulla presenza, sulla distributione numerica e sul significato delle Mastzellen nella mucosa nasale. *Arch. ital. Otol.,* **72,** 34 (1961). [D26659

——: Sulla presenza e sul significato delle Mastzellen negli epiteliomi laringei. *Arch. ital. Otol.,* **72** 397 (1961). [D26658

——: Osservazioni sul comportamento delle Mastzellen nelle neoplasie maligne tonsillari e del rinofaringe. *Arch. ital. Otol.,* **73,** 47 (1962). [D33261

Ormsby, ?.: Urticaria pigmentosa. *J. cutan. Dis.,* **35,** 855 (1917). [E38144

——: Urticaria pigmentosa. *J. cutan. Dis.,* **36,** 469 (1918). [E38007

——, and **Mitchell, ?.:** Urticaria pigmentosa, acquired. *J. cutan. Dis.,* **37,** 269 (1919). [E38012

——, and ——: Urticaria pigmentosa. *A.M.A. Arch. Derm. Syph. (Chic.),* **7,** 134 (1923). [E25267

Ormsby, O. S., and **Montgomery, H.:** *Diseases of the Skin.* Philadelphia: Lea & Febiger (1948). [E37428

Orr, J. W.: The changes antecedent to tumour formation during the treatment of mouse skin with carcinogenic hydro-carbons. *J. Path. Bact.,* **46,** 495 (1938). [D27606

Osada, Y.: The influence of hormones on the basophil leucocytes. *Bull. Inst. Publ. Health (Tokyo),* **4,** 1 (1954). [C41768

——: Diurnal rhythms of the numbers in circulating basophils and eosinophils in healthy adults. *Bull. Inst. Publ. Health (Tokyo),* **5,** 5 (1956). [C41767

——, and **Ogawa, S.**: Local accumulation of basophils and eosinophils produced by repeated intraperitoneal injection of horse serum in guinea-pigs. *Bull. Inst. Publ. Health (Tokyo),* **11**, 111 (1962). [E48023

Osgood, E. E., Seaman, A. J., Tivey, H., and **Rigas, D. A.**: Duration of life and of the different stages of maturation of normal and leukemic leukocytes. *Rev. Hemat.,* **9**, 543 (1954). [D62861

Ottoson, R., Kahn, K., and **Glick, D.**: Dry mass of mast cells measured by interference microscopy and X-ray absorption. *Exp. Cell Res.,* **14**, 567 (1958). [D31592

Padawer, J.: Studies of endocrine influences upon the cellular components of peritoneal fluid. *Thesis, New York University* (1954). [D64997

——: Hormonal influence upon the mast cells of peritoneal fluid. *Anat. Rec.,* **118**, 275 (1954). [B95453

——: Studies on mammalian mast cells. *Trans. N.Y. Acad. Sci.,* **19**, 690 (1957). [D30194

——: A stain for mast cells and its application in various vertebrates and in a mastocytoma. *J. Histochem. Cytochem.,* **7**, 352 (1959). [D30206

——: Quantitative study of mast cell alteration following colchicine injection in the rat. *Anat. Rec.,* **133**, 416 (1959). [D33680

——: Effect of colchicine and related substances on the morphology of peritoneal mast cells. *J. nat. Cancer Inst.,* **25**, 731 (1960). [D26620

——: Autoradiographic studies with mast cells. *Anat. Rec.,* **139**, 343 (1961). [D63166

——: Autoradiography of mast cells incubated with tritiated histidine, cytidine or thymidine. A preliminary report. *Angiology,* **12**, 538 (1961). [D26701

——: Effect of podophyllin lignans on mast cell morphology in rat peritoneal fluid. *Am. J. Physiol.,* **200**, 1340 (1961). [D26320

——: Quantitative studies with mast cells. *Ann. N.Y. Acad. Sci.,* **103**, 87 (1963). [D58275

——: Mast cells and basophils. *Ann. N.Y. Acad. Sci.,* **103**, 1 (1963). [G5248

——, and **Gordon, A. S.**: Peritoneal fluid as a site for the study of endocrine effects on blood cells. *J. Clin. Endocrinol.,* **13**, 850 (1953). [B83891

——, and ——: Isolation of mast cells from other cellular elements of rat peritoneal fluid. *Proc. Soc. exp. Biol. (N.Y.),* **88**, 29 (1955). [D27619

——, and ——: Mammalian mast cells and histamine liberators. *Anat. Rec.,* **121**, 411 (1955). [D63174

——, and ——: Effects of colchicine on mast cells of the rat. *Proc. Soc. exp. Biol. (N.Y.),* **88**, 522 (1955). [D26447

——, and ——: Hormonal influences upon mast cells. *J. clin. Endocr.,* **15**, 873 (1955). [C7186

——, and ——: Studies on peritoneal fluid in the pregnant rat. *Amer. J. Obstet. Gynec.,* **72**, 79 (1956). [C18005

——, and ——: Cellular elements in the peritoneal fluid of some mammals. *Anat. Rec.,* **124**, 209 (1956). [D27053

——, and ——: Peritoneal fluid mast cells: their numbers and morphology in rats of various body weights (ages). *J. Geront.,* **11**, 268 (1956). [C21135

——, and ——: Effects of colchicine and podophyllotoxin on mast cells. *Anat. Rec.,* **124**, 427 (1956). [D33681

——, and ——: Endocrine influences on the mast cells of the rat. *Anat. Rec.,* **124**, 659 (1956). [C19322

——, **Marsland, D.,** and **Pankove, J. I.**: Return to sphericity following centrifugal elongation of rat mast cells. I. Population studies with rats of different ages. *Exp. Cell Res.,* **21**, 316 (1960). [D26629

——, ——, and ——: Return to sphericity following centrifugal elongation of rat mast cells. II. Studies with individual cells. *Exp. Cell Res.,* **25**, 65 (1961). [D26628

——, **Zimmerman, A. M., Auclair, W.,** and **Marsland, D.**: Pressure-centrifuge studies on the mast cells of peritoneal fluid in rats of various ages. *Exp. Cell Res.,* **15**, 570 (1958). [D29151

——, ——, **Gordon, A. S.,** and **Marsland, D.**: Effect of high hydrostatic pressures on colchicine-damaged mast cells of peritoneal fluid. *Proc. Soc. exp. Biol. (N.Y.),* **92**, 328 (1956). [D26480

Paff, G. H., and **Bloom, F.**: Vacuolation and the release of heparin in mast cells cultivated in vitro. *Anat. Rec.,* **104**, 45 (1949). [D26472

——, ——, and **Reilly, C.**: The morphology and behavior of neoplastic mast cells cultivated in vitro. *J. exp. Med.,* **86**, 117 (1947). [D26765

——, and **Mergenthaler, D. D.**: Vacuolation in normal mast cells and in mast cells treated with protamine sulfate. *Anat. Rec.,* **121**, 579 (1955). [D27516

——, **Montagna, W.,** and **Bloom, F.**: Cytochemical studies of normal and tumor mast cells in tissue and in vitro. *Cancer Res.,* **7**, 798 (1947). [D27729

——, and **Stewart, R.**: Free wandering

cells and cortisone. *Proc. Soc. exp. Biol. (N.Y.),* **83,** 591 (1953). [B85351
——, **Sugiura, H. T., Boucher, C. A.,** and **Roth, J. S.:** The probable mechanism of heparin inhibition of mitosis. *Anat. Rec.,* **114,** 499 (1952). [D28673
Palo, A. de, and **Papadia, S.:** Aspetti morfologici e significato biologico delle Mastzellen e della metacromasia stromale nei linfonodi satelliti degli epiteliomi della portio. *Quad. Clin. ostet. ginec.,* **10,** 29 (1955). [C9397
Palva, T., and **Palva, A.:** Allergic changes in mastoiditis. *Acta oto-laryng. (Stockh.),* **56,** 215 (1963). [D68123
Paniagua, G., López-Galiacho, E., and **Casado, M. J.:** Anemias aplasticas. Los mastocitos en la médula ósea como interesante dato citologico de aplicación a su diagnóstico. *Rev. clin. esp.,* **50,** 135 (1953). [D39785
Paplanus, S. H., and **Sheldon, W. H.:** Acute inflammation and tissue mast cells in adrenalectomized rats with cutaneous mucormycosis. *J. exp. Med.,* **118,** 165 (1963). [E21614
Pappenheim, A.: Eine neue chemisch-elektive Doppelfärbung für Plasmazellen. *Monatsh. prakt. Derm.,* **33,** 79 (1901). [D28277
——: Zusatz zu der Mitteilung von Pröscher über experimentelle Leukocytosen. *Folia haemat. (Lpzg.),* **1,** 686 (1904). [D31529
——: Erwiderung auf die 'kritischen Bemerkungen' von Türk. *Folia haemat. (Lpzg.),* **2,** 591, 671, 764 (1905). [E90962
——: *Atlas der Menschlichen Blutzellen.* Jena: Gustav Fisher (1905). [G19254
——: Über Mastzellen. *Folia haemat. (Lpzg.),* **5,** 156 (1908). [D33701
——: Einige interessante Tatsachen und theoretische Ergebnisse der vergleichenden Leukozytenmorphologie. *Folia haemat. (Lpzg.),* **8,** 504 (1909). [D27984
——, and **Nakano, J.:** Beiträge über Beziehungen zwischen Vitalfärbung Supravitalfärbung und Oxydasereaktion. *Folia haemat. (Lpzg.),* **14,** 260 (1912). [D27418
——, and **Szécsi, S.:** Hämazytologische Beobachtung bei experimenteller Saponinvergiftung der Kaninchen. *Folia haemat. (Lpzg.),* **13,** 25 (1912). [D30558
Parekh, A. C. and **Glick, D.:** Heparin and hexosamine in isolated mast cells: determination, intracellular distribution, and effects of biological state. *J. biol. Chem.,* **237,** 280 (1962). [D27898
Parish, W. E.: The distribution of mast cells and the possible function of some of their pharmacological agents. In: *Chalmers et al., Biological Aspects of Occlusive Vascular Disease.* Cambridge: University Press, p. 84 (1964). [E4391
——, **Richards, C. B.; France, N. E.** and **Coombs, R. R. A.:** Further investigations on the hypothesis that some cases of cot-death are due to a modified anaphylactic reaction to cow's milk. *Int. Arch. Allergy,* **24,** 215 (1964). [G16492
Parounagian, ?.: Urticaria pigmentosa. *A.M.A. Arch. Derm Syph. (Chic.),* **7,** 123 (1923). [E37996
Parratt, J. R. and **West, G. B.:** The location and possible function of tissue 5-hydroxytryptamine in the rat. *J. Physiol. (Lond.),* **134,** 11P (1956). [C26727
——, and ——: Tissue histamine and 5-hydroxytryptamine. *J. Physiol. (Lond.),* **132,** 40 (1956). [C19991
——, and ——: 5-Hydroxytryptamine and the anaphylactoid reaction in the rat. *J. Physiol. (Lond.),* **139,** 27 (1957). [C56384
——, and ——: 5-Hydroxytryptamine and tissue mast cells. *J. Physiol. (Lond.),* **137,** 169 (1957). [C37857
——, and ——: Release of 5-hydroxytryptamine and histamine from tissues of the rat. *J. Physiol. (Lond.),* **137,** 179 (1957). [C37858
Parrot, J. L. and **Laborde, C.:** Captation de l'histamine par l'héparine. *C.R. Soc. Biol. (Paris),* **145,** 1047 (1951). [B74584
Paschoud, J. M.: Experimentelle Untersuchungen zur Heparin-Genese der Urticaria pigmentosa. *Dermatologica (Basel),* **108,** 361 (1954). [D26812
Pasternak, C. A.: The synthesis of 3'-phosphoadenosine 5'-phosphosulfate by mouse tissues: sulfate activation in vitro and in vivo. *J. biol. Chem.,* **235,** 438 (1960). [D67481
Paterson, J. C. and **Mills, J.:** Myocardial mast-cell counts in coronary sclerosis. *A.M.A. Arch. Path.,* **66,** 335 (1958). [C71884
Paton, W. D. M.: Histamine metabolism. *Int. Arch. Allergy,* **6,** 203 (1955). [D39572
——: The mechanism of histamine release. In: *Histamine, Ciba Found. Sympos. Physiol. Soc., Brit. Pharmacol. Soc.,* London: J. & A. Churchill Ltd., p. 59 (1956). [D30564
——: Histamine release by compounds of simple chemical structure. *Pharmacol. Rev.,* **9,** 269 (1957). [D27354
——: The release of histamine. *Progr. Allergy,* **5,** 79 (1958). [D39576
——, and **Schachter, M.:** The influence of an antihistamine drug on the release of

histamine in the unanaesthetized dog. *Brit. J. Pharmacol.*, **6**, 509 (1951). [D30372
Pautrier, L. M.: Urticaire pigmentaire remarquablement intense, ayant débuté vers la quarantaine, et à type angiomateux. *Bull. Soc. franç. Derm. Syph.*, **49**, 511 (1939). [D39734
——, and **Fernet, P.**: Cas d'urticaire pigmentaire à début tardif. *Bull. Soc. franç. Derm. Syph.*, **20**, 107 (1909). [E24203
——, and **Woringer, F.**: L'anatomie pathologique des chéloïdes. *Ann. Derm. Syph. (Paris)*, **2**, 1145 (1931). [D27883
Pava, S. de la and **Pickren, J. W.**: Mast cells and thrombosis: a correlative study. *N.Y. St. J. Med.*, **62**, 1634 (1962). [E90345
Pavone-Macaluso, M., *cf.* Macaluso, P. M. [D26436; D5225; D26434; D26435; D33720
——: Tissue mast cells in renal diseases. *Acta path. microbiol. scand.*, **50**, 337 (1960). [D26615
Pearce, M. L., and **Valentine, W. N.**: Studies on urinary histamine in chronic myelocytic leukemia. *Proc. Soc. exp. Biol. (N.Y.)*, **75**, 348 (1950). [B53380
Pearse, A. G. E.: The nature of Russell bodies and Kurloff bodies. Observations on the cytochemistry of plasma cells and reticulum cells. *J. clin. Path.*, **2**, 81 (1949). [D30087
Pelagatti, M.: Contributo allo studio dell'orticaria pigmentosa. *G. ital. Mal. vener.* **44**, 534 (1909). [G2957
Pelc, S. R.: Labelling of DNA and cell division in so called non-dividing tissue. *J. Cell Biol.*, **22**, 21 (1964). [D52734
Pellegrini, N. and **Ziliotto, G.**: Sul comportamento delle cellule mastocitarie nella tubercolosi extrapolmonare e nei granulomi lipofagici e colesterinici. *Riv. Anat. pat.*, **14**, 229 (1958). [D65521
Pellerat, J. and **Jeantet, R.**: Urticarie pigmentaire tardive chez un adulte. *Bull. Soc. franç. Derm Syph.*, **59**, 71 (1949). [D39731
Pepler, W. J. and **Meyer, B. J.**: Mast cells in the coronary arteries. *A.M.A. Arch. Path.*, **71**, 209 (1961). [D26748
Perera, B. A. V. and **Mongar, J. L.**: The role of a chymotrypsin-like enzyme in histamine release from rat mast cells. *Immunology*, **6**, 472 (1963). [E27298
——, and ——: The role in anaphylaxis of a chymotrypsin-like enzyme in rat mast cells. *Immunology*, **6**, 478 (1963). [E27299
Perez-Tamayo, R. and **Ihnen, M.**: The effect of methionine in experimental wound healing. A morphologic study. *Amer. J. Path.*, **29**, 233 (1953). [D28955
Pernet, G.: Case of congenital urticaria pigmentosa. *Proc. Roy. Soc. Med.*, **9**, 157 (1916). [D71209
——: A case of congenital urticaria pigmentosa, with remarks on aetiology. *Brit. J. Child. Dis.*, **13**, 301 (1916). [E38153
Pernis, B., Saffiotti, U. and **Degna, A. T.**: Il comportamento delle mastcellule polmonari nel corso della silicosi del ratto. *Med. d. Lavoro*, **49**, 405 (1958). [D39793
Perry, W. L. M., Skin Histamine. In: *Histamine. Ciba Found. Symp.*, London: J. & A. Churchill Ltd., p. 242 (1956). [D30574
Persson, B. H.: The effect of combined estrogen-progesterone treatment on the function and structure of mammary glands in lactating rats. *Acta Soc. Med. upsalien*, **65**, 101 (1960). [D9616
Pescetto, G.: Sulla presenza di elementi granulosi basofili metacromatici nella placenta fetale umana. *Biol. lat. (Milano)*, **2**, 744 (1950). [D27071
Peter, H.: Das histologische Bild des Igel-Thymus im jahreszeitlichen Zyklus. *Ztschr. Anat. Entwickl.-Gesch.*, **104**, 295 (1935). [D29160
Petrásek, R. and **Fábry, P.**: Some effects of diets with a high proportion of fat and cholesterol. *Acta Inst. Nutr. Hum.*, **3**, 82 (1962). [D36095
Pettersson, T.: The effect of X-ray total-body irradiation on the mast cell count in the skin. *Acta path. microbiol. scand.* sup., 102 (1954). [D33702
——: Beobachtungen an Mastzellen bei Vitalfärbung. *Anat. Anzgr.*, **103**, sup., 77 (1956). [D7232
——: Scurvy as a cause of morphological changes in mast cells in the guinea pig. *Acta path. microbiol. scand.*, **45**, 32 (1959). [C67832
——, and **Hjelmman, G.**: The effect of experimental venous thrombosis on the mast cells and fibrocytes in the vascular wall of the rabbit. *Acta med. scand.*, **175**, sup. 412, 265 (1964). [G15429
Pettinari, V.: Il cancro dello stomaco. *Tumori*, **15**, 361 (1929). [D30642
Peyron, A.: Sur certains éléments lymphoconjonctifs du tissu sous-cutané de la souris et leur présence dans l'épithélioma expérimental du goudron. *C.R. Soc. Biol. (Paris)*, **88**, 151 (1923). [D26801
Pezzani, M. and **Verga, V.**: Contributo sperimentale allo studio delle Mastzellen del timo di ratto dopo Roentgen-irradiazione con varie dosi e con diverse modalità. *Riv. Anat. pat.*, **15**, 345 (1959). [C83622

Phillips, J. H., Burch, G. E. and **Hibbs, R. G.**: Tissue mast cells and chromaffin cells in man. *Clin. Res.*, **8**, 48 (1960). [C91246

——, ——, and ——: Significance of tissue chromaffin cells and mast cells in man. *Circulat. Res.*, **8**, 692 (1960). [D26570

——, and **Hibbs, R. G.**: Electron microscopic study of tissue mast cells and chromaffin cells in man. In: *Proc. 52nd Ann. Meet. Amer. Soc. Clin. Invest., Atlantic City, May 1960*. p. 53 (1960). [C84241

Pianigiani, A. and **Fiornovelli, F.**: Rilievi sperimentali di istopatologia della reazione di allarme dopo surrenectomia. *Gazz. int. Med. Chir.*, **63**, 1268 (1958). [C71744

Piccaluga, A.: Azione delle diverse proteine di albume d'uovo sulle Mastzellen. *Arch. De Vecchi Anat. pat.*, **24**, 1103 (1956). [D28533

Piccinelli, O.: Modificazioni indotte dal tetracloruro di carbonio sulle 'Mastzellen' del ratto. *Farmaco, Ed. Sci.*, **11**, 823 (1956). [C28175

Pick, F. J.: Ueber Urticaria perstans. Ein Beitrag zur Pathologie der Urticaria. *Prager Ztschr. Heilk.*, **2**, 417 (1881). [D33733

Piette, C. and **Piette, M.**: Coloration métachromatique et coloration 'acid periodique réactif de Schiff' appliquée aux granulocytes basophiles du sang humain normal. *C.R. Acad. Sci. (Paris)*, **242**, 2775 (1956). [D78336

Piette, M. and **Piette, C.**: Etude critique des méthodes de numération directe des granulocytes basophiles dans le sang humain. Proposition d'une technique. *Ann. Biol. clin.*, **20**, 197 (1962). [E89770

Pindborg, J. J.: *Tandorganets Histologi.* Copenhagen: Langkjaers Bogtrykkeri (1956). [E20183

Pioch, W.: Über die Darstellung saurer Mucopolysaccharide mit dem Kupferphthalocyaninfarbstoff Astrablau. *Virchows Arch. pathol. Anat.*, **330**, 337 (1957). [D33707

Piper, H. G. and **Würbach, G.**: Zur natürlichen Ausscheidung von metachromasiegebenden Substanzen im Urin Hautkranker unter besonderer Berücksichtigung der Urticaria pigmentosa. *Arch. klin. exp. Dermat.*, **218**, 632 (1964). [F10290

Plenk, H.: *Der Magen des Menschen.* Berlin: Springer, 1932. [D39521

Plimpton, N. C.: Basophil leukocytes and myelocytes after local injection of ventriculin. *Anat. Rec.*, **76**, 474 (1940). [D76318

Policard, A. and **Collet, A.**: Recherches par microcinématographie en contraste de phase sur le comportement des mastocytes péritonéaux à l'état vivant. *Bull. Micr. appl.*, **9**, 81 (1959). [D33662

——, ——, **Martin, J. C.**, and **Prégermain, S.**: Sur une disposition périodique inframicroscopique dans les granulations de leucocytes basophiles ganglionnaires. *Nouv. Rev. franc. Hémat.*, **2**, 915 (1962). [D42103

——, ——, and **Prégermain, S.**: Etude au microscope électronique des mastocytes des tissus chez les mammifères. *Rev. Hématol.*, **15**, 374 (1960). [D26749

Pollak, O. J.: Mast cells in the circulatory system of man. *Circulation*, **16**, 1084 (1957). [D26440

Pomerance, A.: Peri-arterial mast cells in coronary atheroma and thrombosis. *J. Path. Bact.*, **76**, 55 (1958). [D33710

Poppel, M. H., Gruber, W. R., Silber, R., Holder, A. K. and **Christman, R. O.**: The roentgen manifestations of urticaria pigmentosa (mastocytosis). *Amer. J. Roentgenol.*, **82**, 239 (1959). [D30192

Post, C. F.: Urticaria pigmentosa. *A.M.A. Arch. Derm.*, **73**, 77 (1956). [D39632

Postnov, Y. V., Anacheko, V. G., and **Ulitina, P. D.**: The effect of disturbances of vascular and connective tissue permeability due to histamine on some indices of physiological anticlotting blood system under experimental conditions. *Ark. Pat.*, No. 5, 31 (1964). [D60610

——, and **Nikolaeva, L. F.**: Lipidosis of the endocardium and coronary arteries in white rats due to influences on connective-tissue mast cells. *Fed. Proc.*, **22**, T1083 (1963). [G1181

Potter, M.: Biologic studies on the development of DON resistance in a mast-cell neoplasm of the mouse. *J. nat. Cancer Inst.*, **23**, 163 (1959). [E90592

Potuzhek, O.; Thumb, N.; Braitenberg, H. and **Braunsteiner, H.**: Quantitative Veränderungen der Blutbasophilen durch Schwangerschaft, Zyklus und Sexualhormone. *Wien. klin. Wchnschr.*, **71**, 595 (1959). [E53262

Prager, M. D. and **Bearden, J.**: Mast cell increase in mouse leukaemia. *Nature (Lond.)* **193**, 180 (1962). [E90981

Prakken, J. R. and **Woerdeman, M. J.**: Mast cells in diseases of the skin; their relation to tissue eosinophilia. *Dermatologica (Basel).* **105**, 116 (1952). [D26813

Pratt, A. C.: Urticaria pigmentosa with sensitiveness to temperature. *A.M.A. Arch. Derm. Syph. (Chic.)*, **52**, 190 (1945). [D39672

Priest, R. J., Rebuck, J. W., and **Havey, G. T.:** A new qualitative defect of leukocyte function in ulcerative colitis. *Gastroenterology,* **38,** 715 (1960). [E43293
Prior, C.: Le Mastzellen nella ipertrofia della prostata. *Riv. Anat. pat.,* **7,** 963 (1953). [D39610
——, and **Sesenna, R.:** Le Mastzellen ed i loro rapporti con i tumori della vescica. *Riv. Anat. pat.,* **7,** 809 (1953-54). [D27080
Proell, F.: Lipoide Substanz und basophile Granula in Plasmazellen. *Ztrbl. allg. Pathol. pathol. Anat.,* **22,** 385 (1911). [D33635
Pröscher, F.: Über experimentelle basophile Leukozytose beim Kaninchen. *Folia haemat.,* **7,** 107 (1909). [D27970
Prosser-Thomas, E. W. and **Rook, A. J.:** Urticaria pigmentosa in an adult. *Brit. J. Derm. Syph.,* **62,** 89 (1950). [D39749
Pruniéras, M.: Contribution à l'étude du mastocyte. *Rev. lyon. Méd.,* **5,** 1 (1956). [E61998
Prus, J.: Eine neue Form der Zellentartung. Secretorische fuchsinophile Degeneration. *Ztrbl. allg. Pathol. pathol. Anat.,* **6,** 705 (1895). [D31542
Pültz, O.: Über eosinophile Zellen und Mastzellen in vesikulösen Hauteffloreszenzen. *Arch. Derm. Syph. (Berlin),* **111,** 19 (1912). [D30085
Pusey, ?.: Urticaria pigmentosa in an adult. *J. cutan. Dis.,* **35,** 48 (1917). [E38141
Pyziol, A.: Zmiany morfologiczne heparynocytów po wstrzyknieciu heparyny u myszek. *Endokr. pol.,* **13,** 159 (1962). [D25216
Quattrin, N.: Therapie der basophilen Leukämien. *Med. Welt. (Stuttg.),* **1963,** 1119 (1963). [E22504
Quensel, U.: Some investigations concerning mast cells. *Acta path. microbiol. scand.,* **5,** 34 (1928). [D39827
——: Studien über die Gewebsmastzellen. *Acta pathol. et microbiol. scand.,* sup. 16, 358 (1933). [D26221
Quevedo, C. C.: Urticaria pigmentosa. *Rev. argent. Dermatosif.,* **27,** 160 (1943). [D39834
——, **Lewis, Y. S.,** and **Smith, D. E.:** On the relationship of mast cells and melanocytes. *J. invest. Derm.,* **30,** 133 (1958). [D27069
Quiroga, M. I. and **Helman, M.** Urticaria pigmentaria. *Rev. argent. Dermatosif.,* **24,** 616 (1940). [D39833
Raab, W.: Die Mastzellen beim experimentellen Dinitrochlorbenzolekzem des Meerschweinchens: ihre Reaktionen nach Verabfolgung von Compound 48/80. *Arch. klin. exp. Dermat.,* **215,** 1 (1962). [D39956
——: Die Mastzellen der Meerschweinchenhaut: ihr Verhalten nach epicutaner Aufbringung von Cantharidin. *Arch. klin. exp. Dermat.,* **216,** 121 (1963). [D64083
——: Ergebnisse der experimentellen Anwendung mastzellerschöpfender Substanzen. *Hautarzt,* **14,** 241 (1963). [D68111
Rabinovich, S., and **Ley, D. C. H.:** Mast cell disease. *Canad. med. Ass. J.,* **89,** 770 (1963). [D66453
Radden, B. G.: A specific stain for mast cell granules. *Nature (Lond.),* **186,** 400 (1960). [D26768
——: An investigation of the factors influencing the metachromatic staining of mast cell granules. *J. Histochem. Cytochem.,* **9,** 165 (1961). [D63164
——: Cytochemical variations in the granules of rat mast cells, and their relation to mast cell maturation. *Austral. J. exp. Biol.,* **40,** 9 (1962). [D33222
Ranvier, L.: Des clasmatocytes. *C.R. Acad. Sci. (Paris),* **110,** 165 (1890). [D31575
——: Transformation in vitro des cellules lymphatiques en clasmatocytes. *C.R. Acad. Sci. (Paris),* **112,** 688 (1891). [D31524
——: Des clasmatocytes. *Arch. Anat. micr. Morph. exp.,* **3,** 123 (1900). [D31525
Räsänen, T.: Tissue eosinophils and mast cells in the human stomach wall in normal and pathological conditions. *Acta path. microbiol. scand.,* sup. 129 (1958). [D27066
——: Mucosal mast cells of rat stomach; influence of ACTH, cortisone and growth hormone. *Gastroenterology,* **38,** 70 (1960). [C81536
——: Quantitative effect of some steroid hormones on the mucosal mast cells and tissue eosinophils in the rat stomach wall. *Acta endocr. (Kbh.),* **37,** 153 (1961). [D3451
——: The role of the adrenals on the mucosal mast cells and tissue eosinophils in the gastric wall of rat. *Acta physiol. scand.,* **52,** 162 (1961). [D33725
——: Effect of prednisolone and deoxycorticosterone, administered separately and with growth hormone, on the mucosal mast cells and tissue eosinophils of rat stomach wall. *Gastroenterology,* **40,** 232 (1961). [D6149
——: The function of the mast cells in the mucous membrane of the stomach. (Finnish text) *Duodecim (Helsinki),* **77,** 440 (1961). [E94505

——: Mucosal mast cells and tissue eosinophils in rat stomach wall after aldosterone and after simultaneous deoxycorticosterone and prednisolone application. *Ann. Med. exp. Fenn.*, **40**, 162 (1962). [E92220
——: Effects of dexamethasone, prednisolone and cortisol on the mast cells and tissue eosinophils in rat gastric mucosa. *Acta endocr. (Kbh.)*, **41**, 432 (1962). [D33739
——: Effects of heparin and asbestos with corticotrophin on the mucosal mast cells and tissue eosinophils of rat stomach. *Acta endocr. (Kbh.)*, **41**, 437 (1962). [D33740
——: A mucosal bleeding mechanism in the upper part of the gastrointestinal tract. *Gastroenterology*, **44**, 168 (1963). [D39969
——: Fluctuations in the mitotic frequency of the glandular stomach and intestine of rat under the influence of ACTH, glucocorticoids, stress and heparin. *Acta physiol. scand.*, **58**, 201 (1963). [E22623
——: Effect of histamine and insulin on eosinophils and mast cells in the rat gastric mucosa. *Acta physiol. scand.*, **61**, 205 (1964). [G19874
——, and **Siurala, M.**: Effect of ACTH upon tissue eosinophils and mast cells in the mucosa of the aboral parts of the human intestine. *Ann. Med. inter. Fenn.*, **49**, 33 (1960). [D26630
Rasch, C.: Urticaria pigmentosa. *Hospitalstidende*, **5**, 1569 (1912). [G1237
Rask-Nielsen, R. and **Christensen, H. E.**: Studies on a transplantable mastocytoma in mice. I. Origin and general morphology. *J. nat. Cancer. Inst.*, **30**, 743 (1963). [D64074
Raudnitz, R. W.: Beitrag zur Kenntniss der im Bindegewebe vorkommenden Zellen. *Arch. mikros. Anat.*, **22**, 228 (1883). [D28536
Rawlins, A. G.: The corticosteroids in otolaryngology. *Ann. Otol. (St. Louis)*, **65**, 318 (1956). [C22570
Rebuck, J. W., Hodson, J. M., Priest, R. J. and **Barth, C. L.**: Basophilic granulocytes in inflammatory tissues of man. *Ann. N.Y. Acad. Sci.*, **103**, 409 (1963). [D58294
Recklinghausen, F. von: Ueber Eiter- und Bindegewebskörperchen. *Virchows Arch. path. Anat.*, **28**, 157 (1863). [D29297
Redei, A., David, M. and **Karady, S.**: Investigations on the mechanism of adaptation to shock induced by distilled water. *Exp. Cell Res.*, **15**, 154 (1958). [D65502
Regaud, C. and **Crémieu, R.**: Données relatives aux petites cellules ou lymphocytes du parenchyme thymique, d'après les résultats de la röntgénisation du thymus, chez le chat. *C.R. Soc. biol. (Paris)*, **72**, 253 (1912). [D26829
——, and ——: Sur la formation temporaire de tissu myéloïde dans le thymus pendant l'involution de cet organe, consécutive à l'action des rayons X. *C.R. Soc. biol. (Paris)*, **64**, 960 (1913). [D27341
——, and **Lacassagne, A.**: A propos des mastocytes des épithéliomas. Importance de la fixation pour la coloration des granulations des mastocytes. *C.R. Soc. biol. (Paris)*, **87**, 1084 (1922). [D26872
Reilly, E. B., Shintani, J., and **Goodman, J. R.**: Systemic mast-cell disease with urticaria pigmentosa. *A.M.A. Arch. Derm. Syph. (Chic.)* **71**, 561 (1955). [D10435
Remy, D.: Die Mastocytose. *Dtsch. med. Wchnschr.*, **82**, 719 (1957). [D31528
——: Das klinische Bild der Mastocytose (Mastzellenreticulose). *Verhandl. Dtsch. Gesellsch. inn. Med.*, **65**, 188 (1959). [D39664
——: Die Klinik der Mastzellenretikulose. *Proc. 8th Congr. Europ. Soc. Haematol. Vienna*, **1**, 88 (1961). [D46809
——: Gewebsmastzellen und Mastzellen-Reticulose. (Funktionelle Zytologie und Klinik). *Ergebn. inn. Med. Kinderheilk.*, **17**, 132 (1962). [D32662
Renn, P.: Zur Funktionsfrage der Gaumenmandel. Cytodiagnostische und histopathologische Untersuchungen. *Beitr. pathol. Anat.*, **53**, 1 (1912). [D28933
Reynolds, B. L., Levesque, T. F. and **Buxton, R. W.**: Metabolic parameters in the healing of open skin wounds in animals. *Amer. Surg.*, **29**, 325 (1963). [D64852
Rheindorf, A.: Naevus pigmentosus. Beziehungen desselben zu Sommersprossen und Chromatophoromen. *Thesis, University of Berlin* (1905). [D33731
Rheingold, J. J., and **Wislocki, G. B.**: Histochemical methods applied to hematology. *Blood*, **3**, 641 (1948). [D39650
Rhodin, J., Adams-Ray, J. and **Nordenstam, H.** Electron miscroscopy of human skin cells containing chromaffin granules. *Ztschr. Zellforschg.*, **49**, 275 (1959). [D39527
Ricci, M. and **Lombardi, V.**: I leucociti basofili nelle sindromi asmatiche bronchiali. *Minerva med.*, **52**, 4552 (1961). [E40138
——, ——, **Passaleva, A.**, and **Toscani, A.**: Dinamica dei leucociti basofili, eosinofili e totali e variazioni emocoagulative e fibrinolitiche in corso di accesso asmatico provocato inalazioni di allergeni esogeni. Ricerche condotte in parallelo con lo studio dell'azione

farmacodinamica dell'eparina sui leucociti basofili. *Settim. med.*, **49**, 886 (1961). [D9605

——, ——, **Toscani, A.**, and **Passaleva, A.**: Interferenze e correlazioni tra leucociti basofili ed eosinofili e metabolismo glicidico e lipidico. *Minerva med.*, **54**, 353 (1963). [D66411

Rice, L. I., Spolter, L., Tökes, Z., and **Marx, W.**: Ultracentrifugal separation of subcellular mastocytoma fractions involved in sulfate incorporation into heparin. *Fed. Proc.*, **23**/1, 484 (1964). [F5316

Rice, W. G. and **Mitchener, J.**: Histochemical evidence of 5-hydroxytryptamine in a dog mast cell tumour. *Nature (Lond.)*, **189**, 767 (1961). [D2299

Rider, T. L., Stein, A. A. and **Abbuhl, J. W.**: Generalized mast cell disease and urticaria pigmentosa. Report of a case. *Pediatrics*, **19**, 1023 (1957). [E35352

Riehl, R.: Über einen Fall von Urticaria pigmentosa bei einem hereditär-luetischen Kinde. *Wien. med. Wchnschr.*, **63**, 2565 (1913). [D72670

Riley, J. F.: Histamine in tissue mast cells. *Science*, **118**, 332 (1953). [B86264

——: The relationship of the tissue mast cells to the blood vessels in the rat. *J. Path. Bact.*, **65**, 461 (1953). [B90275

——: The effects of histamine-liberators on the mast cells of the rat. *J. Path. Bact.*, **65**, 471 (1953). [B90276

——: The riddle of the mast cells. A tribute to Paul Ehrlich. *Lancet*, **1**, 841 (1954). [B92944

——: Heparin, histamine and mast cells. *Blood*, **9**, 1123 (1954). [C53

——: Pharmacology and functions of the mast cells. *Pharmacol. Rev.*, **7**, 267 (1955). [C9303

——: Histamine and mast cells. In: *Histamine. Ciba Found. Symp.*, London: J. & A. Churchill Ltd., p. 45 (1956). [D30562

——: The location of histamine in the body. In: *Histamine. Ciba Found. Symp.*, London: J. & A. Churchill Ltd., p. 398 (1956). [D30582

——: Fluorescent mast cells in precancerous mouse-skin. *Experientia (Basel)*, **14**, 141 (1958). [C69692

——: The mechanism of histamine release from mast cells. *J. Pharm. Pharmacol.*, **10**, 271 (1958). [D27438

——: *The Mast Cells.* Edinburgh & London: E. & D. Livingstone Ltd., 1959. [C70315

——: Tissue mast cells: distribution and significance. *Canad. J. Biochem.*, **39**, 633 (1961). [D2369

——: Histamine and heparin in mast cells. Why both. *Lancet*, **2**, 40 (1962). [D26692

——: The mast cells. *Physiol. Physicians*, **1**, No 4, 1 (1963). [D61078

——: Functional significance of histamine and heparin in tissue mast cells. *Ann. N.Y. Acad. Sci.*, **103**, 151 (1963). [D58277

——: Mast-cells and anaphylaxis. *Lancet*, May 23, 1155 (1964). [F9669

——, and **Drennan, J. M.**: The presence and significance of alkaline phosphatase in the cytoplasm of mast cells. *J. Path. Bact.*, **61**, 245 (1949). [D26775

——, **Shepherd, D. M., West, G. B.**, and **Stroud, S. W.**: Function of heparin. *Nature (Lond.)*, **176**, 1123 (1955). [D27737

——, and **West, G. B.**: Histamine in tissue mast cells. *J. Physiol. (Lond.)*, **117**, 72P (1952). [D39656

——, and ——: Mast cells and histamine in normal and pathological tissues. *J. Physiol. (Lond.)*, **19**, 44P (1953). [D39662

——, and ——: The presence of histamine in tissue mast cells. *J. Physiol. (Lond.)*, **120**, 528 (1953). [B96668

——, and ——: Tissue mast cells. Studies with a histamine-liberator of low toxicity (compound 48/80). *J. Path. Bact.*, **69**, 269 (1955). [C14427

——, and ——: Histamine-liberation in the rat and mouse. *Arch. int. Pharmacodyn.*, **102**, 304 (1955). [D39574

——, and ——: A binding site for histamine in hog pyloric mucosa. *Experientia (Basel)*, **12**, 153 (1956). [D27968

——, and ——: Skin histamine. Its location in the tissue mast cells. *A.M.A. Arch. Derm.*, **74**, 471 (1956). [C29554

Rinehart, J. F. and **Abul-Haj, S. K.**: An improved method for histologic demonstration of acid mucopolysaccharides in tissues. *A.M.A. Archives of Pathology*, **52**, 189 (1951). [D33696

——, and **Greenberg, L. D.**: Pathogenesis of experimental arteriosclerosis in pyridoxine deficiency. With notes on similarities to human arteriosclerosis. *A.M.A. Arch. Path.*, **51**, 12 (1951). [D29295

Ringertz, N. R.: Acid polysaccharides of mast cell tumours. *Thesis, Univ. of Stockholm* (1960). [E22676

——: Biological sulphation of mast cell tumour polysaccharides. In vitro experiments with transplantable mouse tumours. *Arkiv Kemi*, **16**, 67 (1960). [D67467

——: Acid polysaccharides of two mast cell tumors in mice. *Acta chem. scand.*, **14**, 312 (1960). [D63189

——: Polysaccharides of neoplastic mast cells. *Ann. N.Y. Acad. Sci.,* **103,** 209 (1963). [D58282

——, and **Bloom, G.:** Acid polysaccharides of two dog mastocytomas. *Arkiv Kemi,* **16,** 57 (1961). [D39806

Ringoen, A. R.: Observations on the origin of the mast leucocytes of the adult rabbit. *Anat. Rec.,* **9,** 233 (1915). [D27738

——: The mast leucocytes in the adult guinea pig under experimental conditions. *Amer. J. Anat.,* **31,** 319 (1923). [D27892

Rivela, ?.: Sul reperto di 'Mastzellen' nel bulbo olfattorio normale. *Boll. Accad. med. Pugliese,* **?,** ? (1928). [G10729

Robbins, J. G.: Bullous urticaria pigmentosa. Report of an unusual case. *A.M.A. Arch. Derm. Syph.,* **70,** 232 (1954). [D26739

Roca de Vinãls, R., *cf.* Vinãls, R. R. de. [D13202, D30196

Rodén, L., and **Dorfman, A.:** The acid mucopolysaccharides of Furth's mastocytoma in the mouse. *Acta chem. scand.,* **13,** 2121 (1959). [D65652

Rogers, G. E.: Electron microscopy of mast cells in the skin of young mice. *Exp. Cell Res.,* **11,** 393 (1956). [D27741

Rohr, K.: Reaktive Retikulosen des Knochemarkes. *Acta haemat. (Basel),* **7,** 321 (1952). [D27402

Rollier, R.: Mastocytose cutanée diffuse. *Bull. Soc., franç. Derm. Syph.,* **67,** 881 (1960). [D33730

Romani, J. D.: L'influence de la cortisone sur les mastocytes du tissu conjonctif et de quelques organes chez le rat. *C.R. Soc. Biol. (Paris),* **147,** 391 (1953). [B90840

——: Action des glycocorticoïdes sur les mastocytes dans le tissu conjonctif du granuloma expérimental chez le rat. *C.R. Soc. Biol. (Paris),* **147,** 1771 (1953). [C672

Romanini, M. G.: Contributions à l'étude histochimique des mucopolysaccharides. I. Gelée de Wharton et substance métachromatique des vaisseaux. *Acta anat. (Basel),* **13,** 256 (1951). [D33671

Romhányi, G.: Über die submikroskopische strukturelle Grundlage der metachromatischen Reaktion. *Acta histochem. (Jena),* **15,** 201 (1963). [E25972

Romieu, M.: Contribution à l'étude des mastocytes des poissons osseux. *C.R. Soc. Biol. (Paris),* **91,** 655 (1924). [D27443

Rondanelli, E. G.: Biochemistry of specific granules in mastleucoblasts, mastleucocytes and mastcells in normal and pathological conditions. A cytochemical evaluation. *Rev. belge Path.,* **24,** 329 (1955). [D26656

——, **Fiori, G. P.,** and **Giordano, M.:** Comportamento citochimico dei granuli specifici dei mastgranuloblasti e mastleucociti di nuovo caso di leucocemia basofila. *Acta histochem. (Jena),* **13,** 16 (1962). [D33212

Rondez, R., and **Rüttner, J. R.:** Mastzellenreaktion im Mesenterium der Maus nach Einwirkung von Quarz- und Korund-Staub. Mast-cell reaction to quartz- and corundum-dust in the mesentery of the mouse. *Naturwschft.,* **18,** 534 (1959). [D27391

——, ——, and **Anders, G.:** Mastzellreaktion nach Einwirkung von Quarz in isotoner und nicht isotoner Suspension im Intraperitonealversuch bei der Maus. *Med. exp. (Basel),* **1,** 33 (1959). [D26891

Rorsman, H.: Basophil leucocytes and urticaria. *Acta derm.-venereol. (Stockh.),* **37,** 121 (1957). [D96270

——: Basophil leucocytes in asthma, atopic dermatitis and psoriasis. *Acta derm.-venereol. (Stockh.),* **38,** 175 (1958). [E40272

——: Basophil leucocytes in urticaria, asthma and atopic dermatits. *Acta allerg. (Kbh.),* **12,** 205 (1958). [E41623

——: Basophils and other leucocytes in allergic reactions in rabbits. *Acta allerg. (Kbh.),* **16,** 302 (1961). [D39534

——: Basophils and other leucocytes in allergic reactions in guinea-pigs. *Acta allerg. (Kbh.),* **17,** 36 (1962). [D39535

——: Studies on basophil leucocytes with special reference to urticaria and anaphylaxis. *Acta derm.-venereol. (Stockh.),* **42,** sup. 48 (1962). [D32191

——: Normal variation in the count of circulating basophil leucocytes in man. *Acta allerg. (Kbh.),* **17,** 49 (1962). [E41991

——: Basophilic leucopemia in different forms of urticaria. *Acta allerg. (Kbh.),* **17,** 168 (1962). [D39084

——, and **Rosengren, E.:** Basophil leucocytes and blood histamine in urticaria. *Acta derm.-venereol. (Stockh.),* **38,** 377 (1958). [E88078

Rosate, A.: I mastociti (Mastzellen) dello strato sinoviale nelle diartrosi normali e sperimentalmente immobilizzate. *Biol. lat. (Milano),* **12,** 451 (1959). [D99736

Rosenbaum, R. M., and **Deane, H. W.:** Effects of temperature on the binding of acid and basic dyes, including reference to metachromasy. *Ztschr. Zellforschg., Abt. Histochem.,* **1,** 213 (1959). [D27959

Rosenheim, T.: Ueber das Vorkommen und die Bedeutung der Mastzellen im Ner-

vensystem des Menschen. *Arch. Psychiat. Nervenkrht.*, **17**, 820 (1886). [D26865
Rostenberg, ?.: Urticaria pigmentosa. *A.M.A. Arch. Derm. Syph. (Chic.)*, **5**, 400 (1922). [E38165
Roth, E., Noltenius, H., and **Oehlert, W.**: Autoradiographische Untersuchungen zur DNS-Neubildung und zum Sulfateinbau in Gewebsmastzellen. *Frankfurt. Ztschr. Pathol.*, **73**, 40 (1963). [E34000
Roth, J. S.: Inhibitors and activators for ribonuclease and desoxyribonuclease. *Fed. Proc.*, **11**, 277 (1952). [D30553
Rothschild, A. M., and **Schayer, R. W.**: Characterization of histidine decarboxylase from rat peritoneal fluid mast cells. *Biochim. biophys. Acta (Amst.)*, **34**, 392 (1959). [C76258
Rott, ?.: Urticaria pigmentosa. *Berl. klin. Wchnschr.*, **48**, 86 (1911). [E37999
Rowley, D. A.: Mast cell damage and vascular injury in the rat: an electron microscopic study of a reaction produced by thorotrast. *Brit. J. exp. Path.*, **44**, 284 (1963). [D69169
——, and **Benditt, E. P.**: 5-Hydroxytryptamine and histamine as mediators of the vascular injury produced by agents which damage mast cells in rats. *J. exp. Med.*, **103**, 399 (1956). [C15372
Rubarth, S.: Något om 'Mastzellen'-tumörer och liknande bildningar hos hund. *Nord. Med.*, **41**, 826 (1949). [D50784
Rubinato, J.: Sur la valeur des recherches hématologiques dans le diagnostic des cirrhoses hépatiques et sur l'importance de l'augmentation des mastzellen. *Folia haemat.*, **4**, sup. 198 (1907). [D28463
Rukavina, J. G., Dickison, G., and **Curtis, A. C.**: The simultaneous occurrence of urticaria pigmentosa and primary systemic amyloidosis: report of a case with autopsy findings. *J. invest. Derm.*, **28**, 243 (1957). [E36437
Rupe, C. E.: Mast cells in non-neoplastic diseases of man and their relationship to the basophilic leucocyte. *Ann. N.Y. Acad. Sci.*, **103**, 436 (1963). [D58296
Ryzhikh, G. N.: About the origin of mast cells. (Russian text) *Dokl. Akad. Nauk. USSR*, **84**, 591 (1952). [D39895
Saal, J. R., and **Riek, R. F.**: Studies on bovine mast cells: I. The effect of formalin fixation. *Stain Technol.*, **33**, 123 (1958). [D31598
Sabin, F. R.: Studies of living human blood cells. *Bull. Johns Hopk. Hosp.*, **34**, 277 (1923). [G16025
Sabrazès, J.: Granulobasocytes (Mastzellen) des sérosités pleurale et péritonéale. *Gaz. hebd. Sci. méd. Bordeaux*, **43**, 73 (1922). [D65653
——: Taux élevés des mastzellen après radiothérapie efficace des leucémies myéloides. Eosinophilie postradiothérapique des leucémies lymphogènes. *Bull. Acad. Med. (Paris)*, **93**, 748 (1925). [G16740
——: Présence d'hémohistioblastes se différenciant en Mastzellen dans un cas de myéloleucémie chronique (Radiorésistance des hémohistioblastes). *Arch. Mal. Coeur*, **19**, 38 (1926). [D30601
——: Leucémie à mastzellen et à cellules de Ferrata radiorésistantes. Poussée aigüe terminale. *Arch. Mal. Coeur*, **19**, 453 (1926). [D27634
——, and **Husnot, P.**: Eléments cellulaires du tissu interstitiel des glandes surrénales. *Folia haemat.*, **4**, 799 (1907). [D27425
——, and ——: Tissu interstitiel des surrénales. Mastzellen et macrophages. *C.R. Soc. Biol. (Paris)*, **62**, 1079 (1907). [D27507
——, and ——: Mastzellen dans les surrénales des animaux. *C.R. Soc. Biol. (Paris)*, **62**, 1081 (1907). [D27508
——, and **Lafon, C.**: Granulome de la lèvre à mastzellen et à éosinophiles chez un cheval. *Folia haemat. (Lpzg.)*, **6**, 3 (1908). [D27301
——, **Murated, L.,** and **Antoine, H.**: Infiltration massive de mastzellen agglomérées en nodules dans la rate d'un chat porteur d'un épithélioma mélanique de la paupière. *C.R. Soc. Biol. (Paris)*, **64**, 292 (1908). [D27505
Sacerdote, M.: Modificazioni cicliche delle mastzellen nella ghiandola pelvica di Triturus cristatus carnifex ♂ (Laur.). *Boll. Soc. ital. Biol. sper.*, **38**, 920 (1962). [D33407
——, and **Pennisi, F.**: Primi dati sulla distribuzione di S^{35} nelle Mastzellen di Triturus cristatus carnifex (Laur.). *Boll. Soc. ital. Biol. sper.*, **40**, 205 (1964). [G12876
Saeki, S.: The appearance of the basophil leucocyte in early embryonic life. *Acta haemat. jap.*, **15**, 1 (1952). [D78337
Sagher, F.: Mast cell disorders. The changing aspect of urticaria pigmentosa from a pure cutaneous to a systemic disease. *Excerpta med. (Amst.)*, Sect. XIII, **10**, 311 (1956). [D27978
——, **Cohen, C.,** and **Schorr, S.**: Concomitant bone changes in urticaria pigmentosa. *J. invest. Derm.*, **18**, 425 (1952). [D10437
——, and **Even-Paz, Z.**: The mast cells and mastocytosis. With special reference to

bone changes. *S. Afr. med. J.,* **35,** 470 (1961). [D9772

——, **Liban, E., Ungar, H.,** and **Schorr, S.:** Urticaria pigmentosa with bone involvement: Mast cell aggregates in bones and myelosclerosis found at autopsy in a case dying of monocytic leukemia. *J. invest. Derm.,* **27,** 355 (1956). [D33675

——, and **Schorr, S.:** Bone lesions in urticaria pigmentosa. *J. invest. Derm.,* **26,** 431 (1956). [D28279

Saito, A.: On the essential nature of the hematopoietic function of bone marrow. Report 8. Functional observation on monocytes, endothel cells, eosinophils, basophils and plasma cells from the standpoint of the hematopoietic phases of the bone marrow and the blood reaction fields. *Tohoku J. exp. Med.,* **77,** 42 (1962). [D31873

Salvato, G.: Mast cells in bronchial connective tissue of man. Importance of such cells in allergic tissue injury. *Experientia (Basel),* **15,** 308 (1959). [C73693

——: Mast cells in bronchial connective tissue of man: Their modifications in asthma and after treatment with the histamine liberator 48/80. *Internat. Arch. Allergy Appl. Immunol.,* **18,** 348 (1961). [D10341

——: Asthma and mast cells of bronchial connective tissue. *Experientia (Basel),* **18,** 330 (1962). [D27641

——: Ineffectiveness of antihistamines to inhibit mast cells damage by compound 48/80 in man. *Acta allerg. (Kbh.),* **18,** 529 (1963). [G12997

Sandler, A. I. and **Putschar, W. G. J.:** Urticaria pigmentosa, with systemic mast-cell disease. *New Engl. J. Med.,* **271,** 570 (1964). [G19842

Sangster, A.: An anomalous mottled rash, accompanied by pruritus, factitious urticaria and pigmentation, "Urticaria pigmentosa?" *Trans. clin. Soc. Lond.,* **11,** 161 (1878). [D39840

Sannazzari, G. L.: Il comportamento delle mastzellen nel connetivo sotto-epidermico del ratto albino in seguito ad irradiazioni roentgen. *Radiol. med. (Torino),* **42,** 701 (1956). [D68633

——, and **Visioli, O.:** Contributo alla conoscenza dell'origine e delle funzione delle cellule a granulazioni basofili. *Riv. Anat. pat.,* **6,** 1129 (1953). [D66745

Sansonow, N. M.: Wanderelemente der Darmschleimhaut bei Säugetieren. *Thesis, Kaiserl. mil. med. Acad., St. Petersburg,* (1908). [D27433

Santamaria, L.: Sul comportamento delle Mastzellen trattate con enzimi mucinolitici e con soluzioni a diverso pH. *Boll. Soc. ital. Biol. sper.,* **24,** 452 (1948). [D39715

Santini, F.: Le Mastzellen nella tiroide di ratto e le loro modificazioni in rapporto ai vari stati funzionali della ghiandola. *Arch. ital. Anat. Embriol.,* **67,** 443 (1962). [D64084

Sanyal, R. K.: Mast cell response in aseptic inflammation. *J. Pharm. Pharmacol.,* **11,** 447 (1959). [C80812

——: Histamine and 5-hydroxytryptamine metabolism after superficial skin burns. *Int. Arch. Allergy,* **21,** 326 (1962). [D54916

Sarzi-Sartori, P.: Emoistoblasti a granulazioni basofile in un caso di leucemia basogranulocitica (Mastzellenleucemia). *G. Clin. med.,* **8,** 784 (1927). [G18740

Saunders, A. M.: Histochemical identification of acid mucopolysaccarides with acridine orange. *J. Histochem. & Cytochem.,* **12,** 164 (1964). [G19424

Savill, T. D.: On certain skin diseases. Urticaria pigmentosa (sometimes called Sangster's disease). *Hospital (Lond.),* **43,** 521 (1908). [D34031

Scevola, P.: Sull'origine e sulla distribuzione degli elementi basofili granulosi del connettivo (Mastzellen) nell'anello del Waldeyer in alcuni mammiferi. *Arch. ital. Otol.,* **49,** 285 (1937). [D39779

——: Le Mastzellen come sistema difensivo locale e generale nelle ustioni del territorio palatofaringeo di mammiferi. *Arch. ital. Otol.,* **50,** 169 (1938). [D27705

——: Osservazioni sopra le Mastzellen nei processi infiammatori acuti e cronici della tonsilla. *Arch. ital. Otol.,* **50,** 314 (1938). [D27701

Schäfer, E.: Über Urticaria pigmentosa und das Mastzellenproblem. *Acta derm.-venereol. (Stockh.),* **8,** 161 (1927–28). [D26711

Schaffer, J.: Präparate von lockerem Subkutangewebe. *Ztrbl. Physiol.,* **21,** 258 (1907). [D30589

——: *Lehrbuch der Histologie. Leipzig, 1922.* [A54121

Schallock, G.: Neuere Untersuchungen über kollagenes und lymphoretikuläres Gewebe in der Haut. *Arch. Derm. Syph. (Berlin),* **198,** 567 (1954). [D39666

Schauer, A.: Zur Entwicklung der Mastzellgranula. *Naturwschft.,* **49,** 382 (1962). [D30586

——: Histochemische Enzymuntersuchungen an transplantablen Mäusemastzelltumoren. *Beitr. pathol. Anat.,* **127,** 395 (1962). [D39984

——: Untersuchungen zur Charakterisierung der Mastzellamino-peptidase. *Naturwschft.*, **50**, 550 (1963). [D62962
——: Die Histo- und Biochemie der akuten Entzündung. *Münch. med. Wchnschr.*, **106**, 799 (1964). [F10764
——: Die Mastzelle. *Stuttgart: Gustav Fischer Verlag, 1964.* [E4510
——, and **Eder, M.**: Nachweis und Bedeutung der Bindung von Histamin an Adenosin-5'-Triphosphorsäure und andere Phosphatverbindungen. *Klin. Wchnschr.*, **39**, 76 (1961). [D764
——, and ——: Die Entwicklung von Mucopolysacchariden und Bildung histochemisch nachweisbarer Enzyme während der Mastzellreifung. *Virchows Arch. pathol. Anat.*, **335**, 72 (1962). [D30202
——, and **Werle, E.**: Zur histochemischen Darstellung des Histamins der Mastzellen. *Ztschr. gesamt. exp. Med.*, **131**, 100 (1959). [D31603
Schayer, R. W.: Formation and binding of histamine by free mast cells of rat peritoneal fluid. *Amer. J. Physiol.*, **186**, 199 (1956). [D27727
——: Histidine decarboxylase in mast cells. *Ann. N.Y. Acad. Sci.*, **103**, 164 (1963). [D58278
——: Histamine and hyperaemia of muscular exercise. *Nature (Lond.)*, **201**, 195 (1964). [E37862
——, and **Kobayashi, Y.**: Histidine decarboxylase and histamine binding in rabbit platelets. *Proc. Soc. exp. Biol. (N.Y.)*, **92**, 653 (1956). [D30376
Schiebler, T. H.: Metachromasie Fixierung und Artefaktbildung. 5th Symp. Histochemie, Kiel 1957. *Acta histochem. (Jena)*, sup. 1, p. 270 (1958). [G18947
Schiff, M., and **Burn, H. F.**: The effect of intravenous estrogens on ground substance. *A.M.A. Arch. Otolaryng.*, **73**, 43, (1961). [D3030
——, and ——: The effect of estrogens on mast cells and enzymes in connective tissue metabolism in humans. *Laryngoscope (St. Louis)*, **71**, 765 (1961). [D28988
Schiller, S.: Mucopolysaccharides of normal mast cells. *Ann. N.Y. Acad. Sci.*, **103**, 199 (1963). [D58281
——, and **Dorfman, A.**: The isolation of heparin from mast cells of the normal rat. *Biochem. biophys. Acta (Amst.)*, **31**, 278 (1959). [D63194
Schindler, R.: The conversion of 14C-labelled tryptophan to 5-hydroxytryptamine by neoplastic mast cells. *Biochem. Pharmacol.*, **1**, 323 (1958). [C71500
——, **Day, M.**, and **Fischer, G. A.**: Culture of neoplastic mast cells and their synthesis of 5-hydroxytryptamine and histamine in vitro. *Cancer Res.*, **19**, 47 (1959). [C68305
Schlecht, H.: Über die Einwirkung von Seruminjektionen auf die Eosinophilen und Mastzellen des menschlichen und tierischen Blutes. *Dtsch. Arch. klin. Med.*, **98**, 308 (1910). [D28465
Schlich, G., and **Piccaluga, S.**: Le mastzellen nelle nefrosclerosi vascolari ed infiammatorie. *Arch. ital. Anat. Istol. Pat.*, **30**, 197 (1956). [D65256
Schmauch, G.: Über endoglobuläre Körperchen in den Erythrocyten der Katze. *Virchows Arch. pathol. Anat.*, **157**, 201 (1899). [D76213
Schoch, E. P., and **Glick, D.**: The effect of cold stress, ACTH, cortisone, pyrogen and nitrogen mustard on tissue mast cells in the skin and subcutaneous tissues of the rat. *J. invest. Derm.*, **20**, 119 (1953). [D26848
Schöll, H., Bennhold, I., and **Diezel, P. B.**: Über die verschiedenen Arten von Farbänderungen bei Azofarbstoffen. *Ztschr. Zellforschg. mikros. Anat. Abt. Histochem.*, **1**, 315 (1959). [D27961
Schoenberg, M. D., and **Moore, R. D.**: Studies on connective tissue. III. Enzymatic studies on the formation and nature of the carbohydrate intermediate of the connective tissue polysaccharides in the human umbilical cord. *A.M.A. Arch. Path.*, **65**, 115 (1958). [D27894
Schönherr, D., and **Hermann, F.**: Basophylendegranulation bei anaphylaktoiden Reaktionen, insbesondere erworbener Kälteurticaria. *Arch. klin. exp. Derm.*, **220**, 362 (1964). [F22262
Schorr, S., Loewenthal, M., Berlin, C., Rabinowitz, M., and **Efrati, P.**: Mastocytosis: urticaria pigmentosa, myelofibrosclerosis and occlusive panarteritis. *Clin. Radiol.*, **15**, 84 (1964). [G1315
——, **Sagher, F.**, and **Liban, E.**: Generalized osteosclerosis in urticaria pigmentosa. The radiologic aspect. *Acta radiol. (Stockh.)*, **46**, 575 (1956). [D63795
Schreiber, L.: Über ein bequemes Objekt zum Studium der Mastzellen (Clasmatocyten). *Münch. med. Wchnschr.*, **49**, 2075 (1902). [D33633
——: Bemerkungen zu A. Maximows Aufsatz. 'Ueber Klasmatocyten und Mastzellen.' *Ztrbl. allg. Pathol. pathol. Anat.*, **14**, 913 (1903). [D27643
——, and **Neumann, E.**: Clasmatocyten, Mastzellen und primäre Wanderzellen. In:

Chemische und Medicinische Untersuchungen. Festschrift 60. Geburtstag M. Jaffe. Braunschweig: F. Vieweg u. Sohn, p. 125 (1901). [D28537

——, and ——: Die Bedeutung der sogenannten 'Clasmatocyten' Ranvier's. *Ztrbl. allg. Pathol. pathol. Anat.,* **12,** 593 (1901). [D27639

Schreus, H. T.: Über einen Mastzellen-Tumor bei der weissen Maus nach Teerpinselung. *Derm. Ztschr.,* **40,** 9 (1923). [D39778

Schridde, H.: Beiträge zur Lehre von den Zellkörnelungen. Die Körnelungen der Plasmazellen. *Anat. Hefte,* **28,** 693 (1905). [D31610

Schuberg, A.: Untersuchungen über Zellverbindungen. *Ztschr. Wisschftl. Zool.,* **74,** 155 (1903). [D39531

Schubert, J. C. F.: Differenzierungsmethode metachromatischer Zellen nach ihrem Säuregrad. *Experientia (Basel),* **12,** 346 (1956). [D31611

Schubert, M., and **Hamerman, D.:** Metachromasia; chemical theory and histochemical use. *J. Histochem. Cytochem.,* **4,** 159 (1956). [D28653

Schuh, M.: Über Blut- und Sekret-Untersuchungen auf eosinophile Zellen und basophile Leukozyten (Mastzellen) bei Gonorrhoikern. *Arch. Dermat. Syph. (Berlin),* **109,** 101 (1911). [D27589

Schultz, A.: Über die Chromotropie des Gefässbindegewebes in ihrer physiologischen und pathologischen Bedeutung, insbesondere ihre Beziehungen zur Arteriosklerose. *Virchows Arch. pathol. Anat.,* **239,** 415 (1922). [D29296

Schultz, H. J., Code, C. F., and **Brunsting, A.:** Blood histamine and basophil-eosinophil counts in skin diseases. *A.M.A. Arch. Derm.,* **80,** 44 (1959). [G11135

Schürer, W.: Speicherung von Heparin in den Zellen des Reticuloendothels. *Helv. med. Acta,* **13,** 161 (1946). [D40720

Schuster, C.: Gewebsmastzellen und Blutbasophile bei Urticaria pigmentosa und myeloischer Leukose. *Ztschr. gesamt. inn. Med.,* **16,** 245 (1961). [D26851

Schwartz, ?.: Case of urticaria pigmentosa. *J. cutan. Dis.,* **27,** 206 (1909). [E38146

Schwarz, E.: Ein Fall von Leukämie mit Riesenzellenembolie und allgemeiner Osteosklerose. *Ztschr. Heilk.,* **22,** 294 (1901). [G9072

Schwenter-Trachsler, J.: Ergebnisse von Untersuchungen an Mastzellen der Haut. *Monatsh. prakt. Derm.,* **43,** 47, 114 (1906). [D26846

——: Neuere Befunde an Mastzellen der Haut. *Folia haemat.,* **3,** 519 (1906). [D27426

——: Über Mucin und Mastzellenkörner. *Monatsh. prakt. Derm.,* **47,** 1, 83 (1908). [D27711

——: Mastzellen. In: *Encyklopädie der Mikroskopischen Technik,* **2,** 69 (1910). [E21126

Scott, K. G.: The mast cell, its amines, and tumor growth in rodents and man. *Ann. N.Y. Acad. Sci.,* **103,** 285 (1963). [D58287

——, **Scheline, R. R.,** and **Stone, R. S.:** Mast cells and sarcoma growth in the rat. *Cancer Res.,* **18,** 927 (1958). [D63179

Scott, M., and **Lewis, G. M.:** Urticaria pigmentosa with solitary lesions. Report of a case. *A.M.A. Arch. Derm. Syph. (Chic.),* **66,** 618 (1952). [D39665

Seawright, A. A., and **Grono, L. R.:** Malignant mast cell tumour in a cat with perforating duodenal ulcer. *J. Path. Bact.,* **87,** 107 (1964). [G2729

Séguin, P.: Les mastzellen histiogènes dans le chorion de la muqueuse du gros intestin du cheval. *C.R. Soc. Biol. (Paris),* **73,** 30 (1912). [D27447

Sellyei, M., and **David, H.:** Untersuchungen über die Ultrastruktur einer Variante des Furthschen Mäusemastozytoms. *Ztschr. mikros.-anat. Forschg.,* **70,** 103 (1963). [E30333

Selye, H.: Studies on adaptation. *Endocrinology,* **21,** 169 (1937). [38798

——: Effect of folliculoid hormones on abnormal skin. Further observations of the effect of estradiol on the skin of mice of the rhino, hairless and naked strains. *A.M.A. Arch. Derm. Syph. (Chic.),* **50,** 261 (1944). [A57745

——: Changes in the adrenal medulla following treatment with an ACTH-preparation containing carboxymethylcellulose. *Proc. Soc. exp. Biol. (N.Y.),* **90,** 670 (1955). [C8400

——: *The Stress of Life.* New York: McGraw Hill (1956). [C19000

——: The dermatologic implications of stress and calciphylaxis. *J. invest. Derm.,* **39,** 259 (1962). [D25668

——: *Calciphylaxis.* Chicago: The University of Chicago Press (1962). [D15540

——: The experimental production of calcified deposits on the rotator cuff. *Surg. Clin. N. Amer.,* **43,** 1483 (1963). [D59442

——: Calciphylaxis and calcergy. *5th Internat. Congr. Allergol. Madrid, Oct. 1964.* [E24150

——, and **Bois, P.:** Anaphylactoide Entzündung und Magengeschwüre bei mit

Serotonin behandelten Ratten. *Allergie u. Asthma,* **3**, 11 (1957). [C23958
——, and ——: Effect of STH on experimental lathyrism. *Proc. Soc. exp. Biol. (N.Y.),* **94**, 133 (1957). [C23297
——, **Caruso, P. L.**, and **Tuchweber, B.**: Histochemische Studien über die Beteiligung der Mastzellen bei der Calciphylaxie. *Virchows Arch. pathol. Anat.,* **337**, 538 (1964). [E24138
——, ——, and ——: Various forms of anaphylactoid reaction demonstrable by mastocalcergy. *Brit. J. exp. Path.,* **46**, 86 (1965). [G11122
——, ——, ——, and **Gabbiani, G.**: Mastocalciphylaxis. *Ann. Allergy,* **22**, 645 (1964). [E24139
——, **Dieudonné, J. M.**, and **Tuchweber, B.**: Siderocalciphylactic sensitization to distilled water. *Arch. Int. Med.,* **110**, 290 (1962). [D15688
——, ——, and **Veilleux, R.**: Siderocalciphylactic sensitization to mastocyte dischargers. *Canad. J. Biochem. & Physiol.,* **41**, 291 (1963). [D15989
——, and **Gabbiani, G.**: Role of the mastocytes in soft-tissue calcification. *Fed. Proc.,* **23**, 339 (1964). [E24133
——, ——, and **Nielsen, K.**: The 'Periosteal Spread' technic for study of mast cells. *Proc. Soc. exp. Biol. (N.Y.),* **112**, 460 (1963). [D36698
——, ——, and **Rojo Ortega, J. M.**: Neurotropic calciphylaxis. *Proc. Soc. exp. Biol. (N.Y.),* **113**, 771 (1963). [D58540
——, ——, and **Serafimov, N.**: Histochemical studies on the role of the mast cell in calcergy. *J. Histochem. Cytochem.,* **12**, 563 (1964). [E24136
——, ——, and **Tuchweber, B.**: The effect of cyproheptadine on the anaphylactoid reaction and the localization of certain calciphylactic syndromes. *Ann. Allergy,* **20**, 777 (1962). [D26792
——, ——, and ——: The role of mastocytes in the regional fixation of blood-borne particles. *Brit. J. exp. Path.,* **44**, 38 (1963). [D24159
——, ——, and ——: An experimental model of osteomyelosclerosis. *Acta haemat. (Basel),* **29**, 51 (1963). [D25659
——, ——, and ——: Calciphylaxis and the parathyroid glands. *Recent Progr. Hormone Res.,* **20**, 33 (1964). [E24102
——, ——, and ——: Neurotropic calcergy. *Neurology,* **14**, 1084 (1964). [G11112
——, **Gentile, G.**, and **Dieudonné, J. M.**: Effect of adjuvants upon cutaneous calciphylaxis induced by topical or systemic challenge. *Internat. Arch. Allergy,* **20**, 80 (1962). [D10088
——, ——, and **Jean, P.**: An experimental model of dermatomyositis induced by calciphylaxis. *Canad. med. Ass. J.,* **85**, 770 (1961). [D8490
——, and **Jahnke, V.**: Über das Entstehen metachromatischer Substanz nach Behandlung mit Uranylazetat. *Acta histochem.* (in press). [G11105
——, **Miranda Garay, M.**, and **Tuchweber, B.**: Mastocalciphylaxis as influenced by adrenalectomy and hypophysectomy. *Proc. Endocr. Soc. Meet., San Francisco, June 1964.* No. 246 (1964). [E24147
——, and **Nielsen, K.**: Participation of the mast cells in certain thrombohemorrhagic phenomena. (in preparation). [D78786
——, and **Tuchweber, B.**: Mast-cell products and tissue calcification. *Quart. J. exp. Physiol.,* (in press). [G11117
——, ——, and **Caruso, P. L.**: Drug-induced resistance to tissue calcification. *J. pharm. Sci.* (in press). [G11118
——, ——, and ——: Topical resistance to mastocalcergy. *J. Pharmacol. exp. Ther.,* **146**, 252 (1964). [G11121
——, ——, and ——: Protection against neurotropic mastocalcergy. *Exp. Neurol.,* **10**, 451 (1964). [G11123
——, ——, and **Gabbiani, G.**: Prevention of cutaneous calciphylaxis by topical stress. *Arch. Derm.,* **87**, 566 (1963). [D40219
——, ——, and ——: The passive transfer of calcergy. *Growth,* **28**, 213 (1964). [G11107
Semon, ?.: Urticaria pigmentosa. *Brit. J. Derm.,* **25**, 265 (1913). [E37587
Serafimov, N., Tuchweber, B., Gabbiani, G., Jean, P., and **Selye, H.**: The action of histamine liberators on calcification produced by various metals. *Arch. int. Pharmacodyn.* (in press). [E24149
Serrão, D.: Os mastócitos em certos estados patológicos. *Portugal méd.,* **37**, 275 (1953). [C8615
Sézary, A.: Nosologie de l'urticaire pigmentaire. *Bull. méd. (Paris),* **50**, 211 (1936). [D39815
——: A propos de la nosologie de l'urticaire pigmentaire. Les mastocytomes. *Bull. Soc. franç. Derm. Syph.,* **43**, 357 (1936). [D26804
——, **Caroli, J.**, and **Horowitz, A.**: Urticaire pigmentaire sans pigmentation. Dermographisme et mastocytes. *Bull. Soc. franç. Derm. Syph.,* **43**, 78 (1936). [D26806

——, **Lefèvre, P.,** and **Chauvillon, P.:** 'Urticaire pigmentaire' sans pigmentation. *Bull. Soc. franç. Derm. Syph.,* **42,** 302 (1935). [D26815

——, ——, and ——: Urticaire pigmentaire, dermographisme et mastocytes. *Bull. Soc. franç. Derm. Syph.* **43,** 1263 (1936). [D10612

——, **Lévy-Coblentz, G.,** and **Chauvillon, P.:** Dermographisme et mastocytose. *Bull. Soc. franç. Derm. Syph.,* **43,** 359 (1936). [D26805

Shaffner, ?.: Urticaria pigmentosa. *J. cutan. Dis.,* **33,** 397 (1915). [E37990

Sheldon, W. H., and **Bauer, H.:** Tissue mast cells and acute inflammation in experimental cutaneous mucormycosis of normal, 48/80-treated, and diabetic rats. *J. exp. Med.,* **112,** 1069 (1960). [C96633

Shelley, W. B.: Adventures with the basophils. *J. invest. Derm.,* **39,** 277 (1962). [E52331

——: Indirect basophil degranulation test for allergy to penicillin and other drugs. *J. Amer. med. Ass.,* **184,** 171 (1963). [D62401

——: Methods of observing the basophil leucocyte degranulation response. *Ann. N.Y. Acad. Sci.,* **103,** 427 (1963). [D58295

——: The circulating basophil as an indicator of hypersensitivity in man. Experimental novobiocin sensitization. *A.M.A. Arch. Derm.,* **88,** 759 (1963). [E35090

——, and **Caro, W. A.:** Detection of anaphylactic sensitivity by the basophil degranulation response. An experimental study. *J. Amer. med. Ass.,* **182,** 172 (1962). [D36685

——: The basophil leucocyte as an index of immediate hypersensitivity. *Trans. Coll. Phycns. Philad.,* **32,** 15 (1964). [G18654

——, and **Florence, R.:** A technic for the study of mast cells: the guinea-pig mesentery. *J. invest. Derm.,* **37,** 195 (1961). [D33736

——, and ——: Ethylene glycol monomethyl ether, a new fixative for histological work. *Nature (Lond.),* **191,** 719 (1961). [E91256

——, and **Juhlin, L.:** Degranulation of the basophil in man induced by alimentary lipemia. *J. Amer. med. Sci.,* **242,** 211 (1961). [D39536

——, and ——: A new test for detecting anaphylactic sensitivity: The basophil reaction. *Nature (Lond.),* **191,** 1056 (1961). [D61814

——, and ——: Functional cytology of the human basophil in allergic and physiologic reactions: Technic and atlas. *Blood,* **19,** 208 (1962). [D41202

——, and ——: In vitro effect of lecithinase A on the cytology of the human basophil. *J. Lab. clin. Med.,* **60,** 589 (1962). [D80542

Shelmire, J. B.: Case report: Urticaria pigmentosa. *Tex. St. J. Med.,* **12,** 267, (1916). [E37585

Shibata, A., Negishi, T., and **Yamada, A.:** Studies on the dynamics of basophil leucocytes. IV. Basophil leucocytes and histamine. *New Medicine,* **49,** 265 (1962). [E44169

Shikhodirov, V. V.: Changes in the mast cells in acute and chronic radiation sickness. (Russian text) *Arkh. Pat.,* **19,** 35 (1957). [D27086

Shimkin, M. B., and **Bierman, H. R.:** Blood histamine in leukemia. *Amer. J. Med.,* **8,** 542 (1950). [B53091

——, **Sapirstein, L., Goetzl, F. R.,** and **Wheeler, P. M.:** Blood histamine in leukemia and erythremia. *J. Nat. Cancer Inst.,* **9,** 379 (1949). [B49546

Shionoya, S.: Electron miscroscopic study on the catecholamine metabolism in the human adrenal medulla. *Nagoya J. med. Sci.,* **26,** 60 (1963). [G9199

Shipley, P. G., Park, E. A., McCollum, E. V., and **Simmond, N.:** Is there more than one kind of rickets? *A.M.A. J. Dis. Child.,* **23,** 91 (1922). [D33700

Shoulders, H. H., and **Meng, H. C.:** Effects of fat emulsion upon tissue mast cells. *Fed. Proc.,* **16,** 371 (1957). [D27067

——, and **Meng, H. C.:** Release of histamine-like substance from mast cells following intraperitoneal administration of fat emulsion in rats. *Proc. Soc. exp. Biol. (N.Y.),* **104,** 657 (1960). [D26886

Shubich, M. G.: A new selective method of staining mast cells. *Bull. exp. Biol. Med.,* **46,** 1528 (1958). [D39830

Sibley, W. K.: Urticaria pigmentosa in a soldier, aged 19 years. *Brit. J. Derm.,* **28,** 327 (1916). [E37586

Sicuteri, F., Michelacci, S., and **Franchi, G.:** The activation of mast cells by the histamine liberator 48/80 in man. *Int. Arch. Allergy,* **22,** 408 (1963). [E21615

Sidi, E., Reinberg, A., and **Gervais, P.:** Le test des basophiles. Une reaction serologique nouvelle en allergologie. *Presse méd.,* **71,** 2777 (1963). [E51719

Silbert, J. E.: Incorporation of ^{14}C and ^{3}H from nucleotide sugars into a polysaccharide in the presence of a cellfree preparation from mouse mast cell tumors. *J. biol. Chem.,* **238,** 3542 (1963). [E32901

Simpson, W. L.: Distribution of mast cells as a function of age and exposure to carcinogenic agents. *Ann. N.Y. Acad. Sci.*, **103**, 4 (1963). [D58271

——, and **Hayashi, Y.**: Distribution of mast cells in the skin and mesentery of BALB/c and C57BL mice. *Anat. Rec.*, **138**, 193 (1960). [D26645

——, **Hayashi, Y.**, and **Pawley, E.**: Mesenchymal and mast cell changes during hydrocarbon carcinogenesis. In: *Proceedings of an International Symposium on Biological Interactions in Normal and Neoplastic Growth*. Boston, Mass.: Little, Brown and Co. (1962). [E21127

——, ——, and ——: Mast cells and susceptibility to mammary cancer in inbred strains of mice. In: *University of Perugia, Division of Cancer Research*, p. 329 (1962). [D61512

Sirois, J.: Mast cell disease. *Canad. med. Ass. J.*, **89**, 1043 (1963). [E31826

Siurala, M., Räsänen, T., and **Sundberg, M.**: The effect of ACTH upon the tissue eosinophils and mast cells in the human gastric mucosa. *Acta path. microbiol. scand.*, **47**, 337 (1959). [C79697

——, and **Sundberg, M.**: Occurrence of mast cells in the gastric mucosa under normal and pathological conditions. *Ann. Med. exp. Fenn.*, **36**, 271 (1958). [D27075

Sjoerdsma, A.: Serotonin. *New Engl. J. Med.*, **261**, 181 (1959). [D30551

——, **Waalkes, T. P.**, and **Weissbach, H.**: Serotonin and histamine in mast cells. *Science*, **125**, 1202 (1957). [C35838

——, ——, and ——: Studies on serotonin and histamine in mast cells. *J. Pharmacol. exp. Ther.*, **122**, 69A (1958). [C48610

Smirnowa-Zamkowa, A.: Zur pathologischen Anatomie des Scharlachs. *Virchows Arch. pathol. Anat.*, **261**, 190 (1926). [D31602

Smith, C.: Glycogen in basophilic leucocytes in human blood smears. *Proc. Soc. exp. Biol. (N.Y.)*, **72**, 209 (1949). [D85923

Smith, D. E.: Dynamics of release of histamine from tissue mast cell. *Science*, **128**, 207 (1958). [D63185

——: Nature of the secretory activity of the mast cell. *Amer. J. Physiol.*, **193**, 573 (1958). [C54403

——: Influence of antihistamines on mast cell disruption following X-irradiation. *Proc. Soc. exp. Biol. (N.Y.)*, **97**, 872 (1958). [D27082

——: Electron microscopy of normal mast cells under various experimental conditions. *Ann. N.Y. Acad. Sci.*, **103**, 40 (1963). [D58273

——: The tissue mast cell. *Int. Rev. Cytol.*, **14**, 327 (1963). [D63031

——, and **Lewis, Y. S.**: Effects of total-body X-irradiation on the tissue mast cell. *Proc. Soc. exp. Biol. (N.Y.)*, **82**, 208 (1953). [B79377

——, and ——: Influence of total-body X-irradiation upon tissue mast cell number. *Proc. Soc. exp. Biol. (N.Y.)*, **85**, 306 (1954). [B91529

——, and ——: Influence of hypophysis and adrenal cortex upon tissue mast cell of the rat. *Proc. Soc. exp. Biol. (N.Y.)*, **87**, 515 (1954). [C1168

——, and ——: Influence of hypophysis and of adrenal cortex upon tissue mast cell of the hamster. *Proc. Soc. exp. Biol. (N.Y.)*, **88**, 631 (1955). [C4564

——, and ——: Electronmicroscopy of mast cells after X-irradiation and treatment with chemical agents. *Amer. J. Physiol.*, **183**, 662 (1955). [C11751

——, and ——: Electron microscopy of the tissue mast cell. *J. biophys. biochem. Cytol.*, **3**, 9 (1957). [D33719

——, and ——: Phagocytosis of granules from disrupted mast cells. *Anat. Rec.*, **132**, 93 (1958). [D63176

——, and ——: Influence of hormones and X-rays upon the tissue mast cell. *Experientia (Basel)*, **14**, 335 (1958). [C72227

——, and ——: Preparation and effects of an anti-mast cell serum. *J. exp. Med.*, **113**, 683 (1961). [D2416

——, ——, and **Svihla, G.**: Blood clotting time and tissue mast cell number of the bat (Myotis lucifugus) in different physiological states. *Proc. Soc. exp. Biol. (N.Y.)*, **86**, 473 (1954). [D67482

——, ——, and ——: Cinephotomicrography of living mast cells under the influence of pharmacological agents. *Anat. Rec.*, **136**, 359 (1960). [D63177

Smith, E. W., and **Atkinson, W. B.**: Simple procedure for identification and rapid counting of mast cells in tissue sections. *Science*, **123**, 941 (1956). [D26639

Smith, R. S.: The development of mast cells in the vascularized cornea. *A.M.A. Arch. Ophthal.*, **66**, 383 (1961). [D39764

Smith, W. G.: Mast cell population of lung of the guinea pig and other tissues. *Nature (Lond.)*, **184**, 1154 (1959). [D26773

Smyth, C. J., and **Gum, O. B.**: Vasculitis, mast cells and the collagen diseases. *Arthr. and Rheum.*, **4**, 1 (1961). [D4499

Snellman, O., Jensen, R., and **Sylvén, B.:** A new extraction procedure for the preparation of heparin. *Nature (Lond.),* **161,** 639 (1948). [D27734
——, **Sylvén, B.,** and **Julén, C.:** Analysis of the native heparin-lipoprotein complex including the identification of a heparin complement (Heparin co-factor) obtained from extracts of tissue mast cells. *Biochim. biophys. Acta,* **7,** 98 (1951). [D27963
Solger, B.: Zur Mastzellenfrage. *Münch. med. Wchnschr.,* **44,** 1514 (1897). [D63186
Sousa, A. T. de, *cf.* Tavares de Sousa, A. [D39613, D39787
Spangenthal, J.: A case of urticaria pigmentosa. *Buffalo med. J.,* **69,** 76 (1913). [E37995
Spargo, B., Bloomfield, J. R., Glotzer, D. J., Gordon, E. L., and **Nichols, O.:** Histological effects of long-continued whole-body gamma-irradiation of mice. *J. nat. Cancer Inst.,* **12,** 615 (1951). [B90582
Spaziante, G., and **Giani, E.:** Contributo allo studio della metachromasia stromale nella ipertrofia della prostata. *Urologia (Treviso),* **28,** 103 (1961). [E98826
Spector, W. G., and **Willoughby, D. A.:** The demonstration of the role of mediators in turpentine pleurisy in rats by experimental suppression of the inflammatory changes. *J. Path. Bact.,* **77,** 1 (1959). [C63466
Speirs, R. S.: Physiological approaches to an understanding of the function of eosinophils and basophils. *Ann. N.Y. Acad. Sci.,* **59,** 706 (1955). [C3414
——, **Osada, Y.,** and **Jansen, V.:** DNA synthesis in inflammatory cells of immunized and non-immunized mice. *Proc. Soc. exp. Biol. (N.Y.),* **106,** 251 (1961). [D63716
——, and **Wenck, U.:** Effect of cortisone on the cellular response during allergic inflammation. *Acta haemat. (Basel),* **17,** 271 (1957). [C34890
——, ——, and **Dreisbach, M. E.:** Quantitative studies of the cellular responses to antigen injections in adrenalectomized mice. *Blood,* **11,** 56 (1956). [C10808
Spicer, S. S.: A correlative study of the histochemical properties of rodent acid mucopolysaccharides. *J. Histochem. Cytochem.,* **8,** 18 (1960). [D30596
——: Siderosis associated with increased lipofuscins and mast cells in aging mice. *Amer. J. Path.,* **37,** 457 (1960). [C92580
——: Histochemically selective acidophilia of basic nucleoproteins in chromatin and nucleoli at alkaline pH. *J. Histochem. Cytochem.,* **10,** 691 (1962). [D63192
——: Histochemical properties of mucopolysaccharide and basic protein in mast cells. *Ann. N.Y. Acad. Sci.,* **103,** 322 (1963). [D58289
Spillmann, L., and **Weille, R.:** Urticaire bulleuse et pigmentée chez un hérédosyphilitique. *Bull. Soc. franç. Derm. Syph.,* **44,** 12 (1937). [D39654
Spode, E.: Beitrag zur Physiologie der Mastzellen des Blutes. *Ztschr. gesamt. inn. Med.,* **12,** 234 (1957). [D16626
Spolter, L., and **Marx, W.:** Paper chromatography of heparin and related sulfated mucopolysaccharides. *Biochim. biophys. Acta (Amst.),* **38,** 123 (1960). [D65505
——, **Rice, L. I.,** and **Marx, W.:** Effect of diphosphopyridine nucleotide on the formation of ^{35}S-labelled substances in a particle-free supernatant of mouse mast-cell tumor. *Biochim. biophys. Acta (Amst.),* **69,** 583 (1963). [D62371
Squartini, F., Caschera, F., and **Passaretti, J. R.:** Significato istofunzionale delle Mastzellen. I. In base ad uno studio istologico al altezza del duodeno. *Lav. Ist. Anat. Univ. Perugia,* **16,** 299 (1956). [D30649
——, ——, ——, and **Rossi, G.:** Significato istofunzionale delle Mastzellen. II. Le Mastzellen nell'ulcera gastrica. *Lav. Ist. Anat. Univ. Perugia,* **16,** 367 (1956). [D30195
——, and **Giacanelli, F.:** Le Mastzellen nel sistema nervoso centrale. *Lav. Ist. Anat. Univ. Perugia,* **16,** 383 (1956). [D39823
Stach, W.: Morphologische Beziehungen zwischen Mastzellen und vegetativer Endformation. *Ztschr. mikros.-anat. Forschg.,* **67,** 257 (1961). [D39563
Staemmler, M.: Untersuchung über Vorkommen und Bedeutung der histiogenen Mastzellen im menschlichen Körper unter normalen und pathologischen Verhältnissen. *Frankf. Ztschr. Pathol.,* **25,** 391 (1921). [D26807
Staffel, H.: Die Genese des melanotischen Pigments. *Folia haemat.,* **3,** 576 (1906). [D27427
——: Die Genese des Hautpigmentes. *Verhandl. Dtsch. pathol. Gesellsch. (11th Meet. Dresden Sept. 1907)* p. 136 (1908). [D33661
Stainer, E.: Urticaria pigmentosa. *Brit. J. Derm.,* **18,** 186 (1906). [E37379
Stark, E., van Buskirk, F. W., and **Daly, J. F.:** Radiologic and pathologic bone changes associated with urticaria pigmentosa. Report of a case. *A.M.A. Arch. Path.,* **62,** 143 (1956). [D28278
Stasney, J., and **Higgins, G. M.:** A qualitative cytologic study of the bone marrow of the adult albino rat. *Anat. Rec.,* **62,** 77 (1935). [D27357

Stassano, ?., and **Haas, ?.:** Contribution à la physiologie des clasmatocytes. *C.R. Soc. Biol. (Paris),* **52,** 807 (1900). [D33741
Steiner, K.: Cutaneous mast cells in carcinoid. *A.M.A. Arch. Dermat.,* **84,** 477 (1961). [D12749
Stella, A.: Sobre los mastzellen de la encia humana. *An. Fac. Odont. (Montevideo),* **2,** 125 (1955). [D63057
Stelwagon, ?.: Urticaria pigmentosa. *J. cutan. Dis.,* **33,** 216 (1915). [E37988
Stern, P., Nikulin, A., and **Ferluga, J.:** The role of histamine and bradykinin in the inflammatory process. *Arch. int. Pharmacodyn.,* **140,** 528 (1962). [G6829
Stillians, ?.: Urticaria pigmentosa. *J. cutan. Dis.,* **34,** 615 (1916). [E38134
Stinson, J. C., Sunbury, T. R., and **Lea, W. A.:** A stain for mast cells which is rapid and permanent. *J. invest. Derm.,* **36,** 1 (1961). [D26841
Stintzing, R.: Zum feineren Bau und zur Physiologie der Magenschleimhaut. *Verhandl. Gesellsch. Morphol. Physiol. München, July 1889,* p. 90 (1889). [E29587
——: Zur Struktur der erkrankten Magenschleimhaut. *Münch. med. Wchnschr.,* **36,** 819 (1889). [D31578
——: *Zur Struktur der Magenschleimhaut.* Leipzig: Fischer Verlag (1899). [D30650
Stockinger, W.: Bindegewebsstudien. IV. Das lockere Bindegewebe der weissen Maus in verschiedenen Lebensaltersstufen, mit besonderer Berücksichtigung der Mastzellen und der Gewebsleukozyten. *Ztschr. Zellforschg. mikroskop. Anat.,* **6,** 27 (1928). [D65522
Stoeckenius, W.: Zur Feinstruktur der Granula menschlicher Gewebsmastzellen. *Exp. Cell Res.,* **11,** 656 (1956). [D27740
Stolk, A.: Fluorescent mast-cell reaction in precancerous skin of the lizard Lacerta agilis. *Nature (Lond.),* **182,** 1177 (1958). [C61615
——: Effect of high-fat diet on mast-cell count in mesenterium of some viviparous toothcarps. *Naturwschft.,* **46,** 361 (1959). [D39774
——: High-fat diet and mast cell count in myocardium of some teleosts. *Naturwschft.,* **46,** 409 (1959). [D65681
——: Leucine aminopeptidase activity in mesenterial mast cells of the carp Cyprinus carpio L. *Acta morph. neerl.-scand.,* **3,** 1 (1960). [D39816
——: Leucine aminopeptidase activity in cutaneous mast cells of the precancerous skin of the lizard Lacerta agilis L. *Acta morph. neerl.-scand.,* **3,** 13 (1960). [D39817
——: Differences in mechanism of staining reaction for mast cells of some lower vertebrates. *Nature (Lond.),* **190,** 360 (1961). [D26444
——: Mast cell reaction during chemical skin carcinogenesis of the lizard Lacerta agilis. *Experientia (Basel),* **19,** 20 (1963). [D39819
Stone, H., and **Robillard, E.:** Pulmonary mast cell infiltration after chronic exposure to submicronic dust inhalation in the rat. *Proc. Can. Fed. Biol. Soc.,* **7,** 53 (1964). [E81532
Stuart, E. G.: Connective tissue mast-cell responses to bacterial pyrogens, ovalbumin and cortisone. *Anat. Rec.,* **109,** 351 (1951). [D2340
——: Mast cell responses to anaphylaxis. *Anat. Rec.,* **112,** 394 (1952). [D15089
Studer, A.: Vorkommen und Bedeutung des körpereigenen Heparins. *Experientia (Basel),* **10,** 148 (1954). [C6137
Stünzi, H.: Zur Pathologie des sog. Mastozytoms des Hundes. *Schweiz. Ztschr. allg. Pathol.,* **18,** 1271 (1955). [C14513
Sturm, A., and **Stüttgen, G.:** Nachweis von 5-Hydroxytryptophan in menschlichen Mastzellen. *Klin. Wchnschr.,* **40,** 199 (1962). [D21093
Stüttgen, G., Sturm, A., and **Brüster, H.:** Biochemische Studien zur Reaktivität mastzellenreicher menschlicher Haut. *Arch. klin. exp. Dermat.,* **214,** 362 (1962). [D26860
Stutzman, L., and **Urbach, F.:** Mast cell disease. *Pediat. Clin.* **8,** 857 (1961). [D14152
——, **Zsoldos, S., Ambrus, J. L.,** and **Asboe-Hansen, G.:** Systemic mast cell disease. Physiologic considerations and report of a patient treated with nitrogen mustard. *Amer. J. Med.,* **29,** 894 (1960). [C95789
Sumi, T.: Clinical and cytochemical studies on tissue mast cells. *Nagoya J. med. Sci.,* **21,** 222 (1958). [C60846
Sundberg, M.: On the mast cells in the human vascular wall. A quantitative study on changes at different ages. *Acta path. microbiol. scand.,* sup. 107, (1955). [D27403
——, and **Siurala, M.:** Mast cells in the gastric mucosa of patients with peptic ulcer and gastric cancer. *Ann. med. exp. Fenn.,* **37,** 175 (1959). [D26634
Sundberg, R. D., Schaar, F. E., Powell, M. J. S., and **Denboer, D.:** Tissue mast cells in human umbilical cord, and the anticoagulant activity of dried extracts of cords and placentae. *Anat. Rec.,* **118,** 35 (1954). [D26731

Suomalainen, P.: Further investigations on the physiology of hibernation. *Proc. Finnish Acad. Sci.,* p. 131 (1953–54). [C852
——, and **Granström, T.:** Haematological changes in the hibernating golden hamster (mesocricetus auratus). *Exp. Cell. Res.,* sup., 3, 335 (1955). [C29531
——, and **Härma, R.:** Heparinocytes and hibernation. *Experientia (Basel),* **7,** 380 (1951). [D30082
——, and **Lehto, E.:** Prolongation of clotting time in hibernation. *Experientia (Basel),* **8,** 65 (1952). [B89504
Sussmann, P.: Über das Vorkommen histiogener Mastzellen im Epithel. *Folia haemat.,* **12,** 337 (1911). [D27432
Sutter, M. C., Beaulieu, G., and **Birt, A. R.:** Histamine liberation by codeine and polymyxin B in urticaria pigmentosa. *A.M.A. Arch. Derm.,* **86,** 217 (1962). [D63193
Swoboda, N.: Urticaria pigmentosa. *Mittlg. Gesellsch. inn. Med.,* **4,** 159 (1905). [D31857
Sylvén, B.: Über das Vorkommen von metachromatischer Substanz in wachsendem Gewebe und ihre Bedeutung. *Klin. Wchnschr.,* **17,** 1545 (1938). [D26877
——: Über die Elektivität und die Fehlerquellen der Schleimfärbung mit Mucicarmin im Vergleich mit metachromatischer Färbung. *Virchows Arch. pathol. Anat.,* **303,** 280 (1939). [D31570
——: Studies on the liberation of sulphuric acids from the granules of the mast cells in the subcutaneous connective tissue after exposure to Roentgen and gamma rays. *Acta radiol. (Stockh.),* **21,** 206 (1940). [D27881
——: Über das Vorkommen von hochmolekularen Esterschwefelsäuren im Granulationsgewebe und bei der Epithelregeneration. *Acta chir. scand.,* **86,** sup. 66, 1 (1941). [D26048
——: Ester sulphuric acids of high molecular weight and mast cells in mesenchymal tumors. *Acta radiol. (Stockh.),* sup., 59, (1945). [D30594
——: The occurrence of ester sulphuric acids of high molecular weight and of mast cells in the stroma of the normal uterine corpus mucosa. *Acta obstet. gynec. scand.,* **25,** 189, 202 (1946). [D33704
——: Ester sulphuric acids in stroma connective tissue. *Acta radiol. (Stockh.),* **32,** 11 (1949). [D31569
——: The cytoplasm of living tissue mast cells in visual phase-contrast. *Exp. Cell Res.,* **1,** 492 (1950). [D65265
——: The qualitative distribution of metachromatic polysaccharide material during hair growth. *Exp. Cell Res.,* **1,** 582 (1950). [D29140
——: On the cytoplasmatic constituents of normal tissue mast cells. *Exp. Cell Res.,* **2,** 252 (1951). [D31551
——: On the topographical cytochemistry of tissue mast cells. In: *Connective Tissue. A Symposium* Springfield: Charles C Thomas Publ., First Printing, p. 27 (1957). [C77656
——, and **Larsson, L. G.:** The mast cell reaction in mouse skin to some organic chemicals. III. The early effect of aromatic hydrocarbons. *Cancer Res.,* **8,** 449 (1948). [D26612
——, and **Malmgren, H.:** On the alleged metachromasia of hyaluronic acid. *Lab. Invest.,* **1,** 413 (1952). [D26590
Symmers, W. S. C., and **Thomson, A. P. D.:** Multiple carcinomata and focal mastcell accumulations in the skin of a ferret (Mustela furo L.), with a note on other tumours in ferrets. *J. Path. Bact.,* **65,** 481 (1953). [D66474
Szabó, E., and **Mészáros, C.:** Die Rolle der Mastocyten in der Histogenese der Psoriasis. *Ztschr. Haut-u. Geschl.-Krht.,* **36,** 373 (1964). [F14221
Szécsi, S.: Experimentelle Studien über Serosa-Exsudatzellen. *Folia haemat.,* **13,** 1 (1912). [D27413
——: Lucidol, ein neuses Fixiermittel. *Dtsch. med. Wchschr.,* **39,** 1584 (1913). [D27988
Szirmai, J. A.: Studies on the connective tissue of the cock comb: I. Histochemical observations on the ground substance. *J. Histochem. Cytochem.,* **4,** 96 (1956). [C47033
——: Studies on the connective tissue of the cock comb. III. Mast cells and the effect of testosterone. *Acta endocrinol. (Kbh.),* **25,** 225 (1957). [C43968
Szweda, J. A., Abraham, J. P., Fine, G., Nixon, R. K., and **Rupe, C. E.:** Systemic mast cell disease. A review and report of three cases. *Amer. J. Med.,* **32,** 227 (1962). [D20223
Szymanski, F. J., and **Becker, L. A.:** Urticaria pigmentosa (Solitary lesion). *A.M.A. Arch. Derm.,* **73,** 608 (1956). [D39633
Takeda, Y.: On reaction of subcutaneous connective tissue mast cell in various fixatives. *Okajimas Folia anat. jap.,* **31,** 49 (1958). [C60733
——: On the variation of stainability and of the mast-cell granules in inflammatory

tissue. *Okajimas Folia anat. jap.*, **31**, 63 (1958). [C60734

——: On the origin of the tissue mast cell. *Okajimas Folia anat. jap.*, **31**, 143 (1958). [C60737

——: Studies on the mast cells in gingival tissue. *Okajimas Folia anat. jap.*, **31**, 377 (1958). [D63362

Takeoka, O., Angevine D. M., and **Lalich, J. J.:** Stimulation of mast cells in rats fed various chemicals *Amer. J. Path.*, **40**, 545 (1962) (No. 5). [D39931

——, ——, and ——: Proliferation of mast cells in the bone marrow of rats after feeding β-aminopropionitrile and β-mercaptoethylamine. *Amer. J. Path.*, **43**, 639 (1963). [E20322

Täljedal, I. B., and **Hellman, B.:** Morphological characteristics of the epididymal adipose tissue in different types of hereditary obese mice. *Path. et Microbiol. (Basel)*, **26**, 149 (1963). [D5553

Tanon, L.: Sur la présence de cellules à granulations métachromatiques dans la pulpe vaccinale. *C. R. Soc. Biol. (Paris)*, **66**, 1069 (1909). [D27445

Tavares, A., and **Ribeiro, C. S.:** Estudo sobre os carcinoides. *J. méd. (Pôrto)*, **13**, 314 (1949). [D39612

Tavares de Sousa, A.: Les 'Mastzellen' sont-elles des éléments constituants normaux de l'hypophyse du boeuf ? *Fol. anat. (Coimbra)*, **12**, 1 (1937). [D39613

——: Sur la coloration des granulations des Mastzellen par le tannin-fer-hematoxylin. *Arch. portug. Sci. Biol.*, **8**, 28 (1945). [D39787

Taylor, H. E., and **Saunders, A. M.:** The association of granulation tissue ground substance with fibroblastic activity. *Amer. J. Path.*, **32**, 617 (1956). [D27882

Tedeschi, G., Cavazzuti, F., and **Angeli, G.:** Variazioni quantitative dei granulociti basofili del sangue periferico in diverse condizioni patologiche. *Minerva med.*, **50**, 1535 (1959). [C70550

Teichert, G.: Spongiosklerose bei der Mastzellenretikulose. *Dtsch. med. Wchnschr.*, **87**, 1242 (1962). [D26594

Telkkä, A., and **Kuusisto, A. N.:** The mast cell count of the rat liver in experimental obstructive jaundice. *Acta path. microbiol. scand.*, **41**, 183 (1957). [C45221

Ten Berg, J. A. G., *cf.* Berg, J. A. G., ten. [E57228

Teodori, U., Bigozzi, U., and **Salti, F.:** Sindrome di Ehlers Danlos in padre e figlio con reperto di mastzellen nel derma. Studio genetico della sindrome e considerazioni sulla sua patogenesi. *Arch. De Vecchi Anat., pat.*, **39**, 1075 (1963). [G19161

Texier, L: Sur un cas de mastocytome chez l'enfant. *Bull. Soc. franç. Derm. Syph.*, **60**, 205 (1953). [D39655

Thibierge, ?., and **Boutelier, ?.:** Urticaire pigmentée discrète chez une enfant de 7 mois. *Bull. Soc. franç. Derm. Syph.*, **27**, 9 (1920). [E38016

Thiersch, J. B.: Histamine and histaminase in chronic myeloid leukaemia of man. I. Histaminase in blood of chronic myeloid leukaemia. *Austral. J. exp. med. Sci.*, **25**, 73 (1947). [G18799

Thiéry, J. P.: Mise en évidence de polysaccharides acides (héparine) dans les granules des mastocytes. Third European Regional Conference on Electron Microscopy, Prague: *Czechoslovak Academy of Sciences*, p. 209 (1964). [D5220

——: Etude au microscope électronique de la maturation et de l'excrétion des granules des mastocytes. *J. Microscopie*, **2**, 549 (1963). [E39146

Thin, G.: On the microscopic appearances of the skin of a patient whose case is described by Mr. Morrant Baker in the 8th volume of this Society's Transactions. *Trans. clin. Soc. Lond.*, **10**, 198 (1877). [D39839

Thoma, K., and **Wiercinski, A.:** Untersuchungen über die Funktion der Granula der basophilen Leukozyten. *Dtsch. med. Wchnschr.*, **75**, 86 (1950). [E50870

Thompson, J. C., Lerner, H. J., Vakil, H. C., and **Tramontana, J. A.:** Heparin inhibition of gastric secretion: Role of histamine and gastric mast cells. *Surg. Forum*, **14**, 342 (1963). [E39861

——, **Vakil, H. C.,** and **Miller, J. H.:** Mast cell degranulation and gastric secretion: inhibitory role of heparin. *Fed. Proc.* **23**/1, 214 (1964). [F3698

Thonnard-Neumann, E.: Los leucocitos basofilos en la endocrinopathia de las glandulas sexuales. *Rev. Fac. Med. (Bogota)*, **19**, 535 (1951). [D20120

——: Basophile Leukozyten und Ovarialfunktion. *Ärztl. Forschg.*, **8**, 443 (1954). [G9153

——: Basophile Leukozyten und Steroidhormone. *Medizinische*, No. 27/28, 1087 (1958). [C59519

——: The influence of hormones on the basophil leukocytes. *Acta haemat. (Basel)*, **25**, 261 (1961). [E93067

——: Studies of basophils. Variation with age and sex. *Acta haemat. (Basel)*, **30**, 221 (1963). [G15063

Thorne, N. A.: Bullous urticaria pigmentosa. *Brit. J. Derm.,* **69,** 285 (1957). [D39670

Thumb, N., Braitenberg, H., and **Braunsteiner, H.:** Quantitative Veränderungen der Blutbasophilen durch Schwangerschaft, Zyklus und Sexualhormone. *Wien. klin. Wchnschr.,* **71,** 595 (1959). [E53262

——, **Potuzhek, O., Braitenberg, H.,** and **Braunsteiner, H.:** Hochgradige Verminderung der Blutbasophilen während der Schwangerschaft. *Wien. Ztschr. inn. Med.,* **40,** 129 (1959). [C73066

Tièche, ?.: Urticaria pigmentosa. *Korresp.-Bl. schweiz. Ärz.,* **46,** 1494 (1916). [E37994

Timphus, L.: Die Mastzellen und myeloischen Zellen im lymphatischen Gewebe des Menschen. *Thesis, University of Leipzig* (1914). [D27412

Tinel, J., and **Vimeux, J.:** Les mastocytes dans les organes de la reproduction. *C.R. Soc. Biol. (Paris),* **146,** 1915 (1952). [D33688

Tinti, M.: Sui derivati istioidi nelle leucemie. *Rev. Clin. méd.,* **27,** 365 (1926). [G11138

Tischendorf, W., and **Hartmann, F.:** Makroglobulinaemie (Waldenström) mit gleichzeitiger Hyperplasie der Gewebsmastzellen. *Acta haemat. (Basel),* **4,** 374 (1950). [D39646

Titschack, H.: Beobachtungen über das Vorkommen von Mastzellen in der Stromareaktion bei Hauttumoren der Augenlider und der Haut der oberen Gesichtsteile. *Ztschr. Haut- u. Geschl.-Krht.,* **26,** 287 (1959). [D39667

——: Untersuchungen über die Gewebsmastzellen des menschlichen Auges bei Melanoblastom der Aderhaut. *Ophthalmologica (Basel),* **140,** 41 (1960). [D26861

Todaro, F.: Osservazioni sulla presenza e sulle variazioni delle Mastzellen nella gengiva con dente sano e con dente cariato. *Atti Accad. Peloritana Messina,* **40,** 292 (1938). [D63791

——: Morfologia, frequenza ed ubicazione degli elementi granulosi basofili del connettivo nei territori dentali, paradentali e buccali dell'uomo e dei mammiferi. *Stomatologia (Roma),* **17,** 438 (1939). [D39783

Togawa, A.: Studies on the tissue mast cells in the liver. I. Observations on the tissue mast cells in the liver of viral hepatitis. *Abstr. Jap. Soc. intern. Med.,* **49,** 30 (1960–61). [D39528

Tokuda, S., and **Weiser, R. S.:** Studies on the role of serotonin and mast cells in anaphylaxis of the mouse produced with soluble antigen-antibody complexes *J. Immunol.,* **86,** 292 (1960). [D26827

Tokué, K.: The blood mast cell and its oxidase and peroxidase reaction. *Tohoku J. exp. Med.,* **12,** 459 (1928–29). [D26880

Tomaszewski, Z.: Über einen Fall von Mastzellenleukämie. *Folia haemat. (Lpzg.),* **12,** 115 (1911). [D63793

Törö, I.: Histologische Untersuchungen über die Beziehungen zwischen reticuloendothelialem System und Histaminwirkung. *Ztschr. mikrosk.-anat. Forschg.,* **52,** 552 (1942). [D33638

Torp, A.: Histamine and mast cells in nerves. *Med. exp. (Basel),* **4,** 180 (1961). [D27063

Torres, M.: Urticaria pigmentaria. *Act. dermo-sifiliogr. (Madr.),* **42,** 457 (1951). [D39814

Torsegno, M. E.: Le 'Mastzellen' nel bulbo olfattorio normale. *Note Riv. Psichiat., Apr.,* 215 (1935). [D39799

——: Les mastzellen dans le bulbe olfactoire du chien nouveau-né. *Trab. Inst. Cajal Invest. biol.,* **30,** 355 (1935). [D39595

Tötterman, G.: Are the basophilic leucocytes 'heparinocytes' ? (Part I). *Acta med. scand.,* **130,** 176 (1948). [D39744

Touraine, A.: Urticaire pigmentaire familiale. *Bull. Soc. franç. Derm. Syph.,* **55,** 105 (1948). [D39735

——, and **Harliz, G. A.:** Urticaire pigmentaire à début fébrile. *Bull. Soc. franç. Derm. Syph.,* **54,** 177 (1947). [D39679

——, and **Renault, P.:** Urticaire pigmentaire (Forme tardive à poussée unique). *Bull. Soc. franç. Derm. Syph.,* **41,** 1911 (1934). [D39751

——, **Solente, G.,** and **Renault, P.:** Urticaire pigmentaire avec réaction splénique et myélémique. *Bull. Soc. franç Derm. Syph.,* **2,** 1691 (1933). [D39649

Trautwein, G., and **Stöber, M.:** Leukämische Mastzellenretikulose beim Rind—Ein Beitrag zum klinischen und histopathologischen Bild der nicht-lymphatischen Leukose des Rindes. *Ztrbl. Vet.-Med.,* (in press). [D97999

Trevan, D. J., and **Sharrock, A.:** A methyl green-pyronin-orange G stain for formalin-fixed tissues. *J. Path. Bact.,* **63,** 326 (1951). [D39525

Trimble, ?.: Urticaria pigmentosa. *J. cutan. Dis.,* **32,** 151 (1914). [E38132

——: Urticaria pigmentosa. *J. cutan. Dis.,* **34,** 405 (1916). [E38135

Trincão, R. de A. C.: Os mastócitos. Alguns aspectos da sua fisiopatologia. *Arch.*

Anat. pat. (Coimbra), **7**, 1 (1953) **8**, 709 (1954). [D26962

Tsuda, S.: Experimentelle Untersuchungen über die entzündliche Reaktion der Subcutis in Beziehung zum individuellen Immunitätszustand. *Virchows Arch. pathol. Anat.,* **247**, 123 (1923). [D27349

Tsusaki, T., Eriguchi, K., and **Kojo, Y.:** Über die basophil granulierten Zellen im Plexus chorioideus partis lateralis ventriculi telencephali. *Yokohama med. Bull.,* **2**, 110 (1951). [D30211

Tuchweber, B.: Interacción de dos complejos de hierro en un sindrome calcifiláctico. *Trib. med. (Bogota),* **3**, 1 (1964). [D57153

——, **Gabbiani, G.,** and **Selye, H.:** Einfluss des Hypophysen-Nebennierenrindensystems auf die durch Hexadimethrin hervorgerufenen Organveränderungen. *Med. Welt. (Stuttg,)* **?**. No. 45, 2272 (1963). [D27884

Tuci, P., and **Cipriani, P. L.:** Angiotropismo degli ormoni gonadotropi: influsso sulle Mastzellen. *Boll. Soc. med.-chir. (Pisa),* **24**, 271 (1956). [C24338

Tuffanelli, D. L.: The response of hairless mice to long-term serotonin administration. *J. invest. Derm.,* **41**, 135 (1963). [E28359

Tuma, V.: De l'histologie de la glande mammaire des rats normaux et avitaminés. *C.R. Ass. Anat.,* **23**, 455 (1928). [D27638

Turchini, J., and **van Kien, L. K.:** L'héparine et les granulations des mastocytes. *Presse méd.,* **61**, 11 (1953). [D26718

——, and ——: Étude des basophiles du sang dans quelques conditions où leur nombre se trouve augmenté *Rev. belge Path.,* **24**, 520 (1955). [D88984

——, and ——: Étude histochimique des basophiles tissulaires après action massive de cortisone. *C.R. Soc. Biol. (Paris),* **149**, 1623 (1955). [D65691

Turin, E.: Blutveränderungen unter dem Einfluss der Schilddrüse und Schilddrüsensubstanz. *Ztschr. Chir.,* **107**, 343 (1910). [34610

Türk, W.: Kritische Bemerkungen über Blutzellenbildung und -benennung. *Folia haemat. (Lpzg.),* **2**, 231 (1905). [G19257

Tusini, G.: Sui rapporti tra cangerogenesi e mastzellen. (Influenza di un trattamento con 48/80 sull'azione tumorigena del benzopirene e sullo sviluppo del cardinoma di Walker). *Boll. Soc. med.-chir. (Pisa),* **23**, 537 (1955). [C11236

Twort, C. C., and **Twort, J. M.:** Classification of four thousand experimental oil and tar skin tumours of mice. *Lancet,* Apr. 19, 1331 (1930). [D26712

Tzanck, A., and **Civatte, J.:** Un cas d'urticaire pigmentaire chez l'adulte. *Bull. Soc. franç. Derm. Syph.,* **56**, 341 (1949). [D39732

Ubukata, A.: An electron microscopical observation of septic granules contained in the cytoplasm of mouse mastocytoma cells. *Med. J. Osaka Univ.,* **14**, 319 (1964). [D18745

Udenfriend, S., and **Weissbach, H.:** Studies on serotonin (5-hydroxytryptamine) in platelets. *Fed. Proc.,* **13**, 312 (1954). [B91942

Ulesco-Stroganowa, K.: Über die Bedeutung des Bindegewebes bei der Krebsentwicklung. *Ztschr. Krebsforschg.,* **25**, 394 (1927). [D28927

Ultmann, J. E., Mutter, R. D., Tannenbaum, M., and **Warner, R. R. P.:** Clinical, cytologic, and biochemical studies in systemic mast cell disease. *Ann. intern. Med.,* **61**, 326 (1964). [G19654

Undritz, E.: Les cellules sanguines de l'homme et dans la série animale. *Schweiz. med. Wchnschr.,* **76**, 88, 115 (1946). [98255

——: Die nicht zur Blutkörperchenbildung gehörenden Zellen intravitaler Knochenmarkspunktate nebst Auszählungsschema für Myelogramme. *Schweiz. med. Wchnschr.,* **76**, 333 (1946). [D30200

——: Anomalies héréditaires des cellules du sang. *Rev. Hémat.,* **5**, 644 (1950). [B56478

Unna, P. G.: *Dermatologische Studien. Beiträge zur Anatomie und Pathogenese der Urticaria simplex und pigmentosa. Zur Kenntnis des elastischen Gewebes der Haut.* Hamburg & Leipzig: Leopold Voss (1887). [D31522

——: Beiträge zur Anatomie und Pathogenese der Urticaria simplex und pigmentosa. *Monatsh. prakt. Derm.,* **6**/3, 9 (1887). [D39515

——: Über Plasmazellen, insbesondere beim Lupus. *Monatsh. prakt. Derm.,* **12**, 296 (1891). [D27089

——: Ueber die Reifung unserer Farbstoffe. *Ztschr. wisschftl. Mikros.,* **8**, 475 (1891). [D28273

——: *Histopathologie der Hautkrankheiten. (Neurofibrom, Urticaria pigmentosa, Miliaria, Syphilide).* Hamburg: Leopold Voss, 1894. [D31523

——: Die spezifische Färbung der Mastzellenkörnung. *Monatsh. prakt. Derm.,* **19**, 367 (1894). [D28274

Upton, A. C., and **Gude, W. D.:** Physiologic and histochemical changes in con-

nective tissue of rat induced by total body irradiation. *A.M.A. Arch. Path.*, **58**, 258 (1954). [C3289

Urbach, F., Bell, W. N., and **Jacobson, C.**: Studies on urticaria pigmentosa: I. Release of a heparinoid material into the circulation following direct stimulation of urticaria pigmentosa lesions. *J. invest. Derm.*, **25**, 211 (1955). [D39716

——, **Jacobson, C.,** and **Bell, W. N.**: Urticaria pigmentosa treated with desoxycorticosterone. *Arch. Derm. Syph. (Chic.)*, **70**, 675 (1954). [D39652

Urist, M. R., and **McLean, F. C.**: Accumulation of mast cells in endosteum of bones of calcium-deficient rats. *A.M.A. Arch. Path.*, **63**, 239 (1957). [D30209

——, and ——: Mast cells in bones. *Surg. Forum*, **7**, 590 (1957). [D14540

Urtubey, L.: Nuevas orientaciones acerca de la significación de los mastocitos (Mixoblastos). *Med. clin. (Barcelona)*, **10**, 95 (1948). [D27059

Uvnäs, B.: The mechanism of histamine liberation. *J. Pharm. Pharmacol.*, **10**, 1 (1958). [D26424

——: Histamine release from mast cells by lecithinases A and C. *J. Pharm. Pharmacol.*, **10**, 336 (1958). [D39577

——: Mechanism of action of a histamine-liberating principle in jellyfish (Cyanea capillata). *Ann. N.Y. Acad. Sci.*, **90**, 751 (1960). [D26479

——: Mechanism of release from mast cells. *Chemotherapia (Basel)*, **3**, 137 (1961). [D25283

——: Mechanism of histamine release. In: *Proceedings of the International Union of Physiological Sciences.* Amsterdam, London, Milan, New York: Excerpta Medica Foundation, Int. Congr. Ser. 47, **1**/1, p. 106 (1962). [D68430

——: Mechanism of histamine release in mast cells. *Ann. N.Y. Acad. Sci.*, **103**, 278 (1963). [D58286

——: Lipid spasmogens appearing in connection with histamine liberation. *Biochem. Pharmacol.*, **12**, 439 (1963). [D64029

——, and **Antonsson, J.**: Triggering action of phosphatidase A and chymotrypsins on degranulation of rat mesentery mast cells. *Biochem. Pharmacol.*, **12**, 867 (1963). [E23517

——, **Diamant B.,** and **Högberg, B.**: Trigger action of phospholipase A on mast cells. *Arch. int. Pharmacodyn.*, **140**, 577 (1962). [D39811

——, ——, ——, and **Thon, I. L.**: Mechanism of mast-cell disruption induced by a principle extracted from Ascaris suis. *Am. J. Physiol.*, **199**, 575 (1960). [D26167

——, and **Thon, I. L.**: Isolation of 'biologically intact' mast cells. *Exp. Cell Res.*, **18**, 512 (1959). [D26067

——, and ——: Evidence for enzymatic histamine release from isolated rat mast cells. *Exp. Cell Res.*, **23**, 45 (1961). [D26478

Valentine, W. N.: Quantitative biochemical studies on leukocytes in man: A review. *Blood*, **6**, 845 (1951). [B61807

——, **Lawrence, J. S., Pearce, M. L.,** and **Beck, W. S.**: The relationship of the basophil to blood histamine in man. *Blood*, **10**, 154 (1955). [D39647

——, **Pearce, M. L.,** and **Lawrence, J. S.**: Studies on the histamine content of blood, with special reference to leukemia, leukemoid reactions and leukocytosis. *Blood*, **5**, 623 (1950). [G18804

Vallesi, R. N.: Il derma del condotto uditivo nelle varie età. *Monit. zool. Ital.*, **65**, sup. 1, p. 367 (1956–57). [D39807

——: Le Mastzellen nelle varie fasi funzionali della ghiandola sottomascellare del ratto. *Monit. zool. Ital.*, sup. 66, 448 (1956-57). [D31597

Vallone, A.: Le 'Mastzellen' dei connettivi nei diversi organi e nei vari processi morbosi dell'uomo. *Arch. De Vecchi Anat. pat.*, **7**, 249 (1944). [D26432

Valtonen, E. J.: The effect of ultra-violet radiation of some spectral wavebands on the mast cell count in the skin. *Acta path. microbiol. scand.*, sup. 151, 1 (1961). [D26623

——, and **Kock, B.**: The effect of hydrocortisone on the mastocytosis produced in mice by short-wavelength ultra-violet radiation. *Acta rheum. scand.*, **9**, 41 (1963). [D66170

Van Arsdel, P. P., *cf.* Ardel, P. P., van. [D26617

Van den Brenk, H.A.S., *cf.* Brenk, H.A.S., van den. [C59465

Van den Hooff, A.: *cf.* Hooff, A. van den. [D61469

Van der Hoop, ?.: *cf.* Hoop, ? van der. [E37992

Vannas, S.: Mast cells in glaucomatous eyes. *Acta ophthal. (Kbh.)*, **37**, 330 (1959). [D26763

Vara, P.: Über die Funktion der Mastzellen im Endometrium und ihre Beteiligung an der Ungerinnbarkeit des Menstrualblutes. *Geburtsh. u. Frauenheilk.*, **22**, 989 (1962). [D39825

Various Authors: Round table discussion on mast cells and basophils. *Ann. N.Y. Acad. Sci.,* **103,** 441 (1963). [D58297
Vasaturo, A.: La mastzellenleucemia. *Studium,* **15,** 172 (1952). [G18741
Vasilenko, A. G., Nogachevskii, I. I., and **Dzis, I. P.:** On the interrelations of autoinfection with leukopenia and connective tissue mast cell reactions in radiation injury. (Russian text) *Med. Radiol.,* **5,** 72 (1960). [D39687
Veil, C.: Etude des labrocytes de l'écaille de poisson. Action d'un libérateur d'histamine (composé 48–80) et variations saisonnières. *J. Physiol. (Paris),* **48,** 736 (1956). [E24154
——: Contribution à la physiologie des labrocytes des écailles de poisson mise en évidence de réactions anaphylactiques et comportement en présence d'un libérateur d'histamine. *Acta physiol. pharmacol. neerl.,* **6,** 386 (1957). [E62531
——, and **Denèfle, J. P.:** Le cycle des mastocytes chez un Cyprinidé. *J. Physiol. (Paris),* **55,** 365 (1963). [D66476
——, and **Gabe, M.:** Action des injections de sérum de cheval sur les héparinocytes de l'écaille chez la carpe. *C.R. Soc. Biol. (Paris),* **144,** 1633 (1950). [D33689
——, and **Quivy, D.:** Sur la présence d'héparine dans les écailles de Cyprinus carpio. *C.R. Soc. Biol. (Paris),* **144,** 1483 (1950). [D10146
Veilleux, R.: Rôle de la réaction anaphylactoïde dans un syndrôme calcifiant expérimental. *Rev. Canad. Biol.,* **22,** 15 (1963). [D27369
——: Anaphylactoid oedema produced in rats by certain dextrins. *Brit. J. Pharmacol.,* **21,** 235 (1963). [D20584
——: Rôle du fer dans une réaction anaphylactoïde calcifiante. *Acta histochem. (Jena),* **17,** 343 (1964). [D55007
Velican, C., and **Velican, D.:** Sur les inclusion minérales des mastocytes. *Nouv. Rev. franc. Hémat.,* **29,** 717 (1958). [D20431
——, and ——: Observations sur le noyau des mastocytes. *Nouv. Rev. franc. Hémat.,* **29,** 708 (1958). [D20112
——, and ——: Histochemical investigations on the presence of hyaluronic acid in mast cells. *Acta haemat. (Basel),* **21,** 109 (1959). [D27405
——, and ——: Recherches histochimiques sur la mastocytogénèse expérimentale. *Ann. Histochim.,* **7,** 91 (1962). [D34404
Vercauteren, R.: The properties of the isolated granules from blood eosinophiles. *Enzymologia,* **16,** 1 (1953). [D27722
Verga, V., and **Pezzani, M.:** Modificazioni delle Mastzellen dopo trattamento röntgen in alcuni organi emolinfopoietici (timo, linfoghiandole e milza). Ricerche sperimentali sul ratto albino. *Rediconto Atti Accad. sci. med. (Napoli),* **113,** 3 (1959). [C83626
——, and ——: Le Mastzellen delle linfoghiandole mesenteriche del ratto dopo trattamento röntgen. *Riv. Ist. siertoer. ital.,* **34,** 270 (1959). [C79437
Vezzini, A.: Modificazioni quantitative e morfologiche delle 'Mastzellen' di ratti variamente alimentati. *Monit. zool. ital.,* **44,** 270 (1933). [D39606
Viale del Carril, A., et al. *cf.* Carril, A. V. del et al. [G16997
Vidal, B. de C.: Histochemistry of the dental granuloma. *Ann. Histochim.,* **8,** 35 (1963). [E22485
Vilanova, X., Castillo, R., and **Aguade, J. P.:** Mastocytosis with coagulation defects induced by biopsy. *A.M.A. Arch. Derm.,* **84,** 603 (1961). [D26651
Villavicencio, J. L., and **Takats, G. de:** Mast cell activity under various forms of stress. *Surgery,* **44,** 312 (1958). [C56397
Vimeux, J.: Métachromasie du liquide folliculaire. *C.R. Soc. Biol. (Paris),* **146,** 1918 (1952). [D33732
Viñals, R. R. de: Les 'Mastzellen' dans le cancer expérimental de la souris blanche. *C.R. Soc. Biol. (Paris),* **108,** 177 (1931). [D13202
——: Celulas cebadas tisulares (heparinocitos) en los organos hematopoyeticos. *Folia clin. int. (Barcelona),* **4,** 471 (1954). [D30196
Vincentiis, I. de and **Bernicchi, L.:** Le Mastzellen nelle rinopatie allergiche. *Riv. Biol.,* **50,** 77 (1958). [C68645
Vinyals, R. R. de: *cf.* Viñals, R. R. de. [D13202
Vogel, M.: The femoral bone marrow cells of the albino rat. *Am. J. med. Sci.,* **213,** 456 (1947). [B3641
von Marschalkó, T.: *cf.* Marschalkó, T. von [D31616
von Möllendorff, W.: *cf.* Möllendorff, W. von [B78338
von Numers, C., *cf.* Numers, C. von. [D26635 [D67345
von Recklinghausen, F.: *cf.* Recklinghausen, F. von. [D29297
Vörner, H.: Ein Fall von Urticaria pigmentosa maculosa. *Dermat. Ztschr.,* **13,** 274 (1906). [G1238
Voutsa, N., Beveridge, G. C., and **Foraker, A. G.:** The uterine cervix at term: Glycogen,

mast cells, and connective-tissue elements. *Obstet. and Gynec.,* **22,** 108 (1963). [D69713

Wachstein, M.: Alkaline phosphatase activity in normal and abnormal blood and bone marrow cells. *J. Lab. clin. Med.,* **31,** 1 (1946). [G18688

Wada, Y., Tamura, J., Tomita, Y., and **Yamada, M.:** Relation between mast cells and tumor cells in ascites hepatoma and Takeda sarcoma. *Gann,* **46,** 397 (1955). [D6659

Waldeyer, W.: Ueber Bindegewebszellen. *Arch. mikros. Anat.,* **11,** 176 (1875). [A6120

——: Ueber Bindegewebszellen. *Sitzgber. Preuss. Akad. Wisschft.,* P75 (1895). [D27091

Walker, B. E.: Mast cell turnover in adult mice. *Nature (Lond.),* **192,** 980 (1961). [D27899

——: Effect of thymectomy on mast cells in mice. *Proc. Soc. exp. Biol. (N.Y.),* **115,** 1028 (1964). [F9506

——: Mast cells, thymectomy and tumor rejection in dystrophic mice. *Tex. Rep. Biol. Med.,* **22,** 640 (1964). [D19393

——, and **O'Steen, W. K.:** Proliferation of mast cells in normal and dystrophic mice. *Proc. Soc. exp. Biol. (N.Y.),* **113,** 183 (1963). [D66467

Walker, J.: A case of widespread urticaria pigmentosa with episodes of flushing. *S. Afr. med. J.,* **34,** 348 (1960). [C91546

Walton, K. W.: Investigation of the toxicity of a series of dextran sulphates of varying molecular weight. *Brit. J. Pharmacol.,* **9,** 1 (1954). [G21527

Warin, R. P.: Histamine antagonist therapy in dermatology. *Brit. J. Derm.,* **62,** 159 (1950). [D30600

——, and **Hughes, R. C. W.:** Diffuse cutaneous mastocytosis. *Brit. J. Derm.,* **75,** 296 (1963). [E23545

Watanabe, N.: The role of plasmin in the mechanism of allergy. (Japanese text) *Jap. J. Allergy (Tokyo),* **11,** 170 (1962). [E48030

Waters, L. L.: The effect of vascularization on lipid-connective tissue reactions in the cornea. *Circulation,* **14,** 487 (1956). [D27068

Waters, W. J., and **Lacson, P. S.:** Mast cell leukemia presenting as urticaria pigmentosa. *Pediatrics,* **19,** 1033 (1957). [D39669

Watson, W. C.: The role of the tissue mast cell in experimental atherosclerosis. *Brit. J. exp. Path.,* **39,** 540 (1958). [C59777

——: Hypercholesterolaemia, coronary lipidosis and the tissue mast cell. *Brit. J. exp. Path.,* **42,** 15 (1961). [D26643

——, and **Kennedy, J. S.:** Regeneration of the tissue mast cell: an autoradiographic study. *Brit. J. exp. Path.,* **41,** 385 (1960). [D26562

Webb, R. L.: Peritoneal reactions in the white rat, with especial reference to the mast cells. *Amer. J. Anat.,* **49,** 283 (1931). [D27897

——: Changes in the number of cells within the peritoneal fluid of the white rat, between birth and sexual maturity. *Folia haemat.,* **51,** 445 (1934). [D26822

——: Numerical changes of mast cells within the dermis of the white rat. *Anat. Rec.,* **64,** 55 (1935). [D30627

Wegelius, O.: The content of mast cells in the pleural membranes, pericardium and liver capsule of cattle and horse. *Acta physiol. scand.,* **35,** 365 (1956). [D67713

——, and **Asboe-Hansen, G.:** Hormonal effects on mast cells. Studies of living connective tissue in the hamster cheek pouch. *Acta endocr. (Kbh.),* **22,** 157 (1956). [C18789

——, and ——: Mast cells and tissue water. Studies on living connective tissue in the hamster cheek pouch. *Exp. Cell Res.,* **11,** 437 (1956). [C29551

——, and **Hjelmman, G.:** Vital staining of mast cells and fibrocytes. *Acta path. microbiol. scand.,* **36,** 304 (1955). [C10599

——, ——, and **Wasastjerna, C.:** Morphological changes caused by anti-hamster serum in the mast cells of the hamster. *Acta path. microbiol. scand.,* **36,** 309 (1955). [D27732

——, and **Wahlberg, P.:** Early cardiac connective tissue changes in scleroderma. Report of a case. *Acta med. scand.,* **156,** 487 (1957). [D63170

Weidenreich, F.: Ueber die zelligen Elemente der Lymphe und der serösen Höhlen. *Verhandl. anat. Gesellsch. (Jena), 21st Meet. Würzburg Apr. 1907,* p. 51 (1907). [D33716

——: Zur Kenntnis der Zellen mit basophilen Granulationen im Blut und Bindegewebe. *Folia haemat.,* **5,** 135 (1908). [D27422

——: Die Thymus des erwachsenen Menschen als Bildungsstätte ungranulierter und granulierter Leukozyten. *Münch. med. Wchnschr.,* **59,** 2601 (1912). [A25630

Weidman, A. I., and **Franks, A. G.:** Hodgkin's disease concurrent with urticaria pigmentosa. *A.M.A. Arch. Derm.,* **88,** 167 (1963). [E22563

Weill, P.: Über die Bildung von Leukozyten in der menschlichen und tierischen Thymus des erwachsenen Organismus. *Arch. mikros. Anat.,* **83,** 305 (1913). [A1826

——: Mastzellenstudien an Sarkommetastasen. *Folia haemat.,* **23,** 185 (1919). [D26215

——: Über die Bildung von granulierten Leukozyten im Karzinomgewebe. *Virchows Arch. pathol. Anat.,* **226,** 212 (1919). [D27097

——: Über die leukocytären Elemente der Darmschleimhaut der Säugetiere. Ein Beitrag zur Beurteilung der Granulationen in Leukocyten. *Arch. mikros. Anat.,* **93,** 1 (1920). [D27707

Weimar, V. L.: The sources of fibroblasts in corneal wound repair. A quantitative analysis. *A.M.A. Arch. Ophthal.,* **60,** 93 (1958). [C71862

Weiss, ?.: Mastzellenleukose beim Hund. *Ztrbl. allg. Pathol. pathol. Anat.,* **97,** 97 (1957). [G17190

Weissbach, H., Lovenberg, W., and **Udenfriend, S.:** Characteristics of mammalian histidine decarboxylating enzymes. *Biochim. biophys. Acta (Amst.),* **50,** 177 (1961). [D33695

——, **Waalkes, T. P.,** and **Udenfriend, S.:** A simplified method for measuring serotonin in tissues; simultaneous assay of both serotonin and histamine. *J. biol. Chem.,* **230,** 865 (1958). [C50586

Wells, P. D.: Mast cell, eosinophil and histamine levels in Nippostrongylus brasiliensis infected rats. *Exp. Parasit.,* **12,** 82 (1962). [D63160

Welsh, R. A., and **Geer, J. C.:** Phagocytosis of mast cell granule by the eosinophilic leukocyte in the rat. *Amer. J. Path.,* **35,** 103 (1959). [D39505

Werle, E., and **Amann, R.:** Ueber eine Bindung des Histamins an Heparin. *Naturwschft.,* **42,** 583 (1955). [D26786

——, and ——: Zur Physiologie der Mastzellen als Träger des Heparins und Histamins. *Klin. Wchnschr.,* **34,** 624 (1956). [C18291

——, **Schauer, A.,** and **Bühler, H. W.:** Klassifizierung histidindecarboxylierender Gewebs- und Bakterienenzyme. *Arch. int. Pharmacodyn.,* **145,** 198 (1963). [E28902

Wermel, E., and **Sassuchin, D.:** Untersuchungen über die Kernsubstanzen und die Methoden ihrer Darstellung. II. Mitteilung: Über die Natur des Volutins und der Mastzellen-Granula. *Ztschr. Zellforschg. mikros. Anat.,* **6,** 424 (1928). [D39520

West, G. B.: Histamine in mast cell granules. *J. Pharm. Pharmacol.,* **7,** 80 (1955). [D31552

——: Histamine and mast cells. In: *Histamine. Ciba Foundation Symposium.* London: J. & A. Churchill Ltd., p. 14 (1956). [C19992

——: 5-Hydroxytryptamine, tissue mast cells and skin oedema. *Int. Arch. Allergy,* **10,** 257 (1957). [C45485

——: Pharmacology of the tissue mast cell. *Brit. J. Dermat.,* **70,** 409 (1958). [C64139

——: Tissue mast cells and tissue amines. *J. Pharm. Pharmacol.,* **11,** 513 (1959). [D65259

——: Function of mast-cells. *J. Pharm. Pharmacol.,* **14,** 618 (1962). [D33712

——: Mast-cells and anaphylaxis. *Lancet,* June 13, 1332 (1964). [F13144

——, and **Parratt, J. R.:** 5-Hydroxytryptamine and the skin. *A.M.A. Arch. Derm.,* **76,** 336 (1957). [C45206

Westberg, F.: Ein Fall von mit weissen Flecken einhergehender, bisher nicht bekannter Dermatose. *Monatschr. prakt. Dermat.,* **33,** 355 (1901). [C97252

Westerholm, R.: The influence of anoxia on 48/80–induced histamine release from cat skin. *Acta physiol. scand.,* **50,** 300 (1960). [D65672

Westin, B.: The influence of some ovarian hormones on the occurrence of mast cells in the mouse uterus. *Acta path. et microbiol. scand.,* **36,** 337 (1955). [C11073

——: The occurrence of mast cells in the mouse vagina in prolonged oestrogenic treatment. *Exp. Cell Res.,* **10,** 558 (1956). [C23800

——, and **Odeblad, E.:** The acute influence of some ovarian hormones on the occurrence of mast cells in the mouse vagina. *Acta path. microbiol. scand.,* **39,** 81 (1956). [C22791

Westphal, A. K. O.: Über Mastzellen. *Thesis, University of Frankfurt* (1880). [A8394

Wexler, B. C.: Myocardial mast cell changes in arteriosclerotic rats. *A.M.A. Arch. Path.,* **78,** 46 (1964). [D45267

White, R. G., Jenkins, G. C., and **Wilkinson, P. C.:** The production of skin-sensitizing antibody in the guinea-pig. *Int. Arch. Allergy,* **22,** 156 (1963). [E22503

Whitehouse, ?.: Urticaria pigmentosa. *J. cutan. Dis.,* **33,** 855 (1915). [E37991

——: Urticaria pigmentosa. *J. cutan. Dis.*, **34**, 767 (1916). [E38150

Wichmann, B. E.: The mast cell count during the process of wound healing. An experimental investigation on rats. *Acta path. microbiol. scand.*, sup. 108, 1 (1955). [D11765

Wiedmann, A.: Das Verhalten des neurohormonalen Systems der Haut beim Ekzem. *Ztschr. Haut- u. Geschl. Krht.*, **24**, 34 (1960). [C99174

——: Über das neurohormonale System der Haut. *Hautarzt*, **14**, 60 (1963). [D60447

——: Über die Struktur des neurovegetativen Systems. *Hautarzt*, **15**, 13 (1964). [F814

——, and **Niebauer, G.**: Die Beeinflussung der chronisch-ekzematösen Reaktion durch die Neurosekretion der Haut. *Hautarzt*, **10**, 16 (1959). [C67755

Wilander, O.: Studien über Heparin. *Skand. Arch. Physiol.*, **81**, sup. 15 (1938). [D29595

Wilke, J.: Über das Verhalten von Plasmazellen und Mastzellen in den metastasefreien Halslymphknoten beim Kehlkopfcarcinom. *Arch. Ohren-, Nasen-, u. Kehlk. Heilk.*, **181**, 458 (1963). [E38744

Williams, G. T.: Tissue mast cells in human bone marrow. *Amer. J. clin. Path.*, **22**, 1039 (1952). [D27399

Williams, H. U.: A critical summary of recent literature on plasma-cells and mast-cells. *Amer. J. med. Sci.*, **119**, 702 (1900). [D27891

Williams, W. J., Larsson, E., and **Phillips, T. L.**: A neoplastic connective tissue mast cell capable of continuous growth tissue culture. *J. biophys. biochem. Cytol.*, **6**, 361 (1959). [D26619

Wimsatt, W. A.: Cytochemical observations on the fetal membranes and placenta of the bat, myotis lucifugus. *Amer. J. Anat.*, **84**, 63 (1949). [D27404

Windrum, G. M.: The histochemical demonstration of hyaluronic acid. *A.M.A. Arch. Path.*, **65**, 513 (1958). [D33686

Winer, L. H., Bierman, S. M., and **Sternberg, T. H.**: Observations of acid mucopolysaccharide and mast cells in the skin of hairless mice following the topical application of estrone and pregnenolone. *J. invest. Derm.*, **41**, 141 (1963). [D32027

Winkelmann, R. K.: Orthochromatic, species-limited staining of mast cells with night blue. *Stain Technol.*, **34**, 227 (1959). [D33685

——: Histochemical aspects of the affinity of mast cell granules for night blue. *Stain Technol.*, **34**, 321 (1959). [C77749

Winqvist, G.: The ultrastructure of the granules of the basophil granulocyte. *Ztschr. Zellforschg.*, **52**, 475 (1960). [E43466

——: Experimental production of basophil granulocytes in guinea-pig. *Exp. Cell Res.*, **19**, 7 (1960). [D39532

——: Electron microscopy of the basophilic granulocyte. *Ann. N.Y. Acad. Sci.*, **103**, 352 (1963). [D58291

Wise, ?.: Urticaria pigmentosa. *J. cutan. Dis.*, **37**, 132 (1919). [E38011

——: Urticaria pigmentosa. *J. cutan. Dis.*, **37**, 360 (1919). [E38013

——: Urticaria pigmentosa. *A.M.A. Arch. Derm. Syph. (Chic.)*, **3**, 325 (1921). [E37985

Wise, F.: Urticaria pigmentosa. *A.M.A. Arch. Derm. Syph. (Chic.)*, **1**, 223 (1920). [E37993

Wislocki, G. B., Bunting, H., and **Dempsey, E. W.**: Metachromasia in mammalian tissues and its relationship to mucopolysaccharides. *Amer. J. Anat.*, **81**, 1 (1947). [D26750

——, and **Dempsey, E. W.**: Observations on the chemical cytology of normal blood and hemopoietic tissues. *Anat. Rec.*, **96**, 249 (1946). [D27437

——, and ——: The chemical histology of the human placenta and decidua with reference to mucopolysaccharides, glycogen, lipids and acid phosphatase. *Amer. J. Anat.*, **83**, 1 (1948). [D26759

——, and **Fawcett, D. W.**: Some histochemical properties of mast cells and tissue eosinophils in stained spreads of normal rat mesentery. *J. nat. Cancer Inst.*, **12**, 258 (1951). [D30373

——, **Rheingold, J. J.**, and **Dempsey, E. W.**: The occurrence of the periodic acid-Schiff reaction in various normal cells of blood and connective tissue. *Blood*, **4**, 562 (1949). [D28970

Witthaus, G.: Bestimmung freier Nukleotide im Mastocytom P–815. *Med. exp. (Basel)*, **9**, 416 (1963). [E38878

Woglom, W. H.: Experimental tar cancer. *Arch. Path. Lab. Med.*, **2**, 533, 709 (1926). [D26714

Wolff, A.: Ueber Mastzellen in Exsudaten. Ein Beitrag zur Frage der aktiven Lymphocytose. *Münch. med. Wchnschr.*, **49**, 226 (1902). [D27718

——: Über Leukocytengranulationen (speziell über Azurgranula und über Pseudo-

mastzellengranula). *Ztschr. klin. Med.*, **52**, 114 (1903). [E48694
——: Zur Genese der Mastzellen. *Dtsch. med. Wchnschr.*, **30**, 114 (1904). [D27646
——: Kurze Bemerkung zu meiner Arbeit: 'Ueber Leukocytengranulationen'. *Ztschr. klin. Med.*, **52**, 556 (1904). [G17715
Wolf-Jürgensen, P.: Cytological examination of experimental contact allergy using the skin window technique. *Acta allergol. (Kbh.)*, **17**, 547 (1962). [G17220
Wöringer, F.: Mastocytes et pigmentation cutanée. *Bull. Soc. franç. Derm. Syph.*, **62**, 31 (1955). [D26819
——, and **Bendoraitis, F. V.**: Urticaire pigmentaire. *Bull. Soc. franç. Derm. Syph.*, **59**, 529 (1949). [D39733
Worthington, W. C., and **Bailey, N. C.**: Dual staining of mast-cell cytoplasmic constituents by alcian blue and safranin. *J. Histochem. Cytochem.*, **10**, 503 (1962). [D14170
Yakovleva, A. I., *cf.* Iakovleva, A. I. [D25508
Yamasaki, H., and **Kawamoto, S.**: Effects of peptone, sinomenine, polyvinylpyrrolidone and the extract of corbicula on the tissue mast cells in dogs. (Japanese text) *Folia pharmacol. jap.*, **53**, 75 (1957). [D31596
——, **Kuroda, A., Kamimura, Y., Tasaka, K., Sanuki, K., Nishiyama, R., Kume, M.**, and **Kawamoto, S.**: Studies on the histamine release by chemical substances. In: *Proc. 14th Japan. Med. Congr. Kyoto, April 1955.* **II**, 60 (1955). [C21613
Yamura, T.: Histone shock and the relation between histone and plasmin. *Acta med. Nagasaki*, **6**, 20 (1961). [D39162
——, and **Watanabe, N.**: Histamine release from isolated rat mast cells by adding plasmin. *Acta med. Nagasaki*, **5**, 142 (1961). [D58429
Yanagihara, K.: The parallel change of circulating eosinophils and basophils in the rabbit with insulin administration. *Bull. Inst. Public Health*, **7**, 14 (1958). [C58484
Young, P. R., and **Kimura, E. T.**: Studies with low and high molecular weights of hexadimethrine bromide. *Fed. Proc.*, **21**, 60 (1962). [G6599
Zachariae, F.; **Asboe-Hansen, G.**, and **Boseila, A. A.**: Studies on the mechanism of ovulation. Migration of basophil leucocytes from blood to genital organs at ovulation in the rabbit. *Acta endocr. (Kbh.)*, **28**, 547 (1958). [C57334
——, and **Jensen, C. E.**: Studies on the mechanism of ovulation. Histochemical and physico-chemical investigations on genuine follicular fluids. *Acta endocr. (Kbh.)*, **27**, 343 (1958). [C48660
Zachariae, H.: Skin histamine in urticaria pigmentosa. Spectrolfluorometric assay. *Acta derm.-venereol. (Stockh.)*, **43**, 125 (1963). [D69687
——: Histamine and mast cells in human fetal skin. *Proc. Soc. exp. Biol. (N.Y.)*, **117**, 63 (1964). [F10412
——: Histamine in a transplantable mouse mastocytoma. *Proc. Soc. exp. Biol. (N.Y.)*, **117**, 283 (1964). [F10402
Zachariae, L., and **Moltke, E.**: Influence of hydrocortisone (Compound F) on mast cells of normal skin and healing wounds in the rabbit. *Acta endocr. (Kbh.)*, **16**, 300 (1954). [D26761
Zackheim, H. S.: Urticaria pigmentosa with mast cell tumor. *A.M.A. Arch. Derm.*, **75**, 140 (1957). [D39653
Zahl, P. A., and **Nowak, A.**: A rapid technic for demonstrating mast cells in mouse skin. *Stain Technol.*, **24**, 185 (1949). [D72190
Zak, F. G., Covey, A. J., and **Snodgrass, J. J.**: Osseous lesions in urticaria pigmentosa. *New Engl. J. Med.*, **256**, 56 (1957). [D27410
Zakon, S. J., Gruhn, J. G., and **Biava, C.**: Urticaria pigmentosa. *A.M.A. Arch. Derm.*, **87**, 662 (1963). [D65525
Zakrzewski, Z.: Untersuchungen über den Einfluss von Heparin auf das Wachstum der Sarkomzellen in vitro. *Ztschr. Krebsforschg.*, **36**, 513 (1932). [D31586
Zbinden, G.: Biochemische, funktionelle und morphologische Organveränderungen durch Beeinflussung des 5-Hydroxytryptamin-Stoffwechsels. *Ergebn. allg. Pathol. pathol. Anat.*, **39**, 225 (1960). [D501
Zeisler, E. P.: Urticaria pigmentosa. *J. cutan. Dis.*, **37**, 69 (1919). [E38010
Zemplényi, T., Fodor, J., and **Lojda, Z.**: Mast cell histamine and the accumulation of colloid particles in the vascular endothelium. *Quart. J. exp. Physiol.* **45**, 50 (1960). [D27057
Zeppa, R., and **Hemingway, G. G.**: Inhibition of histamine release from mast cells. *Surg. Forum*, **14**, 56 (1963). [E39862
——, **Williams, H.**, and **Womack, N. A.**: Histamine release by gastrin. *Clin. Res.*, **12**, 215 (1964). [F14725
Ziegler, K.: Histologische Untersuchungen über das Oedem der Haut und des Unterhautzellgewebes. *Beitr. pathol. Anat.*, **36**, 436 (1904). [D26838
Ziliotto, C., and **Pellegrini, N.**: Sul comportamento delle Mastzellen in alcune forme

di iperplasie del sistema reticoloendoteliale delle linfoghiandole. *Riv. Anat. pat.,* **11,** 389 (1956). [D27056

Ziliotto, G., and **Pellegrini, N.:** Le mastzellen in alcune alterazioni endocrine della ghiandola tiroide. *Riv. Anat. pat.,* **11,** 903 (1956). [D12772

Zimmermann, A.: Über das Vorkommen der Mastzellen beim Meerschweinchen. *Arch. mikros. Anat.,* **72,** 662 (1908). [D27591

Zitcer, E. M., Elsasser, W., and **Kirk, P. L.:** Cultivation and morphology of human tissue mast cells in vitro. *Growth,* **17,** 111 (1953). [D26964

——, and **Kirk, P. L.:** The effect of serum ultrafiltrate on cultivated mast cells and fibroblasts from human skin. *Science,* **119,** 99 (1954). [D26428

Zollinger, H. U.: Gewebsmastzellen und Heparin (Phasenmikroskopische Untersuchung). *Experientia (Basel),* **6,** 384 (1950). [D10328

Zollinger, R.: Über das Vorkommen von Gewebemastzellen in Iris und Ziliarkörper. *Ophthalmologica (Basel),* **117,** 249 (1949). [D26862

Zotta, G.: Les leucocytes du sang de Carausius morosus. Les mastocytes. *C.R. Soc. Biol.,* **87,** 298 (1922). [D27503

Zwillenberg, L. O.: The dendritic cell system and mast cells in non-epidermal stratified squamous epithelium. *Nature (Lond.),* **181,** 1343 (1958). [D42931

INDEX

Index

SINCE the entire book deals with Mast Cells (MC), it would defeat the purpose of this index were we to place "MC" constantly as the first keyword. Therefore, entries are indexed in the alphabetic order of the factors concerned with the mast cells. The same procedure is adopted in dealing with the Basophils. When a "target" A is influenced by an agent B, this is indicated by an arrow pointing from B to A thus: $A \leftarrow B$ or $B \rightarrow A$. Interrelations between A and B are indexed thus: $A \leftrightarrows B$. If two stimuli (B and C) act upon the same target (A), this is indexed thus: $B \rightarrow A \leftarrow C$. Boldface numerals (e.g., **17**) refer to principal discussions of a subject.

Accessory sex organs, female, MCs, 93, 113
  male, MCs, 93, 117
Acetone → MC, 148
Achromycin → MC, 148
ACTH → Basophils, 338
  → MC, 133
Adiposity, in mouse, 300
Adrenalectomy
  → MC, 134
    ← chemical agents, 136
    ← hormones, 134
    ← physical agents, 136
Adrenaline; *cf. also* Catecholamines
  → MC, 137
Adrenals, MCs, 92, 110
Adrenocorticotrophic hormone; *cf.* ACTH
Agar-agar → MC, 148
Age → Basophils, 346
  → MC, 240, 402
Aleuronat → MC, 148
Allergy → Basophils, 342, 354, 357
  → MC, **225**
Allicin → MC, 148
Alloxan → MC, 143
Aluminum dextran → MC, 148
Amino-caproic acid → MC, 148
Amitosis, mitosis, 84
Ammonium hydroxide → MC, 148
  oxalate → MC, 148
Amphibia, MCs, 125
Amyloid ← MC, 329
Anaphylactoid inflammation, 3
  calcifying (systemic mastocalciphylaxis), *Fig. 12*
  ← Cyproheptadine, *Fig. 8*
  ⇆ MC, 3, 160, 379
Anaphylaxis
  ← MC, 378
    ← Compound 48/80, 163
Anaphylotoxin → MC, 148
Androgens; *cf.* Testoids
Antibiotics → MC, 149
Antihistamine liberators → MC, 149
Antihistaminics
  → MC, 149
    ← Compound 48/80, 163
Antimitotics → MC, 150
Antimony dextran → MC, 150
Arsenic → MC, 150
Arteritis, obliterating, 287
Arteriosclerosis, 285
  in rat, 300
  → MC, 386, 387
Articulations; *cf.* Joints
Asbestos → MC, 150
Asthma → Basophils, 354
Atherosclerosis; *cf.* Arteriosclerosis
ATP, 328
Atropine → MC, 150
Aureomycin → MC, 150
Autoradiographic techniques, 54

Bacitracin → MC, 150
Bacteria, bacterial toxins → MC, 150, 204
Basophils, **331**
  agents influencing, 337
  in guinea-pig bone marrow, *Fig. 24*
  ⇆ MC, 357, **359**
"Basophilic bone granules", MCs, in osteomyelosclerosis, *Fig. 20*
Basophilic leukemia, **346**
  agents influencing, 350
  in animals, 355
Basophilic myelocyte in mitosis, *Figs. 25, 26, 27*
Benadryl → MC, 151
Benzene → MC, 151

Biochemistry, **301**
of basophils, 355
Birds, MCs, 126
Blood basophil; *cf.* Basophils
Blood clots → MC, 151
Blood dyscrasias, 290
→ Basophils, 352
Blood pressure ← MC, 386
Blood vessels ← MC, 385, 386
Bone, MCs, 92, 108
Bone marrow, MCs, 91, 106

Calcergy, 393, 396, *Fig. 28*
→ MC, 5, 145
← Compound 48/80, 164
← Polymyxin, 207
Calcified granules ← Ferric oxysaccharate + Polymyxin, *Fig. 14*
Calcifying anaphylactoid inflammation (systemic mastocalciphylaxis), *Fig. 12*
Calciphylaxis → MC, 5, 145, 372, 393, 394, *Fig. 28*
(cutaneous) ← Compound 48/80, *Figs. 9, 11*
← Histamine liberators, *Figs. 9, 11*
← Topical trauma, *Fig. 10*
→ MC ← Compound 48/80, 163
← Polymyxin, 206
Calcium, 329
metabolism, theories, 393
→ MC, 237
⇆ MC, 393, 397
Cantharidin → MC, 152
Capillary permeability ← MC, 386
Carbon tetrachloride → MC, 152
Carboxymethylcellulose → MC, 152
Carcinogens → MC, 152
Carcinoids, 297
Carcinolytics → MC, 156
Cardiovascular diseases, 285
system, MCs, 92, 108
Cartilage; *cf.* Bone
Catecholamines, theories, 369
Cell proliferation ← MC, 392
Cellule mastlipoidi, 22
Cerebrosides, 328
Chemical agents → MC ← adrenalectomy, 136
Chlorpromazine → MC, 156
Cholesterol → MC, 156
Chondroitin sulfate → MC, 156, 329
Chromaffin MCs, 23, 60, *Fig. 4*
Chromium → MC, 156
Cinematographic observation, 69; *cf. also* Phase-contrast microscopy
Classification, basophilic leukemia, 347
of basophils, 332
MCs, 17
Mastocytoses, 249
Colchicine → MC, 156
Colitis, ulcerative, 288
Collagenoses, 297
Colloids → MC, 157
Comparative anatomy, **123**
basophils, 335
Compound 48/80, heparin liberation, 162
histamine liberation, 161
structure, 145
→ Anaphylactoid inflammation
← mepyramine, 160
→ Basophils, 341
→ Calciphylaxis, *Fig. 10*
→ MC, 157
← Antihistaminics, 163
← Calcergy, 164
← Calciphylaxis, 163, *Fig. 9*
← Immunity, anaphylaxis, 163
← Ink fixation, *Fig. 3*
Compound 1935L → MC, 165
Connective tissue ← MC, 372
Croton → MC, 165
Cyanides → MC, 165
Cycle → Basophils, 346
Cycle → MC, 401
Cyclic changes → Basophils, 345
→ MC, 239
Cyclizine → MC, 166
Cyproheptadine → Anaphylactoid inflammation, *Fig. 8*
→ MC, 166
Cysteic acid, 329

Decamethylene diamine → MC, 166
Decylamine → MC, 166
Defense phenomena ← MC, 383
Definition of MC, 11
Degranulation, 64, 71, 73, *Fig. 7*
⇆ Edema formation, 72
Dermatoses, 283
→ Basophils, 352
Dextran → MC, 166
Dextrin → MC, 169
Diabetes, 293
→ Basophils, 354
Diagnosis, basophilic leukemia, 349
Mastocytoses, 267
Dicumarol → MC, 169
Diet → Basophils, 345
→ MC, 236

Diethylaminoleate → MC, 169
Digestive tract; *cf.* Gastrointestinal system
Diseases, **247**
→ Basophils, 351
→ MC, 281
Distribution of MCs, 90
Diurnal variations → Basophils, 345
DOPA, 329
→ MC, 170
Drugs → Basophils, 341
→ MC, **144**, 219
Dyes → MC, 170

Edema ⇆ MC, 72, 385, 386
Egg white → MC, 170
Electron-microscopy, 57, 334
Embryology, **121**
basophils, 335
"Emergency kit" hypothesis, 6
Emulsifiers → MC, 170
Endocrine diseases, 293
Endocrines ← MC, 399
Endomyocardial fibrosis, 287
Enzymes, in MCs, **325**
→ MC, 171
⇆ MC, 400
Eosinophils, in guinea-pig bone marrow, *Fig. 24*
⇆ MC, 357, **364**
Epithelium, MCs, 90, 93
Ergot → MC, 174
Ethanol → MC, 174
Ethanolamine → MC, 174
Ether → MC, 174
Ethionine → MC, 174
Eye; *cf. also* Ocular
MCs, 97

Fat metabolism ⇆ MC, 6
Ferric dextran → MC, 174, 179
Ferric dextrin → MC, 179
Ferric oxysaccharate
→ MC, 181
← Polymyxin, *Fig. 14*
Ferric sorbitol → MC, 181
Fibrillogenesis ← MC, 373
Fibrosis, endomyocardial, 287
Fish, MCs, 125
Fixation, 25
Fluorenylacetamide → MC, 181
Fluorescence microscopy, 67
Folliculoids → Basophils, 339
→ MC, 140
Formaldehyde → MC, 181
Gastric secretion ⇆ MC, 6, 400
Gastrointestinal diseases, 288
system, MCs, 91, 99
Gelatin → MC, 183
Genetic factors; *cf.* Heredity
Gingivitis, 291
Globulin → MC, 183
Glucocorticoids → Basophils, 338
→ MC, 137
Glucosamine → MC, 183
Glucose → MC, 183
Glycogen → MC, 184
Goldthioglucose → MC, 184
Gonadotrophic hormones; *cf.* GTH
Gravity → MC, 219
Ground substance, theories, 374
Growth ← MC, 392
Growth hormone; *cf.* STH
GTH → MC, 134

Hair growth ← MC, 391
Head, MCs, 91, 95
Hemoglobin → MC, 184
Hemopoiesis ⇆ MC, 401
Hemorrhage → MC, 219
Heparin, in MCs, 301
theories, 365
→ Basophils, 341, 356
→ MC, 4, 184, 301
Hepatic diseases → Basophils, 354
Heptamethylene diamine → MC, 186
Heredity → MC, 245
Hexadimethrine → MC, 186
Hexosamine, 329
Hibernation → Basophils, 345
→ MC, 244, 402
Histamine, in MCs, **309**
discharge of MCs; *cf.* Degranulation
theories, 366
→ Basophils, 356
→ MC, 4, 187
→ Sympathetic nerves ← Lead acetate, *Figs. 17, 18*
→ Vagus calcification ← Lead acetate, *Fig. 16*
liberators, 145, 191
→ Calciphylaxis, *Figs. 9, 11*
releasers, 145, 191
Histiocytoid MCs, 24
Histochemistry, **45**
basophils, 334
Histology, basophils, 332
MC, **16**
Histone → MC, 193
Histophysiology, 71

History of MC, **1**
Hormones → Basophils, 338
→ MC, **132**
← adrenalectomy, 134
Hyaline metabolism ← MC, 402
Hyaluronic acid, 329
theories, 367, 374
Hyaluronic acid ⇆ MC, 4, 193
Hydralazine → MC, 193
Hydrazine → MC, 193
5–HT, in MCs, **320**
theories, 366
→ MC, 193
⇆ MC, 5
5-hydroxytryptamine; *cf.* 5–HT
Hyperthyroidism, 293
Hypocorticoidism, 293
Hypophysectomy → MC, 132
Hypophysis, MCs, 92, 111
Hypothyroidism, 293

Imidazolacetic acid, 328
Immunity → MC ← Compound 48/80, 163
Immunologic reactions ⇆ MC, 6, 378
Infections, 290
→ Basophils, 354
Inflammation ← MC, 377
Ink fixation → MC ← 48/80, *Fig. 3*
Insulin → Basophils, 339
→ MC, 143
Interference microscopy, 68
Intestinal activity ⇆ MC, 402
Inulin → MC, 196
Invertebrates, MCs, 124
Invertebrate and plant toxins → MC, 196
In vivo observation, 63
Ionizing radiation → MC, 222
Ionizing rays → Basophilic leukemia, 350
Iron, 329
Iron metabolism ⇆ MC, 401

Joints, MCs, 92, 109
Juxtaglomerular apparatus ⇆ MC, 390

Keloids, 285
Kidney; *cf. also* Renal
MCs, 92, 110
"Kugelhaufen", 25, 92

Lactation → MCs, 240
Lathyrogens → MCs, 197
Lead-induced osteomyelosclerosis, *Fig. 19*
Lead → MC, 197
→ Sympathetic nerves ← Histamine, *Figs. 17, 18*
→ Vagus calcification ← Histamine, *Fig. 16*
Lecithin, 328
Leprosy, 291
Leukemia, basophilic, 346
Light-microscopy, 55
Lipid-containing MC; *cf.* Cellule mastlipoidi
Lipid metabolism ← Basophils, 357
← MC, 398
Lipids, 329
→ MC, 197
Liver; *cf. also* Hepatic
MCs, 91, 102
Luteoids → MC, 142
Lymph nodes, MCs, 91, 104
vessels, MCs, 104
Lymphadenitis, 290
Lymphedema, 298
Lymphomastcells, 22
Lytic enzymes in MC degranulation, 72

Magnesium → MC, 237
Malaria, 292
Mammals, MCs, 127
Mastitis, 291
Mastocalcergy, 5, 393, *Fig. 28*
topical resistance, *Fig. 15*
Mastocalciphylaxis, systemic, *Fig. 12*
Mastocytomas in animals, 275
Mastocytosis, agents influencing, 270
classification and terminology, 249
cutaneous manifestations, *Figs. 21, 22*
diagnosis, 267
in man, **247**
intragranular cylinders in a MC, *Fig. 6*
pathogenesis, 267
pathologic anatomy, 255
(urticaria pigmentosa), *Fig. 23*
Mastopexis, 6, 301
produced with polymyxin + India ink or ferric oxysaccharate, *Fig. 13*
McKibben's spider-shaped MCs, *Fig. 2*
Meningioma, MCs, 61, *Fig. 5*
Metachromasia, 31
Methanol → MC, 201
Microbes, invertebrates, MCs, 124
Microscopy, basophils, 334
cinephotomicrography, 69
electron-, 57
fluorescence, 67
interference, 68
light-, 55
phase-contrast, 66
polarized light, 68

Mineralocorticoids → MC, 140
Mitosis, amitosis, 84
Monocrotaline → MC, 201
Monographs, compilation technique, *xi*
Morphine → MC, 201
Morphology of MC, 16
Motility, 80
Mucin, theories, 367
  → MC, 61, 201
Mucopolysaccharides, 301
Muscles, MCs, 92, 109
Muscular dystrophy, in hamster, mouse, 299
Myeloid leukemia → Basophils, 352
Myocarditis, 287

Naphthalene → MC, 201
Neoplasia, 293
Nephrosis → Basophils, 354
Nerves, sympathetic ← Histamine + Lead acetate, *Figs. 17, 18*
Nervous activity ⇆ MC, 6
  diseases, 298
  function ⇆ MC, 389
  stimuli → MC, 238
  system, MCs, 93, 118
Nitrogen mustard → MC, 201
Noradrenaline; *cf.* Catecholamines
Nucleotides, ATP, 328

Octylamine → MC, 201
Ocular diseases, 289
Oral cavity, MCs, 96
Osteomyelosclerosis, "basophilic bone granules", MCs, *Fig. 20*
  lead-induced, *Fig. 19*
Ovalbumen → MC, 202
Ovomucoid → MC, 202
Ovariectomy → MC, 140
Ovary, MCs, 92, 112

Pancreas, MCs, 92, 111
Parachloromercuribenzoate → MC, 203
Parasitic infestations, 292
Parathyroid, MCs, 92, 112
Pathogenesis, basophilic leukemia, 349
  mastocytoses, 269
Pathologic anatomy, basophilic leukemia, 348
  mastocytoses, 255
Penicillin → MC, 203
Pentamidine → MC, 203
Peptic ulcer, 288
Peptone → MC, 203
Peptone shock; *cf.* Anaphylactoid inflammation
"Periostal spread" preparation, 27, *Fig. 3*
Peritoneum, MCs, 91, 103
*p*H → MC, 204, 402
Phagocytosis, 82
  ← MC, 399
Phase-contrast microscopy, 66
Phenol → MC, 204
Phenylbutazone → MC, 204
Phlogogens → MC, 204
Phosphatidyl choline, 328
Phospholipid-A → MC, 205
Physical agents → Basophils, 341
  → MC, 217
    ← adrenalectomy, 136
Pigment MCs, 22
Pigments ⇆ MC, 370
Pilocarpine → MC, 205
Pineal gland, MCs, 92, 112
Placenta (and amnion), MCs, 116
Plasma cell (Unna), 2
Plasmamastcells, 21
Podophyllin → MC, 156, 205
Polarized light microscopy, 68
Polymyxin
  → MC, 205
    ← Calcergy, Calciphylaxis, 206
    ← Ferric oxysaccharate, *Fig. 14*
Polyvinylpyrrolidone; *cf.* PVP
Pregnancy → Basophils, 346
  → MC, 239
Propamidine → MC, 209
Protamine → MC, 209
PVP → MC, 208
Pyramidon → MC, 210
Pyrilamine → MC, 210

Quasi-MCs, 24

Regional distribution of MCs, **90**
Regranulation, 79
Renal diseases, 287
Reproduction → MC, 238
Reptiles, MCs, 126
RES ← MC, 399
Reserpine → MC, 210
Respiratory diseases, 289
Respiratory system, MCs, 91, 98
RES-stimulators → MC, 210
Reticuloendothelial system; *cf.* RES
Rheumatic fever, 297
Rheumatoid arthritis, 297
Russell-body MCs, 22

Salicylates → MC, 211
Salivary glands, MCs, 91, 102

Shwartzman-Sanarelli phenomenon ⇆ MC, 402
Sclerosing agents → MC, 211
Seasonal variations → Basophils, 345
→ MC, 244
Serotonin; *cf.* 5–HT
Sex → Basophils, 346
→ MC, 238
Sexual cycle; *cf.* Cycle
Silica → MC, 211
Silver nitrate → MC, 211
Sinomenine → MC, 211
Skin, MCs, 90, 94
Slow reacting substance; *cf.* SRS
Sodium salts → MC, 201
Species differences, 124
Spider-shaped MCs, 24
in rat calvarium, *Fig. 1*
McKibben's, *Fig. 2*
Spleen, MCs, 91, 105
SRS, 324
theories, 367
⇆ MC, 6
Staining techniques, 31, 36
cf. also Histochemistry, Histology
vital and supravital, 63
Starvation → MC, 237
Stellate MCs, 23
Stilbamidine → MC, 211
STH → MC, 134
Stress ⇆ MC, 385
Stressors → Basophils, 341
→ MC, 217
Style of this monograph, *xi*
Sulfanilamide → MC, 212
Sweat glands, 401
Sympathetic nerves ← Histamine + Lead acetate, *Figs. 17, 18*
Syphilis, 291
Syphilitic cell (Ramon y Cajal), 2

Tannic acid → MC, 212
Taurine, 329
Temperature → MC, 220
regulation ⇆ MC, 391
Terminology, 12
cf. also Classification
Testis, MCs, 117
Testoids → Basophils, 339
→ MC, 142
Theories, 357, **359**
Thorium dextrin → MC, 212
Thrombin → MC, 213
Thrombo-embolic disease → MC, 386, 387
Thrombokinase → MC, 213
Thromboplastin → MC, 213
Thromboses, varices, 287
Thymus, MCs, 91, 104
Thyroid, MCs, 92, 112
diseases → Basophils, 353
hormones → Basophils, 339
→ MC, 142
Thyroid stimulating hormone; *cf.* TSH
Tissue culture, in study of MC, 69
extracts → MC, 143
respiration ⇆ MC, 402
Tonsillitis, 291
Transformation of cells into MCs, 86
Trauma → MC, 218
Trephocytosis ← MC, 377
TSH → Basophils, 339
→ MC, 134
Tuberculosis, 291
Tuberculostatics → MC, 213
d-Tubocurarine → MC, 213
Tumorigenesis ⇆ MC, 6
Tumors, 293, 296
theories, 378
→ Basophils, 354
Tween 20 → MC, 213
Types of MCs; *cf.* Classification of MCs
Typical MCs, *Fig. 3*

Ulcerative colitis, 288
Umbilical cord; *cf.* Placenta
Uranyl acetate → MC, 213
Urinary passages, diseases, 287
MCs, 110
Urticaria pigmentosa; *cf.* Mastocytosis

Vagus calcification ← Histamine + Lead acetate, *Fig. 16*
Varices, thromboses, 287
Vasoconstriction ← MC, 386
Viomycin → MC, 214
Vital and supravital staining, 63
Vitamin-A → MC, 214
Vitamin-B → MC, 214
Vitamin-C → MC, 214
Vitamin-D → MC, 214
Vitamin-K → MC, 215
Vitamins → MC, 215
Vitamin metabolism ← MC, 402

Waldenström's macroglobulinemia, 298
Water (including osmotic pressure) → MC, 215
Wound healing ← MC, 376

Zinc, 329