Clinical Oral Investigations (2024) 28:600
https://doi.org/10.1007/s00784-024-05989-5

REVIEW

Machine learning and deep learning models for the diagnosis of apical periodontitis: a scoping review

Ángelo Basso[1] · Fernando Salas[1] · Marcela Hernández[2,3] · Alejandra Fernández[1,4] · Alfredo Sierra[1,2] · Constanza Jiménez[1]

Received: 16 April 2024 / Accepted: 2 October 2024 / Published online: 18 October 2024
© The Author(s), under exclusive licence to Springer-Verlag GmbH Germany, part of Springer Nature 2024

Abstract

Objectives To assess the existing literature on the use of machine learning (ML) and deep learning (DL) models for diagnosing apical periodontitis (AP) in humans.

Materials and methods A scoping review was conducted following the Arksey and O'Malley framework. The PubMed, SCOPUS, and Web of Science databases were searched, focusing on articles using ML/DL approaches for AP diagnosis. No restrictions were applied. Two independent reviewers screened publications and charted data in predefined Excel tables for analysis.

Results Nineteen publications focused on diagnosing AP by identifying periapical radiolucent lesions (PRLs) in dental radiographs were included. The average sensitivity and specificity for reviewed models were 83% and 90%, respectively. Only three studies explored the direct impact of artificial intelligence (AI) assistance on clinicians' diagnostic performance. Both consistently showed improved sensitivity without compromising specificity. Significant variability in dataset sizes, labeling techniques, and algorithm configurations was noticed.

Conclusions Findings affirm AI models' effectiveness and transformative potential in diagnosing AP by improving the accurate detection of periapical radiolucencies using dental radiographs. However, the lack of standardized reporting on crucial aspects of methodology and performance metrics prevents establishing a definitive diagnostic approach using AI. Further studies are needed to expand AI applications in AP diagnosis beyond radiographic analysis.

Clinical relevance AI can potentially improve diagnostic accuracy in AP diagnosis by enhancing the sensitivity of PRL detection in dental radiographs without compromising specificity.

Keywords Periapical periodontitis · Apical periodontitis · Diagnosis · Artificial intelligence · Machine learning · Deep learning

Introduction

Apical periodontitis (AP) is a chronic inflammatory disease that affects the periapical tissues in half of the global adult population [1, 2]. AP arises from the dynamic interplay between bacterial infection of the endodontic root canal system and the host's subsequent immune response [2]. This interaction leads to the destruction of nearby periodontal and alveolar bone structures, ultimately resulting in the development of an osteolytic apical lesion, which stands as the defining feature of the disease [2]. Apical lesions are characterized by their appearance on dental radiographs, which usually ranges from a subtle image of a widened periodontal ligament space to a distinct periapical radiolucent lesion (PRL) that may or may not exhibit bone cortication

✉ Alfredo Sierra
alf.sierra@uandresbello.edu

✉ Constanza Jiménez
c.jimenezlizama@uandresbello.edu

1 Facultad de Odontología, Universidad Andres Bello, Santiago, Región Metropolitana 8370133, Chile

2 Laboratorio de Biología Periodontal, Facultad de Odontología, Universidad de Chile, Santiago 8380544, Chile

3 Departamento de Patología y Medicina Oral, Facultad de Odontología, Universidad de Chile, Santiago 8380544, Chile

4 Laboratorio de Interacciones Microbianas, Facultad de Odontología, Universidad Andres Bello, Santiago, Región Metropolitana 8370133, Chile

[2]. Importantly, PRLs are always in direct association with the periodontal ligament space of the affected tooth [2], thus requiring precise analysis for their diagnosis.

Depending on the presence or absence of clinical symptoms, AP can clinically manifest as symptomatic apical periodontitis or asymptomatic apical periodontitis, respectively. Since asymptomatic AP may present itself in up to 42.6% of cases of the disease, radiographic imaging becomes of paramount importance for diagnosing AP [2]. However, traditional radiographic approaches for identifying PRLs have inherent limitations and may be subjective in some cases [3, 4]. For instance, two-dimensional images often miss information due to the superimposition of anatomical structures, leading to the concealment of early-stage PRLs that are barely visible [3, 5]. Likewise, three-dimensional cone beam computed tomography (CBCT) scans offer more data and detail, but they also come with higher costs and increased patient radiation exposure [6]. Moreover, the appearance of PRLs may closely resemble that of other conditions (e.g., dentigerous cysts, ameloblastoma, and odontogenic keratocytes), leading to potential confusion and misdiagnoses [7]. The digitalization of radiological data and the introduction of computer-assisted diagnostic tools have emerged as an auspicious solution to these problems, promising to enhance clinicians' diagnostic accuracy while reducing their subjectivity.

Artificial Intelligence (AI) is an umbrella term encompassing a wide range of technologies combining engineering and computer sciences to create machines capable of performing tasks with human-like intelligence [8, 9]. Machine Learning (ML) is a specialized subfield focused on developing computational systems capable of learning and making decisions based on previously provided data [8, 10]. Deep Learning (DL), on the other hand, is a subset of ML oriented to replicate the functionality of the human brain by simulating its neuronal structure using convolutional neural networks (CNNs) [8, 10]. CNNs consist of several layers of interconnected nodes or "neurons", that sequentially process complex data [9]. For example, in image recognition tasks, the first layer of neurons might learn to recognize edges, while the second focuses on recognizing shapes by combining these edges, and later layers learn to identify objects by combining these shapes. Remarkably, DL accomplishes all this autonomously, learning directly from data without prior human instruction. It efficiently processes and analyzes the information, unraveling complex spatial and temporal relationships [8, 10].

The recent introduction of ML and DL technologies into the healthcare sector has revolutionized the approach to medical radiological diagnostics [11]. For example, CNN-based DL models are currently employed to achieve impressive feats such as identifying and classifying lung nodules in computer tomography scans, detecting primary bone tumors in radiographs and distinguishing them from other bone lesions, as well as differentiating renal cell carcinoma subtypes on magnetic resonance images [12–14]. These models do so with high levels of accuracy, often rivaling or even exceeding the expertise of seasoned radiologists. Similarly, the oral and maxillofacial radiology field has also witnessed parallel advances, with AI tools increasingly assisting in interpreting oral and maxillofacial images to detect and diagnose a wide range of conditions and diseases. These include the detection of caries, vertical root fractures, periodontal bone loss, salivary gland diseases, maxillary sinusitis, apical lesions, maxillofacial cysts, tumor and cancer lesions, cervical lymph nodes metastasis, osteoporosis, locating the minor apical foramen, determining root morphology, predicting orthodontic extractions, assessing the need for orthodontic treatments, determining the growth and development of cervical vertebrae, and identifying cephalometric landmarks, among others [15–18]. These AI systems mimic the precision and accuracy of trained oral and maxillofacial radiologists and, in some studies, have even surpassed these specialists in terms of both performance and accuracy [16]. However, the literature on the use of AI systems for AP diagnosis is still sparse [19].

This scoping review aims to bridge this knowledge gap by thoroughly examining and synthesizing the existing scientific literature on the application of ML and DL algorithms for AP diagnosis in human populations. Our work will additionally address critical questions, including (1) "What are the predominant AI techniques, models, algorithms, and tasks used for AP diagnosis?", (2) "What are the characteristics that define the main datasets used in this topic?", (3) "What is the diagnostic performance of existing ML and DL models in diagnosing AP?" and (4) "What impact does AI assistance have on the diagnostic performance of human clinicians diagnosing AP?". In doing so, we aim to provide a comprehensive overview of the current state of the art and future of radiographic diagnosis of AP in an era of rapidly advancing AI technologies.

Materials and methods

Protocol and registration

For this scoping review study, the Ethics and Scientific Committee at Universidad Andres Bello determined that no ethical approval was required. The study was conducted following the scoping review framework established by Arskey and O'Malley in 2005 for developing scoping reviews [20]. It also incorporated successive recommendations from Levac et al. [21] and the "Scoping Reviews Chapter" from

the Joanna Briggs Institute's manual for evidence synthesis [22]. The complete protocol (PROPRGFO_2023_44) is publicly accessible on the Open Science Framework platform at: https://osf.io/964pv/?view_only=d9e85410a4b44a27b577c86555c04958.

Research question

The primary research question explored was: "What insights does current scientific literature provide on the application of machine learning (ML) and deep learning (DL) technologies for the diagnosis of AP in human populations?"

Secondary questions included: (1) "What are the predominant AI techniques, models, algorithms, and tasks used for AP diagnosis?", (2) "What are the characteristics that define the main datasets utilized in this field?", (3) "What is the diagnostic performance of current ML and DL models in diagnosing AP?", (4) "What impact does AI assistance have on the diagnostic performance of human clinicians diagnosing AP?".

Eligibility criteria

Eligibility criteria were established following the Population/Concept/Context framework following JBI's guidelines. The inclusion criteria were:

a. Population: studies involving human populations, regardless of age, gender, or ethnicity.
b. Concept: research focused on ML/DL techniques, models, or algorithms for diagnosing AP.
c. Context: studies conducted across all types of clinical settings and countries.

Conversely, the exclusion criteria were:

a. Secondary studies (such as narrative reviews, umbrella reviews, systematic reviews, etc.).
b. Studies conducted on animal models.
c. Studies on ML/DL techniques, models, or algorithms for diagnosing oral pathologies other than AP.
d. Studies using ML/DL techniques, models, or algorithms for purposes other than diagnosis (e.g., prognosis or therapy).

Information sources

A comprehensive and systematic electronic literature search was performed between March and May of 2023 across PubMed, SCOPUS, and Web of Science (WOS) databases. Due to the emerging nature of the topic and the reasonable anticipation of limited publications in the field, no date or language restrictions were applied. Furthermore, a complementary search was performed in February 2024. This step was intended to update and enrich the search database with the most recent publications, ensuring the final manuscript included the latest articles in the field before final submission for publication.

Electronic literature search

To devise the most effective literature search strategy, we initially performed a pilot search using an array of popular terms and commonly used words within the field. Informed by the results of this preliminary effort and the subsequent identification and incorporation of relevant Medical Subject Headings (MESH) terms, the final search strategy was implemented as follows:

1) In PubMed: ((“Periapical periodontitis“[Mesh]) OR (“Periapical periodontitis“[all fields])) AND ((“Artificial Intelligence“[Mesh]) OR (“Deep Learning“[Mesh]) OR (“Machine Learning“[Mesh]) OR (“Unsupervised Machine Learning“[Mesh]) OR (“Supervised Machine Learning“[Mesh]) OR (“Neural Networks, Computer“[Mesh])).
2) In SCOPUS: TITLE-ABS-KEY (artificial intelligence) OR TITLE-ABS-KEY(deep learning) OR TITLE-ABS-KEY(machine learning) OR TITLE-ABS-KEY(neural networks, computer) OR TITLE-ABS-KEY(supervised machine learning) OR TITLE-ABS-KEY(unsupervised machine learning) AND TITLE-ABS-KEY(periapical periodontitis).
3) In Web of Science (WOS): ALL=(periapical periodontitis) AND ((((((ALL=(artificial intelligence)) OR ALL=(deep learning)) OR ALL=(machine learning)) OR ALL=(neural networks, computer)) OR ALL=(supervised machine learning)) OR ALL=(unsupervised machine learning)).

Selection of the sources of evidence

Two independent reviewers (A.B. and F.S.) screened the titles, abstracts, and full-text articles against the eligibility criteria. The open-source software Rayyan (https://www.rayyan.ai/) was used to facilitate the selection process and removal of duplicate publications. The software's "blind mode" feature was activated to ensure each reviewer made unbiased and independent decisions. Conflicts over including or excluding a specific article were settled by consulting with the lead supervisor (C.J.).

Data charting processes and data items

Data extraction and charting were independently conducted by reviewers A.B and F.S, with discrepancies resolved through consultation with C.J. All information was recorded in predefined Excel forms. The standardized collation sheet included the following data items: author(s), year of publication, country of origin, language, study objective, study design, population inclusion and exclusion criteria, dataset origin, dataset size (total, training, validation, and test), dataset inclusion and exclusion criteria, operational definition of healthy and diseased (PRLs), dataset manipulation (labeling, preprocessing, augmentation), hardware, AI technique (ML and/or DL), AI model, AI algorithm structure, AI task, AI's diagnostic performance (sensitivity, specificity, recall, AUC-ROC), AI performance metrics (accuracy, precision, recall, F1-score, loss function), unaided dentist's diagnostic performance (sensitivity, specificity, AUC-ROC), unaided dentists' performance metrics (accuracy, precision, recall, F1-score, loss function), AI aided dentist's diagnostic performance (sensitivity, specificity, AUC-ROC), and AI-aided dentists' performance metrics (accuracy, precision, recall, F1-score, loss function).

Synthesis of results

Results were primarily synthesized using descriptive narrative, graphical, and tabular approaches. A quantitative synthesis or meta-analysis was not performed due to the methodological heterogeneity of included studies and the nature of a scoping review design. Figures were prepared using the GraphPad Prism software v.8.0 for Windows (GraphPad Software, Dotmatics, Boston, MA, USA).

Manuscript preparation

The manuscript was prepared following the "Preferred Reporting Items for Systematic Reviews and Meta-analysis Extension for Scoping Reviews" (PRISMA-ScR) guideline for comprehensive and transparent reporting [23].

Results

This work began with an initial electronic literature search between March and May 2023, uncovering 60 studies. Deduplication left 36 articles for in-depth evaluation, of which 22 were excluded for not meeting the "Concept" eligibility criteria ($n=21$) or being secondary studies ($n=1$). This process resulted in 14 primary articles for inclusion. The search was subsequently updated in February 2024, prior to manuscript submission. This second evaluation resulted in an additional 21 studies, which were reduced to 17 articles after deduplication. Of these, 1 article could not be retrieved, and 11 were excluded due to non-compliance with the "Concept" eligibility criteria ($n=9$) or being secondary studies ($n=2$). Consequently, this resulted in the addition of 5 new articles. Additionally, 1 article was also included based on the recommendation from an expert [24]. The entire data selection process, resulting in the final 19 articles included in this work, is illustrated in Fig. 1.

Characteristics of included studies

The main characteristics of the included articles are summarized in Table 1. All articles employed experimental-quantitative research designs, focusing on using ML or DL computer vision algorithms to enhance the diagnosis of AP by detecting PRLs in radiographic images. Furthermore, we observed a notable absence of studies exploring alternative AI applications in diagnosing AP, such as aiding in the analysis of clinical records, identifying biomarkers in fluids and/or other tissue samples, or empowering other non-radiographic diagnostic methods, such as proteomics and genomics analyses.

While a few articles were published in the last decade [25, 26], most of the research output emerged in the past four years. Notably, the years 2022 and 2023 witnessed a significant increase in publication volume on the topic compared to previous years [24, 27–37], perhaps reflecting on current advancements in the AI technology field and a growing interest in this research topic.

In terms of geographical distribution, most of the included articles originated from the European Union (EU) [26–29, 38] and Turkey [25, 30, 36, 39, 40], followed by China [31, 37, 41], India [33, 34], and the United States [24, 42] (Fig. 2). Additional input came from countries such as South Korea [35] and Qatar [32]. However, studies from South American, Oceanic, or African regions were not found.

Predominant ML and DL techniques, models, algorithms, and tasks

Reviewed studies encompassed a broad spectrum of artificial intelligence methodologies in computer vision for image recognition tasks, with results detailed in Table 1. DL techniques were the most utilized approach ($n=15$), followed by ML techniques ($n=2$) and a combination of both ML and DL approaches ($n=2$). Within the studies employing DL and DL/ML methods, convolutional neural networks (CNNs) were identified as the primary model, and they were used either independently or in conjunction with other ML algorithms, such as gradient boosting. Conversely, studies focusing solely on ML techniques preferred non-CNN

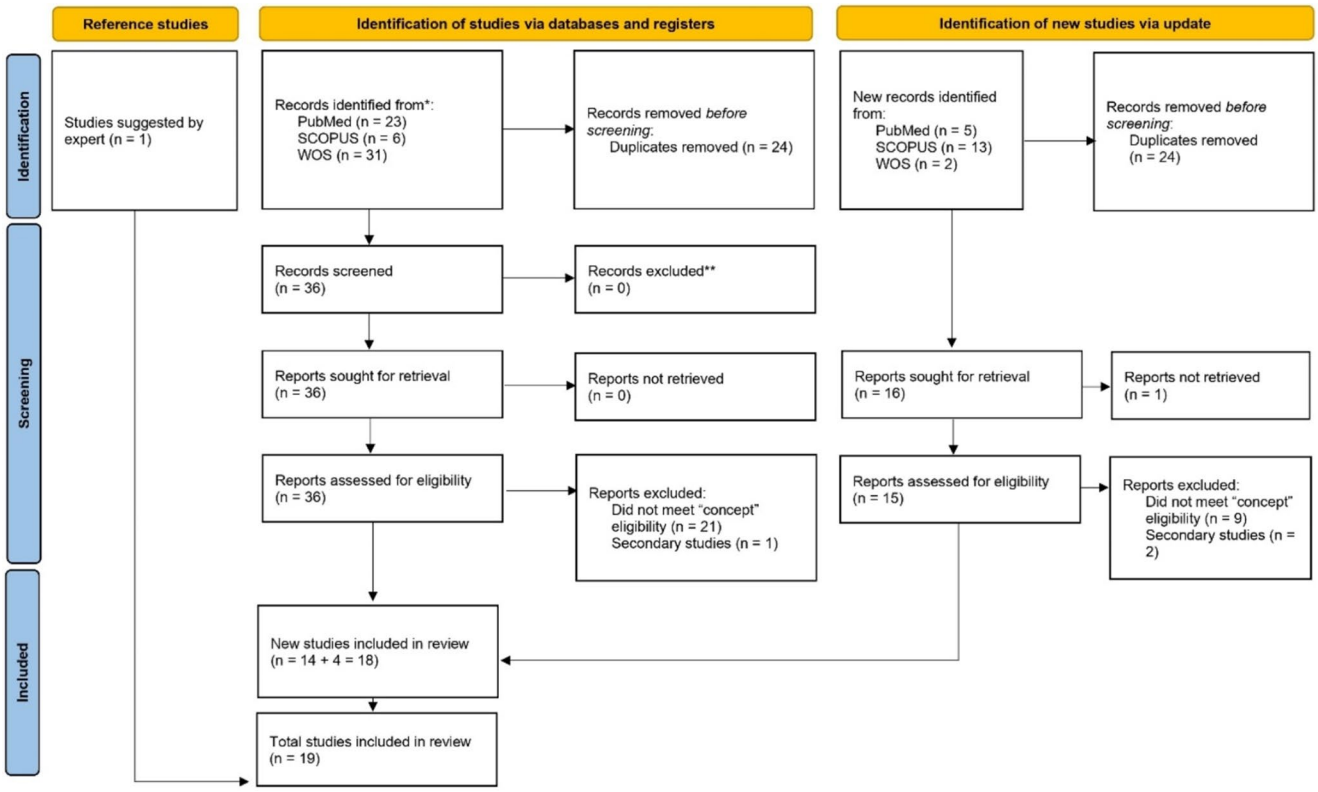

Fig. 1 Preferred Reporting Items for Systematic Reviews and Meta-analyses extension for scoping reviews (PRISMA-ScR) flow diagram of included studies

models, opting for ensemble methods with LDA-ADA-Boost algorithms [26] and regression models [25].

In terms of tasks, the DL and ML/DL studies performed image segmentation ($n=9$), image classification ($n=4$), and object detection tasks ($n=7$). Image segmentation frequently employed the U-Net algorithm architecture, while image classification tasks utilized a myriad of algorithms, including VGG-16, InceptionV3, MobileNet, and ResNet families, among others. Object detection tasks were primarily achieved using faster R-CNN or Yolo.v.3 algorithms. In contrast, ML-exclusive studies focused on classification or regression tasks, employing algorithms such as LDA-ADABoost for classification and polynomial regression for regression tasks.

Dataset characteristics, labeling, and preprocessing techniques

The dataset characteristics of included articles, along with their labeling and processing methods, are summarized in Table 2. The primary datasets comprised digital radiographic images sourced from panoramic ($n=8$), periapical ($N=6$), and cone beam computed tomography (CBCT) ($n=5$) examinations. A considerable variation in dataset sizes was observed across studies. While some investigations employed extensive collections of over a thousand images for training, validation, and testing purposes, others relied on relatively small datasets, sometimes expanding their size through preprocessing techniques such as image segmentation and/or cropping. This diversity, coupled with the lack of uniform methodologies and reporting standards for AI publications, makes it challenging to conclusively identify a preferred method for preprocessing and augmenting digital images for analysis.

All studies utilized supervised learning methodologies to train their models. In supervised learning, models are "educated" using a "training dataset" of images that human experts have previously labeled. These labels provide a "ground truth" against which the model measures its accuracy [8, 10]. In this review, most articles reported the involvement of dentists with various levels of expertise and specializations in labeling the presence of PRLs in the training datasets. However, criteria for what constituted a case of PRL varied considerably across studies, with some even omitting these definitions entirely, as detailed in Table 2.

Table 1 Overview of included studies

Reference	Year	Country	Aim	Artificial intelligence technique	Model	Main algorithm structure	Main task
[39]	2021	Turkey	Detecting periapical pathology in CBCT	DL	CNN	U-Net, ResNeXt, DenseNet	Image Segmentation
[37]	2023	China	Identifying common lesions in dental X-rays	DL	CNN	VGG-16, InceptionV3, ResNet-50, DenseNet-121	Image Classification
[42]	2020	The United States of America	Detection of periapical lesions	DL	CNN	U-Net	Image Segmentation
[41]	2021	China	Detection of lesions on periapical radiographs	DL	CNN	Faster R-CNN	Object Detection
[36]	2022	Turkey	Segmentation of apical lesions on panoramic radiographs	DL	CNN	U-Net	Image Segmentation
[35]	2022	South Korea	Apical lesion segmentation from panoramic radiographs	DL	CNN	U-Net	Image Segmentation
[40]	2020	Turkey	Detecting periapical pathosis on CBCT	DL	CNN	U-Net	Image Segmentation
[26]	2015	Italy	Differential diagnosis of periapical lesions	ML	Ensemble methods	LDA-AdaBoost	Classification
[38]	2020	Germany	Compare the assessment of periapical lesions between OMF surgeons and a DL model	DL	CNN	U-Net	Image Segmentation
[34]	2022	India	Score periapical lesions on intra-oral radiographs	DL	CNN	YOLO.v.3	Object Detection
[33]	2022	India	Detecting tooth wear, periapical, periodontitis, tooth decay, missing teeth, and impacted teeth	ML/DL	CNN with Gradient Boosting	ResNet50V2/XGBoost-1, ResNet101V2/XGBoost-2, MobileNetV3 Large/XGBoost-3, MobileNetV3 Small/XGBoost-4, MobileNet/XGBoost-5, EfficientNetB0/XGBoost-6, EfficientNetB1/XGBoost-7, EfficientNetB2/XGBoost-8	Image Segmentation
[32]	2023	Qatar	Detecting periapical lesions	ML/DL	CNN	ResNet x101, InceptionV3, VGG16 y Xception	Object Detection
[25]	2015	Turkey	Detecting apical lesions	ML	Regression models	Polynomial Regression	Regression
[31]	2022	China	Detecting caries and periapical periodontitis on periapical radiographs	DL	CNN	ResNet-18	Image Classification
[30]	2023	Turkey	Detecting roots with apical periodontitis on panoramic radiographs	DL	CNN	Yolo.v3	Object Detection
[29]	2023	Poland	Detecting periapical pathosis on periapical radiographs	DL	CNN	Diagnocat (Diagnocat Ltd., San Francisco, CA, USA)	Object Detection
[28]	2023	Belgium	Distinguish between radicular cysts and periapical granulomas on panoramic images	DL	CNN	MobileNetV2, Yolov3	Image Classification and Object detection
[27]	2023	Austria	Detecting periapical lesions on CBCT	DL	CNN	SCN, U-Net	Image segmentation
[24]	2022	The United States of America	Determine the efficacy of a deep-learning tool in assisting dentists in detecting apical radiolucencies on periapical radiographs.	DL	CNN	Denti.AI (Denti.AI Technology Inc., Toronto, CA)	Image Segmentation, Classification, and Object detection

DL, Deep Learning; ML, Machine Learning; CNN, Convolutional Neural Network

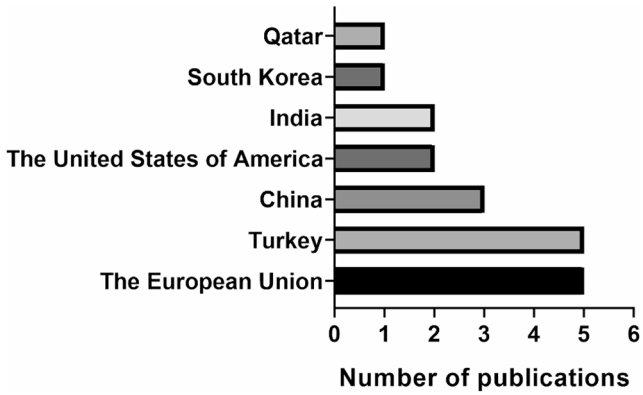

Fig. 2 Geographical distribution of included studies

Diagnostic performance of current ML and DL models for PRLs

Most authors in this review primarily reported the diagnostic accuracy of their models in terms of specificity, sensitivity, and recall outcomes [43]. Specificity, in this context, should be understood as the model's ability to accurately identify and label images of teeth without PRLs (in other words, those with normal periodontal periapical ligament) as "negative" or "non-diseased" [44]. Sensitivity, conversely, refers to the model's ability to correctly identify and label images of teeth with PRLs as "positive" or "diseased" [44]. Notably, in the context of artificial intelligence and diagnostic testing, the term "sensitivity" is usually interchangeable with the term "recall" [43]. Therefore, a decision was made to analyze studies reporting recall values as if they were reporting sensitivity values. In cases where studies provided multiple sensitivity or recall values, an average of these values was calculated for analysis.

In terms of reporting, sixteen of the eighteen studies included in this review provided data on sensitivity and/or recall values, whereas specificity values were documented in only 11 publications. Detailed findings are presented in Table 3, with a graphic summary available in Fig. 3. Sensitivity values across studies varied from 0.5353 to 1 with a median of 0.8635 and a mean (± standard deviation) of 0.8251 (± 0.1349). In contrast, specificity values ranged from 0.76 to 0.9965 with a median of 0.8900 and a mean (± standard deviation) of 0.9011 (± 0.0799).

A deeper analysis focusing on the type of radiographic assessment revealed further differences. Results are illustrated in Fig. 4. For periapical radiographs, the sensitivity values ranged extensively from 0.5353 to a perfect 1.0, with a median of 0.9055 and a mean (± standard deviation) of 0.8368 (± 0.1803). Specificity scores for these radiographs varied from 0.7600 to 0.9965, with a median of 0.9094 and a mean (± standard deviation) of 0.8938 (± 0.1134). Similarly, CBCT scans showcased sensitivity values between 0.7559 and 0.9800, with a median of 0.8935 and a mean (± standard deviation) of 0.8807 (± 0.09517). Their specificity values spanned from 0.8430 to 0.9956 with a median of 0.8800 and a mean (± standard deviation) of 0.9062 (± 0.0796). Finally, panoramic radiographs showed the lowest average sensitivity and specificity values, with sensitivity scores spanning from 0.5600 to 0.9200, with a median of 0.7913 and a mean (± standard deviation) of 0.7852 (± 0.1237). Specificity ranged from 0.8233 to 0.9750 with a median of 0.9100 and a mean (± standard deviation) of 0.9046 (± 0.0643).

Interestingly, Hadzic and colleagues conducted another sub-analysis focused on the diagnostic capacities of their model, stratifying its outcomes by jaw and tooth type [27]. Their findings showed no significant differences in sensitivity and specificity values when comparing the upper and lower jaws [27]. However, stratification by tooth type resulted in a notable drop in sensitivity for detecting PRLs in third molars, canines, and lateral incisors, with values falling below 70% [27]. These findings hint at the importance of considering specific tooth types when assessing PRLs using novel AI tools.

Performance metrics of current ML and DL models for the detection of PRLs

The evaluation of ML and DL models solely through individual metrics such as specificity, sensitivity, and recall is insufficient to capture the full diagnostic spectrum that these models offer. Therefore, a comprehensive assessment and understanding of the model's performance metrics is crucial [43, 45]. These metrics are integral to determining a model's overall accuracy and effectiveness [46, 47]. Their analysis is important not only for selecting the most appropriate model for a given task from a range of options, but also for validating and testing the model with new data, thereby providing key insights into its generalizability [43, 45–47]. The choice of which metrics to use depends on the project's goal and the nature of the task at hand. For example, general multi-task models are usually evaluated in terms of cross-validation metrics and their "area under the precision-recall curve" (AUC-PR) [46]. Models developed for classification tasks typically rely on accuracy (ACC), precision (PREC), F1 score (F1), and the "area under the curve of the receiver operating characteristic curve" (AUC-ROC) for their evaluation [46]. In contrast, regression models are assessed through metrics like mean squared error (MSE), root mean squared error (RMSE), mean absolute error (MAE), and the r-squared (coefficient of determination) [46].

In this review, we identified significant gaps in the documentation and reporting of performance metrics for the evaluated ML and DL models, as detailed in Table 3. These omissions hindered the execution of in-depth inter-study

Table 2 Dataset characteristics, labeling, and preprocessing methods

Reference	Dataset	Dataset size (Train, Validate, Test)	Inclusion criteria	Exclusion criteria	Healthy definition	PRL definition	Labeling	Image preprocessing and augmentation	Hardware
[39]	CBCT	1135 (N/R, N/R, 300)	Images from patients ≥ 21 years-old	Images with artifacts or images from patients with cleft lip palate, trauma, severe bone lesions, and/or dental erosions	Healthy periodontal ligament	Thickening of periodontal ligament, Ill-defined radiolucency, well-defined radiolucency, periapical	3 OMF radiologists with 10 years of experience	Normalization of radiodensity (Hounsfield Units)	N/R
[37]	Periapical	188 (NR, N/R, N/R)	N/R	Images with artifacts or lesions other than PRLs	N/R	Periapical periodontitis, periapical cyst	General dentists	Mirroring, rotation, random cropping, and scaling to 5 times the original size, and normalization with re-scaling to 256 × 256 × 3 pixels.	NVIDIA RTX 2060 GPU, 16 GB RAM, Intel Core i5-10400
[42]	CBCT	20 (16, 4, NR)	Images with a limited field of view, showing multiple roots with at least 1 PRL per volume	Images with scatter or artifacts	N/R	Detection of disruption of the lamina dura with the presence of a radiolucent zone associated with the dental apex at a distance of up to twice the width of the periodontal ligament space.	An OMF radiologist, an endodontist, and a general dentist. Discrepancies resolved through discussion.	N/R	N/R
[41]	Periapical	2900 (N/R, N/R, N/R)	Images of permanent teeth	Images with incorrect exposure, distorted images, images with deciduous teeth, and images with teeth in incorrect axial position.	N/R	Mild periapical periodontitis (width of the periapical area is less than 1 mm), Moderate periapical periodontitis (width of the periapical is between 1 and 3 mm), and Severe periapical periodontitis (width of the periapical area is more than 3 mm).	An expert dentist with 5 years of clinical experience drew minimal bounding boxes to frame areas of interest. Each area was labeled according to severity: mild, moderate, and severe.	N/R	NVIDIA Quadro RTX 800 GPU, 48 GB RAM, 4608 CUDA
[36]	Panoramic	470 (380, 43, 47)	N/R	Images with artifacts	N/R	N/R	3 OMF radiologists with at least 3 years of experience annotated images.	Horizontal and vertical flipping, cropping, CLAHE, resizing, removal of complete black masks	NVIDIA GTX 1060 Ti, 16 GB RAM

Table 2 (continued)

Reference	Dataset	Dataset size (Train, Validate, Test)	Inclusion criteria	Exclusion criteria	Healthy definition	PRL definition	Labeling	Image preprocessing and augmentation	Hardware
[35]	Panoramic	1000 (800, 100, 100)	Images from adult patients with permanent dentition	Images with artifacts	N/R	N/R	3 OMF radiologists with over 10 years of experience. Discrepancies resolved through discussion.	Resizing to 960×480 pixels and conversion to PNG. Then Flip, blur, shift, scale, rotate, sharpen, emboss, adjust contrast, brightness, grid distortion, and elastic transformation through inline augmentation	NVIDIA DGX Station, 256 GB RAM DDR4, 4 V100 GPU and Intel Xeon E5-2698 v4
[40]	CBCT	3900 (2800, N/R, 153)	N/R	N/R	N/R	N/R	1 OMF radiologist and 1 OMF surgeon with 8 years of experience. Lesion volume was manually calculated.	N/R	N/R
[26]	CBCT	28 (N/R, N/R, N/R)	N/R	N/R	N/R	Periapical granuloma, periapical cyst	Endodontists	N/R	Pentium Core Duo 1.83 GHz
[38]	Panoramic	2902 (2902, 95, 102)	N/R	Images with artifacts, inadequate anatomical coverage due to poor placement, lower density, poor contrast	N/R	Periapical inflammation / infection, periapical granuloma, periapical cyst	4 OMF surgeons with 5 to 20 years of experience	Resizing to 1280×2560 pixels, manual cropping of edges (top and bottom: 100 pixels, right and left: 300 pixels), resizing to 256×512 pixels, intensity normalization (range: 0.1), Random translations in horizontal and vertical directions (up to 20 pixels in each direction), horizontal flips, and rotations (up to 15 degrees).	NVIDIA Tesla K80 GPU
[34]	Periapical	2200 (1950, N/R, 250)	Images from permanent mandibular teeth	Third molars or teeth with periapical lesions other than PRLs	Healthy (PAI 1 or 2)	PRL (PAI 3, 4 or 5)	3 Endodontists classified lesions based on severity according to the PAI Index. Discrepancies were solved by consulting with an endodontist with over 25 years of experience	Intensity normalization (range: 0.1), horizontal flipping, rotation (5 degrees clockwise and counterclockwise), and cropping (from 0.8 to 1).	NVIDIA Tesla K80 GPU

Table 2 (continued)

Reference	Dataset	Dataset size (Train, Validate, Test)	Inclusion criteria	Exclusion criteria	Healthy definition	PRL definition	Labeling	Image preprocessing and augmentation	Hardware
[33]	Panoramic	500 (400 N/R, 100)	N/R	Images with artifacts or from patients wearing prostheses or orthodontic devices	N/R	N/R	OMF radiologists, Prosthodontists, OMF surgeons, Periodontists, and Endodontists.	Automatic cropping into four parts: top right, top left, bottom right, and bottom left, each with a size of 1000 × 530 pixels. Then, flipping, blurring, shifting, scaling, rotating, sharpening, embossing, adjusting contrast, brightness, grid distortion, and elastic transformation.	NVIDIA Tesla V100, 32 GB RAM
[32]	Panoramic	713 (513, 57, 143)	N/R	Images with artifacts or derived from patients with mixed dentition or who are edentulous	N/R	N/R	3 examiners independently annotated the periapical root areas with and without PRLs in duplicate; a fourth examiner solved discrepancies	Image resizing and flipping, pixel normalization (range: 0.1), resizing to 75 × 75, random rotation between 0–20 degrees, random zoom between 0.8 and 1.2, shuffling images (classification stage)	NVIDIA Tesla P100
[25]	Panoramic	9 (N/R, N/R, 9)	N/R	N/R	Pixel signal intensity of alveolar bone	Pixel signal intensity of PRL and expansion of the periodontal space up to at least TL/10 pixels from the apex	N/R	Noise reduction (5 × 5 Gaussian mask with a standard deviation of $r = 1$) and image contrast enhancement (top-hat and bottom-hat transformations applied to the initial image).	N/R
[31]	Periapical	4129 (3829, N/R, 300)	N/R	Low-quality images or from teeth that had undergone pulpal treatments or restorations	N/R	Circumscribed low-density shadow around the apical root in radiography, with a rough boundary in the lesion area.	2 General dentists with more than 10 years of experience. Discrepancies were solved by a third dentist with over 20 years of experience	Automatic cropping to separate crown from root, followed by resizing the image to 450 × 420 pixels.	NVIDIA RTX 2080 Ti
[30]	Panoramic	306 (N/R, N/R, N/R)	Images with sufficient diagnostic quality with at least 1 PRL	N/R	N/R	Widened periodontal ligament / uncertain PRL / Clearly identified PRL	OMF radiologists	Images in jpeg format without filtering	N/R

Table 2 (continued)

Reference	Dataset	Dataset size (Train, Validate, Test)	Inclusion criteria	Exclusion criteria	Healthy definition	PRL definition	Labeling	Image preprocessing and augmentation	Hardware
[29]	Periapical	20 (N/R, N/R, N/R)	High-quality Images of permanent dentition teeth (at least showing 1 tooth with periodontium) obtained from patients ≥ 18 years old	Images with artifacts, low resolution, or deciduous teeth	Healthy (PAI = 1 and 2)	Unhealthy (PAI = 3, 4 and 5)	*	**	***
[28]	Panoramic	249 (N/R, N/R, 67)	Image clarity sufficient to depict PRLs in symptomatic and asymptomatic patients	Images of composite lesions or those showing motion, position artifacts, foreign bodies, or poor-quality	Images without any pathology	Radicular cyst = epithelium-lined radicular cyst on pathology or granulomatous tissue with sharp cortical lining, ballooning effect, and off apical lesion's center on the radiograph Granuloma = diffuse borders, lesion creeping coronally, and dense tissue collection	2 dentists with clinical expertise in OMF radiology Discrepancies solved by a third OMF radiologist	Cropping, augmentation, optical distortion, horizontal flip, random gamma noise, multiplicative noise, random tone curve, sharpening the edges, Gaussian noise, resizing to 256 × 256 pixels, normalization (range: 0.1)	12th Gen Intel(R) core™ i9-12900 K 3.2 GHz with 128 GB RAM and NVIDIA Quadro P500 GPU

Table 2 (continued)

Reference	Dataset	Dataset size (Train, Validate, Test)	Inclusion criteria	Exclusion criteria	Healthy definition	PRL definition	Labeling	Image preprocessing and augmentation	Hardware
[27]	CBCT	108 (N/R, N/R, 36)	Images with field of view of the entire dental arch, 200 µm voxel, completed root development with up to 11 missing teeth per jaw	Unacceptable degree of scatter and/or artifacts	Healthy (PAI = 1 and 2)	PRL (PAI = 3, 4 and 5)	2 OMF surgeons with > 15 years of experience and 1 junior dentist	Cropping, resizing, cropping	Intel(R) CPU 920 with an NVIDIA GeForce GTX TITAN X
[24]	Periapical	68 (†)	Diagnostically acceptable periapical radiographs acquired within a six-month window of CBCT reference.	Periapical images of apical radiolucencies measuring less than 2 mm at their widest dimension, radiographs from patients > 18 years old.	Sound periodontum (no evidence of apical radiolucencies on CBCT reference standard and associated reports).	Apical radiolucencies including: "apical rarefying osteitis", "apical radiolucent lesions", and "apical widening of the PDL space" divided by extent (small: 2–5 mm or large: ≥5 mm) or treatment status (endodontically treated or untreated teeth).	††	**	***

PRL, Periapical radiolucent lesion; CBCT, Cone beam computed tomography; OMF, Oral and Maxillofacial; PAI, Periapical index, N/R, Not reported

* This study tested a previously developed AI model (Diagnocat, Diagnocat Ltd., San Francisco, CA, USA). Manual radiographic evaluations were conducted by an OMF radiologist with > 10 years of experience and a trainee in OMF radiology. These evaluations served as the ground truth for comparison. Importantly, the clinicians did not label the images used for training the AI model

** Since the AI model was already fully developed, there was no need to preprocess/augment the images

*** Because the AI model was fully developed, there was no need for specific hardware for its testing

† Model was pretrained ahead of the study using > 1000 images obtained from sites other than the dental school's clinics. A subset of the periapical radiographs (54/184) was used to further adapt the model to the devices used in the clinics

†† This study tested a previously developed AI model (Denti.AI, Denti.AI Technology Inc., Toronto, CA). Manual radiographic evaluations were conducted by one of three OMF radiologist with > 10 years of experience to provide ground truth for comparison. Participating clinicians (6 operative dentistry residents, a general dentist and an endodontist) did not label the images used for training the AI model

comparisons, thereby limiting a full assessment of the generalizability and reliability of the different models.

Impact of AI assistance on clinicians' diagnostic performance

Only three of the nineteen studies reviewed specifically explored the impact of AI assistance on clinicians' ability to detect PRLs [24, 31, 39]. Results are presented in Table 4; Fig. 5.

In Ezhov's study [39], unaided dentists exhibited sensitivity values ranging from 0.2045 to 0.6830, with a median of 0.4625 and a mean (± standard deviation) of 0.4531 (± 0.2275). Following the introduction of the AI assistant, clinicians' sensitivity values improved greatly, ranging from 0.4318 to 0.8304, with a median of 0.6148 and a mean (± standard deviation) of 0.6230 (± 0.1818) underscoring the positive impact of AI assistance on the accurate identification of true positives (Fig. 5, images A and C). Meanwhile, specificity values remained consistently high, with a nominal decrease from a median of 0.9676 to 0.9643 and a mean (± standard deviation) of 0.9659 (± 0.0182) to 0.9632 (+ 0.0315) (Fig. 5, images A and C). This slight variation indicates that using the AI model did not impact the clinician's ability to correctly identify true negatives. Similar results were observed in Li's study [31] (Fig. 5, images B and D), which showed higher overall sensitivity improvement using its AI model, further endorsing the potential of AI tools for enhancing the radiographic detection of PRLs in dental x-rays.

In Hamdan's study, using AI resulted in an 8.6% increase in AFROC AUC compared to unaided evaluations ($p = 0.005$), indicating significant improvements in clinicians' ability to localize and accurately detect PRLs in periapical radiographs. Also, specificity by case improved by 23.1% ($p = 0.005$), and sensitivity by lesion increased by 8.2% ($p = 0.01$) with AI assistance, further reflecting enhanced localization and detection of PRLs. Finally, sensitivity by case mainly remained unchanged ($p = 0.712$) (Fig. 5, image E).

Discussion

AP is a prevalent inflammatory disease targeting the periapical tissues of teeth. It is radiographically identified by the presence of PRLs at the tooth's apex. While this may suggest a straightforward diagnosis on paper, clinical reality is often fraught with significant challenges and inconsistencies, largely attributed to clinician subjectivity [3]. The recent integration of AI tools into the standard workflow of dental healthcare promises to change this paradigm, enhancing both the accuracy and consistency of AP diagnosis [17]. This scoping review explored the scientific literature on the application of ML and DL algorithms for the specific purpose of diagnosing AP, offering a comprehensive synthesis of the existing evidence and current advancements within the field. While related reviews have addressed AI in the field of endodontics [48, 49], our study distinguishes itself by focusing specifically on the application of AI technologies for AP diagnosis.

In addressing our primary research question, our main findings reveal that current research on AP diagnosis is solely focused on using AI models for identifying PRLs in dental radiographs. Moreover, a significant void in studies investigating AI's capabilities to enhance alternative diagnostic methods, such as clinical record analysis, biomarker identification, biopsy analysis, and other non-radiographic diagnostic approaches was noted. Altogether, these omissions highlight an important gap in the literature of this field, suggesting that the full scope of AI's capabilities for AP diagnosis remains largely unexplored and thus should be further explored in the future with a broadened scope.

Concerning the use of AI for PRL detection, it is important to notice that the earliest studies on this topic were published in 2015 [25, 26]. Nevertheless, a pronounced increase in the number of scientific articles related to this matter was observed in the past two years alone [27–37]. We believe this aligns with AI technologies' rapid growth and democratization in recent years, facilitated by open-source platforms like OpenAI's ChatGPT-4 and Google's BARD. These platforms have made AI more understandable and accessible to the general public, empowering individuals with and without in-depth AI training to experiment with, create, and apply AI solutions for different problems [50, 51]. We believe that this shift has spurred innovation across several scientific fields, including dentistry, acting as a key driver in the expansion of the literature regarding the applications of AI for AP diagnosis through the detection of PRLs.

Most of the evidence in this research topic originates from countries within the EU [26–29, 38], Turkey [25, 30, 36, 39, 40], China [31, 37, 41], and India [33, 34]. This geographical distribution likely reflects the competitive dynamics of the so-called "AI race", in which these nations are striving for global leadership and innovation in AI [52]. We identified only one study from the USA [42], despite its significant role in AI initiatives across other fields [52]. This discrepancy may be attributed to differences in regulatory and ethical approval processes governing AI research. The EU recently enacted the AI Act, providing a comprehensive legal framework designed to foster human-centric and trustworthy AI while ensuring patient safety and promoting innovation [53]. In contrast, the absence of a federal AI law in the USA may compel researchers to independently navigate

Table 3 Comprehensive sensitivity, specificity, and performance metrics of AI models in PRL diagnosis

Reference	SENS	SPEC	REC	ACC	PREC	F1 Score	AUC-ROC	Cross-validation	AUC-PR	MSE	RMSE	MAE	R^2
[39]	Periapical lesion: 0.8383 Periapical lesion, PDL widening: 0.7587 Ill-defined radiolucency: 0.6957 Well-defined radiolucency: 0.729	Periapical lesion: 0.9953 Periapical lesion, PDL widening: 0.9807 Ill-defined radiolucency: 0.9942 Well-defined radiolucency: 0.9974	N/R	N/R	N/R	N/R	N/R	N/R	N/R	N/R	N/R	N/R	N/R
[37]	Periapical periodontitis: 1 Periapical cyst: 1	Periapical periodontitis: 0.9930 Periapical cyst: 1	N/R	Periapical periodontitis: 0.9950 Periapical cyst: 1	N/R	N/R	N/R	N/R	N/R	N/R	N/R	N/R	N/R
[42]	0.92	0.88	N/R	0.93	0.87	N/R	N/R	Five-fold	N/R	N/R	N/R	N/R	N/R
[41]	N/R	N/R	0.5353	N/R	0.5508	N/R	N/R	N/R	N/R	N/R	N/R	N/R	N/R
[36]	0.92	N/R	N/R	N/R	0.84	0.88	N/R	N/R	N/R	N/R	N/R	N/R	N/R
[35]	N/R	N/R	0.3 IoU: 0.826 0.4 IoU: 0.8080 0.5 IoU: 0.7400	N/R	0.3 IoU: 0.831 0.4 IoU: 0.8220 0.5 IoU: 0.7440	N/R	N/R	N/R	N/R	N/R	N/R	N/R	N/R
[40]	N/R	N/R	0.89	N/R	0.95	0.93	N/R	N/R	N/R	N/R	N/R	N/R	N/R
[26]	N/R	N/R	N/R	0.8570	N/R	N/R	N/R	Seven-fold	N/R	N/R	N/R	N/R	N/R
[38]	N/R	N/R	N/R	0.60	N/R	0.58	N/R	N/R	N/R	N/R	N/R	N/R	N/R
[34]	0.9210	0.76	0.89	N/R	0.8630	0.89	N/R	N/R	N/R	N/R	N/R	N/R	N/R
[33]	N/R	0.93	0.86	0.92	0.72	0.78	N/R	N/R	N/R	N/R	N/R	N/R	N/R
[32]	Inception v3: 0.81 VGG-16: 0.76 Xception: 0.77	Inception v3: 0.86 VGG-16: 0.82 Xception: 0.79	N/R	N/R	Inception v3: 0.84 VGG-16: 0.79 Xception: 0.78	N/R	N/R	N/R	N/R	N/R	N/R	N/R	N/R
[25]	0.70	0.89	N/R	N/R	N/R	N/R	N/R	N/R	N/R	N/R	N/R	N/R	N/R
[31]	0.82	0.84	N/R	N/R	N/R	0.8283	0.8790	N/R	N/R	N/R	N/R	N/R	N/R
[30]	N/R	N/R	0.56	0.98	0.71	N/R	N/R	N/R	N/R	N/R	N/R	N/R	N/R
[29]	0.9230	0.9787	N/R	0.9666	N/R	0.9200	N/R	N/R	N/R	N/R	N/R	N/R	N/R

Table 3 (continued)

Reference	SENS	SPEC	REC	ACC	PREC	F1 Score	AUC-ROC	Cross-validation	AUC-PR	MSE	RMSE	MAE	R^2
[28]	Radicular cysts: 1 Periapical granuloma: 0.77	Radicular cysts: 0.95 Periapical granuloma: 1	N/R	N/R	Radicular cyst: 0.83 Periapical granuloma: 0.74	N/R	Radicular cysts: 0.97 Periapical granu-loma: 0.88	10-fold	N/R	N/R	N/R	N/R	N/R
[27]	0.867	0.843	N/R	N/R	N/R	N/R	N/R	4-fold	N/R	N/R	N/R	N/R	N/R
[24]	*	*	*	*	*	*	*	*	*	*	*	*	*

ML, Machine learning; DL, Deep learning; PRLs, Periapical radiolucent lesions; SENS, Sensitivity; SPEC, Specificity; REC, Recall; ACC, Accuracy; PREC, Precision; AUC-ROC, Area under the curve of the receiver operating characteristic curve; AUC-PR, Area under the precision-recall curve; MSE, Mean squared error; RMSE, Root mean squared error; MAE, Mean absolute error; R^2, r-squared or coefficient of determination; N/R, Not reported

* This study tested a previously developed AI model (Denti.AI, Denti.AI Technology Inc., Toronto, CA). The study does not provide metrics for the stand-alone performance of the model

varying and extensive state and sector-specific regulations, potentially slowing the pace of AI research in certain sectors [54]. Another possible explanation could be that, despite our efforts to develop a comprehensive search strategy for this review, our approach may have inadvertently missed some relevant literature on this topic. This is a common limitation reported in scoping reviews [55], as it has been acknowledged that retrieving and screening all relevant literature in a scoping review may be unrealistic due to its broader focus compared to systematic reviews [55, 56].

In addressing the secondary question, "*What are the predominant AI techniques*, *models*, *algorithms*, *and tasks used for AP diagnosis?*" we observed a pronounced preference for DL methods over traditional ML techniques. This was not always the case, as earlier studies predominantly employed ML methodologies [25, 26]. We believe this shift stems from recent advancements in the fields of AI and computer sciences. Given that DL represents a more specialized branch within ML, capable of processing complex data through CNNs that mimic the human brain's structure [8, 10], it is logical for newer publications to increasingly focus on and rely upon DL approaches over traditional ML. In addition, DL enhances the process of image recognition by automating data feature extraction and learning from its own errors autonomously, thereby reducing the need for human intervention and providing a more efficient method for tackling complex problems [8, 10]. CNNs were also the most widely used model within the DL studies [27–42], which is a trend frequently seen in computer vision applications [57]. CNNs have gained popularity due to their remarkable ability to automatically detect significant features within complex databases [57]. Moreover, their architecture is inherently flexible, allowing for easy customization and scalability through the addition of more neural layers, which enhances their utility in PRL identification [57].

When addressing the question, "*What are the characteristics that define the main datasets utilized in the field*?" we came across the realization that the majority of primary data sources were two-dimensional dental radiographs [25, 28–38, 41], rather than CBCT scans [26, 27, 39, 40, 42]. This is not surprising, as research on this topic focuses on the detection of PRLs in dental radiographs, and although useful, CBCT scans are still a diagnostic resource very underutilized in the daily practice of many clinicians [58]. Considerable variation in the size of the used datasets was also observed across studies. Some studies employed over a thousand images for the purposes of training, validation, and testing, while others utilized relatively smaller datasets, performing preprocessing techniques to artificially expand their size. Although common sense could lead us to assume bigger datasets are better for model training, recent evidence suggests that data quality is more crucial than quantity for

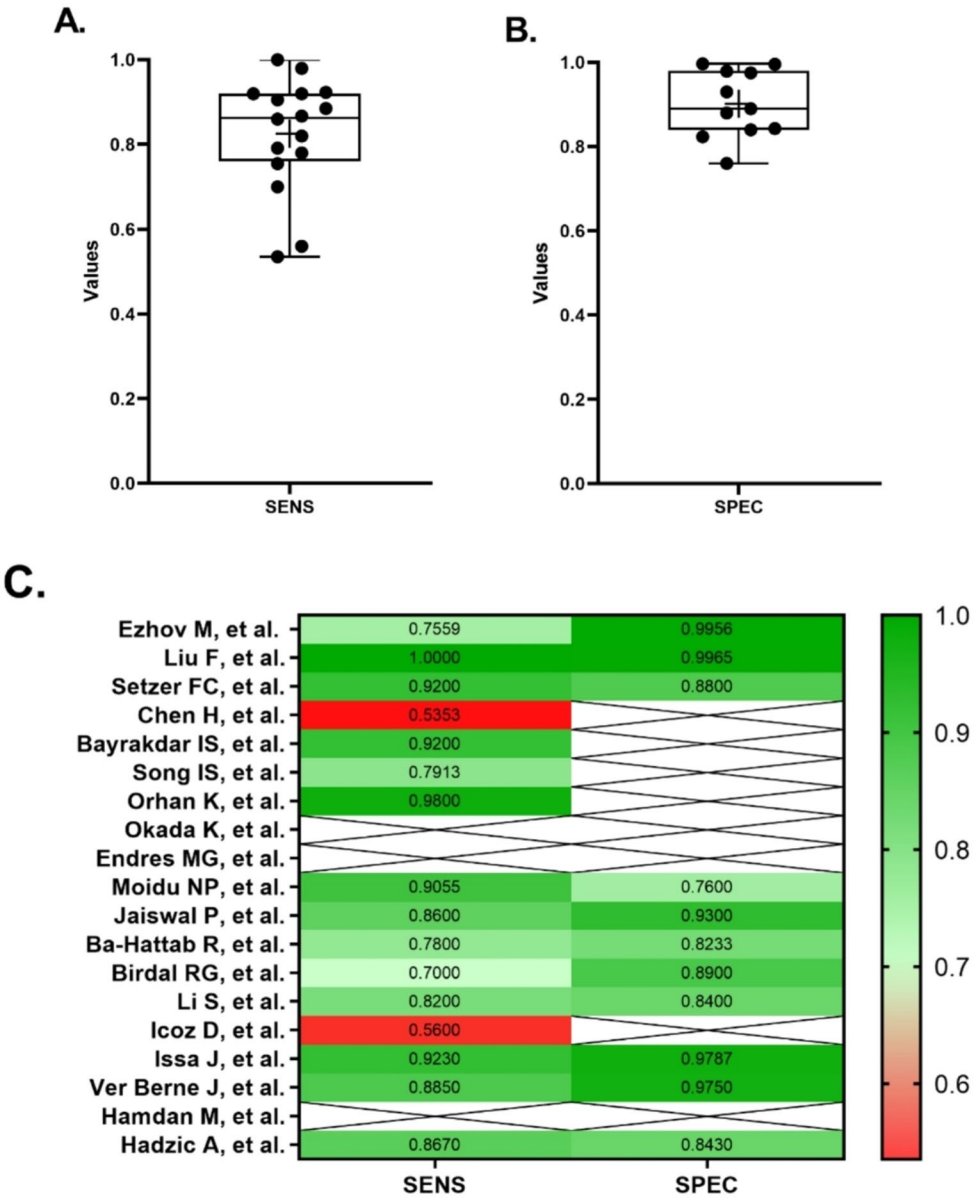

Fig. 3 Comparative analysis of AI model performance in PRL diagnosis across reviewed studies. (**A**) Boxplot of pooled sensitivity (SENS), (**B**) Boxplot of pooled specificity (SPEC), and (**C**) Heatmap of mean sensitivity (SENS) and specificity (SPEC) by Study. Dots in the boxplot graphics represent each study, + = mean; central line = median, whiskers set to min. and max

models' performance [59]. While bigger datasets can provide more information for models to learn from and reduce the risk of overfitting, they can also introduce noise, outliers, and irrelevant information that may decrease accuracy [59]. Therefore, we believe that prioritizing the quality and representativeness of the radiographic datasets used in this field of research should be more important than focusing excessively on their quantity, and that this priority should remain in place until a broader consensus is reached regarding what constitutes an adequate dataset for this specific domain.

A more problematic subject came when analyzing the different methods employed for the training of the AI models. Our findings revealed that most studies relied on human clinicians to label their images; however, we observed notable differences in their levels of expertise and specializations. Additionally, there was no standard definition for what constituted a PRL in dental radiographs nor what could be considered healthy periapical tissues. This lack of standardized definitions, along with the heterogenicity in clinicians' years of expertise and specialty training, introduce considerable inconsistencies and variability in the training methodologies of these models, consequently affecting the impact and reliability of the model's diagnostic performance as well as its generalizability in real-world settings.

When addressing the question, "*What is the diagnostic performance of current ML and DL models in diagnosing AP?*" our analysis revealed that contemporary AI models demonstrated a diagnostic performance comparable to Cone-Beam Computed Tomography (CBCT), with a

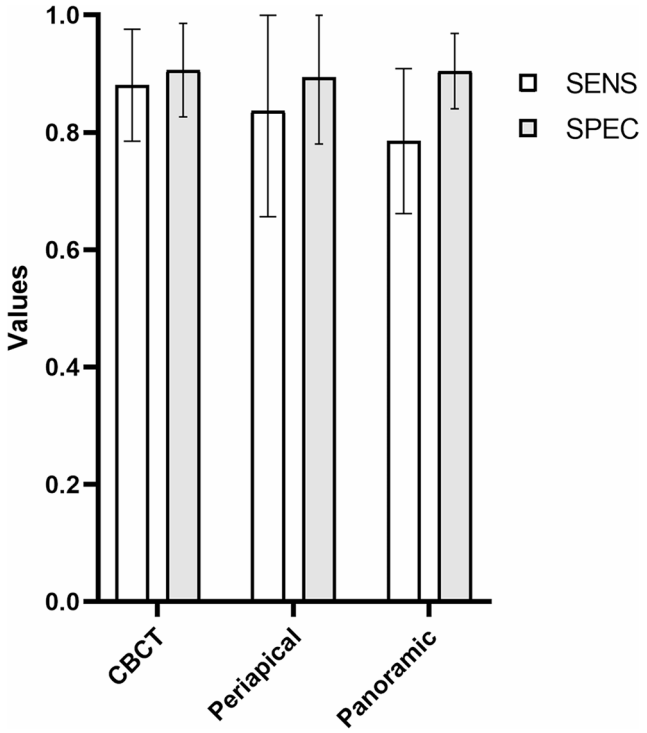

Fig. 4 Pooled sensitivity (SENS) and specificity (SPEC) of AI models by radiograph type (mean ± standard deviation)

marginally lower but still acceptable average sensitivity of 88% and a matching specificity of 90%. Research indicates that CBCT scans offer superior diagnostic accuracy than periapical radiographs, detecting PRLs in 84% of AP cases compared to the 71% accuracy rate associated with periapical radiographs [4]. Consequently, CBCT scans are currently considered the radiographical gold standard for PRL identification [60], with average sensitivity and specificity rates of 95% and 90%, respectively [61]. A recent 2023 meta-analysis by Abesi and Golkani further supports these figures, reporting pooled sensitivity and specificity rates of 94.6% and 91.2% for CBCTs, respectively [62]. The close performance of reviewed AI models to this gold standard indicates that AI tools have a significant and transformative potential for PRL identification and will likely become important assets for AP diagnosis in the future, particularly given the advancements expected in the field over the next decade.

In the context of periapical radiographs, the AI models evaluated in this review demonstrated remarkable efficacy, achieving sensitivity and specificity values that surpassed those of human experts reported in previous investigations. For instance, a systematic review and meta-analysis by Mostafapoor and colleagues in 2021 found that stand-alone clinicians achieved average sensitivity and specificity rates of 50% and 83% when identifying PRLs using periapical

Table 4 Comparative sensitivity and specificity for AI-aided and unaided clinician evaluations in PRL diagnosis

Reference	UNAIDED					AIDED				
	SENS	SPEC	F1 Score	AUC-ROC	AFROC AUC	SENS	SPEC	F1 Score	AUC-ROC	AFROC AUC
[39]	Periapical lesion: 0.6830 Periapical lesion, PDL widening: 0.3202 Ill-defined radiolucency: 0.2045 Well-defined radiolucency: 0.6048	Periapical lesion: 0.9465 Periapical lesion, PDL widening: 0.9542 Ill-defined radiolucency: 0.9810 Well-defined radiolucency: 0.9817	N/R	N/R	N/P	Periapical lesion: 0.8304 Periapical lesion, PDL widening: 0.5161 Ill-defined radiolucency: 0.4318 Well-defined radiolucency: 0.7135	Periapical lesion: 0.9388 Periapical lesion, PDL widening: 0.9332 Ill-defined radiolucency: 0.9897 Well-defined radiolucency: 0.9912	N/R	N/R	N/P
[31]	Dentist 1: 0.4000 Dentist 2: 0.4850 Dentist 3: 0.5150	Dentist 1: 0.9350 Dentist 2: 0.9000 Dentist 3: 0.9200	Dentist 1: 0.5461 Dentist 2: 0.6120 Dentist 3: 0.6458	Dentist 1: 0.6680 Dentist 2: 0.6930 Dentist 3: 0.7810	N/P	Dentist 1: 0.7000 Dentist 2: 0.7400 Dentist 3: 0.7950	Dentist 1: 0.9400 Dentist 2: 0.8950 Dentist 3: 0.9250	Dentist 1: 0.7955 Dentist 2: 0.8022 Dentist 3: 0.8503	Dentist 1: 0.8200 Dentist 2: 0.8100 Dentist 3: 0.8600	N/P
[24]	By case: 0.938 By lesion: 0.821	By case: 0.596	N/P	N/P	0.822	By case: 0.931 By lesion: 0.888	By case: 0.733	N/P	N/P	0.892

SENS, Sensitivity; SPEC, Specificity; AUC-ROC, Area under the curve of the receiver operating characteristic curve; AFROC AUC, Alternative free-response receiver operating characteristic area under the curve; PDL, Periodontal ligament; N/R, Not reported; N/P, Not performed

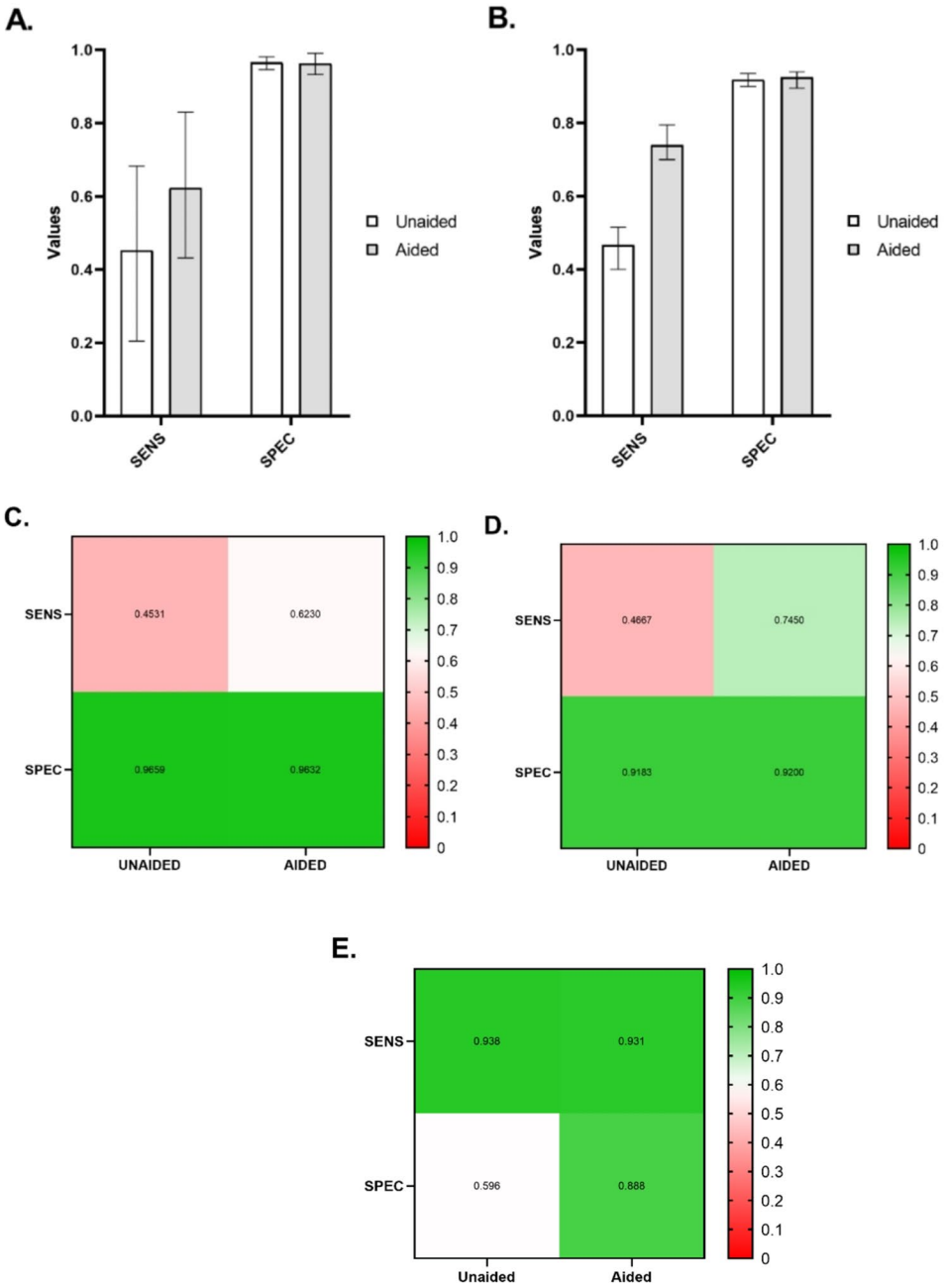

Fig. 5 Comparative analysis of sensitivity (SENS) and specificity (SPEC) for aided and unaided clinicians. (**A**) Bar graph depicting average and range sensitivity (SENS) and specificity (SPEC) for aided and unaided clinicians in Ezhov's study; (**B**) Bar graph depicting average and range sensitivity (SENS) and specificity (SPEC) for aided and unaided clinicians in Li's study, (**C**) Heatmap of mean sensitivity (SENS) and specificity (SPEC) in Ezhov's study, (**D**) Heatmap of mean sensitivity (SENS) and specificity (SPEC) in Li's study, (**E**) Heatmap of mean sensitivity (SENS) and specificity (SPEC) in Hamdan's study

radiographs [61]. In contrast, our findings showed that contemporary AI models comfortably surpassed these figures, achieving average sensitivity and specificity rates of 84% and 89%, respectively. This pattern of enhanced performance by AI models was similarly observed in the analysis of panoramic radiographs: while stand-alone clinicians have been reported to achieve an average sensitivity and specificity of 28% and 100%, respectively [63], AI models in this review demonstrated a significant improvement, with a mean sensitivity of 79% and specificity of 90%. This enhancement in PRL detection highlights the substantial potential of AI models to enhance the diagnostic precision of AP diagnosis through the correct identification of PRLs in two-dimensional radiographs.

In response to the last secondary question, "*What impact does AI assistance have on the diagnostic performance of human clinicians diagnosing AP?*" the studies included in this scoping review consistently highlight the advantageous role of AI in enhancing clinicians' diagnostic accuracy, particularly by improving sensitivity without detrimentally compromising specificity [31, 39]. In other words, the AI models reviewed here significantly boosted the clinicians' ability to correctly identify PRLs in dental radiographs while avoiding an increase in the occurrence of false positives or

misdiagnoses. This improvement in the identification of true PRL cases, coupled with maintained and typically high specificity, enhances the precision of AP diagnosis while addressing the long-standing issue of clinician subjectivity in radiographic interpretation. This development may well represent one of the most notable advancements in the radiographic diagnosis of AP in the past decade.

Limitations

Results from this work should be interpreted with caution due to the inherent limitations associated with scoping reviews. Firstly, we did not assess the quality or risk of bias in the included studies, as this is not typically required for this type of review. Additionally, the broad nature of the research question and the time constraints usually associated with a scoping review design may have limited our ability to capture all relevant research on this particular topic. Furthermore, the diverse nature of the scientific body literature of gathered in this work poses challenges in achieving a concise synthesis of results. Notable methodological differences and reporting omissions were found across some of the included studies, making it difficult to make comparisons. Finally, none of the included articles presented techniques that could address potential racial and ethnic biases in the algorithms, and complex questions such as when and how these technologies should be used remain unanswered.

Conclusion

Current AI efforts in the field are primarily focused on enhancing the radiographic aspects of AP diagnosis through the precise identification of PRLs in dental radiographs. This progress has been achieved thanks to the use of CNN-based DL algorithms, which are specially designed for computer vision tasks like image segmentation, classification, and object detection. Most of the datasets in this field consist of digital images from periapical and panoramic evaluations, with about a third deriving from CBCT scans. Importantly, we noted considerable heterogeneity in dataset sizes and image preprocessing and labeling approaches, highlighting the need for standardized industry practices to ensure consistency and comparability across studies.

Overall, the diagnostic performance of the reviewed models is promising, with an average sensitivity of 83% and a specificity of 90%. This reflects contemporary AI models' substantial effectiveness and potential for AP diagnosis by accurately detecting PRLs in dental radiographs. Although limited, preliminary studies on AI-assisted diagnostics show these technologies can bolster clinicians' sensitivity without compromising their specificity, representing a notable advancement in mitigating human subjectivity in the radiographic diagnosis of AP.

As we look into the future, it is crucial that research in this domain expands beyond radiographic analysis to include other aspects of AP diagnosis, such as clinical record analysis and biomarker discovery. Only then we will we be able to unlock the full potential of AI in AP diagnostics. Furthermore, additional studies are still needed to effectively test these algorithms in large-scale clinical settings and to address critical concerns regarding potential racial and ethnic biases, as well as how and when these technologies should be used.

Acknowledgements The authors wish to express their profound acknowledgement of the outstanding contributions made by all members of the Department of Oral Medicine and Pathology at the Faculty of Dentistry, Universidad Andrés Bello, Santiago. Special recognition is extended to Dr. Felipe Cáceres, Dra. Daniela Cavagnola, and Dra. Magdalena Pinto for their invaluable insights and support throughout this research.

Author contributions A.S and C.J had the idea for this article. Material preparation, literature search, and data collection/analysis were performed by A.B, F.S, A.S and C.J. The first draft of the manuscript was written by A.B, F.S, and C.J. Subsequent revisions were undertaken by M.H, A.F, A.S and C.J. All authors critically revised the work and approved the final manuscript.

Funding This study was funded by the National Fund for Scientific and Technological Development (FONDECYT), Chile, under grant number 11240301.

Data availability No datasets were generated or analysed during the current study.

Declarations

Ethical approval For this scoping review study, the Ethics and Scientific Committee at Universidad Andrés Bello determined that no ethical approval was required.

Employment The authors declare that they have no employment disclosures.

Financial & non-financial interests The authors have no relevant financial or non-financial interests to disclose.

Competing interests The authors declare no competing interests.

References

1. Tiburcio-Machado CS, Michelon C, Zanatta FB, Gomes MS, Marin JA, Bier CA (2021) The global prevalence of apical periodontitis: a systematic review and meta-analysis. Int Endod J 54:712–735. https://doi.org/10.1111/iej.13467
2. Patel S, Durack C (2019) Radiology of Apical Periodontitis. In: Essential Endodontology, D. Ørstavik (Ed.) Book title. https://doi.org/10.1002/9781119272014.ch6

3. Gliga A, Imre M, Grandini S, Marruganti C, Gaeta C, Bodnar D, Dimitriu BA, Foschi F (2023) The limitations of Periapical X-ray Assessment in Endodontic Diagnosis-A systematic review. J Clin Med 12. https://doi.org/10.3390/jcm12144647
4. De Paula-Silva FW, Wu MK, Leonardo MR, da Silva LA, Wesselink PR (2009) Accuracy of periapical radiography and cone-beam computed tomography scans in diagnosing apical periodontitis using histopathological findings as a gold standard. J Endod 35:1009–1012. https://doi.org/10.1016/j.joen.2009.04.006
5. Tanomaru-Filho M, Jorge EG, Duarte MA, Goncalves M, Guerreiro-Tanomaru JM (2009) Comparative radiographic and histological analyses of periapical lesion development. Oral Surg Oral Med Oral Pathol Oral Radiol Endod 107:442–447. https://doi.org/10.1016/j.tripleo.2008.12.009
6. Patel S, Brown J, Pimentel T, Kelly RD, Abella F, Durack C (2019) Cone beam computed tomography in Endodontics - a review of the literature. Int Endod J 52:1138–1152. https://doi.org/10.1111/iej.13115
7. Sirotheau Correa Pontes F, Paiva Fonseca F, Souza de Jesus A, Garcia Alves AC, Marques Araujo L, Silva do Nascimento L and Rebelo, Pontes HA (2014) Nonendodontic lesions misdiagnosed as apical periodontitis lesions: series of case reports and review of literature. J Endod 40:16–27. https://doi.org/10.1016/j.joen.2013.08.021
8. Briganti G (2023) Artificial intelligence: an introduction for clinicians. Rev Mal Respir 40:308–313. https://doi.org/10.1016/j.rmr.2023.02.005
9. Choi RY, Coyner AS, Kalpathy-Cramer J, Chiang MF, Campbell JP (2020) Introduction to machine learning, neural networks, and Deep Learning. Transl Vis Sci Technol 9:14. https://doi.org/10.1167/tvst.9.2.14
10. Lidströmer N, Aresu F, Ashrafian H (2022) Basic concepts of Artificial Intelligence: primed for clinicians. In: Lidströmer N, Ashrafian H (eds) Book title. Springer International Publishing, Cham
11. Bindra S, Jain R (2023) Artificial intelligence in medical science: a review. Ir J Med Sci Doi. https://doi.org/10.1007/s11845-023-03570-9
12. Wang H, Zhu H, Ding L (2022) Accurate classification of lung nodules on CT images using the TransUnet. Front Public Health 10:1060798. https://doi.org/10.3389/fpubh.2022.1060798
13. Kowalewski KF, Egen L, Fischetti CE, Puliatti S, Juan GR, Taratkin M, Ines RB, Sidoti Abate MA, Muhlbauer J, Wessels F, Checcucci E, Cacciamani G, Young Academic Urologists U-G (2022) Artificial intelligence for renal cancer: from imaging to histology and beyond. Asian J Urol 9:243–252. https://doi.org/10.1016/j.ajur.2022.05.003
14. Salehi MA, Mohammadi S, Harandi H, Zakavi SS, Jahanshahi A, Shahrabi Farahani M, Wu JS (2024) Diagnostic performance of Artificial Intelligence in detection of primary malignant bone tumors: a Meta-analysis. J Imaging Inf Med. https://doi.org/10.1007/s10278-023-00945-3
15. Ding H, Wu J, Zhao W, Matinlinna JP, Burrow MF, Tsoi JKH (2023) Artificial intelligence in dentistry—A review. Front Dent Med 4. https://doi.org/10.3389/fdmed.2023.1085251
16. Khanagar SB, Al-Ehaideb A, Maganur PC, Vishwanathaiah S, Patil S, Baeshen HA, Sarode SC, Bhandi S (2021) Developments, application, and performance of artificial intelligence in dentistry - A systematic review. J Dent Sci 16:508–522. https://doi.org/10.1016/j.jds.2020.06.019
17. Thurzo A, Urbanova W, Novak B, Czako L, Siebert T, Stano P, Marekova S, Fountoulaki G, Kosnacova H, Varga I (2022) Where is the Artificial Intelligence Applied in Dentistry? Systematic Review and Literature Analysis. Healthc (Basel) 10. https://doi.org/10.3390/healthcare10071269
18. Schwendicke F, Golla T, Dreher M, Krois J (2019) Convolutional neural networks for dental image diagnostics: a scoping review. J Dent 91:103226. https://doi.org/10.1016/j.jdent.2019.103226
19. Hamdan M (2021) Detecting apical radiolucencies using deep learning technology. Master of Science thesis, The University of North Carolina at Chapel Hill
20. Arksey H, O'Malley L (2005) Scoping studies: towards a methodological framework. Int J Soc Res Methodol 8:19–32. https://doi.org/10.1080/1364557032000119616
21. Levac D, Colquhoun H, O'Brien KK (2010) Scoping studies: advancing the methodology. Implement Sci 5:69. https://doi.org/10.1186/1748-5908-5-69
22. MDJ P, C G, Z PM M, AC T and H K (2020) Chap. 11: scoping reviews (2020 version). In: Z M (ed) Book title. JBI, JBI
23. Tricco AC, Lillie E, Zarin W, O'Brien KK, Colquhoun H, Levac D, Moher D, Peters MDJ, Horsley T, Weeks L, Hempel S, Akl EA, Chang C, McGowan J, Stewart L, Hartling L, Aldcroft A, Wilson MG, Garritty C, Lewin S, Godfrey CM, Macdonald MT, Langlois EV, Soares-Weiser K, Moriarty J, Clifford T, Tuncalp O, Straus SE (2018) PRISMA Extension for scoping reviews (PRISMA-ScR): Checklist and Explanation. Ann Intern Med 169:467–473. https://doi.org/10.7326/M18-0850
24. Hamdan MH, Tuzova L, Mol A, Tawil PZ, Tuzoff D, Tyndall DA (2022) The effect of a deep-learning tool on dentists' performances in detecting apical radiolucencies on periapical radiographs. Dentomaxillofac Radiol 51:20220122. https://doi.org/10.1259/dmfr.20220122
25. Birdal RG, Gumus E, Sertbas A, Birdal IS (2015) Automated lesion detection in panoramic dental radiographs. Oral Radiol 32:111–118. https://doi.org/10.1007/s11282-015-0222-8
26. Okada K, Rysavy S, Flores A, Linguraru MG (2015) Noninvasive differential diagnosis of dental periapical lesions in cone-beam CT scans. Med Phys 42:1653–1665. https://doi.org/10.1118/1.4914418
27. Hadzic A, Urschler M, Press JA, Riedl R, Rugani P, Stern D, Kirnbauer B (2023) Evaluating a Periapical Lesion Detection CNN on a clinically Representative CBCT Dataset-A validation study. J Clin Med 13. https://doi.org/10.3390/jcm13010197
28. Ver Berne J, Saadi SB, Politis C, Jacobs R (2023) A deep learning approach for radiological detection and classification of radicular cysts and periapical granulomas. J Dent 135:104581. https://doi.org/10.1016/j.jdent.2023.104581
29. Issa J, Jaber M, Rifai I, Mozdziak P, Kempisty B, Dyszkiewicz-Konwinska M (2023) Diagnostic test accuracy of Artificial Intelligence in detecting Periapical Periodontitis on two-dimensional radiographs: a Retrospective Study and Literature Review. Med (Kaunas) 59. https://doi.org/10.3390/medicina59040768
30. Icoz D, Terzioglu H, Ozel MA, Karakurt R (2023) Evaluation of an artificial intelligence system for the diagnosis of apical periodontitis on digital panoramic images. Niger J Clin Pract 26:1085–1090. https://doi.org/10.4103/njcp.njcp_624_22
31. Li S, Liu J, Zhou Z, Zhou Z, Wu X, Li Y, Wang S, Liao W, Ying S, Zhao Z (2022) Artificial intelligence for caries and periapical periodontitis detection. J Dent 122:104107. https://doi.org/10.1016/j.jdent.2022.104107
32. Ba-Hattab R, Barhom N, Osman S, Naceur I, Odeh A, Asad A, Al-Najdi S, Ameri E, Daer A, Silva R, Costa C, Cortes A, Tamimi F (2023) Detection of Periapical Lesions on panoramic radiographs using deep learning. Appl Sci 13. https://doi.org/10.3390/app13031516
33. Jaiswal P, Katkar V, Bhirud SG (2022) Multi oral disease classification from panoramic radiograph using transfer learning and XGBoost. Int J Adv Comput Sci Appl 13:11. https://doi.org/10.14569/ijacsa.2022.0131230
34. Moidu NP, Sharma S, Chawla A, Kumar V, Logani A (2022) Deep learning for categorization of endodontic lesion based on

radiographic periapical index scoring system. Clin Oral Investig 26:651–658. https://doi.org/10.1007/s00784-021-04043-y
35. Song IS, Shin HK, Kang JH, Kim JE, Huh KH, Yi WJ, Lee SS, Heo MS (2022) Deep learning-based apical lesion segmentation from panoramic radiographs. Imaging Sci Dent 52:351–357. https://doi.org/10.5624/isd.20220078
36. Bayrakdar IS, Orhan K, Celik O, Bilgir E, Saglam H, Kaplan FA, Gorur SA, Odabas A, Aslan AF, Rozylo-Kalinowska I (2022) A U-Net Approach to apical lesion segmentation on panoramic radiographs. Biomed Res Int 2022:7035367. https://doi.org/10.1155/2022/7035367
37. Liu F, Gao L, Wan J, Lyu ZL, Huang YY, Liu C, Han M (2023) Recognition of Digital Dental X-ray images using a convolutional neural network. J Digit Imaging 36:73–79. https://doi.org/10.1007/s10278-022-00694-9
38. Endres MG, Hillen F, Salloumis M, Sedaghat AR, Niehues SM, Quatela O, Hanken H, Smeets R, Beck-Broichsitter B, Rendenbach C, Lakhani K, Heiland M, Gaudin RA (2020) Development of a deep learning algorithm for Periapical Disease Detection in Dental radiographs. Diagnostics (Basel) 10. https://doi.org/10.3390/diagnostics10060430
39. Ezhov M, Gusarev M, Golitsyna M, Yates JM, Kushnerev E, Tamimi D, Aksoy S, Shumilov E, Sanders A, Orhan K (2021) Clinically applicable artificial intelligence system for dental diagnosis with CBCT. Sci Rep 11:15006. https://doi.org/10.1038/s41598-021-94093-9
40. Orhan K, Bayrakdar IS, Ezhov M, Kravtsov A, Ozyurek T (2020) Evaluation of artificial intelligence for detecting periapical pathosis on cone-beam computed tomography scans. Int Endod J 53:680–689. https://doi.org/10.1111/iej.13265
41. Chen H, Li H, Zhao Y, Zhao J, Wang Y (2021) Dental disease detection on periapical radiographs based on deep convolutional neural networks. Int J Comput Assist Radiol Surg 16:649–661. https://doi.org/10.1007/s11548-021-02319-y
42. Setzer FC, Shi KJ, Zhang Z, Yan H, Yoon H, Mupparapu M, Li J (2020) Artificial Intelligence for the computer-aided detection of Periapical Lesions in Cone-Beam Computed Tomographic images. J Endod 46:987–993. https://doi.org/10.1016/j.joen.2020.03.025
43. Hicks SA, Strumke I, Thambawita V, Hammou M, Riegler MA, Halvorsen P, Parasa S (2022) On evaluation metrics for medical applications of artificial intelligence. Sci Rep 12:5979. https://doi.org/10.1038/s41598-022-09954-8
44. Monaghan TF, Rahman SN, Agudelo CW, Wein AJ, Lazar JM, Everaert K, Dmochowski RR (2021) Foundational statistical principles in Medical Research: sensitivity, specificity, positive predictive value, and negative predictive value. Med (Kaunas) 57. https://doi.org/10.3390/medicina57050503
45. Ahmad OF, Mori Y, Misawa M, Kudo SE, Anderson JT, Bernal J, Berzin TM, Bisschops R, Byrne MF, Chen PJ, East JE, Eelbode T, Elson DS, Gurudu SR, Histace A, Karnes WE, Repici A, Singh R, Valdastri P, Wallace MB, Wang P, Stoyanov D, Lovat LB (2021) Establishing key research questions for the implementation of artificial intelligence in colonoscopy: a modified Delphi method. Endoscopy 53:893–901. https://doi.org/10.1055/a-1306-7590
46. Varoquaux G, Colliot O (2023) Evaluating Machine Learning Models and Their Diagnostic Value. In: Colliot O (ed) Book title., New York, NY
47. Erickson BJ, Kitamura F (2021) Magician's corner: 9. Performance Metrics for Machine Learning models. Radiol Artif Intell 3:e200126. https://doi.org/10.1148/ryai.2021200126
48. Umer F, Habib S (2022) Critical Analysis of Artificial Intelligence in Endodontics: a scoping review. J Endod 48:152–160. https://doi.org/10.1016/j.joen.2021.11.007
49. Asiri AF, Altuwalah AS (2022) The role of neural artificial intelligence for diagnosis and treatment planning in endodontics: a qualitative review. Saudi Dent J 34:270–281. https://doi.org/10.1016/j.sdentj.2022.04.004
50. Bohr A, Memarzadeh K (2020) Chap. 2 - the rise of artificial intelligence in healthcare applications. In: Bohr A, Memarzadeh K (eds) Book title. Academic
51. Noorman M, Swierstra T (2023) Democratizing AI from a Sociotechnical Perspective. Mind Mach 33:563–586. https://doi.org/10.1007/s11023-023-09651-z
52. Castro D (2019) Who is winning the AI race: China, the EU or the United States? Center for Data Innovation. https://futurium.ec.europa.eu/en/european-ai-alliance/open-library/who-winning-ai-race-china-eu-or-united-states. Accessed Acces Date 2023
53. Gilbert S (2024) The EU passes the AI act and its implications for digital medicine are unclear. NPJ Digit Med 7:135. https://doi.org/10.1038/s41746-024-01116-6
54. He J, Baxter SL, Xu J, Xu J, Zhou X, Zhang K (2019) The practical implementation of artificial intelligence technologies in medicine. Nat Med 25:30–36. https://doi.org/10.1038/s41591-018-0307-0
55. Pham MT, Rajic A, Greig JD, Sargeant JM, Papadopoulos A, McEwen SA (2014) A scoping review of scoping reviews: advancing the approach and enhancing the consistency. Res Synth Methods 5:371–385. https://doi.org/10.1002/jrsm.1123
56. Grant MJ, Booth A (2009) A typology of reviews: an analysis of 14 review types and associated methodologies. Health Info Libr J 26:91–108. https://doi.org/10.1111/j.1471-1842.2009.00848.x
57. Alzubaidi L, Zhang J, Humaidi AJ, Al-Dujaili A, Duan Y, Al-Shamma O, Santamaria J, Fadhel MA, Al-Amidie M, Farhan L (2021) Review of deep learning: concepts, CNN architectures, challenges, applications, future directions. J Big Data 8:53. https://doi.org/10.1186/s40537-021-00444-8
58. Campello AF, Goncalves LS, Guedes FR, Marques FV (2017) Cone-beam computed tomography versus digital periapical radiography in the detection of artificially created periapical lesions: a pilot study of the diagnostic accuracy of endodontists using both techniques. Imaging Sci Dent 47:25–31. https://doi.org/10.5624/isd.2017.47.1.25
59. Althnian A, AlSaeed D, Al-Baity H, Samha A, Dris AB, Alzakari N, Abou Elwafa A, Kurdi H (2021) Impact of dataset size on classification performance: an empirical evaluation in the Medical Domain. Appl Sci 11:796. https://doi.org/10.3390/app11020796
60. Patel S (2009) New dimensions in endodontic imaging: part 2. Cone beam computed tomography. Int Endod J 42:463–475. https://doi.org/10.1111/j.1365-2591.2008.01531.x
61. Mostafapoor M, Hemmatian S (2022) Evaluation of the accuracy values of cone-beam CT regarding apical periodontitis: a systematic review and meta-analysis. Oral Radiol 38:309–314. https://doi.org/10.1007/s11282-021-00549-z
62. Abesi F, Golikani A (2023) Diagnostic performance of cone-beam computed tomography for apical periodontitis: a systematic review and meta-analysis. Pol J Radiol 88:e597–e605. https://doi.org/10.5114/pjr.2023.134035
63. Estrela C, Bueno MR, Leles CR, Azevedo B, Azevedo JR (2008) Accuracy of cone beam computed tomography and panoramic and periapical radiography for detection of apical periodontitis. J Endod 34:273–279. https://doi.org/10.1016/j.joen.2007.11.023

Publisher's note Springer Nature remains neutral with regard to jurisdictional claims in published maps and institutional affiliations.

Springer Nature or its licensor (e.g. a society or other partner) holds exclusive rights to this article under a publishing agreement with the author(s) or other rightsholder(s); author self-archiving of the accepted manuscript version of this article is solely governed by the terms of such publishing agreement and applicable law.