Original article

Nuclear Medicine Communications

The influence of colour scale in lesion detection and patient-based sensitivity in [^{68}Ga]Ga-PSMA-PET/CT

Clemens Mingels, Christos Sachpekidis, Karl P. Bohn, Jan-Niklas Hünermund, Robin Schepers, Viktor Fech, George Prenosil, Axel Rominger, Ali Afshar-Oromieh and Ian Alberts

Objective **To investigate the influence of colour scales on the interpretation of [^{68}Ga]Ga-PSMA-11 PET/CT for the diagnosis of recurrent prostate cancer.**

Methods **50 consecutive patients who underwent [^{68}Ga]Ga-PSMA-11 PET/CT for recurrent prostate cancer were selected for this retrospective study. The scans were randomised, anonymised and read by five different readers first in the visually nonlinear colour scale 'PET-rainbow'. Scans were then rerandomised and read in the visually linear colour scale 'hot-metal new'. For each scan in each colour scale the numbers of pathological, equivocal and benign lesions were noted. Scans where the majority of readers (≥3) reported at least one PET-positive lesion were recorded as 'pathological'. Patient-level sensitivity was obtained by composite standard with 14.8 ± 1.2 months of follow-up.**

Results **Increased numbers of lesions per patient were reported for all readers in PET-rainbow compared to hot-metal new (37.4 ± 15.2 vs. 33.9 ± 16.4, respectively, *P*=0.0005). On a per-patient basis, 43 scans were rated pathological in PET-rainbow, compared to 39 in hot-metal new. Follow-up was available for 30 patients confirming 26 pathological scans with positive follow-up in PET-rainbow, and 23 in hot-metal new. Three pathological scans were missed in hot-metal new. Patient-level sensitivity was higher for PET-rainbow (0.96) compared to hot-metal new (0.85). Inter-reader reliability was higher for hot-metal new (Fleiss κ=0.76) compared to PET-rainbow (Fleiss κ=0.60).**

Conclusion **Use of PET-rainbow was associated with improved lesion detection and sensitivity compared to hot-metal new, although at cost of reduced inter-rater agreement. Consequently, the use of PET-rainbow for clinical routine and future studies involving [^{68}Ga]Ga-PSMA-11 is recommended. *Nucl Med Commun* 42: 495–502 Copyright © 2021 Wolters Kluwer Health, Inc. All rights reserved.**

Nuclear Medicine Communications 2021, **42**:495–502

Keywords: colour scale, PET, prostate cancer, prostate-specific membrane antigen

Department of Nuclear Medicine, Inselspital, Bern University Hospital, University of Bern, Bern, Switzerland

Correspondence to Clemens Mingels, MD, Department of Nuclear Medicine, Freiburg street 18, 3010 Bern, Switzerland
Tel: +41 031 632 2656; fax: +41 031 632 3137;
e-mail: clemens.mingels@insel.ch

Received 27 October 2020 **Accepted** 14 December 2020

Introduction

Nuclear medicine concerns itself with the interpretation of imaging data represented in colourised scans. Indeed, the vibrancy and increasingly high fidelity of colour representation of molecular imaging data is what is most striking about nuclear medicine modalities when compared to the usually grey-scale representations of conventional imaging modalities such as computed tomography (CT) or MRI. Recent decades have seen not only rapid improvements in display technology with older cathode-ray monitors being replaced by flat-panel display technologies, but the replacement of analogue photomultiplier tubes (PMT) in PET/CT. Indeed, the recent introduction of digital PET scanners with solid-state silicon photomultipliers allows for improved visualisation and detection of tumour lesions [1,2], including in digital PET/CT with [^{68}Ga]Ga-PSMA-11 [3]. Concomitant developments in radio-pharmacy have been made, with the recent introduction of [^{18}F]-labelled prostate-specific membrane antigen (PSMA) radiotracers such as [^{18}F]F-rhPSMA-7, [^{18}F]F-DCFPyL or [^{18}F]F-PSMA-1007 [4–6]. Although no increased detection rate or sensitivity has yet been demonstrated for these new tracers compared to [^{68}Ga]Ga-PSMA-11, increased detection of benign, PSMA-positive lesions has been reported [7]. A plethora of publications demonstrates that nonspecific causes of tracer uptake can be a potential pitfall [8–11]. Indeterminate lesions are clinically challenging, sometimes leading to further investigations such as MRI and invasive testing [12]. Furthermore, as Yin *et al.* [13] demonstrate through follow-up of lesions initially categorised as indeterminate at PSMA-PET/CT with [^{18}F]-DCFPyl, 58.7% of lesions subsequently demonstrated evidence of malignancy at subsequent imaging. In combination with new tracers and scanners, lesions that pose clinical conundrums are being observed with

Supplemental Digital Content is available for this article. Direct URL citations appear in the printed text and are provided in the HTML and PDF versions of this article on the journal's website, www.nuclearmedicinecomm.com.

0143-3636 Copyright © 2021 Wolters Kluwer Health, Inc. All rights reserved.

DOI: 10.1097/MNM.0000000000001364

Copyright © 2021 Wolters Kluwer Health, Inc. Unauthorized reproduction of this article is prohibited.

increasing frequency. Accurate interpretation and classification of PSMA-avid lesions therefore remains a clinical challenge; for example, Toriihara *et al.* [14] report variable inter-reader agreement seen across three common PSMA-PET interpretation criteria, demonstrating wide variation in the interpretation of an individual lesion even among expert readers.

Although a number of visual interpretation criteria are proposed [15,16], no publications adequately consider whether the colour look-up table used for fusion of the PET data with the CT influences interpretation of the scan. Although expert opinion suggests that visually nonlinear colour scales such as the National Electrical Manufacturers Association -standard 'PET-rainbow' are better suited to PET/CT [17,18], we find no scientific data in support of this. Anecdotally, a wide variety of colour scales are in routine clinical use, often chosen at the reader's discretion. The aim of this study is to report the first systematic investigation of the influence of visually linear and nonlinear colour scales in [^{68}Ga]Ga-PSMA-11 PET/CT for recurrent prostate cancer with respect to detection rate, sensitivity, intra- and inter-reader agreement.

Materials and methods

Patient population

In this retrospective analysis, we included 50 consecutive individuals who were examined at the University Clinic for Nuclear Medicine, Inselspital Bern. The patients' characteristics are outlined in Table 1. All patients were referred to our centre for [^{68}Ga]Ga-PSMA-11 PET/CT in the setting of biochemically recurrent prostate cancer.

Radiotracer

[^{68}Ga]Ga-PSMA-11 was produced as previously described [19,20]. The [^{68}Ga]Ga-PSMA-11 solution was given by intravenous bolus injection with a target dose of 3 MBq/kg. Mean dose was 202 ± 18 MBq, ranging 124–280 MBq.

Imaging

All patients received regular whole-body PET on the same Biograph-VISION 600 PET/CT (Siemens, Erlangen, Germany) scans (from head to the thighs) at 1.5 h p.i following oral hydration with 1 L of water and 20 mg of intravenous Furosemide as previously published [21]. The examination protocols are outlined in Supplementary Materials, Supplemental digital content 1, *http://links.lww.com/NMC/A185*.

Table 1 Patients characteristics: age (median and range) (years), initial TNM stage (median, range; Union for International Cancer Control, 8th ed.), Gleason Score (median, range) and prostate-specific antigen (mean ± SD, range) (ng/ml)

Parameter	Patients
Age (mean, range)	68.62 (54–84)
T stage (median, range)	3 (1–3)
N stage (median, range)	0 (0–1)
M stage (median, range)	0 (0)
Gleason score	7 (6–9)
PSA-value (mean, SD, range)	6.09 ± 17.42 (0.02–101)

PSA, prostate-specific antigen.

Image evaluation and colour scales

Image analysis was performed using an appropriate workstation and software (SyngoVia; Siemens, Erlangen, Germany). A dedicated four mega pixel (4MP) medical monitor was used (Barco, Karlsruhe, Germany), exceeding requirements for diagnostic display monitors [22]. Five nuclear medicine physicians [two board certified nuclear medicine readers (1 and 2), two experienced readers (3 and 4) and one junior resident reader (5); with 12, 6, 8, 3 and 1 years' clinical experience respectively] read all scans independently in the randomised order. Further information about the clinical experience of the readers is given in the Supplementary Material, Supplemental digital content 1, *http://links.lww.com/NMC/A185*. Readers were blinded to patient demographics, clinical details and each other's results. All scans were evaluated in the randomised order first using the visually nonlinear colour look-up table 'PET-rainbow' for the PET data. All scans were then rerandomised and evaluated using the visually linear colour look-up table 'hot-metal new' after a minimum of 2 days. Window levels were preset to 0 and 8.5 SUV, and further windowing by the reader was permissible.

Prior to the study, all readers were provided with an information pack which was read prior to commencement, including literature and instructions regarding image interpretation, technical study details and visual criteria for the identification of pathological lesions and known pitfalls [8,9,11,16]. All readers passed an Ishihara test to exclude red–green colour deficiency. Lesions were rated using a 3-point Likert scale (benign, equivocal and pathological). Scans with at least one definite pathological lesion were recorded as 'pathological' at a patient-based level, and those without pathological (prostate cancer) lesions as 'nonpathological' in a binary scale. In cases of discrepancy, a majority vote (≥3 readers) was taken. To avoid discrepancies in lesion numbers in highly polymetastastatic patients, a maximum of 10 lesions per category (benign, equivocal and pathological) were recorded (i.e. the 10 most visually prominent lesions in terms of intensity).

Statistical analysis

Statistical analyses were performed using Excel (Microsoft, Redmond, Washington, USA) and SPSS (IBM, Armonk, New York, USA). Differences in the average number of lesions per patient were compared using a paired *t*-test. P values <0.05 were considered statistically significant. Intrareader agreement between the two colour look-up tables was evaluated by the Bland–Altman statistic (mean ± SD of differences) [23] and by Cohen's Kappa κ. Inter-reader reliability on both colour scales was

Copyright © 2021 Wolters Kluwer Health, Inc. Unauthorized reproduction of this article is prohibited.

Fig. 1

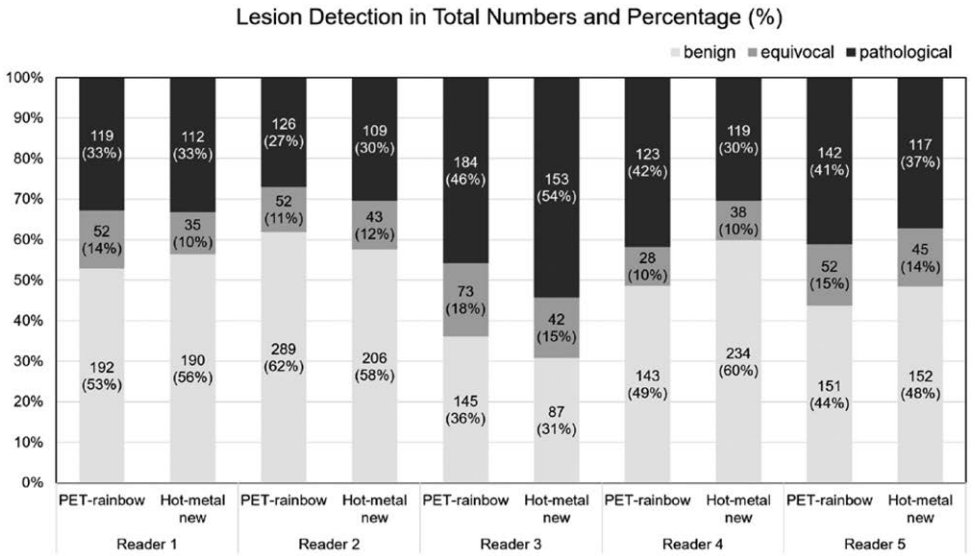

Number of lesions per reader in both colour scales. Shown are the percentages (*y*-axis and for each column shown in brackets) and for comparison, total number of lesions, which were counted by all five readers. Reader 1 and reader 2 are the consultant physicians and reader 3–5 are resident physicians, in order of experience. In total, all readers counted greater numbers of pathological lesions in the PET-rainbow colour scale.

compared using Fleiss' Kappa κ. κ <0 was rated as poor, κ = 0–0.2 as slight, κ = 0.21–0.40 as fair, κ = 0.41–0.60 as moderate, κ = 0.61–0.80 as substantial and κ = 0.81–1.00 as (almost) perfect agreement [24]. Correlation was tested by Pearson's correlation test.

Ethics approval and consent to participate

This evaluation was approved by the regional ethics committee (KEK-Nr. 2018-00299). The study was performed in accordance with the Declaration of Helsinki. Informed consent was obtained.

Follow-up

Follow-up was available for 30 of 50 (60%) patients (14.8 ± 1.2 month follow-up). All medical records of the 50 patients were analysed. Where available, prostate-specific antigen (PSA), subsequent treatment and correlative imaging were collected. Sensitivity was calculated on a per-patient basis, using validation criteria as previously published [25]. Correlative imaging, biopsy or fall in serum PSA following exclusively targeted radiotherapy of a lesion rated as pathological were considered confirmatory of a pathological scan in a composite standard of truth (CSOT) and as previously published [25]. Scans were rated as pathological if one or more pathological lesions per patient and reader were described.

Results

Detection rate

More lesions were observed in PET-rainbow compared to hot-metal new for all readers (mean number of lesions per patient by all five readers ± SD: PET-rainbow 7.48 ± 3.05; hot-metal new 6.73 ± 3.29; $P = 0.0005$). The absolute number of lesions detected varied among all readers, and the results are to be found in Fig. 1.

Likewise, the average number of benign, equivocal and pathological lesions found by all five readers per patient were higher in PET-rainbow (benign 3.7 ± 1.2; equivocal 1.0 ± 0.7 and pathological 2.8 ± 2.5) compared to hot-metal new (benign 3.5 ± 1.5; equivocal 0.8 ± 0.9 and pathological 2.4 ± 2.4). Significantly more pathological lesions were found in the PET-rainbow colour scale ($P = 0.0004$) compared to linear hot-metal new scale; equivocal lesions were higher in PET-rainbow with borderline significance ($P = 0.055$). For benign lesions, there was no statistical difference ($P = 0.2155$) observed between both colour scales Fig. 2.

Clinical follow-up

Subsequent treatment data were available for 30 of 50 patients (60%). For all patients where follow-up data were available, either histological confirmation or a composite standard of post-treatment PSA-decline by exclusively external beam radiation therapy (without concomitant androgen deprivation) or concordant imaging (MRI or PET/CT) were available to confirm the PET/CT findings. The details are to be found in Supplementary Materials, Supplemental digital content 1, *http://links.lww.com/NMC/A185*.

A total of 27/30 (90%) patients with available follow-up data had confirmation of a pathological scan. Only 3/30 (10%) had no reported or confirmed prostate cancer-lesion with composite follow-up of additional images and active surveillance without evidence of a rising-PSA following the PET/CT scan to 14.8 ± 1.2 months' follow-up.

Copyright © 2021 Wolters Kluwer Health, Inc. Unauthorized reproduction of this article is prohibited.

Fig. 2

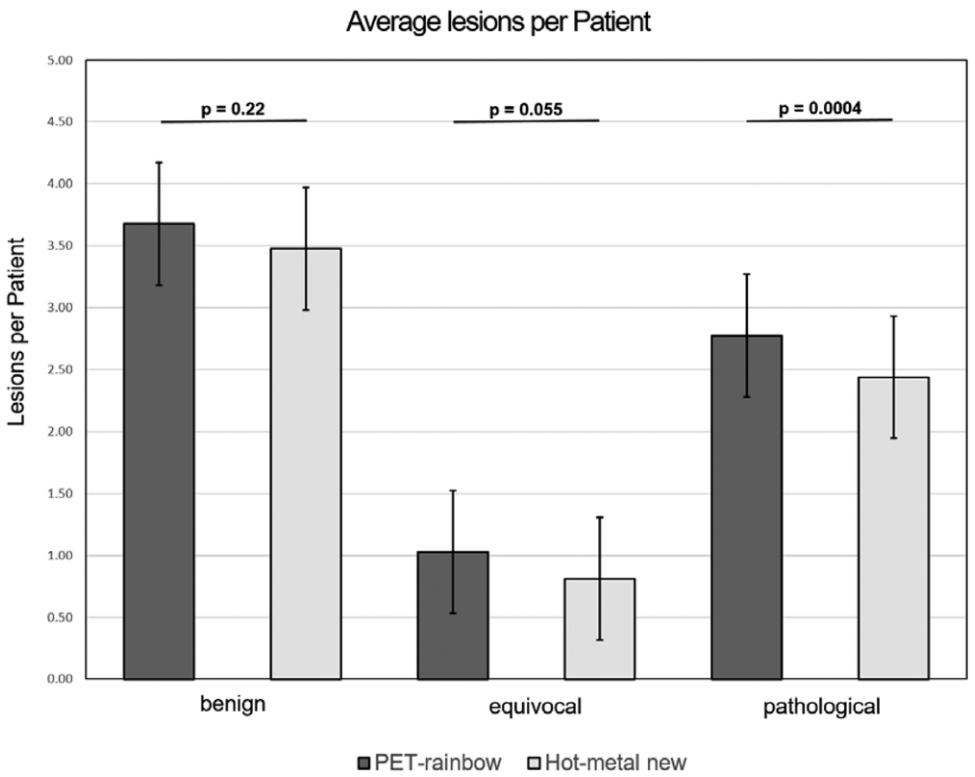

The average number of lesions per patient compared in both colour scales is shown, with error bars showing standard error in the mean. The mean number of pathological lesions rated as pathological (i.e. PET-positive) per patient counted by all readers was statistically significantly higher in PET-rainbow compared to hot-metal new (2.8 ± 2.5 vs. 2.4 ± 2.4; $P = 0.0004$). Likewise, the mean number of equivocal lesions with borderline significance was greater in PET-rainbow (1.0 ± 0.7, vs. 0.8 ± 0.9; $P = 0.055$). No significant difference in the per patient average of benign lesions was observed between both colour scales (PET-rainbow: 3.7 ± 1.2; hot-metal new: 3.5 ± 1.5; $P = 0.22$).

On both colour scales, these three scans were correctly rated as nonpathological. No examples of false-positive scans (scans rated as pathological with discordant CSOT which refutes the pathological diagnosis), were found as shown in Fig. 4.

We found one example of a scan reported as nonpathological by both colour scales but with follow-up confirmatory of recurrent disease. Additionally, four scans were incorrectly reported as nonpathological in hot-metal new. For these patients, the majority (≥3 readers) reported no pathological findings. For three of these four patients, consecutive follow-up data were available. On scrutiny of these patients' medical records, two were identified by [^{68}Ga]Ga-PSMA-11 PET/CT as having local recurrence and one as having prevesical lymph node metastases. Example images of patient 1 are shown in Fig. 5. Subsequently, two of these three patients underwent combined radiotherapy and androgen deprivation-therapy [26], and one was treated with radiotherapy only Table 2. For one patient, histologic confirmation of a local recurrence was available in addition to a PSA-decline post-salvage radiotherapy. For two patients, follow-up imaging (one MRI and one PET/CT) were available and confirmed the pathological findings.

Sensitivity

As described in materials and methods, if a majority of the five readers (i.e. three or more) found at least one pathological lesion, the scan was counted as pathological. Overall, more pathological scans (86 vs. 78%; $P = 0.04$) were found in PET-rainbow compared to hot-metal new Fig. 3.

A CSOT was available for 30/50 patients (60%), allowing for confirmation or refutation of the scans rated by majority as pathological. No significant difference in the rate of pathological scans was observed for the scans with or without follow-up (PET-rainbow 87 vs. 85%, respectively $P = 0.8$; hot-metal new 78 vs. 80%; $P = 0.78$).

At follow-up, a greater number of scans rated as pathological were confirmed true-positive in PET-rainbow compared to hot-metal new (26/30 vs. 23/30). In PET-rainbow, one scan was incorrectly reported as nonpathological, whereas in hot-metal new four such false-negatives were reported. The results are shown in Fig. 4. As such, the diagnostic performance of PET-rainbow was higher compared to hot-metal new (true-positive rate = 0.96 vs. 0.85) Fig. 4.

Copyright © 2021 Wolters Kluwer Health, Inc. Unauthorized reproduction of this article is prohibited.

Intrareader agreement

The Bland–Altman statistic for the intrareader agreement in both colour scales showed a higher detection rate in PET-rainbow (–0.36 ± 1.34), especially for the junior reader 5. The Bland–Altman statistic correlated with reader experience in terms of years of clinical experience ($r = 0.91$).

Intrareader agreement was assessed by Cohen's kappa (κ). This varied from substantial to almost perfect [reader 1 (0.88), reader 2 (0.70), reader 3 (0.63), reader 4 (0.93) and reader 5 (0.86)]. There was no correlation with reader experience.

Fig. 3

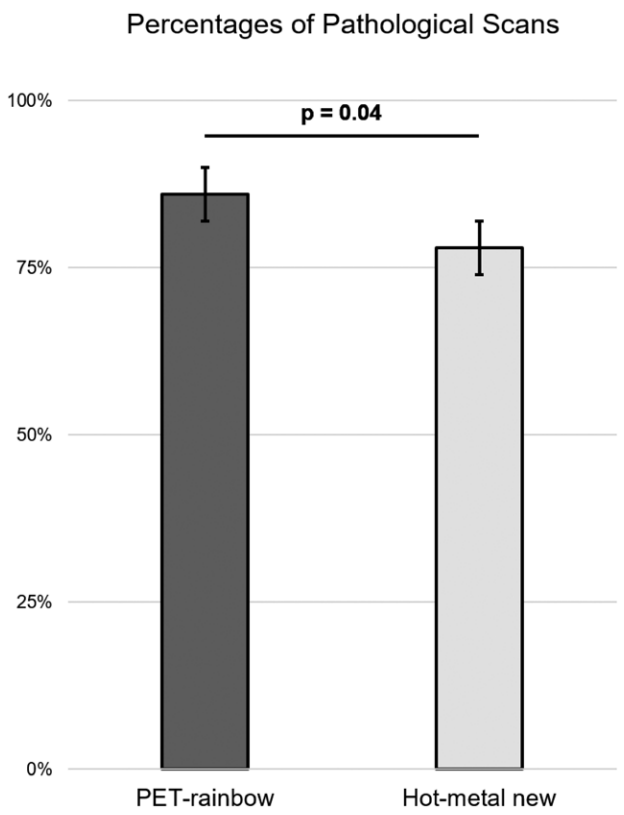

Proportion of scans, which were rated as pathological in both colour scales, with significantly higher proportion of pathological scans (=patient-based sensitivity) in PET-rainbow compared to hot-metal new (86 ± 0.35 vs. 78 ± 0.42%; $P = 0.04$).

Inter-rater agreement

Inter-rater agreement was assessed using Fleiss' kappa for all five readers with moderate agreement (κ = 0.60) for the PET-rainbow colour scale and substantial agreement (κ = 0.76) for hot-metal new.

Discussion

Hitherto, several interpretation criteria have been published for PSMA-PET/CT which attempt to standardise interpretation and reporting [15,16]. However, the choice of colour scale has not been standardised, and anecdotally a wide range of scales are in popular clinical use. The topic has received scant attention in the literature, with only two expert opinion publications available [17,18], and no published data for PSMA-ligands. Only Siennicki *et al.* [27] report variation in diagnostic performance in myocardial scintigraphy according to the colour scale. Given that PSMA-PET/CT interpretation is largely visual, we hypothesised that the choice of colour scale could affect lesion detectability and interpretation, which this present study aims to address.

Our findings show improved lesion detection in PET-rainbow when compared with hot-metal new in a retrospective, intrapatient analysis of 50 individuals undergoing PET/CT. All five readers report the increased numbers of pathological lesions in PET-rainbow ($P = 0.0004$) Fig. 2.

At a patient-based level, more scans were reported by a majority of readers as pathological in PET-rainbow (86%) compared to hot-metal new (78%). Confirmatory follow-up was available for a total of 30/50 patients, including

Fig. 4

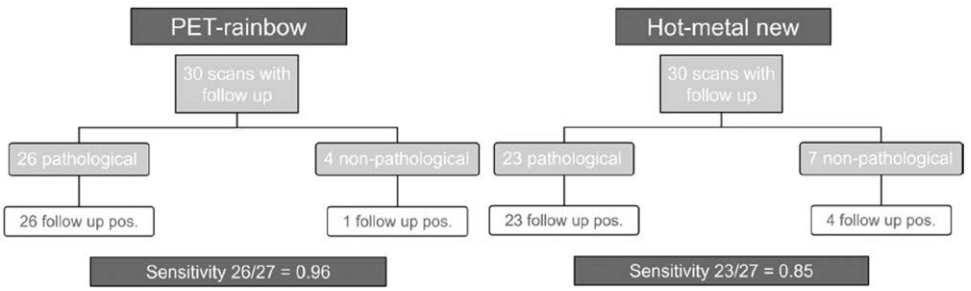

Indicative flowcharts showing details of clinical follow-up for patients. The patient-based sensitivity (number of scans reported as pathological) are shown for both colour scales. All of the patients rated as positive in both scales had confirmatory follow-up and were therefore positive findings. In hot-metal new 4 of the 7 scans which were described as non-pathological scans had subsequent follow-up of prostate cancer confirmatory of recurrence compared to one such patient in PET-rainbow. Three patients were ergo incorrectly identified as having nonpathological scans in hot-metal new.

Copyright © 2021 Wolters Kluwer Health, Inc. Unauthorized reproduction of this article is prohibited.

Fig. 5

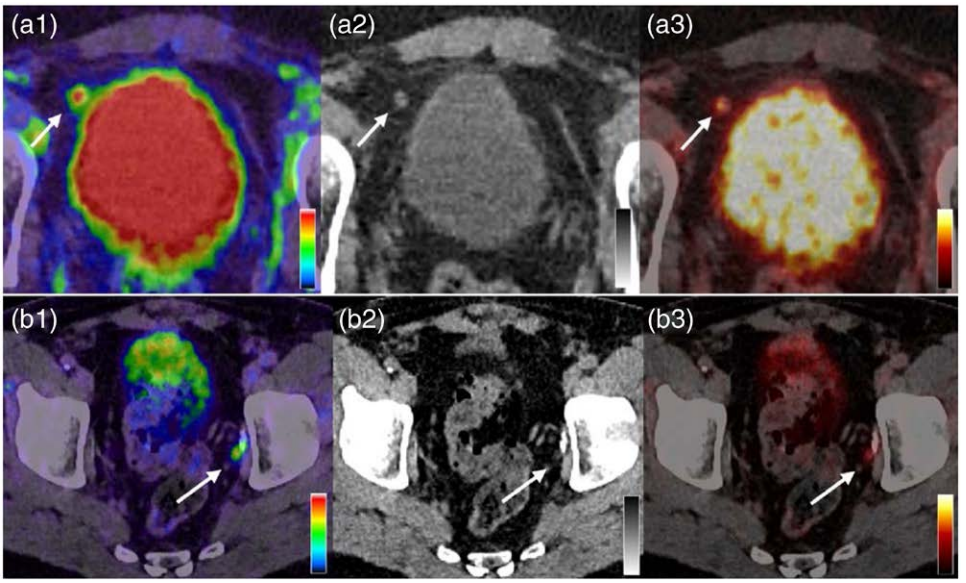

Examples of lesions which were missed in hot-metal new colour scale. Shown are hybrid images in PET-rainbow scale (1), stand-alone CT scan (soft-tissue window) (2) and hybrid hot-metal new colour scale of two patients (a/b). The relevant lesions are marked with an arrow. Although the pathological lymph nodes for both patients are readily appreciated, the majority of the readers missed the pathological [^{68}Ga]Ga-PSMA-11-avid prevesical lymph node in hot-metal new (a) and the pelvic lymph node (b) in the hot-metal new colour scale.

Table 2 Characteristics of the three patients incorrectly reported as having nonpathological scans in hot-metal new, with confirmation by follow-up. Listed are the initial TNM-state, the initial Gleason score, the initial treatment

	Patient 1	Patient 2	Patient 3
Inital TNM-Classification	pT2 pN0 R1	pT3a R1 G3	pT3a pN0
Inital Gleason score	8	7	7
Inital treatment	OP+RT	OP	OP
Treatment after recurrence	RT	RT+ADT	RT+ADT
Confirmation of pathological scan	PSA+PET/CT	PSA+MRI	Histology(+) (local rec.)+PSA
PSA before treatment	2.50 ng/ml	2.37 ng/ml	5.00 ng/ml
PSA after treatment	2.37 ng/ml	0.03 ng/ml	<0.01 ng/ml

Subsequent treatment postrecurrence and clinical findings confirmatory of the pathological scan.
ADT, androgen deprivation-therapy; OP, operation; PSA, prostate-specific antigen; RT, radiotherapy.

three individuals who were reported as having nonpathological scans in hot-metal new but pathological as positive in PET-rainbow. The proportion of patients with available follow-up was similar to previously published PSMA studies [3,28]. We found that for PET-rainbow the true positive rate was 11% points higher than that for hot-metal new (96 vs. 85%) Fig. 4, with consequently improved diagnostic performance. Based on these data, we posit that clinically relevant findings are at risked to be missed when using the hot-metal new colour scale. Indeed, three patients were incorrectly identified by a majority of five readers as having negative scans, with clear potential for adverse clinical impact [29].

Our results find explanation in some of the physical properties of light and the psychology of colour perception. Most humans have trichromatic colour perception with three different types of retinal cone cell [30]. The cones vary in ability to discriminate between different colour hues at different parts of the visible spectrum [31]. The eye is better able to differentiate between hues at the yellow portion of the spectrum compared to the green end. Although all colour scales are physically linear (insofar as they encompass a portion of the visible spectrum), perceptually, these differences in colour perception render colour scales like PET-rainbow nonlinear in their interpretation. Differences between green may be suppressed, while smaller changes in the yellow portion may appear more prominent, representing a potential pitfall. However, caution must also be advised when using a colour scale restricted to the red portion of the visible spectrum (hot-metal new). The ability of the eye to resolve differences in hue at the orange-red end of the spectrum is limited to a just-noticeable difference of 3–7 nm [32], making smaller contrasts difficult to resolve across a restricted portion of the spectrum. Furthermore, use of perceptually linear colour scales is associated with visual illusions such as Mach banding [33], a known pitfall in the interpretation of radiographs [34]. This can be used to advantage in nonlinear colour scales, where the appearance of Mach bands occurs more frequently due to higher and more abrupt frequency of changes leading to improved contrast-to-background perception [35]. We, therefore, find it consistent that more lesions were found in PET-rainbow and posit that this was a result of the higher contrast-to-background perception for this colour scale.

Copyright © 2021 Wolters Kluwer Health, Inc. Unauthorized reproduction of this article is prohibited.

Our results are in agreement with expert opinion, which favours the use of PET-rainbow [17,18], albeit in [^{18}F] F-FDG and [^{18}F]-fluorocholine. No opinion is reported for PSMA-ligands. Hofman *et al.* [17] report for [^{18}F] F-FDG-PET that a colour scale which ranges from blue (low expression) through green/yellow (moderate expression) to red (high expression) allows for better differentiation between low, mid-range and high-tracer expression compared to a linear colour scale, which is consistent with both our findings and the theoretical considerations outlined above. We find substantial inter-reader reliability ($k = 0.76$) for hot-metal new and is in-keeping with previously reported data [36,37].The inter-reader agreement was lower for PET-rainbow ($k = 0.60$). The Bland–Altman statistic favours PET-rainbow especially for the most junior reader. Hofman *et al.* [17] report using a 'traffic-light' system for their residents, with the colours red, amber and green being associated with high, moderate and low uptake, respectively, implying that there is a pedagogical advantage for PET-rainbow. This is consistent with our finding of a greater bias towards PET-rainbow for the less experienced residents, for whom PET-rainbow may be of particular advantage.

Furthermore, the substantial difference in patient-based sensitivity and inter-reader agreement observed between these two colour scales suggests that whatever colour look-up table chosen, it ought to be standardised in studies. This must be considered by future interpretation criteria.

We note several weaknesses with our study. Our small cohort is at risk of recall bias. In mitigation, we randomised the scan order and allowed for a minimum period of 2 days between reading sessions. Although a longer time-period may be beneficial, very few studies report the optimal time and most published studies suggest that visual memory recall for imaging studies is poor [38]. Furthermore, we note that the scans were first read in PET-rainbow and then in hot-metal new. Given that higher numbers of pathological findings were reported in PET-rainbow which were not subsequently recalled in hot-metal new, we argue that recall bias was not a significant confounder in this study. Ideally, prospective trials with random scan allocation among a larger cohort of readers could resolve this issue, although the variable inter-rater agreement using PSMA interpretation criteria may mean that the magnitude of the inter-reader difference could mask any difference between colour scales [39]. Although we cannot exclude personal reader preference for colour scale as a potential confounder, we note that all readers routinely use the institutionally preferred hot-metal new, they nevertheless report increased lesion detection in PET-rainbow. In common with most studies in recurrent prostate cancer, we cannot provide lesion-based histological verification. Clinical follow-up was available for 30/50 patients with a follow-up rate favourable in comparison with other studies of similar design [25,40] allowing a patient-based sensitivity to be determined by composite standard [7]. Further studies are required to confirm whether these findings are generalisable to other radiotracers, particularly [^{18}F]-labelled PSMA-radioligands, or colour scales different to the ones evaluated in the present study.

Conclusion

We find significantly higher detection rates in the nonlinear colour scale PET-rainbow, compared to hot-metal new. Additionally, a composite standard of clinical follow-up shows higher sensitivity for the nonlinear scale, albeit with a slightly lower inter-reader agreement. The intrareader agreement showed a bias towards PET-rainbow colour, particularly in inexperienced readers, suggesting that the use of PET-rainbow is most beneficial for junior readers. We found that in hot-metal new, three patients were incorrectly identified as having nonpathological scans, suggesting lower performance of this nontripartite colour scale in comparison to the tripartite PET-rainbow scale, and suggest that PET-rainbow is better suited to imaging with [^{68}Ga]Ga-PSMA-11 PET/CT. These data highlight the importance of standardising colour scales for clinical studies as well as clinical routine. Therefore, PET/CT for recurrent prostate cancer in [^{68}Ga]Ga-PSMA-11 should be routinely analysed in the tripartite colour scale PET-rainbow.

Acknowldgements

Conflicts of interest

There are no conflicts of interest.

Refrences

1 López-Mora DA, Flotats A, Fuentes-Ocampo F, Camacho V, Fernández A, Ruiz A, *et al.* Comparison of image quality and lesion detection between digital and analog PET/CT. *Eur J Nucl Med Mol Imaging* 2019; **46**:1383–1390.
2 Nguyen NC, Vercher-Conejero JL, Sattar A, Miller MA, Maniawski PJ, Jordan DW, *et al.* Image quality and diagnostic performance of a digital PET prototype in patients with oncologic diseases: initial experience and comparison with analog PET. *J Nucl Med* 2015; **56**:1378–1385.
3 Alberts I, Prenosil G, Sachpekidis C, Weitzel T, Shi K, Rominger A, Afshar-Oromieh A. Digital versus analogue PET in [^{68}Ga]Ga-PSMA-11 PET/CT for recurrent prostate cancer: a matched-pair comparison. *Eur J Nucl Med Mol Imaging* 2020; **47**:614–623.
4 Rahbar K, Afshar-Oromieh A, Seifert R, Wagner S, Schäfers M, Bögemann M, Weckesser M. Diagnostic performance of 18F-PSMA-1007 PET/CT in patients with biochemical recurrent prostate cancer. *Eur J Nucl Med Mol Imaging* 2018; **45**:2055–2061.
5 Chen Y, Pullambhatla M, Foss CA, Byun Y, Nimmagadda S, Senthamizhchelvan S, *et al.* 2-(3-{1-Carboxy-5-[(6-[18F]fluoro-pyridine-3-carbonyl)-amino]-pentyl}-ureido)-pentanedioic acid, [18F]DCFPyL, a PSMA-based PET imaging agent for prostate cancer. *Clin Cancer Res* 2011; **17**:7645–7653.
6 Oh SW, Wurzer A, Teoh EJ, Oh S, Langbein T, Krönke M, *et al.* Quantitative and qualitative analyses of biodistribution and PET image quality of a novel radiohybrid PSMA, (18)F-rhPSMA-7, in patients with prostate cancer. *J Nucl Med* 2020; **61**:702–709.
7 Rauscher I, Kronke M, Konig M, Gafita A, Maurer T, Horn T, *et al.* Matched-pair comparison of (68)Ga-PSMA-11 and (18)F-PSMA-1007 PET/CT: frequency of pitfalls and detection efficacy in biochemical recurrence after radical prostatectomy. *J Nucl Med* 2020; **61**:51–57.
8 Afshar-Oromieh A, Sattler LP, Steiger K, Holland-Letz T, da Cunha ML, Mier W, *et al.* Tracer uptake in mediastinal and paraaortal thoracic lymph nodes as a potential pitfall in image interpretation of PSMA ligand PET/CT. *Eur J Nucl Med Mol Imaging* 2018; **45**:1179–1187.

Copyright © 2021 Wolters Kluwer Health, Inc. Unauthorized reproduction of this article is prohibited.

9 Krohn T, Verburg FA, Pufe T, Neuhuber W, Vogg A, Heinzel A, *et al*. [(68) Ga]PSMA-HBED uptake mimicking lymph node metastasis in coeliac ganglia: an important pitfall in clinical practice. *Eur J Nucl Med Mol Imaging* 2015; **42**:210–214.
10 Rauscher I, Maurer T, Fendler WP, Sommer WH, Schwaiger M, Eiber M. (68)Ga-PSMA ligand PET/CT in patients with prostate cancer: how we review and report. *Cancer Imaging* 2016; **16**:14.
11 Rischpler C, Beck TI, Okamoto S, Schlitter AM, Knorr K, Schwaiger M, *et al*. (68)Ga-PSMA-HBED-CC uptake in cervical, celiac, and sacral ganglia as an important pitfall in prostate cancer PET imaging. *J Nucl Med* 2018; **59**:1406–1411.
12 De Coster L, Sciot R, Everaerts W, Gheysens O, Verscuren R, Deroose CM, *et al*. Fibrous dysplasia mimicking bone metastasis on ^{68}GA-PSMA PET/MRI. *Eur J Nucl Med Mol Imaging* 2017; **44**:1607–1608.
13 Yin Y, Werner RA, Higuchi T, Lapa C, Pienta KJ, Pomper MG, *et al*. Follow-up of lesions with equivocal radiotracer uptake on PSMA-targeted PET in patients with prostate cancer: predictive values of the PSMA-RADS-3A and PSMA-RADS-3B categories. *J Nucl Med* 2019; **60**:511–516.
14 Toriihara A, Nobashi T, Baratto L, Duan H, Moradi F, Park S, *et al*. Comparison of 3 interpretation criteria for (68)Ga-PSMA11 PET based on inter- and intrareader agreement. *J Nucl Med* 2020; **61**:533–539.
15 Eiber M, Herrmann K, Calais J, Hadaschik B, Giesel FL, Hartenbach M, *et al*. Prostate cancer molecular imaging standardized evaluation (PROMISE): proposed miTNM classification for the interpretation of PSMA-ligand PET/CT. *J Nucl Med* 2018; **59**:469–478.
16 Rowe SP, Pienta KJ, Pomper MG, Gorin MA. PSMA-RADS version 1.0: a step towards standardizing the interpretation and reporting of PSMA-targeted PET imaging studies. *Eur Urol* 2018; **73**:485–487.
17 Hofman MS, Hicks RJ. How we read oncologic FDG PET/CT. *Cancer Imaging* 2016; **16**:35.
18 Beauregard JM, Beaulieu A. How we read FCH-PET/CT for prostate cancer. *Cancer Imaging* 2016; **16**:41.
19 Afshar-Oromieh A, Avtzi E, Giesel FL, Holland-Letz T, Linhart HG, Eder M, *et al*. The diagnostic value of PET/CT imaging with the (68)Ga-labelled PSMA ligand HBED-CC in the diagnosis of recurrent prostate cancer. *Eur J Nucl Med Mol Imaging* 2015; **42**:197–209.
20 Eder M, Neels O, Müller M, Bauder-Wüst U, Remde Y, Schäfer M, *et al*. Novel preclinical and radiopharmaceutical aspects of [^{68}Ga] Ga-PSMA-HBED-CC: a new PET tracer for imaging of prostate cancer. *Pharmaceuticals (Basel)* 2014; **7**:779–796.
21 Haupt F, Dijkstra L, Alberts I, Sachpekidis C, Fech V, Boxler S, *et al*. ^{68}Ga-PSMA-11 PET/CT in patients with recurrent prostate cancer-a modified protocol compared with the common protocol. *Eur J Nucl Med Mol Imaging* 2020; **47**:624–631.
22 The Royal College of Radiologists. *Picture archiving and communication systems (PACS) and guidelines on diagnostic display devices*. 3rd ed. London: The Royal College of Radiologists; 2019.
23 Bland JM, Altman DG. Measuring agreement in method comparison studies. *Stat Methods Med Res* 1999; **8**:135–160.
24 Landis JR, Koch GG. The measurement of observer agreement for categorical data. *Biometrics* 1977; **33**:159–174.
25 Fendler WP, Calais J, Eiber M, Flavell RR, Mishoe A, Feng FY, *et al*. Assessment of ^{68}Ga-PSMA-11 PET accuracy in localizing recurrent prostate cancer: a prospective single-arm clinical trial. *JAMA Oncol* 2019; **5**:856–863.
26 Giesel FL, Hadaschik B, Cardinale J, Radtke J, Vinsensia M, Lehnert W, *et al*. F-18 labelled PSMA-1007: biodistribution, radiation dosimetry and histopathological validation of tumor lesions in prostate cancer patients. *Eur J Nucl Med Mol Imaging* 2017; **44**:678–688.
27 Siennicki J, Kuśmierek J, Kovacevic-Kuśmierek K, Bieńkiewicz M, Chiżyński K, Płachcińska A. The effect of image translation table on diagnostic efficacy of myocardial perfusion SPECT studies. *Nucl Med Rev Cent East Eur* 2010; **13**:64–69.
28 Rauscher I, Krönke M, König M, Gafita A, Maurer T, Horn T, *et al*. Matched-pair comparison of (68)Ga-PSMA-11 PET/CT and (18)F-PSMA-1007 PET/CT: frequency of pitfalls and detection efficacy in biochemical recurrence after radical prostatectomy. *J Nucl Med* 2020; **61**:51–57.
29 Roach PJ, Francis R, Emmett L, Hsiao E, Kneebone A, Hruby G, *et al*. The impact of (68)Ga-PSMA PET/CT on management intent in prostate cancer: results of an australian prospective multicenter study. *J Nucl Med* 2018; **59**:82–88.
30 Gouras P. Colour vision. In: eLS, editor. 2007. doi: 10.1002/9780470015902.a0000043.
31 MacAdam DL. Visual sensitivities to color differences in daylight*. *J Opt Soc Am* 1942; **32**:247–274.
32 Loreto V, Mukherjee A, Tria F. On the origin of the hierarchy of color names. *Proc Natl Acad Sci U S A* 2012; **109**:6819–6824.
33 Mach E. Über die Wirkung der räumlichen Vertheilung des Lichtreizes auf die Netzhaut. *Sitzungsberichte der mathematisch-naturwissenschaftlichen Klasse der Kaiserlichen Akademie der Wissenschaften* 1865; **52**:303–322.
34 Lane EJ, Proto AV, Phillips TW. Mach bands and density perception. *Radiology* 1976; **121**:9–17.
35 Keil MS, Cristóbal G, Neumann H. Gradient representation and perception in the early visual system–a novel account of Mach band formation. *Vision Res* 2006; **46**:2659–2674.
36 Fendler WP, Calais J, Allen-Auerbach M, Bluemel C, Eberhardt N, Emmett L, *et al*. (68)Ga-PSMA-11 PET/CT interobserver agreement for prostate cancer assessments: an international multicenter prospective study. *J Nucl Med* 2017; **58**:1617–1623.
37 Kranzbühler B, Nagel H, Becker AS, Müller J, Huellner M, Stolzmann P, *et al*. Clinical performance of ^{68}Ga-PSMA-11 PET/MRI for the detection of recurrent prostate cancer following radical prostatectomy. *Eur J Nucl Med Mol Imaging* 2018; **45**:20–30.
38 Evans KK, Marom EM, Godoy MC, Palacio D, Sagebiel T, Cuellar SB, *et al*. Radiologists remember mountains better than radiographs, or do they? *J Med Imaging (Bellingham)* 2016; **3**:011005.
39 Werner RA, Bundschuh RA, Bundschuh L, Javadi MS, Leal JP, Higuchi T, *et al*. Interobserver agreement for the standardized reporting system PSMA-RADS 1.0 on (18)F-DCFPyL PET/CT imaging. *J Nucl Med* 2018; **59**:1857–1864.
40 Miksch J, Bottke D, Krohn T, Thamm R, Bartkowiak D, Solbach C, *et al*. Interobserver variability, detection rate, and lesion patterns of ^{68}Ga-PSMA-11-PET/CT in early-stage biochemical recurrence of prostate cancer after radical prostatectomy. *Eur J Nucl Med Mol Imaging* 2020; **47**:2339–2347.

Copyright © 2021 Wolters Kluwer Health, Inc. Unauthorized reproduction of this article is prohibited.