Medical Endoscopy Report

Patient Information

Patient Name: SEETHA

Patient ID: SEETHA_81314_RP241106_121043

Report Date: 2026-02-26 00:13:52

Endoscopy Images

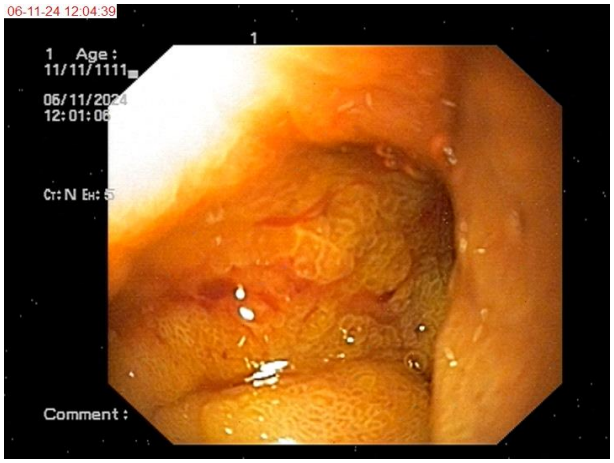

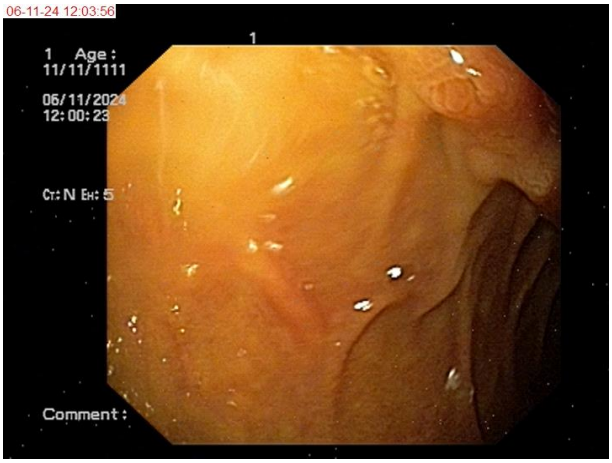

Findings

Indication:	CLD-S/P EVL, Now with hematemesis and melena . Previous study showed Post EVR changes , Now for relook OGD FUNDUS AND BOD
Scope Passed Upto:	D2 FOOD STASIS ? C/C CECT ABDOMEN WITH EVENTUAL PSEUDOANEURYSM TO R/O IMPENDING PERFORATION IRREGUL
Premedication:	10% XYLOCAINE FOOD STASIS ?CARCINOMA STOMACH-BIOPSY TAKEN FROM ANTRUUM AND D2 FOR ESR TE
Esophagus:	Normal

Ge Junction:	Laxim at 35 cm
Stomach:	FOOD & FLUID STASIS ?GERD plan - relook after 6 weeks if further bleed and Hb fall >5mls uptake in body polyp) in case of any further
Fundus:	No fundal varix .Mosaic pattern of m ucosa wit h hemor rhaghc spots s een
Body:	Erythematous and edematous mucosas noted .Multiple small sessile polyps <5mm noted throughout body- ? fundic gland polyp ,removed with biopsy forceps . No
Antrum:	Erythematous and edematous mucosal folds noted, no ulcers/ no luminal blood noted . Co- operation normal , no food stasis noted , scope passed upto body . Biops
Pylorus:	Normal
Duodenum:	DUODENAL EROSIONS FUNDUS ,BODY AND ANTRAL EROSIONS .NOW WITH HB 5.6 AND ULCERS IN DUODEX .BI
Rut:	Not taken due to poor patient tolerability during procedure and scope not passing beyond distal body of stomach due to luminal narrowing .Maximum circumferential extent of ulcers noted was 5 cm
Biopsy:	Not taken
Impression:	HEMOSTASIS ACHIEVED WITH HEMOCLIPS,NO ACTIVE OOZE OR LUMINAL BLOOD FOUND AFTER PROCEDURE.PLAN-RELOOK IF FURT