Medical Endoscopy Report

Patient Information

Patient Name: SEETHA

Patient ID: SEETHA_81314_RP241106_121043

Report Date: 2025-12-04 12:51:10

Endoscopy Images

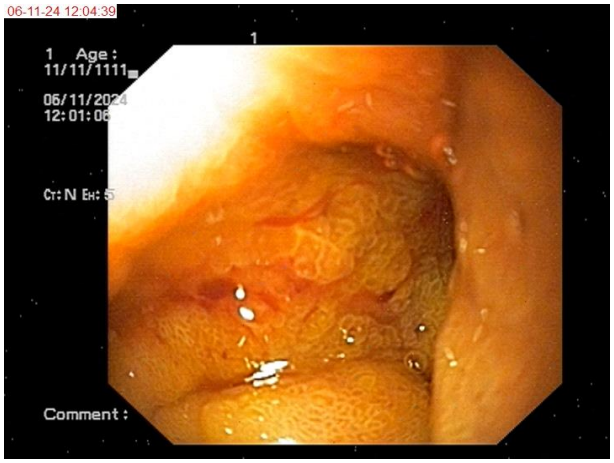

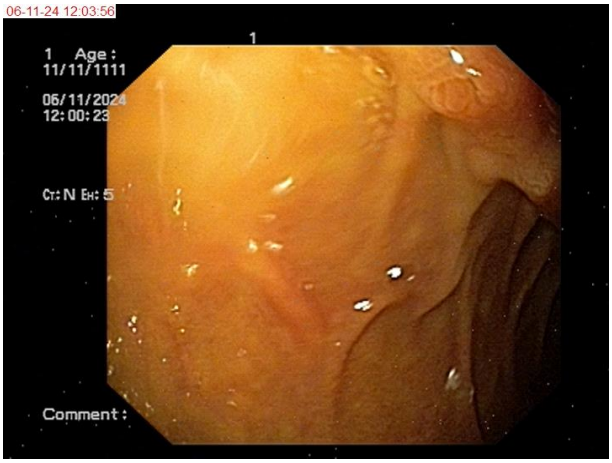

Findings

Indication:	CLD-S/P EVL-Relook 2 weeks after 1st session 1.1.2024 10.10.2024 10.10.2024 10.10.2024 10.10.2024 10.10.2024 10.10.2024 10.10.2024 10.10.2024 10.10.2024 10.10.2024 10.10.2024 10.10.2024 10.10.2024
Scope Passed Upto:	D2 mucosa without ulcers/ erosions/ luminal narrowing .Scope passed upto D3 .No resistance encountered during scope passage .Surrounding mucosa appears edematous and erythematous .No active bleeding noted at present .No immediate complications noted .No altered blood noted in lumen .No active ooze noted .No areas of ooze noted .No areas of active bleeding noted .No areas of recent bleed noted .No areas of ongoing bleed noted .

Premedication:	10% XYLOCAINE ANTRUM AND PYLORUS WITH SURROUNDING NODULARITY AND ULCERATION IN ANTRUM AND PYLORUS WITH SURROUNDING NODULARITY AND ULCERATION IN ANTRUM AND PYLORUS WITH SURROUNDING NODULARITY AND ULCERATION IN ANTRUM AND PYLORUS WITH SURROUNDING NODULARITY AND ULCERATION IN ANTRUM AND PYLORUS WITH SURROUNDING NODULARITY AND ULC
Esophagus:	Normal mucosa without ulcers/ erosions/ luminal narrowing .No food or fluid stasis noted .Normal peristalsis noted .No mass lesion .Normal distensibility and peristalsis noted .No food or fluid stasis noted .Normal peristalsis noted .No mass lesion .Normal distensibility and peristalsis noted .No food or fluid stasis noted .Normal peristalsis noted .No mass lesion .Normal distensibility and peristalsis noted .No food or fluid stasis noted .Normal peristalsis noted .No mass les
Ge Junction:	40CMS and edematous and erythematous mucosa noted with nodularity. Biopsy taken. No ulcer/ tear/ varices noted in the GE junction at present. No altered blood noted in lumen . No luminal blood noted in the GE junction at present. No altered blood noted in lumen . No luminal blood noted in the GE junction at present. No altered blood noted in lumen . No luminal blood noted in the GE junction at present. No altered blood noted in lumen . No lum
Stomach:	No stasis . Normal peristalsis and distensibility noted . No ulcer/ erosions noted . Normal blood in lumen . No active bleed at present . Normal mucosal folds and contours noted . No luminal blood noted . Normal peristalsis and distensibility noted . No ulcer/ erosions noted . Normal blood in lumen . No active bleed at present . Normal mucosal folds and contours noted . No luminal blood noted . Normal peristalsis
Fundus:	Normal mucosa without ulcers/ erosions/ luminal narrowing with normal distensibility and peristalsis. No altered blood in the lumen or ooze from the mucosa in the stomach or body of stomach or antrum of stomach or pylorus of stomach or duodenum of stomach or D1 of stomach or D2 of stomach or antrum of stomach or pylorus of stomach or duodenum of stomach or body of st
Body:	Erythematous and edematous mucosa noted with mosaic pattern and hemorrhagic spots noted. Few telangiectasia without active ooze noted in the body. Few ulcers noted with clean base without active ooze. Few nodularity noted with surface erosions. Few ulcers noted with surface erosions. Few nodularity noted with surface erosions. Few ulcers noted with surface erosions. Few nodularity noted with surface erosions. Few ulcers noted with surface erosions. Few nodularity noted with surface eros
Antrum:	Erythematous mucosa noted with multiple erosions seen. No active ooze noted. No luminal blood noted in the stomach. No ulcers seen in the antrum of the stomach in the present study . No altered blood noted in the lumen of the stomach . No luminal blood noted in the antrum of the stomach in the present study . No altered blood noted in the lumen of the stomach . No luminal blood noted in the antrum of the stomach in the present study . No altered blood noted in
Pylorus:	Normal mucosal folds, normal distensibility and peristalsis. No ulcers/ erosions/ growth. No luminal blood or sites of ooze in the stomach or duodenum at this time of the study . No active bleeding at present . All regions of stomach show normal peristalsis and distensibility . No luminal blood or sites of ooze in the stomach or duodenum at this time of the study . No active bleeding at present . All regions of stomach show normal peristalsis and distensibility

Duodenum:	D1: Normal | D2: Normal mucosa. No ulcers/ growth/ luminal blood/ areas of active ooze or areas of necrosis. All stomach regions show normal distensibility and peristalsis and no areas of stasis or luminal narrowing noted in the present study . All regions show normal mucosal folds and no areas of fluid stasis noted in the present study . All regions show normal mucosal folds and no areas of fluid stasis noted in the present study . All regions
Rut:	Not taken D1 ulcer healing compared to previous study. Normal distensibility and peristalsis noted. No luminal blood or sites of ooze. All stomach regions show normal mucosal appearance and no erosions/ulcers. No altered blood in the lumen or areas of active ooze. All regions of stomach show normal distensibility and peristalsis except for mild decreased peristalsis in the antrum. No luminal blood or sites of ooze. All stomach regions show normal muc
Biopsy:	Not taken antrum and body due to poor patient tolerability. Taken from antral ulcer margins and D2 ulcer margins to r/o malignancy and to assess the growth potential of ulcer margins in the future . From antrum and D2 ulcer margins , multiple biopsies were taken to r/o H.Pylori infection and to assess the growth potential of ulcer margins in the future . From antrum and D2 ulcer margins , multiple biopsies
Impression:	ANTRAL GASTRITIS RUT- BIOPSY TAKEN FROM ANTRUM AND D2 FOR CBNAAT TAKEN PLAN : RELOOK OGD AFTER 8 WEEKS AND BIOPSY FROM NODULARITY IN D2 AFTER 8 WEEKS IF FURTHER EPISODE/HB FALL THEN BIOPSY FROM NODULARITY IN D2 AFTER 8 WEEKS IF FURTHER EPISODE/HB FALL THEN RELOOK OGD AFTER 8 WEEKS AND B