Medical Endoscopy Report

Patient Information

Patient Name: SEETHA

Patient ID: SEETHA_81314_RP241106_121043

Report Date: 2026-02-24 01:21:23

Endoscopy Images

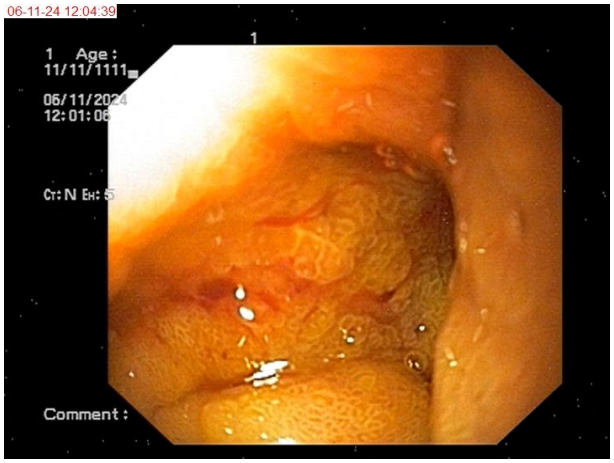

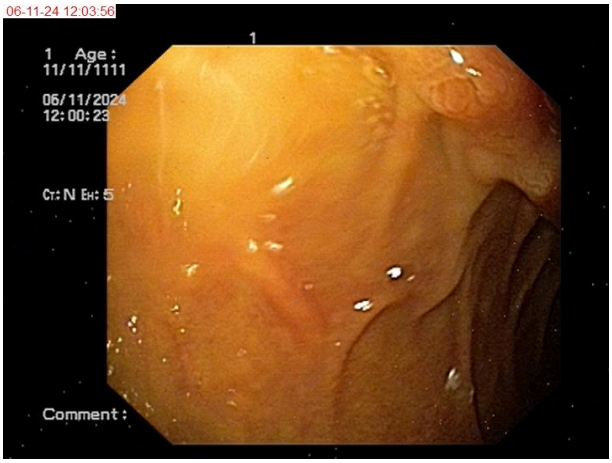

Findings

Indication:	CLD-S/P EVL-Relook 2 weeks after 1st session 1.1.2024 10.10.2024 10.10.2024 10.10.2024 10.10.2024 10.10.2024 10
Scope Passed Upto:	D2 mucosa without ulcers/ erosions/ luminal narrowing
Premedication:	10% XYLOCAINE ANTRUM AND PYLORUS WITH SURROUNDING NODULARITY AND ULCERATION IN ANTRUM AND PYLORUS WI
Esophagus:	Normal mucosa without ulcers/ erosions/ luminal narrowing

Ge Junction:	40CMS and edematous and erythematous mucosa with nodularity
Stomach:	No stasis
Fundus:	Normal mucosa without ulcers/ erosions/ luminal narrowing with normal distensibility and peristalsis
Body:	Erythematous and edematous mucosa with mosaic pattern and hemorrhagic spots
Antrum:	Erythematous mucosa with multiple erosions
Pylorus:	Normal mucosal folds, normal distensibility and peristalsis
Duodenum:	D1: Normal | D2: Normal mucosa
Rut:	Not taken D1 ulcer healing compared to previous study
Biopsy:	Not taken antrum and body due to poor patient tolerability
Impression:	ANTRAL GASTRITIS RUT- BIOPSY TAKEN FROM ANTRUM AND D2 FOR CBNAAT TAKEN PLAN : RELOOK OGD AFTER 8 WEE