AI Dental Diagnostic Suite

Upload X-rays for instant anomaly detection and analysis.

Drag & drop or browse

image.png

START DIAGNOSIS

Filter Results

- [x] Crown
- [x] Filling
- [x] Missing teeth
- [x] Periapical lesion
- [x] Root Canal Treatment
- [x] Bone Loss

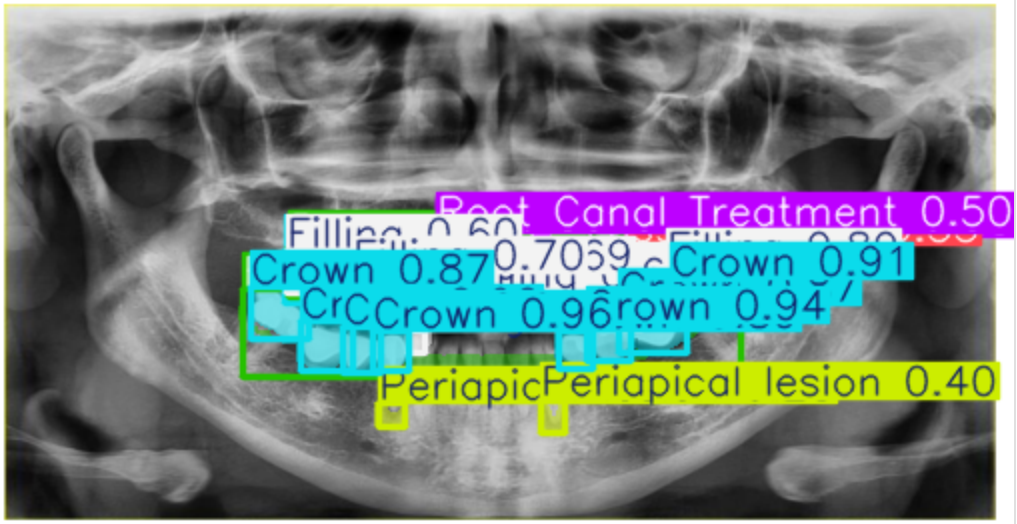

Findings Summary

Crown → 9

Filling → 10

Root Canal Treatment → 3

Periapical lesion → 2

Bone Loss → 2

Missing teeth → 1

Detected Anomalies

- Crown
- Filling
- Missing teeth
- Periapical lesion
- Root Canal Treatment
- Bone Loss

🎤 UPLOAD DIAGNOSIS AUDIO

GENERATE AI REPORT

🦷 Professional Clinical Analysis

Clinical Summary

The panoramic radiograph reveals a patient with significant dental history including multiple missing teeth, extensive fixed prosthodontics (bridges and crowns), endodontic treatments, and generalized moderate to severe alveolar bone loss.

Detailed Findings (FDI Notation)

Tooth	Condition	Severity	Treatment	N
16 Upper Right First Molar	Crown (Cap)	Moderate	Clinical evaluation of marginal integrity	F c ra re c e c c
12 Upper Right Lateral Incisor	Root Canal Treatment (Nerve Treatment)	Moderate	Endodontic review or retreatment	R fi m w ro s a w ra
12 Upper Right Lateral Incisor	Periapical Lesion (Infection)	Moderate	Endodontic evaluation	W ra lo th re ro

Tooth	Condition	Severity	Treatment	N
11 Upper Right Central Incisor	Root Canal Treatment (Nerve Treatment)	Moderate	Endodontic review	C r w r m e th
11 Upper Right Central Incisor	Periapical Lesion (Infection)	Moderate	Clinical monitoring and vitality testing	R a r s c p p
21 Upper Left Central Incisor	Root Canal Treatment (Nerve Treatment)	Low	Routine monitoring	E fi ir c c
22 Upper Left Lateral Incisor	Root Canal Treatment (Nerve Treatment)	Low	Routine monitoring	R e m p w c
27 Upper Left Second Molar	Crown (Cap)	Moderate	Evaluation of fit and periodontal status	R fu re
33, 34, 35, 36 Lower Left Canine to First Molar	Crown (Bridge/Fixed Partial Denture)	Moderate	Prosthetic maintenance and hygiene instruction	M ra b s re m te lc q

Tooth	Condition	Severity	Treatment	N
43, 44, 45, 46 Lower Right Canine to First Molar	Crown (Bridge/Fixed Partial Denture)	Moderate	Prosthetic maintenance	R fi s fr c fi
Generalized Maxilla and Mandible	Bone Loss (Periodontal Disease)	High	Comprehensive periodontal therapy and deep cleaning	G h re th b h a a
18, 17, 24, 25, 26, 28, 37, 38, 47, 48 Multiple Teeth	Missing teeth (Edentulism)	High	Evaluation for further prosthetic replacement or implants	A d s th F n

Overall Severity

High

Recommendations

- Step 1: Immediate periodontal consultation for management of generalized bone loss.
- Step 2: Endodontic evaluation of teeth 12 and 11 to address periapical lesions.
- Step 3: Clinical assessment of all fixed prosthodontics (bridges and crowns) for marginal leakage.
- Step 4: Long-term maintenance plan for oral hygiene and prosthetic care.

Detailed Report

- The patient presents with significant tooth loss, with 10 teeth missing across all four quadrants.
- Extensive restorative work is present, including multiple root canal treatments in the maxillary anterior region (12, 11, 21, 22).
- Active periapical pathology is noted at the apices of teeth 12 and 11, requiring clinical intervention.
- Fixed bridge restorations are utilized in the mandibular arch to replace missing posterior teeth.

- There is evidence of advanced generalized horizontal bone loss, indicating a history of or active periodontal disease.
- The overall dental condition is complex, requiring a multidisciplinary approach involving periodontics, endodontics, and prosthodontics.