Automatic Segmentation of Cerebral Hemispheres in MR Human Head Scans

P. Kalavathi,[1] V. B. Surya Prasath[2]

[1] Department of Computer Science and Applications, Gandhigram Rural-Institute Deemed University, Gandhigram 624 302, Tamil Nadu, India

[2] Computational Imaging and VisAnalysis (CIVA) Lab, Department of Computer Science, University of Missouri-Columbia, Columbia, MO 65211, USA

Received 25 May 2015; revised 28 October 2015; accepted 15 December 2015

ABSTRACT: Automatic segmentation of cerebral hemispheres in magnetic resonance (MR) brain images help to quantify the brain asymmetry and correct several MR brain deformities. The detection of mid-sagittal plane (MSP) in human brain image is necessary to segment the hemispheres for both operator-based and automated brain image asymmetric analysis. In this article, a computationally simple and accurate technique to detect MSP in MRI human head scans using curve fitting is developed. The left and right hemispheres are segmented based on the detected MSP. The accuracy of the MSP is evaluated by comparing the segmented left and right hemispheres against the manually segmented ones. Experimental results using 78 volumes of T1, T2 and PD-weighted MRI brain images show that the proposed method has accurately segmented the cerebral hemispheres based on the detected MSP in axial and coronal orientations of normal and pathological brain images. © 2016 Wiley Periodicals, Inc. Int J Imaging Syst Technol, 26, 15–23, 2016; Published online in Wiley Online Library (wileyonlinelibrary.com). DOI: 10.1002/ima.22152

Key words: cerebral hemisphere segmentation; mid-sagittal plane; interhemispheric fissure; longitudinal cerebral fissure; MRI brain structure segmentation

I. INTRODUCTION

The human brain exhibits an approximately bilateral symmetry across the sagittal plane. An inter-hemispheric fissure (IHF) or mid-sagittal plane (MSP) separates the human brain into two distinct cerebral hemispheres. However, these two parts are almost never perfectly symmetric even for the normal brains (Geschwind and Levitsky, 1968; Guillemaud et al., 1995; Toga and Thompson, 2003; Zhao et al., 2009). The automatic detection of MSP in brain magnetic resonance (MR) images is useful in various medical imaging applications such as volumetric analysis, construction of anatomical models, 3D visualization, multimodal visualization, surgical planning as well as simulations and detection of many brain related diseases such as multiple sclerosis, schizophrenia, epilepsy, Parkinson's disease, Alzheimer's disease, cerebral atrophy, tumors and other pathologies. Several techniques have been developed for whole brain segmentation (also known as skull stripping) (Somasundram and Kalavathi, 2012a, 2013, 2014; Kalavathi and Prasath, 2015), segmentation of various brain structures for automatic diagnosis of brain related diseases such as multiple sclerosis, white matter lesion (Shiee et al., 2010; Ong et al., 2012; Kalavathi, 2013), identification of mid-sagittal plane, and multi-tissue (Moreno et al., 2014) or left right hemispheres segmentations (Liang et al., 2007; Kuijf et al., 2014). There exists wide variety of image segmentation techniques which can be utilized for brain MSP detection (Ma et al., 2009, 2010). Further, some of the higher order image processing applications of brain images like image registration (Oliveira and Tavares, 2014; Tavares, 2014; Alves and Tavares, 2015) require the detection of MSP as the first step for spatial normalization and/or anatomical standardization of brain images (Minoshima et al., 1994; Lancaster et al., 1995). Automatic detection of MSP simplifies the registration of two-dimensional brain images and bifurcation of left and right cerebral hemispheres (Kapouleas et al., 1991) and is required in many clinical applications such as brain lesions detection (Hojjatoleslami and Kruggel, 2001; Kruggel, 2004).

Brain hemispheres segmentation is often needed for various biomedical and neuro-scientific applications, because most of the brain structures have the bilateral morphology and functional lateralization (Zhao et al., 2010). Moreover, brain asymmetry analysis provides methods for computer-assisted diagnosis for mental diseases such as schizophrenia (Bilder et al., 1994; Petty, 1999; Sommer et al., 2001; Ekin, 2006). For such purposes the location of MSP is ultimately needed to estimate the head orientation. However, the scanning techniques do not use any optimal head position as a point of reference and hence a brain slice captured in different orientations may make the process of diagnosis difficult and ambiguous. The presences of various imaging artifacts (Somasundaram and Kalavathi, 2012b) may also make this process more complex. Therefore, an automated

Correspondence to: V. B. Surya Prasath; e-mail: prasaths@missouri.edu; surya.iit@gmail.com

© 2016 Wiley Periodicals, Inc.

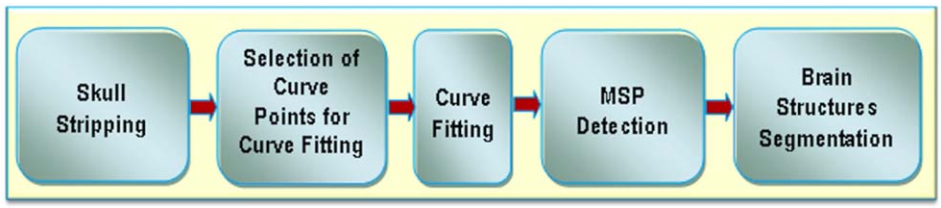

Figure 1. Block diagram of the proposed method. [Color figure can be viewed in the online issue, which is available at wileyonlinelibrary.com.]

and an efficient MSP detection is useful to bifurcate the cerebral hemispheres for various biomedical and neuro-scientific applications of brain images (Brummer, 1991; Thirion et al., 2000; Teverovskiy and Liu, 2006).

The existing algorithms to detect MSP are broadly classified into two groups based on the anatomical structure of the brain and a symmetric plane. The first group assumes the MSP of the brain as approximately a planar surface (Stegmann et al., 2005) and so, it is straightforward to find the location of MSP. However, even for the normal brain the MSP is not planar and also these types of methods are proved to be highly sensitive to image modality, orientation and artifacts. The second group of techniques defines symmetric measures to find the best plane which maximizes the similarity between the image and its reflection to detect MSP (Ardekani et al., 1997; Liu et al., 2001). But, the accuracy of these techniques depends on the type of symmetric measures used. Although, the human brain is never absolutely symmetric and the inter-hemispheric boundary is a curved surface not a straight line. Therefore, it is necessary to identify the curved MSP to segment the left and right brain hemispheres for brain asymmetric studies. In this article, a new automatic method to segment the cerebral hemispheres based on MSP in T1, T2 and PD-weighted MR brain images using second order polynomial curve fitting is developed. The proposed method was tested with 78 volumes of T1, T2 and PD-weighted brain images and accurately segments the cerebral hemispheres in the axial and coronal orientation of normal and pathological brain volumes with image noises, gray-scale inhomogeneity, partial volume effects, low contrast and various imaging artifacts. Computed similarity measures for the cerebral segmentation produced good result when compared with the gold standard left and right cerebral hemispheres. The block diagram of this proposed method is depicted in Figure 1.

The remaining part of the paper is organized as follows. In Section II, the methodological details of our proposed method are given. The results and discussions are given in Section III and the conclusion is given in Section IV.

II. MATERIAL AND METHODS

A. MSP Detection. In general, the MSP appears as a curved surface but most of the conventional methods defines it as a straight line as illustrated in Figure 2. The original T1-weighted (normal brain), T2-weighted (pathological brain) and PD-weighted (pathological brain) images from the selected dataset are shown in Figures 2a–2c, respectively. The difference between MSP detected as a straight line (white color) and as a curve (yellow color) is depicted on the same figures. The image slices shown in Figures 2b and 2c represent pathological brain, for these slices the MSP is accurately represented by curved lines than the straight lines. Hence it is clear from these figures that the MSP of a given brain slice can be accurately detected using curved lines rather than a straight line even for the normal brain (Fig. 2a). Therefore, in this article to segment the cerebral hemispheres, we have devised an efficient method to detect MSP first in 2D brain slices using a second order polynomial curve fitting approach. This MSP detection has three principal steps: (i) skull stripping (ii) curve points selection and (iii) curve fitting. These steps are discussed in the following sections in detail.

A.1. Skull Stripping. To increase the robustness of the proposed method, all the non-brain tissues such as skin, fat, muscle, neck, eye balls etc., are to be removed first from MR brain images. For this purpose, first the input brain image is enhanced to correct the contrast bias in the brain image by gamma correction method. Gamma value is automatically calculated based on the method given in

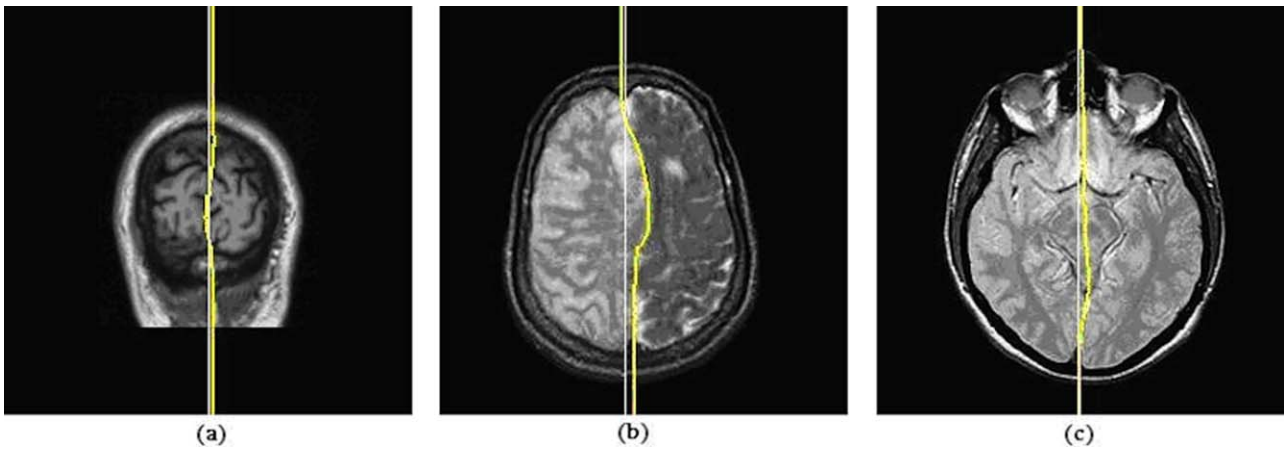

Figure 2. MSP as straight line (white line) and curve (yellow line) in 2D MRI slice; (a) T1-weighted image, (b) T2-weighted image, and (c) PD-weighted image. [Color figure can be viewed in the online issue, which is available at wileyonlinelibrary.com.]

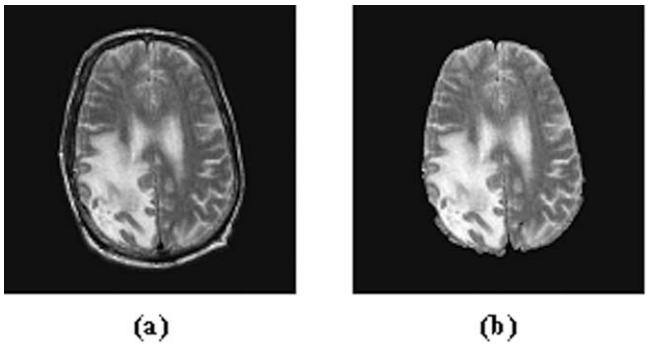

Figure 3. Removal of non-brain tissues; (a) original image and (b) skull-stripped image.

(Somasundram and Kalavathi, 2011b). Then the non-brain tissues are removed using a contour-based two-stage brain extraction method proposed in (Somasundram and Kalavathi, 2013). Note that this method finds the brain border using a robust contouring technique. A selected sample T2-weighted brain image from the chosen datasets and its corresponding skull-stripped image are shown in Figures 3a and 3b, respectively.

A.2. Curve Points Selection. After extracting the brain region from the input brain MR image, the curve points are automatically identified using the area of IHF. Usually, the IHF or longitudinal fissures appear dark in T1 and PD-weighted images and dark gray in T2-weighted image as indicated with red arrows in Figures 4a–4c. In this method, the area of the IHF is defined as a region of interest (ROI) and is positioned at the center of the image to select the curve points. The ROI is represented by a bounding box and it is defined to cover the longitudinal fissure of the brain (Fig. 5a). The width of the bounding box is estimated as W/5 (after executing this algorithm on several volumes of brain images), where W is the width of the skull-stripped brain in X-axis and the height of the bounding box is same as the height (length in Y-axis) of the skull-stripped brain. To find the curve points in the ROI for curve fitting, the selected ROI is converted into binary form by the method of image binarization using a square wave representation given in (Somasundram and Kalavathi, 2011a), since the binary images are easier to process than the gray-scale images. Once the pixels in the bounding box are converted into binary form, the dark/dark gray pixels are changed into black pixels and these black pixels in the ROI are selected as curve points. In Figure 5a, the yellow box represents the chosen ROI after binarization. The yellow stars (Fig. 5b) are the detected curve points and the white star at the middle is a center point of the bounding box. In addition to these curve points and the center point, the start and the end points (white squares) for curve fitting are included in the curve points list. The start and end points are the two intersecting points of a bounding box (top and bottom) when a vertical line is drawn by passing through the center point of the bounding box. In an unusual case, when there is no black pixel present in the binary form of the selected ROI, the proposed method uses three points (start, center and end points) for curve fitting. Then, the MSP is detected by fitting the selected curve points using a second order polynomial curve fitting method. Note that this particular approach utilizes automatic bounding box and curve points selection which are then utilized in further curve fitting thereby alleviating the need for manual seed placements.

A.3. Curve Fitting. Curve fitting is the process of constructing a curve that best fits the series of data points. The most common approach is based on the polynomial least squares method. It is a mathematical procedure to find the coefficients of the polynomial equations that best fit to a set of (x, y) data. The general form of a polynomial of order j can be expressed as:

$$y = a_0 + a_1 x + a_2 x^2 + \cdots + a_j x^j = a_0 + \sum_{k=1}^{j} a_k x^k \tag{1}$$

where, $a_0, \ldots, a_k$ are the coefficients, x represent a data point and j is the degree/order of the polynomial. A polynomial equation expresses the dependent variable y as a polynomial in the independent variable x. The coefficients $a_0, \ldots, a_k$ can be used to predict the values of y for each x that best fits, which means that the difference between the actual y values and predicted y values by the polynomial equation is to be minimized. Moreover, the polynomial order should always be lower than the number of data points for best fitting. For instance, the N-th order polynomial that best fits $N + 1$ data points. Thus, the first order polynomial fit a straight line (degree $N = 1$, the number of points are 2) through any two points with distinct x coordinates, and the second order polynomial fits a curve with a minimum of three points. When the number of points is less than $N + 1$ then it is expected to produce infinite solutions. As the proposed curve fitting

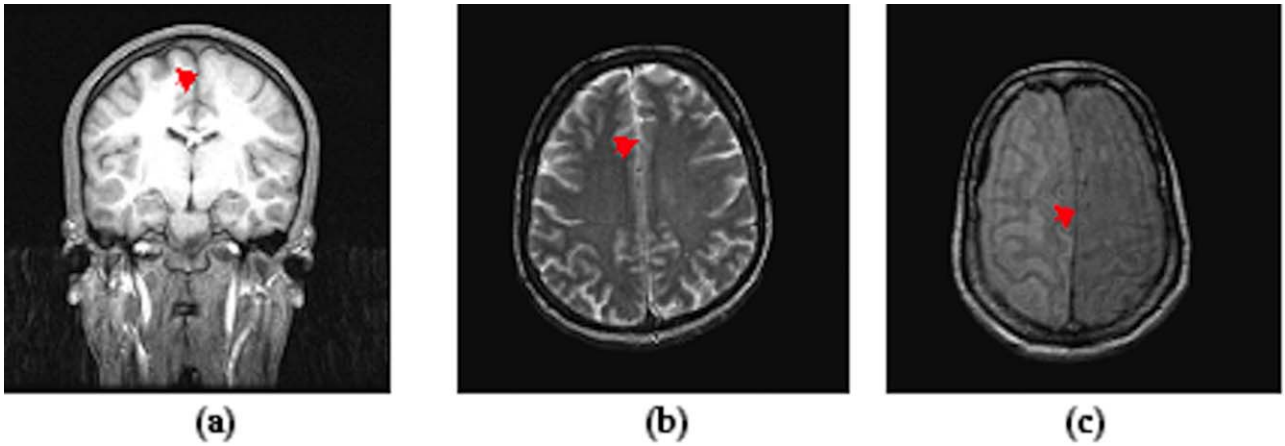

Figure 4. IHF in MR brain images denoted by red arrow; (a) T1-weighted image, (b) T2-weighted image, and (c) PD-weighted image. [Color figure can be viewed in the online issue, which is available at wileyonlinelibrary.com.]

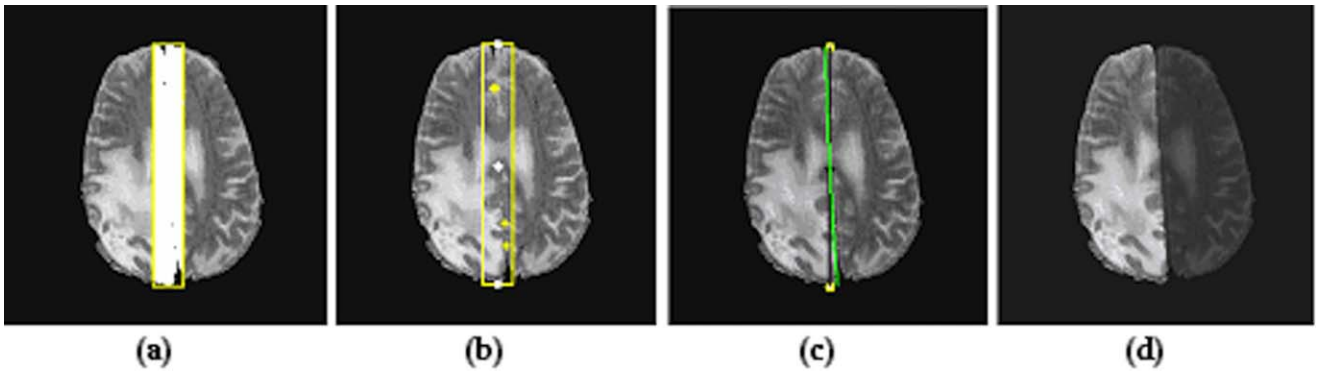

Figure 5. MSP detection; (a) selected ROI (yellow box) after binarization, (b) selected curve points (yellow points) along with start, mid and end points (white points), (c) detected MSP line (black line) and MSP curve (green line), and (c) resultant left and right segmented brain hemispheres. [Color figure can be viewed in the online issue, which is available at wileyonlinelibrary.com.]

method finds three points from the curve points selection step, a second order polynomial is ideally suited for curve fitting. It is expressed as:

$$y_i = a_0 + a_1 x_i + a_2 x_i^2 \tag{2}$$

where, $i = 1, \ldots, n$, n is the number of curve points, x_i and y_i are the data points. The coefficients a_0, a_1, a_2 of second order polynomial are computed by solving the following matrix form:

$$\begin{bmatrix} n & \sum x_i & \sum x_i^2 \\ \sum x_i & \sum x_i^2 & \sum x_i^3 \\ \sum x_i^2 & \sum x_i^3 & \sum x_i^4 \end{bmatrix} \begin{bmatrix} a_0 \\ a_1 \\ a_2 \end{bmatrix} = \begin{bmatrix} \sum y_i \\ \sum x_i y_i \\ \sum x_i^2 y_i \end{bmatrix} \tag{3}$$

where, n is the number of curve points, $\sum x$ means sum of all x values $\sum xy$ means sum of all product of x and y values etc. The computed coefficients a_0, a_1, a_2 are substituted in Eq. (2) to predict the values of y_i for each x_i. Then, the MSP is detected by fitting the curve using the curve points x_i and the corresponding predicated y_i values. The overall summary of steps involved in the proposed method is given in Algorithm 1.

Algorithm 1: MSP Detection and Cerebral Hemisphere Segmentation

Input: Skull stripped MRI head scan volume.
Output: Segmented left and right hemispheres and computed similarity measures.

1. Repeat Steps from (i) to (v) for all the brain slices in the input volume.
   i. Read the current brain slice S.
   ii. Select the curve points in S.
   iii. Fit the curve using the second order polynomial curve fitting method to detect MSP.
   iv. Segment the brain slice S into left and right brain hemispheres based on the detected MSP and denote them as image A and B respectively.
   v. Read the corresponding left and right brain hemispheres in the gold standard or ground truth images (if available) and denote them as image A′ and B′ and compute the D and J value using (A and A′) and (B and B′).

In Figure 5c, the detected MSP curve is represented as green line, and the MSP line drawn using the three points (start, center and end) is represented as black line in the same figure. It can be seen from Figure 5c that the detected MSP curve could accurately segment the brain hemispheres than the straight line. Figure 5d, is the resultant left and right segmented brain image using MSP curve detected in Figure 5c.

We note that higher order splines can also be utilized at the curve fitting stage, but at the expense of slower computing times as splines require tuning of the control points. Here our aim was to show a simple polynomial is sufficient to obtain satisfactory MSP segmentations.

The accuracy of the proposed approach is evaluated using region overlap based similarity measures. The common similarity metrics based on region overlap are Jaccard (J) (Jaccard, 1912) and Dice (D) (Dice, 1945). The J and D metrics take two images as an input and produce values between 0 and 1. The value varies from 0 for complete disagreement to 1 for complete agreement between the two images.

Table I. Computed Jaccard (J) and Dice (D) similarity measures by the proposed method for Dataset-1.

	Volume Name	Left brain		Right brain	
		J	D	J	D
1	IBSR_01	0.927	0.953	0.919	0.943
2	IBSR_02	0.946	0.965	0.948	0.965
3	IBSR_03	0.904	0.924	0.907	0.926
4	IBSR_04	0.935	0.954	0.932	0.950
5	IBSR_05	0.858	0.789	0.845	0.859
6	IBSR_06	0.937	0.951	0.930	0.918
7	IBSR_07	0.876	0.910	0.882	0.911
8	IBSR_08	0.871	0.897	0.877	0.901
9	IBSR_09	0.920	0.936	0.921	0.937
10	IBSR_10	0.875	0.914	0.895	0.916
11	IBSR_11	0.853	0.869	0.854	0.868
12	IBSR_12	0.943	0.961	0.942	0.959
13	IBSR_13	0.961	0.976	0.963	0.978
14	IBSR_14	0.955	0.976	0.949	0.968
15	IBSR_15	0.941	0.964	0.911	0.926
16	IBSR_16	0.909	0.943	0.852	0.871
17	IBSR_17	0.943	0.958	0.934	0.946
18	IBSR_18	0.883	0.920	0.838	0.862
	Mean	0.913	0.931	0.906	0.922
	STD	0.035	0.046	0.039	0.038

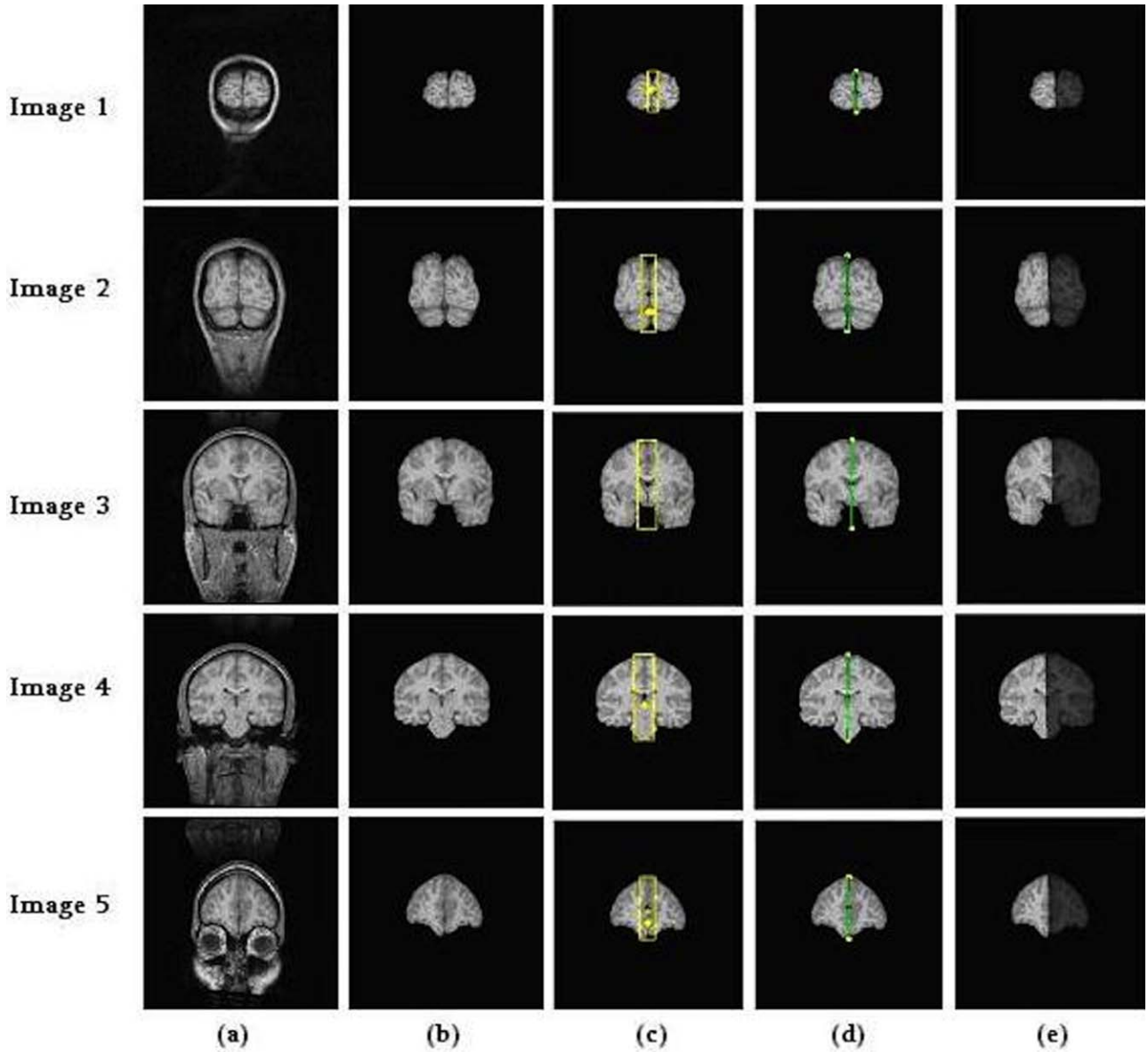

Figure 6. Results of MSP detection and hemisphere segmentation in T1-weighted images; (a) original image, (b) skull-stripped image, (c) selected ROI with curve points, (d) detected MSP curve (green line) and line (black line), and (e) segmented left and right brain structures. [Color figure can be viewed in the online issue, which is available at wileyonlinelibrary.com.]

The J and D are computed by:

$$J(S_1, S_2) = \frac{|S_1 \cap S_2|}{|S_1 \cup S_2|} \tag{4}$$

$$D(S_1, S_2) = \frac{2|S_1 \cap S_2|}{|S_1| + |S_2|} \tag{5}$$

where S_1 represents the total pixels in the left/right segmented brain image obtained by the proposed segmentation method, and S_2 represents the total pixels in the left/right brain image obtained from ground truth (gold standard) image.

B. Brain Image Datasets Used. *B.1. Dataset-1.* Eighteen volumes of T1-weighted images were obtained from the Internet Brain Segmentation Repository (IBSR) of the Centre for Morphometric Analysis (CMA) at the Massachusetts General Hospital (Available online at http://www.nitrc.org/projects/ibsr). Each volume consists of 128 two-dimensional sequential coronal slices with dimensions of 256 × 256 pixels and the slice thickness is 1.5 mm. These MRI scans are acquired from all age groups including juvenile to old age. The IBSR also maintains the manually segmented (ground truth or gold standard) brain mask and delineation of the brain structures performed by trained experts. Several volumes of these dataset had relatively low contrast images.

B.2. Dataset-2. Twenty volumes of T1-weighted images were also obtained from IBSR. It contains MR brain volumes obtained from young-middle aged normal individuals. Each volume consists of T1-weighted 2D sequential coronal slices with dimensions of 256 × 256 pixels. The number of slices ranges from 60 to 65 and the slice thickness is 3.1 mm. Several volumes of this dataset had severe

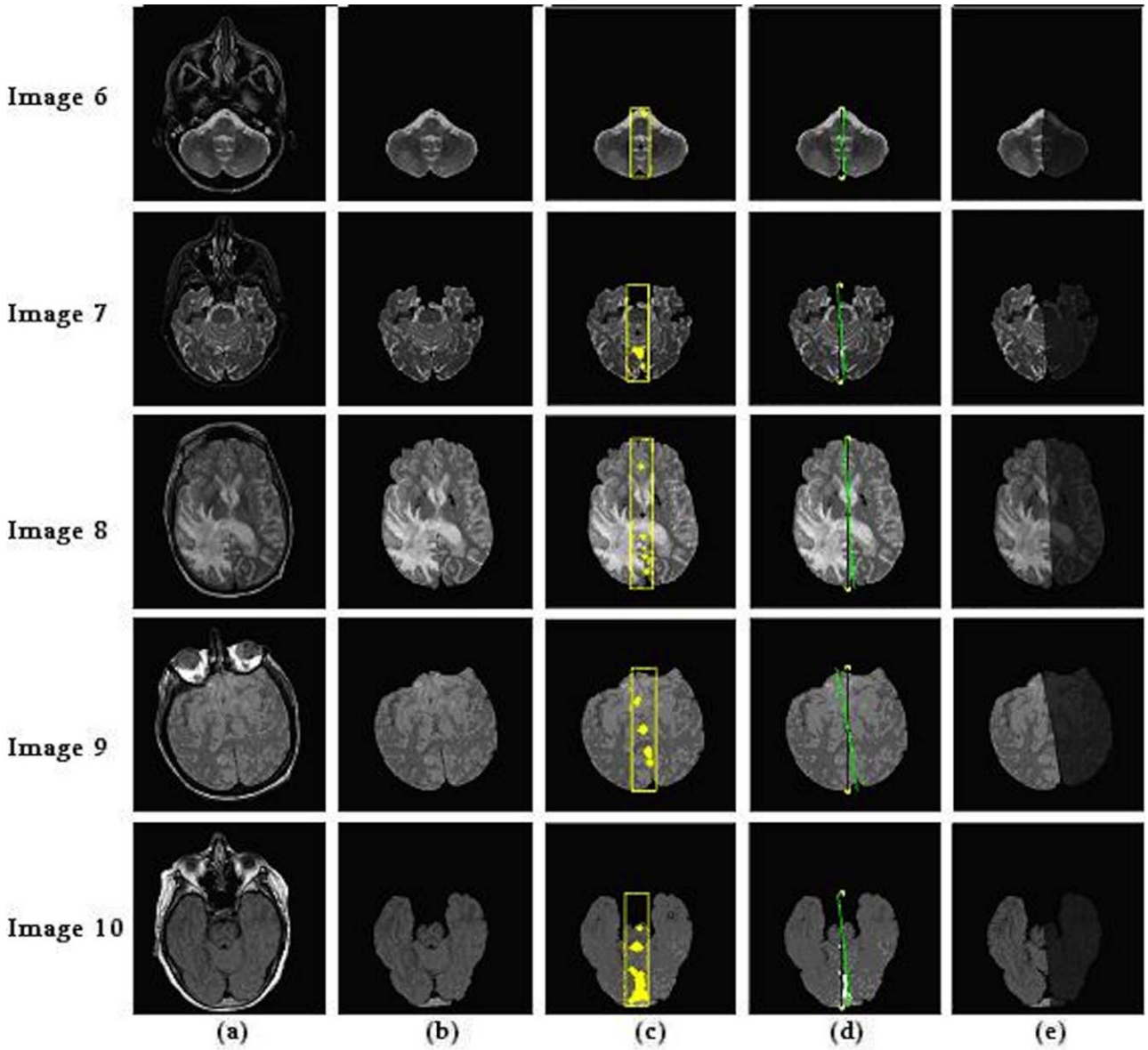

Figure 7. Results of MSP detection and hemisphere segmentation in T2 and PD-weighted images; (a) original image, (b) skull-stripped image, (c) selected ROI with curve points, (d) detected MSP curve (green line) and line (black line), and (e) segmented left and right brain structures. [Color figure can be viewed in the online issue, which is available at wileyonlinelibrary.com.]

intensity inhomogeneities caused by the non-uniformity of magnetic fields, radio frequency coils and noise factors.

B.3. Dataset-3. Twenty volumes of normal and abnormal brain images were collected from the website The Whole Brain Atlas (WBA) maintained by the Department of Radiology and Neurology of Brigham and Womens Hospital, Harvard Medical School, the Library of Medicine and the American academy of neurology (Available online at http://www.med.harvard.edu/aanlib/home.html). Each volume consists of T2-weighted axial slices with dimensions of 256 × 256 pixels. The slice thickness varies from 2 to 5 mm with 260 mm field of view. The number slices ranges from 18 to 56. The first two volumes are normal volumes and the remaining 18 are abnormal volumes.

B.4. Dataset-4. Twenty volumes of normal and abnormal brain volumes, used in this experiment were collected from the WBA. Each volume consists of PD-weighted axial slices with dimensions of 256 × 256 pixels. The slice thickness varies from 2 to 5 mm with 260 mm field of view. The number slices ranges from 17 to 55. The first volume is a normal volume and the remaining 19 are abnormal volume.

III. RESULTS AND DISCUSSION

The accuracy of the proposed segmentation method was tested using T1, T2 and PD-weighted brain images of chosen datasets (Dataset-1 to Dataset-4). As a preprocessing step, the non-brain tissues are removed from the input brain slices. For quantitative analysis, the Jaccard (J) and Dice (D) similarity measures were calculated for the Dataset-1 (since only this dataset contain the hand-stripped delineation of the brain structures) using the Eqs. (4) and (5) respectively. The J and D values were computed separately for the segmented left

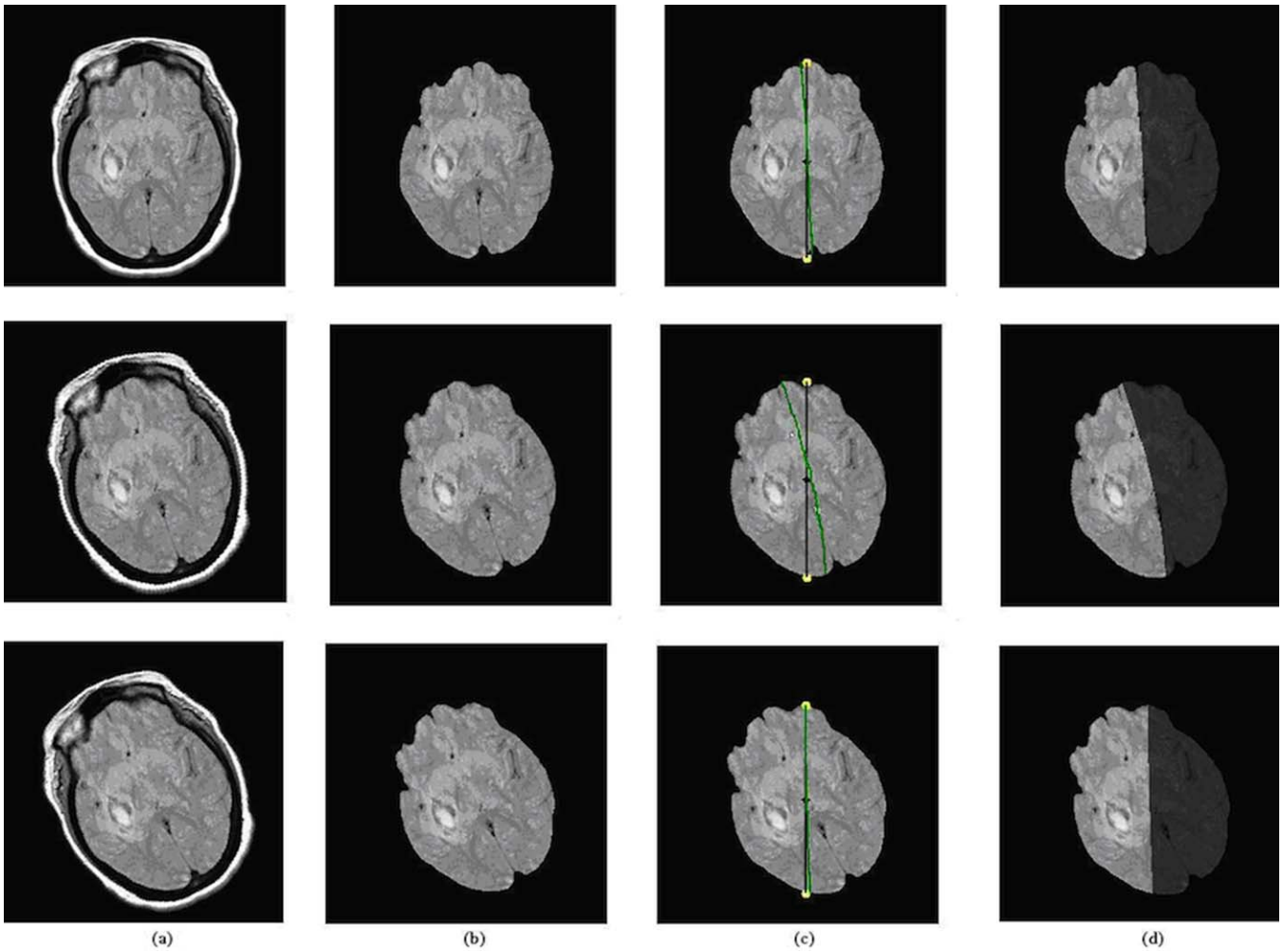

Figure 8. Results of hemisphere segmentation in rotated images; (a) original brain slice, (b) skull-stripped image, (c) detected MSP curve (green line) and line (black line), and (d) segmented left and right hemispheres. [Color figure can be viewed in the online issue, which is available at wileyonlinelibrary.com.]

and right brain hemispheres and are given in Table I. The proposed method has produced average (Mean) and standard deviation (STD) value of $J = 0.913 \pm 0.035$ and $D = 0.931 \pm 0.046$ for left brain of Dataset-1. The obtained Mean and STD of J and D value for right brain are $J = 0.906 \pm 0.039$ and $D = 0.922 \pm 0.038$ respectively. Although several volumes of these datasets have low contrast images, the proposed method has produced consistent and promising results for all the eighteen volumes of Dataset-1.

The proposed method is also applied to analyze the performance on Dataset-2, Dataset-3, and Dataset-4. The qualitative measures were carried out on these datasets since the repositories of these datasets has not provided the hand-stripped delineated (gold standard) images of the brain structures. The result of MSP detection and hemisphere segmentation for a few sample images of T1, T2 and PD-weighted brain images of Dataset-2, Dataset-3 and Dataset-4 are shown in Figures 6 and 7. T1-weighted images are given in Figure 6, and T2 and PD-weighted images are shown in Figure 7.

In Figures 6 and 7, the first columns (6(a) and 7(a)) are the original brain images labeled as Image1 to Image10 and their corresponding skull-stripped images are given in the respective next columns in Figures 6b and 7b. The selected ROI is shown as a yellow box, and the yellow points inside of this box are the curve points as represented in Figures 6c and 7c, in addition to these points, the start, center and end points are included in the curve point list. The detected MSP line (black line) and curve (green line) for all these images are drawn and represented in Figures 6d and 7d. The segmented left and right brain using the detected MSP curve are presented in Figures 6e and 7e. For visual comparison, the segmented right brains are represented darker than the left brain. It is also evident from the Figures 6d and 7d that the MSP detected using curve gives the accurate segmentation of left and right hemispheres than detected by straight line. Based on the quantitative and qualitative measures on all the volumes of Dataset-1 to Dataset-4, it is found that the proposed method has produced better and consistent results and is also robust on pathological brain images having various noises and image artifacts. From the experimental results it is found that, the proposed algorithm have also accurately segmented the cerebellum and brain stem (Fig. 6 (Image 2 & Image 4) and Fig. 7 (Image 6, Image 7 & Image 10)) in addition to the segmentation of the cerebral hemispheres.

Although, the proposed method has exhibited the best performance on axial and coronal oriented T1, T2 and PD-weighted brain images of Dataset-1 to Dataset-4, sometimes it may fail to detect the MSP accurately if the image slice is rotated largely or when the head

is positioned away from the optimal position thereby keeping the MSP away from the selected ROI and illustrated in Figure 8. Fortunately, none of the brain slices in the selected volumes (Dataset-1 to Dataset-4) had these problems. In Figure 8, row 1 shows MSP detection on the original PD-weighted brain slice from Dataset-4 and row 2 of Figure 8 denotes the MSP detection when the original image is rotated by 15°. The resultant MSP detection when the original image is rotated by 20° is given in row 3 of Figure 8. From this illustration, it is found that the proposed method detects the MSP accurately even when the image is rotated by 15° and at the worst case it just divides the image vertically into two parts as shown in row 3 of Figure 8. Furthermore, any failure in the skull stripping may also influence the accuracy of the proposed hemisphere segmentation method.

IV. CONCLUSION

A computationally simple and robust cerebral hemispheres segmentation method presented in this article was evaluated with normal and pathological T1, T2 and PD-weighted MR brain images having practical noises, artifacts and varying morphologies. According to the experimental results, it is proved that the proposed MSP detection method correctly identifies the MSP and thus enables to segment the left and right hemispheres accurately. We compared our method with hand-stripped delineation of the brain structures of eighteen volumes with different artifacts, and overall our automatic results indicate above good accuracy when compared to the manual results. Further works include detailed comparison of related MSP detection algorithms for benchmarking the accuracy, robustness of MSP separation in different 3D brain MR volumes and handling large rotations or brain torque. Unfortunately there are no standardized ways to compare different MSP detection methods on 3D brain volumes. Nevertheless, benchmarking available MSP detection algorithms for accuracy and robustness is an important avenue in this area that requires further research.

CONFLICT OF INTEREST

Authors declare that there is no conflict of interest.

REFERENCES

R.S. Alves and J.M.R.S. Tavares, Computer image registration techniques applied to nuclear medicine images, Proc ICCEBS, Springer LNCVB 21, 2015, pp. 173–191.

B.A. Ardekani, J. Kershaw, M. Braun, and I. Kanuo, Automatic detection of the mid- sagittal plane in 3-D brain images, IEEE Trans Med Imaging 16 (1997), 947–952.

R.M. Bilder, H. Wu, B. Bogerts, G. Degreef, M. Ashtari, J.M. Alvir, P.J. Snyder, and J.A. Lieberman, Absence of regional hemispheric volume asymmetries in first-episode schizophrenia, Am J Psychiatry 151 (1994), 1437–1447.

M.E. Brummer, Hough transforms detection of the longitudinal fissure in tomographic head image, IEEE Trans Med Imaging 10 (1991), 74–81.

L. Dice, Measures of the amount of ecologic association between species, Ecology 26 (1945), 297–302.

A. Ekin, Feature-based brain mid-sagittal plane detection by RANSAC, Proc IEEE EUSIPCO, 2006, pp. 1–4.

N. Geschwind and W. Levitsky, Human brain: Left-right asymmetries in temporal speech region, Science 161 (1968), 186–187.

R. Guillemaud, P. Marais, A. Zisserman, T. McDonald, and B. Crow, A 3-dimensional midsagittal plane for brain asymmetry measurement, Schizophr Res 18 (1995), 183–184.

S.A. Hojjatoleslami and F. Kruggel, Segmentation of large brain lesions, IEEE Trans Med Imaging 20 (2001), 666–669.

P. Jaccard, The distribution of flora in alpine zone, New Phytol 11 (1912), 37–50.

P. Kalavathi, Brain tissue segmentation in MR brain images using Otsu's multiple thresholding technique, Proc IEEE ICCSE Conf, 2013, pp. 639–642.

P. Kalavathi and V.B.S. Prasath, Methods on skull stripping of MRI head scan images—A review, J Digit Imaging (2015), http://dx.doi.org/10.1007/s10278-015-9847-8.

I. Kapouleas, A. Alavi, W.M. Alves, R.E. Gur, and D.W. Weiss, Registration of three-dimensional MR and PET images of the human brain without markers, Radiology 181 (1991), 731–739.

F. Kruggel, Segmentation of focal brain lesions, Proc MIAR Conf, Springer LNCS 3150, 2004, pp. 10–18.

H.J. Kuijf, S.J. van Veluw, M.I. Geerlings, M.A. Viergever, G.J. Biessels, and K.L. Vincken, Automatic extraction of the midsagittal surface from brain MR images using the Kullback-Leibler measure, Neuroinformatics 12 (2014), 395–403.

J.L. Lancaster, T.G. Glass, B.R. Lankipalli, H. Downs, H. Mayberg, and P.T. Fox, A modality-independent approach to spatial normalization of tomographic images of the human brain, Human Brain Mapping 3 (1995), 209–223.

L. Liang, K. Rehm, R.P. Woods, and D.A. Rottenberg, Automatic segmentation of left and right cerebral hemispheres from MRI brain volumes using the graph cuts algorithm, NeuroImage 4 (2007), 1160–1170.

Y. Liu, R.T. Collins, and W.E. Rothfus, Robust midsagittal plane extraction from normal and pathological 3D neuroradiology images, IEEE Trans Med Imaging 20 (2001), 175–192.

Z. Ma, J.M.R.S. Tavares, and R.N. Jorge. A review on the current segmentation algorithms for medical images, Proc IMAGAPP, INSTICC Press, 2009, pp. 135–140.

Z. Ma, J.M.R.S. Tavares, R.N. Jorge, and T. Mascarenhas, A review of algorithms for medical image segmentation and their applications to the female pelvic cavity, Comput Methods Biomech Biomed Eng 13 (2010), 235–246.

S. Minoshima, R.A. Koeppe, K.A. Frey, and D.E. Kuhl, Anatomic standardization: Linear scaling and nonlinear warping of functional brain images, J Nucl Med 35 (1994), 1528–1537.

J.C. Moreno, V.B.S. Prasath, H. Proenca, and K. Palaniappan, Fast and globally convex multiphase active contours for brain MRI segmentation, Comput Vis Image Underst 125 (2014), 237–250.

F.P. Oliveira and J.M.R.S. Tavares, Medical image registration: A review, Comput Methods Biomech Biomed Eng 17 (2014), 73–93.

K.H. Ong, D. Ramachandram, R. Mandava, and I.L. Shuaib, Automatic white matter lesion segmentation using an adaptive outlier detection method, Magn Reson Imaging 30 (2012), 807–823.

R.G. Petty, Structural asymmetric of human brain and their disturbance in schizophrenia, Schizophr Bull 25 (1999), 121–139.

N. Shiee, P.L. Bazin, A. Ozturk, D.S. Reich, P.A. Calabresi, and D.L. Pham, A topology-preserving approach to the segmentation of brain images with multiple sclerosis lesions, NeuroImage 49 (2010), 1524–1534.

K. Somasundram and P. Kalavathi, Medical image binarization using square wave representation, Proc ICLICC, Springer CCIS 140, 2011a, pp. 152–158.

K. Somasundram and P. Kalavathi, Medical image contrast enhancement based on gamma correction, Int J Knowl Manag e-Learning 3 (2011b), 15–18.

K. Somasundram and P. Kalavathi, A novel skull stripping technique for T1-weighted MRI human head scans, Proc ICVGIP Conf, ACM Digital Library, 2012a, pp. 1–8.

K. Somasundaram and P. Kalavathi, Analysis of imaging artifacts in MR brain images, Oriental J Comput Sci Technol 5 (2012b), 135–141.

K. Somasundram and P. Kalavathi, Contour-based brain segmentation method for magnetic resonance imaging human head scans, J Comput Assist Tomogr 37 (2013), 353–368.

K. Somasundram and P. Kalavathi, Brain segmentation in magnetic resonance human head scans using multi-seeded region growing, Imaging Sci J 62 (2014), 273–284.

I. Sommer, N. Ramsey, R. Kahn, A. Aleman, and A. Bouma, Handedness, language lateralization and anatomical asymmetry in schizophrenia: Meta-analysis, Br J Psychiatry 178 (2001), 344–351.

M.B. Stegmann, K. Skoglund, and C. Ryberg, Mid-sagittal plane and mid-sagittal surface optimization in brain MRI using a local symmetry measure, Proc SPIE Medical Imaging Conf, 2005, pp. 568–579.

J.M.R.S. Tavares, Analysis of biomedical images based on automated methods of image registration, Proc ISVC, Springer LNCS 8887, 2014, pp. 21–30.

L. Teverovskiy and Y. Liu, Truly 3D midsagittal plane extraction for robust neuroimage registration, Proc IEEE ISBI, 2006, pp. 860–863.

J.P. Thirion, S. Prima, G. Subsol, and N. Roberts, Statistical analysis of normal and abnormal dissymmetry in volumetric medical images, Med Image Anal 4 (2000), 111–121.

A.W. Toga and P.M. Thompson, Mapping brain asymmetry, Nat Rev Neurosci 4 (2003), 37–48.

L. Zhao, J. Hietala, and J. Tohka, Shape analysis of human brain interhemispheric fissure bending in MRI. Proc MICCAI Conf, Springer LNCS 5762, 2009, pp. 216–223.

L. Zhao, U. Ruotsalainen, J. Hirvonen, J. Hietala, and J. Tohka, Automatic cerebral and cerebellar hemisphere segmentation in 3D MRI: Adaptive disconnection algorithm, Med Image Anal 14 (2010), 360–372.