Dynamic 2D Ultrasound and 3D CT Image Registration of the Beating Heart

Xishi Huang*, *Member, IEEE*, John Moore, Gerard Guiraudon, Douglas L. Jones, Daniel Bainbridge, Jing Ren, *Member, IEEE*, and Terry M. Peters, *Fellow, IEEE*

***Abstract*—Two-dimensional ultrasound (US) is widely used in minimally invasive cardiac procedures due to its convenience of use and noninvasive nature. However, the low quality of US images often limits their utility as a means for guiding procedures, since it is often difficult to relate the images to their anatomical context. To improve the interpretability of the US images while maintaining US as a flexible anatomical and functional real-time imaging modality, we describe a multimodality image navigation system that integrates 2D US images with their 3D context by registering them to high quality preoperative models based on magnetic resonance imaging (MRI) or computed tomography (CT) images. The mapping from such a model to the patient is completed using spatial and temporal registrations. Spatial registration is performed by a two-step rapid registration method that first approximately aligns the two images as a starting point to an automatic registration procedure. Temporal alignment is performed with the aid of electrocardiograph (ECG) signals and a latency compensation method. Registration accuracy is measured by calculating the TRE. Results show that the error between the US and preoperative images of a beating heart phantom is 1.7 ± 0.4 mm, with a similar performance being observed in *in vivo* animal experiments.**

***Index Terms*—Beating heart surgery, beating heart surgical navigation, image-guided cardiac surgery, multimodality image registration, temporal synchronization.**

Manuscript received July 19, 2008; revised December 07, 2008. First published January 06, 2009; current version published July 29, 2009. This work was supported in part by the Canadian Foundation for Innovation, in part by the Ontario Innovation Trust, in part by the Canadian Institutes for Health Research (MOP 74626), in part by the Natural Sciences and Engineering Council of Canada, and in part by the Ontario Consortium for Image-guided Therapy and Surgery. *Asterisk indicates corresponding author.*

*X. Huang was with Imaging Research Laboratories, Robarts Research Institute, London, ON, N6A 5K8 Canada. He is now with The Hospital for Sick Children, Toronto, ON M5G 1X8 Canada (e-mail: edward.huang@sickkids.ca).

J. Moore is with Imaging Research Laboratories, Robarts Research Institute, London, ON, N6A 5K8 Canada (e-mail: jmoore@imaging.robarts.ca).

G. Guiraudon is with the Canadian Surgical Technology and Advanced Robotics (CSTAR) and London Health Sciences Centre, Imaging Research Laboratories, Robarts Research Institute, London, ON, N6A 5K8 Canada (e-mail: gguiraud@uwo.ca).

D. Jones is with Departments of Physiology and Pharmacology and Medicine, The University of Western Ontario, London, ON N6A 5C1, Canada, and also with CSTAR, London Health Sciences Centre, London, ON, N6A 5A5 Canada (e-mail: doug.jones@schulich.uwo.ca).

D. Bainbridge is with Department of Anesthesia and Perioperative Medicine, London Health Sciences Centre, University of Western Ontario, London, ON N6A 5A5, Canada (e-mail: daniel.bainbridge@lhsc.on.ca).

J. Ren is with the Faculty of Engineering and Applied Sciences, University of Ontario Institute of Technology, Oshawa, ON, L1H 7K4 Canada (e-mail: jing.ren@uoit.ca).

T. M. Peters is with the Biomedical Engineering Graduate Program and Department of Medical Biophysics, The University of Western Ontario and Imaging Research Laboratories, Robarts Research Institute, London, ON, N6A 5K8 Canada (e-mail: tpeters@robarts.ca).

Color figures are available online at http://ieeexplore.ieee.org.

Digital Object Identifier 10.1109/TMI.2008.2011557

I. Introduction

ENDOSCOPY-BASED techniques for minimally invasive epi-cardiac interventions are relatively mature [1], and the efficacy of these procedures can be further improved by fusion of endoscope images with a virtual dynamic 3D computed tomography/magnetic resonance (CT/MR) model [2]. However, procedures performed inside the beating heart, such as implantation of mitral valves and repair of atrial septal defects, generally lack adequate image guidance at both the procedure-planning and guidance phases. These procedures involve introducing surgical tools directly inside the cardiac chamber, so that conventional optical imaging modalities cannot be used for guidance. Alternative intra-cardiac visualization methods, such as interventional computed tomography (CT), magnetic resonance imaging (MRI), or ultrasound (US) must be considered instead.

Interventional CT or MRI units are capable of producing detailed and comprehensive images of the beating heart. Ideally, these modalities would be readily available in the operating room (OR), and attempts have been made towards achieving this goal [3], [4]. However, at present the use of MRI as an interventional imaging modality has been limited, due to a number of implementation issues including restricted surgical access, incompatibility with conventional surgical instruments, and increased expense and complexity of procedures. Also, the advent of "CT fluoroscopy" or "fluoro CT" has established CT scanning as a true intra-operative imaging modality. Lauritsch *et al.* [5] discussed the recent advancement in C-arm computed tomography and demonstrated the feasibility of C-arm guidance in simulation in both an experimental phantom and in preclinical *in vivo* studies. In spite of its appealing capability to distinguish bones from soft tissues, CT images show only small contrast differences in the anatomy of the heart and require the use of X-ray contrast to adequately delineate the cardiac chambers. Moreover, interventional CT exposes both the patient and surgeon to harmful ionizing radiation. Likewise, the use of intra-operative X-ray fluoroscopy in cardiac interventions is also restricted by radiation exposure, and low contrast between heart tissue and blood pool. In spite of these limitations, unsubtracted X-ray angiography is routinely used in the diagnosis and therapy of cardiac disease [6].

US imaging is an attractive alternative to CT and MRI during surgery due to its safety, comparatively low cost, ease of use, minimal disruption of the procedure, and lack of compatibility problems between US imaging and standard OR equipment. Although real-time 3D US is being adapted to beating heart

0278-0062/$26.00 © 2009 IEEE
Authorized licensed use limited to: Florida Institute of Technology. Downloaded on May 12,2025 at 00:40:28 UTC from IEEE Xplore. Restrictions apply.

surgery [7], [8], it is still a new and relatively expensive procedure compared to 2D US and the limited access to the streaming 3D data makes it poorly suited to real-time fusion with other images. Real-time 2D US imaging (cardiac echo), such as the routinely used trans-esophageal echo (TEE) and intra-cardiac echo (ICE) systems, has relatively high spatial and temporal resolution. Despite the inferior image quality compared with CT or MRI, 2D US is employed routinely during cardiac interventions.

The ability to correlate 2D US images with preoperative dynamic 3D CT/MR images would provide the surgeon with complementary information captured in two different modalities, and greatly facilitate the interpretation of the images. In a combined navigation system, the orientation of the 2D US transducer can then be flexibly adjusted to track the location of surgical tools, which are constantly compared to the surrounding anatomy and targets depicted in 3D virtual models. In addition, the overlay of 2D US and 3D virtual models offers a potential means of providing image-guidance for procedures that involve both anatomical and functional imaging.

Image registration is essential to integrate intra-operative US with preoperative CT images. Existing literature outlines methods and techniques for multimodality image registration [9]–[13]. 3D–3D registration has been used for image guidance in neurosurgical applications [14], abdominal interventions [15], orthopedic applications [16], and offline cardiac analysis [17], [18]. Since a single 2D US slice contains less information than a 3D volume, 2D–3D registration is a more challenging task and deserves separate investigation. 2D to 3D registration can be grouped into several registration methods, including feature-based [19], intensity-based [20], [21], and hybrid methods [22]. There are two main categories of 2D to 3D registration. The first involves establishing correspondence between 3D volumes and 2D projection images, such as X-ray or video images [2], [22]. The second approach is to derive a transformation that maps the 2D slice from ultrasound, CT, or MRI to its 3D pre-operative counterpart, which is further detailed as follows.

2D Slice to 3D Volume Registration: Specifically, the 2D slice is one slice imaged from a 3D object with an arbitrary pose and is equivalent to a slice extracted from a 3D volume of the object. Micu *et al.* [23] registered interventional 2D CT-fluoroscopy to high-resolution contrast-enhanced preoperative CT image data using an intensity-based similarity measure for a radio-frequency liver ablation procedure. Similarly, Xu *et al.* [24] employed an intensity-based similarity metric within a small region to register intra-operative 2D CT-fluoroscopy images to a preoperative CT volume to track the motion of pulmonary lesions for a robotically assisted lung biopsy. Smolikova–Wachowiak *et al.* [25] used intensity-based similarity measures to register intraprocedural 2D MR images with preprocedural 3D MR images during an MRI-guided intervention. Finally, Penny *et al.* [26] performed a rigid registration to align tracked surgical instruments with the CT images.

To facilitate the registration of 2D US with preoperative 3D images, some researchers have recently developed registration approaches to align a set of multiple tracked 2D US images with preoperative 3D models. In a static heart phantom study, Zhong *et al.* [27] employed an iterative closest point (ICP) method to register the surface points of left atrium extracted from multiple tracked 2D intracardiac ultrasound images to the surface model derived from CT images to guide a left atrium endocardium ablation procedure. Wein *et al.* [28] registered multiple tracked 2D US abdominal images to 3D CT/CTA using a new similarity measure that assesses the correlation of ultrasound with the simulated ultrasound from CT, while Sun *et al.* [29] aligned a set of 2D ICE images with preoperative 3D CT images only at one cardiac phase for complex ablation procedures by maximizing the normalized cross-correlation of the ICE images and CT gradient magnitude slices. These techniques are essentially equivalent to aligning preoperative 3D images with the "reconstructed" 3D US image without the need for explicit 3D reconstruction.

In most of above applications, registration speed is generally not a critical issue, whereas during cardiac procedures it is a primary concern, as image registration must be completed rapidly. In this study, we extend our two-step rapid 3D–3D registration method [30] to 2D–3D registration.

Previous work in our lab towards the goal of an image-guided cardiac intervention environment has included the development of a cardiac surgery planning environment [31], an angiography-based registration system [22], a means of integrating endoscopic information with dynamic cardiac models [2], and the development of a virtual-reality based system for intra-cardiac intervention [32].

In this paper, we discuss the implementation of a navigation system using fused intra-operative real-time 2D US and preoperative dynamic 3D CT images of the heart. Issues such as temporal synchronization of imaging and tracking components and image spatial registration are investigated, and a laboratory version of the system is evaluated using a beating heart phantom. We also evaluate this system in an animal study.

The paper is organized as follows. In Section II, we describe the system components and the details of both the laboratory and *in vivo* investigations. In Section III, we present the experimental results, and in Section IV, we discuss the limitations of the proposed system and possible future improvements. Section V concludes with a discussion of future research directions.

II. Materials and Method

In this section, we first describe a prototype of a real-time 2D US-based surgical navigation system, and then investigate a method for dynamically registering preoperative dynamic 3D CT images to intra-operative real-time 2D US images of the heart. In the laboratory study, we focused on registration and synchronization issues. To minimize the errors due to the tracking system, we used the Polaris optical tracking system (OTS) (tracking accuracy $\sim$0.3 mm) to track a hand-held US probe. A realistic environment was simulated using a beating heart phantom (BHP). For the animal study, we employed a magnetic tracking system (MTS) to track the TEE probe inside the esophagus.

A. System Description

A schematic of the prototype real-time 2D US-based surgical navigation system, augmented with preoperative dynamic 3D CT images, is shown in Fig. 1. The tracking system is employed to determine the pose (i.e., position and orientation) of the US transducer, while the electrocardiograph (ECG) signals are used

Authorized licensed use limited to: Florida Institute of Technology. Downloaded on May 12,2025 at 00:40:28 UTC from IEEE Xplore. Restrictions apply.

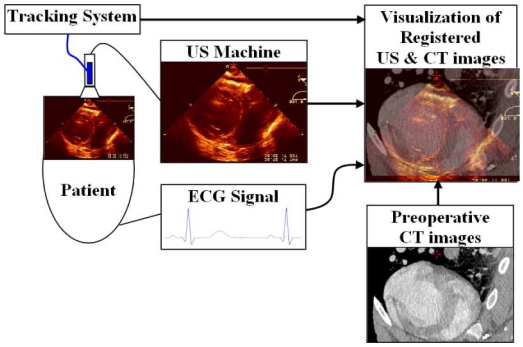

Fig. 1. The prototype of a real-time surgical navigation system. Preoperative dynamic 3D CT images are employed to provide an appropriate context to improve the interpretability of intra-operative 2D US images, an ECG signal temporally synchronizes the dynamic US and CT images, a tracking system tracks the position and orientation of the US probe to accelerate intra-operative US-CT registration, and fusion of registered US-CT images provides surgical navigation for intracardiac surgery.

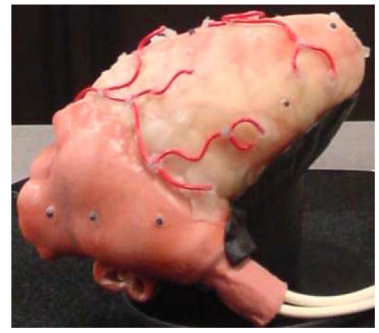

Fig. 2. Beating heart phantom.

to synchronize image datasets with the real-time cardiac motion. A detailed description for each component is provided in Section II-B.

Surgical navigation for minimally invasive cardiac surgery is a complex process, and we propose a workflow for this procedure as follows.

1) *Preoperative*: Prior to surgery, preoperative dynamic 3D MR or CT images of the beating heart are acquired and the image datasets are transferred to the workstation. The role of these images is to provide a high quality context for intra-operative real-time 2D US images.
2) *Peri-operative*: After the patient is set up in the OR, just prior to surgery, peri-operative US images augmented with spatial tracking information and ECG signals are acquired. These US images are then registered to the preoperative images. This preliminary registration cannot be expected to accurately bring the dynamic images into exact registration with the US image, but it provides a convenient starting point for an explicit image-based registration procedure.
3) *Intra-operative*: Using the initial registration from the peri-operative step, the mutual information (MI) metric [33] is maximized by a gradient ascent method to optimize the registration of the two images. After registration, the overlaid images are fused and displayed to provide a real-time environment where the intra-operative US and the preoperative CT images are aligned spatially and temporally.

B. Components of the Simulation Environment

1) *Beating Heart Phantom*: We use a beating heart phantom (Fig. 2) (Chamberlain Group, Great Barrington, MA) for validation and performance assessment. An air pump is attached to the phantom and operated by a controller that inflates and deflates chambers within the phantom to simulate realistic cardiac contraction. The controller outputs a simulated real-time ECG trigger from which the heart rate and cardiac phase can be established. In this study, fiducial markers (2.5-mm-diameter bead targets) were attached to the surface of the heart phantom. These fiducial markers could be identified in both CT and US and were used to evaluate the registration accuracy.
2) *ECG Signal Generator*: This device is directly connected to the computer parallel port for real-time ECG signal acquisition.
3) For our laboratory tests, we used an Aloka SSD-2000 ultrasound machine (Aloka Company, Ltd, Tokyo, Japan) to acquire real-time 2D ultrasound images of the phantom with an Aloka UST-9104-5 neuro probe with the array dimensions of 27 mm wide $\times$ 11.5 mm high at the center frequency of 5 MHz. The slice thickness of the neuro probe at the elevation focal depth of 41.1 mm is 1.5 mm.
4) *Tracking System*: We used an active POLARIS optical tracking system (Northern Digital Inc., Waterloo ON, Canada) in the phantom study to provide the pose information of the US probe.
5) *Workstation*: A visualization workstation based on the Atamai Viewer[1] with a Matrox video frame grabber card (Matrox Electronic Systems Ltd., Dorval QC, Canada) was employed to acquire real-time information (2D US images, spatial tracking information and ECG signals), register intra-operative images with preoperative dynamic images, and fuse and display the registered images.

C. Image Acquisition

1) Preoperative Image Acquisition: Ten 3D CT images of the beating heart over the cardiac cycle with retrospective ECG gating were acquired using a GE Lightspeed VCT with imaging parameters: slice thickness $= 0.625$ mm, pitch $= 0.0$, table translation $= 3.75$ mm/rotation, field of view $= 16.2$ cm, kVp $= 120$, mA $= 300$, imaging time $= 1.5$ s, and image resolution $= 512 \times 512$. The reconstructed voxel size was $0.488 \times 0.488 \times 0.625$ mm^3.

2) Peri-Operative Image Acquisition and Pre-Processing: Eighteen tracked 2D US images were acquired with ECG-gating. These images were first processed by a median filter to reduce speckle noise and then reconstructed into 3D US images based on tracking information.

For 3D image reconstruction, we need to map the 2D US images into tracking system (TS) space by transformation $T_{\mathrm{TS}\leftarrow 2\mathrm{DUS}} = T_{\mathrm{TS}\leftarrow S} * T_{S\leftarrow 2\mathrm{DUS}}$, where

- $T_{S\leftarrow 2\mathrm{DUS}}$, which transforms the 2D US pixel coordinates into tracking tool space defined by the sensor attached to the US probe.

[1]http://www.atamai.com

Authorized licensed use limited to: Florida Institute of Technology. Downloaded on May 12,2025 at 00:40:28 UTC from IEEE Xplore. Restrictions apply.

- $T_{\mathrm{TS}\leftarrow S}$, which transforms the coordinates from the tracking tool space into TS space.

The second matrix, $T_{\mathrm{TS}\leftarrow S}$, was determined automatically by the tracking system. To find the transformation $T_{S\leftarrow 2\mathrm{DUS}}$ a Z-string US calibration procedure [34] was used. The calibration was performed on a Z-string phantom with four Z-strings, consisting of strings supported by a lucite frame. The cross section through each Z-string is visible as three bright spots in the 2D US image. The position of the central point of each point triplet in frame space is calculated and then converted to coordinates in tracking tool space (i.e., tracking sensors attached to the 2D US probe). For each point in tracking tool space, there is a homologous point in US image space. Least-squares minimization was used to calculate the transform $T_{S\leftarrow 2\mathrm{DUS}}$. Over twenty US images were used in computing the calibration transform.

3) Intra-Operative Image Acquisition and Preprocessing: During the "procedure," intra-operative real-time 2D US images augmented with tracking information and ECG signals were acquired. A median filter was applied as before, and the field-of-view (FOV) in each US image restricted to depict only the relevant cardiac structures and to remove the background in each image [35].

D. Image Registration

Dynamic registration of the 2D US and CT images of the beating heart must not only spatially align two images but also synchronize them to the same cardiac phase. We first use ECG signals to perform temporal synchronization, then we align US and CT images using mutual information. Spatial registration and temporal synchronization are separately elaborated in the following sections.

1) Temporal Synchronization: Due to different sampling latencies in the US images, ECG signal, and tracking information, the readings for different modalities, even acquired at the same time point, may not correspond to the same cardiac phase. In this section, we propose a method to calibrate and compensate the temporal latencies between US video frames, ECG signals, and tracking information. Time stamping is used to align multiple modalities in time and to synchronize US images, ECG signals, and pose of tracked US probe to achieve an accurate US-CT registration. The details of this approach are described below.

Temporal synchronization between CT and US was achieved by using ECG signals. In the beating heart phantom, the controller outputs two pulse signals as an "ECG" trigger, which control the inflation and deflation of the heart to create periodic heartbeats. We used one of these signals as a simulated R-wave trigger pulse to synchronize US images with preoperative dynamic 3D CT images of the phantom. The sampling precision was approximately 33 ms.

For each US image, we calculated the timestamp t_{ECG} of the corresponding ECG signal at the same cardiac phase, $t_{\mathrm{ECG}} = t_{\mathrm{US}} - T_{d\mathrm{ECG_US}}$, where t_{US} was the timestamp of the US image and $T_{d\mathrm{ECG_US}}$ was the time delay between the US image and the ECG signal. Next, we computed the corresponding cardiac phase $0 \leq t_p < 1$ as follows:

$$t_p = \frac{t_{\mathrm{ECG}} - t_{\mathrm{ECG}p}}{T_{\mathrm{ECG}}} \tag{1}$$

where T_{ECG} was the cardiac cycle period and $t_{\mathrm{ECG}p}$ was the time point at the starting phase of the ECG signals (corresponding to the R-wave peak) before t_{ECG}.

Based on the calculated cardiac phase t_p, we were able to obtain a corresponding preoperative image CT_{tp} at the same cardiac phase using nearest-neighborhood or linear interpolation. The US and interpolated CT images were then registered spatially as described in Section II-D2.

To obtain the initial transformation as described in Section II-D2b, we required temporal synchronization of each 2D US image and the associated tracking information. For each US image, we calculated the timestamp t_{TS} of the corresponding tracking information at the same cardiac phase, $t_{\mathrm{TS}} = t_{\mathrm{US}} - T_{d\mathrm{TS_US}}$, where t_{US} was the timestamp of the US image and $T_{d\mathrm{TS_US}}$ was the time delay between the US image and the tracking information. Based on the synchronized timestamp t_{TS}, we determined the correct tracking transformation matrix associated with the 2D US image.

To achieve temporal registration, two time delay parameters $T_{d\mathrm{ECG_US}}$ and $T_{d\mathrm{TS_US}}$ must be determined as discussed in detail in Section II-D3.

2) Spatial Registration: For spatial alignment, a rigid transformation is used to register all synchronized pairs of US and CT images [30]. In this study, we employ the MI method for 2D US to 3D CT image registration. MI is arguably the best method for multimodality image registration; however, this method, in common with many others, is difficult to use in real-time applications due to local minima and slow convergence. The poor quality of the US images further complicates and prolongs the registration process. Since registration is often formulated as an iterative nonlinear optimization problem, the speed of convergence depends strongly on the selection of an appropriate starting point. If we start the registration procedure with the source image in the neighborhood of the optimal solution (correct registration), the registration method converges more rapidly. Our rapid two-step registration procedure is described as follows.

a) Peri-Operative Image Registration: For this step, a single ECG-gated reconstructed 3D US image was mapped to the pre-operative 3D CT image at the same cardiac phase. After reconstruction, the 3D US and synchronized CT images were viewed using custom software (OCCIViewer[1]) and the two image sets were manually translated and rotated until the volumes were approximately aligned to obtain an initial transformation. Next, we maximized the MI metric of the 3D US and CT images by a gradient ascent method to obtain an optimal peri-operative registration transformation ($T_{\mathrm{CT}\leftarrow 3\mathrm{DUS}}$). The final peri-operative transformation responsible for mapping the preoperative dynamic CT images to the patient (i.e., TS space) is $T_{\mathrm{TS}\leftarrow\mathrm{CT}} = T_{\mathrm{TS}\leftarrow 3\mathrm{DUS}} T^{-1}_{\mathrm{CT}\leftarrow 3\mathrm{DUS}}$, where $T_{\mathrm{TS}\leftarrow 3\mathrm{DUS}}$ is the transformation from 3D US image space to TS space and determined during 3D US reconstruction.

b) Intra-Operative Image Registration: The objective of intra-operative registration is to rapidly register the preoperative dynamic 3D images to the 2D US images. During the procedure, each real-time 2D US image was acquired along with the spatial tracking information and ECG signals. ECG signals were employed to synchronize US images to the pre-operative dynamic

Authorized licensed use limited to: Florida Institute of Technology. Downloaded on May 12,2025 at 00:40:28 UTC from IEEE Xplore. Restrictions apply.

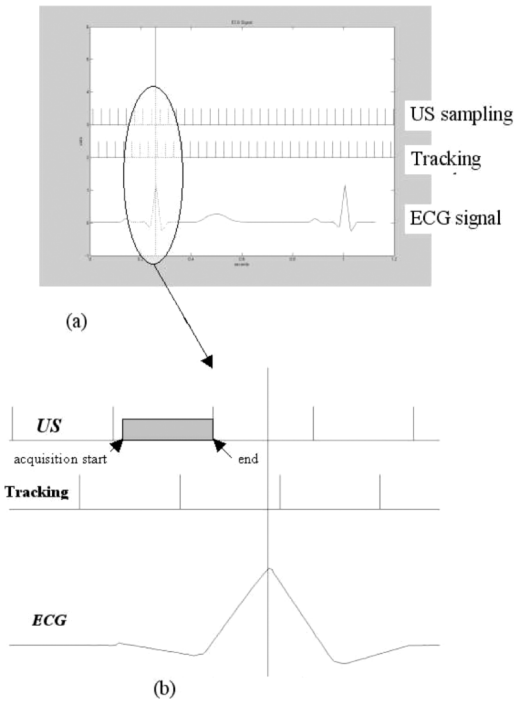

Fig. 3. Schematic diagram of information acquisition latency. Besides ECG signals, this figure illustrates the sampling instants of 2D US images and tracking information which is acquired as a 4×4 transformation matrix. (a) Asynchronous informatio acquisitions. (b) A Close-up of (a).

3D CT images, and spatial tracking information ($T_{\mathrm{TS}\leftarrow\mathrm{2DUS}}$ from 2D US image space to TS space) was combined with the peri-operative transformation ($T_{\mathrm{TS}\leftarrow\mathrm{CT}}$) to produce a near-optimal starting point $T_{\mathrm{CT}\leftarrow\mathrm{2DUS}} = T^{-1}_{\mathrm{TS}\leftarrow\mathrm{CT}} T_{\mathrm{TS}\leftarrow\mathrm{2DUS}}$ for the intra-operative registration. The real-time 2D US and synchronized 3D CT images were then registered by maximizing the MI metric.

3) Calibration of Time Delay Parameters in Temporal Synchronization: As indicated by Fig. 3, there are two areas involved in asynchronous information acquisition. The first is the asynchronous acquisitions of 2D US images, ECG signals, and spatial tracking information, i.e., the sampling rates for these acquisition systems may be different. The second area is the varied latency within the different data acquisition systems. The latency is the period between the commencement of data collection and when the data are reported to the processing system. Unless system latencies are properly accounted for, robust synchronization of the dynamic model to the US cannot be achieved.

Accurate synchronization of the ECG and tracking measurements with the US video frames requires not only that accurate timestamps be attached to each video frame, ECG measurement, and tracking measurement, but that this information then be used to align the three data streams. $T_{d\mathrm{TS_US}}$ was measured experimentally, and the time delay $T_{d\mathrm{ECG_US}}$ between the ECG and the US image was calculated from $T_{d\mathrm{ECG_US}} = T_{d\mathrm{ECG_TS}} - T_{d\mathrm{TS_US}}$, where $T_{d\mathrm{ECG_TS}}$ was the time delay between the ECG measurement and the tracking measurement. In general $T_{d\mathrm{ECG_TS}}$ can be more accurately determined than $T_{d\mathrm{ECG_US}}$ in the experiment due to the smaller localization error of the reference marker employed for calibration in TS space than in US image space.

Temporal calibration was performed by treating the beating heart phantom as a known motion source. We first attached a reference marker to the heart surface, and then acquired dynamic 3D CT images over the cardiac cycle with ECG gating. Next, an active tracking pointer was attached to the reference marker, and we simultaneously acquired real-time 2D US images, tracking information (position) of the reference marker and ECG signals with timestamps over multiple cardiac cycles. Finally, the position of the reference marker was localized in all dynamic 2D US images and dynamic 3D CT images, i.e., the motion of the reference marker was extracted in both dynamic 2D US image space and 3D CT image space for all the cardiac phases.

After the locations of the reference marker were identified in US image space, tracking system space and CT image space, we obtained three motion trajectories of the reference marker over time in three different spaces. After these trajectories were mapped into the same coordinate system, the discrepancy between them was interpreted as the time delay in asynchronous information acquisition.

Because of the one-to-one correspondence between ECG signals and dynamic CT images over the cardiac cycle due to the ECG-gated CT image acquisition, temporal synchronization of ECG signals and US (or tracking) was achieved by synchronizing CT and US (or tracking). Hence, the time delay parameter $T_{d\mathrm{ECG_TS}}$ between ECG and tracking information was obtained by minimizing the discrepancy between the motion trajectory of the reference marker in CT space and one that was rigidly transformed from tracking system space to CT space. The optimization problem was formulated as follows:

$$\min_{T_{d\mathrm{ECG_TS}}, T_{\mathrm{CT}\leftarrow\mathrm{TS}}} J = \sum_{k=1}^{N_{CT}} \|P_{\mathrm{CT}k}(T_{d\mathrm{ECG_TS}}) - T_{\mathrm{CT}\leftarrow\mathrm{TS}} P_{\mathrm{TSk}}\|^2 \quad (2)$$

where

- $T_{d\mathrm{ECG_TS}}$ is the time delay/latency between the ECG signal and tracking information;
- $T_{\mathrm{CT}\leftarrow\mathrm{TS}}$ is the transformation matrix from tracking system space to CT image space;
- $P_{\mathrm{CT}k}(T_{d\mathrm{ECG_TS}}) = f_{\mathrm{CT}}(P_{\mathrm{CT}t}, t_k + T_{d\mathrm{ECG_TS}})$ is the marker position at the cardiac phase k_d (i.e., cardiac phase k delayed by $T_{d\mathrm{ECG_TS}}$) by interpolating $P_{\mathrm{CT}t} = \{P_{\mathrm{CT}k}, k = 1, 2, \ldots, N_{\mathrm{CT}}\}$, which denotes the motion trajectory of the reference marker over the cardiac cycle in CT image space, N_{CT} is the number of dynamic 3D CT images over the cardiac cycle, and t_k is the time instant at the cardiac phase k;
- $P_{\mathrm{TS}k} = (1)/(N_c)\sum_{j=1}^{N_c} P_{TSkj}$ is the mean position of the reference marker at the k-th cardiac phase over N_c cardiac cycles, where P_{TSkj} is the marker position at the kth cardiac phase in the jth cardiac cycle and obtained by interpolating $P_{\mathrm{TS}t} = \{P_{\mathrm{TSraw}k}, k = 1, 2, \ldots, N_{\mathrm{TS}}\}$, which denotes the trajectory of the reference marker moving over multiple cardiac cycles in tracking system space, where N_{TS} is the number of samples of the tracking information.

Authorized licensed use limited to: Florida Institute of Technology. Downloaded on May 12,2025 at 00:40:28 UTC from IEEE Xplore. Restrictions apply.

From the raw ECG signal data, all the cardiac phases of the dynamic CT images and their corresponding timestamps were extracted via interpolation (N_c cardiac cycles) and $P_{\mathrm{TS}kj}$ was derived from the raw tracking information $P_{\mathrm{TS}t}$ via interpolation (N_c cardiac cycles) based on ECG (cardiac phase) timestamps.

The time delay parameter $T_{d\mathrm{TS_US}}$ between 2D US images and tracking information was obtained by minimizing the discrepancy between the motion trajectory of the reference marker in US space and one that was rigidly transformed from tracking system space to US space. The optimization problem was formulated as follows:

$$\min_{T_{d\mathrm{US_TS}}, T_{\mathrm{US}\leftarrow\mathrm{TS}}} J_2 = \sum_{k=1}^{N_{\mathrm{TS}}} \|P_{\mathrm{US}k}(T_{d\mathrm{US_TS}}) - T_{\mathrm{US}\leftarrow\mathrm{TS}} P_{\mathrm{TS}k}\|^2 \quad (3)$$

where

- $T_{\mathrm{US}\leftarrow\mathrm{TS}}$ is the transformation matrix from tracking system space to US image space;
- $P_{\mathrm{TS}k}(k = 1, 2, \ldots, N_{\mathrm{TS}})$ denotes the trajectory of the reference marker moving over multiple cardiac cycles in tracking system space, N_{TS} is the number of samples of the tracking information;
- $P_{\mathrm{US}k}(T_{d\mathrm{US_TS}}) = f_{\mathrm{US}}(P_{\mathrm{US}t}, t_k + T_{d\mathrm{US_TS}})$ denotes the motion trajectory of the reference marker over the cardiac cycles in US image space, which is obtained by linear interpolation from $P_{\mathrm{US}t} = \{P_{\mathrm{US}j}, j = 1, 2, \ldots, N_{\mathrm{US}}\}$, N_{US} is the number of 2D US images over the same multiple cardiac cycles as the tracking information, and t_k is the time timestamp associated with the kth sample $P_{\mathrm{TS}k}$.

Compared with the previous methods based on principal component analysis [2], one advantage of our temporal calibration method is that the motion curve of the reference marker need not be a sine wave, but in the case of cardiac motion, can be an arbitrary periodic curve. We obtained the time delay parameters: $T_{d\mathrm{US_TS}} = -36$ ms, $T_{d\mathrm{ECG_TS}} = 157$ ms, $T_{d\mathrm{ECG_US}} = T_{d\mathrm{ECG_TS}} - T_{d\mathrm{US_TS}} = 193$ ms.

E. Implementation Framework of the Surgical Navigation System

Our surgical navigation system is integrated into the AtamaiViewer software platform, whose role in surgical guidance has previously been described by Linte *et al.* [32].

To take advantage of different open-source packages and provide a unified platform for surgical guidance, we have adopted the Insight Toolkit (ITK) for image registration, the Visualization Toolkit (VTK)/AtamaiViewer for image visualization and custom VTK classes for information acquisition, including acquisition of real-time 2D US, spatial tracking information and ECG signals. All the components are integrated using multithreading techniques to simultaneously handle asynchronous tasks such as US image acquisition, image registration, and visualization of registered images.

Within this navigation system, five threads run simultaneously on a multi-CPU workstation in parallel. Each thread is a running task within this application program.

- The main thread is employed to display the overlay of the registered real-time 2D US and preoperative dynamic 3D CT images. This thread acquires the latest transformation from the registration thread and applies it to the current real-time 2D US frame. The transformed US images are overlaid with the corresponding preoperative 3D CT images.
- The registration thread is responsible for rapid alignment of pre-operative dynamic 3D CT images with intra-operative 2D US images. It first uses ECG signals to synchronize the real-time 2D US frame with the preoperative dynamic 3D CT images, and then spatially aligns the paired 2D US and 3D CT images. Once the 2D $-$3 D registration is completed, the resulting transformation is sent to the visualization thread.
- The US acquisition thread acquires real-time 2D US video frames, which are stored in a circular buffer after attaching a timestamp to indicate the video frame's sampling time.
- The tracking acquisition thread acquires spatial tracking information through a serial port, to which a tracking device is interfaced, and converts the tracking information into a 4×4 matrix containing the position and orientation information of the US transducer, and places the matrix in a circular buffer with a timestamp.
- The ECG acquisition thread is used to acquire real-time ECG triggers from the beating heart, after which they are also stored in a circular buffer with a timestamp.

F. Validation

1) Static Heart Phantom: Precise assessment of dynamic 2D US—3D CT registration accuracy on a dynamic phantom is not trivial, mainly due to the difficulty of capturing a sufficient number of fiducial markers in a single 2D US image slice. To establish a baseline against which to compare the errors measured under dynamic conditions, we determined the intrinsic accuracy of the registration between US images and preoperative 3D CT images in the static case. A complete and thorough assessment on a static heart was readily performed by calculating the target registration error (TRE) of the fiducial markers attached to the surface of the beating heart phantom. The locations of the fiducial markers were measured by an active pointer associated with the spatial tracking system.

The TRE was calculated as the root mean square (rms) of the displacements between the positions of the reference fiducial points in CT image space and the corresponding fiducial markers in US image space after registration. In this study, the centers of mass (COM) of the fiducial markers were identified in both 3D CT and 3D US image spaces.

To overcome the difficulty of assessing 2D–3D registration, we first employed the tracking information associated with the 2D US image to transform all the fiducial marker positions in 3D US image space into 2D US image space (still in the 3D coordinate system) by using the transformation matrix $T_{\mathrm{2DUS}\leftarrow\mathrm{3DUS}} = (T_{\mathrm{TS}\leftarrow S} T_{S\leftarrow\mathrm{2DUS}})^{-1} T_{\mathrm{TS}\leftarrow\mathrm{3DUS}}$. We then computed the TRE based on the positions of the paired fiducial markers after registration. One assumption of this approach is that the tracking information is accurate and any error in

Authorized licensed use limited to: Florida Institute of Technology. Downloaded on May 12,2025 at 00:40:28 UTC from IEEE Xplore. Restrictions apply.

tracking can be ignored. In our case, the Polaris OTS had an accuracy of ~ 0.3 mm. The TRE was calculated by

$$\mathrm{TRE} = \sqrt{\frac{1}{N}\sum_{k=1}^{N} \|P_{\mathrm{CT}k} - T_{\mathrm{CT}\leftarrow\mathrm{2DUS}} T_{\mathrm{2DUS}\leftarrow\mathrm{3DUS}} P_{\mathrm{3DUS}k}\|^2} \tag{4}$$

where the transformation $T_{\mathrm{CT}\leftarrow\mathrm{2DUS}}$ was obtained from 2D US—3D CT registration, the transformation $T_{\mathrm{TS}\leftarrow S}$ was the tracking information directly measured by the tracking system, $T_{S\leftarrow\mathrm{2DUS}}$ is the calibration transformation matrix, and $T_{\mathrm{TS}\leftarrow\mathrm{3DUS}}$ is the transformation from 3D US image space to TS space obtained during 3D US image reconstruction.

2) Beating Heart Phantom: In the dynamic heart case, "ECG" trigger signals generated by the beating heart phantom were acquired along with US image acquisition, and were used to reconstruct the peri-operative 3D US image with ECG-gating and to synchronize the real-time 2D US images and pre-operative dynamic 3D CT images. We adopted a different method to assess the registration accuracy, since we were not able to measure multiple fiducial markers simultaneously by an active pointer associated with the spatial tracking system as in the static case. The registration accuracy was quantitatively assessed by measuring the rms distance between two sets of homologous points measured over all phases of the cardiac cycle.

3) Animal Study: One major difference between the two experimental environments was that in the animal study, a trans-esophageal echocardiography unit (Philips SONOS 7500) was used to acquire the real-time 2D US images of the pig's beating heart with an Agilent T6210 Omniplane II TEE transducer with the diameter of 10.5 mm at the center frequency of 7 MHz, which has the slice thickness of 2.0 mm at the elevation focal depth of 50.9 mm. The major advantage of the TEE probe is that it was small enough to be inserted into the esophagus directly beneath the heart to acquire high quality cardiac US images without interference from the subject's lungs and ribs. An Aurora magnetic sensor (Northern Digital Inc., Waterloo, ON, Canada) was attached to the TEE probe to track its pose in real time.

The animal was treated in accordance with the policy of the University of Western Ontario Animal Use Protocol. Actual ECG signals of the pig (Fig. 4) were acquired using a standard three lead configuration together with an ECG Cardiac Trigger Monitor (Model 3150, Ivy Biomedical Systems, Inc., Branford, CT). The monitor detected the peak of R-wave in the ECG signals and produced a 100-ms trigger pulse, which began at the peak of each R-wave. This signal was subsequently conditioned to ensure compatibility with the parallel port of the computer.

The pig was anesthetized and ventilated during the entire procedure. After placing the pig in the CT gantry, contrast agent was injected, followed 12 s later by a dynamic 3D CT scan. The ventilator was paused at the end-expiration point in the respiratory cycle (i.e., equivalent to a breath-hold in humans). Ten dynamic 3D CT images over the cardiac cycle were reconstructed using retrospective ECG-gating. The CT imaging parameters were slice thickness $= 0.625$ mm, pitch $= 0.0$, table translation $= 3.75$ mm/rotation, field of view (FOV) $= 16.2$ cm, kVp $= 120$, mA $= 400$, imaging time $= 11$ seconds, and image matrix size $= 512 \times 512$. All the 2D TEE images were acquired with ECG gating and breath-holding at end-expiration. For "peri-operative" US image acquisition, 2D US images, consisting of 18 slices at equi-angular increments about the normal TEE probe axis with ECG gating at the mid-diastole cardiac phase, were acquired. For "intra-operative" 2D TEE image acquisition, 2D US images were acquired at each of 20 cardiac phases for a fixed rotation angle of the TEE probe. The FOV depth for the TEE images was 10 cm, viewangle 90°, frequency 7 MHz, and pixel size 0.3 mm $\times$ 0.3 mm.

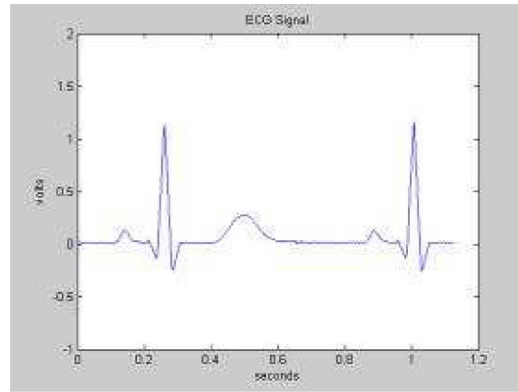

Fig. 4. ECG signals from the subject.

A median filter was employed to reduce the noise in the dynamic 3D CT images of the heart and a region-of-interest (ROI) was determined by manually segmenting the heart from the surrounding tissues. Registration of dynamic 2D US and 3D CT images within the ROI was performed in the same manner as described for the phantom study.

III. Results

This section includes validation results of intra-operative 2D US and pre-operative 3D CT image registration under static and dynamic conditions on both the beating heart phantom and the animal study.

A. Laboratory Validation

1) Static Heart Phantom: MI was employed to register reconstructed 3D US and 3D CT images of the heart phantom, yielding a registration result with a 3D TRE of 1.37 ± 0.34 mm (Fig. 5). Fig. 6 shows the registration result of intra-operative 2D US and pre-operative 3D CT images with a 3D TRE of 2.52 ± 0.27 mm.

2) Beating Heart Phantom: In this section, we evaluated the performance of the dynamic registration by computing the registration error on the beating heart surface. Fig. 7 shows selected images of the overlay of registered 2D US and preoperative dynamic 3D CT images of the beating heart phantom over the cardiac cycle, where the 2D US images match well with the corresponding 3D CT images.

Based on the surface alignment in the overlay of dynamically registered real-time 2D US and preoperative 3D CT images, we calculated the registration accuracy for all the cardiac phases over the cardiac cycle. For each cardiac phase, five homologous

Authorized licensed use limited to: Florida Institute of Technology. Downloaded on May 12,2025 at 00:40:28 UTC from IEEE Xplore. Restrictions apply.

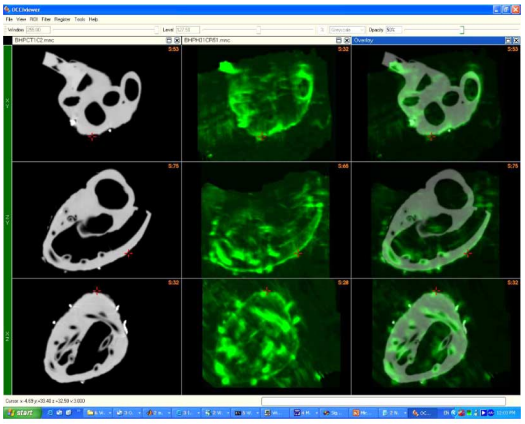

(a) (b) (c)

Fig. 5. Peri-operative 3D US—3D CT static heart phantom registration (a) three orthogonal slices of the 3D CT image, (b) three orthogonal slices of the reconstructed 3D US image after registration, (c) overlay of registered images.



(a) (b) (c)

Fig. 6. Intra-operative 2D US—3D CT static heart phantom registration (a) 2D US image (b) CT image after registration (c) overlay of two registered images. Note that the "vessels" on the surface of the heart phantom are aluminum wires and show clearly in both US (indicated by arrows) and CT (indicated by bright dots) images, but because of the nature of the MI registration algorithm, this is not expected to influence the registration appreciably.

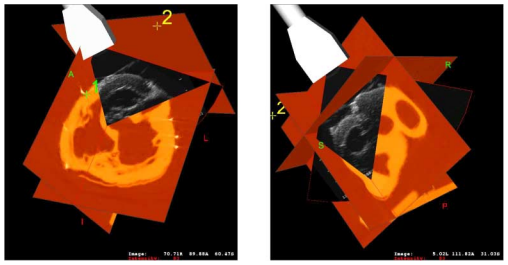

Fig. 7. Registered real-time 2D US—dynamic 3D CT images.

TABLE I
ACCURACY OF DYNAMIC REGISTRATION OF 2D US—3D CT IMAGES. THE ENTIRE CARDIAC CYCLE IS DIVIDED INTO 10 PHASES OF EQUAL TIME DURATION (100 MS). PHASE 1 CORRESPONDS TO THE RISING EDGE OF TRIGGER SIGNALS SQUARE WAVE PULSES

Phase	TRE (mm)	Phase	TRE (mm)
1	2.46±1.12	6	1.58±0.61
2	1.54±0.50	7	1.57±0.99
3	1.44±0.64	8	2.08±0.38
4	1.31±0.45	9	1.53±0.89
5	1.41±0.55	10	1.96±0.35
		mean±SD	1.69±0.36

points were identified in both the CT and US images after registration, the 2D TRE was then calculated as the rms of the displacements between the positions of the homologous points in CT and US spaces, shown in Table I.

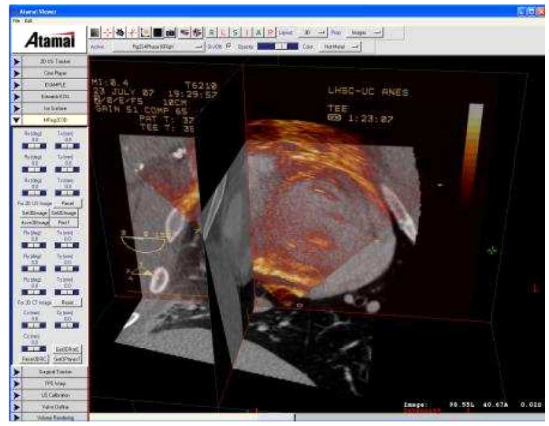

(a)

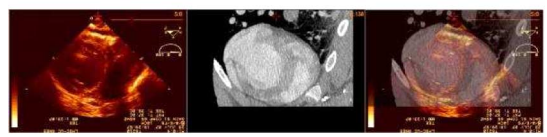

(b)

Fig. 8. Registration of 2D US (hot metal color) and 3D CT (grayscale) images of the *in vivo* beating porcine heart. (a) 3D view of registered 2D US and 3D CT images. (b) 2D view of the overlay (right) of registered US (left) and resampled CT (middle) images.

B. Animal Study: In Vivo Validation

Here we present the TEE 2D US to 3D CT registration results with the *in vivo* porcine model. This registration was performed offline after all data acquisition. The typical intra-operative registration time was approximately 122 s. ECG signals were employed for temporal synchronization, then the synchronized US and CT images were registered spatially by maximizing the MI metric. The selected overlay of the registered 2D US and 3D CT images is shown in Fig. 8, demonstrating satisfactory registration results.

It is very challenging to quantitatively evaluate registration accuracy for animal studies, because there are few identifiable landmarks in the heart. Furthermore, it is difficult to select sufficient landmarks in a single 2D US image for registration accuracy assessment, due to the limited field of view and low quality of the 2D US image. In this study, we carefully examined the US images at all ten phases over the cardiac cycle, and chose ten landmarks that were able to be reliably identified in all the 2D US images at ten phases and were distributed as evenly as possible in the heart. At each cardiac phase, these ten landmarks such as papillary muscles were first identified in the 2D US image as illustrated in Fig. 9, then the closest homologous points were identified in the corresponding resampled 2D CT slice after registration. The landmark (or target) localization error (TLE) is defined as the distance of the localized landmark from the "forever unknown" actual landmark location. The target localization error of 0.40 ± 0.20 mm (rms $= 0.44$ mm) was determined by having a single observer localize the ten markers for a single phase image 10 times over a period of 50 days. This TLE forms a component of the TRE as reported in Table II. To calculate the TRE, we employed MI to register the synchronized 2D US and 3D CT images at the mid-diastole cardiac phase in 3D

Authorized licensed use limited to: Florida Institute of Technology. Downloaded on May 12,2025 at 00:40:28 UTC from IEEE Xplore. Restrictions apply.

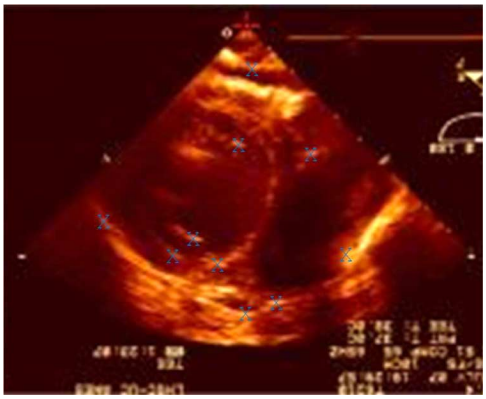

Fig. 9. Landmarks are indicated by blue symbols "X" in the 2D US image of the *in vivo* beating porcine heart.

TABLE II
ACCURACY OF DYNAMIC REGISTRATION OF 2D US—3D CT IMAGES OF THE *IN VIVO* ANIMAL HEART, USING TRANSFORMATION OBTAINED BY REGISTRATION AT MID-DIASTOLE PHASE. THE ENTIRE CARDIAC CYCLE IS DIVIDED INTO 10 PHASES OF EQUAL TIME DURATION (67 MS) AND PHASE 1 CORRESPONDS TO THE R-WAVE PEAK OF ECG SIGNALS. THE RESULTS (TRE) REPORTED HERE ARE 2D DISTANCES BETWEEN 3D LINES AND SURFACES IN THE TRANSECTED US PLANE AND EQUIVALENT RESAMPLED CT PLANE

Phase	TRE (mm)	Phase	TRE (mm)
1	2.17±1.04	6	1.69±0.93
2	2.41±1.51	7	1.44±0.65
3	1.53±0.60	8	1.87±0.70
4	2.39±1.35	9	2.27±1.37
5	1.53±0.80	10	2.39±1.17
		mean±SD	1.97±0.40

TABLE III
ACCURACY OF DYNAMIC REGISTRATION OF 2D US—3D CT IMAGES OF THE *IN VIVO* ANIMAL HEART, RE-REGISTRATION AT EACH CARDIAC PHASE STARTING FROM THE REGISTRATION RESULT OBTAINED AT THE MID-DIASTOLE PHASE. THE ENTIRE CARDIAC CYCLE IS DIVIDED INTO 10 PHASES OF EQUAL TIME DURATION (67 MS) AND PHASE 1 CORRESPONDS TO THE R-WAVE PEAK OF ECG SIGNALS. THE RESULTS (TRE) REPORTED HERE ARE 2D DISTANCES BETWEEN 3D LINES AND SURFACES IN THE TRANSECTED US PLANE AND EQUIVALENT RESAMPLED CT PLANE

Phase	TRE (mm)	Phase	TRE (mm)
1	3.45±1.23	6	2.61±1.49
2	2.51±1.51	7	1.97±1.00
3	4.68±2.59	8	1.72±1.04
4	4.53±2.67	9	4.34±2.53
5	6.56±3.19	10	3.09±2.07
		mean±SD	3.55±1.49

space, then applied the resultant registration transformation to all similar image sets at the ten phases of the cardiac cycle. The resulting TRE measurements (1.97 ± 0.40 mm in Table II) are the 2D rms distances between landmarks seen in the 2D US images (lines, surfaces), and the similar features seen in the 3D CT images re-sampled at the same plane as the 2D US image. While we acknowledge that this approach will underestimate components of the errors that are perpendicular to the US slice, we found this to be the only practical means of estimating the errors in the *in vivo* data. Starting from the above transformation, we then performed MI registration to align the US and CT images at each cardiac phase, and obtained a 2D TRE of 3.55 ± 1.49 mm in the transected 2D US plane over the cardiac cycle (Table III). This result is higher than that obtained using the registration transformation at mid-diastole phase with least motion in the cardiac cycle, which we attribute to the fact that there are more motion artifacts and blurring in US and CT images when the cardiac contraction is rapid. Motion artifacts/blurring in the CT images are mainly due to the low sampling rates i.e., 10 phases over the cardiac cycle since the CT image at each phase was reconstructed over 10% of the cardiac cycle period. Under these conditions the registration is expected to be less robust.

IV. DISCUSSION

Our navigation system provides a flexible platform for mapping intra-operative 2D US to pre-operative dynamic 3D CT images as a compensation for the lack of direct vision during minimally-invasive off-pump interventional procedures performed inside the beating heart. Within the high-quality dynamic 3D anatomical context provided by CT images, interpretability of intra-operative 2D US images is significantly improved. With more rapid and accurate interpretation of cardiac structures in the surgical site, procedure time can be reduced. However, several aspects of this navigation procedure still need to be refined. First, to assess registration accuracy, fiducial markers were attached to the phantom heart prior to CT and US scanning. Since it was difficult to place fiducial markers on the inner wall of the heart phantom, we instead attached them on the outside wall, and acquired the images from the exterior of the phantom. In the future, we will modify the heart phantom to incorporate interior fiducial markers to more closely replicate the situation in intra-cardiac surgery.

This study represents the preliminary stage of a project that aims to provide real-time, high quality image guidance for minimally invasive intra-cardiac surgery of the beating heart. The next phase will refine and extend our results to guide intra-cardiac beating heart surgery for an animal model in the operating room, and incorporate the proposed technique in human clinical trials. One procedure for which this technique can be initially applied will be the implantation of mitral valves inside the beating heart [36]. Further technical issues requiring attention involve improving magnetic tracking accuracy, and optimizing the entire procedure to shorten the image processing time in the preoperative, peri-operative, and intra-operative phases.

It has been widely accepted that virtual reality models, when appropriately constructed and registered to the intra-operative images, can significantly facilitate surgical navigation. The efficacy of using virtual models such as the virtual representation of surgical tools has been exhibited in the mitral valve replacement procedure in a porcine model *in vivo* by our colleagues [37].

Temporal synchronization of the US and CT images was achieved using linear interpolation with the aid of the ECG signal, since there was no significant variation of the heart shape and heart motion between the imaging sessions in our experiments. In the heart phantom study, the heart rate did not change. In the animal study, the heart rate of the pig was constant during the US and CT imaging sessions. If the heart rate changes significantly for some cardiac procedures, a nonlinear temporal scaling of ECG signals (different scalings during systole and diastole) will be required.

Results in Tables II and III show that it is more robust to register US and CT images at diastole phases due to fewer motion artifacts, and registration transformation at mid-diastole can provide a good match for all the cardiac phases. We observe that

Authorized licensed use limited to: Florida Institute of Technology. Downloaded on May 12,2025 at 00:40:28 UTC from IEEE Xplore. Restrictions apply.

surgical instruments are often moved slowly for many cardiac procedures, so it is feasible to register US and CT images at the diastolic phase and apply the resultant transformation to all the other cardiac phases over the cardiac cycle.

In this study, we validated the feasibility of this real-time surgical navigation system in the phantom study using a Polaris optical tracking system, and in an animal study using an Aurora magnetic tracking system. Although the magnetic tracking is more convenient for cardiac procedures inside the chambers of the beating heart, the accuracy of the magnetic tracking system is somewhat inferior to the optical tracking system and thus has some impact on the registration. Nevertheless errors in tracking can be minimized by ensuring that the tracking environment is free of ferrous material.

V. Conclusion

In this paper, we have demonstrated the technical feasibility of dynamic registration of intra-operative 2D US to preoperative 3D CT on a beating heart phantom and an animal study, and laid the groundwork for subsequent clinical experiments. To the best of our knowledge, this is the first discussion of a prototype of a beating heart surgical navigation system using fused real-time dynamic US and CT images. This proposed technique has the potential to substantially improve interactive image guidance for minimally invasive beating heart surgery, and through multi-modality dynamic US/CT image fusion, to offer improved diagnostic capabilities for cardiac diseases.

One future research direction will be to investigate the use of nonrigid registration techniques to match preoperative dynamic CT images with intra-operative 2D US images. Currently, we assume periodic heart motion and use a rigid-body transformation. Although this hypothesis is valid in some surgical scenarios, a general surgical cardiac procedure involves heart deformation caused by surgical instruments and respiration. In the future, we will employ the rigid-body registration as a basis and utilize nonrigid registration techniques to compensate for heart deformation.

Acknowledgment

The authors would like to thank Dr. M. Wierzbicki, Dr. D. Gobbi, and Dr. M. Wachowiak for valuable insight and discussions, C. Wedlake, N. Hill, and Dr. U Aladl for technical support and assistance, and J. Williams for editorial assistance.

References

[1] E. Buffolo and L. Gerola, *Minimally Invasive Cardiac Surgery*, 2nd ed. Totowa, NJ: Humana, 2004, ch. Minimally invasive bypass grafting: A historical perspective, pp. 45–51.

[2] S. Szpala, M. Wierzbicki, G. Guiraudon, and T. M. Peters, "Real-time fusion of endoscopic views with dynamic 3-D cardiac images: A phantom study," *IEEE Trans. Med. Imag.*, vol. 24, no. 9, pp. 1207–1215, Sep. 2005.

[3] E. R. McVeigh, M. A. Guttman, P. Kellman, A. N. Raval, and R. J. Lederman, "Real-time, interactive MRI for cardiovascular interventions," *Acad. Radiol.*, vol. 12, no. 9, pp. 1121–1127, Sep. 2005.

[4] E. McVeigh, M. Guttman, R. Lederman, M. Li, O. Kocaturk, T. Hunt, S. Kozlov, and K. Horvath, "Real-time interactive MRI-guided cardiac surgery: Aortic valve replacement using a direct apical approach," *Magn. Reson. Med.*, vol. 56, no. 5, pp. 958–964, 2006.

[5] G. Lauritsch, J. Boese, L. Wigström, H. Kemeth, and R. Fahrig, "Towards cardiac C-arm computed tomography," *IEEE Trans. Med. Imag.*, vol. 25, no. 7, pp. 922–934, Jul. 2006.

[6] J. T. Cusma, M. R. Bell, M. A. Wondrow, J. P. Taubel, and D. R. Holmes, "Real-time measurement of radiation exposure to patients during diagnostic coronary angiography and percutaneous interventional procedures," *J. Am. Coll. Cardiol.*, vol. 33, no. 2, pp. 427–435, Feb. 1999.

[7] Y. Suematsu, G. R. Marx, J. A. Stoll, P. E. DuPont, R. O. Cleveland, R. D. Howe, J. K. Triedman, T. Mihaljevic, B. N. Mora, B. J. Savord, I. S. Salgo, and P. J. del Nido, "Three-dimensional echocardiography-guided beating-heart surgery without cardiopulmonary bypass: A feasibility study," *J. Thorac. Cardiovasc. Surg.*, vol. 128, no. 4, pp. 579–587, Oct. 2004.

[8] Y. Suematsu, J. F. Martinez, B. K. Wolf, G. R. Marx, J. A. Stoll, P. E. DuPont, R. D. Howe, J. K. Triedman, and P. J. del Nido, "Three-dimensional echo-guided beating heart surgery without cardiopulmonary bypass: Atrial septal defect closure in a swine model," *J. Thorac. Cardiovasc. Surg.*, vol. 130, no. 5, pp. 1348–1357, Nov. 2005.

[9] W. R. Crum, T. Hartkens, and D. L. G. Hill, "Non-rigid image registration: Theory and practice," *Br. J. Radiol.*, vol. 77, no. 2, pp. S140–S153, 2004, Spec.

[10] D. L. Hill, P. G. Batchelor, M. Holden, and D. J. Hawkes, "Medical image registration," *Phys. Med. Biol.*, vol. 46, no. 3, pp. R1–45, Mar. 2001.

[11] J. B. Maintz and M. A. Viergever, "A survey of medical image registration," *Med. Image Anal.*, vol. 2, no. 1, pp. 1–36, Mar. 1998.

[12] T. Makela, P. Clarysse, O. Sipil, N. Pauna, Q. C. Pham, T. Katila, and I. E. Magnin, "A review of cardiac image registration methods," *IEEE Trans. Med. Imag.*, vol. 21, no. 9, pp. 1011–1021, Sep. 2002.

[13] J. P. W. Pluim, J. B. A. Maintz, and M. A. Viergever, "Mutual-information-based registration of medical images: A survey," *IEEE Trans. Med. Imag.*, vol. 22, no. 8, pp. 986–1004, Aug. 2003.

[14] D. Gobbi, R. Comeau, and T. Peters, "Ultrasound/MRI overlay with image warping for neurosurgery," in *Med. Image Comp. Computer-Assited Intervention (MICCAI 2000) LNCS*, 2000, vol. 1935, pp. 106–114.

[15] J. Kaspersen, E. Sjlie, J. Wesche, J. Asland, J. Lundbom, A. Odegard, and F. Lindseth, "Three-dimensional ultrasound-based navigation combined with preoperative CT during abdominal interventions: A feasibility study," *Cardiovasc. Intervent. Radiol.*, vol. 26, pp. 347–356, 2003.

[16] D. C. Barratt, G. P. Penney, C. S. K. Chan, M. Slomczykowski, T. J. Carter, P. J. Edwards, and D. J. Hawkes, "Self-calibrating 3D-ultrasound-based bone registration for minimally invasive orthopedic surgery," *IEEE Trans. Med. Imag.*, vol. 25, no. 3, pp. 312–323, Mar. 2006.

[17] U. E. Aladl, G. A. Hurwitz, D. Dey, D. Levin, M. Drangova, and P. J. Slomka, "Automated image registration of gated cardiac single-photon emission computed tomography and magnetic resonance imaging," *J. Magn. Reson. Imag.*, vol. 19, no. 3, pp. 283–290, Mar. 2004.

[18] V. Grau, H. Becher, and J. A. Noble, "Registration of multiview real-time 3-D echocardiographic sequences," *IEEE Trans. Med. Imag.*, vol. 26, no. 9, pp. 1154–1165, Sep. 2007.

[19] A. Gueziec, P. Kazanzides, B. Williamson, and R. Taylor, "Anatomy-based registration of CT-scan and intraoperative X-ray images for guiding a surgical robot," *IEEE Trans. Med. Imag.*, vol. 17, no. 5, pp. 715–728, Oct. 1998.

[20] J. Hipwell, G. Penney, R. McLaughlin, K. Rhode, P. Summers, T. Cox, J. Byrne, J. Noble, and D. Hawkes, "Intensity-based 2-D—3-D registration of cerebral angiograms," *IEEE Trans. Med. Imag.*, vol. 22, no. 11, pp. 1417–1426, Nov. 2003.

[21] J. Weese, G. Penney, P. Desmedt, T. Buzug, D. Hill, and D. Hawkes, "Voxel-based 2-D/3-D registration of fluoroscopy images and CT scans for image-guided surgery," *IEEE Trans. Inf. Technol. Biomed.*, vol. 1, no. 4, pp. 284–293, Dec. 1997.

[22] G.-A. Turgeon, G. Lehmann, G. Guiraudon, M. Drangova, D. Holdsworth, and T. Peters, "2D-3D registration of coronary angiograms for cardiac procedure planning and guidance," *Med. Phys.*, vol. 32, no. 12, pp. 3737–3749, Dec. 2005.

[23] R. Micu, T. F. Jakobs, M. Urschler, and N. Navab, "A new registration/visualization paradigm for CT-fluoroscopy guided RF liver ablation," in *Med. Image Comput. Comput. Assist. Interv. Int. Conf. Med. Image Comput. Comput. Assist. Interv.*, 2006, vol. 9, no. 1, pp. 882–890.

[24] S. Xu, G. Fichtinger, R. H. Taylor, and K. Cleary, "3D motion tracking of pulmonary lesions using CT fluoroscopy images for robotically assisted lung biopsy," *Proc. SPIE*, vol. 5367, pp. 394–402, 2004.

[25] R. Smolkov-Wachowiak, M. P. Wachowiak, A. Fenster, and M. Drangova, "Registration of two-dimensional cardiac images to preprocedural three-dimensional images for interventional applications," *J. Magn. Reson. Imag.*, vol. 22, no. 2, pp. 219–228, Aug. 2005.

Authorized licensed use limited to: Florida Institute of Technology. Downloaded on May 12,2025 at 00:40:28 UTC from IEEE Xplore. Restrictions apply.

[26] G. Penney, J. Weese, J. Little, P. Desmedt, D. Hill, and D. Hawkes, "A comparison of similarity measures for use in 2-D-3-D medical image registration," *IEEE Trans. Med. Imag.*, vol. 17, no. 4, pp. 586–595, Aug. 1998.

[27] H. Zhong, T. Kanade, and D. Schwartzman, ""Virtual touch': An efficient registration method for catheter navigation in left atrium," in *Med. Image Comput. Comput. Assist. Interv. Int. Conf. Med. Image Comput. Comput. Assist. Interv.*, 2006, vol. 9, pp. 437–444.

[28] W. Wein, A. Khamene, D.-A. Clevert, O. Kutter, and N. Navab, "Simulation and fully automatic multimodal registration of medical ultrasound," in *Med. Image Comput. Comput. Assist. Interv. Int. Conf. Med. Image Comput. Comput. Assist. Interv.*, 2007, vol. 10, pp. 136–143.

[29] Y. Sun, S. Kadoury, Y. Li, M. John, J. Resnick, G. Plambeck, R. Liao, F. Sauer, and C. Xu, "Image guidance of intracardiac ultrasound with fusion of pre-operative images," in *Med. Image Comput. Comput. Assist. Interv. Int. Conf. Med. Image Comput. Comput. Assist. Interv.*, 2007, vol. 10, no. Pt 1, pp. 60–67.

[30] X. Huang, N. A. Hill, J. Ren, G. Guiraudon, D. Boughner, and T. M. Peters, "Dynamic 3D ultrasound and MR image registration of the beating heart," in *Med. Image Comput. Comput. Assist. Interv. Int. Conf. Med. Image Comput. Comput. Assist. Interv.*, 2005, vol. 8, no. Pt 2, pp. 171–178.

[31] A. M. Chiu, D. Dey, M. Drangova, W. D. Boyd, and T. M. Peters, "3-D image guidance for minimally invasive robotic coronary artery bypass," *Heart Surg. Forum*, vol. 3, no. 3, pp. 224–231, 2000.

[32] C. A. Linte, J. Moore, A. D. Wiles, C. Wedlake, and T. M. Peters, "Virtual reality-enhanced ultrasound guidance: A novel technique for intracardiac interventions," *Comput. Aided. Surg.*, vol. 13, no. 2, pp. 82–94, Mar. 2008.

[33] F. Maes, D. Vandermeulen, and P. Suetens, "Medical image registration using mutual information," *Proc. IEEE*, vol. 91, no. 10, pp. 1699–1721, Oct. 2003.

[34] D. Gobbi, R. Comeau, and T. Peters, "Ultrasound probe tracking for real-time ultrasound/MRI overlay and visualization of brain shift," in *MICCAI 1999*, Cambridge, U.K., 1999, pp. 920–927.

[35] X. Huang, N. A. Hill, J. Ren, and T. M. Peters, "Rapid registration of multimodal images using a reduced number of voxels," in *Proc. SPIE Int. Soc. Opt. Eng. Med. Imag.*, San Diego, CA, 2006, vol. 6141, p. 614116.

[36] C. Linte, M. Wierzbicki, J. Moore, G. Guiraudon, S. Little, and T. Peters, "Towards subject-specific models of the dynamic heart for image-guided mitral valve surgery," in *Medical Image Computing and Computer-Assisted Intervention—MICCAI 2007: 10th International Conference*. New York: Springer-Verlag, 2007, vol. 4792, Lecture Notes in Computer Science, pp. 94–101.

[37] T. Peters, C. Linte, A. Wiles, N. Hill, J. Moore, C. Wedlake, D. Jones, D. Bainbridge, and G. Guiraudon, "Development of an augmented reality approach for closed intracardiac interventions," in *Proc. 4th IEEE Int. Symp. Biomed. Imag.: From Nano to Macro* , Apr. 2007, pp. 1004–1007.

Authorized licensed use limited to: Florida Institute of Technology. Downloaded on May 12,2025 at 00:40:28 UTC from IEEE Xplore. Restrictions apply.