Chapter 1:

Ultrasound Evaluation of the Upper Abdomen

Overview and Clinical Importance

Ultrasound examination of the upper abdomen is a first- line, non- invasive imaging modality used to evaluate patients presenting with abdominal pain, jaundice, organ enlargement, fever, or suspected hepatobiliary and splenic disease. It is particularly valuable in resource- limited settings because it is portable, repeatable, and free of ionizing radiation. Upper abdominal ultrasound allows real- time assessment of the liver, gallbladder, bile ducts, pancreas, spleen, and the presence of free intraperitoneal fluid.

Right upper quadrant (RUQ) pain commonly indicates hepatobiliary pathology such as gallstones, cholecystitis, cholangitis, liver abscess, or liver tumors.

Left upper quadrant (LUQ) pain may arise from splenic disease, pancreatitis, renal pathology, or gastrointestinal causes.

Upper abdominal symptoms may also reflect extra- abdominal conditions including cardiac, pulmonary, or aortic disease, making ultrasound an essential screening tool.

14.1 Patient Preparation and Scanning Technique

1. *Transducer Selection and Equipment Handling*

A low- frequency curved array transducer (5–2 MHz) is ideal for upper abdominal scanning. This probe provides sufficient penetration to visualize deep abdominal organs while maintaining acceptable resolution. Adequate acoustic coupling should be ensured using ultrasound gel or clean water if gel is unavailable. Oil- based substances must be avoided as they can damage the probe surface. Proper hand hygiene and disinfection of the transducer between patients are mandatory to prevent cross- infection.

2. *Patient Positioning and Preparation*

The examination usually begins with the patient in the supine position. Alternative positions such as left lateral decubitus, right lateral decubitus, or oblique positions are frequently required to optimize visualization and reduce bowel gas interference. For planned examinations, a fasting period of at least four hours is recommended. Fasting distends the gallbladder and reduces gastric and intestinal gas, improving image quality.

14.2 Right Upper Quadrant (RUQ) Ultrasound Examination

1.Systematic Scanning Approach

Scanning begins along the right mid- clavicular line just below the costal margin. The transducer is initially placed in the transverse plane to identify the liver. A slow sweeping motion is used to examine the entire liver parenchyma. Asking the patient to take a deep breath and hold it helps lower the liver beneath the rib cage, improving visualization.

The probe Is then angled obliquely toward both shoulders to assess superior and posterior liver segments. Longitudinal views are obtained by rotating the transducer 90 degrees, allowing evaluation of liver size, contour, and internal architecture. When bowel gas limits visualization, placing the patient in a left lateral or oblique position and using intercostal windows can significantly improve imaging of the liver and gallbladder.

- Practical Scanning Notes

Continuous adjustment of depth and gain is necessary to evaluate both superficial and deep hepatic regions accurately. The liver serves as an excellent acoustic window for gallbladder assessment, which should be examined from neck to fundus in both transverse and longitudinal planes. In non- fasted patients the gallbladder may be contracted and difficult to assess. The common bile duct normally measures 4–5 mm; dilation beyond 6 mm suggests biliary obstruction, though accurate measurement may be challenging for inexperienced operators. Colour Doppler can assist in evaluating hepatic vessels and differentiating bile ducts from vascular structures when clinically required.

14.3 Left Upper Quadrant (LUQ) Ultrasound Examination

Scanning Technique

The examination of the left upper quadrant begins in the left posterior axillary line at the level of the lower ribs. The spleen and left kidney are identified using transverse sweeps. Longitudinal views are then obtained to assess splenic size and texture. Intercostal scanning between the 9th and 10th ribs is often required due to overlying bowel gas.

Key Considerations

It is essential to clearly differentiate the spleen from the stomach to avoid misinterpretation. Identifying the left kidney adjacent to the spleen provides an important anatomical landmark and comparison for echogenicity.

14.4 Liver Evaluation

Normal Liver Appearance

A normal liver has a homogeneous echotexture with echogenicity equal to or slightly greater than that of the renal cortex. Portal triads appear as small echogenic foci scattered throughout the liver parenchyma. Ligaments and fissures are highly echogenic due to their fatty content.

Figure 1: Normal liver
The normal liver parenchyma (L) is uniform
and is equal in echogenicity to the normal kidney parenchyma (K).
The portal triads appear as echogenic foci (arrowheads) in the periphery of the liver.

Liver Abnormalities

- Hepatitis

Acute hepatitis typically does not produce significant changes in the sonographic appearance of the liver. In some cases, hepatic oedema may lead to reduced parenchymal echogenicity, making the portal triads appear more prominent, and may be associated with hepatomegaly.

In contrast, chronic hepatitis usually results in a mild, diffuse increase in liver echogenicity due to ongoing inflammatory changes.

- Fatty Liver (Hepatic Steatosis)

Fatty infiltration of hepatocytes is a common and non-specific response to liver injury, regardless of the underlying cause. Frequent risk factors include malnutrition, chronic alcohol consumption, diabetes mellitus, and obesity.

On ultrasound, fatty liver is characterized by a marked increase in hepatic echogenicity, causing the liver to appear significantly brighter than the renal cortex. In severe cases, excessive fat deposition reduces ultrasound beam penetration, limiting visualization of deeper structures. Fatty infiltration may be diffuse or focal, affecting only certain regions of the liver.

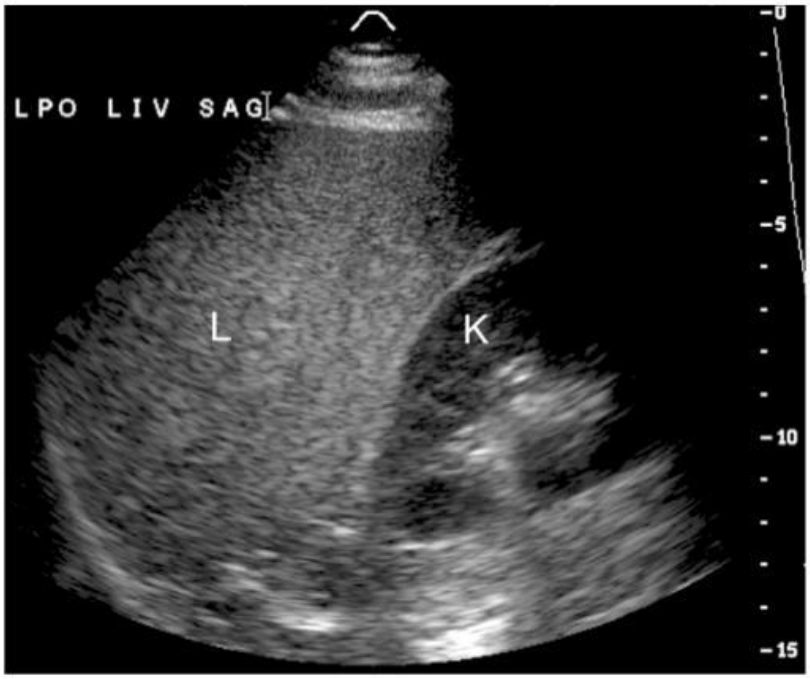

Figure 2: Diffuse fatty liver
In this malnourished patient the liver (L) is much more echogenic (brighter) than the kidney (K). This finding is indicative of injury to liver cells.

- Cirrhosis and Portal Hypertension

Cirrhosis represents the end result of chronic, progressive hepatocellular injury, where repeated cell death is followed by fibrosis and nodular regeneration. This leads to distortion of normal hepatic architecture, including both parenchymal and vascular structures.

Sonographically, the liver demonstrates a coarse echotexture, mildly increased echogenicity, an irregular nodular surface, and the presence of iso- or hypoechoic regenerative nodules. In advanced stages, the liver size is often reduced and accompanied by jaundice and ascites.

As cirrhosis progresses, portal hypertension develops, manifested by dilatation of the portal vein (>13 mm) and abnormal flow patterns such as biphasic or reversed flow, which can be evaluated using colour Doppler by experienced operators.

Although cirrhosis is the most common cause of portal hypertension, other conditions including portal vein thrombosis, Budd–Chiari syndrome, and right-sided heart failure may also produce similar findings.

The most frequent causes of cirrhosis include chronic viral hepatitis (B and C), alcohol abuse, parasitic infections, sclerosing cholangitis, metabolic disorders, and primary biliary cirrhosis.

Figure 3: Liver cirrhosis
The liver (L) shows heterogeneous mildly increased echogenicity characteristic of cirrhosis. Ascites (a) outlines the nodular surface of the cirrhotic liver.

Benign Cystic Lesions of the Liver

- Simple Hepatic Cysts

Benign liver cysts are frequent incidental findings, seen in approximately 2–5% of the population, and are usually of no clinical significance. Complications such as intracystic hemorrhage or secondary infection are uncommon.

On ultrasound, simple hepatic cysts appear as anechoic, well-defined lesions with thin, smooth, avascular walls. The cyst margins are often lobulated, and their size can range from a few millimeters to very large lesions. Larger cysts typically demonstrate posterior acoustic enhancement (through-transmission). Fine internal septations may occasionally be present. Cysts are often multiple and clustered, and Doppler imaging confirms absence of vascularity within the cyst wall or septa.

Figure 4: Benign liver cyst
Longitudinal image of the liver reveals a well-defined anechoic mass (arrowheads) with ultrasound characteristics of a benign liver cyst. The cyst is sharply defined and lobulated in contour. No internal echoes are present within the cyst. Accentuated through-transmission (arrows) is evidenced by bright echoes deep to the cyst.

Liver Abscesses: General Overview

Liver abscesses represent localized collections of infected fluid within the liver parenchyma. They arise due to several etiologies, including:

- Amoebic infection
- Hydatid disease
- Pyogenic (bacterial) infection

Opportunistic infections in immunocompromised individuals

The sonographic appearance is variable. Most abscesses appear as ill-defined hypoechoic or complex masses with thick, irregular walls. Internal echoes representing pus or necrotic debris are common, and many lesions demonstrate septations and multiple loculations.

- **Amoebic Liver Abscess**

Pathogenesis and Epidemiology

Amoebiasis, caused by Entamoeba histolytica, is one of the most prevalent parasitic infections worldwide, particularly in regions with poor sanitation and limited resources. Although it is primarily an intestinal disease, extraintestinal involvement is common and potentially fatal, with reported mortality rates of 7–14%.

Ultrasound Features

The most frequent and serious complication is amoebic liver abscess, which typically occurs in the right hepatic lobe adjacent to the diaphragm. Parasites migrate from the intestine via the portal circulation, forming colonies that merge into large unilocular abscesses, though smaller micro-abscesses may also be present.

On ultrasound, amoebic abscesses usually appear as relatively homogeneous, single-cavity lesions abutting the liver surface or diaphragm. This appearance contrasts with pyogenic abscesses, which are often multiloculated and heterogeneous.

Complications

Common complications include rupture into the pleural space, causing empyema, or rupture into the peritoneal or retroperitoneal spaces. Associated ultrasound findings may include biliary wall thickening, gallbladder inflammation, pancreatitis, pericardial effusion, cardiac tamponade, or retroperitoneal abscess formation.

Ultrasound is the imaging modality of choice for diagnosis, detection of rupture, monitoring disease spread, and assessing response to therapy.

Figure 5: Amoebic liver absces
The abscess is represented as a large mass (between arrowheads) in the posterior dome of the right lobe of the liver (L).
The mass presents a large surface to liver capsule abutting the diaphragm (arrow).
This is the most common location for amoebic abscess.

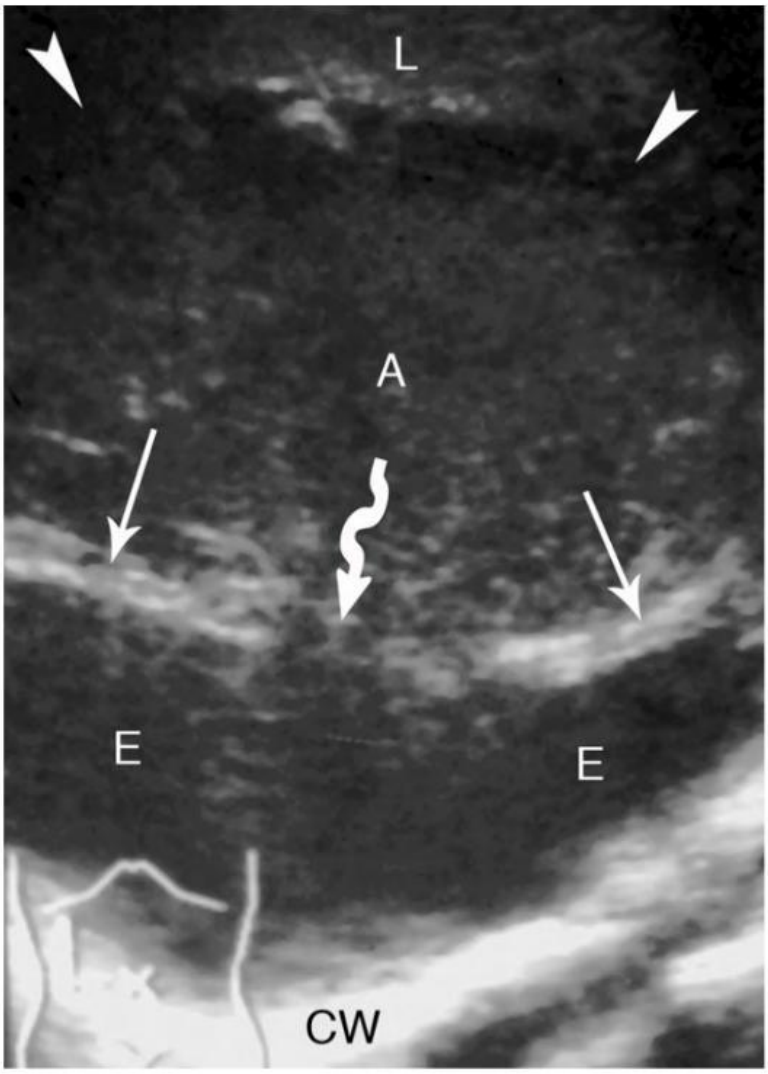

Figure 6: Rupture of hepatic amoebic abscess through the diaphragm
A large amebic abscess (between arrowheads) in the right lobe of the liver (L) has ruptured through the diaphragm into the pleural space causing an amebic empyema (E).
The diaphragm is seen as a thick bright line (straight arrows).
The defect in the thick bright line (curvy arrow) is the site of rupture.
The posterior chest wall (CW) is seen as a thicker bright interface.

Hydatid Disease of the Liver

Etiology and Transmission

Hydatid disease is caused by Echinococcus granulosus and is endemic in grazing regions such as Africa, South America, Australia, the Middle East, and the Mediterranean. Humans acquire infection by ingesting food or water contaminated with parasite eggs.

Ultrasound Characteristics

Hydatid cysts most commonly involve the liver, though they may occur in nearly any organ. Cysts contain clear fluid and are often unilocular, but frequently show daughter cysts.

Characteristic sonographic features include:

- Multilayered cyst wall producing a double echogenic line
- Daughter cysts attached initially to the wall and later floating freely
- Hydatid sand, seen as echogenic particulate matter within the cyst
- Floating membranes from collapsed daughter cysts

Wall calcification in chronic disease

The imaging appearance remains consistent regardless of organ location. Ultrasound guidance is essential for aspiration and drainage when required, with definitive diagnosis confirmed by laboratory testing.

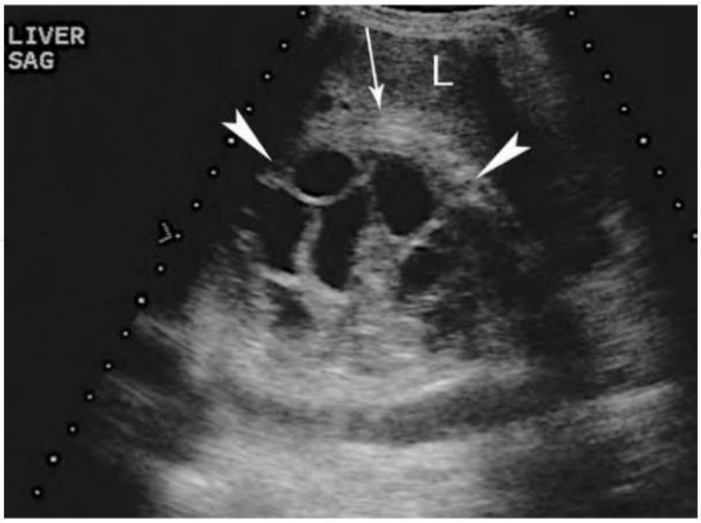

Figure 7: Hydatid liver cyst
Ultrasound image of the liver (L) reveals a multiloculated cyst (arrowheads) with a multi-layered thick wall (arrow).
The appearance is typical of a hydatid mother cyst containing multiple daughter cysts.

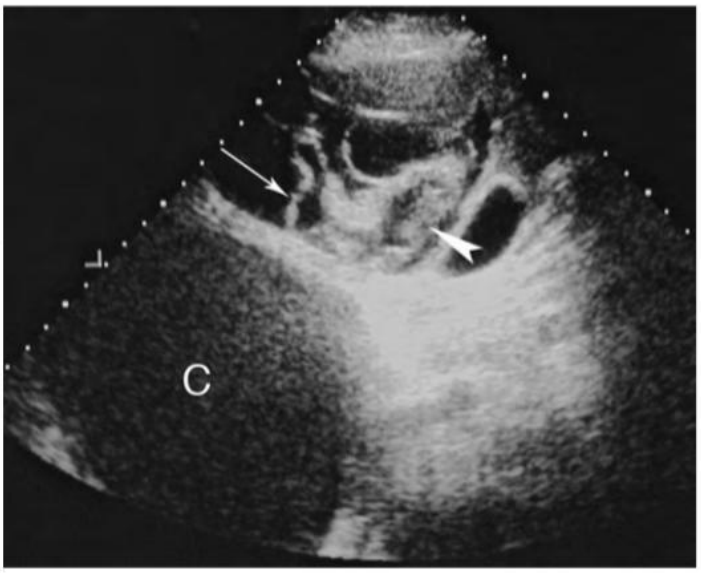

Figure 8: Hydatid cysts containing hydatic sand and floating membranes
Ultrasound of the liver in a different patient reveals two hydatid cysts.
The more proximal cyst contains daughter cysts that have detached from the wall of the mother cyst and are collapsed (arrowhead) in the bottom of the mother cyst.
A characteristic floating membrane (arrow) is also present. The larger more distal cyst (C) is filled with particulate echoes characteristic of hydatid sand.

Pyogenic Liver Abscess

- Clinical Presentation and Causes

Pyogenic abscesses present with acute systemic illness, including fever, abdominal pain, jaundice, anorexia, vomiting, malaise, and weight loss. Laboratory findings commonly show leukocytosis and elevated liver enzymes.

They usually develop as a complication of biliary tract infection, trauma, or sepsis, though the source may be unidentified.

- Ultrasound Findings

On ultrasound, pyogenic abscesses appear as poorly defined hypoechoic or complex masses with thick, irregular walls. The contents consist of thick purulent fluid, often with fluid–fluid levels or gas. Septations and multiple locules are common, and lesions are frequently multiple and clustered.

Doppler imaging shows no flow within the abscess cavity, with increased vascularity in the surrounding wall and septa. Diagnosis and treatment are effectively achieved by ultrasound-guided aspiration and drainage.

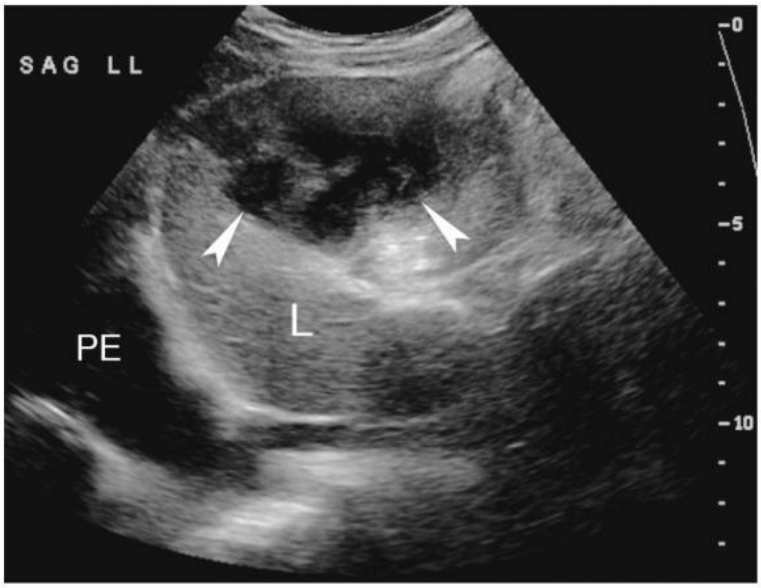

Figure 9: Liver abscess
Longitudinal ultrasound image through the liver (L) in an acutely ill febrile patient reveals a cystic mass (arrowheads) with irregular thick walls, thick septa, and containing fluid with echogenic particulate matter.
On ultrasound-guided aspiration this lesion proved to be a pyogenic abscess caused by *Escherichia coli*. An associated right pleural effusion (PE) is also present.

Figure 10: Liver micro-abscesse
Longitudinal ultrasound image through the liver in an HIV-positive patient reveals innumerable small hypoechoic lesions (arrows) highly indicative of micro-abscesses. Similar lesions were present in the spleen. Note the punctate echogenic foci in many of the lesions strongly suggestive of fungal infection. Candida was proven to be the causative organism.

Most infections are polymicrobial, with Escherichia coli and Klebsiella pneumoniae being the most common organisms.

Opportunistic Hepatic Infections

- In immunocompromised patients, liver involvement typically manifests as numerous micro-abscesses, usually less than 10 mm in size, often affecting both the liver and spleen.
- Causative organisms include fungi (Candida, Aspergillus, Cryptococcus, Histoplasma, Mucor), Pneumocystis, cytomegalovirus, tuberculosis, and atypical mycobacteria.
- Fungal infections classically produce target lesions with a central echogenic focus and hypoechoic halo, while Pneumocystis causes diffuse punctate echogenic lesions. Healing micro-abscesses may undergo calcification.

Primary Malignant Tumours of the Liver

- Hepatocellular Carcinoma (HCC)

HCC is the most common primary malignant liver tumour, typically arising in patients with cirrhosis or chronic hepatitis B or C. Tumours may present as a single mass, a dominant lesion with satellite nodules, or diffuse infiltration.

Small lesions are difficult to distinguish from regenerative nodules, whereas larger tumours are heterogeneous with necrosis and hemorrhage. Vascular invasion of the portal or hepatic veins is a characteristic feature.

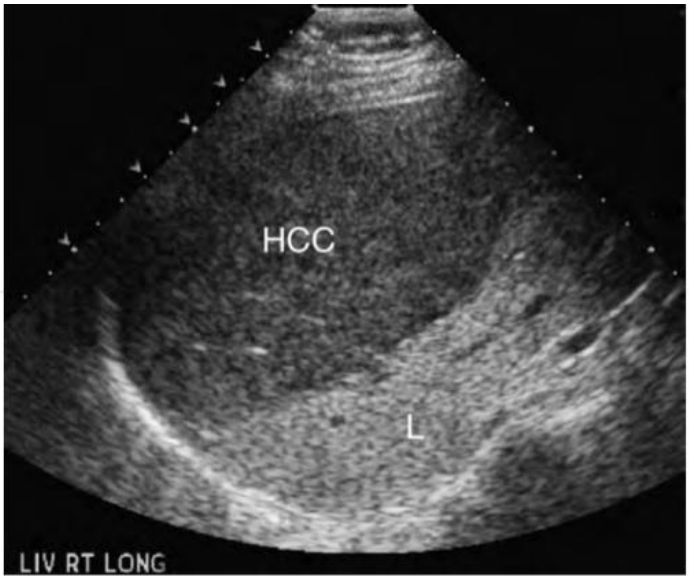

Figure 12: Hepatocellular carcinoma
Longitudinal image shows a large hepatocellular carcinoma (HCC) arising in a liver (L) affected by chronic hepatitis C.

Secondary Malignant Liver Disease

- Liver Metastases

Metastases are the most common hepatic malignancies, frequently originating from cancers of the gastrointestinal tract, breast, pancreas, and lungs.

They often appear as multiple lesions, though solitary metastases may occur, particularly from colorectal cancer. A target or bull's-eye pattern is common, but lesions may be solid, cystic, calcified, hyperechoic, or hypoechoic. Metastatic disease should always be considered in the differential diagnosis of focal liver lesions.

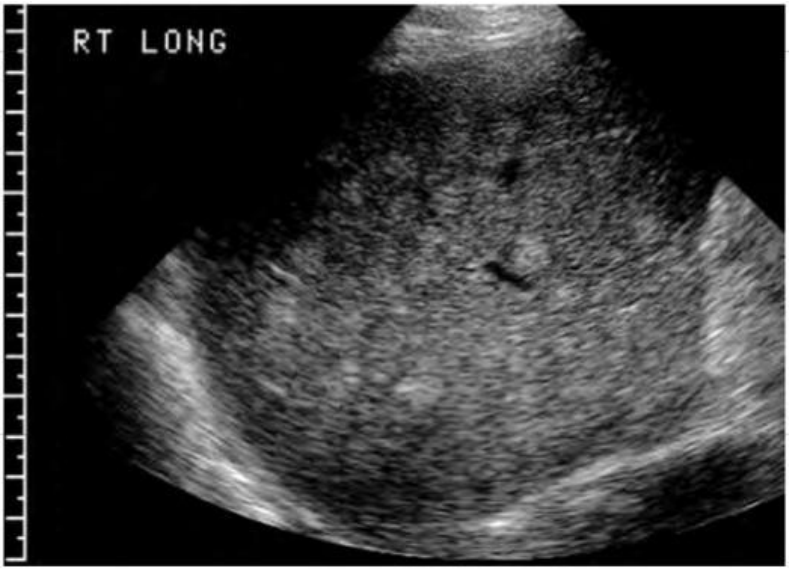

Figure 13: Liver metastases
Innumerable small hyperechoic nodules are distributed throughout the liver in this patient with metastatic colon carcinoma.

- Hepatic Schistosomiasis

Disease Overview

Schistosomiasis is caused by chronic infection with Schistosoma species, with geographic distribution varying by species. Hepatic involvement leads to chronic liver and splenic complications.

Ultrasound Features

The hallmark ultrasound finding is periportal fibrosis, seen as hyperechoic thickening around portal veins, known as the periportal “ruff.” Thickness exceeding 3 mm is significant and may surpass 7 mm. Progressive fibrosis causes straightened portal veins, producing the classic “pipe-stem” and “starry sky” appearances.

Portal hypertension develops, evidenced by portal vein dilatation (>13 mm in adults), splenomegaly, portosystemic collaterals, and possible portal vein thrombosis.

Differentiation from Cirrhosis

Unlike cirrhosis, normal liver architecture is preserved, liver function tests remain normal, regenerative nodules do not form, and hepatic veins remain patent with normal Doppler flow. Importantly, hepatic schistosomiasis is reversible with treatment, whereas cirrhosis is not. Co-infection with hepatitis B or C accelerates disease progression, and schistosomiasis is reported in a significant proportion of HIV-infected patients in endemic regions.

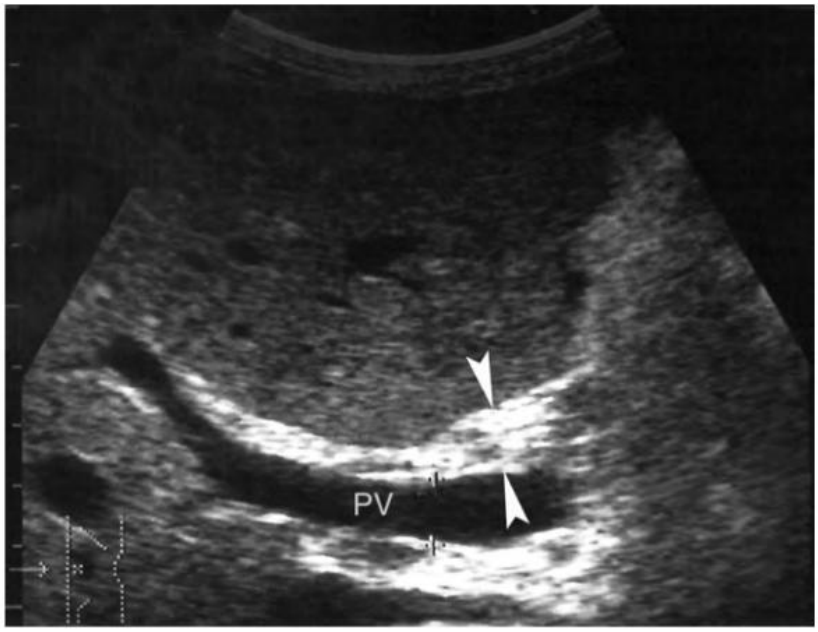

Figure 14: Periportal fibrosis due to hepatic schistosomiasis
Ultrasound image of the liver in a 12 year old boy shows marked echogenic thickening of the tissues surrounding the main portal vein, i.e. 'ruff' (PV).
The periportal fibrosis exceeds 11 mm in thickness (between arrowheads).
This finding is strongly associated with hepatic schistosomiasis.
The portal vein is measured at 10 mm (between cursors, +), which is considered dilated for a child of 12 years (normal diameter = 8 mm).
Portal vein diameter in children increases progressively with age.
A dilated portal vein is evidence of developing portal hypertension, an important complication of hepatic schistosomiasis.

Figure 15: Periportal fibrosis of small portal veins due to hepatic schistosomiasis
Liver ultrasound in a 25 year old man reveals the 'starry sky' appearance of echogenic fibrosis (arrowheads) involving small portal veins within the liver parenchyma.
Fibrosis of the portal veins thickening the tissue surrounding the veins and causes the portal triads to appear highly echogenic on a background of normal liver parenchyma.
Progressive fibrosis straightens the small portal veins causing a characteristic 'pipe-stem' appearance and eventually leads to portal hypertension.

14.5 Gallbladder and Biliary Tract

Normal Gallbladder

The gallbladder is a pear- shaped, fluid- filled structure located on the inferior surface of the liver. In fasting patients it is distended and easily visualized. The wall is thin and echogenic, and the neck leads toward the common bile duct in the porta hepatis.

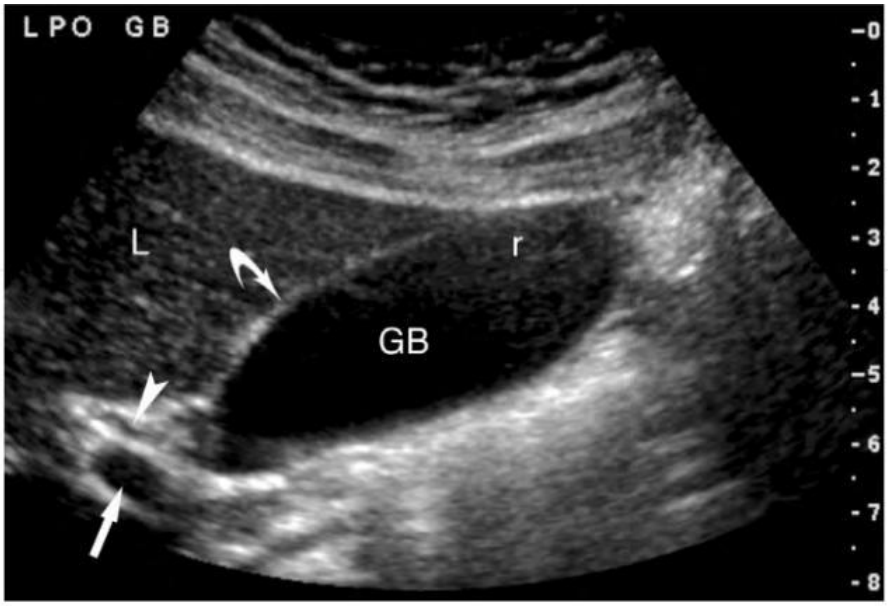

Figure 16: Normal gallbladder
The normal distended gallbladder (GB) appears as a fluid-filled sac on the inferior surface of the liver (L). Reverberations echoes (r) are a common artefact seen in the anterior aspect of the gallbladder and should not be misinterpreted as pathology.
The neck of the gallbladder extends toward portal vein (straight arrow) and common bile duct (arrowhead) in the porta hepatis. The wall of the gallbladder (curved arrow) appears as a uniformly thin echogenic line abutting the liver. This region should always be examined for wall thickening and oedema that would indicate gallbladder disease.

Gallbladder Pathology

Gallstones appear as echogenic foci with posterior acoustic shadowing and typically move with patient repositioning. Acute cholecystitis is characterized by gallbladder wall thickening greater than 3 mm, gallbladder distension, internal debris, and a positive sonographic Murphy's sign. Acalculous cholecystitis occurs without stones, particularly in critically ill patients. Bile duct dilation indicates obstruction due to stones, tumors, or strictures and is commonly associated with jaundice.

Gallbladder and Biliary Tract Disorders

- Gallstones (Cholelithiasis)

Gallstones are visualized on ultrasound as bright echogenic structures within the gallbladder lumen that produce posterior acoustic shadowing. A key diagnostic feature is their mobility, as stones typically change position when the patient's posture is

altered. Gallstones vary widely in size and are most often multiple, although solitary stones may also occur.

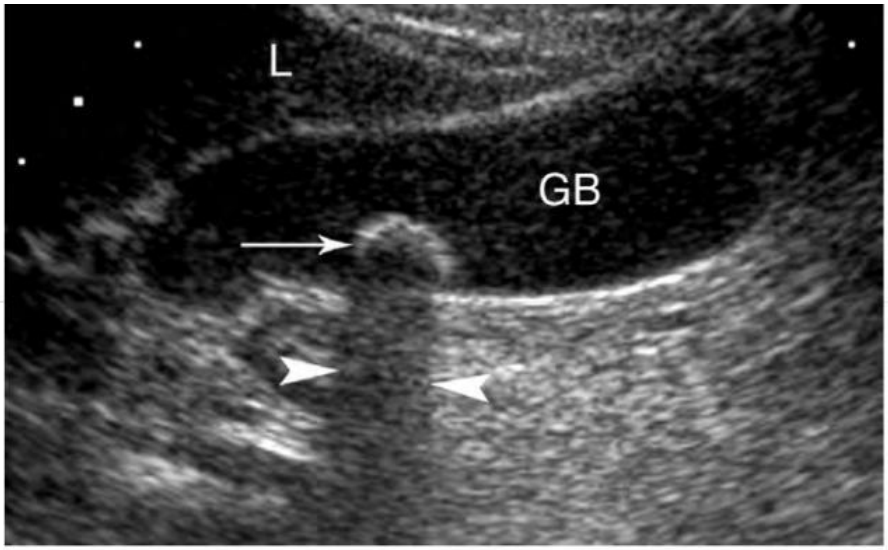

Figure 17: Gallstone in the gallbladder
Ultrasound image through the liver (L) in the long axis of the gallbladder (GB) reveals a gallstone in the gallbladder lumen. The gallstone (arrow) appears as an echogenic nodule that casts a prominent acoustic shadow (between solid arrowheads). The gallstone was observed to move within the gallbladder as the patient rolled into a different position.

- Acute Inflammation of the Gallbladder (Acute Cholecystitis)

Acute cholecystitis is most commonly caused by impaction of gallstones in the gallbladder neck or cystic duct, accounting for approximately 90–95% of cases. In critically ill adults, inflammation may develop without gallstones, a condition known as acalculous cholecystitis, while in children nearly half of acute cases are acalculous.

<u>Ultrasound findings</u>

include gallbladder wall thickening greater than 3 mm, often showing a layered or stratified appearance due to oedema. The gallbladder is frequently distended, with a transverse diameter exceeding 5 cm. The lumen may contain echogenic debris, representing pus, blood, necrotic material, or biliary sludge caused by concentrated bile.

<u>Sonographic Murphy’s Sign</u>

The sonographic Murphy’s sign is a highly specific indicator of acute cholecystitis when performed correctly. Gentle pressure is applied with the transducer over different abdominal regions. The sign is considered positive when maximal tenderness occurs

directly over the imaged gallbladder. It is regarded as negative if tenderness is absent, generalized, or not localized to the gallbladder.

Important Note: Gallbladder wall thickening is not specific to acute cholecystitis and may also be observed in conditions such as gallbladder carcinoma, renal failure, hepatitis, right-sided heart failure, cirrhosis, and pancreatitis.

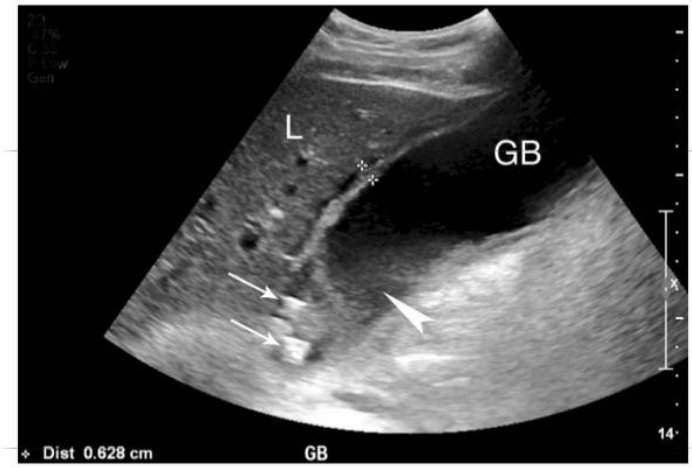

Figure 18: Acute cholecystitis
Using the liver (L) as a sonographic window the gallbladder (GB) is shown in its long axis.
Multiple gallstones (arrows) are impacted in the gallbladder neck.
These stones did not move with changes in the patient's position.
Echogenic debris (arrowhead) layers within the bile in the gallbladder lumen.
The gallbladder wall (cursors +) is thickened to 6 mm.
Acute cholecystitis was confirmed at surgery.

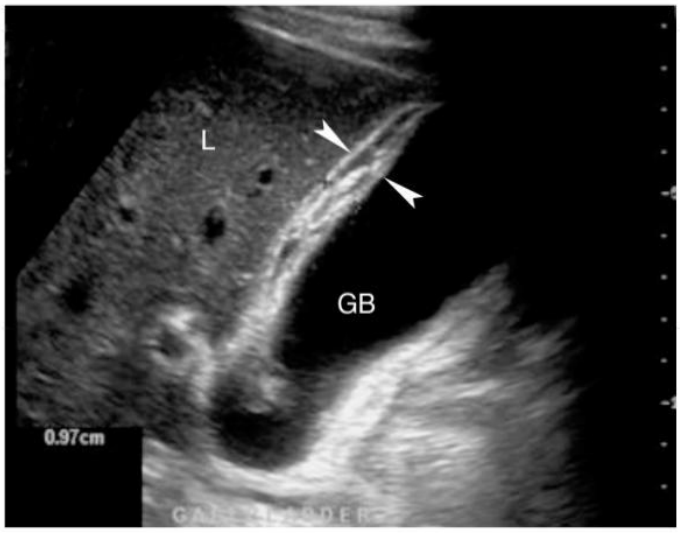

Figure 19: Acute acalculous cholecystitis
The gallbladder (GB), seen through the liver (L), is without detectable gallstones and shows laminated wall thickening (between arrowheads) characteristic of oedema and inflammation of the gallbladder wall. This acutely ill patient has acalcuous cholecystitis.

Bile Duct Dilatation and Biliary Obstruction

Under normal conditions, the bile ducts run alongside the portal vein and hepatic artery within the portal triads and are not usually visible on ultrasound. When biliary obstruction occurs—most commonly due to gallstones, tumours, or strictures—the bile ducts become dilated, producing a characteristic branching or “tree-like” appearance within the liver.

The common bile duct (CBD) is considered dilated when its internal diameter exceeds 6 mm. Patients with significant biliary obstruction typically present with clinical jaundice.

In elderly individuals and in patients who have undergone cholecystectomy, mild dilatation of the extrahepatic bile ducts may be seen without pathological obstruction and should be interpreted cautiously in the clinical context.

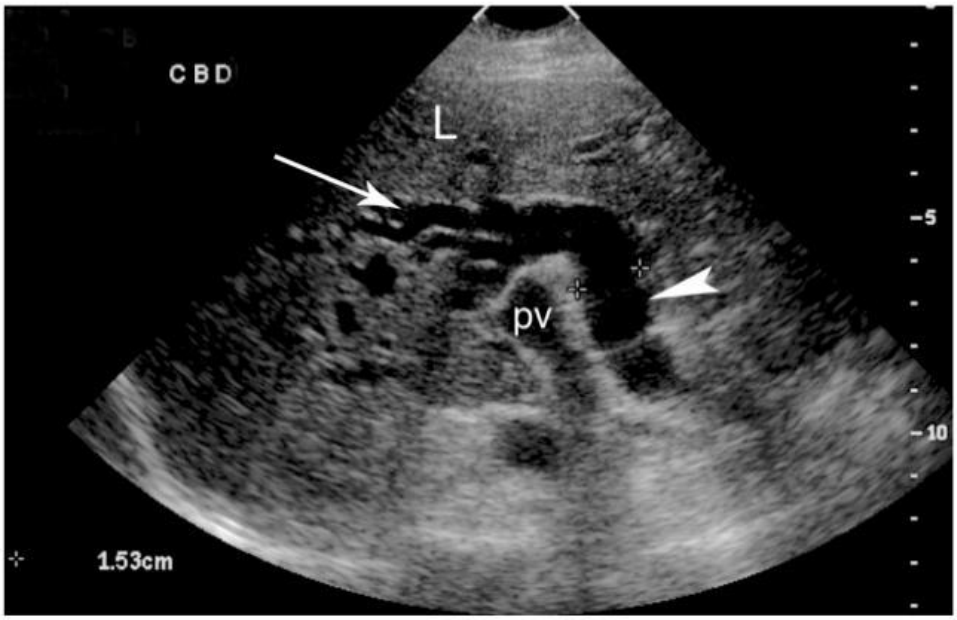

Figure 20: Dilated bile ducts
Oblique image of the liver (L) through the region of the porta hepatis shows the characteristic twisted appearance of dilated bile ducts (arrow). The common bile duct (arrowhead), seen anterior to the portal vein (pv), is measured at 1.5 cm (cursors, +) well above the upper limit of normal (6 mm). This patient had a malignant tumour in the head of the pancreas.

14.6 Pancreatic Assessment

Normal Pancreas

The pancreas lies posterior to the stomach and is best visualized in the transverse epigastric plane. It is identified by its relationship to the splenic vein and portal vein. The pancreas is normally slightly more echogenic than the liver and spleen.

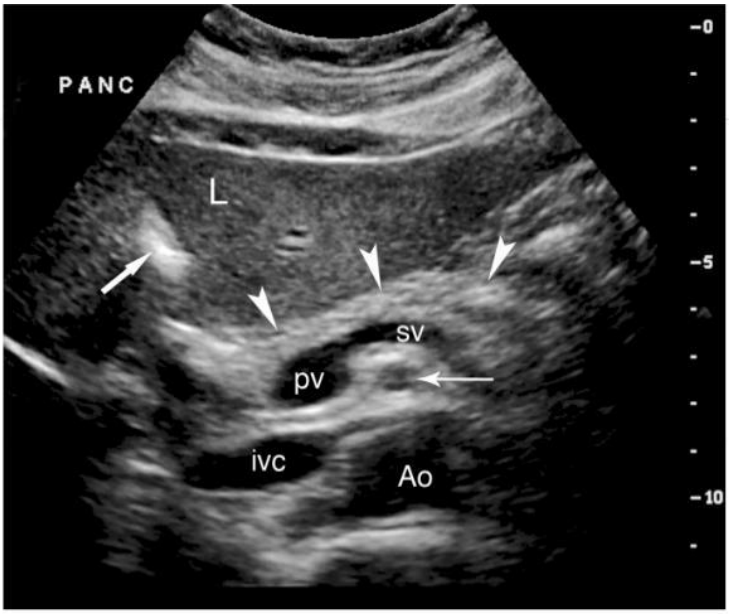

Figure 21: Normal pancreas
The normal pancreas is more echogenic than the liver, kidneys, or spleen. It is identified as the echogenic tissue (arrowheads) anterior to the splenic vein (sv) and portal vein (pv). A large left lobe of the liver (L) serves as a good acoustic window. The pancreas is commonly obscured on ultrasound by gas in the stomach or colon. Other anatomic landmarks to identify are the inferior vena cava (ivc), aorta (Ao), and superior mesenteric artery (thinner arrow). Fat (thicker arrow) in the fissure of the ligamentum teres in the liver is normal and should not be misidentified as a tumour.

Pancreatic Pathology

The most common ultrasound finding in pancreatitis is peripancreatic fluid collection. Chronic collections persisting beyond six weeks are termed pancreatic pseudocysts. These collections may become infected and require image- guided drainage.

Pancreatic pseudocyst / peripancreatic fluid

The most common pancreatic pathology identified by ultrasound is fluid that accumulates anterior To the pancreas associated with acute pancreatitis (Figure 22). If the fluid collection is long-standing (>6 weeks) it is considered a pancreatic pseudocyst. While fluid collections associated with severe Acute pancreatitis may be found anywhere in the abdomen the most common location is in The epigastric region. These fluid collections are usually sterile but commonly become infected Resulting in increasing abdominal pain and sepsis. Infection is confirmed by guided fluid aspiration Efficiently performed with ultrasound

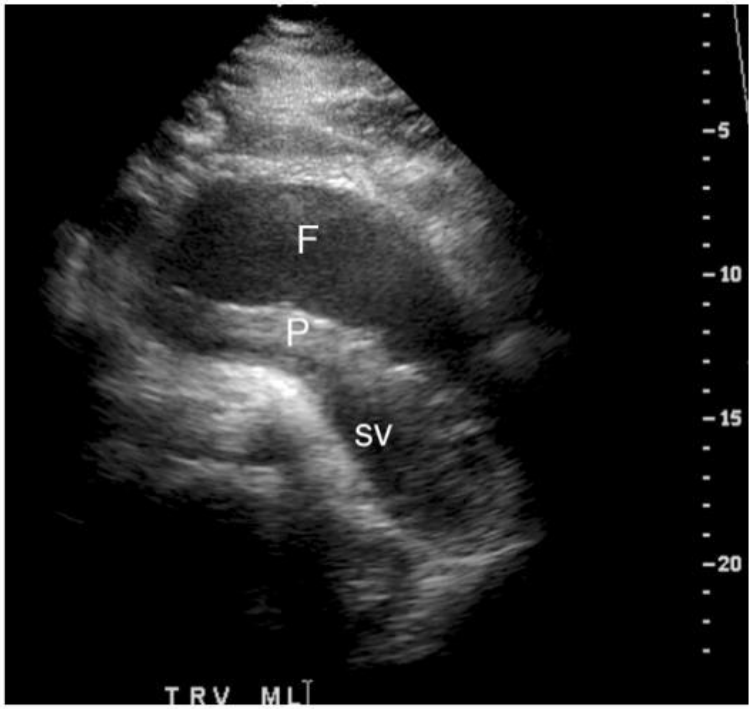

Figure 22: Peripancreatic fluid collection
Transverse image in the midline epigastrium shows a collection of fluid (F) containing echogenic particulate debris anterior to the pancreas (P). The pancreas is identified by its location anterior to the splenic vein (sv).

14.7 Spleen Assessment

Normal Spleen

The spleen is homogeneous, slightly more echogenic than the liver, and has a smooth contour. Its maximum normal length does not exceed 14 cm.

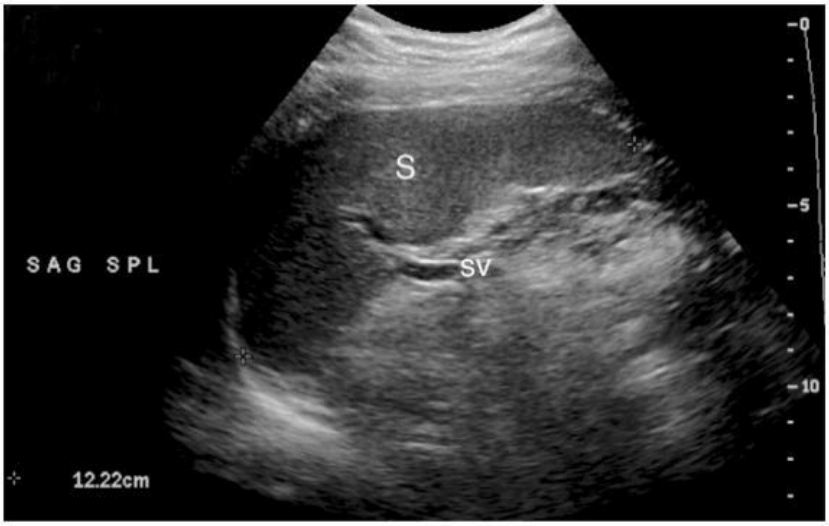

Figure 23: Normal spleen
Longitudinal image through the left upper quadrant of the abdomen demonstrates the normal appearance of the spleen (S). The convex outer surface of the spleen conforms to the shape of the diaphragm. The splenic vein (sv) is seen exiting from the splenic hilum.

Splenic Abnormalities

Splenomegaly is a non- specific finding associated with infections, hematological disorders, and portal hypertension. Focal splenic lesions include cysts, abscesses, micro- abscesses in immunocompromised patients, and infiltrative diseases such as lymphoma.

- Splenomegaly

Splenomegaly is non-specific and can be due to a broad range of infections, tropical diseases and Neoplasms. Causes include portal hypertension, lymphoproliferative disorders such as lymphoma, Malaria, infectious mononucleosis, AIDS, and splenic vein thrombosis. Splenomegaly is present If any dimension of the spleen exceeds 14 cm. To obtain the maximum dimension of the spleen Lie the patient supine or in the right lateral decubitus position if needed. Scan through the spleen With whichever orientation of the transducer (i.e. transverse, longitudinal or oblique) creates an Image that maximizes the long dimension of the spleen, and measure with the callipers.

- Focal splenic lesions

Simple splenic cysts typically appear as solitary, round shapes with clear regular borders, uniformly Anechoic, and with through transmission and posterior wall enhancement. Pseudocysts are typically solitary with thick, sometimes calcified walls,

and contain echogenic Debris which can be caused by infection or haemorrhage.Splenic abscesses are usually pyogenic caused by sepsis, penetrating trauma, or as a complication Of splenic infarction. Patients usually present with pain, fever, and chills. Findings on ultrasound Are variable including focal fluid collections containing particulate debris or gas with acoustic shadowing.

Splenic micro-abscesses occur in immune-compromised patients and appear as multiple small (<10 mm) echolucencies or echodensities, commonly in association with similar lesions in the liver.Lymphoma in the spleen, most commonly manifested as splenomegaly, can sometimes mimic The appearance of micro abscesses, with numerous hypoechoic (though not anechoic) lesions of Similar size located throughout the spleen, and often also in the liver.

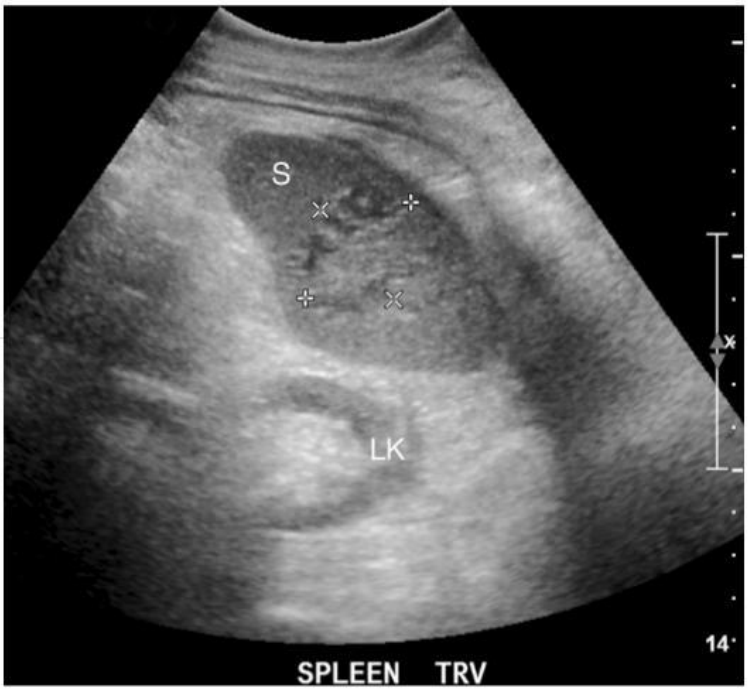

Figure 24: Splenic abscess
Transverse scan in the left upper quadrant in a patient with abdominal pain and sepsis shows a heterogeneous mass (marked by callipers: x, +) in the central portion of the spleen (S). This appearance is typical for splenic abscess.
The left kidney (LK) is evident.

14.8 Free Fluid in the Upper Abdomen

Detection and Interpretation

The presence of free intraperitoneal fluid is an important pathological finding. Simple ascites appears anechoic and is commonly associated with chronic liver disease or heart failure. Complex fluid with internal echoes, septations, or debris suggests infection, hemorrhage, or malignancy. Careful evaluation of fluid distribution and characteristics assists in determining the underlying cause.

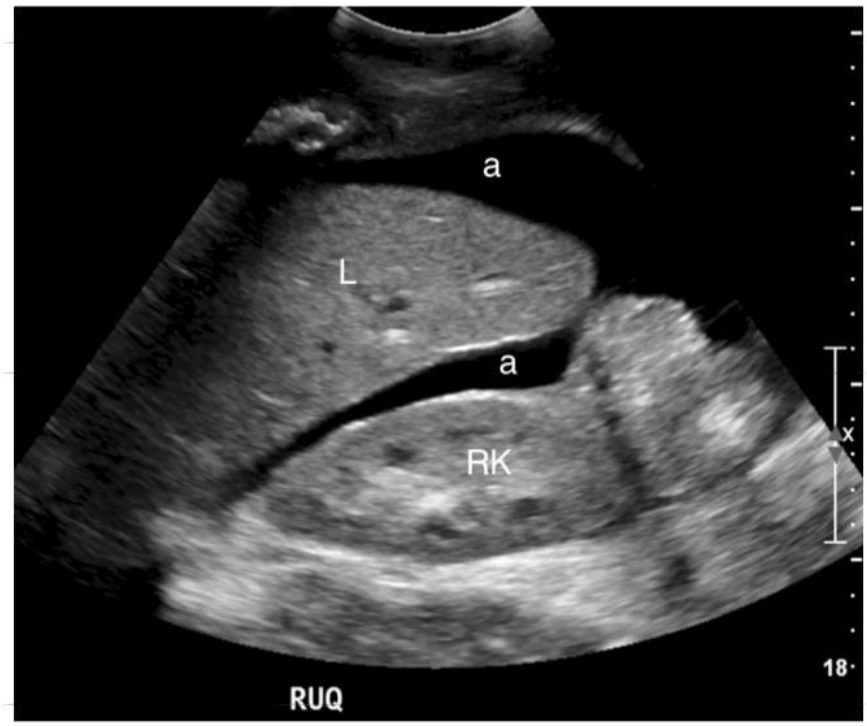

Figure 25: Free fluid
Longitudinal scan through the right upper quadrant reveals anechoic fluid (a) around the liver (L) and between the liver and spleen.
Clear fluid without echoes is likely a transudate most commonly associated with chronic liver disease, congestive heart failure or electrolyte imbalance.

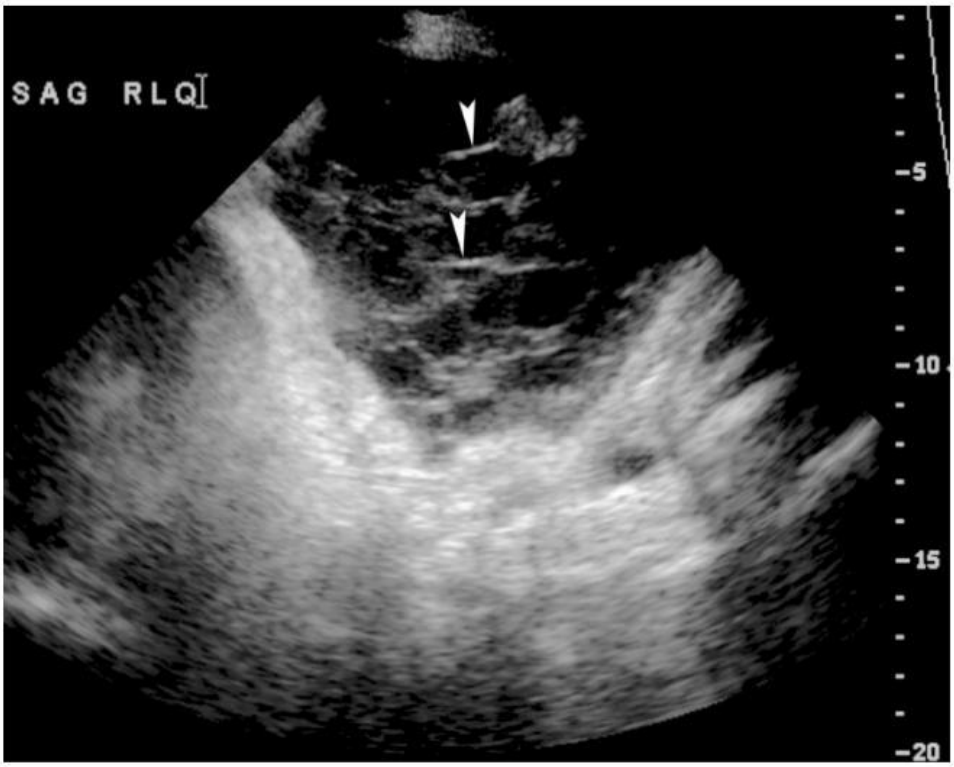

Figure 26: Tuberculous peritonitis
Longitudinal scan through the right lower quadrant reveals complex fluid with prominent septations (arrowheads) distending the peritoneal cavity. In this case the cause was tuberculous peritonitis. However, this appearance of complex ascites may be seen with trauma (e.g. blood or bowel contents), malignant disease (e.g. ovarian cancer), or other infections of the peritoneal cavity.

Summary

A structured and methodical ultrasound examination of the upper abdomen enables early detection of a wide range of abdominal and systemic diseases. Correlation with clinical findings is essential for accurate diagnosis and appropriate patient management.