International Journal of Impotence Research (2012) 24, 206 – 209
© 2012 Macmillan Publishers Limited All rights reserved 0955-9930/12
www.nature.com/ijir

ORIGINAL ARTICLE

Radiological evaluation by magnetic resonance of the 'new anatomy' of transsexual patients undergoing male to female sex reassignment surgery

E Brunocilla[1], M Soli[2], A Franceschelli[2], R Schiavina[1], M Borghesi[1], G Gentile[2], CV Pultrone[1], G Martorana[1], MG Orrei[3] and F Colombo[2]

Magnetic resonance (MR) is the best way to assess the new anatomy of the pelvis after male to female (MtF) sex reassignment surgery. The aim of the study was to evaluate the radiological appearance of the small pelvis after MtF surgery and to compare it with the normal women's anatomy. Fifteen patients who underwent MtF surgery were subjected to pelvic MR at least 6 months after surgery. The anthropometric parameters of the small pelvis were measured and compared with those of ten healthy women (control group). Our personal technique (creation of the mons Veneris under the pubic skin) was performed in all patients. In patients who underwent MtF surgery, the mean neovaginal depth was slightly superior than in women ($P = 0.009$). The length of the inferior pelvic aperture and of the inlet of pelvis was higher in the control group ($P < 0.005$). The inclination between the axis of the neovagina and the inferior pelvis aperture, the thickness of the mons Veneris and the thickness of the rectovaginal septum were comparable between the two study groups. MR consents a detailed assessment of the new pelvic anatomy after MtF surgery. The anthropometric parameters measured in our patients were comparable with those of women.

International Journal of Impotence Research (2012) **24,** 206–209; doi:10.1038/ijir.2012.18; published online 7 June 2012

Keywords: anatomy; magnetic resonance; neovagina; sex reassignment; transsexualism

INTRODUCTION

Transsexualism is a disorder of gender identification described for the first time by Benjamin in 1953.[1] A person in a transsexual condition is characterized by genital characteristics that are the opposite of his own sexual identification as male or female. The main goal of the treatment is to conform the body to the gender self-perception.[2] Surgical gender conversion is the last step of a fairly lengthy process that involves psychological, endocrinological, aesthetic and legal procedures. Sex reassignment surgery involves the correction of the external genitalia, breast enlargement, changes in body hair characteristics and the redistribution of fat tissue in a female mode.[3] In male to female (MtF) gender reassignment surgery, the main target is the creation of aesthetic and functional external female genitalia, with a normal-looking vestibulum, and a profound and compliant vaginal channel. Moreover, the creation of a neoclitoris substantially improves the clinical and functional results. Jones *et al.*[4] described the surgical principles of the operation of MtF sex reassignment, using the cutis of the penis and the scrotum for the creation of neovagina. This technique was the starting point for the development of many other techniques.[5–7] The technique for clitoroplasty was first described by Hinderer[8–10] and is based on the use of a portion of the glans penis with preservation of the dorsal penile neurovascular bundle. In a recent paper, we proposed a new surgical technique for the creation of the neoclitoris and the configuration of a natural-looking female mons Veneris.[11] Even if this surgery has increased in the last few years, there are at present few studies in the literature concerning the follow-up of these patients.[12] Moreover, there are only two published papers addressing the radiological evaluation of sex reassignment surgery.[13,14] As far as we know, if we exclude the external appearance of the external genitalia, the best way to assess the new anatomy of the pelvis after MtF sex reassignment surgery is magnetic resonance (MR).[15] The aim of the present study was to evaluate the radiological appearance of the small pelvis after MtF surgery and to compare it with the anatomy of normal women.

MATERIALS AND METHODS

From April 2004 to May 2010, 33 patients (mean age 34 ± 3. 4 years, range 20–60) underwent MtF sex reassignment surgery at our department, which was performed by a single surgeon. All the patients had been taking estrogen/progestin hormones for at least 12 months. This treatment was suspended 1 month before surgery. Before the surgical procedure, all patients were living as women, and all had obtained legal permission for surgery. In the last 15 patients (mean age 27 ± 4.0 years, range 22–35), MR was performed as a part of the follow-up protocol in order to evaluate the final result of the surgical procedure, and the images of the patients were compared with those performed in 10 women (mean age 29.5 ± 4.1 years, range 25–35) who underwent MR for benign pathologies.

Surgical procedure

In MtF gender genital conversion, we use a surgical technique derived from Jones *et al.*[4] Briefly, the superior neovaginal wall is obtained from the penis skin whereas the inferior neovaginal wall is prepared from a flap of perineoscrotal skin. The bilateral orchidectomy is performed through the perineal–scrotal incision. The crura of the corpora cavernosa are excised,

[1]Department of Urology, University of Bologna, S. Orsola-Malpighi Hospital, Bologna, Italy; [2]Department of Andrology, Azienda Ospedaliero-Universitaria di Bologna, Bologna, Italy and [3]Department of Radiology, Azienda Ospedaliero-Universitaria di Bologna, Bologna, Italy. Correspondence: Dr F Colombo, Department of Urology, University of Bologna, S. Orsola-Malpighi Hospital, Palagi 9, Bologna 40134, Italy. E-mail: fulvio.colombo@aosp.bo.it or mark.borghesi@gmail.com
Received 26 January 2012; accepted 20 April 2012; published online 7 June 2012

preserving the penile dorsal arteries. The corpora cavernosa are longitudinally incised parallel to the urethra, as far as the detached crura. The preparation of the albuginea–neurovascular bundle complex, as previously described, was applied in the last 19 patients.[11] A space between the superior rectal wall and the bulbous–membranous urethra/posterior prostatic aspect is created by a blunt dissection. The superior and inferior neovaginal walls are sutured and fixed with four stitches to the periprostatic muscular tissues. The neoclitoris is sutured to the superior flap whereas the urethra is spatulated and sutured 1 cm below the neoclitoris. The labia minora and majora are created by appropriately trimming the residual lateral scrotal tissue and suturing it laterally to the perineal edge and medially to the neovagina. In our personal modification of the original surgical technique, the mons Veneris is created using the albuginea—neurovascular bundle which is folded-up, positioned and fixed with reabsorbable stitches under the pubic skin, in order to mimic the mons Veneris.

Magnetic resonance protocol

MR imaging was performed at least 6 months after surgery (mean time after surgery: 7.3 months, range 6–9) in a supine position in a 1.5-T superconductive MR unit (Milwaukee, WI, USA; GE Signa 1.5T, 8-channel Body) using a body coil (Figures 1–3). No oral or intravenous contrast agent was administered. Images were acquired from the sagittal, coronal and axial planes with spin-echo T1- and turbo spin-echo T2-weighted sequences. T2-weighted sequences were preferred because of better contrast between different anatomical structures (repetition time (ms)/echo time (ms): 5200/107; section thickness: 5 mm; gap: 0.7 mm; number of signal acquired: 3; flip angle: 90°; matrix: 512 × 512). In all patients, the MR examination was performed both with and without a vaginal tutor. We evaluated the following postoperative radiological anthropometric parameters: (a) depth of the neovagina, (b) length of the inferior pelvic aperture (IPA), defined as the distance between the inferior margin of the symphysis and the apex of the coccyx in a sagittal plane, (c) length of inlet of pelvis (IOP), defined as the distance between the superior margin of the symphysis and the cape of sacrum, (d) angle between the neovaginal axis and IPA axis, (e) thickness of the mons Veneris, considering the perpendicular axis to the middle part of the symphysis, (f) thickness of the rectovaginal septum measured in the middle part of the neovagina and (g) remnants of the crura of corpora cavernosa (Figure 2). We also evaluated the same radiological parameters in ten healthy women undergoing MR for benign diseases and the data were compared. The study was performed in accordance with the Helsinki declaration and national regulations. All patients provided informed consent for anonymous publication of data. The means, ranges and s.d. were used as descriptive statistics and the *t*-test for the comparison of the means.

RESULTS

In patients who underwent sex reassignment surgery, the mean neovaginal depth was slightly superior than in women (9.3 ± 1.4 cm, range 7.2–12.0 vs 7.9 ± 0.8 cm, range 6.2–9.1; $P = 0.009$) (Tables 1 and 2). Considering the length of the IPA, in patients who underwent MtF sex reassignment surgery, the mean value was 8.6 ± 1.4 cm (5.8–11.2), whereas in control group it was 10.5 ± 1.2 cm (range: 9.0–12.7, $P = 0.007$). In transsexual patients the mean length of the inlet of pelvis was 10.5 ± 0.9 cm (range: 9.0–12.0); in women it was 12.5 ± 1.4 cm (range: 10.4–14.5, $P < 0.001$). The inclination between the axis of the neovagina and the IPA axis was fairly comparable between the two study groups but the *P*-value was statistically significant (the mean value in patients examined was 54° ± 11°, range 30°–70°, whereas the female vagina inclination was 40° ± 3°, range 34°–44°, $P < 0.001$). The mean value of the thickness of the mons Veneris in transsexual patients was similar (3.4 ± 0.8 cm, range 2.0–4.7) to the mean value in the control group (3.7 ± 0.7 cm, range: 2.7–5.0, $P = 0.345$). The thickness of the rectovaginal septum was similar in both groups: the mean value was 3.0 ± 0.8 mm (range 2.5–5.1) in patients who underwent sex reassignment surgery and 3.2 ± 0.4 mm (range 2.5–4.0) in women ($P = 0.473$). Finally, there was no radiological evidence of remnants of erectile tissue in the 15 patients.

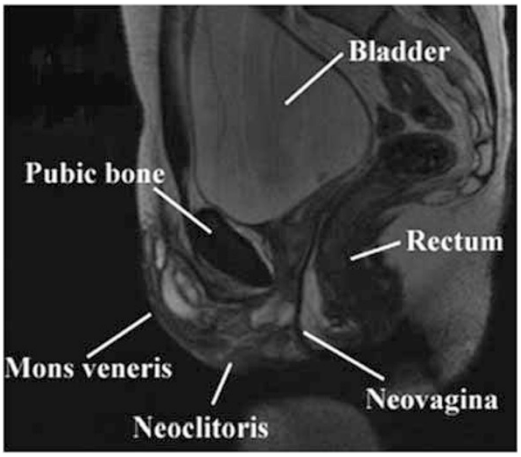

Figure 1. Sagittal magnetic resonance (MR) image of a patient who underwent male to female sex reassignment surgery showing the new structures of the pelvis without the vaginal tutor.

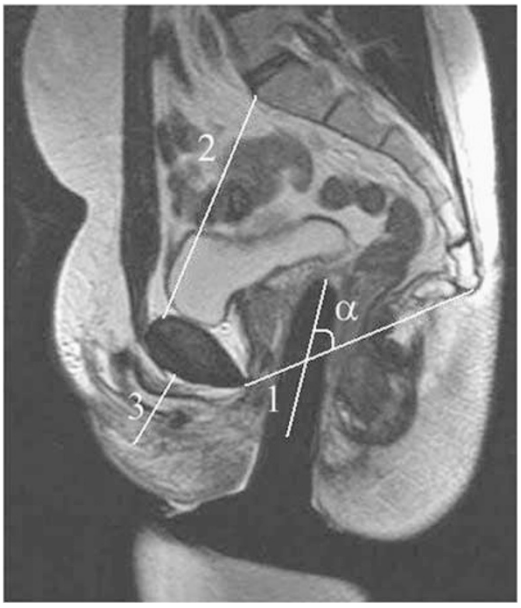

Figure 2. Sagittal magnetic resonance (MR) image of a patient who underwent male to female sex reassignment surgery with the vaginal tutor showing the length of the neovagina of the inferior pelvic aperture (1), the length of the inlet of pelvis. (2), the angle between the neovagina axis and inferior pelvic axis and the thickness of the mons Veneris (3).

DISCUSSION

In MtF sex reassignment surgery, the configuration of a neovagina of adequate depth and inclination is one of the main goals of the procedure and it is mandatory in achieving satisfying sexual intercourse. An adequate length of the neovagina is also important for psychological reasons because patients wish to have genitalia as similar as possible to those of women. MR is the best imaging technique to evaluate pelvis anatomy.[15] In all patients the radiological images were obtained with the use of a

© 2012 Macmillan Publishers Limited

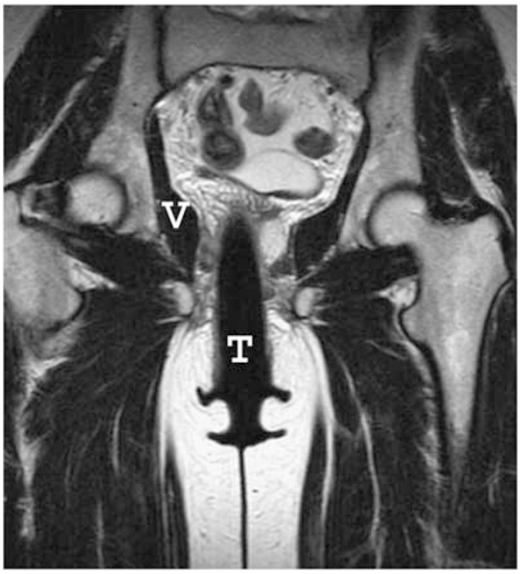

Figure 3. Coronal magnetic resonance (MR) image of a patient who underwent male to female sex reassignment surgery (T: tutor, V: right seminal vescicle).

silicon neovaginal tutor because this may help to better evaluate the length of the neovagina. In patients of our series undergoing MR, the mean length of the neovagina was 9.3 cm, which may be considered a good result, considering the length of the female vagina (average 8 cm). In order to obtain a neovagina of this length, it is necessary to perform a wide dissection of the rectoprostatic space as far as the peritoneal reflection of the Douglas pouch; furthermore this depth is guaranteed by the constant use of the tutor: if the tutor is not used, there will be neovaginal atrophy with a reduction of length and depth, requiring second surgery. This complication occurred in two patients: in one of them, we performed a secondary ileal vaginoplasty.

A physiological inclination of the neovagina is essential to permit satisfying sexual intercourse. In this series, the angle between the neovagina and the anteroposterior axis of the IPA was on average 54°, which is slightly greater than the angle in women (40 degrees). In order to obtain a correct inclination of the neovagina, it is essential to perform a blunt dissection of the rectoprostatic space as close as possible to the rectum. As expected, the length of the IPA and of the inlet of pelvis was higher in women than in the patients. The thickness of the rectovaginal septum of our patients was comparable to the thickness in women and seems adequate to obtain a more trophic rectovaginal space. Finally, there was no evidence in our patients of remnants of erectile tissue: the complete resection of erectile

Table 1. Values of radiological parameters in patients who underwent male to female sex reassignment surgery

Patients	*Depth of the neovagina (cm)*	*Inferior pelvic aperture (cm)*	*Inlet of pelvis (cm)*	*Angle between neovagina axis and inferior pelvic axis (grade)*	*Thickness of mons Veneris (cm)*	*Thickness of rectovaginal septum (mm)*
1	8.0	9.3	12.0	53	2.7	2.5
2	10.3	9.0	9.0	45	4.7	2.7
3	8.1	9.8	11.0	60	2.8	2.5
4	9.5	8.5	10.0	70	3.7	3.0
5	8.1	5.8	9.6	60	2.3	2.5
6	7.2	7.6	9.4	67	2.0	2.5
7	8.6	9.0	11.0	51	4.0	4.0
8	12.0	9.4	11.0	30	4.1	2.5
9	11.0	11.2	11.5	54	3.8	5.1
10	9.4	9.0	10.4	54	3.8	3.0
11	10.8	9.3	9.4	60	3.0	2.5
12	11.1	10.0	9.0	65	2.8	2.8
13	8.3	9.1	10.5	48	4.0	3.1
14	9.5	10.5	9.0	55	3.2	2.7
15	8.5	9.0	10.2	40	3.5	2.7
Mean value	9.3	8.9	10.5	54	3.4	2.9

Table 2. Values of radiological parameters in women who underwent magnetic resonance of the pelvis for benign pathology

Patients	*Depth of the neovagina (cm)*	*Inferior pelvic aperture (cm)*	*Inlet of pelvis (cm)*	*Angle between neovagina axis and inferior pelvic axis (grade)*	*Thickness of mons Veneris (cm)*	*Thickness of rectovaginal septum (mm)*
1	8.3	10.0	12.1	44	2.7	3.0
2	8.1	9.9	14.2	44	3.6	3.6
3	9.1	10.6	11.7	34	2.9	3.5
4	8.6	9.6	12.0	38	4.1	2.5
5	6.2	10.3	10.4	40	5.0	3.0
6	7.6	12.7	10.4	41	3.9	4.0
7	7.2	12.5	12.5	36	4.0	3.1
8	8.0	10.0	13.2	40	3.0	3.6
9	8.2	9.0	13.7	42	4.3	3.0
10	8.1	11.0	14.5	41	3.5	3.4
Mean value	7.9	10.5	12.5	40	3.7	3.2

© 2012 Macmillan Publishers Limited

tissue is essential during this operation because remnants of the corpora cavernosa may lead to stenosis of the neovagina and unpleasant sensations during sexual intercourse.

In our opinion, MR evaluation allows a detailed assessment of the new pelvic anatomy after MtF sex reassignment surgery and represents important feedback for the surgeon. The anthropometric parameters measured in our patients were comparable to the control group with a satisfactory length of the neovagina and a physiological appearance of the mons Veneris. Our personal modifications seem to offer our patients optimal results in terms of new anatomy, which is the basis for satisfaction during sexual intercourse.

CONFLICT OF INTEREST

The authors declare no conflict of interest.

REFERENCES

1 Benjamin H. Transvestism and transsexualism. *Int J Sexol* 1953; **7**: 12–14.
2 Hamburger C, Sturup GK, Dahl-Iversen E. Transvestism: hormonal, psychiatric, and surgical treatment. *JAMA* 1953; **12**: 391–396.
3 Laub DR, Fisk N. A rehabilitation program for gender dysphoria syndrome by surgical sex change. *Plast Reconst Surg* 1974; **53**: 388–403.
4 Jones HW, Schirmer HK, Hoopes JE. A sex conversion operation for males with transsexualism. *Am J Obstet Gynecol* 1968; **100**: 101–109.
5 Pandya NJ, Stuteville OH. A one stage technique for constructing female external genitalia in male transsexuals. *Br J Plast Surg* 1973; **26**: 277–282.
6 Malloy TR, Noone RB, Morgan AJ. Experience with the one-stage surgical approach for constructing female genitalia in male transsexuals. *J Urol* 1976; **116**: 335–337.
7 Perovic S. Male to female surgery: a new contribution to operative technique. *Plast Recostr Surg* 1993; **91**: 703–712.
8 Hinderer UT. La cirurgía plàstica en el tratamiento del intersexo. In: JPM Pallardo (ed.). *Jornadas de Endocrinologia Infantil*. Liade: Madrid, 1974.
9 Hinderer UT. Aesthetic plastic correction of incomplete testicular feminization. *Aesthetic Plast Surg* 1979; **3**: 201–217.
10 Hinderer UT. Reconstruction of the external genitalia in the adrenogenital syndrome by means of a personal one stage procedure. *Plast Reconstr Surg* 1989; **84**: 325–337.
11 Soli M, Brunocilla E, Bertaccini A, Palmieri F, Barbieri B, Martorana G. Male to female gender reassignment: modified surgical technique for creating the neoclitoris and mons veneris. *J Sex Med* 2008; **5**: 210–216.
12 Eldh J, Berg A, Gustafsson M. Long-term follow up after sex reassignment surgery. *Scand J Plast Reconstr Surg Hand Surg* 1997; **31**: 39–45.
13 Cova M, Mosconi E, Liguori G, Bucci S, Trombetta C, Belgrano E *et al.* Value of magnetic resonance imaging in the evaluation of sex-reassignment surgery in male-to-female transsexuals. *Abdom Imaging* 2003; **28**: 728–732.
14 Trombetta C, Liguori G, Bucci S, Salame L, Garaffa G, Cova M *et al.* Radiological evaluation of vaginal width and depth in male-to-female transsexuals by the use of magnetic resonance imaging. *World J Urol* 2004; **22**: 405–408.
15 Togashi K, Nakasi A, Sugimura K. Anatomy and physiology of the female pelvis. MR imaging revisited. *J Magn Reson Imaging* 2001; **13**: 842–849.

© 2012 Macmillan Publishers Limited