Journal of Cranio-Maxillo-Facial Surgery (2010) **38**, 494–500
© 2010 European Association for Cranio-Maxillo-Facial Surgery
doi:10.1016/j.jcms.2010.02.001, available online at http://www.sciencedirect.com

CT measurement of the frontal sinus – Gender differences and implications for frontal cranioplasty

Matthew K. LEE, MD[1], Osamu SAKAI, MD, PhD[2], Jeffrey H. SPIEGEL, MD, FACS[1]

[1] *Department of Otolaryngology – Head and Neck Surgery, Boston University School of Medicine, United States;*
[2] *Department of Radiology, Boston University School of Medicine, United States*

SUMMARY. Objective: **To describe frontal sinus anatomy and explore gender variations that may have significance for cranioplasty and sinus surgery.** Methods: **150 subjects who underwent maxillofacial computed tomography (CT) between 1/1/2008 and 6/11/2008 were enrolled. Frontal sinus dimensions and forehead measurements were taken at midline and at 10, 20, and 30 mm to the left and right of midline using sagittal, coronal, and axial images. The data was analyzed for significant differences between measurements made at the selected points in the frontal sinus, for left to right variations, and for gender variations.** Results: **Mean anterior table thickness ranged from 2.6 to 4.1 mm and was thinnest at 10 mm left and right of midline (2.9 and 2.6 mm). Mean anteroposterior depth of the frontal sinus ranged from 8.0 to 9.3 mm and did not vary significantly at any distance from midline. Frontal sinus height was greatest at midline (mean = 24.5 mm) and progressively lessened at lateral distances. Mean total width at the level of the supraorbital ridge was 52.2 mm. For all measurements, no significant left to right variation was noted. Comparing the sexes, males were found to have greater dimensions in most frontal sinus measurements, though these differences were only found to be significant at or close to midline. The male forehead was marked by more acute nasofrontal angle (119.9° versus 133.5°) and a steeper posterior forehead inclination (−7.2° versus −3.5°). The glabella was wider in males (44.4 versus 33.9 mm) and more frequently protruded beyond the ideal forehead slope line (51% versus 30%).** Conclusions: **Using CT imaging, forehead and frontal sinus dimensions have been described. Generally, males had larger overall frontal sinus dimensions, and this was most pronounced in the medial area of the supraorbital ridge known as the glabella.** © 2010 European Association for Cranio-Maxillo-Facial Surgery

Keywords: **frontal sinus, anatomy, gender variations, cranioplasty, facial feminization, forehead, dimensions**

INTRODUCTION

Surgery in and around the frontal sinus is utilized for a variety of indications including trauma, neoplasm, and sinusitis (*Kuhn*, 2006; *Tadros* and *Costantino*, 2008). Due to its position embedded within the frontal bone, it may also be necessary to open the frontal sinus as part of access to the anterior cranial fossa and skull base. The resulting involvement/penetration of the frontal sinus may potentially lead to adverse post-operative sequelae including cerebrospinal fluid (CSF) fistula formation, bone-flap infections, meningitis, and brain abscesses (*Zöller* et al., 2001; *Pondé* et al., 2003; *Kinnunen* and *Aitasalo*, 2006). As such, knowledge of frontal sinus anatomy is crucial to the success of these and other related procedures.

Another important indication for forehead/frontal sinus surgery is for aesthetic purposes. As an example, pneumosinus dilatans, a rare craniofacial malformation marked by enlargement of the paranasal sinuses, often presents with primarily cosmetic complaints (*Dempf* et al., 2005). In such patients, selective reduction of the frontal sinus may be desirable in order to address the exaggerating frontal bossing which accompanies this condition. In addition, alteration in the appearance of the frontal bone/anterior skull may be sought by patients seeking to reduce undesired facial masculinity. Transsexualism, a condition marked by a strong and persistent cross-gender identification, is commonly and understandably accompanied by the desire to have one's physical appearance congruous with their experienced gender-identity (*Becking* et al., 1996; *Sohn* and *Bosinski*, 2007). Frontal cranioplasty may be extremely useful in the care of the transsexual patient as an important element of gender confirming surgery as one of many procedures encompassed in facial feminization surgery (FFS). FFS is the general term for a group of specific procedures utilized to alter the perceived gender of an individual's face (*Spiegel*, 2008).

Regardless of the indication for bony surgery of the frontal bones/anterior skull, knowledge of the anatomy of the frontal sinus is essential in best preparing the surgeon to achieve the desired goal without precipitating untoward events (*Caroli* et al., 2004). Until recently, our understanding of gender variations in craniofacial anatomy has been chiefly built upon anthropometric studies, which typically employ facial surface measurements or plain film radiography (*Farkas* and *Kolar*, 1987; *Hurst* et al., 2007). However, a common limitation to these studies is the inability to describe in detail the three

dimensional anatomy of the frontal sinus and its anatomical relationship to the forehead.

With modern technological advances in computed tomography (CT) imaging, studies have utilized this imaging modality with increasing frequency to describe forehead and frontal sinus anatomy. A number of studies have reported data of frontal sinus dimensions using measurements obtained from axial CT images (*Spaeth* et al., 1997; *Pondé* et al., 2003). *Sánchez Fernández* et al. (2000) and more recently, *Tatlisumak* et al. (2008) have conducted similar studies, but reported measurements obtained from CT images in both the axial and coronal planes. The results of these and other relevant anatomical studies are summarized in Table 1.

The goal of this study was to confirm and to expand upon the existing base of knowledge. Using CT imaging, this study reports upon the measurements of the forehead and frontal sinus in the axial, coronal, and sagittal planes, at discrete points throughout the sinus. The data compiled in this study allows for the creation of a comprehensive "map" of frontal sinus dimensions, as well as provide measurements relevant to forehead/frontal sinus surgery which have, to these authors' knowledge, not been reported in the current body of literature. Importantly, we evaluated the thickness of the frontal sinus anterior table bone. This data may be useful in predicting fracture patterns, area of dehiscence in inflammatory disorders, and is valuable in predicting areas of thin bone when contouring the frontal sinus, such as for feminizing cranioplasty.

METHODS

Patient selection

This is a computer-assisted anatomical measurement study utilizing existing maxillofacial CT studies performed at our institution. Consecutive one hundred male and fifty female (a total of 150 patients) who underwent maxillofacial CT between the dates of 1/1/2008 and 6/11/2008 were enrolled in this study. The exclusion criteria included bilateral absence of the frontal sinus, a history of prior frontal sinus surgery, current or prior facial skeletal fracture, and congenital or acquired craniofacial skeletal abnormality as indicated by medical records or by the imaging study itself, patients less than 18 years old, and inadequate technical quality to accurately make all required measurements. The anatomical measurements described below were performed, and the data recorded and analyzed both for the entire sample population and between gender groups. This research protocol was reviewed and approved by our institutional review board.

Anatomical measurements

All CT studies were performed by 64 multidetector-row CTs (Lightspeed VCT, GE Medical Systems, Milwaukee, WI). Contiguous axial 1.25 mm thick slices were obtained through the maxillofacial bones, and images were reconstructed with soft tissue and bone reconstruction algorithms and 1.5 mm thick coronal and sagittal reformatted images were obtained per our institutional protocol. All CT measurements were made on bone algorithm reconstructed and bone windowed images using an independent workstation (GE Advantage Windows, GE Medical Systems, Milwaukee, WI).

Initially, horizontal and vertical references planes were defined for the purposes of obtaining angular forehead measurements. This is demonstrated in Fig. 1. The floor of the anterior skull base was defined as the horizontal reference plane (Line H), and its perpendicular defined as the vertical reference plane (Line V). Three additional reference lines were also defined at true midline using the sagittal view:

- Line A: From the nasion (Point N) to the point immediately superior to the supraorbital ridge, at the junction where supraorbital bossing ends and the softer curvature of the forehead begins.
- Line B: From the nasion (Point N) to the most anterior point of the supraorbital ridge.

Table 1 – Literature review

Authors	Imaging method	Measurement parameter	Results	
			Males	Females
Tatlisumak et al. (2008)	CT	AP depth of right sinus	11.66 ± 4.09 mm	10.15 ± 4.08 mm
		AP depth of left sinus	13.15 ± 5.23 mm	10.80 ± 4.10 mm
		Height of right sinus	26.57 ± 8.74 mm	23.63 ± 8.33 mm
		Height of left sinus	28.24 ± 9.13 mm	24.70 ± 8.20 mm
		Width of right sinus	27.05 ± 7.86 mm	24.37 ± 7.63 mm
		Width of left sinus	28.47 ± 8.13 mm	26.05 ± 7.40 mm
Pondé et al. (2003)	CT	AP depth of sinus	12.01 ± 3.07 mm	10.16 ± 2.12 mm
		Height of sinus	31.72 ± 6.47 mm	28.57 ± 7.36 mm
		Width of combined sinuses	56.53 ± 13.43 mm	51.05 ± 17.14 mm
Sánchez Fernández et al. (2000)	CT	AP depth of sinus	13 ± 5 mm (both males and females)	
		Width of single sinus	18 ± 7 mm (both males and females)	
Spaeth et al. (1997)	CT	AP depth of sinus	17.38 ± 5.17 mm	16.11 ± 5.83 mm
		Width of single sinus	27.98 ± 7.11 mm	26.39 ± 6.70 mm
Harris et al. (1987)	XR	Height of sinus	30.1 mm (mean)	26.0 mm (mean)
		Width of combined sinuses	58.3 mm (mean)	46.9 mm (mean)

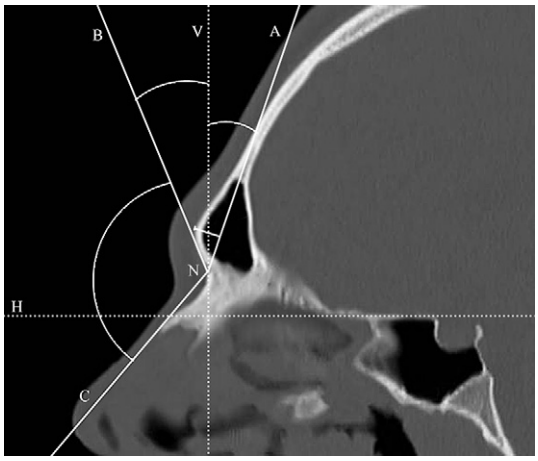

Fig. 1 – Illustration of measurements made in the mid-sagittal plane. *Line A*: ideal slope, *Line B*: actual slope, *Line C*: nasal slope, *Line H (dotted line)*: horizontal reference plane, *Line V (dotted line)*: vertical reference plane, *Point N*: nasion, *Angle ANV*: angle of inclination of ideal forehead slope, *Angle BNV*: angle of inclination of actual forehead slope, *Angle ANB*: angle of deviation of actual from ideal forehead slope, *Angle BNC*: nasofrontal angle. Also shown in the figure is the measured distance of brow ridge protrusion beyond the ideal forehead slope line.

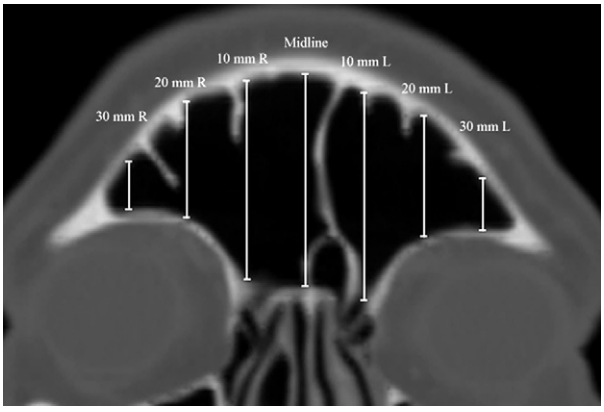

Fig. 2 – Illustration of measurements made in the coronal plane. Vertical height of the frontal sinus is measured at midline and at 10, 20, and 30 mm to the right and left of midline.

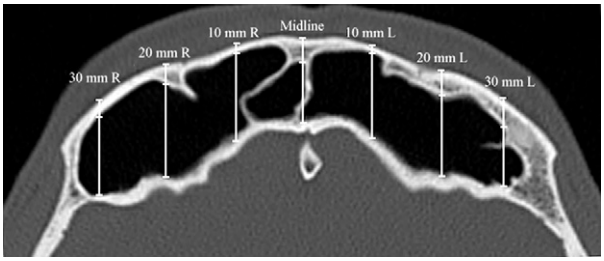

Fig. 3 – Illustration of measurements made in the axial plane, taken at the most prominent level of the supraorbital ridge. Both the AP depth of the frontal sinus and the thickness of the anterior table were measured at midline and at 10, 20, and 30 mm to the left and right of midline.

- Line C: From the nasion (Point N) to the most anterior/inferior point of the nasal bone.

Line A represents the slope of the forehead that would exist if glabellar protrusion was subtle or absent. We refer to this as the "ideal" forehead inclination achieved in facial feminization, and its value is measured as the angle (ANV) formed between Line A and vertical reference plane, Line V. The position for Line A is to a degree subjective, but largely limited from variance by the position of the nasal bones and the position of the anterior most part of the frontal lobes of the brain. Line B represents the actual slope of the forehead, and its inclination is measured as the angle (BNV) formed between Line B and the vertical reference plane, Line V. Line C represents the nasal slope, and the nasofrontal angle was therefore defined as the angle BNC formed between Line B and Line C.

The angular deviation between the actual and ideal inclinations of the forehead (ANB) was measured. This angle represents the amount of correction ideally achieved in feminization cranioplasty. To quantify the likelihood by which frontal sinus involvement may be necessitated during feminization cranioplasty, frequency of frontal sinus protrusion beyond the ideal slope line (Line A) was documented. This represents those individuals in whom the brow ridge is largely caused by frontal sinus airspace rather than by thick frontal bone.

In the coronal view, the height of the frontal sinus was measured at midline and at 10 mm, 20 mm, and 30 mm to the right and left of midline (see Fig. 2). In the axial view, the thickness of the frontal sinus anterior table and the anteroposterior (AP) depth of the sinus were measured at the most protuberant level of the supraorbital ridge (see Fig. 3). These measurements were also made at midline and at 10 mm, 20 mm, and 30 mm to the left and right of midline. The total width of the supraorbital ridge and frontal sinus was documented (Fig. 4), as well as sinus width to either side of midline to assess for left to right variation. Lastly, the width of the glabella, which was determined as a midline area of protrusion beyond the natural arc of the forehead, was measured also at the most prominent level of the supraorbital ridge (Fig. 4).

Statistical analysis

For continuous variables, Student's *t* test analysis was used. Anatomical measurements were analyzed for significant differences between measurements made at the various points in the frontal sinus, for left to right variations, and for gender variations. Fisher's exact test was used to assess for gender difference in the frequency of frontal sinus protrusion past the ideal slope line.

RESULTS

Total sample population

The average age for the total sample population was 40.1 years (range 18–90 years). There was no statistically significant left to right asymmetry noted for any of the measurements made. Mean anterior table thickness ranged

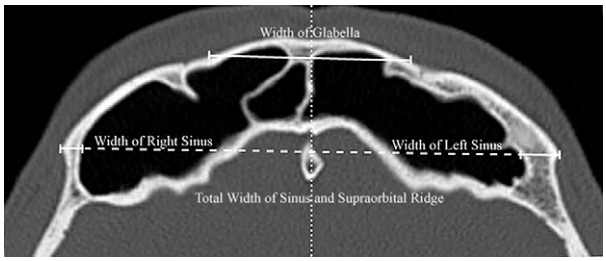

Fig. 4 – Additional measurements made in the axial plane, taken at the most prominent level of the supraorbital ridge. The vertical dotted line represents midline. The total width of the supraorbital ridge is shown measured here, with the inner dashed line representing the width of the frontal sinus alone. Also measured is the width of the glabella, seen as an area of protrusion of the brow ridge beyond the natural arc of the forehead.

Table 2 – Measurements in total sample population

Measurement parameter	*n*	Mean ± 1 SD
Anterior table thickness		
Midline	143	3.5 ± 1.7
10 mm Left of midline	146	2.9 ± 1.6
10 mm Right of midline	142	2.6 ± 1.2
20 mm Left of midline	120	3.5 ± 1.8
20 mm Right of midline	118	3.3 ± 1.5
30 mm Left of midline	50	4.1 ± 2.1
30 mm Right of midline	44	3.6 ± 1.8
AP depth of sinus		
Midline	143	9.1 ± 3.0
10 mm Left of midline	146	9.3 ± 3.1
10 mm Right of midline	142	9.1 ± 3.0
20 mm Left of midline	120	8.7 ± 3.4
20 mm Right of midline	118	9.1 ± 3.8
30 mm Left of midline	50	8.8 ± 3.8
30 mm Right of midline	44	8.0 ± 3.6
Height of sinus		
Midline	143	24.5 ± 9.7
10 mm Left of midline	145	20.9 ± 8.1
10 mm Right of midline	142	21.8 ± 8.9
20 mm Left of midline	118	12.1 ± 5.6
20 mm Right of midline	118	13.6 ± 6.4
30 mm Left of midline	49	9.4 ± 5.3
30 mm Right of midline	44	10.3 ± 5.7
Width of sinus		
Width to left of midline	149	26.4 ± 7.8
Width to right of midline	148	26.3 ± 7.9
Total width	150	52.2 ± 15.1
Width of supraorbital ridge	150	99.4 ± 5.1
Width of glabella	148	41.0 ± 12.2

Summary of anatomical measurement data taken from all subjects included in this study. Though there were 150 subjects in total, individual variations in anatomy did not allow for all measurements to be made in each subject. The number of frontal sinuses for which each measurement could be obtained is noted in the *n* column, with the mean value ± 1 standard deviation shown.

from 2.6 to 4.1 mm and was found to be thinnest at 10 mm to left and right of midline (2.9 and 2.6 mm). This difference was statistically significant when compared to both midline and to measurements made 20 and 30 mm to the left and right of midline. AP depth measurements were relatively consistent (range 8.0 – 9.3 mm) and were not found to vary significantly from each other at any distance from midline. Height of the frontal sinus was greatest at midline (24.5 mm) and progressively decreased at lateral distances. The height at midline was found to be significantly greater when compared to the height at any distance to the left or right of midline. The data for the sample population as a whole is summarized in Table 2.

Unilateral absence of frontal sinus was present in three cases, all male. The sinus was absent on the right side in two cases and on the left in one. In seven patients, the frontal sinus was not present at midline. In four cases, this was secondary to obliteration of the frontal sinus at midline due to a large bony septum. The remaining three cases were secondary to unilateral localization of the frontal sinus.

Comparison of measurements by gender

The "ideal forehead inclination" for males was −7.2° versus −3.5° for females, indicating a more posteriorly sloping forehead above the level of the supraorbital ridge. Deviation of the actual inclination from ideal inclination (20.9° versus 10.2°), and distance from the ideal slope line to supraorbital ridge (4.0 mm versus 2.2 mm) were also greater in males indicating a more protuberant supraorbital ridge and glabella. The frontal sinus protruded beyond the ideal slope line in 51% of males and 30% of females. The nasofrontal angle was more acute in males, 119.9° compared to 133.5° in females. Males also possessed a wider overall width of the supraorbital ridge (100.5 mm) as well as a wider glabella (44.4 mm, as compared to 33.9 mm in women). All of these gender differences were statistically significant at $\alpha = 0.05$.

The mean measurements of anterior table thickness and AP depth at midline and at any distance from midline were generally found to be greater in males. However, these gender differences were only found to be significant at midline or at 10 or 20 mm to the left or right of midline. Frontal sinus dimensions at 30 mm from midline were not statistically significant for gender differences in any of the measurements made. In vertical height of the frontal sinus, gender variations were only noted at 10 mm to the left and to the right of midline (smaller in females). There were no significant differences in sinus height at any other position. Total width of the frontal sinus as well as width to either side of midline also did not vary between genders. Gender variations in anatomical measurements are summarized in the data in Table 3.

DISCUSSION

The frontal sinuses are a pair of triangularly shaped, air-filled chambers lined by mucoperiosteum and located between the inner and outer tables of the frontal bone. Typically asymmetrical and irregularly shaped with numerous incomplete septae, the frontal sinuses are marked by an intricate anatomical architecture. In point of fact, the frontal sinuses possess such complex and variable anatomy that they have been utilized for the purposes of forensic identification of unknown deceased persons (*Nambiar* et al., 1999). In Table 1, we have highlighted

Table 3 – Measurements of gender variation

Measurement parameter	*n*	Male	*n*	Female	*p*
		Mean ± 1 SD		Mean ± 1 SD	
Ideal forehead inclination	100	−7.2° ± 4.6°	50	−3.5° ± 3.9°	<0.05
Deviation of actual from ideal inclination	100	20.9° ± 7.3°	50	10.2° ± 4.4°	<0.05
Nasofrontal angle	100	119.9° ± 11.8°	50	133.5° ± 10.1°	<0.05
Frequency of frontal sinus protrusion beyond "ideal" forehead slope	100	51/100	50	15/50	<0.05
Protrusion of glabella beyond ideal forehead slope	100	4.0 ± 1.7 mm	50	2.2 ± 1.0 mm	<0.05
		Mean ± 1 SD (mm)		Mean ± 1 SD (mm)	
Anterior table thickness					
Midline	94	3.9 ± 1.9	49	2.9 ± 1.1	<0.05
10 mm Left of midline	98	3.1 ± 1.8	48	2.5 ± 1.1	<0.05
10 mm Right of midline	95	2.8 ± 1.3	47	2.3 ± 0.8	<0.05
20 mm Left of midline	82	3.8 ± 1.9	38	3.0 ± 1.2	<0.05
20 mm Right of midline	81	3.4 ± 1.5	37	2.9 ± 1.3	NS ($p = 0.059$)
30 mm Left of midline	38	4.2 ± 2.1	13	3.8 ± 1.9	NS
30 mm Right of midline	29	3.4 ± 1.9	15	3.9 ± 1.7	NS
AP depth of sinus					
Midline	95	9.7 ± 3.1	49	7.9 ± 2.4	<0.05
10 mm Left of midline	98	10.1 ± 3.1	48	7.6 ± 2.3	<0.05
10 mm Right of midline	95	9.9 ± 2.9	47	7.4 ± 2.5	<0.05
20 mm Left of midline	82	9.2 ± 3.5	38	7.7 ± 2.8	<0.05
20 mm Right of midline	81	9.4 ± 3.7	37	8.4 ± 3.8	NS
30 mm Left of midline	38	9.0 ± 4.2	13	8.1 ± 2.4	NS
30 mm Right of midline	29	8.5 ± 4.1	15	7.1 ± 2.1	NS
Height of sinus					
Midline	94	24.7 ± 9.8	49	24.2 ± 9.5	NS
10 mm Left of midline	97	21.9 ± 7.7	48	19.0 ± 8.7	<0.05
10 mm Right of midline	95	23.1 ± 8.9	47	19.0 ± 8.1	<0.05
20 mm Left of midline	80	12.6 ± 5.9	39	11.1 ± 4.9	NS
20 mm Right of midline	81	14.4 ± 6.6	37	12.0 ± 5.5	NS
30 mm Left of midline	38	9.5 ± 5.7	13	9.2 ± 4.1	NS
30 mm Right of midline	29	11.5 ± 6.1	15	8.0 ± 4.2	NS
Width of sinus					
Width to left of midline	99	27.2 ± 7.8	50	25.0 ± 7.7	NS
Width to right of midline	98	26.8 ± 7.9	50	25.4 ± 8.0	NS
Total width	100	53.2 ± 15.4	50	50.4 ± 14.5	NS
Width of supraorbital ridge	100	100.5 ± 4.7	50	97.1 ± 5.1	<0.05
Width of glabella	100	44.4 ± 12.1	48	33.9 ± 8.9	<0.05

Summary of anatomical measurement data taken from each gender group. Measurements were analyzed for significant gender variations using Student's *t* test analysis (for continuous variables) and Fisher's exact test (categorical variables). Differences with a *p-value* <0.05 were considered significant.

a number of existing studies which have provided anatomical measurements of the frontal sinus through a variety of imaging methods (*Harris* et al., 1987; *Spaeth* et al., 1997; *Sánchez Fernández* et al., 2000; *Pondé* et al., 2003; *Tatlisumak* et al., 2008). Previous studies that have utilized plain film radiography for some or all of their anatomical measurements have the common limitation of overlaying the complex three dimensional anatomy of the frontal sinuses onto two dimensional film. For instance, using lateral skull radiographs to measure sinus height provides only a single measurement for a dimension that in fact fluctuates throughout the triangularly shaped sinus.

The goal of the current study is to expand upon this knowledge base and more accurately describe the complex anatomical structure of the frontal sinus. Studies in the available literature have either obtained a single measurement for both frontal sinuses (*Spaeth* et al., 1997; *Sánchez Fernández* et al., 2000; *Pondé* et al., 2003) or a single measurement for each side of the sinus (*Tatlisumak* et al., 2008). It was our intent to achieve a higher resolution of data by utilizing multiplanar CT images to obtain multiple measurements at discrete points throughout the sinus, i.e. at midline and at set distances to the left and right of midline. This methodology allows us more accurately detail the sinus by creating a normative, anatomical "map" of frontal sinus dimensions. By delineating the extent of the frontal sinus, we have compiled a data table which may serve as a referential guide for surgeons operating around this anatomical region. This may prove particularly useful whenever pre-operative imaging is unavailable or when it is ideal for frontal sinus involvement to be avoided during the procedure due to potential complications. The latter situation not uncommonly arises when attempting to gain access to the anterior cranial fossa and skull base from a frontal approach, as during the raising of an osteoplastic flap in anterior craniofacial resections for tumor. Additionally, the forehead and frontal sinus dimensions outlined in this study may prove particularly useful for

surgeons performing contouring of the frontal bone, as the relationship of the frontal sinus to the forehead directly effects surgical decision making.

Implications for feminization cranioplasty

Anthropometric studies have helped to delineate gender variations in facial skeletal anatomy, and these findings have been utilized as a guide in feminization cranioplasty and forehead reconstruction (*Ousterhout*, 1987). These gender-identifying characteristics have typically been documented in studies employing surface measurements and/or radiographic cephalometry. Many of the most prominent gender differences have been found to exist in the supraorbital and frontal cranial region of the facial skeleton. Generally, the forehead contour in females has been described to be more similar to the dimensions exhibited in the infantile cranium, a trait believed to be largely responsible for the more delicate, youthful, and innocent appearance favored by many women (*Hage* et al., 1997). Compared to men, women exhibit a more continuous and mild curvature of the forehead, with a less prominent supraorbital ridge and subtle to absent bossing of the forehead (*Ousterhout*, 1987). The nasofrontal angle is more acute and the glabella fuller and more protruding in males, a distinctly masculine trait precipitated by the development and pneumatization of the frontal sinuses (*Whitaker* et al., 1986). Additionally, the male forehead is typically flatter and marked by a steeper posterior inclination in contrast to the more vertical, softly arcing forehead in women (*Habal*, 1990; *Farkas*, 1994).

Many of these findings have been confirmed by the data produced in this study. The ideal inclination angle of the female forehead was found to be less posterior compared to males, confirming the more vertical positioning of the feminine forehead. The data also reinforces the well established finding of a more acute nasofrontal angle in males. Importantly, our study quantifies and supports the concept of a prominent glabella as a distinctively masculine trait. It is known that the female skull is on average 4/5th the size of the male (*Krogman*, 1979; *Hage* et al., 1997), and this is reflected in our study at the level of the forehead as a smaller overall width of the supraorbital ridge. However, it is interesting to note that despite this, the overall width and height of the frontal sinus was generally not greater in males compared to females (with the exception of height at 10 mm to the left and right of midline). Notably, statistically significant gender variations were only found at or close to midline, in the area identified as the glabella. Here, males clearly possessed a more prominent forehead features as measured by the greater thickness of the anterior table, deeper AP dimensions, and greater overall width of the glabella. Additionally, the glabella was discovered to be more anteriorly protruding in males. This was quantified by the frequency of sinus protrusion beyond the ideal forehead slope line, the greater total distance from this line to the most anterior point of the supraorbital ridge, and the more acute nasofrontal angle.

Whether as an element of FFS for male-to-female transsexuals or for females seeking to reduce masculine facial features, the goal in feminization cranioplasty is to bring the patient's facial dimensions into greater accord with those of the prototypical female. The specific procedures and techniques utilized to achieve this goal are dictated both by surgeon preference and by the forehead and frontal sinus anatomy of the patient (*Becking* et al., 2007; *Noureai* et al., 2007). If the supraorbital ridge and frontal bossing is less prominent, these areas may simply be reduced to more feminine dimensions by contouring the bone. The key limiting factor in this is the location of the frontal sinus, which can restrict the extent of frontal bone reduction and thus necessitate more extensive and invasive surgery. In these patients, it may be required that the frontal sinus be penetrated and the entire anterior sinus wall and associated supraorbital rim set back into its new, more feminine position (*Ousterhout*, 1987; *Dempf* et al., 2005).

In this study, we attempted to quantify the frequency in which surgical manipulation of the frontal sinus would be required in patients undergoing frontal cranioplasty. We estimated this by quantifying how often the frontal sinus extended anteriorly beyond the ideal forehead slope line. In these patients, complete correction of forehead inclination is not possible by reduction with a drill alone. This situation occurred in 51% of males and 30% of females, owing to the more prominent glabella in males and the subsequently greater forehead angle correction required to eliminate its anterior protrusion. From a practical standpoint, however, complete correction of forehead inclination may not always be required and thus these frequencies likely serve as an overestimate of the actual need for penetration of the frontal sinus in feminization cranioplasty. For subjects of both genders, it was found that particular care must be taken when reducing the supraorbital ridge at or near midline (10 mm to the right and left) due to the thinness of the anterior table in these areas. It is this thin area that may result in a dehiscence, or fenestra, into the frontal sinus if burring alone is done to contour the cranium. This technique is favored by some surgeons, but particularly 1 cm left and right of midline, there can be entry into the frontal sinus, with resultant contour irregularity, and potential increase in risk of sequelae should the patient develop a frontal sinusitis.

CONCLUSION

Using maxillofacial CT images in the axial, coronal, and sagittal planes, we report on anatomical measurements made at discrete points throughout the forehead and frontal sinus. Our measurements of forehead and frontal sinus dimensions may serve as a normative map of the surgical anatomy in this area. Specifically, this can be useful when the physician wishes to avoid opening of the sinus during surgical procedures involving the frontal bone. Additionally, gender variations in facial anatomy have been described. These gender variations demonstrate via CT the precise degree to which variation in frontal sinus anatomy exists between genders and the locations of

greatest variation. This information can be useful to surgeons who perform forehead cranioplasty for gender confirming facial surgery.

Overall, the most pronounced differences in forehead and frontal sinus anatomy were found at or near midline. This corresponds to the area of the supraorbital ridge known as the glabella and its underlying frontal sinus, which is much more prominent in males. It is important to take into account these differences in pre-operative planning for and during surgery, as the anatomical dimensions in this region make this the most likely area for frontal sinus penetration, particularly in men.

CONFLICT OF INTEREST

None.

ACKNOWLEDGEMENTS

None.

References

Becking AG, Tuinzing DB, Hage JJ, Gooren LJ: Facial corrections in male to female transsexuals: a preliminary report on 16 patients. J Oral Maxillofac Surg 54(4): 413−418, 1996 discussion 419

Becking AG, Tuinzing DB, Hage JJ, Gooren LJ: Transgender feminization of the facial skeleton. Clin Plast Surg 34(3): 557−564, 2007

Caroli E, Rocchi G, D'Andrea G, Delfini R: Management of the entered frontal sinus. Neurosurg Rev 27(4): 286−288, 2004

Dempf R, Wenzel U, Gundlach KK: Pneumosinus dilatans frontalis: two case reports. J Craniomaxillofac Surg 33(2): 130−134, 2005

Farkas LG, Kolar JC: Anthropometrics and art in the aesthetics of women's faces. Clin Plast Surg 14(4): 599−616, 1987

Farkas LG: Anthropometry of the attractive North American Caucasian face. In: Farkas LG (ed.), Anthropometry of the Head and Face, New York, NY: Raven Press, 159−179, 1994

Habal MB: Aesthetics of feminizing the male face by craniofacial contouring of the facial bones. Aesthetic Plast Surg 14(2): 143−150, 1990

Hage JJ, Becking AG, de Graaf FH, Tuinzing DB: Gender-confirming facial surgery: considerations on the masculinity and femininity of faces. Plast Reconstr Surg 99(7): 1799−1807, 1997

Harris AM, Wood RE, Nortjé CJ, Thomas CJ: The frontal sinus: forensic fingerprint? A pilot study. J Forensic Odontostomatol 5(1): 9−15, Jun 1987

Hurst CA, Eppley BL, Havlik RJ, Sadove AM: Surgical cephalometrics: applications and developments. Plast Reconstr Surg 120(6): 92e−104e, 2007

Kinnunen I, Aitasalo K: A review of 59 consecutive patients with lesions of the anterior cranial base operated on using the subcranial approach. J Craniomaxillofac Surg 34(7): 405−411, 2006

Krogman WM: Sexing skeletal remains. In: The Human Skeleton in Forensic Medicine. Springfield, Ill: Charles C. Thomas, 85, 1979

Kuhn FA: An integrated approach to frontal sinus surgery. Otolaryngol Clin North Am 39(3): 437−461, 2006 Review

Nambiar P, Naidu MD, Subramaniam K: Anatomical variability of the frontal sinuses and their application in forensic identification. Clin Anat 12(1): 16−19, 1999

Noureai SA, Randhawa P, Andrews PJ, Saleh HA: The role of nasal feminization rhinoplasty in male-to-female gender reassignment. Arch Facial Plast Surg 9(5): 318−320, 2007

Ousterhout DK: Feminization of the forehead: contour changing to improve female aesthetics. Plast Reconstr Surg 79(5): 701−713, 1987

Pondé JM, Metzger P, Amaral G, Machado M, Prandini M: Anatomic variations of the frontal sinus. Minim Invasive Neurosurg 46(1): 29−32, Feb 2003

Sánchez Fernández JM, Anta Escuredo JA, Sánchez Del Rey A, Santaolalla Montoya F: Morphometric study of the paranasal sinuses in normal and pathological conditions. Acta Otolaryngol 120(2): 273−278, 2000

Sohn M, Bosinski HA: Gender identity disorders: diagnostic and surgical aspects. J Sex Med 4(5): 1193−1207, 2007

Spaeth J, Krügelstein U, Schlöndorff G: The paranasal sinuses in CT-imaging: development from birth to age 25. Int J Pediatr Otorhinolaryngol 39(1): 25−40, 1997

Spiegel JH: Challenges in care of the transgender patient seeking facial feminization surgery. Facial Plast Surg Clin North Am 16(2): 233−238, 2008

Tadros M, Costantino PD: Advances in cranioplasty: a simplified algorithm to guide cranial reconstruction of acquired defects. Facial Plast Surg 24(1): 135−145, 2008

Tatlisumak E, Ovali GY, Asirdizer M, Aslan A, Ozyurt B, Bayindir P, Tarhan S: CT study on morphometry of frontal sinus. Clin Anat 21(4): 287−293, May 2008

Whitaker LA, Morales Jr L, Farkas LG: Aesthetic surgery of the supraorbital ridge and forehead structures. Plast Reconstr Surg 78(1): 23−32, 1986

Zöller JE, Mischkowski RA, Behr R, Ernestus RI, Speder B: The fronto-orbital osteotomy as plastic-reconstructive approach to the anterior and middle skull base. J Craniomaxillofac Surg 29(3): 159−164, 2001

Jeffrey H. SPIEGEL, MD, FACS
Chief, Facial Plastic and Reconstructive Surgery
Department of Otolaryngology − Head and Neck Surgery
Boston University School of Medicine
Boston
MA 02118
United States

Tel.: +1 (617) 414 5058
E-mail: jeffrey.spiegel@bmc.org

Paper received 24 November 2008
Accepted 5 February 2010