Journal of Plastic, Reconstructive & Aesthetic Surgery (2019) 72, 1694–1699

One-step facial feminization surgery: The importance of a custom-made preoperative planning and patient satisfaction assessment

Simone La Padula*, **Barbara Hersant, Harold Chatel, Paola Aguilar, Romain Bosc, Giovanni Roccaro, Robin Ruiz, Jean Paul Meningaud**

Department of Plastic, Reconstructive, Aesthetic and Maxillofacial Surgery, Henri Mondor Hospital, 51 avenue du Maréchal de Lattre de Tassigny, Créteil 94010, France

Received 2 January 2019; accepted 12 June 2019

KEYWORDS
Facial feminization;
Three-dimensional printing;
Computer-aided design

Abstract *Background:* The availability of more accurate techniques used for transgender surgery has resulted in an increased number of patients requesting facial feminization surgery (FFS). The aim of this study was to present the FFS pre-operative planning of the authors' male-to-female transsexual patients using photo-editing software, computer-aided design (CAD), modeling, and three-dimensional (3D) printing.
Material and Methods: Twenty-five patients underwent FFS between November 2015 and May 2018. They were retrospectively included in this study, and their records were analyzed. Patients' 3D facial models were printed and used for an accurate preoperative planning and shown to the patients. To assess patient satisfaction, the preoperative, six-month, and one-year postoperative scores obtained using Satisfaction With Life Scale (SWLS) and Subjective Happiness Scale (SHS) were compared. The scores following a normal distribution obtained for each patient were compared using a paired *t*-test.
Results: The 3D model preparation mean time was 145±13.2 min. A total of 114 surgical procedures were carried out. The mean operative time was 420±23 min. Patients experienced no postoperative complication. All patients were very satisfied after surgery, with a significant difference between pre- and postoperative scores ($p = 0.002$; $p = 0.03$).

* Corresponding author.
E-mail address: drsimonelapadula@gmail.com (S. La Padula).

https://doi.org/10.1016/j.bjps.2019.06.014
1748-6815/© 2019 Published by Elsevier Ltd on behalf of British Association of Plastic, Reconstructive and Aesthetic Surgeons.

Conclusion: With use of 3D modeling, surgeons are nearing a custom-made surgery era, especially required for complex procedures such as FFS. We suggest using 3D technology for a more accurate preoperative planning.
© 2019 Published by Elsevier Ltd on behalf of British Association of Plastic, Reconstructive and Aesthetic Surgeons.

Introduction

Gender dysphoria has been defined by three criteria: the desire to live and be accepted as a member of the opposite sex, the body transformation desire that can be achieved through surgery and hormones; the persistence of this desire for at least two years; and the absence of mental disorders and chromosomal abnormalities.[1]

The availability of more accurate techniques used for transgender surgery has resulted in an increased number of patients requesting facial feminization surgery (FFS).[2]

FFS is part of the sex reassignment process. With a set of surgical procedures, it has the purpose to alter typically male facial features to make them similar in terms of shape and size to typical female facial features. Conventional techniques require facial skeleton and soft tissue modification, hence making this surgery extremely complex.[3]

Some reports have already been published on FFS, but very few studies have focused on the global facial feminization. No article focused on FFS preoperative planning.[4-9]

The aim of this study was to present the FFS preoperative planning of authors' male-to-female transsexual patients using photo-editing software, computer-aided design (CAD), modeling, and three-dimensional (3D) printing.

Materials and methods

Twenty-five patients underwent FFS between November 2015 and May 2018. They were retrospectively included in this study, and their records were analyzed.

The following criteria, according to the WPATH standards of care,[10] have always been checked before any consultation: patients over 18 years of age; persistent and well-documented gender dysphoria, patients living at least 12 months in the gender role that is congruent with their gender identity, ability to make decisions and consent to a treatment, and patient under hormonal therapy since 12 consecutive months or more.

At the time of consultation, psychiatric assessment certificate, patient informed consent to care and image rights, and endocrinologist evaluation certificate were systematically demanded.

Patients were seen in consultation by the same single experienced operator who collected all the medical information and ensured that the record was complete. A careful clinical examination of the face was performed as follows:

- Upper face: reliefs of the superior orbital arches, position of the hairline.
- Mid-face: reliefs of the nose (tip, osteocartilaginous bump, and angles), projection of the cheekbones in the sagittal and transverse directions.
- Lower face: projection and width of the chin, width of the mandibular angles and horizontal branches, thickness of the masseter muscle, neck–chin angle.

A complete photographic assessment (front and profile at rest and at smile, ¾, plunging and bottom view, dental articulation) was performed. A radiographic assessment including a dental panoramic and front and profile teleradiographies was performed to identify an underlying dental-skeletal disorder. If orthognathic surgery was needed, our team planned it first and separately, after appropriate orthodontic treatment. Finally, a CT scan of the facial bones was requested.

FFS preoperative planning

For the photographic assessment, the Morpheus Photo Warper® photoediting software was used to simulate the postoperative outcome (Figure 1). The proposal was discussed and validated with the patient during the second consultation.

CT scan images allowed reconstructing two facial 3D models. The scans were imported in the DICOM format and processed by contouring and windowing to obtain an image of the face and skull in volume rendering (OsiriX®). The processing in surface rendering with a specific windowing of the bone density and skin covering allowed obtaining 3D files in the stereo-lithographic format: Standard Tesselation Language (STL) (Figure 2). These files were exported and processed into another CAD software. These software programs (Meshmixer® and Blender®) allowed modifying, on the one hand, the 3D structures polygon-by-polygon or in mass and, on the other hand, the textures to show the surgical changes planned. Two types of surface rendering were used for 3D modeling. First a bone rendering (Figure 3), which allowed working precisely on one of the two models and simulating the procedures to be performed on the hard tissue (the other model was used as a reference and was not modified). A second surface rendering of the facial skin covering (Figure 4) was used to simulate the result on the soft tissues. To achieve the final model, 3D files were exported in the STL format to a 3D printer. The third software, Z Suite®, was then used to set up the printing. In our Department, a span of 0.14 or 0.19 mm in thickness, a Z-ABS® or Z-ULTRA® resin, a normal print speed, and mild strength were used.

Zortrax® 3D printers were used in our Department (Figure 5). The models were used during the third consultation to explain the challenge of this surgery to the patient. The preparation time of the 3D models to be printed was also measured. For each patient, the number of planned and actually performed procedures was noted. Finally, the mean operating time and postoperative complications were recorded. To assess patient satisfaction, the preoperative,

Figure 1 Preoperative aspect of a 35-year-old woman. The patient's front view before surgery (a). Simulation of postoperative facial appearance, front view (b). Six-month postoperative result, front view (c). Preoperative aspect of the same woman. Patient's facial profile view (d). Simulation of postoperative facial appearance, profile view (e). Six-month postoperative result, profile view (f).

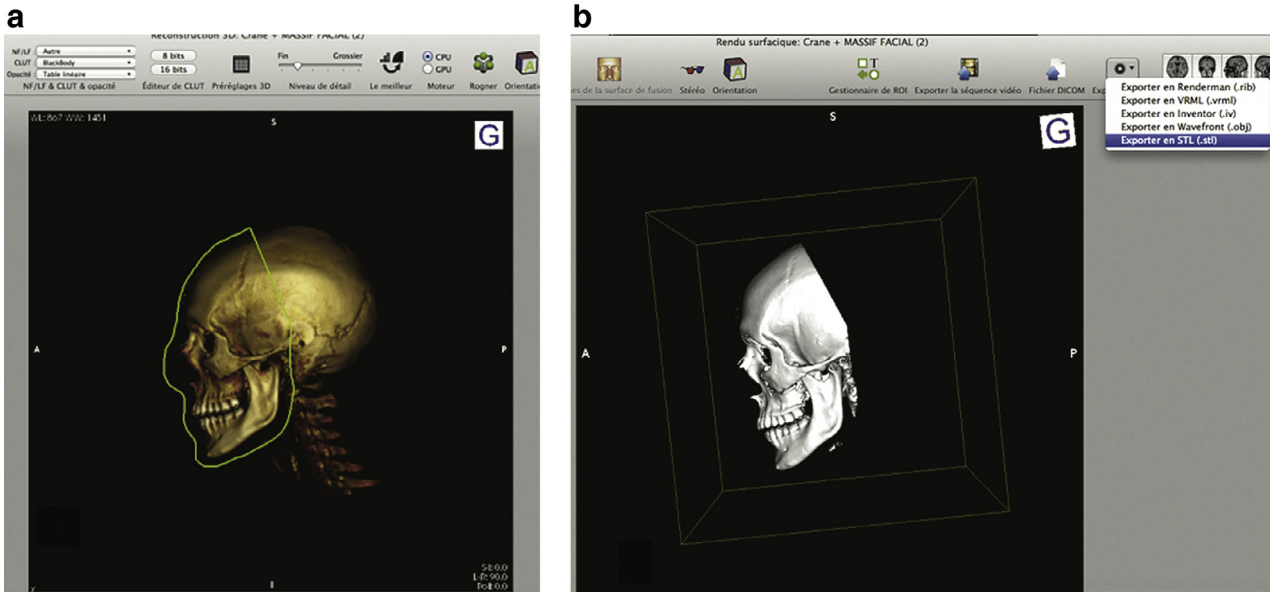

Figure 2 Step-by-step illustration of simulation model creation. Face and skull in volume rendering (OsiriX®) (a). A 3D file in stereo-lithographic format: Standard Tesselation Language (STL) (b).

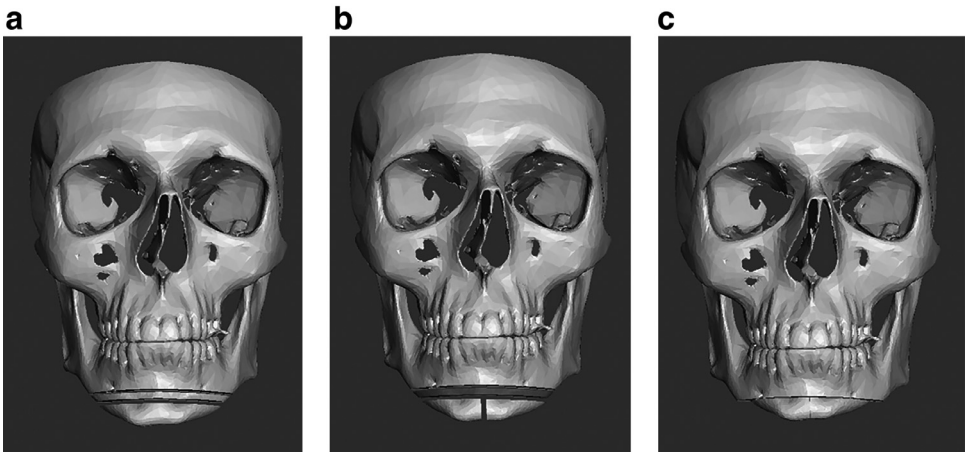

Figure 3 Three steps of a genioplasty simulation are shown (a–c).

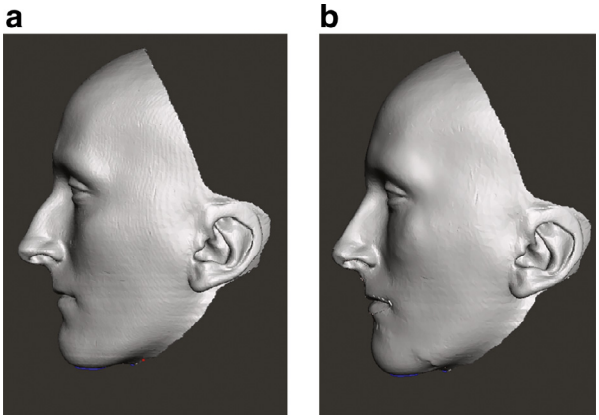

Figure 4 Preoperative soft tissue rendering (a). Simulation of postoperative facial appearance using the same surface rendering (b).

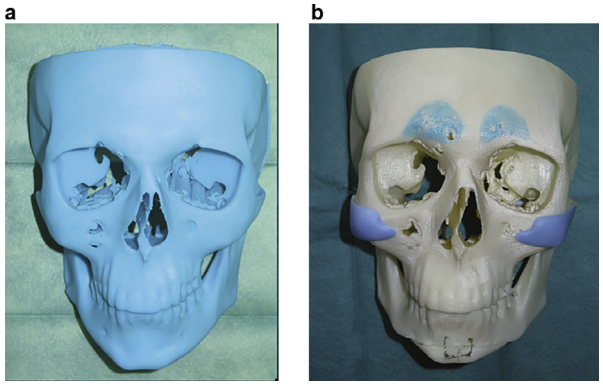

Figure 5 3-D printing has been used to create a model of the patient's skull (here Figure 1 patient model). For this patient, it was decided to perform a brow ridge reduction, a malar augmentation, and a genioplasty. 3-D model front view before simulation (a). Surgical procedures simulation on patient's printed skull front view (b).

six-month, and one-year postoperative scores obtained using Satisfaction With Life Scale (SWLS) and Subjective Happiness Scale (SHS) were compared.[11,12] The scores following a normal distribution obtained for each patient were compared using a paired *t*-test. A *p* value of <0.05 was considered statistically significant. All the authors took full responsibility for the integrity of the data. Analyses were performed using PRISM, version 7 (GraphPad, USA). Two medical statisticians reviewed the results.

Quality of life

Satisfaction with life scale (SWLS)

In this scale, satisfaction with life is measured through the agreement with five statements on a 7-point Likert scale. The sum score represents an overall measure of satisfaction—from low (5) to neutral (20) and high (35).

Subjective happiness scale (SHS)

This scale assesses the level of experienced happiness. The participant reports the agreement with four statements regarding happiness on a 7-point Likert scale. Higher scores represent a higher degree of happiness.

Results

The 3D model preparation time was reduced over time from 240 min for the first case to 60 min for the last one (mean time 145±13.2 min).

All patients accepted the surgery and were only operated once. In total, 192 procedures were planned and then carried out (Table 1), including the following:

- For the upper third of the face: frontal bone grinding in 20 patients, hairline advancement in 11 patients.
- For the middle-third of the face: rhinoplasty in 24 patients, malar implants in 7 patients, malar valgus osteotomy in 2 patients, and facial lipofilling in 19 patients.
- For the lower third of the face: grinding of the angles and mandibular rims in 25 patients, reduction of the masseter muscle in 19 patients, angle implants in 5 patients, upper lip lifting in 10 patients, orthognathic surgery in

Table 1 Surgical procedure distribution.

25 Patients	Total (number of patients)	(%)
Grinding of the frontal bone	20	80
Advancement of the hairline	11	44
Rhinoplasty	24	96
Malar implant	7	28
Malar valgus osteotomy	2	8
Facial lipofilling	19	76
Grinding of the angles and basilar rims	25	100
Masseter muscle reduction	19	76
Angle implant	5	20
Upper lip lifting	10	40
Orthognathic surgery	1	4
Genioplasty	25	100
Cervical liposuction	17	68
Reduction laryngoplasty	7	28
Total (procedures/case)	192	

one patient, genioplasty in 25 patients, subchin liposuction in 17 patients, and reduction laryngoplasty in 7 patients.

The mean operative time was 420±23 min. Patients experienced no postoperative complication, and the printed models were used as a guide for the procedure on the skeleton.

All patients were very satisfied after surgery with a significant difference between pre- and postoperative scores ($p = 0.002$; $p = 0.03$) (Table 2). The additional cost to the procedures was low. The resin used to print our models costs 1€/g; hence, with 150€, we obtained a 3D-printed model. Software used was totally free.

Discussion

To the best of our knowledge and from our experience, an accurate preoperative planning in FFS can be considered a useful method to prepare the surgeon to perform surgery and the patient to undergo surgery.

Having performed multiple surgeries per patient, we can state that for most of the persons undergoing an FFS, the procedures that we feel to recommend are grinding of the frontal bone, advancement of the hairline, rhinoplasty, grinding of the angles and basilar rims, and genioplasty.

With a limited cost, our preoperative planning enabled a better patient adherence to the therapeutic project. Indeed, photographic simulation and 3D-printed facial bone seemed to help them understand and accept the surgery more easily. For the surgeon, printing the facial bones allowed to view the reliefs to be modified and stimulates the touch memory. Even if it did not replace traditional imaging, 3D printing helped to prepare this challenging surgery and was also very useful during surgery.

Facial feminization procedures can provide satisfactory results with a significant impact on patient's quality of life.[13]

Many features distinguish a female face from a male face. A recent study focused on the differences in the features of the mandibular angles between male and female.[14] A narrow mandible, a short chin, a fine nose, a projected zygoma, an oblique palpebral opening, arched eyebrows, a bump-free forehead, and a low hairline are all features feminizing a face.[15] In parallel, some male features may emerge in the media for some actresses or models.[16]

Thus, the large number and complexity of procedures performed in this reassignment surgery are understandable.[17] Each face being unique, the procedures performed should respect the harmony of the face. Surgeons should be precise in their technique while using their creativity. In this context, it is important to discuss on a case-by-case basis the procedures to be conducted within a team.

The indications of 3D printing are increasing, especially in plastic and maxillofacial surgery.[18,19] This is an additional tool to improve FFS. Anyway, preparation of 3D models needs time, especially for the beginners. An intense learning curve has to be considered to learn how to use dedicated software. Presently, there is no consensus on the approach or exact place of this procedure in the reassignment surgical process.[20,21] Ethically, which surgery should be performed first? Based on our experience, we believe that FFS is one of the key points of the surgical management of gender dysphoria and that patient suffering and desire are the first elements to consider when planning the different procedures.

With the use of 3D modeling, surgeons are nearing a custom-made surgery era, especially required for FFS.

Presently, tools are available to better prepare the procedures to be conducted. Thus, photo-editing software, CAD and 3D printing, are useful technical supports that should be used to plan at best during surgery.

Compliance with ethical standards

All procedures in the study involving human participants have been performed in accordance with the ethical

Table 2 Differences between pre- and postoperative scores to assess patients' satisfaction.

Satisfaction with life	Preoperative score Mean (SD)	Six-month postoperative score Mean (SD)	*P* value
SWLS	20.6 (5.3)	31.2(6.7)	0.002
SHS	3.15 (1.4)	6.9 (1.8)	0.03
Satisfaction with life	**Preoperative score Mean (SD)**	**One-year postoperative score Mean (SD)**	***P* value**
SWLS	20.6 (5.3)	32.3(6.9)	0.002
SHS	3.15 (1.4)	7.1 (1.9)	0.03

SHS = Subjective Happiness Scale; SWLS = Satisfaction With Life Scale.

standards of institutional and/or national research committees and adherence to the 1964 Helsinki Declaration and its later amendments or comparable ethical standards.

Funding

None.

Conflict of interest

None declared.

Ethical approval

Ethical Approval was given by FRENCH institutional committee, and the relevant Judgment's reference number is 2018-A03400-55.

Financial disclosure

The authors did not receive any funding support for our work.

References

1. Revol M. *Transformation génitale homme-femme (aïdoïopoïèse)*. Elsevier Masson SAS; 2014.
2. Altman K. Facial feminization surgery: current state of the art. *Int J Oral Maxillofac Surg* 2012;**41**:885–94.
3. Becking AG, Tuinzing DB, Hage JJ, Gooren LJG. Transgender feminization of the facial skeleton. *Clin Plast Surg* 2007;**34**:557–64.
4. Capitán L, Simon D, Kaye K, Tenorio T. Facial feminization surgery: the forehead. Surgical techniques and analysis of results. *Plast Reconstr Surg* 2014;**134**:609–19.
5. Noureai SAR, Randhawa P, Andrews PJ, Saleh HA. The role of nasal feminization rhinoplasty in male-to-female gender reassignment. *Arch Facial Plast Surg* 2007;**9**:318–20.
6. Cho S-W, Jin HR. Feminization of the forehead in a transgender: frontal sinus reshaping combined with brow lift and hairline lowering. *Aesthetic Plast Surg* 2012;**36**:1207–10.
7. Dempf R, Eckert AW. Contouring the forehead and rhinoplasty in the feminization of the face in male-to-female transsexuals. *J Cranio-Maxillo-fac Surg Off Publ Eur Assoc Cranio-Maxillo-fac Surg* 2010;**38**:416–22.
8. Raffaini M, Magri AS, Agostini T. Full facial feminization Surgery: patient satisfaction assessment based on 180 procedures involving 33 consecutive patients. *Plast Reconstr Surg* 2016;**137**:438–48.
9. Ainsworth TA, Spiegel JH. Quality of life of individuals with and without facial feminization surgery or gender reassignment surgery. *Qual Life Res Int J Qual Life Asp Treat Care Rehabil* 2010;**19**:1019–24.
10. Wylie K, Knudson G, Khan SI, Bonierbale M, Watanyusakul S, Baral S. Serving transgender people: clinical care considerations and service delivery models in transgender health. *Lancet Lond Engl* 2016;**388**:401–11.
11. Diener E, Emmons RA, Larsen RJ, Griffin S. The satisfaction with life scale. *J Pers Assess* 1985;**49**:71–5.
12. Lyubomirsky S, Lepper HS. A measure of subjective happiness: preliminary reliability and construct validation. *Soc Indic Res* 1999;**46**:137–55.
13. Marten TJ. Hairline lowering during foreheadplasty. *Plast Reconstr Surg* 1999;**103**:224–36.
14. Mommaerts MY. The ideal male jaw angle – An Internet survey. *J Cranio-Maxillo-fac Surg Off Publ Eur Assoc Cranio-Maxillo-fac Surg* 2016;**44**:381–91.
15. Hage JJ, Becking AG, de Graaf FH, Tuinzing DB. Gender-confirming facial surgery: considerations on the masculinity and femininity of faces. *Plast Reconstr Surg* 1997;**99**:1799–807.
16. Ferrario VF, Sforza C, Poggio CE, Tartaglia G. Facial morphometry of television actresses compared with normal women. *J Oral Maxillofac Surg Off J Am Assoc Oral Maxillofac Surg* 1995;**53**:1008–14 discussion 1014–5.
17. Becking AG, Tuinzing DB, Hage JJ, Gooren LJ. Facial corrections in male to female transsexuals: a preliminary report on 16 patients. *J Oral Maxillofac Surg Off J Am Assoc Oral Maxillofac Surg* 1996;**54**:413–18.
18. Belcastro A, Willing R, Jenkyn T, Johnson M, Galil K, Yazdani A. A three-dimensional analysis of zygomatic symmetry in normal, uninjured faces. *J Craniofac Surg* 2016;**27**:504–8.
19. Darwood A, Collier J, Joshi N, et al. Re-thinking 3D printing: a novel approach to guided facial contouring. *J Cranio-Maxillo-fac Surg Off Publ Eur Assoc Cranio-Maxillo-fac Surg* 2015;**43**:1256–60.
20. Tugnet N, Goddard JC, Vickery RM, Khoosal D, Terry TR. Current management of male-to-female gender identity disorder in the UK. *Postgrad Med J* 2007;**83**:638–42.
21. La Padula S, Hersant B, SidAhmed M, Niddam J, Meningaud JP. Objective estimation of patient age through a new composite scale for facial aging assessment: the face-objective assessment scale. *J Craniomaxillofac Surg* 2016;**44**:775e782.