Minimally Invasive Procedures for Gender Affirmation

Jennifer L. MacGregor, MD*, Yunyoung C. Chang, MD

KEYWORDS

• Transgender • Nonbinary • Gender affirmation • Nonsurgical cosmetic procedures • Minimally invasive cosmetic procedures • Noninvasive cosmetic procedures • Masculinization • Feminization

KEY POINTS

- Although medical and surgical therapy may induce aesthetic transformations in the transgender population, the barriers to access and anatomic changes may be slower than desired, often taking months to years.
- With the growing number of transgender patients transitioning, dermatologists play an important role in improving outreach, implementing transgender-friendly practices, and formulating customized medical/cosmetic treatment plans.
- Dermatologists can address cosmetic concerns, including gender-affirming facial and body contouring, hormone-related skin changes, and surgery-related scarring.
- Aesthetic preferences may not follow the traditional binary ideals of beauty, including masculine versus feminine, and should be personalized during the initial consultation and subsequent follow-ups.
- Increased dermatologic literature detailing the available treatments for transgender transition and effects on quality of life is needed.

INTRODUCTION

Epidemiology of the Transgender Population

The reported overall prevalence of the transgender population has increased over the past decade, with 1 study reporting about 0.6% of adults (approximately 1.4 million) and 0.7% of youth aged 13 to 17 years (approximately 150,000 youth) identify as transgender in the United States.[1,2] This estimate is double those from prior studies less than a decade ago.[1,2] As the awareness and prevalence of the transgender population increases, it will be important to ensure that all health care providers are well versed in caring for this population.

Role of Dermatologists and Other Physicians

Dermatologists are starting to address practice gaps and consider a more supportive role in the care of their transgender patients.[3,4] Dermatologists play a critical role in both the medical and aesthetic care of transgender patients. Transgender patients present with similar dermatologic conditions as the general population as well as distinct cosmetic concerns during the transition process.[3] For example, acne is a common problem in transgender men undergoing testosterone therapy,[5] and recent dermatologic literature calls for a change from the current the gender-binary iPLEDGE labeling system for isotretinoin prescriptions to a more inclusive system that allows appropriate care of all gender orientations. In addition to general dermatologic concerns, cosmetic concerns are especially tied to the emotional well-being of transgender patients, because, by definition, their identity and desired aesthetic presentation to the world differ from their biological

Union Square Laser Dermatology, 19 Union Square West, 5th Floor, New York, NY 10003, USA
* Corresponding author.
E-mail address: jmacgregormd@gmail.com

Dermatol Clin 38 (2020) 249–260
https://doi.org/10.1016/j.det.2019.10.014
0733-8635/20/© 2019 Elsevier Inc. All rights reserved.

sex assigned at birth or chromosomal sex. Cosmetic concerns may include gender-affirming facial and body contouring, hormone-related skin changes, and surgery-related scarring.[3] It is also essential to consider that each patient's aesthetic goals may differ from the traditional masculine or feminine ideals of beauty as listed in **Box 1**.[6–8] This article instead advocates a more fluid result that is patient directed and suits each individual.

Physicians must also consider the many barriers transgender individuals face as they navigate their transition process in order to understand the reasons patients might consider care outside of traditional medicine.[9] Unlicensed providers, international Internet prescriptions, or illegal products are often used when patients seeking transition face barriers they think are insurmountable. Medical providers can themselves become a barrier to good care (often referred to in the community as gatekeepers) because of their ability to decide, delay, and regulate prescriptions or aesthetic treatments that may not seem acceptable to the patients' timeline. Board-certified providers may also charge more money for procedures, and lack of insurance coverage for aesthetics make some of these treatments cost-prohibitive for patients without the necessary disposable income. Further, location far from metropolitan areas and lack of family or social support make access difficult for many. Faced with societal pressures to conform to masculine or feminine ideals of beauty but stopped by the barriers to receiving needed medical care or aesthetic procedures, transitioning patients may experience anxiety and depression. It is understandable, then, why some transgender patients resort to "pumping", or using liquid silicone,[10,11] or receive care from untrained, unqualified providers. The appropriate response of physicians in these cases is to meet the patients where they are, avoid condescending language regarding the patients' decisions, listen, and develop a plan to help move forward. The office staff and physicians must also be trained to ask and address patients with their preferred pronouns and ensure that office medical forms are inclusive of all gender orientations. With compassionate, supportive care and better marketing outreach, clinicians can bring more transgender patients into the care of board-certified and qualified physicians.

Box 1
Selected traditional masculine versus feminine features

- Traditionally masculine features
  - Higher, possibly receding hairline
  - Wider, more angular forehead
  - Flat, horizontal brow
  - More prominent supraorbital brow ridges
  - Wider mouth with thinner lips
  - Longer, more square chin
  - Wider, more square lower face
  - Beard hair or coarser lower face skin texture
  - Acute nasolabial angle
- Traditionally feminine features
  - Lower hairline
  - Smooth, convex forehead
  - Brows arch above softer orbital rim
  - Eyes appear more open and/or wider set
  - Convex, prominent cheek contour
  - Heart-shaped, more tapered lower face
  - Smaller lower face to upper face proportion
  - Fuller vermillion contour and fuller lip body
  - More obtuse nasolabial angle

The authors instead advocate more fluid, patient-directed aesthetic goals that may not adhere to the following ideals.
Data from Refs.[6–8]

Noninvasive aesthetic procedures performed by board-certified physicians have clear advantages. Laser treatments and injectables are performed in an outpatient medical setting with high safety standards, minimal risk, and little downtime compared with surgery. Facial injectables are mostly reversible and can be started immediately to enhance, reduce, masculinize, or feminize features according to the patients' goals. There is minimal need for psychological vetting, pretreatment medication, or other delays that would be routinely needed before invasive surgery. In cisgender patients, minimally invasive aesthetic procedures have been shown to improve body image, self-esteem, and quality of life (QOL).[12]

Educational resources and published data are available regarding hormonal therapy and surgical procedures to support gender transition. However, the dermatologic literature on minimally invasive procedures is currently sparse. Specifics on how dermatologists can assist in the aesthetic transformation of transgender patients, meet their individual goals, and thereby improve QOL need to be elucidated. Current reviews[8,13] consolidate and outline current literature providing useful guides to providers, but new case series, before and after

images, larger studies, and new data are needed. The authors think that all patients can benefit from noninvasive aesthetic procedures to support their aesthetic goals for their appearance and improve their outcomes when transitioning. Studies are underway to assess QOL data specifically in transgender individuals who have received noninvasive aesthetic dermatologic services to quantify the impact and improve future counseling efforts. This article reviews the common factors and medications affecting gender transition as well as the noninvasive cosmetic procedures as they relate specifically to the transgender population (including some case examples). Readers should keep an open mind that the aesthetic procedures transgender patients seek may be feminizing, masculinizing, both, or neither. Practitioners must ask patients about their goals, listen to all patients, and speak candidly about their preferences before proceeding with recommendations and treatments.

Overview: Medications and Procedures Available to Assist with Gender Transition

Transgender individuals may choose to transition socially, medically, and/or surgically to align their gender expressions with their gender identities.[14] Hormonal therapy has become more widely prescribed for the transgender population.[15] Medical guidelines have been created by the World Professional Association for Transgender Health and the Endocrine Society to guide providers caring for the transgender population.[15] Most notably, 1 year of hormonal therapy and living as the desired gender is required before gender-confirming (permanent) surgeries. For transgender women (male to female), hormonal therapy includes estrogen supplementation with or without antiandrogen therapy such as spironolactone or cyproterone acetate.[15] The goal of hormonal therapy is to feminize patients by changing fat distribution, decreasing muscle mass, inducing breast formation, reducing testicular size, and reducing male pattern hair growth.[15,16] The rate at which the physical effects occur after estrogen initiation varies, with changes starting within a few months and progressing for 2 to 3 years.[16] Although the physical changes may be striking, they may be too subtle for some patients (**Fig. 1**). Noninvasive aesthetic treatments can further enhance appearance by softening, contouring, and balancing features according to specific aesthetic goals (**Figs. 2–4**).

Transgender men (female to male) may choose to undergo hormonal therapy with exogenous testosterone.[15] Testosterone therapy suppresses female secondary sex characteristics and masculinizes transgender men. The effects of testosterone can be seen within 3 months of initiating therapy, including cessation of menses, changes in fat distribution, increases in muscle mass, and increased libido. Changes that occur later include deepened voice, vaginal skin atrophy, and increased clitoral size.[15] Skin effects that occur during this period may include increased facial and body hair, increased acne, and male pattern hair loss.[15]

Fig. 1. Before (*A*) and after (*B*) hormonal therapy. Aesthetic changes include wider and more rounded convexities at temple and cheek. Also note the midface appears fuller with a softer and less angular contour through the mandible and chin. Before (*C*) and after (*D*) facial fillers in the same patient reveal more widening at the temple, cheek, and tear trough with a softer and more rounded contour to the mandible chin. The lips are subtly enhanced to reveal a more natural feminine projection with elevated mouth corners.

Surgical procedures are available for transgender patients in addition to medical therapy or if the effects of sex hormone treatment are unsatisfactory.[16] For transgender women, surgical options include genital affirmation surgery to remove the testes (orchiectomy), vaginoplasty (to create a neovagina), breast augmentation surgery,

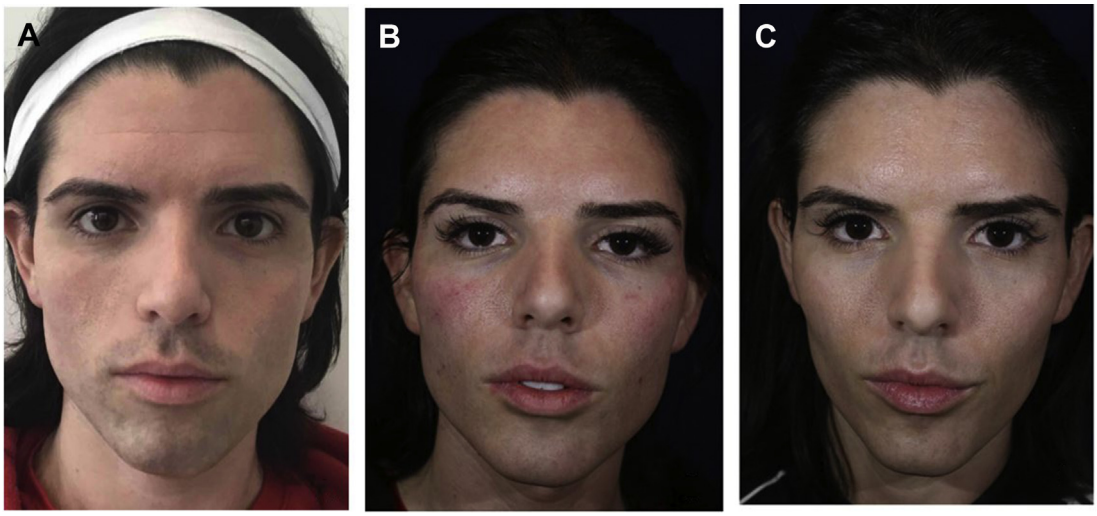

Fig. 2. (*A*) Before and (*B*) after laser hair removal to the lower face, showing reduction in shadowing and softening of skin texture. This patient also received injectables to the upper face (*A*) before and after botulinum toxin to smooth and gently arch the brow and (*B*) immediately after facial fillers to the midface and lower face to enhance convexity of cheek and lips, and smooth contour of the mandible and chin. (*C*) After botulinum to the masseter muscle the face appears more heart shaped.

chondrolaryngoplasty for prominent larynx (tracheal shave for Adam's apple), voice feminization surgery, or facial feminization surgeries including rhinoplasty and forehead and chin implants.[16] For transgender men, surgical options include chest masculinization surgery, metoidioplasty, phalloplasty, scrotoplasty, hysterectomy, and oophorectomy.[17]

One recent population study based in Boston Medical Center between 2004 and 1015, published in July 2017, reported that 35% of subjects had undergone at least 1 gender-affirming surgery.[18] Thus, most transgender clinic patients had not undergone any type of gender-affirmation surgery. The low rate may be caused by financial cost, lack of interest, lack of availability, aversion to invasive procedures,[18] or any of the aforementioned barriers to care.

Quality-of-Life Data for Gender Identity and Aesthetic Procedures

Transgender women and men report a lower QOL compared with the general population.[19–21] Both medical hormonal therapy[19] and gender-reaffirming surgeries[20] have been shown to be associated with high satisfaction and higher quality of life. However, even after transitioning, the population remains at risk for lower QOL and mental health.[21] Adjunct minimally invasive aesthetic procedures may assist in the transition process and further increase body image, satisfaction with appearance, and QOL. This option could be most important for the patients in the first year on hormonal therapy, to ease their gender dysphoria and help them feel more comfortable in their chosen gender identity while they are awaiting gender confirmation surgery.

A recent cross-sectional survey study of 327 people showed that most transgender women thought that their faces were the most essential body part to have changed. Of facial procedures, transgender women reported hair removal was the most important aesthetic procedure, followed by surgery and then injectables.[3] The women reported seeking procedures mostly from plastic surgeons,[3] which may indicate preference, prior therapeutic relationship, marketing/community outreach, or ease of access. In contrast, transgender men were most concerned with their chests, more than their faces or genitals. Patients also reported that their priority with aesthetic procedures is that it looks good, being more important than the risk of scars, complications, or other risks. The authors postulate that minimally invasive aesthetic procedures performed by dermatologists could be more popular in both transgender men and women with more community outreach and literature detailing the available procedures and typical outcomes, thus enhancing safety and reducing the risk of complications in this population. Patients also need before and after images they can relate to, rather than attempting to extrapolate typical results from cisgender patient images.

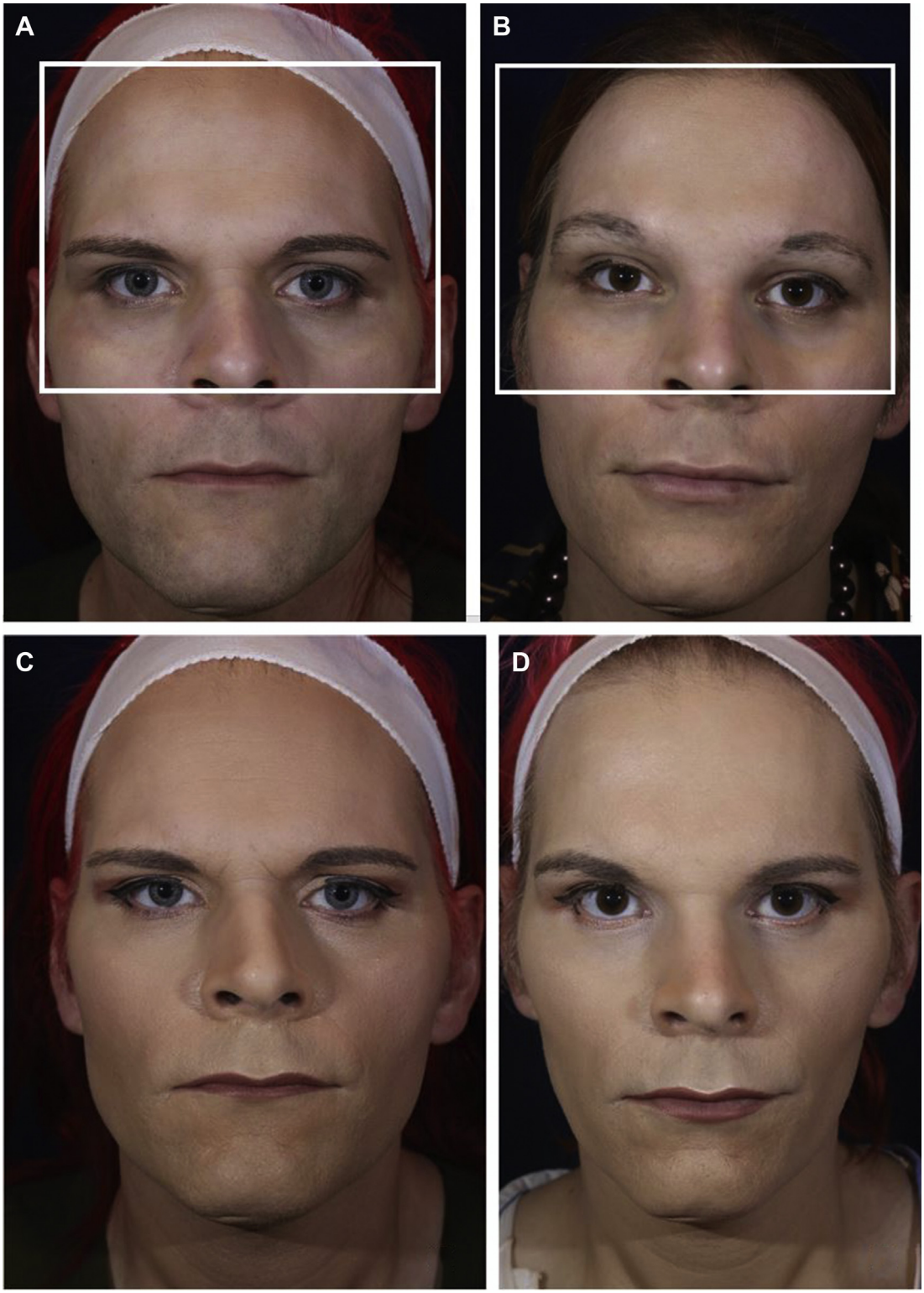

Fig. 3. (*A*) Before and (*B*) after using injectable fillers to soften the temples, lift and smooth the depressed nasal root, and reduce the prominent supraorbital brow ridges (with makeup removed). Additional lift to the brow was achieved after polydioxanone thread lifting, 2 treatments of microfocused ultrasound skin tightening, as well as botulinum toxin injection. (*C*) Before and (*D*) after with makeup showing the overall impact of upper face treatment as well as lower face. The lower face was treated with botulinum toxin injection to masseters to produce a more heart-shaped, tapered jawline and fillers were used to enhance lip volume as well as lift the mouth corners and soften the chin/prejowl sulcus. Note that the lips will be treated in several sessions over time to gradually build volume while preserving a natural shape.

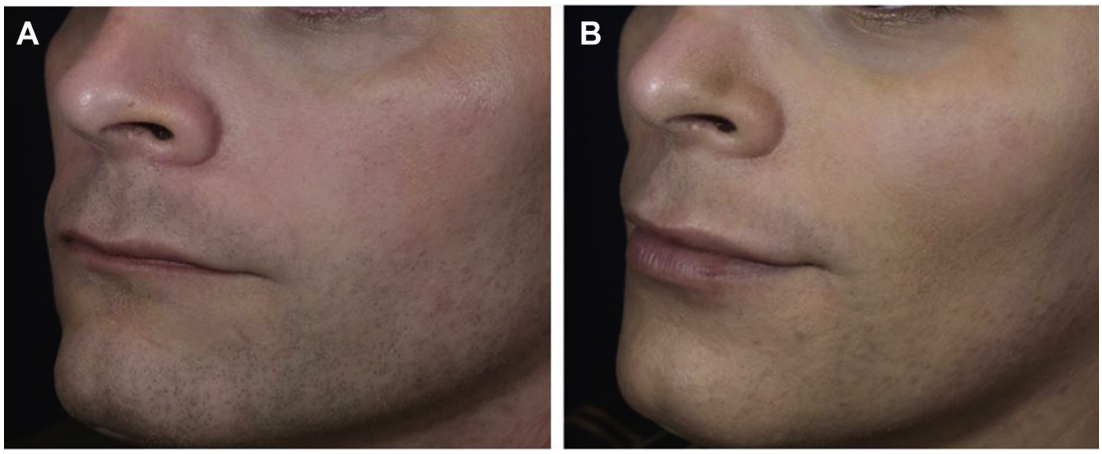

Fig. 4. (*A*) Before and (*B*) after oblique side angle showing the effect of lower face smoothing achieved with injectable facial filler, botulinum toxin, polydioxanone thread lifting, and laser hair removal. The lower face also looks more narrow and lifted in proportion to the upper face.

Transgender Women (Male to Female Transition)

Facial aesthetics are of primary importance to transgender women.[3] The face is the first feature presented to the world and is less easily camouflaged than the chest or genitals. Estrogen therapy may reduce facial hair, but rarely eradicates terminal hairs in the beard distribution, making laser hair removal the first concern for most.[3] Hair reduction on the face smooths the skin and has a major, life-changing impact on appearance in these patients (see **Figs. 2–4**) but often takes more than the average 6 to 8 sessions in the authors' experience. Other changes expected from estrogen therapy may be softening and rounding of the forehead, temple, cheek/midface, and mandible, with less angular features (see **Fig. 1**); however, many patients wish for additional or more rapid enhancements.

Modest facial contouring can be achieved with minimally invasive treatments, such as injectable botulinum toxin, soft tissue fillers, thread lifting (with polydioxanone or poly-L-lactic acid sutures) and energy-based tightening devices. Some patients with prominent supraorbital brow ridges, depressed nasal root, or flat brow benefit from upper face injectable fillers (see **Fig. 4**; **Figs. 5** and **6**), botulinum toxin, thread lifting, and skin tightening in combination. Specifically, transgender women often have stronger and more prominent facial muscles, including the glabellar complex, frontalis, and masseter muscles. These muscles can be treated with botulinum toxin injections to relax and soften them. In the authors' experience, transgender women tend to require a higher dosage than most cisgender women to achieve an adequate response. Long-term use of botulinum toxin also works to chemically shrink these muscles, without the need for surgery. Flat or low-set eyebrows can be lifted and arched by the use of strategically placed botulinum toxin in the glabella, filler injections around and under the brow, thread lifts placed in the forehead from the frontotemporal hairline to lift up, and microfocused ultrasound of the forehead to create a brow lift. Patients with particularly heavy brows or prominent supraorbital brow ridges may elect surgical reduction for more dramatic improvements. For those who transition postpuberty, a flat midface and cheek as well as hollow tear troughs may benefit from lifting and widening to enhance softer, rounder convexities and a more heart-shaped face (see **Figs. 2** and **6**). This outcome can be obtained by filler injections in the cheeks, temples, tear troughs, and forehead to enhance bone structure as well as botulinum toxin injections in the masseters to slim or taper the jawline, thereby creating a heart-shaped, traditionally feminine facial contour (see **Figs. 2–4**). Patients of all gender identities may wish to maintain a stronger or more angular jawline, and this preference should be asked of the patient. Lips can be shaped according to patient preference by manipulating the vermillion border (see **Fig. 1**A, C), and/or enhanced and volumized by injecting at the wet-dry border (see **Figs. 2–4**). The perioral and prejowl area can also be addressed with filler to blend volume and soften harsh angles and shadows as well as to soften the chin (see **Figs. 1–4**). Botulinum toxin injections to the chin can also be used to relax mentalis dimpling.



Fig. 5. The patient's own photographs showing the before and after change achieved through minimally invasive aesthetic procedures including injectable fillers, botulinum toxin, microfused ultrasound skin tightening, polydioxanone thread lifting, and laser hair removal.

Fig. 6. (*A*) Before and (*B*) after a single session of treatment with little to no downtime. This patient received botulinum toxin to the glabella and injectable filler to lift the tear trough and enhance convexities of the cheek and temple.

Some transgender women present already pleased with their features, just wishing for a smaller correction to enhance their beauty or emphasize certain features. Cultural influences, personal preferences, or simply any person's own unique aesthetic can influence the desired outcome. **Fig. 7** shows how small tweaks or details can enhance beauty and improve proportions. This patient wished for a more taut, arched brow and a more tapered jawline, revealing a more heart-shaped face; her goals were achieved with a single session of injectable botulinum to the upper face and masseters along with facial fillers to the temples, cheeks, mouth corners, and body of the lip. Improving facial proportions by making the upper face wider, lifting the nasolabial angle, or small volume filler to the nasal root or nasal dorsum (nonsurgical rhinoplasty) can also make a larger nose appear smaller, more lifted, and/or narrower (see **Figs. 4**, **5**, and **7**)

Potential side effects from estrogen therapy also present new aesthetic issues for transgender women during and after transition. Melasma is known to worsen in response to exogenous estrogens and can develop at any time. Melasma partially responds to maintenance topical therapy with daily application of mineral sunscreens, retinoids, hydroquinone, botanic brighteners, antioxidants, and peeling agents. Low-density, low-energy 1927-nm fractional resurfacing several times per year is also an option to accelerate brightening of pigmentation and maintain remission. New leg veins secondary to estrogen can be treated with sclerotherapy and lasers, whereas new-onset cellulite can be temporarily smoothed with radiofrequency-based energy devices. Striae can be treated with vascular lasers, nonablative fractional resurfacing, microneedling, or combination. Estrogen therapy does not alter a receding hairline. Topical minoxidil and platelet-rich plasma are treatment options for androgenetic alopecia, which may be continued in transgender women to prevent worsening of hairline recession. Transgender women may want to consider follicular unit hair transplant to restore a lower hairline and to cover a thinning vertex, especially if longer hairstyles are desired. In some of our patients, we have also seen a loss of mandibular size and structure following estrogen therapy. The resulting skin laxity and submental adiposity may benefit from skin tightening with radiofrequency or microfocused ultrasound and fat reduction with cryolipolysis or deoxycholate injections, respectively.

There are no data in our medical literature about transgender women's body contouring attitudes and preferences. In the authors' experience, the abdomen, flanks, inner thighs, and bra line adiposity all respond well to cryolipolysis, pulsed

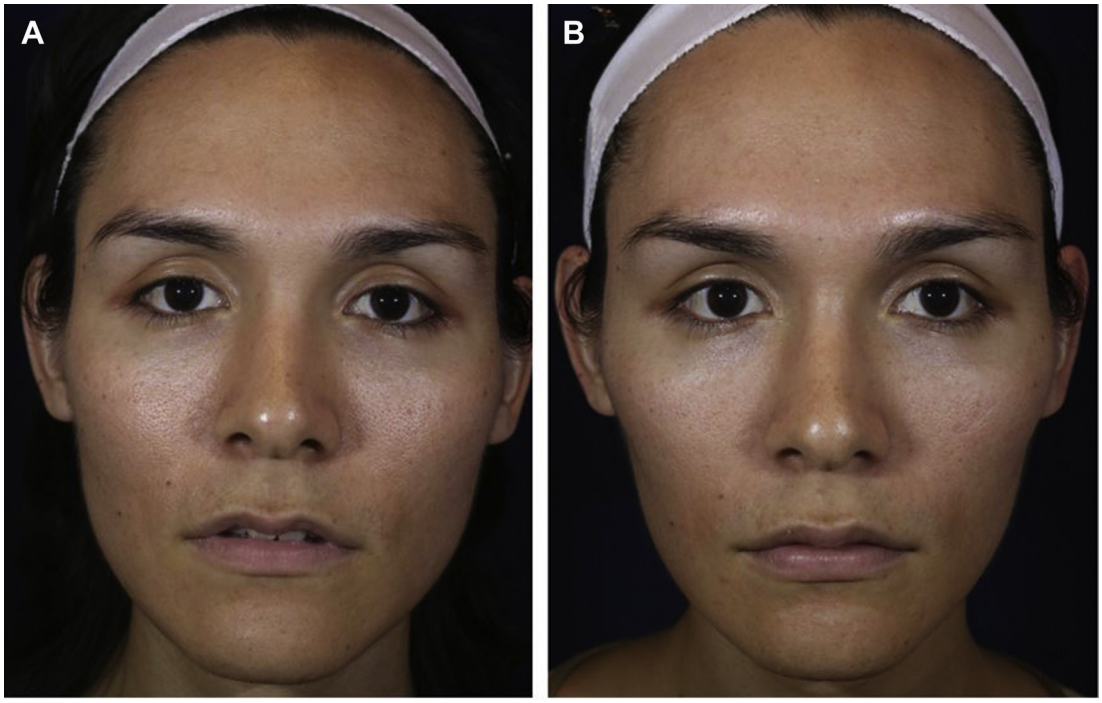

Fig. 7. (*A*) Before and (*B*) after injectable botulinum toxin to the upper face and masseters. Injectable fillers were placed to widen the temples and cheeks as well as lift the mouth corners and plump the body of the lip.

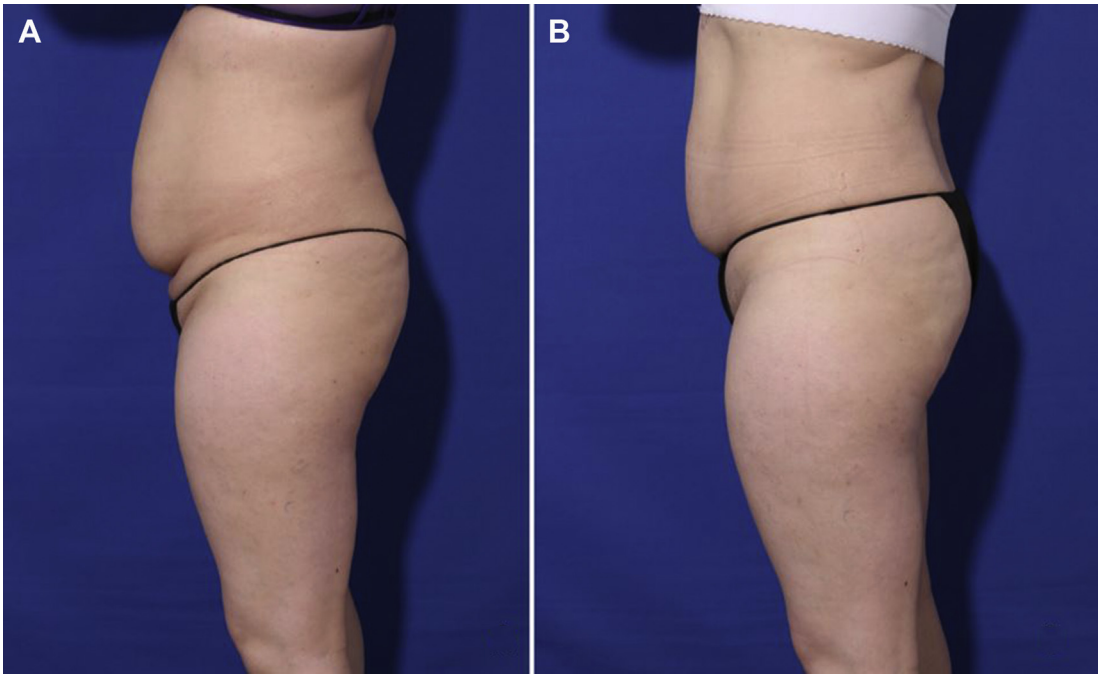

Fig. 8. (*A*) Before and (*B*) 2 months after abdominal Cryolipolysis combined with 3 twice-monthly sessions of pulsed forced ultrasonography in transgender woman.

focused ultrasound, and/or radiofrequency body contouring devices (**Fig. 8**). Hip and buttock augmentation may be desired and could be obtained through filler injections, but the volume of product required over several sessions proves to be cost-prohibitive for most (making this procedure rare in our office).[9,11] For the hip and buttock, fat harvesting and transplant could be another option. Breast augmentation through surgical correction (top surgery) and vaginoplasty (bottom surgery) yields some degree of scarring in most patients. If the scars are undesirable, vascular laser, resurfacing, or microneedling with radiofrequency can be considered (**Figs. 9** and **10**).

Transgender Men (Female to Male Transition)

Although transgender men are more concerned with their chests than their faces or genitals, dermatologic care and noninvasive treatments are of benefit in these patients. In the authors' experience, pseudogynecomastia (residual breast tissue) still present after testosterone therapy does

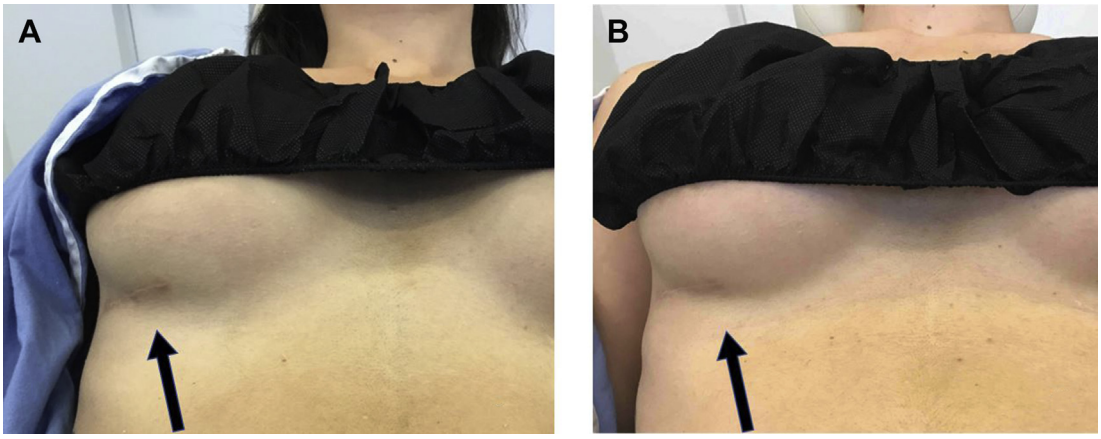

Fig. 9. (*A*) Before and (*B*) after 2 sessions of nonablative fractional laser resurfacing to blend breast augmentation scars in a transgender woman.

Fig. 10. Postoperative result of vaginoplasty in a transgender woman. Scars are not noticeable and require no treatment. She was recently treated for folliculitis and will first receive a topical regimen to fade resulting pigmentation.

not respond well to minimally invasive aesthetic treatment, and we routinely refer these patients for surgical correction (Fig. 11). On the face, some transgender men wish to maintain new hair growth or shave, whereas others in our care have sought laser hair removal of new facial hair experienced after testosterone therapy. Noninvasive body contouring, particularly on the abdomen, flanks, and submental adiposity, should also be considered in transgender men.

Although possibly not the top concern, many transgender men also present for enhancements to facial contour. We have seen many transgender men who benefit from facial injectables to refine facial features. On the upper face, botulinum can be used to flatten and strengthen the brow, whereas injectable fillers can be used on the midface and lower face to refine a more prominent and angular zygoma, mandible, and chin (Fig. 12). Some patients also note that bone structure fluctuates slightly during cyclic testosterone injection cycles, and we recommend photographs, examination, and treatment follow-up at several weekly time points to achieve the desired end point with facial contouring in transgender men. As previously discussed, testosterone-related acne, folliculitis, pigmentation, and scarring can be severe. Dermatologists are the experts and can play a supportive role by managing acne and folliculitis. Scarring and pigmentation can be reduced in all skin types by topical retinoids, peeling, and brightening agents, as well as multiple fractional laser resurfacing and microneedling with radiofrequency treatments in series. In patients who note accelerated male-patterned, or androgenetic, alopecia during and after transition, follicular unit hair transplant should be considered. Finasteride should not be considered in the first 2 years of testosterone therapy until the patient has achieved their desired secondary sex characteristics.

Nonbinary Gender Status

There is increased awareness about individuals who do not identify specifically with either gender (nonbinary or intersex) thanks to educational media campaigns,[22,23] attention in art/film,[24] and public political struggles.[25] This nonbinary status could be related to intersex or ambiguous genitalia at birth, personal preference, or both. Many

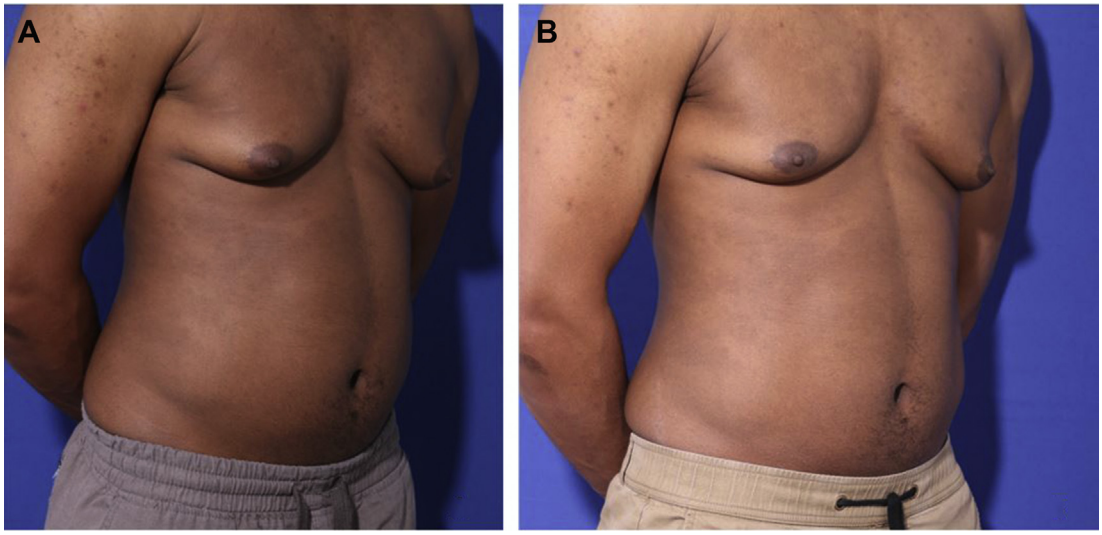

Fig. 11. Transgender man (*A*) before and (*B*) after Cryolipolysis to the chest. No change is seen and the patient ultimately sought surgical correction.

Fig. 12. (*A*) Before (arrows indicate areas where structure was enhanced with injectable filler) and (*B*) immediately after a single session of facial fillers to strengthen and contour the temple, zygoma, mandible, and chin with calcium hydroxylapatite. Testosterone-induced acne is also seen and the patient has started topical retinoids and a brightening/peeling regimen.

advocates think that people in this category should not have surgical intervention in infancy or childhood[24,25] and should be allowed to choose their gender identities themselves after puberty in early adulthood or remain intersex over the long term. In medical offices, all electronic and paper forms should be inclusive and easy to navigate for all gender identities. Patients should be asked which pronouns they prefer and told to fill out forms however they wish or however they identify. Providers should never assume that any individual wishes to receive traditionally masculinizing or femininizing procedures. As with any patient, physicians should ask open-ended questions while viewing their mirror reflection (eg, "Tell me you see," or "What would you like to achieve," or even "What do you love and want to accentuate") and listen carefully to each patient's aesthetic aspirations. It is also important to remember that viewing their own clinical photographs may be psychologically difficult at times (always ask first whether they want to see their images before showing them). Treatment recommendations are then guided by the practitioner's suggestions and continually modified as the patient provides feedback.

SUMMARY

As the number of people seeking gender transition grows, the importance of dermatologists in facilitating this transition process in a safe and smooth manner also increases. Dermatologists may offer much speedier access to minimally invasive procedures that make a significant difference in the confidence and QOL of transgender patients. To that effect, more dermatologic literature is needed on the best, safest treatments that can be provided to patients. Clinicians must also coordinate with transgender patients, medical endocrinologists, and surgeons during the transition process. Staff should be well trained and office procedures should be modified to be inclusive of transgender men, women, and nonbinary gender status individuals. Rather than being all-assuming, the authors recommend being open with patients about their preferred use of pronouns, names, as well as their aesthetic preferences. It is important to understand that everyone experiences transitioning differently, and rather than clinging to paternalistic tendencies, physicians need to listen and accommodate the needs of their patients. Open-minded listening and regularly asking for preferences help cultivate a respectful relationship. To that point, when we ask our transgender patients, "What do you wish doctors would do differently when you seek their help?" we hear repeatedly, "I feel that doctors should listen more than talk and try to understand where the patient is coming from rather than their own opinions. Everyone's journey is different." We hope this article is the first of many steps to understanding and providing the best care for transgender and nonbinary patients.

REFERENCES

1. Estimates of transgender populations in states with legislation impacting transgender people (update): how many adults identify as transgender in the United States? In: The Williams Institute UCLA School of Law. 2016. Available at: http://williamsinstitute.law.ucla.edu/wp-content/uploads/How-Many-Adults-Identify-as-Transgender-in-the-United-States.pdf. Accessed November 11 2018.
2. Estimates of transgender populations in states with legislation impacting transgender people (Update): age of individuals who identify as transgender in the United States. In: The Williams Institute UCLA School of Law. 2017. Available at: https://williamsinstitute.law.ucla.edu/wp-content/uploads/TransAgeReport.pdf. Accessed November 11, 2018.
3. Ginsberg BA, Calderon M, Seminara NM, et al. A potential role for the dermatologist in the physical transformation of transgender people: a survey of attitudes and practices within the transgender community. J Am Acad Dermatol 2016;74:303–8.
4. Boos MD, Ginsberg BA, Peebles JK. Prescribing isotretinoin to transgender youth: a pledge for more inclusive care. Pediatr Dermatol 2019;36(1):169–71.
5. Wierckx K, Van de Peer F, Verhaeghe E, et al. Short- and long-term clinical skin effects of testosterone treatment in trans men. J Sex Med 2014;11(1):222–9.
6. Carruthers JD, Glogau RG, Blitzer A. Facial aesthetics consensus group faculty. Advances in facial rejuvenation: botulinum type a, hyaluronic acid dermal fillers and combination therapies-consensus recommendations. Plast Reconstr Surg 2008;121(5Suppl):5S–30S.
7. Altman K. Facial feminization surgery: current state of the art. Int J Oral Maxillofac Surg 2012;41(8):885–94.
8. Ascha M, Swanson MA, Massie JP, et al. Nonsurgical management of facial masculinization and feminization. Aesthet Surg J 2019;39(5):123–37.
9. Walker H. Body of work: from DIY hormones to silicone injections, why some trans women choose to transition outside the medical industry. Out magazine 2019;75–8.
10. Murariu D, Holland MC, Gampper TJ, et al. Illegal silicone injections create unique reconstructive challenges in transgender patients. Plast Reconstr Surg 2015;135(5):932e–3e.
11. Pinto TP, Teixeira FDB, Barros CRDS, et al. Use of industrial liquid silicone to transform the body: prevalence and factors associated with its use among transvestites and transsexual women in São Paulo, Brazil. Cad Saude Publica 2017;33(7):1–13.
12. Sobanko JF, Dai J, Gelfand JM, et al. Prospective cohort study investigating changes in body image, quality of life and self esteem following minimally invasive cosmetic procedures. Dermatol Surg 2018;44(8):1121–8.
13. Marks DH, Awosika O, Rengifo-Pardo M, et al. Dermatologic surgical care for transgender individuals. Dermatol Surg 2019;45(3):446–57.
14. White Hughto JM, Reisner SL, Pachankis JE. Transgender stigma and health: a critical review of stigma determinants, mechanisms, and interventions. Soc Sci Med 2015;147:222–31.
15. Unger CA. Hormone therapy for transgender patients. Transl Androl Urol 2016;5(6):877–84.
16. Tangpricha V, den Heijer M. Oestrogen and anti-androgen therapy for transgender women. Lancet Diabetes Endocrinol 2017;5(4):291–300.
17. Irwig MS. Testosterone therapy for transgender men. Lancet Diabetes Endocrinol 2017;5(4):301–11.
18. Kailas M, Lu HMS, Rothman EF, et al. Prevalence and types of gender-affirming surgery among a sample of transgender endocrinology patients prior to state expansion of insurance coverage. Endocr Pract 2017;23(7):780–6.
19. Gorin-Lazard A, Baumstarck K, Boyer L, et al. Is hormonal therapy associated with better quality of life in transsexuals? A cross-sectional study. J Sex Med 2012;9(2):531–41.
20. Wierckx K, Van Caenegem E, Elaut E, et al. Quality of life and sexual health after sex reassignment surgery in transsexual men. J Sex Med 2011;8(12):3379–88.
21. Jellestad L, Jäggi T, Corbisiero S, et al. Quality of life in transitioned trans persons: a retrospective cross-sectional cohort study. Biomed Res Int 2018;2018:8684625.
22. These activists get real about being intersex. In: Teen Vogue June 2017. Available at: https://video.teenvogue.com/watch/these-activists-get-real-about-being-intersex. Accessed on April 10, 2019.
23. Common misconceptions about sex and gender. In: Teen Vogue March 2019. Available at: https://video.teenvogue.com/watch/5-common-misconceptions-about-sex-and-gender. Accessed on April 10, 2019.
24. About river Gallo and Ponyboi the film. Available at: https://www.rivergallo.com/about. Accessed on April 10, 2019.
25. California becomes the first state to condemn intersex surgeries on children. In: USA Today August 28, 2018. Available at: https://www.usatoday.com/story/news/nation/2018/08/28/intersex-surgeries-children-california-first-state-condemn/1126185002/. Accessed on April 10, 2019.