Gender-Affirming Surgery of the Mandible

Lower Jaw Feminization and Masculinization

Benjamin B. Massenburg, MD[a,b], Russell E. Ettinger, MD[a,b], Shane D. Morrison, MD, MS[a,b,*]

KEYWORDS

• Gender affirming • Mandible contouring • Genioplasty • Lower jaw augmentation • Chin implants • Osteotomies • Craniofacial surgery

KEY POINTS

- Lower jaw feminization typically consists of bony reduction and contouring of the mandibular angle and body along with genioplasty for shortening, narrowing, and possible advancement or lengthening depending on a patient's facial morphology.
- Lower jaw masculinization consists of augmentation with alloplastic implants, bone grafts, or fat grafting over the mandibular angle and body, and chin augmentation with alloplastic implants, genioplasty, or fat grafting.
- Complications are uncommon but can be significant if there is a mandible fracture, nerve injury, implant infection, or other surgical site infection.
- Standardized guidelines are needed for safe and effective surgical pathways for facial gender-affirming surgery.

Video content accompanies this article at http://www.facialplastic.theclinics.com.

INTRODUCTION

For patients with gender dysphoria, gender-affirming surgery of the face has continued to advance over the last 35 years, since Dr Douglas Ousterhout published his seminal article in 1987.[1] The literature shows that facial feminization surgery is much more common than facial masculinization surgery, likely due to the powerful masculinizing effects of testosterone. Of the aspects of facial feminization surgery, lower jaw contouring tends to be the least commonly performed surgery, when compared to the forehead and midface. This article will review the literature on gender-affirming surgery of the lower jaw, both facial feminization and facial masculinization, and both bony contouring and soft tissue adjunctive procedures.

There are several key differences in the bony and soft tissue architecture of the feminine and masculine face, as highlighted in **Table 1**. Focusing on the lower jaw, there is increased mandibular body height, increased gonial splay, and a gonial angle typically less than 125° in the masculine mandible (**Figs. 1–4**). The chin is typically larger, wider, and squarer in the masculine mandible (see **Figs. 1** and **4**; **Fig. 5**). All of these differences can be addressed with gender-affirming craniofacial surgery of the mandible.

[a] Division of Plastic Surgery, Department of Surgery, University of Washington; [b] Division of Craniofacial and Plastic Surgery, Department of Surgery, Seattle Children's Hospital
* Corresponding author. Division of Plastic and Reconstructive Surgery, Department of Surgery, Harborview Medical Center, 325 9th Avenue, Mailstop #359796, Seattle, WA 98104.
E-mail address: shanedm@uw.edu

Facial Plast Surg Clin N Am 31 (2023) 381–392
https://doi.org/10.1016/j.fsc.2023.04.001
1064-7406/23/© 2023 Elsevier Inc. All rights reserved.

Table 1
Phenotypic differences between the feminine and masculine face

Phenotypes	Feminine	Masculine
Face Shape[40]	Rounded and soft appearing, heart or inverted triangle shape	Angulated and square, with a pronounced jaw and chin
Hairline[41]	Lower, gentle curve, convex	Higher, M-shaped with temporal hairline recession
Frontal Bossing[1]	Smooth continuously round contour of frontal bone	Pronounced bony supraorbital ridge
Eyebrows[42]	Laterally peaked, above the superior orbital rim	Straight, on the superior orbital rim
Naso-Frontal Angle[43]	Obtuse	Acute
Nose[43]	Thin-based and concave, Supratip break, narrower dorsal esthetic lines	Wide and straight or convex, minimal Supratip break, convex dorsal esthetic lines
Lips[12]	Fuller vermilion, shorter cutaneous height, with more incisal show	Thin vermilion and elongated cutaneous upper lip, with less incisal show
Occlusal Plane[13]	More neutral occlusal plane	Flatter occlusal plane
Mandible[44]	Reduced mandibular body height	Increased mandibular body height, increased gonial splay
Gonial Angle[45]	Greater than 125°	<125°
Chin[45]	Small, pointed, or rounded, 20% shorter than in males[46]	Large, wide, square
Masseter[47,48]	Smaller muscle bulk	Bulky muscle
Thyroid Cartilage[49,50]	120° angle of cartilage	90° angle of cartilage

PREOPERATIVE ASSESSMENT

As transgender health and surgery advances toward equity, The World Professional Association for Transgender Health (WPATH) has published updates to their Standards of Care (SOC) since 1979,[2] with the goal of providing clinical guidance for safe and effective medical and surgical pathways for gender diverse people. Version 7 of the SOC, published in 2012, did not explicitly define the medical necessity of facial gender-affirmation surgery.[3,4] However, there have been several studies that show facial feminization can improve the feminine perception of the face,[5,6] improve quality of life,[7] and reduce misgendering.[8] Harmonizing a patient's facial form with their gender identity can also limit the patient's risk for targeting and interpersonal violence based on facial anatomic incongruence with an individual's gender identity.

Fig. 1. Preoperative frontal view of a patient planning on undergoing lower jaw facial feminization surgery.

Fig. 2. Preoperative three-quarter view of a patient planning on undergoing lower jaw facial feminization surgery.

Fig. 3. Preoperative right facial view of a patient planning on undergoing lower jaw facial feminization surgery.

Thus, there have been several international groups that have studied and advocated for the medical necessity of facial gender-affirming surgery,[3,9] which has since been included as medically indicated in the WPATH SOC Version 8.[10]

Preoperatively, patients will meet with their mental health provider and primary care provider before a surgical evaluation. The mental health provider will be able to thoroughly evaluate the patient's gender dysphoria and treat or support any comorbid mental health issue. Evaluation by their primary care provider will optimize any underlying medical conditions which could negatively impact the surgical outcomes. Generally, we prefer patients to have made a medical transition and have completed 1 year of hormone therapy, if they can safely do so and hormones are part of their gender identity. This allows for maximal end-organ effects of testosterone or estrogen to modify the skin and soft tissues so that the remaining dysphoric facial features that cannot be improved with hormone therapy can be identified and addressed directly with surgical intervention.[11]

A thorough preoperative dental and orthodontic evaluation should be performed in all cases with identification of baseline dentofacial disharmony, malocclusion, and the dental show being noted as these can have a dramatic effect on the perception of gender.[12,13] Treatment of dental caries or gingival disease preoperatively is essential to reduce the risk of infection.[14] If planning for orthognathic surgery, the patient must also be evaluated for the presence of third molars which may impact the osteotomy site.[15] Ideally, all patients under consideration for osseous facial gender-affirming surgery procedures should have attained skeletal maturity to assure the longevity of their final post-operative results.

Following these multidisciplinary consultations, the surgical team should additionally evaluate the medical, medication, dental, gender, and mental health history of the patient and also evaluate their face as a whole to determine the feminine and masculine characteristics, while listening to the patient's main areas of concern. Focusing on the lower third of the face, it is important to assess the occlusion, incisal show, bony prominence of the mandible including gonial splay, mandibular body prominence, chin vertical height, and sagittal projection for prognathism or retrognathism. Following skeletal assessment, it is also essential to examine the soft tissue envelope, mimetic muscle thickness, masseter muscle bulk at rest and with masticatory effort, prominent submandibular glands, evidence of prior soft tissue augmentation (fillers) or scarring, and the degree of generalized facial aging as evidence by soft tissue ptosis, perioral rhytids, nasojugal grooving, jowling as well as assessing the overall skin texture and

Fig. 4. Preoperative worm's eye view of a patient planning on undergoing lower jaw facial feminization surgery.

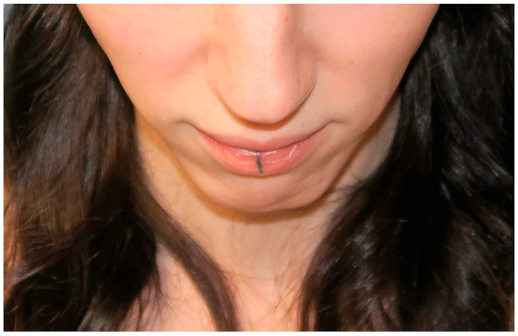

Fig. 5. Preoperative bird's eye view of a patient planning on undergoing lower jaw facial feminization surgery.

quality as these features will inform the need for either skeletal reduction or augmentation to assure optimal surgical results.

Standard preoperative facial photographs should be taken as these are often required when seeking insurance approvals for gender-affirming facial surgery. Advanced imaging modalities, specifically computed tomographic (CT) imaging of the head, face, and neck, can assist with planning of any osteotomies, bony contouring, bony augmentation, and identification of critical anatomic landmarks and facilitate surgical case execution. If pursuing preoperative virtual surgical planning, computer-aided design, or computer-aided manufacturing of cutting guides, splints, or osteosynthesis materials, CT imaging is essential (**Fig. 6**).[16] Our experience is in alignment with the existing research that has shown that the use of cutting guides for mandibular contouring and genioplasty decreases operative times and allows extremely precise and predictable results.[17]

Once the decision has been made to pursue surgery, all risks should be disclosed to the patient. These include risks of wound dehiscence, infection, osteomyelitis, dental injury, sensory nerve neuropraxias, or permanent paresthesia. Patients with active nicotine use are not candidates for facial gender-confirming procedures as the risk of complications is not trivial due to the vasoconstrictive effects and heat generated with smoking or vape delivery methods. Urine cotinine screening is utilized in patients with nicotine use history as part of our standard presurgical clearance pathway. For facial feminization surgery, it is recommended to discontinue estrogen 3 weeks before surgery until 3 weeks after surgery to decrease the risk of a venous thromboembolic event, yet definitive data on this are not robust and some centers continue estrogen throughout facial feminization. For facial masculinization surgery, testosterone can be continued but does carry an anecdotal increased risk of bleeding, but individuals are also assessed for the use of estrogen-containing menstrual suppression medications and a shared decision-making process is used to determine if they will be stopped or continued.

FACIAL FEMINIZATION

Preoperative planning should be performed weeks before the surgical date, to ensure adequate fabrication and transit time for any cutting guides or patient-specific fixation materials (see **Fig. 6**). Modification of the mandible and lower third of the face for facial feminization can be combined with other midfacial, upper facial, and nasal procedures, so the method of airway securement can vary, but we prefer an orotracheal intubation with the endotracheal (ET) tube secured to a maxillary first molar with a 26 gauge circumdental wire.

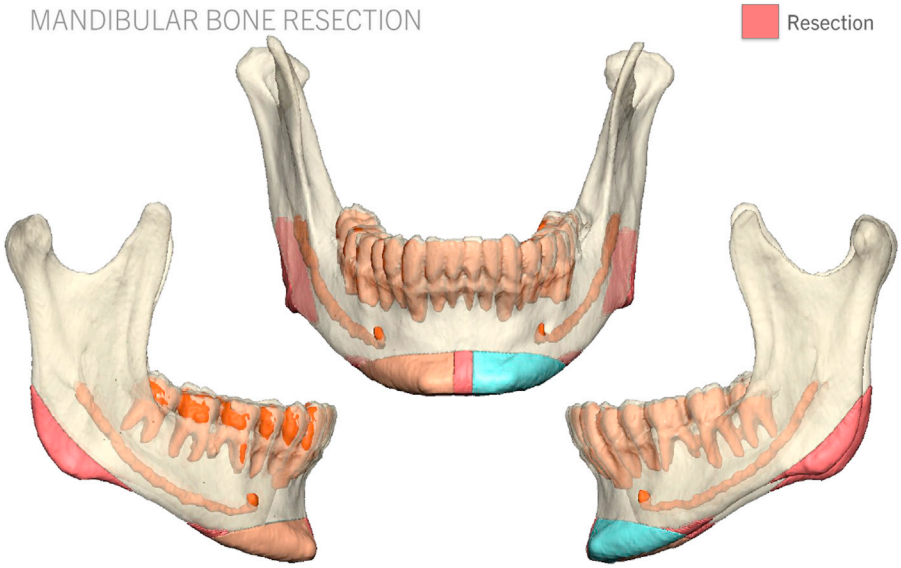

Fig. 6. Computer-aided surgical planning with the use of CT images for mandibular angle ostectomy and narrowing genioplasty allows for visualization of the inferior alveolar nerve along its entire course. In this patient, we planned bony reduction of the transverse and vertical jaw dimensions and softening of the gonial angles with an ostectomy of the buccal and lingual cortices of the mandibular angle, along with a narrowing and advancing genioplasty.

Before definitively securing the ET tube, the patient's neck is fully extended and flexed with the anesthesia team ensuring that ventilation is maintained throughout all positions, and once confirmed, the tube is fully secured with the surgical wire. A throat pack is placed in the pharynx, and the teeth are cleansed and brushed with chlorhexidine mouthwash. Antibiotics with oral flora coverage (ampicillin/sulbactam) are given preoperatively and re-dosed as indicated for time. The patient's face, head, and neck are typically prepped circumferentially with antibiotic irrigation given the need for a full head, hairline, face, and neck exposure for concurrent multilevel facial gender-affirming surgery procedures.

Key intraoral anatomic landmarks including the location of Stenson's ducts as well as the approximate location of the mental nerve should be noted and marked before designing incisions. The incision should be marked wide on the gingival mucosa to ensure that there is an adequate cuff of mucosa for closure. The length and position of the incisions are predicated on what regions of the mandible are going to be accessed to perform osteotomies or bony contouring. Some prefer to completely expose the mandible from angle to angle,[18] while others prefer a three-incision approach at the symphysis and bilateral body/angle region that are tunneled to connect subperiosteally, leaving a cuff of mucosa overlying the mental nerve as a way to reduce incisional burden.[19] Once incisions have been planned and marked, local anesthetic with epinephrine is given along the course of the planned incision for analgesic and vasoconstrictive effects.

Mandibular Angle and Body Contouring

After incision through the mucosa, the dissection is continued directly onto the buccal cortex of the mandible using monopolar electrocautery. Once down to the bone, a periosteal incision is carried out with electrocautery and subperiosteal dissection is used to expose the mandibular angle if gonial angle osteotomies or contouring is to be performed. Mesial extension of this incision toward the mental nerve can be completed to allow for exposure of the mandibular body if buccal cortex or inferior border contouring is required. When using cutting guides, it may be necessary to dissect a larger area to allow for the added bulk of a cutting guide and to allow for bone adaptation in the subperiosteal space (**Fig. 7**).

Once adequate exposure has been obtained, the bony contouring can include reduction of the transverse and/or vertical jaw dimensions and softening of the gonial angles (**Fig. 8**). This can entail ostectomy of the buccal and lingual cortices of the mandibular angle in isolation to increase the gonial angle and reduce gonial splay (Video 1) versus a complete reduction of the height of the mandible from angle to angle to shorten the vertical height of the lower third of the face.[19] When planning for aggressive bony reduction, one should always consider the reciprocal destabilizing effects on the overlying soft tissue envelope. For patients with generalized facial aging and premorbid soft tissue ptosis, aggressive reductive ostectomies can result in iatrogenic worsening of facial aesthetics and yield undesirable results. Consideration for selective expansion of the

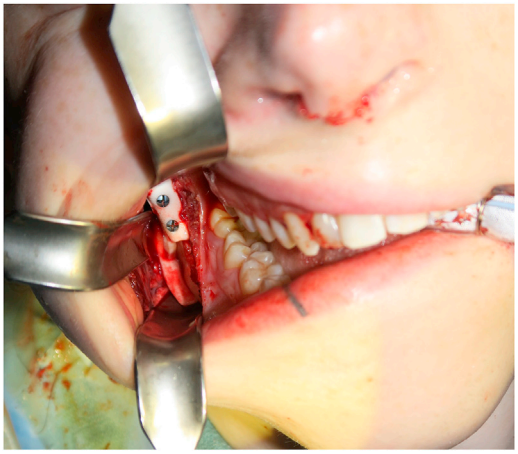

Fig. 7. Surgical approach to the right angle of the mandible through a lower gingivobuccal sulcus incision. The patient-specific cutting guide for a mandibular angle ostectomy is fixed in place before the ostectomy.

Fig. 8. Intra-operative photograph of the right mandibular angle ostectomy, as compared to a model of the patient's pre-operative mandibular morphology. Ostectomy included both buccal and lingual cortices of the mandibular angle reducing the transverse and vertical jaw dimensions and softening the gonial angles.

skeletal support via narrowing advancement genioplasty may be indicated in lieu of reductive ostectomies for some patients with generalized facial aging and baseline skeletal hypoplasia. Bony contouring can be performed with a rotary high-speed burr,[20] or a power rasp while osteotomies and ostectomies with the reciprocating saw,[21] sagittal saw, or a piezoelectric saw.[19] For ostectomies and osteotomies, our preference is to use the piezoelectric saw, as it minimizes the potential damage to adjacent structures[19] and has shown to have improved neurosensory recovery when compared to the reciprocating saw.[22] However, some have noted that using a piezoelectric saw may increase operative time and may be more expensive when compared to other modalities.[23] Preoperative CT imaging can identify the path of the inferior alveolar nerve through the mandible, which is helpful in avoiding nerve injury during bony contouring or ostectomy (see **Fig. 6**).

For a bicortical ostectomy, once the initial cortical cuts have been made, an osteotome is used to complete the osteotomy. If this posterior cut is difficult to visualize, a rigid endoscope can be utilized to facilitate visualization.[19] Due to the attachments of the medial pterygoid muscle, this fragment may migrate medially once the osteotomy is complete, and it will need to be controlled and dissected free of the medial muscular attachments.

If the patient has excessive masseteric bulk, the masseter can either be directly excised or injected with botulinum toxin. However, some reduction in muscle bulk should be expected simply due to atrophy from degloving the masseter off of the mandible.[24]

The wound is then irrigated with antibiotic irrigation and hemostasis is achieved using cautery, thrombin, gel foam, and other hemostatic agents as needed. The incision is then closed with 3-0 or 4-0 absorbable suture. The closure must be watertight, as saliva pools in the lower gingivobuccal sulcus over the incision and can predispose to infection if optimal closure is not achieved.

Genioplasty

After incision through the mucosa, the transverse fibers of the orbicularis oris muscle will be identified. These fibers should be elevated from the underlying submucosa until the sagittal fibers of the mentalis muscle are encountered. Once identified, the plane of dissection is brought up off the origin of the mentalis fibers' attachment to bone such that a robust cuff of mentalis muscle is preserved to allow for later resuspension of the muscle and soft tissue during closure. Failure to leave this cuff and resuspend the muscle can lead to a tendency toward lower lip incompetence and a "witch's chin" deformity.[25] Once the mentalis cuff has been preserved, the dissection plane is taken down directly to the bone with incision directly through the symphyseal periosteum. Subperiosteal dissection is then propagated inferiorly over the inferior border of the mandible. Often, the periosteal attachments are tenacious in the symphyseal region and may require both blunt dissection with a periosteal elevator and the use of the monopolar cautery to facilitate exposure. Once the inferior border of the mandible has been identified, it can be used as a guide to propagate the dissection postero-laterally and identify the mental foramina which can be approached inferior to superior with blunt dissection to ensure adequate protection of the nerve as it exits the foramina. Once identified, additional inferior border dissection can be performed below the nerve to connect to the posterior mandibular dissection plane if needed.

Once adequate exposure has been obtained, the genioplasty proceeds with the patient-specific goals to shorten, narrow, and/or advance or lengthen the chin (**Fig. 9**). The chin can be tapered or vertically shortened using basal ostectomies to reduce the volume or height of the chin (Video 2).[19] If the chin needs to be advanced, an osteotomy at least 5 mm inferior to the mental foramen can be performed using a traditional reciprocating or oscillating saw or with the piezoelectric saw. The genioplasty can then be secured with permanent osteosynthesis material (**Fig. 10**) which can also be customized to a desired pre-surgically planned position with a patient-specific plate. If the chin needs to be advanced, shortened, and narrowed, a T-shaped osteotomy can be performed.[26]

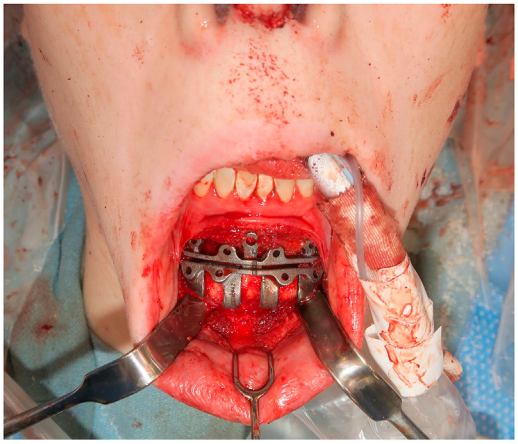

Fig. 9. Patient-specific cutting guide in place for a narrowing and advancing genioplasty.

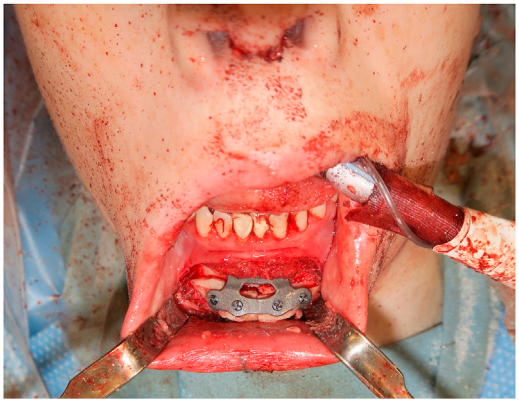

Fig. 10. Osteosynthesis material in place securing the genioplasty segments after the planned advancement and narrowing.

If the chin needs to be vertically lengthened, this can be performed with clockwise rotation of the genioplasty segment while maintaining posterior contact filling the created defect with interpositional bone grafts which can be repurposed from the gonial angle or inferior border ostectomies.[19] For augmentation, some authors have proposed using silicone chin implants, though our preference is to perform an osseous genioplasty as this provides the greatest freedom to idealize the chin position, shape, and contour and harmonize with the remainder of the facial form.[27]

Once the bony recontouring is complete, the wound is irrigated with antibiotic irrigation and hemostasis is confirmed. Before final closure, soft tissue resuspension must be performed to ensure readaptation of the overlying soft tissues to the new surgically improved mandibular contour. If a significant inferior border resection has been performed, the mylohyoid musculature resuspension can be completed using bone anchors or with drill holes along the inferior border.[19] The mentalis muscle should be reapproximated to avoid the "witch's chin" deformity.[25] The incision is then closed with 3-0 or 4-0 absorbable suture.

Preoperative and 1-month photographs of an individual who underwent mandibular angle contouring and genioplasty for mandibular facial feminization can be seen in **Figs. 11–13**.

FACIAL MASCULINIZATION

Facial masculinization is much less common than facial feminization, with sparse data in the literature and few surgeons with sizable experience.[28,29] This may be due to the profoundly masculinizing effects that exogenous testosterone can have on the facial skin texture, facial hair, and the anterior hairline which provide highly masculine facial appearance despite a lack of skeletal masculinization.[9] Most of the literature on facial masculinization has been performed on cis-men,[30] though the techniques will be the same for trans-men.

With facial feminization being largely reductive in nature, facial masculinization is largely additive. Bone, silicone rubber, porous polyethylene, or polyetheretherketone are all materials used to augment the craniofacial skeleton in facial masculinization.[30] The approaches to the craniofacial skeleton are similar between facial feminization and facial masculinization of the lower jaw, so the airway management, surgical preparation, and draping are similar.

The incision is similarly planned wide on the gingival mucosa to ensure a large cuff of mucosa remains for closure, and local anesthetic with epinephrine is infiltrated. The mandible can either be completely degloved[18] or accessed using a three-incision approach with cuffs of mucosa surrounding the mental nerves to again limit incisional burden.[19] With alloplastic implants, meticulous watertight closures are essential to avoid implant infection placed through lower buccal sulcus approaches.

Mandibular Angle Augmentation

When dissecting the angle of the mandible, care is taken to protect the pterygomasseteric musculature, as this is the vascular supply to the mandible in this area. To maximize the bone graft survival and wound healing around implants, adequate blood supply is essential.

Implants are designed to make the gonial angle more acute and produce a squarer lower jaw. They should be tapered appropriately along the body of the mandible. Before placing the implants, the authors prefer to thoroughly irrigate the wound with antibiotic irrigation and avoid any contact between the mucosa and the implant to reduce the contamination from intraoral bacteria. The implants are secured to the mandible with monocortical screws, and the incision is closed with 3-0 or 4-0 absorbable sutures. Watertight closure remains essential as saliva will pool in the lower gingivobuccal sulcus over the incision.

Another method for mandibular angle augmentation is autologous bone grafting from the iliac crest or calvarium. Mandibular augmentation with autologous onlay grafts between the mandible and the masseter results in bone resorption,[28] so the grafts should be placed interpositionally at the angle of the mandible. The buccal cortex is split from the angle and body of the mandible while maintaining the insertions of the masseter muscle, and the remaining mandible consists of an intact

Fig. 11. Preoperative and 1-month postoperative frontal view of the same patient from **Figs. 1–5** after undergoing mandibular angle reduction and advancement and narrowing genioplasty.

alveolar arch in continuity with condyle. The authors prefer to make this split with the piezoelectric saw and complete the inferior split with an osteotome. It is important to leave the inferior pterygomandibular ligament intact to maintain stability of the mandible. The bone graft is inserted in place and secured with osteosynthesis material. Donor site morbidity as well as bony resorption should be discussed with the patient preoperatively.

Autologous fat grafting is another method for angle or chin augmentation, though results can be unpredictable as fat grafting to highly mimetic areas of the face is often subject to increased resorption and may require serial augmentation. Fat is harvested using standard liposuction techniques, rolled on nonstick gauze pads to process the fat, and is injected along the mandible in a supraperiosteal plane.

Fig. 12. Preoperative and 1-month postoperative right facial view of the same patient from **Figs. 1–5** after undergoing mandibular angle reduction and advancement and narrowing genioplasty.

Fig. 13. Preoperative and 1-month postoperative bird's eye view of the same patient from **Figs. 1–5** after undergoing mandibular angle reduction and advancement and narrowing genioplasty.

Genioplasty

Chin masculinization can be performed with alloplastic implants or a bony genioplasty. Implants can aid in accentuating width and sagittal projection but cannot reliably increase the vertical height. Bony genioplasty alternatively can achieve increases in width, height, and projection, though it may need to be supported with interpositional bone grafts for large advancements or lengthening. Implants can either be placed through an intraoral or submental incision.[30]

The intraoral incision should be planned with a wide cuff of mucosa, infiltrated with local anesthesia with epinephrine, and incised down until there is the identification of the mentalis muscle. A large cuff of mentalis muscle should be left to allow for soft tissue and muscle resuspension. The chin is then dissected subperiosteally while protecting the mental nerves. Once adequately exposed, chin implants can be carefully placed and secured to the mandible similar to mandibular angle implants.

The osteotomy for the genioplasty should be designed to achieve the desired changes. To increase the vertical height and projection of the chin, a transverse osteotomy can be designed at least 5 mm below the mental foramen to avoid damage to the inferior alveolar nerve.[31] If the chin needs to be widened, a T-shaped osteotomy should be planned. The authors prefer to use a piezoelectric saw or reciprocating saw for the osteotomy. Any bony gaps in the genioplasty should be filled with autologous bone, bone allograft, or hydroxyapatite granules mixed with blood. The bony segments should be fixated with osteosynthesis material. The wound is thoroughly irrigated with antibiotic irrigation, the mentalis muscle is reapproximated, and the incision is then closed with 3-0 or 4-0 absorbable suture.

POSTOPERATIVE CARE

Lower jaw contouring for gender affirmation can be performed as an outpatient surgery, though patients are often admitted for observation when performed in conjunction with other procedures on the forehead and midface. The largest series on mandibular facial feminization surgery reports that 95% of patients underwent additional feminization procedures, most commonly forehead reconstruction, chondrolaryngoplasty, or rhinoplasty.[19]

Swelling following facial procedures can be significant, so ice packs or controlled cooling therapy are recommended for the first 24 to 48 hours postoperatively.[32] Care must be taken with ice packs to avoid frostbite. Head of bed elevation and compression therapy are also recommended for 6 weeks after surgery which help control edema and assist with soft tissue adaptation to the underlying changes to the neo-mandibular contour. Patients should be counseled that full soft tissue readaptation can take months as there will be initial memory of the soft tissue envelope which may obscure the osseous changes. However, with additive time from surgery, the new mandibular contour will become evident.

As most incisions are within the mouth, excellent oral hygiene is needed to prevent infections. We recommend the use of antiseptic prescription mouthwash for 7 to 10 postoperatively twice daily with salt water rinses after meals. Gentle brushing of teeth can be initiated 48 hours after surgery with a soft bristle toothbrush and over-the-counter mouthwash can be utilized following

discontinuation of the prescription mouthwash for 3 weeks. The patients should be limited to a soft diet for 4 weeks, to prevent hard pieces of food pressing through the suture line. Postoperative antibiotic prophylaxis regimens can be variable, but the authors prefer 24 hours of antibiotics for bone grafts and 7 days for larger structural alloplastic implants in masculinizing procedures.

COMPLICATIONS

The risks of lower jaw contouring procedures include infection, bleeding, wound dehiscence, bony contour abnormalities, unfavorable osteotomy propagation, iatrogenic fractures, nonunion or bone resorption, injury to the dentition, implant malposition, hardware failure, nerve injury, "witch's chin" deformity, or soft tissue ptosis.

An infection could manifest as simple cellulitis, abscess, implant infection, or osteomyelitis. Bony contour abnormalities can remodel and resolve over time, and patients should be counseled regarding an initial course of expectant management with close follow-up for persistent concerns. Infection risks are increased with poor dentition, so preoperative dental evaluation and optimization are essential. Preoperative tooth brushing with an antiseptic mouthwash and regular intraoperative antibiotic irrigation may also reduce the risk of infection.

If a genioplasty was performed, numbness of the lower lips and chin from mental or inferior alveolar nerve neuropraxia is common and is often self-limited.[33] Patients can be counseled that sensation should recover as long as there was no nerve transection, however, diminished or altered sensation can persist for up to 9 to 12 months. Older patients are at higher risk for the prolonged recovery of neurosensory function.

"Witch's chin" deformity can occur due to inadequate resuspension of the mentalis muscle, which results in chin soft-tissue ptosis and a tendency toward oral incompetence. Excessive bony reduction during feminizing procedures can result in a loss of support for the overlying facial soft tissues. Iatrogenic jowling can lead to an undesirable result and may require additional surgical treatment, such as a rhytidectomy or neck lift which fall outside of the typical procedures specifically addressing gender dysphoria.[34] Recognition of this has led to some centers counseling patients older than 45 years planning to undergo mandibular border excision exceeding 5 mm that there may be a need for a future face or neck lift surgery.[19]

Most of these complications can be treated nonoperatively and many large series report few complications.[19,35–38]

OUTCOMES

Data on facial gender-affirming surgery significantly differ between facial feminization and masculinization as previously discussed. There is a plethora of data reporting that facial feminization improves the feminine appearance of patients[5,6] and improves the quality of life and patients are highly satisfied.[7] There are fewer reports on the outcomes of gender-affirming facial masculinization as this procedure is much less common due to the highly masculinizing impact of exogenous testosterone. However, small series specifically evaluating facial masculinization have similarly shown high patient satisfaction.[28,29]

Patients seeking facial gender-affirming surgery seek to align their facial appearance with their gender identity and reduce their exposure to social stigma, targeting, and potential interpersonal violence stemming from their morphologic facial gender incongruence. Evidence has shown that facial gender-affirming procedures can be highly effective toward this end. Fisher and colleagues surveyed the public to identify the gender of a patient through a photograph, and facial feminization surgery increased the female gender-typing of these patients from 57% preoperatively to 94% postoperatively.[5] Chen and colleagues performed a study using artificial intelligence and convolutional neural networks to identify the gender of a facial photograph.[6] They found that facial feminization surgery significantly improved the gender-typing of patients when compared to preoperative values.[6]

Ainsworth and Spiegel performed a retrospective study on 247 transfeminine patients in 2010, where 75 underwent facial gender-affirming surgery and 172 did not.[8] They found that transgender women had significantly decreased mental health quality of life compared with the cis-feminine population, though this significantly improved following facial feminization.[8] The same patient-reported outcome tool was used prospectively by Morrison and Capitán in 2020, and they similarly found that facial feminization surgery improved the facial feminization outcome scores in both short term and long term.[7] Additional patient-reported outcome measures have shown significant improvements in anxiety, anger, depression, meaning and purpose, social isolation, and overall positive affect following facial gender-affirming surgery.[39]

SUMMARY

Mandibular contouring is a safe and effective way to masculinize or feminize the face for facial

gender-affirming surgery. Facial feminization is largely reductive in nature, aiming to decrease the lower facial width, decrease the chin height, and soften the gonial angle. Facial masculinization is largely additive in nature, with bone grafting or alloplastic augmentation of the mandibular angles and chin. Facial feminization successfully feminizes the face, decreases misgendering, and increases mental health quality of life. Facial masculinization is less common, secondary to the profound masculinizing impact of testosterone.

CLINICS CARE POINTS

- Ensure dental and orthodontic evaluation occurs as part of the preoperative assessment
- Preoperative imaging and virtual planning can be used to augment approaches and identify important structures
- Evaluate facial ptosis prior to reductive procedures to minimize risk of iatrogenic jowling
- Leave healthy cuffs of tissue to sew to during incision planning5) Neuropraxia's are common after lower jaw contouring

SUPPLEMENTARY DATA

Supplementary data related to this article can be found online at https://doi.org/10.1016/j.fsc.2023.04.001.

REFERENCES

1. Ousterhout DK. Feminization of the forehead: Contour changing to improve female aesthetics. Plast Reconstr Surg 1987;79(5):701–11.
2. World Professional Association for Transgender Health. Standards of care for the health of transsexual, transgender, and gender nonconforming people. 7th Edition 2012.
3. JU Berli, Capitán L, Simon D, et al. Facial gender confirmation surgery—review of the literature and recommendations for Version 8 of the WPATH Standards of Care. Int J Transgenderism 2017;18(3):264–70.
4. Coleman E, Bockting W, Botzer M, et al. Standards of Care for the Health of Transsexual, Transgender, and Gender-Nonconforming People, Version 7. Int J Transgenderism 2012;13(4):165–232.
5. Fisher M, Lu SM, Chen K, et al. Facial Feminization Surgery Changes Perception of Patient Gender. Aesthetic Surg J 2020;40(7):703–9.
6. Chen K, Lu SM, Cheng R, et al. Facial Recognition Neural Networks Confirm Success of Facial Feminization Surgery. Plast Reconstr Surg 2020;145(1):203–9.
7. Morrison SD, Capitán-Cañadas F, Sánchez-Garciá A, et al. Prospective Quality-of-Life Outcomes after Facial Feminization Surgery: An International Multicenter Study. Plast Reconstr Surg 2020;145(6):1499–509.
8. Ainsworth TA, Spiegel JH. Quality of life of individuals with and without facial feminization surgery or gender reassignment surgery. Qual Life Res 2010;19(7):1019–24.
9. Coon D, Berli J, Oles N, et al. Facial Gender Surgery: Systematic Review and Evidence-Based Consensus Guidelines from the International Facial Gender Symposium. Plast Reconstr Surg 2022;149(1):212–24.
10. Coleman E, Radix AE, Bouman WP, et al. Standards of Care for the Health of Transgender and Gender Diverse People, Version 8. Int J Transgend Health 2022;23:1–259.
11. Hembree WC, Cohen-Kettenis P, Delemarre-Van De Waal HA, et al. Endocrine treatment of transsexual persons: An endocrine society clinical practice guideline. J Clin Endocrinol Metab 2009;94(9):3132–54.
12. Salibian AA, Bluebond-Langner R. Lip Lift. Facial plastic surgery clinics of North America 2019;27(2):261–6.
13. Antonarakis GS, Kiliaridis S, Scolozzi P. Orientation of the occlusal plane in a Class i adult population. Oral Surgery, Oral Medicine, Oral Pathology and Oral Radiology 2013;116(1):35–40.
14. Ludwig DC, Morrison SD. Should Dental Care Make a Transition? JADA (J Am Dent Assoc) 2018;149(2):79–80.
15. Morrison S, Ettinger RE, Kapadia H, et al. Bimaxillary Surgery with Occlusal Plane Alterations: A New Frontier for Gender Confirmation? Plast Reconstr Surg 2020;146(4):518e–9e.
16. Tawa P, Brault N, Luca-Pozner V, et al. Three-Dimensional Custom-Made Surgical Guides in Facial Feminization Surgery: Prospective Study on Safety and Accuracy. Aesthetic Surg J 2021;41(11):NP1368–78.
17. Gutiérrez-Santamaría J, Simon D, Capitán L, et al. Shaping the lower jaw border with customized cutting guides: development, validation, and application in facial gender-affirming surgery. Facial Plast Surg Aesthet Med 2022. https://doi.org/10.1089/fpsam.2021.0418.
18. Morrison SD, Satterwhite T. Lower Jaw Recontouring in Facial Gender-Affirming Surgery. Facial Plastic Surgery Clinics of North America 2019;27(2):233–42.
19. Simon D, Capitán L, Bailón C, et al. Facial Gender Confirmation Surgery: The Lower Jaw. Description of Surgical Techniques and Presentation of Results. Plast Reconstr Surg 2022;149(4):755e–66e.
20. Zhang C, Ma MW, Xu J-J, et al. Application of the 3D digital ostectomy template (DOT) in mandibular

angle ostectomy (MAO). Journal of cranio-maxillofacial surgery 2018;46(10):1821–7.
21. Park S, Lee TS. Strategic Considerations for Effective Sagittal Resection of the Mandible to Achieve a Slim and Attractive Jawline. Plast Reconstr Surg 2018;141(1):152–5.
22. Sobol DL, Hopper JS, Ettinger RE, et al. Does the use of a piezoelectric saw improve neurosensory recovery following sagittal split osteotomy? Int J Oral Maxillofac Surg 2022;51(3):371–5.
23. Pavlíková G, Foltán R, Horká M, et al. Piezosurgery in oral and maxillofacial surgery. Int J Oral Maxillofac Surg 2011;40(5):451–7.
24. Altman K. Facial feminization surgery: current state of the art. Int J Oral Maxillofac Surg 2012;41(8):885–94.
25. Zhang BH, Byrd R, Bradley C, et al. Osseous Genioplasty: Prevention of Witch's Chin Deformity with No-Degloving Technique. Plast Reconstr Surg 2021;148(5):720e–6e.
26. Jegal JJ, Kang SJ, Kim JW, et al. The utility of a three-dimensional approach with T-shaped osteotomy in osseous genioplasty. Archives of Plastic Surgery 2013;40(4):433–9.
27. Newberry CI, Mobley SR. Chin Augmentation Using Silastic Implants. Facial Plast Surg 2019;35(2):149–57.
28. Ousterhout DK. Dr. Paul Tessier and facial skeletal masculinization. Ann Plast Surg 2011;67(6):10–5.
29. Deschamps-Braly JC, Sacher CL, Fick J, et al. First Female-to-Male Facial Confirmation Surgery with Description of a New Procedure for Masculinization of the Thyroid Cartilage (Adam's Apple). Plast Reconstr Surg 2017;139(4):883e–7e.
30. Straughan DM, Yaremchuk MJ. Improving Male Chin and Mandible Eesthetics. Clin Plast Surg 2022;49(2):275–83.
31. Lin HH, Denadai R, Sato N, et al. Avoiding inferior alveolar nerve injury during osseous genioplasty: A guide for the safe zone by three-dimensional virtual imaging. Plast Reconstr Surg 2020;148(2):847–58.
32. Capitán L, Santamaría JG, Simon D, et al. Facial gender confirmation surgery: A protocol for diagnosis, surgical planning, and postoperative management. Plast Reconstr Surg 2020;145(4):818E–28E.
33. Susarla SM, Ettinger RE, Dodson TB. Is It Necessary to Free the Inferior Alveolar Nerve From the Proximal Segment in the Sagittal Split Osteotomy? J Oral Maxillofac Surg 2020;78(8):1382–8.
34. Rochlin DH, Morrison SD, Harirah M, et al. Face Lift after Facial Feminization Surgery: Indications and Special Considerations. Plast Reconstr Surg 2022;149(1):107–15.
35. Tirrell AR, Abu El Hawa AA, Bekeny JC, et al. Facial Feminization Surgery: A Systematic Review of Perioperative Surgical Planning and Outcomes. Plastic and Reconstructive Surgery - Global Open 2022;10(3):E4210.
36. Gupta N, Wulu J, Spiegel JH. Safety of Combined Facial Plastic Procedures Affecting Multiple Planes in a Single Setting in Facial Feminization for Transgender Patients. Aesthetic Plast Surg 2019;43(4):993–9.
37. Raffaini M, Magri AS, Agostini T. Full Facial Feminization Surgery: Patient Satisfaction Assessment Based on 180 Procedures Involving 33 Consecutive Patients. Plast Reconstr Surg 2016;137(2):438–48.
38. Telang PS. Facial Feminization Surgery: A Review of 220 Consecutive Patients. Indian J Plast Surg 2020;53(2):244–53.
39. Caprini RM, Oberoi MK, Dejam D, et al. Effect of Gender-affirming Facial Feminization Surgery on Psychosocial Outcomes. Ann Surg 2022. https://doi.org/10.1097/SLA.0000000000005472.
40. Morrison SD, Vyas KS, Motakef S, et al. Facial Feminization: Systematic Review of the Literature. Plast Reconstr Surg 2016;137(6):1759–70.
41. Capitán L, Simon D, Bailón C, et al. The Upper Third in Facial Gender Confirmation Surgery: Forehead and Hairline. J Craniofac Surg 2019;30(5):1393–8.
42. Sedgh J. The Aesthetics of the Upper Face and Brow: Male and Female Differences. Facial Plast Surg 2018;34(2):114–8.
43. Bellinga RJ, Capitán L, Simon D, et al. Technical and clinical considerations for facial feminization surgery with rhinoplasty and related procedures. JAMA Facial Plastic Surgery 2017;19(3):175–81.
44. Ousterhout DK. Mandibular angle augmentation and reduction. Clin Plast Surg 1991;18(1):153–61.
45. Hage JJ, Becking AG, De Graaf FH, et al. Gender-confirming facial surgery: Considerations on the masculinity and femininity of faces. Plast Reconstr Surg 1997;99(7):1799–807.
46. Deschamps-Braly JC. Approach to feminization surgery and facial masculinization surgery: Aesthetic goals and principles of management. J Craniofac Surg 2019;30(5):1352–8.
47. Balaji SM, Balaji P. Square Face Correction by Gonial Angle and Masseter Reduction. Annals of Maxillofacial Surgery 2018;10(1):66–72.
48. Sella-Tunis T, Pokhojaev A, Sarig R, et al. Human mandibular shape is associated with masticatory muscle force. Sci Rep 2018;8(1):6042.
49. Wolfort FG, Parry RG. Laryngeal Chondroplasty for appearance. Plast Reconstr Surg 1975;56(4):371–4.
50. Wolfort FG, Dejerine ES, Ramos DJ, et al. Chondrolaryngoplasty for appearance. Plast Reconstr Surg 1990;86(3):464–9. discussion 470.