Feminization of the Chin
Genioplasty Using Osteotomies

Jordan Deschamps-Braly, MD, FACS

KEYWORDS

• Sliding genioplasty • Chin feminization • Osseous genioplasty • Facial feminization surgery • FFS • Facial gender confirmation surgery

KEY POINTS

- Male and female chins have markedly different characteristics, so chin reshaping is an important part of facial feminization surgery.
- Chin reshaping can change the chin's width, height, and contour, as well as correcting chins that are too prominent, recessed, or asymmetrical.
- The sliding osseous genioplasty is the most effective approach for creating a chin with a dramatically different female shape.
- Keeping 6 mm or more below the inferior border of the mental nerve canal during osteotomies performed in sliding genioplasty greatly reduces any risk of injury to the nerve.
- Virtual techniques can be used for each genioplasty to precisely plan each surgery to achieve the best aesthetic results and ensure safety.

INTRODUCTION

Chin reshaping is often a crucial part of facial feminization, because the chin plays such a large part in gender recognition. Men's chins are taller, wider, and often more projected than women's chins, which tend to have a softer, more tapered or oval appearance. Although the differences may seem subtle or inconsequential to an untrained observer, reducing the height of a chin by what amounts to millimeters can make a tremendous difference in the appearance of a male-to-female (MTF) transgender patient.

Because the chin is such an identifiable marker of gender, it needs to be altered in almost all feminization procedures to achieve the most aesthetic and feminine effects. We have performed facial feminization (FFS) on hundreds of transgender patients, and my associate, Douglas Ousterhout, has performed similar surgeries on close to 1500 patients. Between us, we found sliding genioplasty to be beneficial in all but a handful of patients who presented to our clinic. In fact, close to 99% of transgender patients will need to have their chins reshaped during facial feminization.

A male chin is on average approximately 20% taller than a female chin, and the male chin is also wider, with paired prominences that add to its square appearance. Besides changing the chin's width, height, and contour, a surgeon can refashion the face to correct chins that are too prominent, too recessed, or asymmetrical during FFS. The "sliding," or more appropriately called "osseous," genioplasty is the preferred and only effective approach for safely creating a more feminine shape (**Fig. 1**).

CONTENT

The sliding or osseous genioplasty is used to modify the chin by sectioning the chin and removing and or repositioning segments of the

Disclosure Statement: The author has no conflicts of interest or financial relationships that would influence our recommendations.
Deschamps-Braly Clinic of Plastic & Craniofacial Surgery, 360 Post Street, Suite 901, San Francisco, CA 94108, USA
E-mail address: info@deschamps-braly.com

Facial Plast Surg Clin N Am 27 (2019) 243–250
https://doi.org/10.1016/j.fsc.2019.01.002
1064-7406/19/© 2019 Elsevier Inc. All rights reserved.

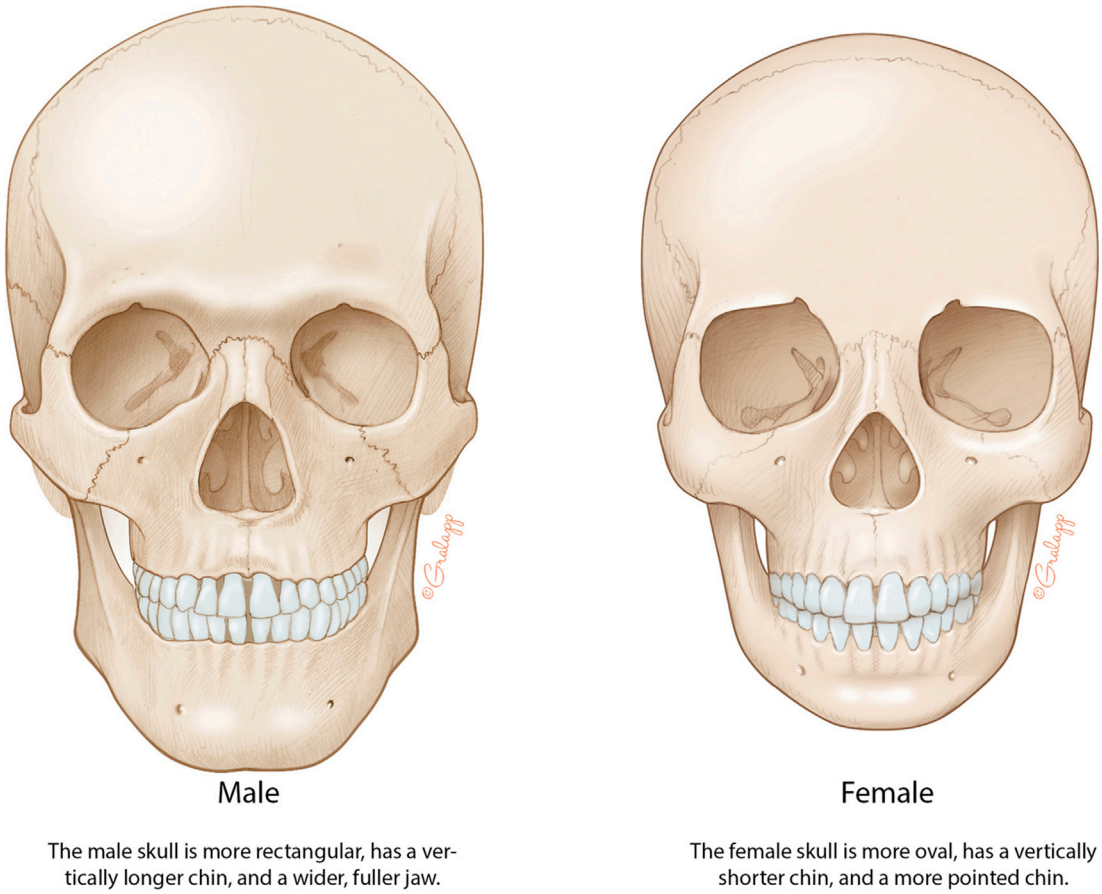

Fig. 1. Comparison of the male versus the female chin. (Illustration ©2018 Chris Gralapp.)

bone and is thus the most effective approach for creating a female chin. By contrast, chin implants make the chin larger in one dimension or another, and, therefore, are counterproductive for most MTF transgender patients. Surface contouring by simple burring the "excess" bone is also unsatisfactory because it does not change the chin's prominence or height appreciably. To be successful in burring the excess bone, the amount of bone removed would need to be so large that the cancellous bone would be totally exposed. This would result in contour irregularities—a truly undesirable complication.

The first detailed review on feminization of the chin with 485 cases was published by my associate, Douglas Ousterhout, MD, DDS, FACS, in 2003.[1] Genioplasty was first described by Otto Hofer[2] in 1942, who published a description of a sliding advancement genioplasty performed on a cadaver via an external approach. Gillies and Millard[3] published the first scientific report of a genioplasty on a living patient in 1957, performed with an extraoral approach. The first modern osseous genioplasties were performed for microgenia after it became understood that placement of bone grafts on the anterior surface of the chin tended to resorb with recurrence of the original deformity.

Trauner and Obwegeser[4] and Converse and Wood-Smith[5] later described sliding advancement genioplasties performed with an intraoral approach, published respectively in 1957 and 1964. It was not until the 1970s and 1980s, however, that the first descriptions of chin height reductions with wedge ostectomy were published by Hohl and Epker (1976)[6] and McBride and Bell (1980).[7]

In 1987, Wolfe[8] fully described methods for altering the vertical dimensions of the chin by shortening or lengthening it. In his report, Wolfe[8] noted that the results of chin lengthening had improved with the use of fixation by small plates. The technique described by Wolfe[8] for shortening the chin involved moving bone above the lower border of the symphysis, while preserving the muscular attachments to the lower border. The bone was then reattached to the remaining upper mandibular segment.[7,8] The methods described by Wolfe[8] have now been modified so that a

T-osteotomy of the chin is used to achieve vertical height or width reduction in FFS, and less commonly, advancement or setback.

Wolfe[8] noted in his 1987 paper that the extent of chin shortening could be limited by the position of the mental nerve. In fact, mental nerve injuries have long been a concern with sliding genioplasties, although the true incidence of these injuries has never been adequately documented. Yet in 1996, Ousterhout[9] reported on a prospective case series in which a method was used to successfully avoid mental nerve injuries.

Ousterhout's technique was based on an anatomic and radiographic study published in 1992,[10] which showed that there were no cases in which the mental nerve's course put it more than 5.5 mm below the inferior border of the mental foramen. Thus, all 50 osteotomies that were performed as part of Ousterhout's prospective case series were at least 6 mm below the inferior border of the mental nerve canal.

The results of Ousterhout's study[9] revealed that there were no mental nerve injuries among the patients who were part of the 50 prospective case cases. Ousterhout[9] then compared these results with those of his preceding 50 cases in which the distance of the osteotomy from the mental nerve was not recorded. Among these patients there were 3 permanent injuries:

- One bilateral complete numbness
- One unilateral complete numbness
- One unilateral partial numbness

In the 1992 study published in the *Journal of Craniofacial Surgery*, Ritter and colleagues[10] found that the course of the inferior alveolar neurovascular canal could be highly variable. In fact, the distance between the inferior border of the mandible to the lowest point in the inferior alveolar canal ranged from 2 to 11 mm in 52 cases assessed with radiographs. The position of the mental foramen also varied, ranging from 6 to 21 mm above the caudal border of the mandible in these cases; yet, the lowest point in the course of the nerve was always less than 6 mm.

The study suggested that the mental foramen was a useful landmark for the anterior intramandibular course of the inferior alveolar nerve. Low mental foramens in general correlated with low-lying nerves in the case series. The study supported the necessity of visually identifying the mental foramen with radiographs before sliding genioplasty, and performing the osteotomy at a minimum of 6 mm below the inferior margin of the mental foramen to avoid nerve injury.

"For many plastic surgeons, the idea of working with bone seems unfathomable, far too complicated and dangerous, and beyond the scope of their practice," Dr Ousterhout[9] wrote in his 1996 article. Thus, many plastic surgeons prefer to fix a retruded chin with an implant. Yet this is a relatively blind procedure and may result in mental nerve injuries from the procedure itself or the implants. Experience with implants has improved over time; however, problems still exist. Implant malposition is one of the most common things we see when problems with implants arise. In addition to an unfavorable appearance, I have personally seen erosion of malpositioned implants through the outer table of bone that resulted in the following:

- Loss of all 4 lower incisors
- Implant malposition that caused mental nerve paresthesias
- Capsules around the nerve causing something approximating mentalis strain

Other issues with implants are less common.

It cannot be said that osseous genioplasty is without some risk of complications; however, feminizing a chin, reducing the height of the chin, setting back a prominent chin, and correcting asymmetries cannot be performed with an implant. They require bony facial contouring procedures. Therefore, learning to perform these procedures well is imperative. Maintaining 6 mm or more below the inferior border of the mental nerve canal during sliding genioplasty cannot always rule out an injury to the nerve, but it greatly reduces the risk of such damage.

Before performing any genioplasty, we obtain a Panorex radiograph and a posterior to anterior and lateral cephalograms. In addition, I obtain a computed tomography (CT) scan of the patient's facial bones as well as 3D-dimensional scans of the teeth. Taken together along with good clinical photographs, these studies help to determine precisely what must be done during the sliding genioplasty.

The cephalometric measurements of each patient will be evaluated against various published male and female standards. The radiographs and CT scan are also used to mark the path of the inferior alveolar nerve along the lower border of the mandible and the precise position of the exit of the right and left mental nerves. It's also crucial to evaluate the relationship of the patient's chin to her facial configuration, especially the profile. Although the front and back positions of the chin vary tremendously in attractive people, they are always in balance with other facial areas. Published

norms are a useful guideline, but one also needs the ability to visualize a pleasing profile for the patient and to determine which movements of the chin can approximate the intended shape and profile.

We use these measurements because they are necessary, but we also keep beauty and aesthetics in mind while developing our surgical plans. Because we are trying to achieve precise facial proportions, changes of only a few millimeters to the chin can make a big difference in feminizing the face. We have taken the chin height down as little as 2 mm and as much as 19 mm, although the amount removed varies from person to person.[11]

We also occasionally use virtual planning techniques to plan genioplasties. CT scans help us establish the guidelines for each genioplasty to achieve the most aesthetic and feminine results. With virtual planning, we can produce surgical guides that can ensure that the results we planned using CT scans are translated into real life. Virtual planning is not used in every case. Yet if certain details of the case call for it, the additional expense incurred in generating the guides and trying the surgery first in a virtual environment can be worth it.[11]

During the procedure, we work through incisions placed inside the mouth to avoid externally visible scars. The initial incision is made in the mobile gingiva, usually from the first molar on each side, which exposes the entire chin, including the mental nerves near the first and second bicuspid teeth root tips. We then do some basic contouring to remove any paired prominences that may be present. From there, we reduce height by first removing a horizontal piece of jawbone and then decrease width by cutting out a vertical segment. More often than not, these 2 maneuvers are performed simultaneously by removing a "T"-shaped piece of bone (**Fig. 2**). The remaining bone is then slid into place before securing it with a central titanium plate and screws. It is important to understand that ostectomy of the inferior border of the chin should be avoided. This creates a sharp edge that is palpable and has a high risk for disturbing the insertions of the genioglossus and anterior belly digastric muscles. This predisposes the patient to loss of cross-sectional airway volume.

Segmentation of the chin also requires additional placement of osteosynthesis plates laterally to stabilize the lateral chin segments. In a final step, we contour any edges that may be palpated due to the osteotomy. Although I use preoperative radiographs as a guide to excise bone for width reduction, I make the final decision about how much bone to remove and how much to contour the lateral prominences in the operating room.

As with jaw tapering, one of the most limiting factors to any chin surgery, particularly width reduction, is the basic shape of the dental arch. Whether it is tapered, oval, or square, the dental arch houses the roots of the teeth and mental

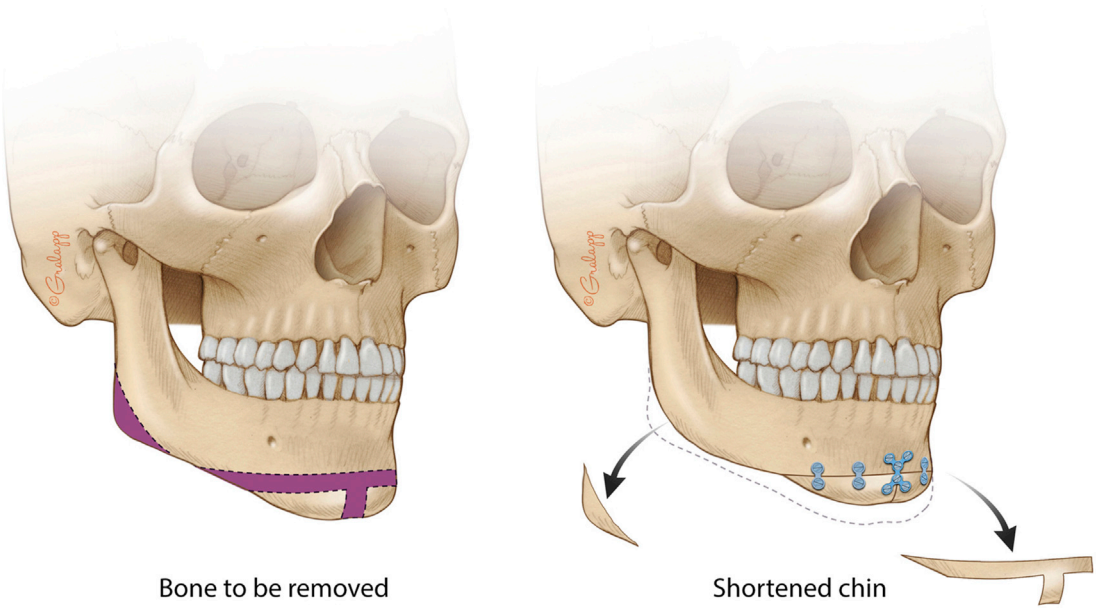

Fig. 2. T-osteotomy of the chin with vertical and horizontal height reduction. (Illustration ©2018 Chris Gralapp.)

nerve, and all must be protected during surgery. This ensures safety, while we endeavor to make the face aesthetically pleasing and attractive.

Although the chin height is excessive in most transgender individuals, approximately 2% of patients need their chin heights increased. In these sliding genioplasties and osteotomies, we reposition the lower segment downward after the bone is cut horizontally. This creates space for new bone growth.

The segments are then stabilized with plates and screws. To help support the area temporarily, we insert a paste made from the patient's own blood. In addition, we insert the bone filler hydroxyapatite, made of sterile processed coral, and Avitene into the space, which provides excellent support until the bone develops.

Advancing a receding chin also can have a dramatic effect on anyone's face, particularly an MTF individual. Moving the chin forward as little as 3.2 mm or as much as 15.9 mm can markedly improve the patient's profile and appearance, while making the neck appear tighter and more attractive. To advance the chin, we make a horizontal cut in the lower mandible jaw and reduce the vertical excess. The inferior or lower portion of the bone is then slid forward and anchored in place with stabilizing titanium plates.

If a patient needs an advance that measures more than 10 mm, she is cautioned to wear a chinstrap for 6 weeks after surgery until the bone is completely healed. The length and cantilever-type projection of such chin advancements are so far forward that every movement of the geniohyoids will pull the chin downward. The chinstrap has been very successful in preventing a relapse or a downward rotation of the prominent chin in our practice.

With an advancement of more than 6.4 mm, patients can experience an unattractive deepening of the sublabial sulcus. However, this can be addressed during the surgery. We treat it by placing a small amount of hydroxyapatite paste into the area as filler (**Figs. 3** and **4**).

The plates we use during genioplasties result in rigid fixation of the chin and along with maintaining some periosteal attachments to the chin segments, reduce the likelihood of bone resorption. By using the sliding genioplasty, we can also affect much greater advancement than we could with implants. The sliding genioplasty also narrows the chin, rather than widening it during FFS (**Figs. 5** and **6**).

The sliding genioplasty technique also can be used to reduce a prominent chin. After the bone cuts, the lower segments are positioned posteriorly for better alignment with the remainder of

Fig. 3. Preoperative and postoperative large sliding genioplasty of 15 mm with use of hydroxyapatite granules. (*Courtesy of* Jordan Deschamps-Braly, MD, San Francisco, CA.)

Fig. 4. Preoperative and postoperative large sliding genioplasty of 15 mm with use of hydroxyapatite granules. (*Courtesy of* Jordan Deschamps-Braly, MD, San Francisco, CA.)

Fig. 5. Lateral view after chin osteotomy with vertical height reduction, narrowing, and advancement. (Courtesy of Jordan Deschamps-Braly, MD, San Francisco, CA.)

Fig. 6. Frontal view after chin osteotomy with vertical height reduction, narrowing, and advancement. (*Courtesy of* Jordan Deschamps-Braly, MD, San Francisco, CA.)

the features. Unfortunately, there is a limit to how much a surgeon can realistically set the bone back without affecting the submental-cervical angle. A setback of more than 5 mm usually causes skin and underlying tissue to accumulate between the chin and upper neck. If the bone is set back too far, we cannot achieve a truly clean, trim angle and the neck will appear fuller and more aged.

Correcting chin asymmetries can be accomplished with an osseous genioplasty technique as well. With this approach, we remove and asymmetrically reposition segments of bone to correct the imbalance. Usually the chin would be segmented, which allows differential movement of the segments. In performing these maneuvers, our aim is to improve the symmetry of the inferior border of the chin, the midline of the chin, and any asymmetry of the chin prominences. Chin asymmetry is not a common problem, but it occurs occasionally, and when it does, it must be corrected.

Over the years, we have revised many sliding genioplasties and chin implant operations performed by other surgeons. Patients have come to us because their previous surgeries did not result in a properly feminized chin or they had complications from the inserted implants. In patients who have had implants and need further surgery, the implants can be removed, and a sliding genioplasty can be performed to correct any bone erosion and properly feminize the chin.

Most wrap-around chin implants of a large nature tend to remain stable; however, they make the chin appear significantly masculine. Narrower or smaller implants used in chin surgeries are more feminine, but they have a higher tendency to rotate, slide out of position, and erode into the bone. Also, implants rarely stay in the right position near the lower level of the chin bone. Instead, they migrate upward to a more stable but higher position. The result is a chin with an unusual abnormal rounded look in profile. Thus, surgery may be needed to remove the implants.

Revision cases after osseous genioplasties are very possible; however, it must be noted that previous hardware is often quite stubborn to remove. In many cases, the hardware must be cut using power tools. At times, this can leave residual metal in the bone. The reward for correcting such issues, however, is usually worth the effort when the final result becomes apparent.

After surgery, bone healing in the maxilla-mandibular skeleton is somewhat different from healing in the long bones of the body. On a radiograph, the line of the mandibular osteotomy may look like a "nonunion," or a fracture that has never healed completely. This appearance lasts almost indefinitely in some patients, but has no impact on the function of the jaws. On reoperating on patients who have had previous osteotomies, we find the bone is always healed despite these radiologic findings. For example, one patient of mine required removal of infected hardware 8 weeks after the initial surgery. The patient had already gone back overseas. The local radiologist was concerned that there was nonunion of the bone, thinking that the linear lucency on the radiograph meant it was not healed. I suggested that the line on the image was not worrisome and suggested that the plate should be immediately removed either locally or back in San Francisco. The bone was in fact healed on removal.

Since the introduction in the 1980s of internal plate and screw fixation, complications from sliding genioplasties have become increasingly rare. Yet they must be performed properly to prevent nerve injury and relapse. They also should be performed with an artistic eye and attention toward symmetry and proportion to avoid a safe but unpleasing result. Wound healing has never been a problem, and the number of infections we have had can be counted on one hand; yet after chin surgery, patients can experience some swelling beneath the lower jaw, particularly in the area just behind the chin osteotomy. The swelling seems to be caused by trapped blood under the periosteum. Usually this resolves, but if it does not, this osteophytic area may require another procedure to correct the excess fullness.

Thus far, I have not had to revise any chins because of relapse. My associate, D.K. Ousterhout, has revised 2 genioplasties because of relapse; the cause of these relapses, however, was not clearly evident. I have revised a few cases because of minor contour irregularities, or palpable hardware. In a few of Ousterhout's cases, the mental nerve was quite low, and the distal piece was shorter than usual. As a result, a small hourglass deformity occurred laterally. To remedy these cases, Ousterhout used 1 to 3 layers of 1-mm-thick MEDPOR, held together with 5 to 0 nylon suture along the side of the bone.[9] I have rarely found this necessary, and have often recommended extending the intraoral incisions sufficiently to perform some minor contouring of the mandible to blend the transition from the chin back along the body of the mandible. This has worked very well.

Many studies have assessed the safety of osseous genioplasty, and when appropriate precautions are taken, the mental nerve should remain undamaged and lip sensation remains intact. Usually some transient numbness occurs in the lips, but that resolves over the course of 2 years. Most often this transient numbness occurs when mandibular contouring is performed in conjunction with osteotomy of the chin. The reason for this is that the nerve must be retracted and manipulated to accomplish the contouring.

Since developing the procedure to avoid injuring the mental nerve, very few of our patients have experienced any permanent nerve damage. Some of my patients have described numbness in a very narrow vertical strip, approximately 3.2 mm wide down the middle of the lower lip and chin, sometimes involving the lower 2 or 4 incisor teeth.

After very large chin advancements (more than 12 mm), the patient also may perceive that her speech seems slurred when saying words that require the lips to touch during enunciation. Although the lower lip is moving perfectly, the patient may not feel it touching the upper lip because of temporary numbness. Although patients may perceive that they are not speaking properly, they actually have no speech problems, even with temporary numbness. This perception of "slurring" spontaneously resolves within 3 months.

In the past, major speech difficulties after a sliding genioplasty were a real, yet extremely rare, risk. The reason was some disturbance in the attachment of the genioglossus muscle. Occasionally a patient would complain of difficulty enunciating words after the surgeries. The situation occurred when there was a significant vertical reduction to the chin of 4.2 mm or more. We prevent this problem by stabilizing the base of the tongue muscle forward with a slowly degrading suture. Patients in our practice have not reported any major speech problems since we began using this approach years ago.

One of the great additional benefits of a feminizing sliding genioplasty is its effect on tooth show. Adult men have a large relative amount of lower tooth show when their mouths are slightly open. Women, however, show their upper teeth, rather than their lower teeth. Unfortunately, there is no good method for vertically lengthening the lower lip to give men a more feminized and reduced lower tooth display. However, the sliding genioplasty allows us to achieve that effect by reducing the underlying vertical height of the bony chin. This functionally allows for more coverage of the lower teeth by decreasing the ratio of bony height to soft tissue height. As a result, lower tooth show is markedly reduced and may

even be eliminated after a properly completed feminizing genioplasty. The result is an overall feminizing effect on the lower jaw.

SUMMARY

To properly feminize the chin, it is necessary to understand the differences between male and female chins. To attempt to feminize the chin without considering the anatomic differences between men and women is like trying to steer a boat without a compass. Often, chin feminization entails reducing the height of the chin, narrowing the chin, and reducing its prominence. In some patients, there are also asymmetries or the chin is too retruded or long. Changing all these features of a chin and altering its position in FFS can best be accomplished with a single procedure.

Serious complications with these procedures are rare, and patient satisfaction is generally high. However, there are important cautions to consider. Mapping the course of the inferior alveolar nerve during preoperative planning is crucial in avoiding nerve injury during the sliding genioplasty. All anterior mandibular horizontal osteotomies also should be performed at least 6 mm below the inferior border of the mental foramen to protect the nerve. Patient education before surgery is also crucial, so that patients will have realistic expectations of the results that can be achieved and are informed about possible complications.

REFERENCES

1. Ousterhout DK. Feminization of the chin: a review of 485 consecutive cases, vol. 10. Bologna (Italy): Medimond International Proceedings; 2003.
2. Hofer O. Die operative Behandlung der alveolaren Retraktion des Unterkiefers und ihre Anwendungsm öglickkeit für Prognathie und Mikrogenie. Dtsch Zahn-Mund-Kieferheilkd 1942;9:121–32.
3. Gillies H, Millard DR. The principles and art of plastic surgery. Boston: Little, Brown; 1957. p. 361.
4. Trauner R, Obwegeser H. The surgical correction of mandibular prognathism and retrognathia with consideration of genioplasty. I. Surgical procedures to correct mandibular prognathism and reshaping of the chin. Oral Surg Oral Med Oral Pathol 1957;10: 677–89.
5. Converse JM, Wood-Smith D. Horizontal osteotomy of the mandible. Plast Reconstr Surg 1964; 34:464.
6. Hohl TH, Epker BN. Macrogenia: a study of treatment results, with surgical recommendations. Oral Surg Oral Med Oral Pathol 1976;41(5):545–67.
7. McBride KL, Bell WH. Chin surgery. In: Bell WH, Proffitt WR, White RP, editors. Surgical correction of dentofacial deformities, vol. II. Philadelphia: Saunders; 1980. p. 1238–40.
8. Wolfe SA. Shortening and lengthening the chin. J Craniomaxillofac Surg 1987;15(4):223–30.
9. Ousterhout DK. Sliding genioplasty, avoiding mental nerve injuries. J Craniofac Surg 1996;7(4): 297–8.
10. Ritter EF, Moelleken BR, Mathes SJ, et al. The course of the inferior alveolar neurovascular canal in relation to sliding genioplasty. J Craniofac Surg 1992;3(1): 20–4.
11. Ousterhout DK, Deschamps-Braly J. Feminization surgery: a guide for the transgendered woman. Omaha (NE): Addicus Books; 2010.