Lower Jaw Recontouring in Facial Gender-Affirming Surgery

Shane D. Morrison, MD, MS[a,*], Thomas Satterwhite, MD[b,1]

KEYWORDS

• Transgender • Mandible contouring • Lower jaw augmentation • Jaw implants • Osteotomies

KEY POINTS

- Facial gender-affirming surgery can lead to significant improvement in quality-of-life for gender-dysphoric patients.
- Lower jaw feminization consists of bony contouring of mandibular angle and body along with sliding genioplasty.
- Lower jaw masculinization consists of placement of alloplastic implants, fat or bone grafts along the mandibular angle and body, and placement of alloplastic implants or fat along the chin or sliding genioplasty.
- Complications are rare, but can be significant in the setting of nerve injuries, surgical site infections, or implant infections.
- Further research is needed on facial gender-affirming surgery, especially related to patient-reported outcomes.

INTRODUCTION

Gender dysphoria develops from the incongruity between one's assigned sex at birth and one's inherent gender identity.[1] Treatment for gender dysphoria comes in many different forms, from mental health to exogenous hormones to surgical intervention, and all fall under the realm of gender-affirming care.[2] With proper treatment, gender-dysphoric patients endorse decreased psychosocial sequelae and improved quality of life.[3–13] Gender dysphoria can affect a wide range of persons, including transgender, gender non-conforming, gender queer, pangender, and agender populations, among others.[14,15] Globally, the number of transgender people exceeds 25 million and trends in gender-affirming surgery are rising within the United States.[16,17]

Because of significant stigma and discrimination, many of those suffering from gender dysphoria are not able to obtain the care they need, and in some cases this may be related to medical provider knowledge and comfort.[17] Further training on gender-affirming care is needed for physicians, and we are making progress.[18–24] The World Professional Association for Transgender Health (WPATH) develops Standards of Care as guidelines for gender-affirming treatment.[1] Continued enhancement in education and awareness will allow for improved multidisciplinary teams to address gender affirmation.[25]

Disclosure: Authors have no disclosures to declare.

[a] Division of Plastic Surgery, Department of Surgery, University of Washington School of Medicine, 325 9th Avenue Mailstop #359796, Seattle, WA 98104, USA; [b] Brownstein and Crane Surgical Services, San Francisco, CA, USA

[1] Present address: 575 Sr. Francis Drake Boulevard, Suite 1, Greenbrae, CA 94904.

* Corresponding author.

E-mail address: shanedm@uw.edu

Facial Plast Surg Clin N Am 27 (2019) 233–242

https://doi.org/10.1016/j.fsc.2019.01.001

1064-7406/19/© 2019 Elsevier Inc. All rights reserved.

Gender-affirming surgery options for transgender men (female-to-male) include facial, chest, body, and genital masculinization.[6,8,26] Options for transgender women (male-to-female) include facial, vocal, chest, body, and genital feminization.[2,10,11,27] In transmen, the most common surgical procedures are related to chest and body masculinization, whereas transwomen more commonly seek facial, body, and chest feminization.[11,27,28] Pioneering work by Douglas Ousterhout, MD, determined aspects of the craniofacial skeleton that depicted more masculine or feminine features, and this has led to the development of facial gender-affirming surgery.[29–31]

The generally accepted differences between the masculine and feminine faces are numerous. Overall, a feminine face is rounded and soft-appearing with a heart or inverted triangle shape (apex of the triangle at chin and base at malar region), whereas a masculine face is angulated and square with a pronounced jaw and chin. An M-shaped hairline with temporal recession constitutes a more masculine shape. An acute nasofrontal angle, presence of a supraorbital ridge (forehead bossing), and straight eyebrows that sit along the superior orbital rim constitute a masculine appearance, whereas a gentle curving convex forehead with laterally peaked eyebrows sitting above the superior orbital rim are more feminine. A wide and straight nose with a minimal supratip break is more masculine compared with a thin-based and concaved nose. Thin and elongated upper lips further accentuate masculine features. In the lower third of the face, a long, square chin with a prominent mandible with bulky masseter musculature and a sharp mandibular angle are more masculine. Last, a prominent thyroid cartilage with a 90° angle, as opposed to a 120° angle, signals masculinity.[6,11,27,29,31–44] Cultural background may alter one's perception of masculinity and femininity[45] (**Fig. 1**).

Various studies have tried to quantify aspects of the face that more substantially determine masculinity or femininity, yet evaluation of the complete harmonious face has proven the most effective in expressing gender.[11,44] In this article, we discuss contouring of the lower jaw for feminization or masculinization in gender-affirming surgery. Preoperative evaluation and planning, operative techniques, and postoperative care and outcomes are discussed. Some of the techniques discussed have not been published widely and used in only

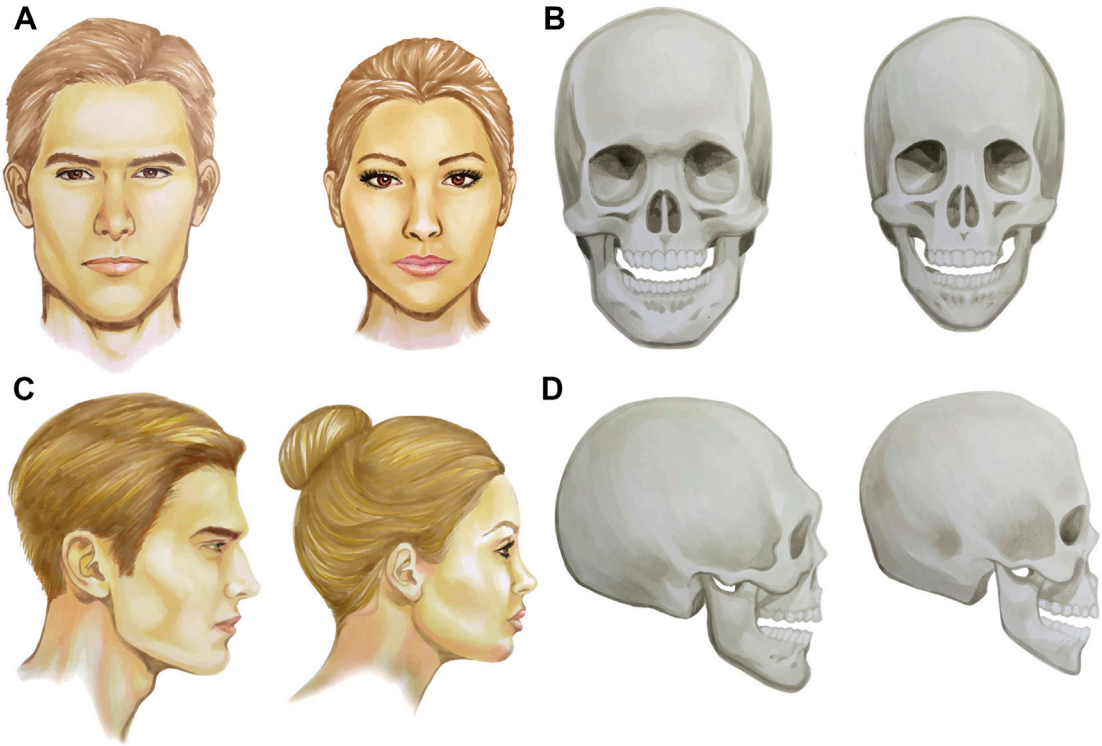

Fig. 1. Difference in male and female faces. (*A*) Frontal soft tissue view. (*B*) Frontal skeletal view. (*C*) Lateral soft tissue view. (*D*) Lateral skeletal view. (*Courtesy of* Thomas Satterwhite, MD.)

a few patients (facial masculinization), whereas others are better known (facial feminization).

PREOPERATIVE ASSESSMENT

Before surgery, all patients have a preoperative evaluation with the surgical team. There are no guidelines set forth by the WPATH for patients who wish to have facial gender-affirming surgery.[1] For our patients, we generally prefer them to have met with a mental health provider who can evaluate their gender dysphoria and treat any concomitant mental health issues. Likewise, prior hormone therapy is preferred, but not a criterion for consultation or surgery. When possible, we prefer our patients to take hormones for a year before surgery, as we feel this appropriately allows remodeling and texturizing of the soft tissues to approximate what their facial skin will be like as their true gender. An evaluation by a primary care provider for underlying medical conditions (eg, diabetes, congestive heart failure, chronic obstructive pulmonary disease, previous myocardial infarction) that could adversely affect surgical outcomes is needed.

Evaluation by dentistry and orthodontics is important before undertaking lower jaw recontouring. Treatment of underlying caries or gingival disease is needed to prevent potential infection of the surgical sites or the rare, but devastating, risk of osteomyelitis.[4] Evaluation of occlusion and interdental relationships are necessary. Appropriate jaw alignment along with the quality of the teeth can have dramatic effects on perceptions of beauty and gender, so these must be evaluated by the surgeon if the patient is has not seen dentistry or orthodontics before facial gender-affirming surgery consultation.[32,40,46,47] Edentulous mandibles also can place the patient at considerable risk for iatrogenic fractures or nonunions due to the quality of the bone. Presence of impacted third molars or unerupted third molars could affect osteotomy sites, so these also must be evaluated.

During the initial consultation, the surgeon should evaluate the entire face to determine which qualities are feminine and masculine, taking into account patient perceptions of their masculine and feminine aspects. Dividing the face into vertical thirds is a common approach used to investigate the various areas of the face, but the ultimate goal should be a harmonious face that portrays the patient's desired gender. During specific evaluation of the lower third of the face, it is important to evaluate the prominence, splay, and angularity of the mandible and associated masseter muscle bulk, along with the position, projection, and angularity of the chin. Feminine features include a narrow, short, and pointed chin with narrow and more rounded mandibular angles. Soft tissue draping and laxity with associated rhytids should be noted, especially if platysmal banding or marionette lines are present, as changes to the bony architecture could accentuate or modify these.

Plain radiographs, cephalograms, or computed tomography imaging is optional, but can help with assessment of potential concomitant osteotomies of the midface or supraorbital bossing reduction. It is common that patients seeking facial gender-affirming surgery have multiple procedures performed during a single operation, so these preoperative images allow for planning.[31,42] Photographs should be taken according to accepted standards of the face (1 m from the patient with 105-mm lens) and appropriate modifications for the brow or nose.

Procedures to be performed and their associated risks should be disclosed at consultation. Specifically, risks of infection, injury to tooth roots, and injury to mental or inferior alveolar nerves should be discussed in relation to lower jaw recontouring. Postoperative oral hygiene, diet, and dressings are reviewed at this consultation. Finally, shared decision-making between the patient and the surgeon should assist with the development of final surgical plans.

If deemed an appropriate candidate for surgery, patients must stop taking estrogen and progesterone-based hormones 2 weeks before surgery to minimize the risk of a deep vein thrombosis or pulmonary embolism. Patients may continue to take androgen blockers. Aspirin, antiplatelet agents, and anti-inflammatory agents should be stopped 1 week before surgery. Herbal medications should be reviewed with the patient because many can increase bleeding risk.

SURGICAL APPROACH

Lower Jaw Feminization

Most studies for facial feminization focus on modification of the upper and middle thirds of the face.[29,33,35,36,39–41,45,47–51] Modification of the lower jaw for feminization consists of osteotomies or burring of the mandibular angle to soften the angularity and sliding genioplasty to narrow and decrease the height of the chin.[11,34,52]

As modification of the lower jaw is generally coupled with other procedures for facial feminization, patients are intubated orally, and the endotracheal tube is wired to the maxillary molars with a 26-gauge wire. Care is taken to ensure ventilation is maintained with flexion and extension of the neck

before starting the case. The teeth are cleaned with chlorhexidine, and a throat pack is placed to minimize swallowing of blood or other fluids. Cefazolin is given 30 to 60 minutes before the procedure. Antibiotics are re-dosed appropriately during the case. Appropriate warming, deep vein thrombosis prophylaxis with sequential compression devices, and glucose control are applied (**Fig. 2**).

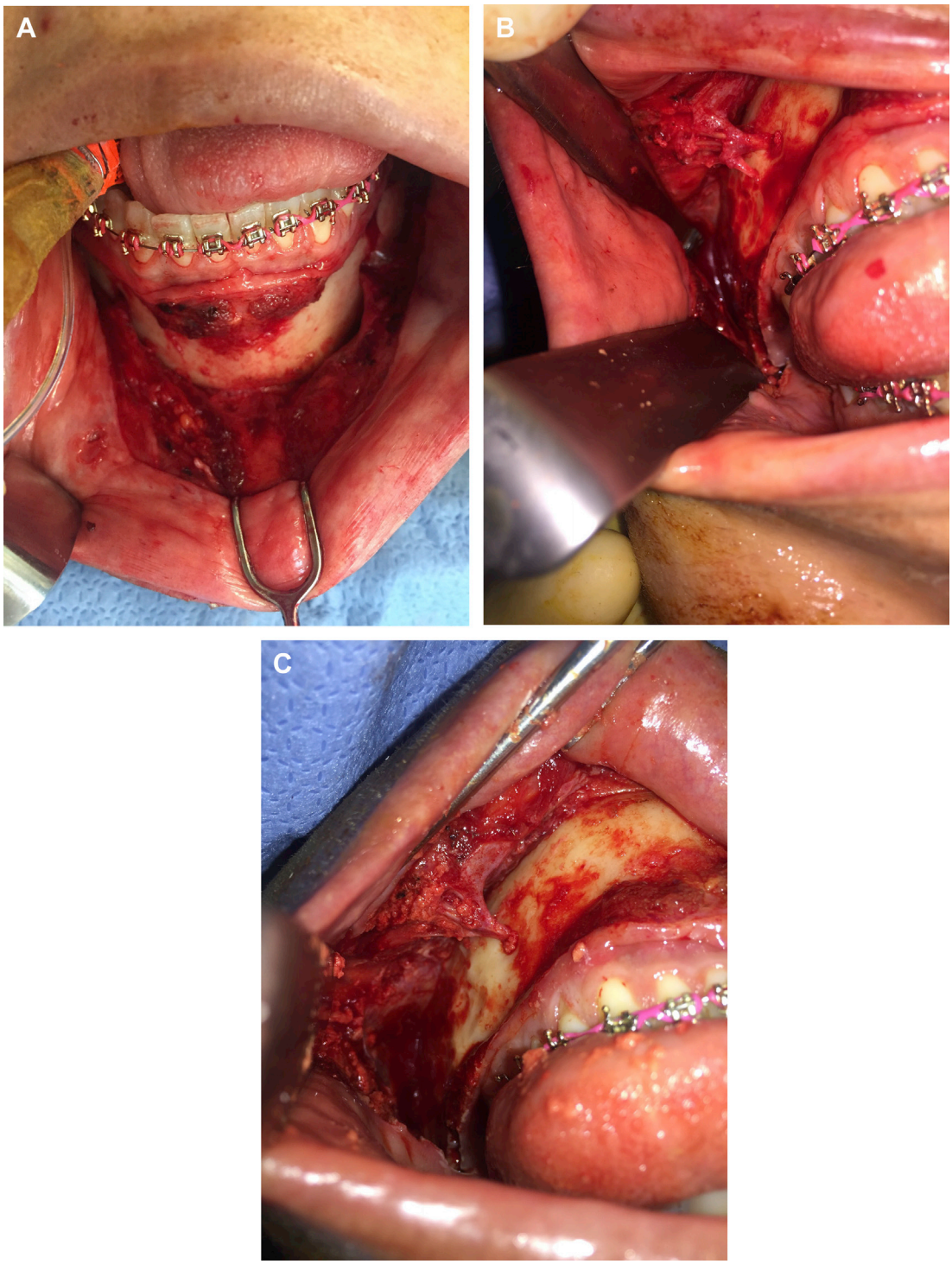

Fig. 2. Mandibular feminization. (*A*) Intraoperative exposure of the entire mandible with exposure and protection of the mental nerves. (*B*) Mandibular angle being smoothed with rasp after burring. (*C*) Mandibular angle and body after contouring.

Mandibular angle recontouring

Local anesthetic is given along the course of the incision from angle to angle. An incision with Bovie electrocautery is made along the area demarcated from the local anesthetic. The incision is placed wide on the gingival mucosa to ensure an adequate cuff of mucosa remains for closure. A cuff of mentalis muscle is left over the symphysis for resuspension during closure to reduce the risk of witch's chin deformity. When combined with genioplasty, the entire soft tissue is stripped off the anterior portion of the mandible in a subperiosteal plane, with care taken to protect the mental nerves. Exposure of the entire lower border of the angle, body, and ramus is paramount to prevent injury to the pterygomasseteric musculature when performing contouring of the mandible. Langenbecks are placed to ensure wide exposure of the mandibular angle. Oftentimes the angle can be contoured sufficiently with the use of a round or pineapple burr at high speed. Burring of the entire mandible may need to be performed for maximal contouring. Particular attention should be paid to the body of the mandible, which can be quite protrusive in some patients. With removal of the cortical bone and exposure of the cancellous bone, it is important to avoid exposure of the molar roots and inferior alveolar nerve. The burr is used to taper the contoured angle into the mandibular body. When the angle is sufficiently prominent, osteotomies are warranted. Reciprocating, oscillating, or piezoelectric saws are used to perform the initial cuts at the cortical bone. A right angle or curved osteotome completes the osteotomy. Because of the attachment of the medial pterygoid, the fragment can translocate medially and needs to be digitally reduced so the muscle can be divided and the bone extracted. If an osteotomy is done, then the lower border should still be burred to contour the angle. If preoperative analysis suggests excessive masseter bulk, then neurotoxin injection or masseteric resection can be offered. However, masseter atrophy also may occur in the setting of stripping of the mandible, so reduction of the muscle is not a requirement.[32] Hemostasis is achieved, especially if injury occurred to the pterygo-masseteric musculature during angle reduction. Thrombin, gel foam, or other hemostatic agents can be used to assist. If performed in isolation, then the incision can be closed with Chromic or Vicryl suture in a watertight fashion to prevent pooling of saliva. If a concomitant genioplasty is to be performed, the attention is shifted to this procedure.

Sliding genioplasty

When performed with the mandible angle reduction, the incision described previously can be used. If performed in isolation, a labial sulcus incision with a wide cuff of mucosa and cuff of mentalis is performed. Dissection of the anterior mandible is performed in a subperiosteal plane with care taken to avoid the mental nerves. The lower border is stripped of its soft tissue attachments. Once exposed, a line 5 mm below the mental nerves bilaterally is marked. Based on preoperative evaluation, width, height, projection, and asymmetries are addressed. A reciprocating saw is used to make the initial cut for the osteotomy and it is completed with an osteotome. If vertical height is to be reduced, the predetermined amount of bone to be resected is marked, and the osteotomy should be performed initially on the lower line, then the superior line. An oscillating saw is then used to remove a predetermined segment of bone in the midline to allow for narrowing of the chin. The bony segments are collapsed medially and fixed temporarily with wires if needed. The segments are set back a predetermined amount for vertical reduction and fixated with plates and screws. The junction between the posterior genioplasty segments and the mandible should be inspected and palpated to ensure there are no step-offs. To ensure a smooth transition, this area should be burred if needed. Once stable, the incisions are irrigated and closed in layers with Vicryl to resuspend the mentalis, then either Vicryl or Chromic to close the mucosa in a horizontal mattress fashion (**Fig. 3**).

Lower Jaw Masculinization

Only 2 studies have reported on facial masculinization, and only a single study was used for a transman.[31,37] In general, many of the procedures can be thought of as pursuing the opposite of feminization, with augmentation of the bony architecture with implants or the use of malleable material.[53] As these procedures are performed infrequently, some of the steps for these procedures are gleaned from the non-transgender patient-based literature.[31,54,55]

Mandibular angle recontouring

Local anesthetic is given along the course of the incision from angle to angle. An incision is made along the area demarcated from the local anesthetic. The incision is placed wide on the gingival mucosa to ensure a large cuff of mucosa remains for closure. A cuff of mentalis muscle is left over the symphysis for resuspension during closure to reduce the risk of witch's chin deformity. When combined with genioplasty, the entire soft tissue is stripped off the anterior portion of the mandible in a subperiosteal plane, with care taken to protect the mental nerves. Exposure of the entire lower border of the angle, body, and ramus is paramount

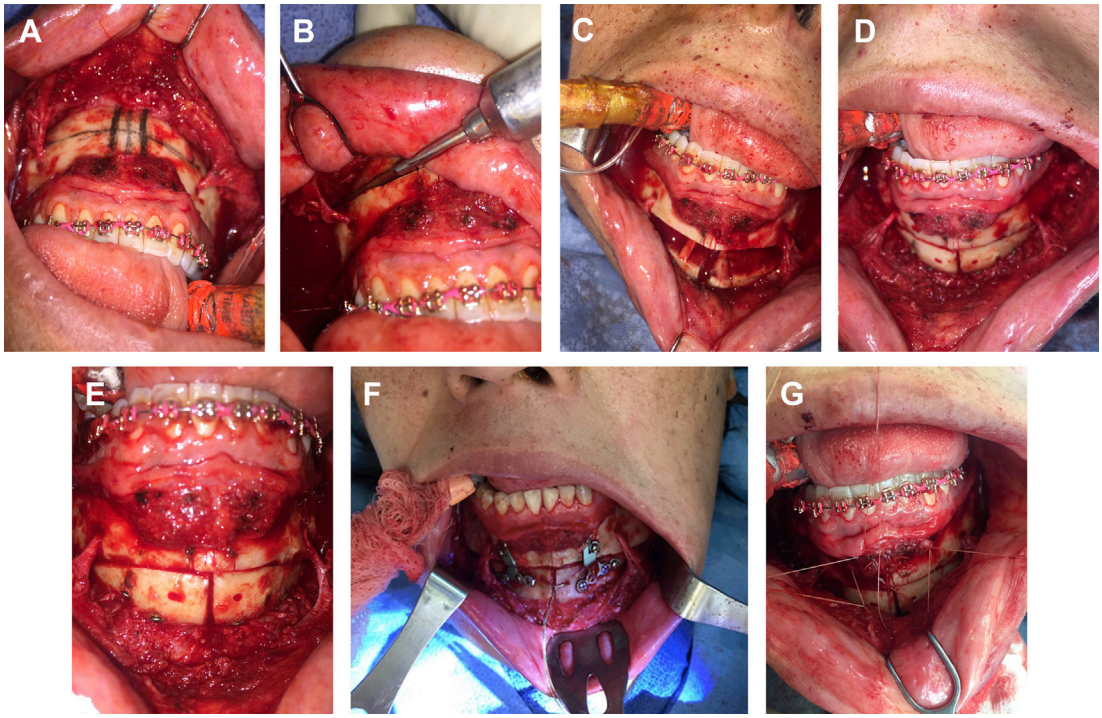

Fig. 3. Sliding genioplasty for feminization. (*A*) Markings for sliding genioplasty illustrating transverse line for horizontal osteotomy and vertical lines for width reduction. (*B*) Horizontal osteotomy being initiated with reciprocating saw. (*C*) Completion of horizontal osteotomy with down-fracturing. (*D*) Inset of chin after horizontal and vertical translation and reduction. (*E*) Placement of screw fixation. (*F*) Alternate fixation of sliding genioplasty with plates. (*G*) Closure of mentalis before mucosal closure.

to prevent injury to the pterygo-masseteric musculature when placing implants, yet when an interposition bone graft is to be placed, then care must be taken to leave the masseter attachments for vascular supply to the bone.

Langenbecks are placed to ensure wide exposure of the mandibular angle when implants are placed. Implants are designed to produce a squarer jaw and are tapered appropriately along the mandibular body to the genioplasty segment (if one is being performed). Care should be taken in their insertion to minimize contamination from intraoral bacteria. The implants are fixed with monocortical screws to the mandible and a watertight closure is needed to prevent saliva pooling on the implants. Most surgeons tend to favor Medpor implants for the angle.

Iliac crest or calvarial bone graft can be harvested through standard means to augment the mandibular angle. Dr Ousterhout pioneered this procedure.[31] He noted that placement of a bone graft between the masseter and lateral cortex of the mandible results in resorption of the bone, so the graft is placed between the medial two-thirds and lateral one-third of the mandible. The approach and technique for a sagittal split osteotomy is used with 2 important considerations: (1) the mandible remains intact with an intact arch and continuity of condyle with dental segment, and (2) the masseter muscle is not stripped from its insertion. The split is made almost completely with a reciprocating saw and finished with an osteotome, leaving the pterygomandibular ligament intact on the lower border of the mandible. Up to 6 mm of bone graft have been placed. The interposition graft is stabilized between the portions of the mandible without fixation.

A less invasive approach involves fat transfer along the mandible to increase width and projection of the lower face; however, results can be unpredictable.[32,56,57] Using standard harvesting and processing techniques, fat can be placed along the angle and body to augment its width. Blunt cannulas are inserted lateral to the mental foramen and passed along the mandible in a supraperiosteal plane. Small aliquots are placed in a retrograde and fanning approach to increase viability of the fat placed.

Genioplasty

The primary approach for masculinizing the chin consists of placement of alloplastic implants

(silicone or Medpor). Implant insertion will aid in accentuating the width and projection of the chin, but cannot adequately increase vertical height. Using a submental approach, an incision is placed 2 mm behind the submental crease. After dissection to the mentalis muscle, this is elevated with or without the periosteum, with care taken not to injure the mental nerves. Implants are placed subperiosteal laterally and supraperiosteal centrally to minimize erosion. Monocortical screw fixation secures the implants to the lower jaw. The mentalis is reapproximated and soft tissue resuspended. Implants also can be inserted intraorally through a similar approach, as described later in this article, for sliding genioplasty, but the soft tissue must be stripped from the lower border of the mandible for placement of the implant. Fixation and closure are similar to mandibular implant placement, as described previously. Sliding genioplasty provides more options and flexibility for contouring the chin.

When sliding genioplasty is performed with the mandible angle augmentation, the incision described in that section can be used. If performed in isolation, a labial sulcus incision with a wide cuff of mucosa and cuff of mentalis is performed. Dissection of the anterior mandible is performed in a subperiosteal plane, with care taken to avoid the mental nerves. The lower border is stripped of its soft tissue attachments. Once exposed, a line 5 mm below the mental nerves bilaterally is marked. A reciprocating saw is used to make the initial cut for the osteotomy and it is completed with an osteotome. An oscillating saw is then used to open the central portion of the bone in the midline to allow for widening of the chin with or without an interposition bone graft or hydroxyapatite granules mixed with the patient's blood. The bony segments are fixed temporarily with wires if needed. The segments are advanced a predetermined amount for vertical augmentation and fixated with plates and screws. Once stable, the incisions are irrigated and closed in layers with Vicryl to resuspend the mentalis, then either Vicryl or Chromic to close the mucosa in a horizontal mattress fashion.

A less invasive approach involves fat transfer along the chin to increase width and projection of the lower face; however, results can be unpredictable.[32,56,57] Using standard harvesting and processing techniques, fat can be placed along the chin to augment its width. Blunt cannulas are inserted at the mental crease, chin apex, anterior chin, submental chin, and pre-jowl sulcus, and passed along the chin in a supraperiosteal plane. Small aliquots are placed in a retrograde and fanning approach to increase viability of the fat placed.

POSTOPERATIVE CARE

Typically when performed as a full-facial gender-affirming procedure, then patients are admitted to the hospital for overnight monitoring. If performed in isolation, then lower jaw contouring can be done as an outpatient procedure. If done as an outpatient, then follow-up in 1 to 2 days postoperatively is needed to ensure the patient is progressing appropriately (**Fig. 4**).

Most incisions will be placed within the mouth and closed with absorbable suture, so appropriate oral hygiene is needed. In most cases, this consists of antiseptic mouthwash (chlorhexidine gluconate) 3 times a day for 1 week (longer use may cause discoloration of teeth). Gentle brushing of teeth and rinsing with water or saline should be done after each meal. Patients are maintained on oral antibiotics for 1 week. A soft diet can be started after surgery and should continue for 4 weeks. Icing of the face and use of facial compression garments are used. Head of bed elevation is continued as much as possible to reduce swelling that will continue for weeks to months after surgery. Numbness of the lower lips and chin as a result of mental nerve neuropraxia is expected and generally resolves after 4 weeks, but can persist for up to a year. Normal activity restrictions and wound care of extraoral incisions are applied.

If a bone graft was harvested, then wound care to these incisions will be needed. Typically, iliac crest bone harvest does not warrant specific therapies. If fat grafting was used, then a compression garment is placed on the torso after surgery. This is continued for 2 weeks as much as possible, and then weaned over the next 4 weeks.

COMPLICATIONS AND OTHER PROCEDURES

As with any craniofacial procedures, there are inherent risks with modification of the facial bones. Specifically, in relation to the lower jaw, risks include infection (including implant, soft tissue, and osteomyelitis), wound dehiscence with exposure of underlying bony architecture, mental nerve injury or neuropraxia, inferior alveolar nerve injury, tooth root injury, nonunion of osteotomy sites, resorption of bone, mentalis muscle dysfunction, salivary fistulas, and iatrogenic injury to nearby structures. Most of these can be treated nonoperatively. Various studies have reported minimal to no surgical complications from lower jaw contouring for gender-affirming surgery.[31,33,34,52,58]

After modification of the craniofacial skeleton, changes to the soft tissue of the face may

Fig. 4. Gender-affirming feminization. (*A–D*) Preoperative and (*E–H*) 6-month postoperative after genioplasty, mandibular angle and body reduction, and thyroid cartilage reduction.

occur. Modification with injectables, including neurotoxins, fillers, or fat grafting, may be useful.[64] Other soft tissue procedures, like submental and neck liposuction or a facelift, may be needed to adequately address underlying soft tissue anomalies. In particular, patients older than 40 (and those with inherent laxity in their skin) should be advised preoperatively that there is a possibility of needing a facelift or necklift after significant bony reduction of the chin and mandible.

OUTCOMES

Data on outcomes of facial gender-affirming surgery report few complications.[11] Patient-reported outcomes are sparse in current literature on facial gender-affirming surgery, with most studies that report these data using nonvalidated instruments.[11] One group has validated an instrument that has been used to assess retrospective quality-of-life outcomes in facial feminization surgery. Results show that transgender women had significantly diminished mental health quality of life compared with the non-transgender population, but this was significantly improved after facial feminization or gender-affirming surgery.[59] This instrument was used in another retrospective study that showed a high "facial feminization outcome score," but was not compared with a standardized group.[42] A prospective study on outcomes of facial feminization has supported the results from this previous research and these data are currently being evaluated for long-term outcomes.[60] Further use of validated instruments in the assessment of outcomes for gender-affirming surgery is needed, along with input from community stakeholders among the transgender and gender nonbinary community on the development of these instruments, and this will be invaluable in future research in this field.[5,7,61–63]

SUMMARY

Lower jaw recontouring for facial gender-affirming surgery offers safe and effective means to masculinize or feminize the face. Shared decision-making between the physician and patient will allow for appropriate adjustments to portray the patient's true gender. Reported complications are minimal, but more robust research is needed, especially related to patient-reported outcomes. Our transgender and gender nonbinary patients deserve quality health care, and surgeons should seek to deliver that care through continued collaborations and multidisciplinary approaches.

REFERENCES

1. Coleman E, Bockting W, Botzer M, et al. Standards of care for the health of transsexual, transgender, and gender-nonconforming people, version 7. International Journal of Transgenderism 2019;13(4): 165–232.
2. Berli JU, Knudson G, Fraser L, et al. What surgeons need to know about gender confirmation surgery when providing care for transgender individuals: a review. JAMA Surg 2017;152(4):394–400.
3. Dhejne C, Lichtenstein P, Boman M, et al. Long-term follow-up of transsexual persons undergoing sex reassignment surgery: cohort study in Sweden. PLoS One 2011;6(2):e16885.
4. Ludwig DC, Morrison SD. Should dental care make a transition? J Am Dent Assoc 2018;149(2):79–80.
5. Massie JP, Morrison SD, Smith JR, et al. Patient-reported outcomes in gender confirming surgery. Plast Reconstr Surg 2017;140(1):236e–7e.
6. Morrison SD, Chen ML, Crane CN. An overview of female-to-male gender-confirming surgery. Nat Rev Urol 2017;14(8):486–500.
7. Morrison SD, Crowe CS, Wilson SC. Consistent quality of life outcome measures are needed for facial feminization surgery. J Craniofac Surg 2017;28(3): 851–2.
8. Morrison SD, Perez MG, Nedelman M, et al. Current state of female-to-male gender confirming surgery. Curr Sex Health Rep 2015;7:38–48.
9. Ascha M, Massie JP, Morrison SD, et al. Outcomes of single stage phalloplasty by pedicled anterolateral thigh flap versus radial forearm free flap in gender confirming surgery. J Urol 2018;199(1):206–14.
10. Morrison SD, Satterwhite T, Grant DW, et al. Long-term outcomes of rectosigmoid neocolporrhaphy in male-to-female gender reassignment surgery. Plast Reconstr Surg 2015;136(2):386–94.
11. Morrison SD, Vyas KS, Motakef S, et al. Facial feminization: systematic review of the literature. Plast Reconstr Surg 2016;137(6):1759–70.
12. Remington AC, Morrison SD, Massie JP, et al. Outcomes after phalloplasty: do transgender patients and multiple urethral procedures carry a higher rate of complication? Plast Reconstr Surg 2018; 141(2):220e–9e.
13. Massie JP, Morrison SD, Wilson SC, et al. Phalloplasty with urethral lengthening: addition of a vascularized bulbospongiosus flap from vaginectomy reduces postoperative urethral complications. Plast Reconstr Surg 2017;140(4):551e–8e.
14. Chaiet SR, Morrison SD, Streed CG Jr. Gender confirmation surgery and terminology in transgender health. JAMA Surg 2017;152(11):1089–90.
15. Massie JP, Streed CG Jr, Neira PM, et al. Terminology in transgender patient care. Plast Reconstr Surg 2018;141(2):317e–8e.
16. Canner JK, Harfouch O, Kodadek LM, et al. Temporal trends in gender-affirming surgery among transgender patients in the United States. JAMA Surg 2018;153(7):609–16.
17. Winter S, Diamond M, Green J, et al. Transgender people: health at the margins of society. Lancet 2016;388(10042):390–400.
18. Dubin SN, Nolan IT, Streed CG Jr, et al. Transgender healthcare: improving medical student and resident training and awareness. Adv Med Educ Pract 2018; 9:377–91.
19. Dy GW, Osbun NC, Morrison SD, et al. Exposure to and attitudes regarding transgender education among urology residents. J Sex Med 2016;13(10):1466–72.
20. Massenburg BB, Morrison SD, Rashidi V, et al. Educational exposure to transgender patient care in otolaryngology training. J Craniofac Surg 2018; 29(5):1252–7.
21. Morrison SD, Chong HJ, Dy GW, et al. Educational exposure to transgender patient care in plastic surgery training. Plast Reconstr Surg 2016;138(4): 944–53.
22. Morrison SD, Dy GW, Chong HJ, et al. Transgender-related education in plastic surgery and urology residency programs. J Grad Med Educ 2017;9(2): 178–83.
23. Morrison SD, Smith JR, Mandell SP. Are surgical residents prepared to care for transgender patients? JAMA Surg 2018;153(1):92–3.
24. Morrison SD, Wilson SC, Smith JR. Are we adequately preparing our trainees to care for transgender patients? J Grad Med Educ 2017;9(2):258.
25. Weissler JM, Chang BL, Carney MJ, et al. Gender-affirming surgery in persons with gender dysphoria. Plast Reconstr Surg 2018;141(3):388e–96e.
26. Morrison SD, Perez MG, Carter CK, et al. Pre- and post-operative care with associated intra-operative techniques for phalloplasty in female-to-male patients. Urol Nurs 2015;35(3):134–8.
27. Berli JU, Capitan L, Simon D, et al. Facial gender confirmation surgery—review of the literature and recommendations for version 8 of the WPATH standards of care. Int J Transgend 2017;18(3):264–70.
28. Wilson SC, Morrison SD, Anzai L, et al. Masculinizing top surgery: a systematic review of techniques and outcomes. Ann Plast Surg 2018;80(6):679–83.
29. Ousterhout DK. Feminization of the forehead: contour changing to improve female aesthetics. Plast Reconstr Surg 1987;79(5):701–13.
30. Ousterhout DK. Facial feminization surgery: a guide for the transgendered woman. Google eBook. San Francisco (CA): Addicus Books; 2010.
31. Ousterhout DK. Dr Paul Tessier and facial skeletal masculinization. Ann Plast Surg 2011;67(6):S10–5.
32. Altman K. Facial feminization surgery: current state of the art. Int J Oral Maxillofac Surg 2012;41(8): 885–94.

33. Becking AG, Tuinzing DB, Hage JJ, et al. Facial corrections in male to female transsexuals: a preliminary report on 16 patients. J Oral Maxillofac Surg 1996;54(4):413–8 [discussion: 419].
34. Becking AG, Tuinzing DB, Hage JJ, et al. Transgender feminization of the facial skeleton. Clin Plast Surg 2007;34(3):557–64.
35. Capitan L, Simon D, Kaye K, et al. Facial feminization surgery: the forehead. Surgical techniques and analysis of results. Plast Reconstr Surg 2014; 134(4):609–19.
36. Dempf R, Eckert AW. Contouring the forehead and rhinoplasty in the feminization of the face in male-to-female transsexuals. J Craniomaxillofac Surg 2010;38(6):416–22.
37. Deschamps-Braly JC, Sacher CL, Fick J, et al. First female-to-male facial confirmation surgery with description of a new procedure for masculinization of the thyroid cartilage (Adam's apple). Plast Reconstr Surg 2017;139(4):883e–7e.
38. Farkas LG, Hreczko TA, Kolar JC, et al. Vertical and horizontal proportions of the face in young adult North American Caucasians: revision of neoclassical canons. Plast Reconstr Surg 1985;75(3):328–38.
39. Habal MB. Aesthetics of feminizing the male face by craniofacial contouring of the facial bones. Aesthetic Plast Surg 1990;14(2):143–50.
40. Hage JJ, Becking AG, de Graaf FH, et al. Gender-confirming facial surgery: considerations on the masculinity and femininity of faces. Plast Reconstr Surg 1997;99(7):1799–807.
41. Hage JJ, Vossen M, Becking AG. Rhinoplasty as part of gender-confirming surgery in male transsexuals: basic considerations and clinical experience. Ann Plast Surg 1997;39(3):266–71.
42. Raffaini M, Magri AS, Agostini T. Full facial feminization surgery: patient satisfaction assessment based on 180 procedures involving 33 consecutive patients. Plast Reconstr Surg 2016;137(2): 438–48.
43. Spiegel JH. Challenges in care of the transgender patient seeking facial feminization surgery. Facial Plast Surg Clin North Am 2008;16(2):233–8, viii.
44. Spiegel JH. Facial determinants of female gender and feminizing forehead cranioplasty. Laryngoscope 2011;121(2):250–61.
45. Cho DY, Massie JP, Morrison SD. Ethnic considerations for rhinoplasty in facial feminization. JAMA Facial Plast Surg 2017;19(3):243.
46. Lee SW, Ahn SH. Angloplasty revision: importance of genioplasty for narrowing of the lower face. Plast Reconstr Surg 2013;132(2):435–42.
47. Lundgren TK, Farnebo F. Midface osteotomies for feminization of the facial skeleton. Plast Reconstr Surg Glob Open 2017;5(1):e1210.
48. Bellinga RJ, Capitan L, Simon D, et al. Technical and clinical considerations for facial feminization surgery with rhinoplasty and related procedures. JAMA Facial Plast Surg 2017;19(3):175–81.
49. Capitan L, Simon D, Meyer T, et al. Facial feminization surgery: simultaneous hair transplant during forehead reconstruction. Plast Reconstr Surg 2017; 139(3):573–84.
50. Cho SW, Jin HR. Feminization of the forehead in a transgender: frontal sinus reshaping combined with brow lift and hairline lowering. Aesthetic Plast Surg 2012;36(5):1207–10.
51. Hoenig JF. Frontal bone remodeling for gender reassignment of the male forehead: a gender-reassignment surgery. Aesthetic Plast Surg 2011; 35(6):1043–9.
52. Ousterhout DK. Feminization of the chin: a review of 485 consecutive cases, vol. 10. Bologna (Italy): Medimond International Proceedings; 2003.
53. Sayegh F, Ludwig DC, Ascha M, et al. Facial masculinization surgery and its role in the treatment of gender dysphoria. J Craniofac Surg, in press.
54. Li J, Hsu Y, Khadka A, et al. Surgical designs and techniques for mandibular contouring based on categorisation of square face with low gonial angle in Orientals. J Plast Reconstr Aesthet Surg 2012; 65(1):e1–8.
55. Yaremchuk MJ, Chen YC. Enlarging the deficient mandible. Aesthet Surg J 2007;27(5):539–50.
56. Coleman SR. Facial augmentation with structural fat grafting. Clin Plast Surg 2006;33(4):567–77.
57. Coleman SR. Structural fat grafting: more than a permanent filler. Plast Reconstr Surg 2006;118(3 Suppl):108S–20S.
58. Shams MG, Motamedi MH. Case report: feminizing the male face. Eplasty 2009;9:e2.
59. Ainsworth TA, Spiegel JH. Quality of life of individuals with and without facial feminization surgery or gender reassignment surgery. Qual Life Res 2010; 19(7):1019–24.
60. Satterwhite T, Morrison SD, Ludwig DC, et al. Prospective quality of life outcomes after facial feminization surgery. Plast Reconstr Surg Glob Open 2017;5(9 Suppl):204–5.
61. Andreasson M, Georgas K, Elander A, et al. Patient-reported outcome measures used in gender confirmation surgery: a systematic review. Plast Reconstr Surg 2018;141(4):1026–39.
62. Morrison SD, Crowe CS, Rashidi V, et al. Beyond phonosurgery: considerations for patient-reported outcomes and speech therapy in transgender vocal feminization. Otolaryngol Head Neck Surg 2017; 157(2):349.
63. Morrison SD, Massie JP, Crowe CS, et al. Patient-reported outcomes needed for chest masculinization. Ann Plast Surg 2018;80(1):90–1.
64. Ascha M, Swanson MA, Massie JP, et al. Nonsurgical management of facial masculinization and feminization. Aesthet Surg J, in press.