Gender-confirming Rhinoplasty

Jens Urs Berli, MD[a,*], Myriam Loyo, MD[b]

KEYWORDS

• Rhinoplasty • Transgender • Facial feminization surgery • Gender confirmation surgery • Gender-affirming surgery

KEY POINTS

- Despite technical overlap, the care for patients seeking rhinoplasty for the indication of gender dysphoria vastly differs from that for the cisgender population.
- Rhinoplasty is often performed in combination with other facial gender-confirming surgeries. This article outlines important concepts that need to be taken into consideration.
- The facial gender mosaic concept is a useful tool to both assess patients and provide affirming care.

INTRODUCTION

Facial gender confirmation surgery (FGCS) encompasses a wide variety of surgical procedures, with the common goal of either feminizing or masculinizing the face. A vast majority of patients presenting for consultation are those seeking feminization procedures. Additionally, most facial plastic surgeons who are not routinely treating gender dysphoric patients are much more likely to see an isolated rhinoplasty consultation rather than a request for full facial feminization. Thus, this article focuses on feminizing rhinoplasty as it pertains to gender confirmation surgery. Different from other aspects of FGCS, the surgical basis of feminizing rhinoplasty is almost the same as for the cisgender population. Despite technical overlap, however, the management and care for patients seeking feminizing rhinoplasty for the indication of gender dysphoria vastly differs from that for the cisgender population. It is, therefore, important to understand these nuances to provide the best possible care. Most readers of this article are familiar with the general rhinoplasty literature and it is the authors' hope that that this knowledge be augmented so that the experience of treating patients seeking feminizing rhinoplasty is rewarding for both patients and surgeons.

This review includes comments on gender norms and outlines considerations for the preoperative work-up and operative execution as well as a comprehensive literature review.

PREOPERATIVE MANAGEMENT

Successfully treating the severe experience of gender dysphoria is not just a question of technical skills and rhinoplasty expertise. It also requires sensitive and affirming care from the moment the patient calls the office but most importantly during the initial consultation. The overall experience to the transgender patient is of utmost importance.

Facial Gender Mosaic Concept

Even during an isolated rhinoplasty consultation, the authors strongly advocate that the surgeon focus on the entire facial appearance and let

Disclosure: None of the authors has any financial conflicts of interest.
[a] Division of Plastic Surgery, Department of General Surgery, Oregon Health & Science University, 3181 SW Sam Jackson Park Road, Mail Code L352A, Portland, OR 97201, USA; [b] Division of Facial Plastic and Reconstructive Surgery, Department of Otolaryngology–Head and Neck Surgery, Oregon Health & Science University, Center for Health and Healing, CH5E, 3303 Southwest Bond Avenue, Portland, OR 97201, USA
* Corresponding author.
E-mail address: jens.berli@gmail.com

Facial Plast Surg Clin N Am 27 (2019) 251–260
https://doi.org/10.1016/j.fsc.2019.01.003
1064-7406/19/© 2019 Elsevier Inc. All rights reserved.

patients point out aspects of their face that they perceive as affirming of their identified gender first. It is advised to avoid strong wording around masculine features and, unless specifically requested to, avoid pointing out those features. On the other hand, it is beneficial to point out the gender-affirming facial features that the patient may already have. The authors refer to this as the "facial gender mosaic" concept. Each face contains feminine and masculine traits. To start out by acknowledging and demonstrating the feminine aspects, the authors potentially assist patients in seeing these aspects for the first time. This not only helps build trust but also lays a foundation to see a patient's authentic female face. Bringing the discussion back to the nose at the end of the consultation and how the nose interacts with other discussed aspects of the face. To fruitfully engage in this conversation, the surgeon must also be informed on gender norms as well as ethnic considerations.

Patient Expectations

Patients seeking FGCS look for a face that is congruent with and affirming of their gender identity. Although this statement sounds simple, it only covers one aspect of the surgical plan: to achieve the opposite gender norm (discussed later). It does not address the version of the nose that is most congruent with patients' anatomy and genetics or patients' internal vision of themselves. Complicating this is that patients often have a negative self-image as it pertains to the face and may have avoided photographs and mirrors for years. In contrast, a cisgender patient often has specific concerns around nasal appearance. For trans-identified patients, a frequently cited request is to make the nose "smaller" and "more sloped." It is, therefore, advised that the conversation around goals starts with the current anatomy and potentially involves photographs of female family members and of perceived ideals.

Setting expectations necessarily involves a thorough evaluation of the intricate anatomy of the nose with its innumerable variations. No single operative plan can be applied to all noses and myriad surgical maneuvers are necessary to successfully perform a feminizing rhinoplasty. On external examination, the skin quality deserves particular attention. Skin thickness and quality may limit the degree of nasal tip refinement that can be accomplished (**Fig. 1**). Exogenous estrogen can have marked effects on skin quality and it may be advised to await the full effect that usually sets in approximately 1 year to 2 years after initiation. The surgeon should discuss realistic expectations and define goals. Simulation software and imaging can assist in this discussion. A commonly heard prejudice is that the transgender patient population has a high degree of body dysmorphia; however, in the authors' experience, this has not been found true.

Functional Considerations as They Pertain to Facial Gender Confirmation

Analogous to rhinoplasties in cisgender patients, functional aspects leading to nasal obstruction need to be taken into consideration, including septal deviation, internal and external valves, and the inferior turbinates. Based on current literature, it can be assumed that there is a higher rate of obstructive sleep apnea in the trans-female

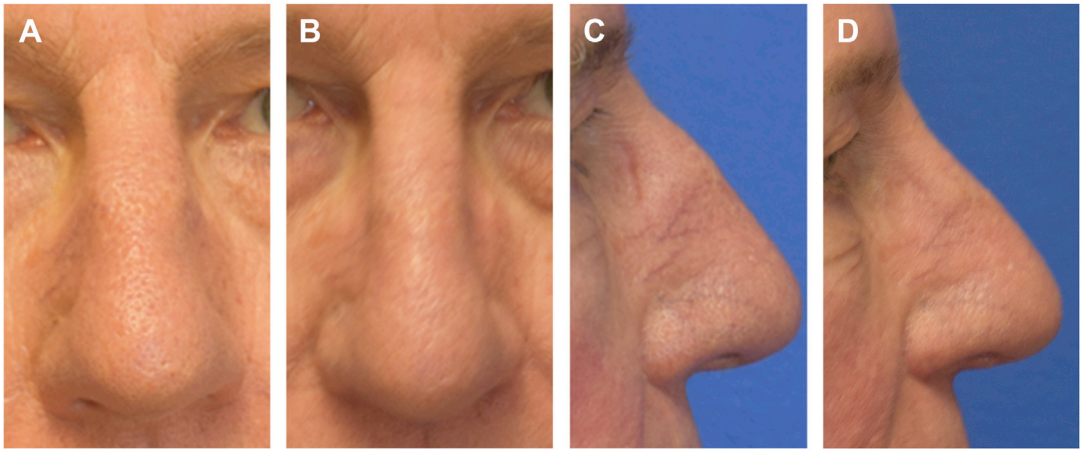

Fig. 1. Patient who presents for feminizing rhinoplasty with porous and thick nasal skin. Before and after tip refinement and dorsal hump reduction through an open approach. Patient did not want to have a slope. (*A*, *C*) Preoperative. (*B*, *D*) Postoperative. Result limited by thick skin envelope. (*Courtesy of* Dr Jens Berli.)

population compared with the cisgender female population; as such, this should be included in the preoperative discussion. Presence of obstructive sleep apnea may be a relative contraindication to combined jaw surgery and rhinoplasty.[1]

Fig. 2 shows a patient who presented for a secondary functional rhinoplasty due to persistent septal deviation and internal valve obstruction but also requesting feminization of the nasal tip.

Gender and Ethnic Differences in Nasal Anatomy

Before diving into the discussion of norms, it should be pointed out that ideals are subject to the times and culture lived in.(**Fig. 3**) There are gender norms that are likely to represent the binary ends of the gender spectrum. Dr Spiegel[2] makes the argument that it is beneficial to try to achieve these extremes because this may assist in decreasing the incidence of being misgendered. Going unrecognized in society as being the opposite gender assigned at birth is probably the most important outcome parameter of FGCS.

The authors agree with the spirit of decreasing cues that increase the probability of misgendering and also believe that patients should be directly involved in the decision because not everyone necessarily wants an appearance altered to match what a surgeon considers the binary end of the spectrum. For example, **Fig. 4** shows a patient who had been recommended dorsal hump reduction and tip work during a feminizing FGCS consultation at a different office, but she preferred to have a straight dorsum and keep her rotation. Her rhinoplasty was performed to feminize her appearance and meet her specific goals.

Another critical consideration is ethnicity and cultural context. A patient with an indigenous American heritage may not want a sloped dorsum because it is not congruent with her ancestry; for this patient, a mild hump or straight nose may be more desirable. On the other hand, another patient of the same ethnic background may live in a different cultural context and desire to blend in with her surroundings, thereby having different goals for her appearance. Ethnic and cultural aspects should be part of the preoperative discussion.

Lastly, cultural trends should be considered within the context of longer-term goals. A patient

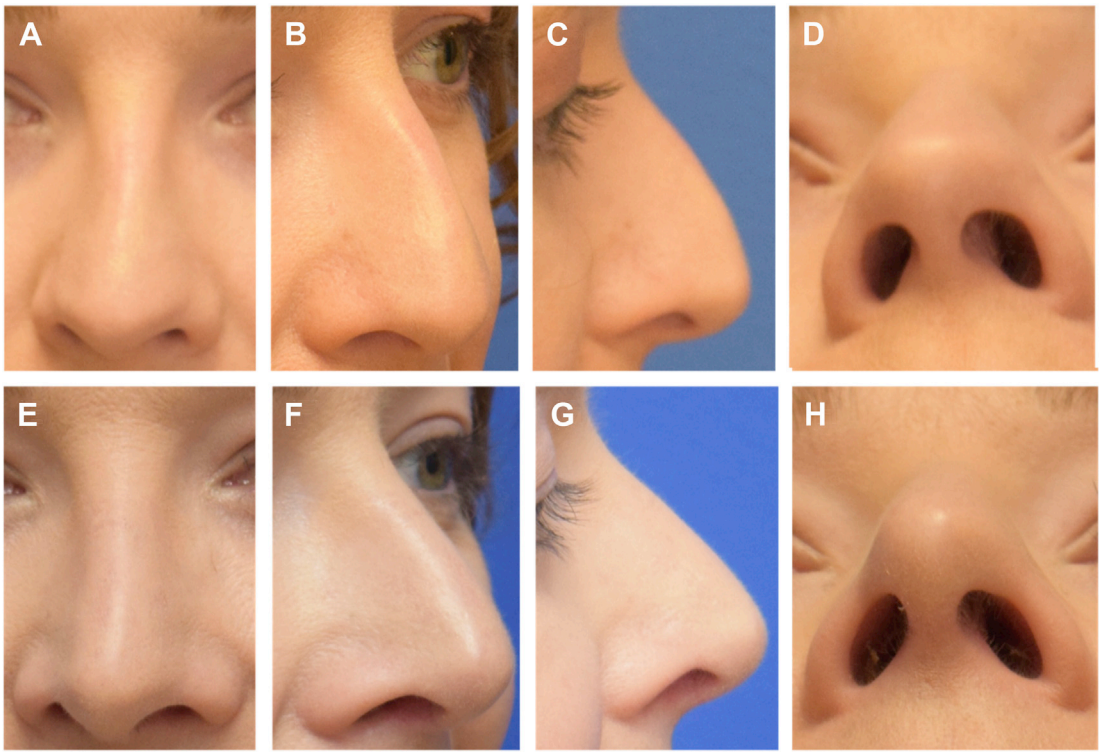

Fig. 2. Patient with status post–closed septorhinoplasty in the past with persistent deviated septum and internal valve obstruction. Functional revision and feminizing rhinoplasty performed through an open approach with component dorsal hump reduction, trapezoid spreader grafts with approximation of upper lateral cartilages, cephalic trim, tip sutures, alar rim, and columellar strut grafts. (*A–D*) are preoperative. (*E–H*) are postoperative. (*Courtesy of* Dr Jens Berli.)

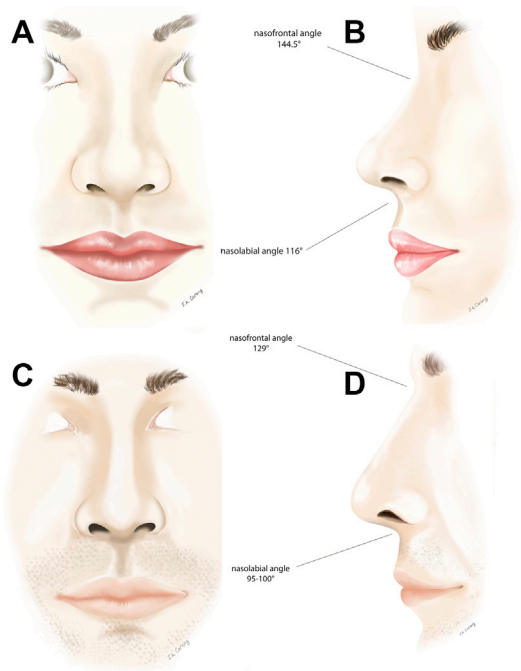

Fig. 3. Drawing of an example of a white gender norm. (*A*, *B*) are female gender normal. (*C*, *D*) are male gender normal. (*Courtesy of* Jens Berli and Jourdan Carboy.)

may present early in her life and seek to be feminized as to the latest trends on social media, but later in life find she lost a facial uniqueness she now desires. These aspects should be part of an educated discussion with the patient.

To help guide this discussion, the authors find it helpful to ask patients to bring in photographs of female family members and perceived ideals.

Gender norms of the face are profoundly impacted by the advent of puberty. Once testosterone levels rise, the bony and cartilaginous framework of the face undergoes marked changes. Similarly, the soft tissue envelope experiences change with increase in porous diameter and dermal thickness.

The expansion of the frontal sinus in male puberty leads to a more acute nasofrontal (NF) angle. Springer and colleagues[3] published a photographic study evaluating the white gender norms as they pertain to nasal anatomy. They noted an optimal NF of 129° in men compared to 144.5° in women. This angle is not addressed adequately by rhinoplasty alone but requires frontal bone reduction (discussed later). The radix is also generally higher in men. The ideal feminine position cited by Springer and colleagues[3] is just above the pupil, whereas in men it is at the upper lid crease. Men in most Asian and some African races, however, have a radix that is lower. The width of the nasal pyramid is wider in men than in women, with the dorsal aesthetic lines straight in the male ideal versus concave the female. The masculine nose is also more projected, with an average projection of 34 mm in men and 29.6 mm in women. Springer and colleagues[3] also noted the nasal tip rotation is decreased in men compared with women. Tanna and colleagues[4] report a nasolabial angle of approximately 95° to 100° in men and 100° to 110° in women. Decreasing nasal projection and increasing nasal tip rotation is a frequent goal of feminizing rhinoplasty. The degree of expected columellar show based on gender is a matter of debate. In the study by Springer and colleagues,[3] women had an increase columellar show compared with men. No such difference was seen in the Tanna and colleagues[4] study. The alar base width is another aspect that is markedly different. The Springer and colleagues[3] study cited a 4-mm difference in alar width between genders whereas men had a wider alar base. Lastly, they report length of the cutaneous upper lip is longer by 4 mm in men versus women. These differences lead to use of alar base reduction and subnasal lip lift during FCGS and feminizing rhinoplasty.

Financial and Psychosocial Aspects

As transgender people become more visible, FGCS has expanded. Third-party insurers and self-insurers, as well as some state insurance markets, are considering FGCS a covered benefit, rejecting the notion that FGCS is an aesthetic intervention. Even in this climate, FGCS remains costly and out of reach for many patients. Transgender people face numerous economic and health disparities, and understanding the psychosocial health of patients is an important consideration in planning for surgery.[5] Complicating social factors, such as financial hardship, unsafe home environments, unemployment, poverty, and even homelessness, can be present. The authors have encountered multiple patients who had previous self-inflicted nasal trauma with the hope to qualify for a posttraumatic rhinoplasty. Evaluation of a patient's psychosocial condition is, therefore, particularly important in these vulnerable patient populations. In particular, patients who have not yet transitioned socially should be encouraged to have a mental health professional at their side assisting them throughout the social transition period that may come with significant stressors.

It is incumbent on surgeons and their office staff to help patients understand if their insurance would cover the procedure.

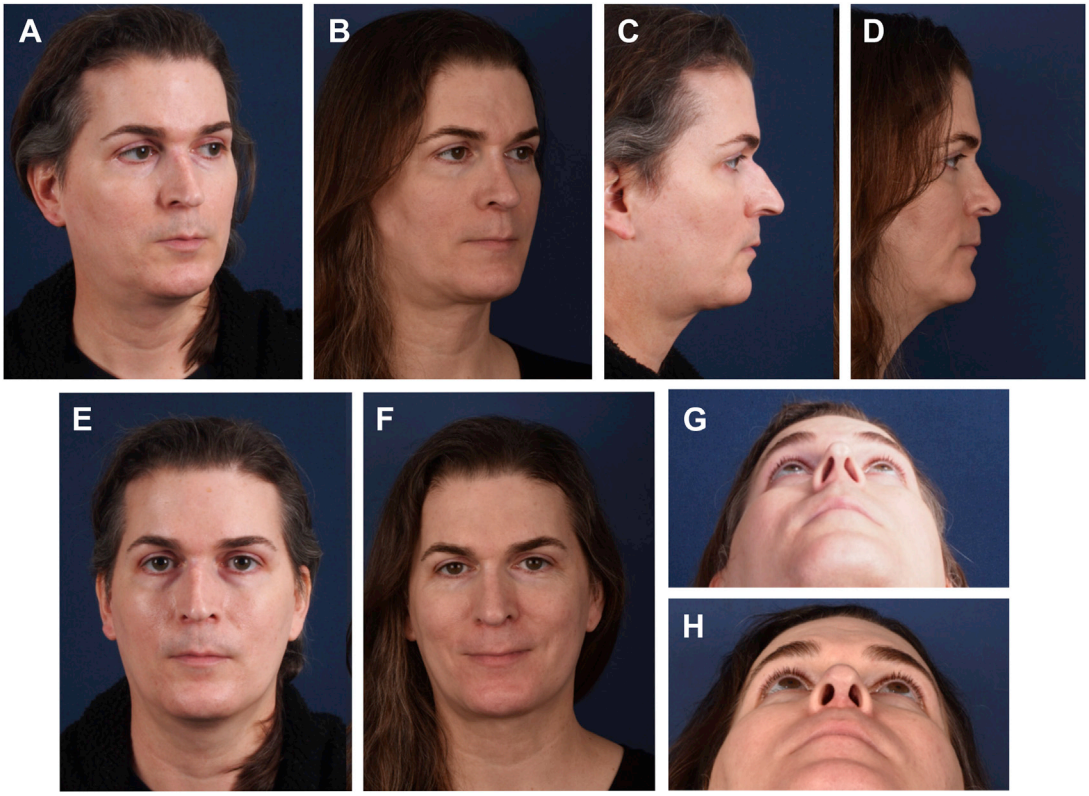

Fig. 4. A hump reduction with radix grafting was used to refine the nasal dorsum. Upper lateral cartilage turn-in flaps were used for the midvault. Projection of the nasal tip was decreased, and rotation was maintained per the patient's request. Cephalic turn-in flaps and alar rim graft were used. An alar base reduction was done to address alar flaring after decreasing projection. (*A*, *C*, *E*, and *G*) Preoperative. (*B*, *D*, *F*, and *G*) Postoperative. (*Courtesy of* Dr Myriam Loyo.)

Note on Gendered Language and Nonbinary Identity

A critical consideration of humane care for transgender identifying patients is respecting a patient's stated gender identity. For the novice to this field, this can be particularly challenging when confronted with patients who do not identify on the binary gender spectrum. In the authors' experience, nonbinary identified patients seeking gender surgery of the chest are almost exclusively female assigned at birth, whereas patients seeking FGCS predominantly are male assigned at birth. Patients should be asked for their preferred pronouns, and the surgeon and all office staff should ensure correct pronoun use. Misgendering by medical personnel has been cited as stressful and, in some cases, traumatic to patients, many of whom carry previous psychosocial trauma.[5,6] Although in-depth discussion of affirming language outside the scope of this article, it is recommended to access frequently updated resources because the language around this care is still evolving. Finally, note that the use of "masculine/male" and "feminine/female" in this anatomic discussion follows gender norms based on gender assigned at birth.

FEMINIZING RHINOPLASTY—TECHNICAL CONSIDERATIONS

Dorsum/Radix

In the profile, the dorsal projection and slope are usually changed to a straight or slightly concave shape that assists in opening the NF angle. (**Figs. 4–6**) A useful guideline for nasal dorsum projection is to draw a line from the nasion to the ideal nasal tip position and have the dorsal projection be 1 mm to 2 mm posterior to this line. As discussed previously, ethnic variations may affect this and should be taken into consideration.

In the front view, reducing the width of the dorsal bridge is common, with the goal to have concave rather than straight dorsal aesthetic lines. The optimal width has been described as 75% to

Fig. 5. The procedures performed included hairline lowering, forehead contouring, right browlift, rhinoplasty, and neck lift. The techniques used for rhinoplasty included a hump reduction and radix grafting for the nasal dorsum and tongue-in-groove to rotate and deproject the nose and cephalic turn in flaps to refine the nasal tip. (*A*) Prior to gender transition. (*B*, *D*) preoperative. (*C*, *E*) Postoperative. (*Courtesy of* Dr Myriam Loyo.)

80% of the alar base width in a female patient with normal alar base width.[7] With these goals in mind, it is common for feminizing rhinoplasty to include technical maneuvers, such as narrowing osteotomies, hump reductions, and radix grafting. Hage and colleagues[8] reported on 22 feminizing rhinoplasties where they used lateral and medial osteotomies in all cases and performed a hump reduction in slightly more than 50% of patients. The NF angle has been used by several investigators as an outcome measure that describes the changes in dorsal shape in feminization rhinoplasty. Nouraei and colleagues[9] from the United Kingdom describe an increase in NF angle from 142° to 151°. These investigators also increased the supratip angle from 2° to 13°. Similarly, Bellinga and colleagues[10] from Spain reported a change in the NF angle from 134° to 149° in their cohort, which includes 200 patients and is the largest cohort to date. In rhinoplasty cases of dorsal reduction, it is important to remember the important function of spreader grafts to stabilize the shape of the dorsum and provide support to the internal nasal valve.

Tip Work

Modifying the nasal tip has been deemed the hardest part of rhinoplasty by many expert rhinoplasty surgeons because of delicate nature of the modifications. Nasal tip refinement is an almost universal goal of feminizing rhinoplasty. Understanding the tripod concept of the nose is essential in understanding how changes to 1 cartilage affect the overall 3-D structure of the nasal tip. Surgeons performing feminizing rhinoplasty need to successfully decrease nasal tip projection, increase rotation, and decrease width. Especially in feminizing rhinoplasty, this can be daunting because the tip often is severely overprotected and underrotated. Compared with cisnormative rhinoplasty, the feminizing rhinoplasty often necessitates

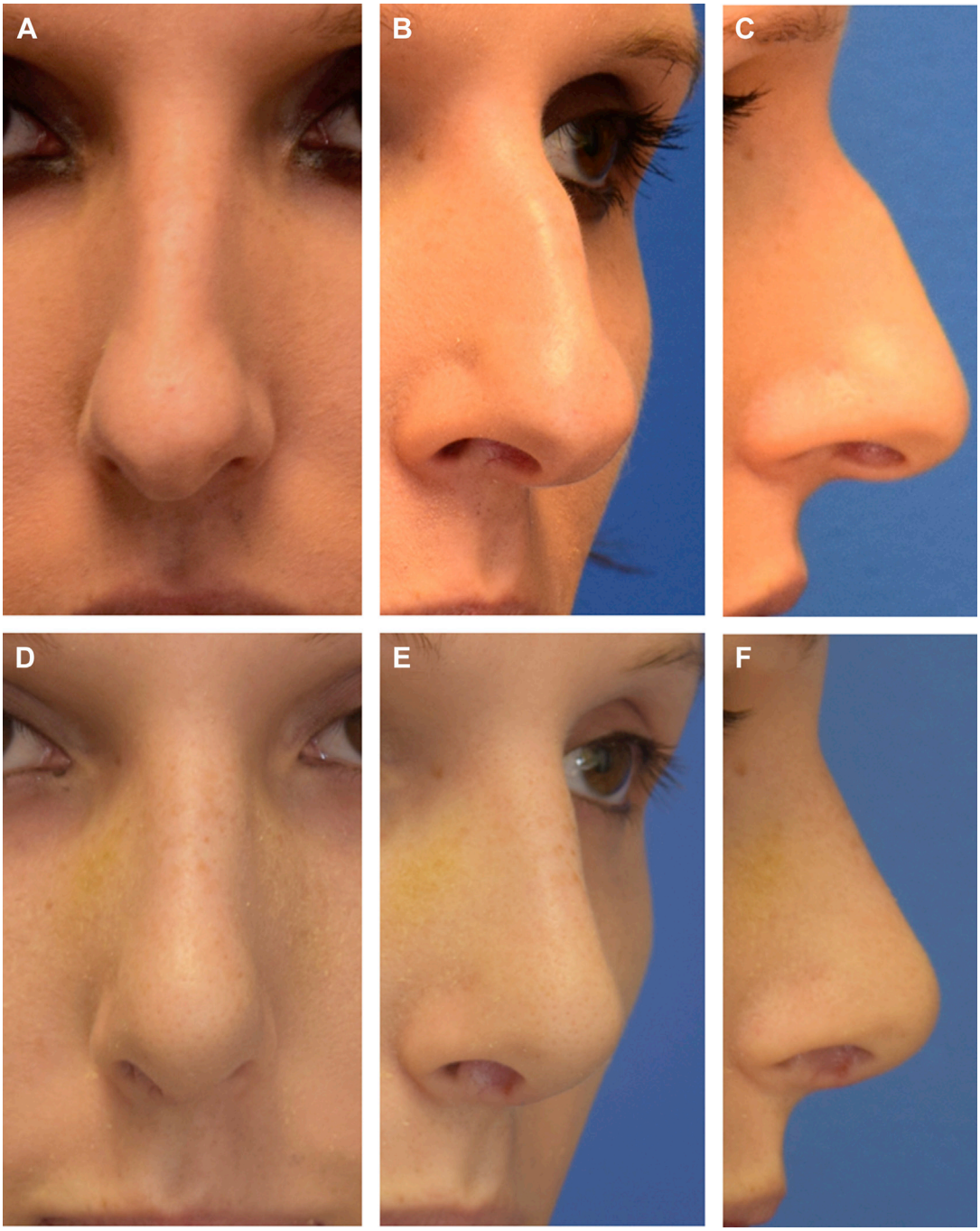

Fig. 6. Feminizing rhinoplasty: component dorsal hump reduction 4mm, caudal septal resection, low to high osteotomies bilateral, cephalic trim, LLC overlay, alar rim grafts, tip defining sutures, temporal-parietal fascia and diced cartilage dorsal onlay graft. Patient also had forehead reduction and browlift. (*Courtesy of* Jens Berli, MD.)

more aggressive techniques to not only normalize the projection within the natal gender norm but also transition it to the feminine spectrum. Nouraei and colleagues[9] reported changes in nasal tip rotation during feminizing rhinoplasty by reporting the nasolabial angle increase from 107° to 115°. Nouraei and colleagues[9] also reported that tip modifications were their only modification in approximately half of their cases (5 of 12 cases). Care should be taken when increasing nasal tip

rotation to control tip projection and prevent an unnatural supra tip break.

Successfully decreasing projection of the nasal tip may require an interrupted strip technique with either overlay or resection of a portion of the lower lateral crura (LLC). When LLC are divided, asymmetric healing and scarring are concerns and meticulous operative technique is necessary. Refining the nasal tip considers the overall shape of the LLC and the position of the tip defining points. The shape of the LLC can be modified to flatten convex cartilages and reduce a bulbous tip as well as reduce excessively wide LLC by means of cephalic trim.

Nasal tip suture techniques and nasal tip grafts can be used to address the final nasal tip definition. When modifying the nasal tip, creating a stable construct and using cartilage grafting to restore nasal tip support is essential in preventing postoperative collapse. As part of the nasal tripod, the shape and strength of the columella should also be considered to prevent postoperative deviations and prevent tip ptosis considering the use of columellar strut grafts, caudal septal extension grafts, or tongue in groove techniques. In addition to the tripod cartilages, the final alar shape should be carefully considered, particularly in cases of dramatic reduction of the LLC width in which alar retraction could occur postoperatively. The authors frequently use alar rim grafts to prevent alar retraction and external valve collapse.

Alar Base

Alar base reduction is most commonly performed after the other structural changes to the nose have been completed. A useful guideline in considering alar base reduction is to compare the width of the ala to the intercanthal distance; if the alar base is wider, an alar base reduction should be considered. Alar flare that was not present preoperative can occur after deprojection of the nasal tip, and alar base reduction should be considered for these cases. Planning the incisions to camouflage the scars is extremely important to prevent unsightly scars (**Fig. 7**).

Combining Feminizing Rhinoplasty with Other Surgeries

Rhinoplasty is frequently combined with other procedures to achieve a feminization. A review of the literature confirms this and is reviewed here. Raffaini and colleagues[11] out of Italy reported on 33 FGCS patients who all underwent rhinoplasty, jaw contouring, and lip augmentation. Frontal reshaping and thyroid cartilage reduction were performed in 94% and 79% of patients, respectively. Similarly, Hage and colleagues[8] from the Netherlands reported that 21 (60%) of 35 patients had a rhinoplasty as part of another FGCS surgery. In the Bellinga and colleagues[10] case series, 75% of the 200 patients had forehead feminization in combination with rhinoplasty and only 2.5% of patients underwent

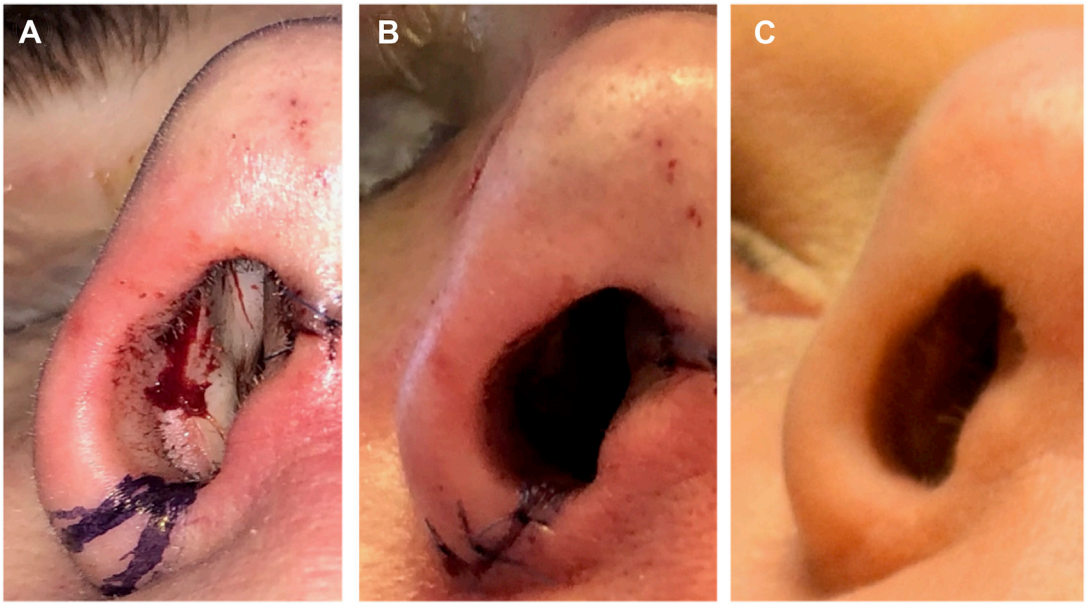

Fig. 7. Close-up view of alar base excision with the planned incisions to be hidden in the nasal sil. (*A*) Perioperative. (*B*) Immediately postoperative. (*Courtesy of* Dr Jens Berli.)

an isolated rhinoplasty. Because this team is specifically set up as a global destination for feminizing procedures, it can be postulated that providers in the United States will have a higher rate of requests for isolated rhinoplasty.

There are differences of opinion among surgeons regarding whether to combine rhinoplasty and a forehead feminization or perform the procedures separately. Raffaini and colleagues[11] advocated performing rhinoplasty first and delaying forehead contouring for 6 months when the jawline and nose are less swollen. In contrast, Bellinga and colleagues[10] frequently combine rhinoplasty and forehead contouring. The Bellinga and colleagues[10] study also exposes the nasal radix through the bicoronal approach and when necessary to reduce the radix. Both studies have published beautiful results that meet the goal of facial feminization. The authors agree with the Bellinga and colleagues[10] study, that improved exposure of the radix is possible when combining the forehead feminization and rhinoplasty. As for sequence during the surgery, the authors recommend performing the rhinoplasty last because the forehead flap can compress the nose.

When combining rhinoplasty with mandible and chin procedures, Bellinga and colleagues[10] recommend starting the surgery by using nasotracheal intubation for the mandibular procedures and subsequently exchanging the endotracheal tube to an oral tube to proceed with the rhinoplasty. In the authors' practice, forehead, mandibular, and nasal procedures are combined during the same procedure and the procedures performed with orotracheal intubation without exchanging tube position during surgery.

Lip lift procedures are intended to reduce the vertical height of the cutaneous upper lip, increase vermillion, and achieve upper incisor show. The literature and the authors' experience show that this can safely be performed during the same surgery (**Figs. 8 and 9**). Two groups have published on this combination of procedures with excellent results and no reported ischemic insults. Insalaco and Speigal[12] published a case series of 105 cases in which the transcolumellar incision was used for an open rhinoplasty approach and a separate incision was used for the lip lift. Bellinga and colleagues[10] reported 12% of their patients undergoing rhinoplasty also underwent a lip lift concomitantly (total 24 patients). In their series, the entire rhinoplasty is performed through a subnasal lip lift incision. Insalaco and Speigal[12] specifically comment on resecting skin from the columella during rhinoplasty in cases of significant nasal tip deprojection.[12] If alar base reduction is intended during surgery, placement of these incisions also should be considered. Delaying the lip lift until the alar reduction incision has healed is a reasonable consideration to prevent nostril stenosis and excessive scarring.

Fig. 8. The procedures performed included forehead contouring with sinus setback, tracheal shave, feminizing rhinoplasty, and lip lift. Incisions: columellar stair step and separate subnasal lip lift incision. (*A*) Preoperative. (*B*) Postoperative. (*Courtesy of* Dr Jens Berli.)

Fig. 9. Demonstration of the 2 separate incisions. (*Courtesy of* Dr Jens Berli.)

REVISIONS

Achieving patient satisfaction after rhinoplasty for gender confirmation involves a combination of meticulous technical maneuvers and open communication to discuss expectations and perceptions of femininity. In the cases series by Nouraei and colleagues,[9] several patients stated that their rhinoplasty was of the factors with the greatest impact in being perceived as female. The few case series that specify revision rates for feminizing rhinoplasties report rates and indications similar to larger cisgender rhinoplasty case series.[13] Hage and colleagues[8] reported that 18% of patients underwent revision after feminizing rhinoplasty (4 of 22 patients). In this case series, all patients reported a more feminine appearance. The largest case series of feminizing rhinoplasty is by Bellinga and colleagues[10] from Spain. In this case series, 4% of patients underwent revision (8 of the 200 patients). The reported indications for revision rhinoplasty were dorsal irregularities, unmet expectations of tip refinement, and chronic infection of the nasal tip.

SUMMARY

Surgeons offering feminizing rhinoplasty not only should be proficient with technical aspects of feminizing rhinoplasty but also have the necessary knowledge and compassion to provide affirming care. A comprehensive preoperative assessment and setting realistic expectations are crucial to successfully treating gender dysphoria associated with facial features.

ACKNOWLEDGMENTS

Seva Khambadkone, BS, for her help with editing the article. Kylie Blume, BS, MA, for her help with editing the article and submission process.

REFERENCES

1. Lin CM, Davidson TM, Ancoli-Israel S. Gender differences in obstructive sleep apnea and treatment implications. Sleep Med Rev 2008;12(6):481–96.
2. Spiegel JH. Rhinoplasty as a significant component of facial feminization and beautification. JAMA Facial Plast Surg 2017;19(3):181–2.
3. Springer IN, Zernial O, Nölke F, et al. Gender and nasal shape: measures for rhinoplasty. Plast Reconstr Surg 2008;121(2):629–37.
4. Tanna N, Nguyen KT, Ghavami A, et al. Evidence-based medicine: current practices in rhinoplasty. Plast Reconstr Surg 2018;141(1):137e–51e.
5. Grant JM, Mottet L, Tanis JE, et al. Injustice at every turn: a report of the national transgender discrimination survey. National Center for Transgender Equality; 2011.
6. Socías ME, Marshall BD, Arístegui I, et al. Factors associated with healthcare avoidance among transgender women in Argentina. Int J Equity Health 2014;13(1):81.
7. Papel ID, Frodel JL, Holt GR. Facial plastic and reconstructive surgery. Thieme; 2016.
8. Hage JJ, Vossen M, Becking AG. Rhinoplasty as part of gender-confirming surgery in male transsexuals: basic considerations and clinical experience. Ann Plast Surg 1997;39(3):266–71.
9. Nouraei SR, Randhawa P, Andrews PJ, et al. The role of nasal feminization rhinoplasty in male-to-female gender reassignment. Arch Facial Plast Surg 2007;9(5):318–20.
10. Bellinga RJ, Capitán L, Simon D, et al. Technical and clinical considerations for facial feminization surgery with rhinoplasty and related procedures. JAMA Facial Plast Surg 2017;19(3):175–81.
11. Raffaini M, Magri AS, Agostini T. Full facial feminization surgery: Patient satisfaction assessment based on 180 procedures involving 33 consecutive patients. Plast Reconstr Surg 2016;137(2):438–48.
12. Insalaco L, Spiegel JH. Safety of simultaneous lip-lift and open rhinoplasty. Jama Facial Plast Surg 2017; 19(2):160–1.
13. Guyuron B, Bokhari F. Patient satisfaction following rhinoplasty. Aesthetic Plast Surg 1996;20(2):153–7.