Gender-related Facial Analysis

Chrisovalantis Lakhiani, MD[a], Michael T. Somenek, MD[b,*]

KEYWORDS

• Gender • Face • Facial • analysis • Dysphoria

KEY POINTS

- There exist several known anthropometric differences between the male and female facial skeleton and soft tissues.
- The use of facial canons is not practical, and often inappropriate for analyzing morphologic differences of sex.
- A standardized system should be used for approaching facial analysis for gender dysphoric patients.

INTRODUCTION

Increasingly in the United States, gender dysphoria is being recognized by the surgical community, and transgender individuals are afforded the ability to undergo gender affirmation surgery. Current estimates for male-to-female transgenderism range from 1 in 11,900 to 1 in 45,000 for male-to-female individuals, and 1 in 30,400 to 1 in 200,000 for female-to-male individuals according to the World Professional Association for Transgender Health.[1] Still other scholars suggest that the prevalence of transgenderism is likely much higher.[1]

Although gender affirmation surgery has long been considered in the surgical literature, there is comparatively little describing morphologic differences between the feminine and masculine faces, and how to achieve them. The increasing prevalence of gender affirmation surgery reveals a shift in therapeutic treatments for gender dysphoria from being focused on the genitalia as the location of bodily sex toward an understanding of sex as a product of social recognition.[2] In a study by Ainsworth and Spiegel,[3] it was shown that the mental health quality of life for male-to-female individuals was diminished compared with the baseline population. However, performance of gender affirmation surgery resulted in a return of mental health quality of life to mean population levels. In addition, despite challenges associated with this surgery,[4] patient satisfaction levels following feminization of the male face are generally very high.[5,6]

Nevertheless, although aesthetic considerations for female facial morphology have been well described, the characteristics that allow a face to be recognized as decidedly masculine or feminine are more difficult to describe and not able to be recognized as a function of external influence (eg, gravity, sunlight). Often, surgeons are forced to use proportions of facial harmony that may be insufficient to achieve the patient goal, or inappropriate to use at all. This article provides a systematic method of facial analysis for gender dysphoric patients seeking facial affirmation surgery and elucidates critical areas that should be addressed with each patient so that the surgical plan and expectations can be discussed preoperatively.

BACKGROUND

The Greco-Roman artists sought to capture and numerically define the ideal form of the human

Disclosure: The authors have nothing to disclose.

[a] MedStar Georgetown University Hospital, 3800 Reservoir Road, Washington, DC 20007, USA; [b] Advanced Facial Plastic Surgery, 2440 M Street Northwest #507, Washington, DC 20037, USA
* Corresponding author.
E-mail address: drsomenek@somenekmd.com

Facial Plast Surg Clin N Am 27 (2019) 171–177
https://doi.org/10.1016/j.fsc.2019.01.006
1064-7406/19/© 2019 Elsevier Inc. All rights reserved.

figure. These forms have come to be known as artistic (sometimes divine) canons, or rules of simple proportions to describe the ideal human form. The canons of facial proportion evolved with the use of Pythagorean mathematics, the best known of which is the so-called golden proportion (1.618). The use of these canons was revived by Renaissance and neoclassical artists, including Albrecht Durer and Leonardo da Vinci. From these artists, several new canons were introduced, including division of the head and face into equal halves, thirds, or fourths, or vertically into equal fifths.[7,8]

What is currently known of the neoclassical canons is from the remnants of much larger bodies of work in artistic experimentation. That is, the intention of these artists was never to describe the typical or normal morphologic appearance of the human face. The growth of anthropometrics in the nineteenth and twentieth centuries afforded scientists the ability to confirm the reliability of the classical canons. The findings were that some of these familiar canons, such as the 3-part and 4-part horizontal divisions, do not exist in nature,[7,8] whereas others represent only a small fraction of natural variation[9] (**Fig. 1**).

The work of anthropometrists such as Leslie Farkas has offered insight into the diversity of human facial morphology. There are notable differences in morphology depending on race, ethnicity, age, and sex. Although it is established that concepts of fashion and beauty may vary by culture, there are generally distinct differences in facial sexual characteristics for any race or ethnicity. It is therefore important for surgeons to familiarize themselves with the anthropometric normative values for the population they are serving. Because a complete discussion of facial sexual dimorphism for all races or ethnicities is outside the scope of this article, this discussion is limited to the white population.

FACIAL ANALYSIS

In general, the male skull is larger, with an endocranial capacity approximately 200 g greater than that of the female, and is usually less round.[8,9] The female skull differs from the male in that it is has more pronounced zygomatic prominences leading to a pointed chin, creating a heart shape, compared with the squarer male skeleton.[10]

It is useful when analyzing the face in preparation for a masculinization or feminization procedure to divide the face into thirds and proceed using a top-to-bottom method. Thus, it is divided into the upper third (forehead region, brow), middle third (orbit, nose, cheeks), and lower third (lips, mandibular width, chin). Skeletal and soft tissue differences are each described for the anatomic subunit when appropriate.

Summaries of the differences between the male and female face and facial skeleton are provided in **Tables 1–3**.

UPPER THIRD

Analysis of the upper third of the face should include evaluation of the hairline shape, forehead length, forehead convexity, supraorbital bossing, glabella, nasofrontal angle, and brow position (see **Table 1**).

The feminine hairline is generally full and smooth contoured. In contrast, the male hairline may be receding and possess a so-called widow's peak or M-shaped hairline. There is generally a shorter distance from nasion to hairline in the female face by approximately 1 cm (5 cm in women, 6 cm in men).[10,11]

The supraorbital ridge is generally more pronounced in the male face, and there is a less steep slant from the supraorbital ridge to the vertex.[6,9,12] In contrast with the female forehead, which possesses a smooth convexity from the orbit to

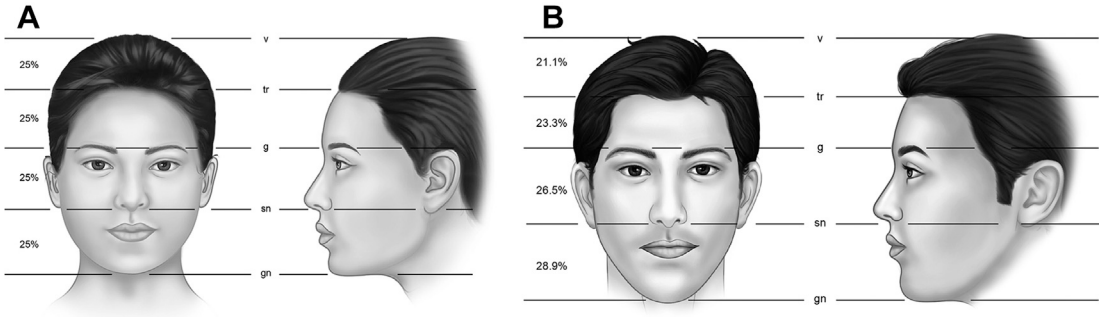

Fig. 1. The neoclassical canons of facial proportion have often been used as an adjunct to modern facial analysis (*A*, female; *B*, male). Nevertheless, the fallacy of these canons in restoring gender-related facial proportions is shown here, because normal anthropometric measurements are different.

Table 1
Upper third

Upper Third	Female	Male
Hairline shape	Smooth	M shaped
Nasion-trichion distance	Shorter than in men	High
Forehead convexity	Less convex, sloping	Flat or convex
Supraorbital bossing	Minimal or absent	Pronounced
Nasofrontal angle	Obtuse	Acute
Glabella	Less protruding	Wider, more protruding
Brow position	Above the supraorbital rim, raised at the lateral third	At the level of the supraorbital rim

vertex, the male forehead displays supraorbital bossing with a prominent anterior convexity to the forehead. Frontal sinus development contributes to greater convexity of the medial forehead in men, which leads to a discontinuous curvature compared with the female skull. Contrastingly, in women supraorbital bossing is considerably less, or minimal. The forehead is less flat, with a generally continuous mild curvature that continues to the vertex.[6,13]

In men, the medial supraorbital ridge blends into the glabella. Thus, men generally have a greater glabellar projection than women and this is considered more masculine.[10] However, the range of glabellar variation is much wider than that of the ridges.[9] More important in this region is attention to the nasofrontal angle, which is more acute in men and more obtuse in women.[14] Importantly, the nasoglabellar region represents the transition between the nose and forehead, and should be considered as an entity for affording facial harmony between upper and middle thirds during surgical planning.[15]

The female brow is club shaped medially, starts at or below the rim, then arches laterally to where it peaks at the lateral third. The most lateral portion of the female brow lies 1 to 2 mm above the medial aspect of the brow, and the entire brow lies at or above the superior orbital rim.[10] In contrast, the male brow tends to be thick, straighter, and tends to lie at the level of the superior orbital rim.[14,15] As in cis-gendered women, transgender women may also apply makeup or tattooing to enhance the shape or thickness of the brow. This makeup must also be noted when considering altering the shape or position of the brow (**Fig. 2**).

MIDDLE THIRD

Analysis of the middle third should include examination of the orbita and periorbital tissue, nose (with special notice of the nasal dorsum, tip, and alar base width), zygomatic width, and zygomatic prominence.

The female orbital height is less than that of men; however, the orbita are generally larger.[9] The upper and lateral portions of the orbital rims are less pronounced than in men.[16] The male upper eyelid crease is generally positioned lower, with a minimum of 8 mm above the lid margin, compared with a maximum of 12 mm for women. The male upper lid also appears fuller, with less pretarsal show.[10] The canthal tilt is subtly more positive in women.[8,10] In contradistinction to the upper lid, there are no significant differences in the lower eyelids of men and women. Spiegel makes note of the

Table 2
Middle third

Middle Third	Female	Male
Orbits	Wider, slight positive tilt	Narrower, neutral tilt
Zygomatic width	Slightly less wide	Wider
Zygomatic prominence	More prominent	Less prominent
Cheek hollowing	Varies by culture	Varies by culture
Nasal dorsum	Straight or slightly concave	Straight or dorsal hump
Alar base width	Much narrower	Wide

Table 3
Lower third

Lower Third	Female	Male
Lips	Greater vermilion show	Less vermilion show, greater cutaneous portion
Mandibular width	Narrower than zygomatic width	As wide as zygomatic width
Gonial angle	More obtuse	More acute
Chin	Trapezoidal, shorter	Square, longer

increased periorbital soft tissue luminance seen in women, likely caused by decreased dermal thickness, and suggests this be addressed as well.[17] The overall appearance is more youthful or cherubic, with larger orbita relative to facial volume and a less sunken appearance.

As previously noted, the nose has a more acute glabellar angle in men than in women.[6,7,9,13] Male nasal bones are generally larger and tend to meet in the midline at a sharper angle.[9,18] The nasal aperture in men is higher and narrower, with sharp rather than rounded margins. Thus, the male nose is somewhat square at the base with a more pronounced dorsal prominence. In contrast, female noses are smaller and shorter; they have narrower bridges and narrow alar bases, with a more obtuse nasolabial angle.[14,18] The male nose may have a dorsal hump or straight dorsum with very little supratip break, whereas the female nose is considered attractive if it shows a straight or mildly concave dorsum with an accented tip.[13,18] The male nose has a slightly wider nasal root than the female nose and a somewhat wider alar width. However, there is a significantly large difference between labial insertions of the alar base in men compared with women.[7] The nasal width to lip ratio is thus larger in men than in women.

The cheek bones are heavier in men, with a flatter convexity. Contrastingly, they are lighter but also more prominent in women.[9,12,14] Often, this is accentuated with some cheek hollowing in the submalar region. Increasing the width of the zygomatic complex creates more roundness of the facial contours and allows the orbits to appear larger.[12] Although interzygomatic distance is generally larger in men, the zygomatic prominence is generally more anterior in women. In addition, there is a significantly greater fullness in the maxilla relative to the mandible in women, which lends a heart-shaped appearance to the face[8] (**Fig. 3**).

LOWER THIRD

Analysis of the lower third should include examination of vermilion show and fullness, mandibular width, gonial angle, chin shape, chin height, and chin width.

Female upper lips are fuller and shorter with a good show of the vermilion and a well-formed Cupid's bow.[14] The upper lip is shorter and wider than in men. The vermilion and cutaneous portions of the lower lip in women are about equal in thickness, whereas in men the vermilion portion tends to be thinner than the cutaneous segment.[8] In

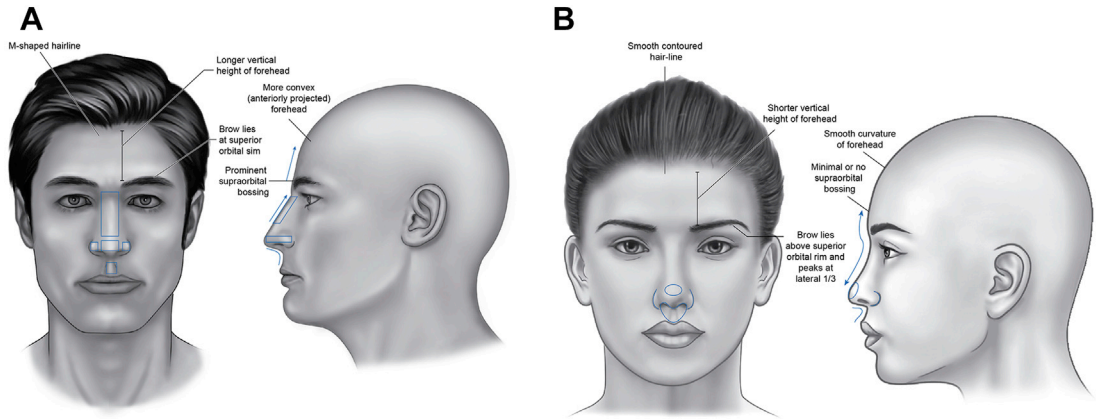

Fig. 2. The key differences between the upper third of the face in men (*A*) and women (*B*).

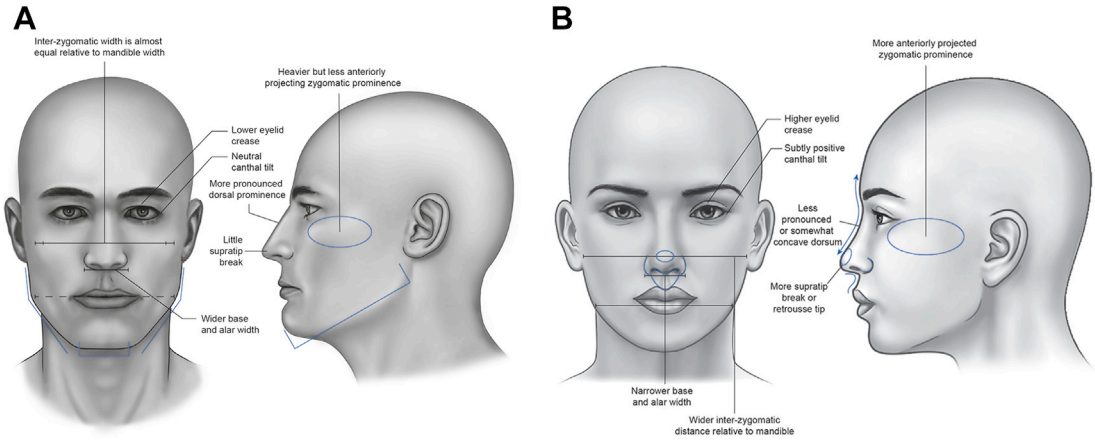

Fig. 3. The middle third of the face is different between men (*A*) and women (*B*) in the orbital, periorbital tissue quality, nasofrontal angle, nasal dorsum, tip, and base width, as well as the zygomatic prominences.

trans women, makeup or fillers may be used to accentuate lip fullness, and these should be noted as well when considering procedures to increase vermilion show.

The mandible in men is larger and thicker, with greater mandibular body height, especially at the symphysis. The male mandible is often heavier and taller, with a greater vertical height to the chin than in women.[9] In addition, men have more mandibular flare caused by mandibular attachments, resulting in a wider jaw.[12] The overall appearance in men is thus of a square or heavy-set jaw with a taller chin.

The mandibular angle should be assessed for its definition and sharpness. Women generally have a softer mandibular angle. The mandibular angle is generally less than 125° in both sexes; however, women tend to have a more obtuse angle than men by approximately 2.7°,[9,12] which creates a softer transition from the mandibular body to ramus, and a narrower mandibular width.

The chin and lower jaw is usually longer in men by as much as 20% and is often, but not always, more prominent in profile.[14] It is more trapezoidal, rather than rectangular in women than inn men.[12] In men, the shape is squarer because of bilateral lateral mental eminences in the region of the canines, whereas women generally have a single median mental eminence, giving their chins a more rounded or pointed appearance.[6,8,13] Although the female chin is slightly posterior to the lower lip vermilion, it is considered masculine if the chin is in line with the lower lip vermilion, or even slightly anterior to this.

When considering nasal-lip-chin relationships, it is important to also examine the patient's occlusion. This examination should include dentition, occlusal plane, and prior use of orthodontia. The use of orthodontia may mask a nonharmonious nasal-lip-chin relationship. A patient with class II malocclusion may have a retrodisplaced or micrognathic chin. This condition may be beneficial in the trans male-to-female population; however, in the trans female to male population, there may be a benefit to using a chin implant, corrective jaw surgery, and/or genioplasty to augment the chin and restore proper occlusion. Contrastingly, for those with class III occlusion, both trans-female and trans-male patients may benefit from corrective jaw surgery in order to restore normal occlusion; however, the mandibular setback or genioplasty for trans women should be greater than that for trans men (**Fig. 4**).

INTEGUMENT/SOFT TISSUE CONSIDERATIONS

It is worthwhile to mention the integumentary and soft tissue considerations between the male and female face. Clinicians should consider how patients wears their hair, the hairline (as discussed), presence of sideburns, brow thickness and position, eyelash length and volume, presence and distribution of facial hair, distribution of facial fat volume and fat compartments, as well as the overall quality and texture of the patient's skin.

Before undergoing surgery, trans-female patients may change their hairstyle to mask a high hairline by growing bangs or wearing a wig. The brow may be colored or tattooed in order to artificially create a higher and more arched brow as well. The eyelashes should be examined for length and volume, and the patient asked whether any products have been used to enhance the eyelash

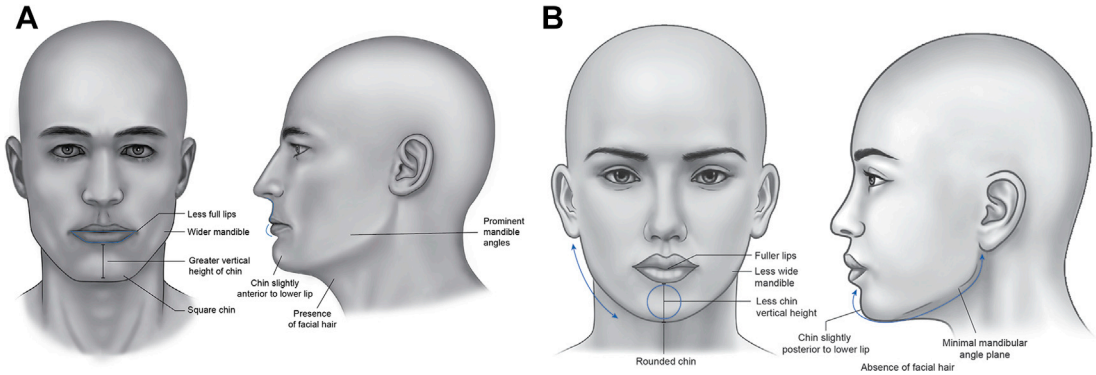

Fig. 4. The male lower third of the face (*A*) differs from the female (*B*) in that there is less vermilion show, wider mandibular width with greater mandibular angle flare, and a squarer chin with a taller vertical height.

length. The presence of facial hair is a decidedly masculine trait in Western cultures, and thus its presence warrants a discussion about hair removal strategies in trans male-to-female patients.

The male integument is 30 to 175 μm thicker than that of women, depending on the location being measured, and there is less subcutaneous fat, largely because of the presence of follicular units and adnexal structures under the influence of male hormones in the reticular dermis. The influence of estrogen contributes to the greater underlying subcutaneous fat, which leads to more fluid female contour, and less obvious muscular contraction during mimetic movements.[5,9] In addition, there exists some debate in the literature regarding the degree to which the sexes age and soft tissue descent occurs. Descent of the soft tissue may lead to a masculinized appearance of the female form. This is primarily due to descent of the brow and midface, a depressed canthal tilt, and squaring of the jaw. In these instances, a discussion of soft tissue rejuvenation procedures may be warranted, because the results of skeletal correction may not be as visibly appreciated.

SUMMARY

There exist several known anthropometric differences between the male and female facial skeleton and soft tissues. In general, the female face is less robust, rounder or heart shaped, with a shorter forehead, no supraorbital bossing, a smaller nose, more pronounced zygomatic prominences, fuller lips, a smaller mandibular width, and a more tapered chin. A method for analyzing these differences is critical for offering facial gender confirming surgery to gender dysphoric patients, for preoperative planning as well as for setting postoperative expectations.

REFERENCES

1. Coleman E, Bockting W, Cohen-Kettenis P, et al. Standards of care of the health of transsexual, transgender, and gender-nonconforming people. Int J Transgend 2011;13:165–232.
2. Plemons E. Formations of femininity: science and aesthetics in facial feminization surgery. Med Anthropol 2017;36(7):629–41.
3. Ainsworth TA, Spiegel JH. Quality of life of individuals with and without facial feminization surgery or gender reassignment surgery. Qual Life Res 2010; 19(7):1019–24.
4. Spiegel JH. Challenges in care of the transgender patient seeking facial feminization surgery. Facial Plast Surg Clin North Am 2008; 16(2):233–8. viii.
5. Raffaini M, Magri AS, Agostini T. Full facial feminization surgery: patient satisfaction assessment based on 180 procedures involving 33 consecutive patients. Plast Reconstr Surg 2016;137(2): 438–48.
6. Ousterhout DK. Feminization of the forehead: contour changing to improve female aesthetics. Plast Reconstr Surg 1987;79(5):701–11.
7. Farkas LG. Anthropometry of the head and face. New York: Raven Press; 1994.
8. Ousterhout DK. Aesthetic contouring of the craniofacial skeleton. Boston: Little, Brown; 1991.
9. Hage JJ, Becking AG, de Graaf F, et al. Gender confirming facial surgery: considerations on the masculinity and femininity of faces. Plast Reconstr Surg 1997;99(7):1799–807.
10. Sedgh J. The aesthetics of the upper face and brow: male and female differences. Facial Plast Surg 2018; 34(2):114–8.
11. Cho SW, Jin HR. Feminization of the forehead in a transgender: frontal sinus reshaping combined with brow lift and hairline lowering. Aesthetic Plast Surg 2012;36(5):1207–10.

12. Becking AG, Tuinzing DB, Hage JJ, et al. Transgender feminization of the facial skeleton. Clin Plast Surg 2007;34(3):557–64.
13. Dempf R, Eckert AW. Contouring the forehead and rhinoplasty in the feminization of the face in male-to-female transsexuals. J Craniomaxillofac Surg 2010;38(6):416–22.
14. Altman K. Facial feminization surgery: current state of the art. Int J Oral Maxillofac Surg 2012;41(8):885–94.
15. Capitan L, Simon D, Kaye K, et al. Facial feminization surgery: the forehead. Surgical techniques and analysis of results. Plast Reconstr Surg 2014; 134(4):609–19.
16. Lundgren TK, Farnebo F. Midface osteotomies for feminization of the facial skeleton. Plast Reconstr Surg Glob Open 2017;5(1):e1210.
17. Spiegel JH. Facial determinants of female gender and feminizing forehead cranioplasty. Laryngoscope 2011;121(2):250–61.
18. Nouraei SA, Randhawa P, Andrews P, et al. The role of nasal feminization rhinoplasty in male-to-female gender reassignment. Arch Facial Plast Surg 2007; 9(5):318–20.