Hair Transplantation Techniques for the Transgender Patient

Anthony Bared, MD*, Jeffrey S. Epstein, MD

KEYWORDS

• Hair transplantation • Transgender • Hair restoration • Hairline patterns

KEY POINTS

- Hairline patterns and facial hair distribution can be gender-identifying traits.
- Women tend to have a lower and more rounded hairline than men as well as more arched brows, whereas men have a prevalence of facial hair.
- Hair transplantation can play a complementary role for the transgender patient undergoing gender transformation.

INTRODUCTION

Hair restoration can play an important role for transgender patients seeking gender transformation procedures.[1–4] The authors' clinic has seen an increase in transgender patients seeking hair restoration. The most common hair restoration procedures performed in the clinic for transgender patients are hairline lowering procedures; facial hair restoration procedures, including eyebrow and beard transplantation; and, less frequently, body hair transplantation. Hair restoration can be an important component for male-to-female (MTF) transgender patients as part of the gender transformation because the rounding of a hairline, for instance, can help provide for a more feminine appearance as does creating an arched shape to the eyebrows. For female-to-male (FTM) patients, beard and chest hair transplantation helps create a more masculine facial and body appearance. This article presents the authors' experience in hair restoration for transgender patients. The best candidates for hair restoration as it relates to transgender patients, the techniques that provide for the most natural results, and the postoperative course from hair transplantation are reviewed.

PREOPERATIVE PLANNING

Consultation

The consultation for hair restoration serves to attain a medical and hair loss history, to ascertain a patient's goals for the procedure, to provide for a proper examination of the scalp donor hair and recipient area, and to establish mutual goals for the procedure. A hair loss–specific questionnaire is completed by the patient prior to the consultation and this is reviewed with the patient at the time of consultation. Hair loss history needs to be obtained if there is androgenic hair loss evident in the patient as well as a family history of hair loss. In the MTF patient taking hormonal therapy or having undergone gender reassignment, there is no further risk of potential future male pattern hair loss. Examination of the scalp, paying close attention to the quality of the donor hair, needs to be performed. The donor hair needs to be examined for its quality and density so as to estimate the number of grafts that may be obtained in a procedure as well as over the course of the patient's lifetime. When reviewing the patient's goals for the procedure, whether hairline lowering or facial hair restoration, it is often helpful that the patient brings model photos of their ideal outcome to

Disclosure Statement: The authors have nothing to disclose.
Private Practice, Foundation for Hair Restoration, 6280 Sunset Drive, Suite 504, Miami, FL, USA
* Corresponding author.
E-mail address: abared@dranthonybared.com

Facial Plast Surg Clin N Am 27 (2019) 227–232
https://doi.org/10.1016/j.fsc.2018.12.005
1064-7406/19/© 2019 Elsevier Inc. All rights reserved.

review at the time of the consultation. The authors do not perform computerized imaging for hair restoration, finding that this gives unrealistic expectations from surgery, but instead marks out photos of patients, drawing in for them the potential position of their hairline or beard shape. As in any area of aesthetic surgery, proper expectations need to be established and understood, whether the degree of hairline lowering possible through a single procedure or the amount of density attainable in either hairline lowering or facial hair restoration. Risks of the procedure are reviewed with the patient. Lastly, patients need to be in generally good medical health to undergo a procedure.

Hairline Design

Although hairline designs vary tremendously, the important goal is that of achieving a natural-appearing female hairline. When designing a hairline for the transgender patient, multiple factors need to be considered. The position of the existing hairline, the presence of androgenic alopecia, family history of hair loss, use of hormonal therapy such as finasteride or estrogens, and the density and quality of the donor hair are all factors to keep in mind. In general, feminizing a hairline entails the lowering of the hairline and the blunting of the temporal region. A soft, heart-shaped hairline design with rounded recession in the frontal-temporal region (**Fig. 1**) is often used to feminize the hairline and achieve a natural appearance to the hairline. To aid in the creation of a natural hairline appearance, often a subtle widow's peak is created slightly off-center. Rounding of the hairline is then performed posteriorly and laterally along the frontal-temporal region, connecting to the temporal points. This design helps soften the hairline, blunt the temporal area, and feminize the hairline. On the day of the procedure, the patient is met in the preoperative suite where her hairline is marked out using a washable surgical marking pen. The hairline is inspected for symmetry. The patient is then shown the hairline design in front of a mirror. Once the hairline design is agreed on, the markings are reinforced with a more permanent-inked marker so as not to wash off during the procedure. Preoperative photos are taken before and after the markings.

Fig. 1. Female hairline design generally follows a heart-shaped design with slight rounding in the frontal-temporal region.

Beard Design

Goals in beard design are often established by the patient. Many patients typically present with a specific understanding of how they want their facial hair to appear. The design and density of the beard may be limited by the quality of the donor hair. Transplantation of full beards requires large amount of grafts, and patients are always made aware of the possibility of undergoing secondary procedures after approximately 1 year if further density is desired. It is the authors' experience that the scalp hair transplants to the face have a high regrowth percentage and, if properly performed, patients can achieve a natural outcome. Depending on the exact design and density, graft counts can range from 250 to 300 grafts to each sideburn, 400 to 800 grafts to the mustache and goatee, and 300 to 500 grafts per cheek. Using the patient's guidelines, the areas to be transplanted are marked out using a surgical marking pen with the patient in a seated position. The markings are checked for symmetry between the 2 sides. Measurements are used to help ensure symmetry. The patient is shown the markings in a mirror, because the 2-D perspective provided by a mirror, which is what the patient sees, is different than what the surgeon sees in direct 3-D. If needed, alterations are made according to patient desires (**Fig. 2**).

Fig. 2. An example of a beard design as drawn preoperatively.

Eyebrow Design

When approaching eyebrow restoration for the transgender patient, it is important to appreciate the shape of the more masculine eyebrow versus that of a more feminine eyebrow appearance. The masculine eyebrow shape is generally less arched but comes to a lateral widening at the peak of the brow, whereas the feminine eyebrow shape is more rounded and arched (**Fig. 3**). The goal in eyebrow restoration for the transgender patient wishing to create a more feminine appearance is to create a more arched-shaped appearance to the eyebrows, whereas in all patients the goals are to provide the desired shape, density, natural direction, and angle of growth of eyebrow hair. Patients are encouraged to bring in photos of their ideal or model eyebrows. On the day of the procedure, the patient is first seen in the preoperative suite where photos are taken. Preoperative photography is important in eyebrow transplantation because it truly helps provide another means of visualizing the planned eyebrow shape prior to the procedure. Photos are taken of the patient both with eyes open and eyes closed. It is often found that eyebrow elevation is asymmetric, because there tends to be an asymmetric elevation of the eyebrows by the facial musculature and sometimes that associated with asymmetry of the eyelids. These asymmetries are noted and made known to the patient. Most female patients are accustomed to drawing in the eyebrows with an eyeliner pen so they are encouraged to do so at this time in front of a mirror. Once preliminary drawings are made by the patient, the surgeon fine-tunes the shape. Measurements are taken along the length and in various places along the width of the eyebrows to ensure as much symmetry as possible. The midline is marked and measurements off the midline also are taken. The final shape is then shown to the patient, and photos of this shape are taken in a fashion similar to the premarking photos.

SURGICAL PROCEDURE

Donor Hair Harvest

In a majority of all hair transplants the authors perform, the donor hairs are harvested by the follicular unit extraction (FUE) technique, which avoids altogether a linear donor site incision and thus patients typically are able to cut the hair as short as desired. The authors still occasionally use, however, particularly in women, including MTF transgender hair transplants, the strip method for harvesting the donor hairs. The strip method avoids the need for significant shaving of the back and sometimes sides of the head that is typically needed for large FUE procedures. The authors also use, however, a no-shave FUE technique, where the donor hair is extracted via the FUE method while the surrounding hairs in the donor area are maintained long and not needed to be entirely trimmed. This is a more tedious procedure but allows for FUE extraction, avoiding a linear scar, and for patients to maintain their hair long.

Hairline

The position and shape of the hairline are, at first, drawn for the patient using a removable ink marking pen. The patient is shown the hairline design in front of a mirror. Once the position and shape of the hairline are determined, photos are taken of the design and the markings are reinforced with a permanent ink marker so as not to be lost during the procedure. Most patients are then given oral anxiolytic medication.

The goal of hairline lowering is to create the most natural-appearing results by replicating the direction and angle of the existing hairline. The smallest possible incisions are made, allowing for the placement of the hair grafts. The 1-hair, 2-hair, and 3-hair grafts are tested to ensure size compatibility with the recipient sites. Acute angulation of the grafts is important, particularly in the first few rows of the hairline. Depending on the characteristics of the hair—thickness and curl—typically the first 2 to 3 rows are composed of single-hair grafts placed in an irregular pattern, followed by the placement of 2-hair to 3-hair grafts. The central portion of the hairline is the area that tends to be most dense, so it is important that the central aspect is adequately filled to allow for creation of the most density in this region. As

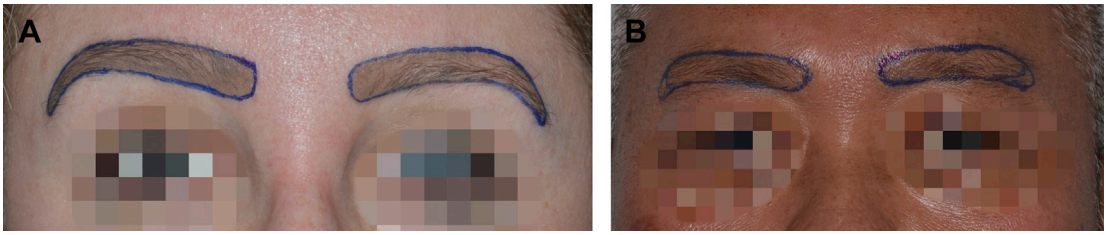

Fig. 3. (*A*) Female eyebrow design. (*B*) Male eyebrow design with a lateral widening and a nonarched design.

discussed previously, the direction of hair growth follows the existing hairline but, most commonly, hairs are placed with an acute forward direction on the central region and then tapered down/inferiorly along the temples (**Fig. 4**). The grafts are then placed in the incisions with implanter devices that minimize trauma to the grafts and can expedite the planting process.

Patients are instructed to expect swelling along the forehead and eyes for 1 day to 2 days after the procedure. They are seen in the office on postoperative day 1 for a hair wash and are instructed how to wash the hair and care for the grafts. Light washings are performed without allowing the shower water to directly hit the grafts for the first 6 days after surgery, followed by normal showers after that point. The crusts are to be gently removed after 6 days.

Beard

Currently in the authors' practice, nearly all patients seeking facial hair restoration elect to have the grafts obtained via the FUE technique. In these cases, the donor area is shaved (unless a no-shave approach is used) and patients are placed in a supine position. The smallest possible drill size, avoiding graft transection, is used for the extractions. The donor area consists of the occiput only in smaller cases and extends into the parietal scalp for larger cases. Once the extractions have been completed from the occipital area, the patient is turned to lie in the supine position.

Local anesthesia is then applied to the face, starting in each sideburn and cheek area. The perioral region is not anesthetized at this point; rather, the area around the mouth is typically worked on after the patient has eaten lunch. The recipient sites in the sideburn and cheek area are made first. The smallest possible recipient sites are made using 0.5-mm, 0.6-mm, and sometimes 0.7-mm slits. In the periphery of the sideburns, 1-hair grafts are used whereas 2-hair grafts can be placed in the central aspect of the sideburn to allow for more density. It is imperative to make the incisions at an ultra-acute angle to the skin. The direction of growth is generally downward but more centrally, closer to the mouth/goatee region, can be somewhat anterior. In the cheek area, mostly 1-hair and 2-hair grafts are used; however, in the occasional patient with fine donor hair, some 3-hair grafts can be used to allow for the achievement of greater density. As soon as recipient site formation is done, the grafts can be placed 1 at a time, according to the vision of the surgeon.

After the patient is given lunch, the area around the mouth is anesthetized. Infraorbital and mental nerve blocks are used to provide initial anesthesia. The goatee and mustache areas' anesthesia are then reinforced with field subdermal local anesthesia complemented by epinephrine 1:50,000 to minimize bleeding. Incisions in the goatee and mustache areas are then made. On the mustache, hairs grow slightly laterally and transition downward along the goatee. Again, it is important to make these at an angle as acute as possible to the skin. The grafts in the mustache region have the tendency to grow perpendicular; thus, patients need to be made aware of the difficulty in creating density along the entire mustache, particularly centrally within the cupid's bow. The creation of density in this area is difficult owing to the topography created by the upper lip's cupid's bow area. The transition from the mustache to the goatee is an important area for the creation of density, which is usually created by the maximal dense packing of 2-hair grafts.

Graft placement continues, and, toward the conclusion of the case, the patient is given a mirror before all grafts are placed. Given that the immediate results closely replicate the final results, it is helpful for the patient to view the beard to assess the design and density of the grafts. This allows for feedback, fine-tuning, and alteration before the conclusion of the case (**Fig. 5**).

Fig. 4. Intraoperative photo of the direction and angulation of the female hairline graft placement.

Fig. 5. Immediate, postoperative photo of the patient in **Fig. 2**, showing beard hair graft placement.

Patients are to keep the face dry for the first 5 days after the procedure. This allows the grafts to set properly, helping assure the maintenance of proper angulation. Topical antibiotic ointment is applied to the donor area whether a strip or FUE technique was used. Patients then wet the face after 5 days with soap and water, starting to remove the dried blood and crusts. Shaving is permitted after 10 days.

Eyebrow

The donor area is anesthetized with local anesthesia composed of lidocaine 2%/epinephrine 1:100,000. These grafts can be obtained by the strip or FUE technique. Given the small number of grafts needed for eyebrow transplantation, the no-shave FUE technique can easily be used for those patients electing to not have the strip method while allowing the surrounding hair to be maintained long.

Once the donor hairs have been harvested, the patient is placed in a seated, reclined position for incision site formation. The eyebrow area is anesthetized with local anesthesia containing epinephrine for hemostasis. The recipient sites are made using the smallest blade size for the graft—typically 0.5 mm or 0.6 mm. Initial recipient sites are made along the periphery along the premarked borders of the eyebrows. It is important to start with these peripheral marking incisions because the preoperative markings can soon be lost with subsequent bleeding and wiping. Incisions are made at an angle as acute as possible to the skin (**Fig. 6**). Within the medial-most aspect of the eyebrow inferiorly, the hairs usually grow in a superior and slightly lateral direction. While moving more superior within the head of the eyebrow, the direction changes to a more lateral and then inferior direction. Moving more laterally into the body (midportion), the hairs grow in an inferior-lateral direction along the superior border and in a superior-lateral direction along the inferior border. Within this body, which constitutes the majority of the eyebrow, this crossed-hatch pattern achieves the greatest amount of density. Then, the lateral-most approximately one-quarter of the eyebrow, called the tail, has typically horizontally oriented recipient sites.

Once all incision sites are made, the grafts are inserted. A typical procedure can range from 150 grafts to as many as 400 grafts per eyebrow. The grafts are placed so that the direction of the hair growth, that is, the curl of the hair, is placed to complement the goal of having the hairs grow in an angle as acute as possible with the skin. In most cases, as many 2-hair grafts as possible are placed within the eyebrows, primarily the central portion but also in parts of the head. Two-hair grafts are not used if the hairs within a graft are divergent in their growth. The utilization of as many 2-hair grafts as possible creates the most amount of density within the eyebrows. Mostly 1-hairs grafts are used along the borders, periphery, and tail region. After all the grafts are placed, the patient is asked to sit up and the eyebrows are inspected. Additional grafts are placed if small adjustments are deemed appropriate. The patient is then shown the eyebrows in a mirror for feedback (**Fig. 7**).

Patients are instructed to maintain the eyebrow area dry for 5 days. The scalp hair may be washed the first postoperative day. Antibiotic ointment is applied to the donor area twice daily for 1 week. Patients are allowed to use makeup in the eyebrow area after all the crusts have fallen out, at typically 5 days to 7 days.

Fig. 6. Incisions are made in an acute angle to the skin with 0.5-mm to 0.6-mm blades.

Fig. 7. Immediate, postoperative results of eyebrow transplantation.

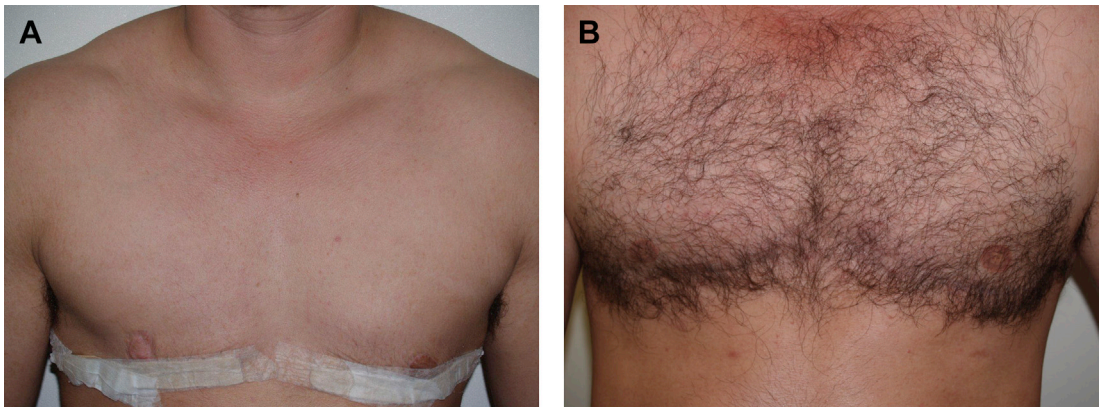

Fig. 8. Before and after 2000 grafts to chest—FTM patient—to create a more masculine appearance and conceal mastectomy scars.

Chest and Other Pubic Region

There are a variety of indications for performing these body hair procedures. Chest hair procedures can serve both to create a more masculine appearance and to help conceal mastectomy scars in MTF patients. Pubic hair transplants are indicated primarily in patients who have undergone gender reassignment, where the normal escutcheon can similarly help conceal any scarring (**Fig. 8**).

For the chest, procedures of 1800 grafts to as many as 3000 grafts are indicated, due to the large area that needs to be covered. These potential areas, depending on patient goals, can include the upper and central chest, ranging laterally and inferiorly (particularly to conceal mastectomy scars) and even continuing caudally in a vertical direction into the abdomen and even upper pubic region. The keys to achieving a natural result, besides careful acute angulation of the recipient sites, is to have a crossed-hatch pattern of hair growth toward the midline, that is, the sternum.

A crossed-hatch pattern centrally—to achieve the greatest appearance of density—is also indicated when performing pubic hair transplants. Typical procedures range from 400 grafts to 900 grafts, depending on a patient's goals in terms of density and area covered.

SUMMARY

Hairline patterns and facial hair distribution can be gender-identifying traits. Women tend to have a lower and more rounded hairline than men as well as having more arched brows, whereas men have a prevalence of facial hair. Hair transplantation can play a complementary role for transgender patients undergoing gender transformation. In the authors' clinic, the most common hair transplantations seen in transgender patients are hairline lowering, beard transplantation, and eyebrow transplantation. Although challenging from artistic and technical perspectives, these procedures have a high satisfaction rate for patients.

REFERENCES

1. Rogers N. Imposters of androgenic alopecia. Facial Plast Surg Clin North Am 2013;21:325–34.
2. Rassman WR, Pak JP, Kim J, et al. Phenotype of normal hairline maturation. Facial Plast Surg Clin North Am 2013;21:317–24.
3. Nausbaum BP, Fuentefria S. Naturally occurring female hairline patterns. Dermatol Surg 2009;35:907–13.
4. Rassman WR, Berstein RM, McClellan R, et al. Follicular unit extraction: minimally invasive surgery for hair transplantation. Dermatol Surg 2002;28:720–8.