Midfacial Bony Remodeling

Kalle Conneryd Lundgren, MD, PhD*, Maarten J. Koudstaal, MD, DMD, PhD

KEYWORDS

• Craniofacial surgery • Midface surgery • Gender reassignment surgery • Facial feminization surgery

KEY POINTS

- Craniofacial procedures to the midface in conjunction with work to the upper face and skull, and if needed the lower jaw, are a permanent and effective way to achieve feminization of the face in transgender patients.
- This surgery is more complex than other procedures, such as placement of implants and fillers, but should be considered for select patients to achieve a predictable and permanent feminization of the face.
- Cosmetic surgery to the face may be considered a separate surgical entity and is not limited in scope or time by having undergone midface osteotomies.

INTRODUCTION

The face is not as easily dressed or hidden as are other areas of one's physique. In particular, the midface is highly exposed, surrounding the eyes, nose, and mouth, and can hardly be covered by clothing or by a wig, as can be done with the upper part of the skull or a scarf, as can be used for covering up the neck and lower face. Because the face, in most cultures, is essential for interpersonal interactions, an incongruity between one's assigned gender at birth and the appearance of one's face may be severely distressing, and many patients have a strong desire to alleviate this dysphoria by means of physical transition.[1] It is an established fact that patients with gender dysphoria are at increased risk of suffering from minority stress and that this is predictive of psychiatric disorders, such as depression and/or suicidal behavior.[2] Data are growing on the specific importance of the facial structures as they relate to perceived congruence between the experienced gender identity and the bodily appearance.[3–5]

The timing of when a person starts the active gender transition is important for what surgical means may be necessary for altering the facial appearance. In individuals who start transition early in life, counter hormones against testosterone are commonly used and such treatment has a significant impact on the development and further growth of the midfacial structures, as the size and depth of the orbits are nearly final by 6 to 8 years of age and the skull circumference even earlier than that. Other areas with bony bossings, the lower jaw, the nasal bones and cartilage, as well as the overall facial projection and shape, do not complete until after puberty and are highly affected by the presence or absence of testosterone. Consequently, the start of hormonal treatment after the onset of puberty will not prevent the development of facial bony structures with a typical masculine appearance.[6] This is perceived as unwanted in many patients undergoing a

Disclosure Statement: The authors have nothing to disclose.
Declaration of Interests: No conflict of interests for any author.
Department of Craniofacial Diseases, Karolinska University Hospital, Stockholm 171 77, Sweden
* Corresponding author.
E-mail address: kalle.conneryd-lundgren@sll.se

Facial Plast Surg Clin N Am 27 (2019) 221–226
https://doi.org/10.1016/j.fsc.2018.12.004
1064-7406/19/© 2019 Elsevier Inc. All rights reserved.

male-to-female gender transition. Patients transitioning from a female to a male gender are less frequently disturbed by the osteology of the face. Although there are scarce data available on the reasons for the female-to-male group of patients being less distressed by a non–gender-conforming (feminine) osteology of the midface, it may be speculated that there are cultural as well as practical reasons in play. In many modern societies, a certain androgyny among male individuals can be regarded as attractive, compared with the male ideals in commercial campaigns and so forth. Also, the possibility of growing a beard or mustache among female-to-male patients undergoing testosterone supplementation may alleviate any need for other masculinizing maneuvers even in an otherwise rather feminine face.

MIDFACIAL BONY REMODELING FOR FEMINIZING PURPOSES

Facial feminization surgery (FFS) is a collective term to describe the surgical alteration of a masculine facial appearance to a more feminine appearance, most commonly performed for male-to-female transsexual individuals. FFS as a collection of techniques is used to decrease the degree of physical incongruence.[7,8] Several separate surgical techniques have been described and are used under the umbrella of FFS. Among these are placement of implants, fat grafting (lipofilling), injection of artificial substances, such as hyaluronic acid mixtures, as well as surgical work to the bony structures using techniques derived from the field of craniofacial surgery. The broader topic of FFS was recently reviewed by Morrison and colleagues.[9] In this section, we limit discussion to surgery on the midfacial bony structures. Several of the nonbony techniques are rather well established in their use toward performing facial feminizations.[7,8,10] With regard to the midface, skeletal work is less common and fewer data are available in the scientific literature. Mostly implants, fillers, or fat grafting have more often been used for the purpose of augmenting and reshaping the midface. Such approaches are technically less challenging compared with skeletal repositioning, but they may come with the limitations of having to be repeated, as well as a difficult to predict long-term result. The need for repeat surgery when implants or grafting techniques are used are a result of the face's well-known propensity to thin out locally and to "sink" as an effect of gravity when the patient ages. This may result in that the position of an augmented soft tissue area after several years will no longer be appropriate for the patient's age and that the relative position of the soft tissues and the underlying bone may no longer match. It should also be kept in mind that this is a patient group in whom the purpose of the surgery is not primarily to improve appearance in terms of beauty, but rather to feminize the face. This means that although the same patient may be interested in acquiring a more youthful or beautiful look as they age, this should be regarded by the surgeon as a somewhat separate entity to the feminization aspects of the face. Such reasoning is the basis for providing a long-term plan and result for the patient and to avoid creating what patients have been calling "a trans-appearance." To this end, an improved midfacial osteology will allow the patient to age gracefully, similar to other female individuals. Whether the patient chooses to add cosmetic procedures for aesthetic reasons at one point or another throughout life is then a personal choice.

The overall purpose of FFS surgery as it relates to bony structures is largely to relatively reduce the supraorbital region and orbital rims compared with the overall projection of the patient's midface; this relation has previously been helped by malar implants or lipo filling to the same region.[7,10,11] When surgery to the bone is considered, this relation is first determined based on 3-dimensional (3D) computed tomography (CT) scans and 3D photography, and patients with limited projection at the zygomatic and malar region may be offered bony surgery to augment the projection and angulation of the zygomatic body and inferior orbital rim. In patients who are planned for surgery of the midface, we also perform surgery to reduce the supraorbital ridge and the superior and lateral orbital rims, as described by Capitan and colleagues.[10] This is necessary to create a natural appearance and to avoid distinct transitions between subunits of the face. Many patients also have a typical male configuration with a prominent mentum and/or mandibular lower border and these areas will then be treated for the same reasons. The techniques for treating the lower jaw and mentum area by bony reduction and reshaping has been well described by other investigators.[11] There are similarities in the objectives between the surgical treatment of feminization patients and patients with midfacial retrusion or underdevelopment, such as is often present in patients with craniofacial syndromes. However, the latter group most often has a general underdevelopment or "dish face" appearance, whereas patients undergoing feminization do not. Male-to-female patients rather have particular areas

that need increased projection, whereas other nearby areas would benefit from reduced projection. Again, obtaining a good result is all about the relations between bony midfacial structures rather than their absolute positions or measurements. As a result of this, a traditional Le Fort 3 advancement would not be beneficial to FFS patients, as this procedure incorporates the nose, which is not an area that is typically in need of increased projection in FFS patients; in fact, the opposite is most often true. Nor is there normally a need for altering the occlusion in FFS patients, which is in contrast to patients with a congenital underdevelopment of the midface. To selectively augment the zygomas and infraorbital rims, a segmentalized osteotomy approach is indicated. Such an approach was pioneered by Hopper and colleagues[12] for children with Apert syndrome, but for that specific patient group it is used to other ends and different purposes.

Surgery for the FFS patient is performed using a coronal incision that is also the access route for the upper supraorbital rim and the frontal sinus area. These 2 areas are treated first, the anterior frontal sinus wall is released, the bone is thinned by bringing it down and reshaped before placing it back in a more posterior position using titanium fixation. The remaining area of the forehead is then burred down to smooth out the overall contour and to create a more posterior slope from caudal to cranial. The supraorbital rim is burred down to decrease the depth of the upper orbit creating a less deep-set eye position, and this reduction of bone is extended to the upper part of the lateral orbital rim. This has been described by Capitan and colleagues.[10] After having reshaped the upper frontal area of the skull, we would then proceed to the midface part of the procedure. The coronal incision is extended caudally toward each ear as necessary for exposure. An intraoral upper sulcus incision is performed for access to the maxilla and a transconjunctival incision is performed bilaterally and used for access to the inferior orbital margin. Using these incisions, the whole midface is exposed in a subperiosteal plane. The first osteotomies are performed at the zygomatic arch (**Fig. 1**). The position of the osteotomies at the arch should be placed far enough posterior in an area in which the arch is nearly straight and running in a sagittal direction, avoiding steps in the most projected areas. The second osteotomies are done inferior to the frontozygomatic suture at a position just below the area in which the previous burring down was stopped (see **Fig. 1**). To allow for advancement of the infraorbital rim, the previous 2 osteotomies must then be connected using an osteotomy at the medial end of the segment of the zygoma. This osteotomy is commonly placed medial to the infraorbital foramen, as a lateral position may create a step in the inferior orbital rim once repositioned. However, this is somewhat dependent on the patient's specific anatomy and it also may be placed lateral to the nerve, reducing the risk of damaging the nerve itself. The medial osteotomy is performed in a straight vertical angle from the transconjunctival access caudally through the anterior maxillary sinus wall. The connection between the lateral osteotomies at the lateral orbital rim and the medial osteotomy at the inferior orbital rim is performed using a piezoelectric saw, but also can be done using an osteotome or reciprocal saw. To connect the cuts intraorbital, we start on the lateral inner side of the orbit, keeping a few millimeters posterior to the infraorbital margin,

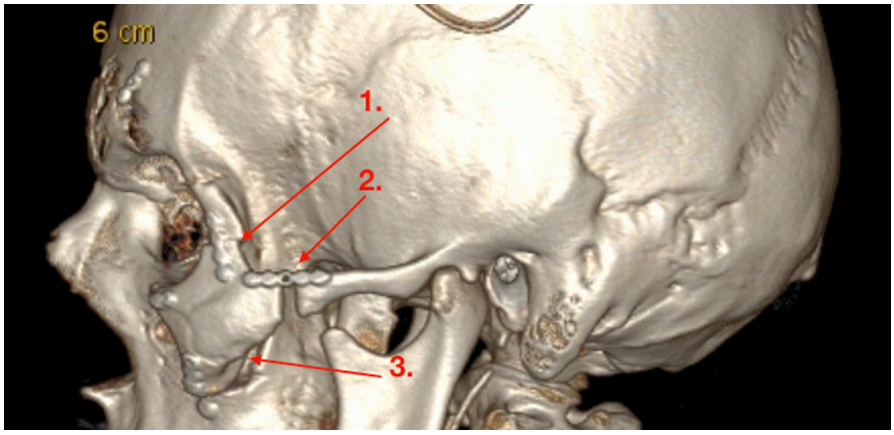

Fig. 1. Computerized tomography, Sagittal view. Osteotomies at the lateral orbital margin (1), zygomatic arch (2), and the posterior wall of the zygoma/maxillary sinus (3).

continue through the orbital floor past the maxillozygomatic suture until the medial osteotomy is reached. From intraoral, the anterior wall of the maxilla is then cut further vertically extending the previous medial osteotomy to a point superior to the alveolar ridge and the roots of the teeth. To allow for mobilization, using a saw, an angled cut from medial to lateral passing through the lateral pillar of the maxilla and then through the posterior wall of the maxillary sinus and the posterior part of the zygomatic body is performed to disconnect the whole segment on each side of the face (see **Fig. 1**). To reposition the zygomatic segments, we use titanium plates prebent for the desired position bridging first the osteotomies at the infraorbital rim. Based on the preoperative CT scans, the distance for advancement has been decided, but our experience is that this usually is between 4 and 7 mm. Furthermore, as the maximum projection of the craniofacial skeleton is not in a straight sagittal direction, the bending of the plates also should guide the position of the zygomatic regions to allow for a slight rotation laterally. We usually rotate the segments approximately 3 mm laterally (**Fig. 2**).[13] Once the position is deemed satisfactory, the bones are finally fixed at the zygomatic arch, lateral orbital rim, and medially on the maxilla using titanium micro plates (see **Fig. 1**). We provide all patients with a cooling mask for the first postoperative night and perform a postoperative CT scan. Antibiotics are given as a single dose at the start of surgery. Patients are swollen after surgery, but can usually open their eyes to see well enough by the first day and most patients can be uneventfully discharged after 1 to 3 days. We do not perform any simultaneous soft tissue surgery, as this is usually not needed and surgery to the nose is done only on esthetic indication. Results are gathered for research using 3D stereophotography surface scanning (**Fig. 3**).

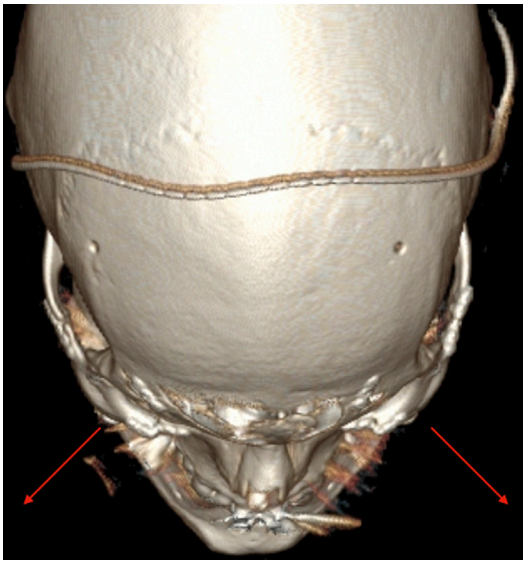

Fig. 2. Computerized tomography, horizontal view. Arrows denote the direction of maximal midface projection.

DISCUSSION

Relative projection of distinct areas of the craniofacial skeleton is largely determining the appearance of the facial framework as it relates to a feminine or masculine appearance. It is important to acquire an understanding of the importance of the relative *relations* rather than absolute measurements within the craniofacial skeleton to fully appreciate which regions are in need of treatment, and how, as the objective in FFS surgery is not that of changing an appearance but of feminizing it. Data on relations in the craniofacial skeleton is not readily available in the literature and especially not with regard to male versus female skeletal configurations. This is a shortcoming and means that we currently need to use experience and trial and error using preoperative surgical planning software to determine the best surgical plan. Where the feminization of the upper face is somewhat more straightforward because the objective here is to reduce the supraorbital and frontal sinus protrusion to somewhat of a straight/smooth contour and we do have the rest of the skull as a reference, the midface is more challenging. In the midface, we disconnect large parts of bone and in doing so, we lose reference to the remainder of the bony structures. This means that a clear surgical plan is needed beforehand and prebent plates are often a necessity to not overproject or underproject and to also avoid creating an asymmetry between the facial halves. It should be taken into account that the patient may not be entirely symmetric by nature and a decision then has to be made, together with the patient, on whether symmetry postoperatively is wished for or not. If not, a nonequidistant advancement is needed between the facial sides. The upper and lateral portions of the orbital rims also should be less pronounced than in the typical male individual,[7,10,11] and these are the regions immediately connecting to the midface. In cases in which the patients already have a good projection of the midface, the reduction of the upper facial areas may be able to fully achieve a feminized appearance, as the relative position compared with the zygomatic projections will be posterior enough. The limitation in the amount of bone being possible to remove at the frontal sinus and frontal bone is determined by the thickness of

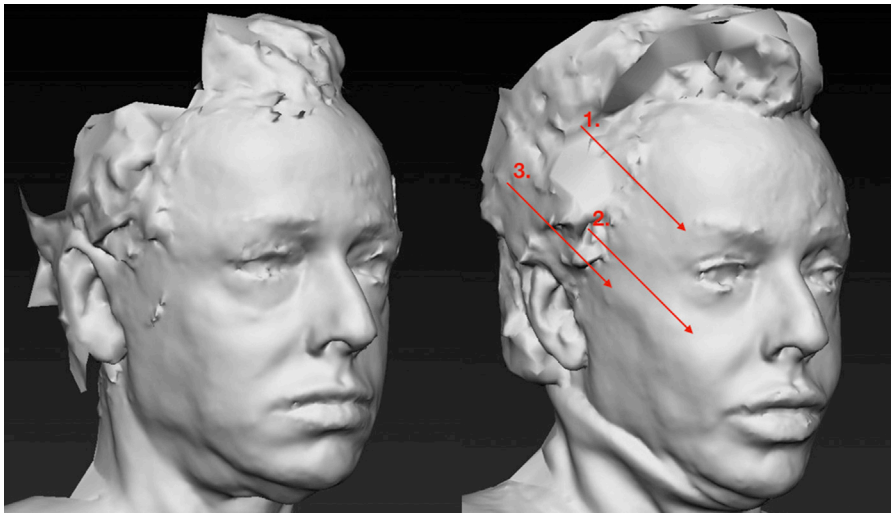

Fig. 3. 3D photography surface scan. Left: preoperative. Right: postoperative. Arrows denote the areas of feminized projection of the midface. (1) Lateral and upper orbital rim, (2) zygomatic body, (3) lateral aspects of the anterior zygomatic arch.

the cortex of the skull and consequently only so much may be reduced. This area then needs to have a smooth connection to the orbital rims, thereby limiting the amount of bone being possible to reduce also at the orbital area, and in a stepwise consequential manner the midface projection is then often needed to be augmented to achieve the desired feminine relations. A significant reduction of the upper facial bones also risks contributing to a dish-face–like look if the midface region is also flat by nature, and this should be taken into account when planning the upper surgery of the face when a midface procedure is not planned. Our decision to perform bony surgery to the midface rather than augmentive work using implants, fillers, or lipo filling is dictated mainly by 2 circumstances. To our knowledge, Sweden is the first country to support FFS for patients with gender dysphoria within public health. This limits us to perform only what can be described as feminizing surgery and not cosmetically driven procedures.[14] This is sometimes not an easily determined distinction, as there can be a blurry line between the desire to look more feminine and to look more beautiful or younger. The other circumstance in our setting is that patients among this group are commonly young and will optimally be treated by surgical means to thereafter live in the desired gender without having to undergo further procedures. They often have a wish to grow old with their feminized face but not have to be seen and treated by public health again for this issue. They do not perceive themselves as ill, and long for a life without frequent health care contacts and appointments. In the long term, the thinning of the soft tissues and the reduced tone of facial musculature as well as the effects of gravity on the soft tissues often leads to a need for further augmentation of previously augmented areas if the soft tissues rather than the bone have been treated. The approach in which the underlying bone is addressed, rather than masking procedures with the soft tissues, has the clear advantage that aging on the soft tissues follows a natural course. Similarly, if implants on the bone are used, repositioning and exchange of the implants to achieve an appearance adequate for the patient's age may be needed. To this end, we chose to perform bony procedures to the midface for most patients. The repositioned skeleton will undergo the same aging as the remainder of the facial skeleton and hopefully follow-up procedures will be unneeded for feminizing purposes. The feminized bony framework is also a good ground for further cosmetic procedures performed in private care should the patient wish for it.

SUMMARY

We suggest that craniofacial procedures to the midface in conjunction with work to the upper face and skull and if needed the lower jaw is a permanent and effective way to achieve feminization of the face in transgender patients. Although the surgery is more complex than other procedures, such as placement of implants and fillers, it should be considered for select patients. Further improvement of cosmesis may be considered a separate surgical entity and is not limited in scope or time by having undergone midface

osteotomies. When carefully planned, bony surgery to the midface using established craniofacial techniques is safe and results in long-term predictive results and a favorable age-appropriate appearance as the patient grows older.

REFERENCES

1. American Psychiatric Association. DSM-5. Available at: http://psychiatry.org/psychiatrists/practice. Accessed October 1, 2018.
2. Rood BA, Puckett JA, Pantalone DW, et al. Predictors of suicidal ideation in a statewide sample of transgender individuals. LGBT Health 2015;2(3):270–5.
3. Dhejne C, Lichtenstein P, Boman M, et al. Long-term follow-up of transsexual persons undergoing sex reassignment surgery: cohort study in Sweden. PLoS One 2011;6(2):e16885.
4. Dhejne C, Van Vlerken R, Heylens G, et al. Mental health and gender dysphoria: a review of the literature. Int Rev Psychiatry 2016;28(1):44–57.
5. Isung J, Möllermark C, Farnebo F, et al. Craniofacial reconstructive surgery improves appearance congruence in male-to-female transsexual patients. Arch Sex Behav 2017;46(6):1573–6.
6. van de Grift TC, Cohen-Kettenis PT, Steensma TD, et al. Body satisfaction and physical appearance in gender dysphoria. Arch Sex Behav 2016;45(3):575–85.
7. Ousterhout DK. Feminization of the forehead: contour changing to improve female aesthetics. Plast Reconstr Surg 1987;79(5):701–13.
8. Altman K. Facial feminization surgery: current state of the art. Int J Oral Maxillofac Surg 2012;41(8):885–94.
9. Morrison SD, Vyas KS, Motakef S, et al. Facial feminization: systematic review of the literature. Plast Reconstr Surg 2016;137(6):1759–70.
10. Capitan L, Simon D, Kaye K, et al. Facial feminization surgery: the forehead. Surgical techniques and analysis of results. Plast Reconstr Surg 2014;134(4):609–19.
11. Becking AG, Tuinzing DB, Hage JJ, et al. Transgender feminization of the facial skeleton. Clin Plast Surg 2007;34(3):557–64.
12. Hopper RA, Kapadia H, Morton T. Normalizing facial ratios in Apert syndrome patients with Le Fort II midface distraction and simultaneous zygomatic repositioning. Plast Reconstr Surg 2013;132(1):129–40.
13. Lundgren TK, Farnebo F. Midface osteotomies for feminization of the facial skeleton. Plast Reconstr Surg Glob Open 2017;5(1):e1210.
14. God vård av vuxna med könsdysfori. Stockholm (Sweden). Socialstyrelsen. Available at: https://www.socialstyrelsen.se/publikationer2015/2015-4-7.