The Journal of Sexual Medicine, 2024, **21**, 827–834
https://doi.org/10.1093/jsxmed/qdae075
Surgeon's Corner

Individually customized gender affirming genital procedures: techniques and considerations

Mona Ascha, MD[1], Siri Rigsby, MPH[2], Maia Shoham, BS[3], Arya Andre Akhavan, MD[4,7], Marco Swanson, MD[5], Carl G. Streed Jr, MD, MPH[6], Anandev Gurjala, MD[7], Shane D. Morrison, MD[2], John Henry Pang, MD[7], Thomas Satterwhite, MD[7,*]

[1]Division of Plastic and Reconstructive Surgery, Department of Surgery, Northwestern University Feinberg School of Medicine, Chicago, IL 60611, United States
[2]Division of Plastic Surgery, University of Washington Medical Center, Seattle, WA 98195-6410, United States
[3]Stanford University School of Medicine, Stanford, CA 94305, United States
[4]Division of Plastic and Reconstructive Surgery, Rutgers New Jersey Medical School, Newark, NJ 07103, United States
[5]Division of Plastic and Reconstructive Surgery, Department of Surgery, University Hospitals Cleveland Medical Center, Cleveland, OH 44106, United States
[6]Center for Transgender Medicine and Surgery, One Boston Medical Center Place, Boston, MA 02118, United States
[7]Align Surgical Associates, San Francisco, CA 94115, United States

*Corresponding author. Align Surgical Associates, San Francisco, CA 94115, United States. Email: tsatterwhite@alignsurgical.com

Abstract

Purpose: Gender-affirming surgery is being increasingly performed for transgender and gender-diverse individuals diagnosed with gender dysphoria. However, there is a group of patients who may seek outcomes that are either a combination of or altogether different from those of binary procedures such as penile inversion vaginoplasty or phalloplasty.
Methods: We describe surgical techniques for less commonly performed gender-affirming genital procedures, in order to introduce these procedures to the medical and surgical community.
Results: Operative techniques for phallus-preserving vaginoplasty, vagina-preserving phalloplasty, and removal of genitalia with creation of perineal urethrostomy are described. Demographic characteristics and complications of these procedures in 16 patients are reported.
Conclusion: Individually customized gender-affirming genital procedures, such as phallus-preserving vaginoplasty, vaginal-preserving phalloplasty, and removal of genitalia and creation of perineal urethrostomy, may better affirm the identities of some gender-diverse patients, and may also preserve desired sexual function of natal genitalia.

Keywords: gender surgery; genital surgery; individually customized.

Introduction

Gender-affirming surgery (GAS) of the genitals, such as phalloplasty and penile inversion vaginoplasty (PIV), result in high levels of satisfaction and improved quality of life.[1-8] These procedures are often considered binary, in that they typically remove external genitalia suggestive of a patient's sex assigned at birth, then construct genitalia consistent with the patient's identified gender (often viewed as the opposite gender). However, some patients may have a desire to express their gender outside of this binary (nonbinary, bigender, agender, etc.) for which traditional vaginoplasty or phalloplasty may not be appropriate.[9] In addition, some patients may desire to preserve functions only possible with natal genitalia.

These patients may seek an outcome that is a combination of binary genital surgeries, such as phallus-preserving vaginoplasty or vagina-preserving phalloplasty. Alternatively, they may seek procedures altogether different from binary procedures, such as nullification, or removal of all external genitalia and creation of a perineal urethrostomy. These genital gender-affirming procedures, referred to as individually customized procedures by the World Professional Association for Transgender Health (WPATH), are supported by the WPATH Standards of Care v.8 (WPATH SOC-8).[10]

Patients may gain mental and physical benefit from individually customized genital procedures if the final genital configuration better matches their gender identities, if their genitalia are a source of gender dysphoria, and/or if their individual medical circumstances warrant these procedures rather than traditional vaginoplasty or phalloplasty.[11-14] However, literature describing individually customized GAS operative techniques and patient outcomes is scant, as the majority of GAS literature focuses on binary genital procedures.[9]

New census data from countries such as Canada are now appropriately capturing this expanding demographic,[15] and the senior author's (T.S.) practice has identified a 150% increase in patients identifying as nonbinary from 2020 to 2022. Given the potential increased need for individually customized procedures, we sought to describe techniques and considerations for surgeons providing individually customized genital GAS, based on the senior author's (T.S.) experience and approach.

Received: September 23, 2023. **Revised:** April 4, 2024. **Accepted:** July 3, 2024
© The Author(s) 2024. Published by Oxford University Press on behalf of The International Society of Sexual Medicine. All rights reserved. For permissions, please e-mail: journals.permissions@oup.com

Downloaded from https://academic.oup.com/jsm/article/21/9/827/7748248 by University of California Library - Berkeley Library user on 20 November 2025

All patients featured in this manuscript gave consent to be included, and the use of patient content in this manuscript was approved by our Institutional Review Board.

Preoperative considerations

Patient selection

Patients who present for surgical consultation will have a broad range of gender identities such as agender, demigender, bigender, genderfluid, nonbinary, genderqueer, etc., and individually customized genital procedures are not necessarily linked to any particular gender identity. There are patients who have a binary gender identity, but wish to have an individually customized procedure. Any patient in consultation for individually customized genital procedures may present for evaluation with a clear idea of their desired genital configuration, or may seek information about what configurations are surgically and technically feasible to achieve.

The WPATH SOC-8 recommend that all patients who undergo individually customized procedures have a comprehensive, multidisciplinary team.[10] In this vein, our practice confirms that the patient has support from their primary care provider, endocrinologist, and other subspecialty physician(s) when relevant, and that the patient is medically optimized for surgery. This is done by direct communication between our surgical staff and the respective physicians.

For patients enrolled in this study, our practice required 2 letters of support from separate mental health professionals, at least 1 of whom has had a relationship with the patient lasting over 1 year, based on WPATH SOC-7 guidelines. Our physicians contact the patient's mental health professional directly to discuss their case in detail, and to ensure that the patient's mental health is optimal for surgery. The mental health professional must support the operative plan, and must be available perioperatively to manage any psychosocial issues that may arise. In addition, our intake process includes screening to ensure the patient has strong social and emotional support.

Operative consultation

When evaluating patients for individually customized procedures, our surgeons follow the same consultation pathway for all patients seeking genital gender-affirming procedures. Each individual undergoes a thorough discussion regarding any dysphoria surrounding their genitals, erogenous sensation and preferences, current and desired sexual practices, and any sexual practices not achievable with the current genital configuration.

With regard to genital configuration, specific questions are asked regarding the desire for preservation, creation, or elimination of a penis, scrotum, testicles, clitoris and clitoral hood, labia majora and minora, and/or vaginal canal. An additional set of questions is asked regarding the desired route of urine elimination (penile, vulvar, perineal). Further questions are asked regarding the patient's desired aesthetic outcome. The details of these line-item questions are used to develop a surgical plan that may retain, create, or eliminate any variety of genitalia.

Following the development of a potential surgical plan, a frank discussion is held with the patient regarding realistic goals, and what is anatomically possible for that individual patient. A thorough discussion of risks, benefits, alternatives, and postoperative course is also done to ensure the patient understands that these procedures are nonreversible, and to set surgical goals in line with the patient's unique needs.

General postoperative care

Following surgery, patients are under direct surgical care for 2 to 3 days in-hospital and are then discharged. Patients must physically remain within a 1-hour driving distance for 1 month postoperatively and have follow-up appointments once weekly during this month. The surgical team maintains close contact with the patient's primary care provider and mental health professional(s) to ensure that they receive appropriate support. Subsequent follow-up appointments take place every 2 months for the first year, in person if local and virtually if nonlocal. There is an on-call provider who is available to address emergent issues at any time.

Phallus-preserving vaginoplasty

Background and patient goals

Phallus-preserving vaginoplasty (PPV) describes the creation of a vaginal canal while maintaining the patient's native phallus. For patients undergoing PPV due to gender dysphoria, dysphoria is often due to the specific absence of a vagina, and is not related to the presence of a native phallus. Patients may also seek to preserve the native phallus for penetrative intercourse, The primary surgical goal of PPV is therefore to create an aesthetic vaginal canal that will permit receptive intercourse (if desired).

Additional goals may vary substantially. Some patients desire vulvoplasty with or without scrotal preservation, and some may desire orchiectomy vs testicular preservation. Urinary diversion from the native phallus may or may not be requested. Patients may or may not desire to preserve erogenous sensation to the native phallus. There is virtually no literature describing this procedure, so information regarding techniques and outcomes is limited to expert opinion.

Procedure

The patient is prepped and draped in lithotomy position, using a Foley catheter and rectal dilator for tactile landmarks. A cruciate incision is made at the inferior scrotum and perineum overlying the central tendon (Figure 1A), with 50% of the scrotal skin removed to be used as lining for the vaginal canal. Dissection is carried out to the base of the urethra. If desired, a high-ligation orchiectomy is carried out at this time.

The neovaginal canal dissection is then performed (Figure 1B). The central tendon is divided and dissection is carried out through the perineal body, to the prerectal space. The canal is then bluntly dissected to the level of the peritoneal reflection, or approximately 14 to 15 cm. Of note, care must be taken not to resect the bulbospongiosus muscle, as over-resection leads to erectile dysfunction and urine dribbling.

Because no penile inversion will be carried out, 200 to 300 cm^2 of full-thickness skin graft will be needed. Scrotal skin that was harvested can be used. It can meshed to increase the surface area. If additional skin is needed, it can be obtained via mini-abdominoplasty or bilateral inguinal crease harvest. The skin graft is defatted, depilated, and sutured on a neovaginal dilator. The graft is inverted and placed, sutured to the perineum, then bolstered in standard fashion. The midline

Downloaded from https://academic.oup.com/jsm/article/21/9/827/7748248 by University of California Library - Berkeley Library user on 20 November 2025

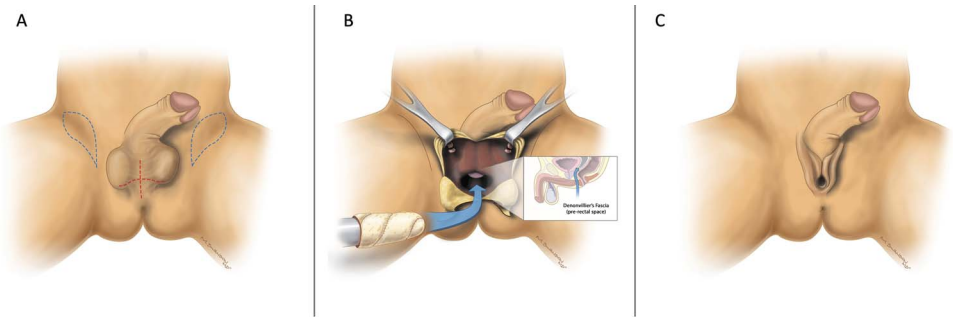

Figure 1. Phallus-preserving vaginoplasty. (A) Preoperative markings. A cruciate incision is made in the inferior aspect of the scrotum with full-thickness skin grafts from the abdomen or inguinal regions. (B) Dissection of the neovaginal canal is performed within the pelvic cavity in the prerectal space along Denonvilliers' fascia between the prostatic capsule and rectum. (C) Neovaginal canal produced with preservation of phallus.

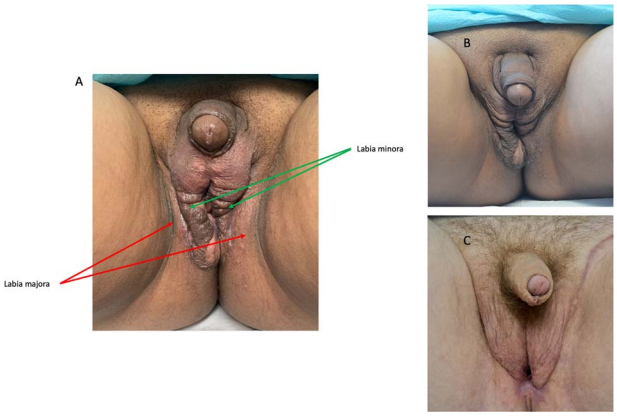

Figure 2. Phallus-preserving vaginoplasty (PPV). (A) Patient who underwent PPV with labia minora and labia majora labeled. (B) Different patient who underwent PPV and revision labiaplasty. (C) Three-month postoperative photo of another patient who underwent PPV. Lining for the full-depth vagina was created using full-thickness skin grafts from the scrotum and from the groin regions (which are in continuity with the lateral labia incisions).

incisional edges of the scrotum are secured to the neovaginal opening.

If labiaplasty is desired, then this may be performed in immediate or delayed fashion. For immediate labiaplasty, the midline perineal-scrotal incision is extended superiorly along the scrotum. Absorbable horizontal mattress sutures are used to create anterior projection of the labia minora, as well as to create an appropriate sulcus between the minora and majora (Figure 1C) (Figure 2A). If orchiectomy was not performed, then the testicles are preserved in the new labia majora. Patients may require revision to adequately create vulvar architecture (Figure 2B).

Discussion

As compared with PIV using penoscrotal skin and prepuce to create a vaginal lining,[1,16] PPV inherently requires full-thickness skin grafting from other sites when performed via an open approach. For patients with a neovaginal canal 15 cm long and 3.5 cm in diameter, this requires 175 cm^2 of full-thickness skin grafting. Patient anatomic variability may require the use of full-thickness skin graft donor sites other than the low abdomen or inguinal creases. Intestinal vaginoplasty techniques obviate the need for skin grafting but come with additional morbidity.[17,18] Peritoneal flaps can also be used to augment the apex of the neovaginal canal with peritoneum, but are also associated with morbidity from the intra-abdominal disturbance.[19] However, a robotic approach for peritoneal flap harvest for PPV may obviate the need for skin grafts, and patients may prefer a peritoneal flap. Reasons include the possibility of a longer neovagina without externally visible donor site, avoidance of potential hair growth in the neovagina from a scrotal skin graft, and self-lubrication from peritoneal tissue. These are important points to include in preoperative consultation and shared decision-making with the patient.

There are additional concerns unique to PPV. Patients with a native phallus often desire to continue urinating through the phallus. During PIV, the bulbospongiosus muscle may be resected; however, the bulbospongiosus contributes to urinary control, ejaculatory function, and penile erection. Over-resection can potentially lead to erectile dysfunction and urine dribbling. In addition, patients who have undergone PPV with the senior author report that engorgement of preserved erectile tissue does not limit use of their vagina; however, patients are counselled that this can be a potential concern.

Patients undergoing PIV often desire maximal resection of erectile tissue. For PPV, however, patients typically desire preservation of erectile tissue. If patients decide to pursue penectomy in the future, there may be limitations in the ability to fully resect the erectile tissue, though creation of a female urethral meatus and clitoris will still be possible. This should be addressed with the patient during preoperative consultation.

Vagina-preserving phalloplasty

Background and patient goals

Vagina-preserving phalloplasty (VPP) describes the creation of a neophallus without vaginectomy or colpoclesis.[20] Patient choice for vaginal preservation is typically related to embodiment goals to address gender dysphoria or desire to preserve sexual function. For patients undergoing VPP for gender dysphoria, the dysphoria is often due to the specific absence of a penis, and is not affected by the presence of a vagina. Some patients may desire to retain their native vagina for sexual gratification.[20]

Patient goals for phalloplasty may be to have a phallus capable of erection, for penetrative intercourse. Others may place the highest priority on tactile and erogenous sensation, and still others may aim for standing micturition. The primary surgical goals of VPP are similar to traditional phalloplasty—creation an anatomic neophallus that is capable of

Downloaded from https://academic.oup.com/jsm/article/21/9/827/7748248 by University of California Library - Berkeley Library user on 20 November 2025

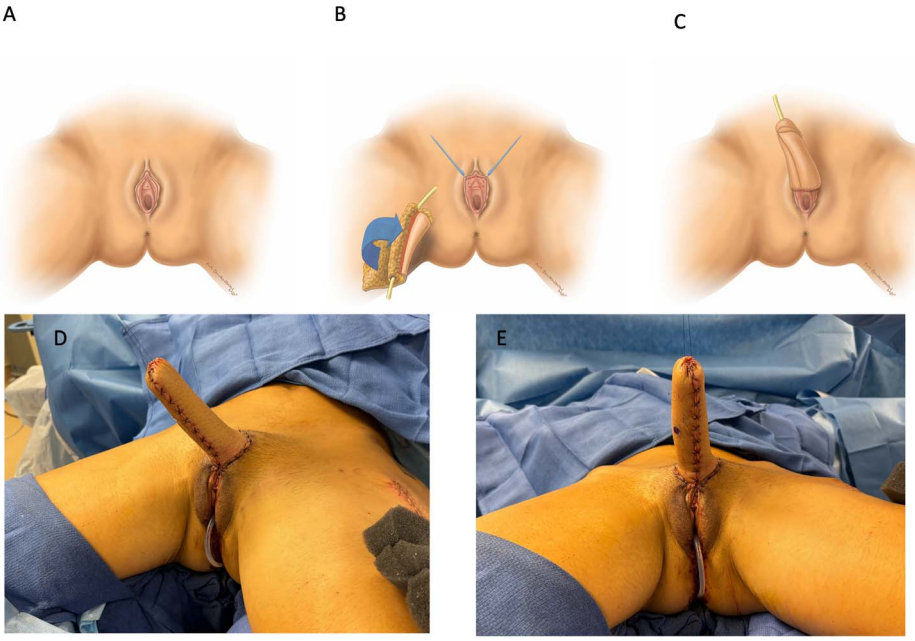

Figure 3. Vagina-preserving phalloplasty. (A) Preoperative appearance. (B) Creation of a phallus (either pedicled or free flap) with planned area of urethral lengthening identified with dotted lines. (C) Postoperative appearance after urethral lengthening that can be done in a single or multistage approach. (D, E) Postoperative photographs.

penetrative intercourse and tactile and erogenous sensation, if desired.[21,22]

Procedure:

VPP is essentially a staged phalloplasty but is performed with the explicit intent of not performing a subsequent vaginectomy, colpocleisis, and/or scrotoplasty. A pedicled or free-flap phalloplasty is selected based on individual patient factors. The flap is designed, raised, and formed, then transferred to the perineum (Figure 3A). The clitoris may be left at the base of the phallus, buried under the phallus, or incorporated into the phallus, per patient preference. If the patient desires urethral lengthening, this is done using labia minora flaps as described in the literature,[18,20] and may be performed in immediate or staged fashion (Figure 3B).

Discussion

In patients preserving their vaginas, labia minora flaps without a vascularized muscular layer were used to construct the horizontal urethra (pars fixa), lending to increased urethral complications.[20] Similar results were seen in patients who did not undergo colpectomy (removal of the vagina) with regard to increased urethral complications by Al-Tamimi et al.[17] Lower rates of urethral stricture and fistula formation in the setting of vaginectomy are most likely due to the ability to line the constructed horizontal urethra with labia minora flaps as well as vascularized vestibular tissue.[17,20] Counseling patients on the increased risk of urethral complications is imperative, including the potential for a fistula into the remaining vaginal canal. Creation of the pars fixa in the setting of vaginal preservation may also constrict the vaginal introitus, possibly impeding vaginal intercourse. This must also be discussed in preoperative counseling.

It should be noted that vaginectomy is associated with greater incidence of nonurethral complications, such as rectal injury, hematoma, and wound dehiscence.[20] Patients may choose to undergo vaginectomy at a later time. Delayed vaginectomy may be indicated in the setting of recurrent fistulas, but tends to not alter outcomes substantially.[17]

In some centers, vaginal preserving phalloplasty or metoidioplasty are performed without urethral lengthening to avoid complications with the neourethra. The senior author recognizes the risk of fistula, and therefore offers phalloplasty and metoidioplasty with urethral lengthening in patients seeking to preserve the vagina.

Removal of genitalia and creation of perineal urethrostomy

Background

Surgical removal of genitalia involves removal of most or all external genitalia structures. This includes orchiectomy, penectomy, and shortening of the urethra to create a perineal urethrostomy. It is important that these individuals understand that orchiectomy with penectomy will eliminate their ability to perform penetrative intercourse.

Procedure

For individuals assigned male at birth, scrotal skin is removed and orchiectomy is performed. Next, the urethra is dissected away from surrounding tissue and protected with a Foley catheter while other external genital structures are resected. The Foley catheter remains in place 7 days postoperatively. A similar approach could be used for removal of the female genitalia with colpectomy, removal of labia and clitoris, and hysterectomy with bilateral salpingo-oophorectomy. Of note, for those desiring retained erogenous sensation, the glans penis can be retained, de-epithelialized, and buried under the skin. For those assigned female at birth, the clitoris can be de-epithelialized and buried under the skin. Figures 4B through 4F demonstrate this procedure.

Downloaded from https://academic.oup.com/jsm/article/21/9/827/7748248 by University of California Library - Berkeley Library user on 20 November 2025

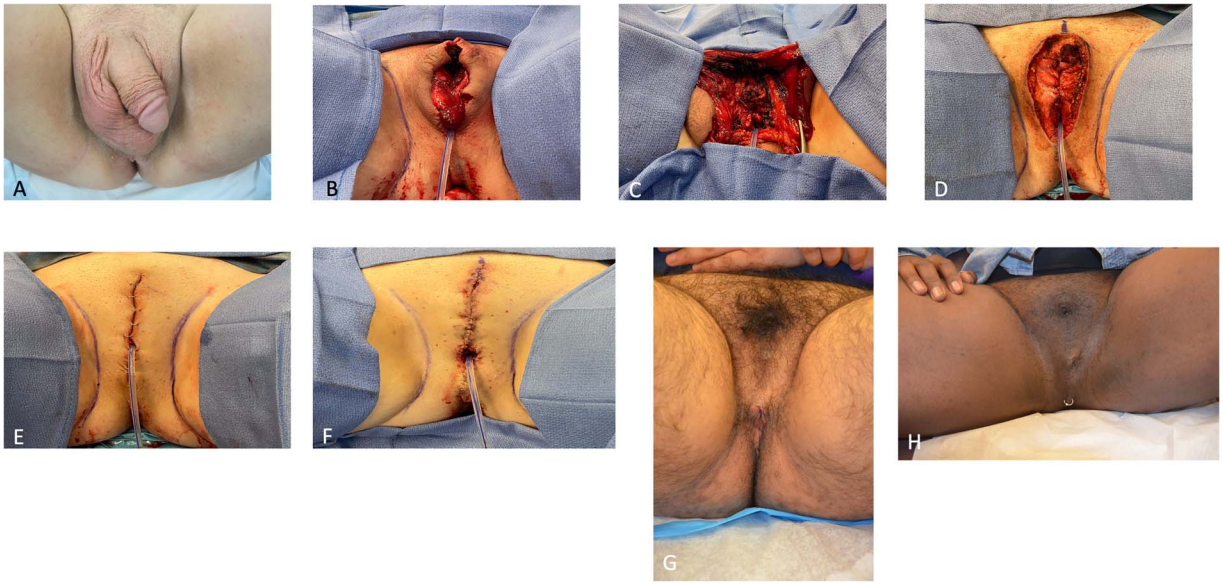

Figure 4. Removal of external genitalia and creation of perineal urethrostomy procedure. (A) Preoperative photograph. (B) Amputation of penis, orchiectomy, and scrotectomy. (C) The proximal urethra is separated from the tunica, shortened, and spatulated. Spatulation of the urethra is performed to prevent meatal stenosis. The stump of the corpora cavernosa is ligated. (D) Scrotal fat is brought to midline and sutured over the remaining corpora to provide a smooth consistent perineum. (E) Excess skin is tailor tacked. (F) After excess skin is resected, the area is closed in a layered fashion, and the spatulated urethra is inset.

For patients assigned female at birth, 5-cm strips of vaginal mucosa are harvested along the length of the canal from 4 sidewalls, taking care not to injure the urethra or rectum. A 4 × 2 cm diamond shape is marked out around the urethral meatus to be inset later. Then, a lentiform incision is marked out in the medial labia majora, incised, and de-epithelialized. The clitoris and glans are then degloved, and the labial edges are reapproximated in the midline. Finally, the diamond-shaped periurethral skin is inset within the labial closure.

In the T.S.'s practice, patients have retained the ability to orgasm after the procedure. Notably, patients have stated they were able to stimulate the perineum, primarily above the urethra where the stump of the corpora and associated dorsal nerve resides, in order to achieve orgasm. Figures 5A and 5B demonstrate patients who have undergone removal of external genitalia and creation of perineal urethrostomy at 1-year follow up.

Complications/disadvantages

Patients undergoing removal of external genitalia and creation of perineal urethrostomy may require lifelong hormone supplementation for overall systemic health, which requires compliance and willingness, depending on their gender expression goals. Changes and limitations in sexual function must be carefully discussed with patients. Satisfaction rates after removal of external genitalia and creation of perineal urethrostomy are unknown.[23]

T.S.'s practice

Table 1 outlines the demographics and outcomes of patients who have undergone individually customized genital procedures.[20] Nine patients undergoing VPP were previously described.[20] This information is provided for context, although a detailed description of indications, outcomes, and complications of these procedures is not the goal of this report.

At T.S.'s practice, 3 patients underwent PPV and 4 patients underwent removal of genitalia and creation of perineal urethrostomy. Nine patients underwent VPP and were reported on in a prior study.[24] Mean follow-up ranged from 8 months to 17 months. Patients were admitted for 2 nights of observation and monitored postoperatively for 12 months. Two patients undergoing PPV experienced complications: 1 patient experienced a surgical site infection and 1 experienced wound dehiscence, resulting in a complication rate of 67% (n = 2 of 3). Patients reported anecdotal satisfaction with their procedures.

Discussion

This report is intended to increase awareness and educate medical professionals about individually customized genital gender affirming procedures. These procedures have been performed by the senior author and others for many years. Providers within GAS and in other specialties may encounter patients with a history of these procedures and should be familiar with postoperative anatomy and potential complications that may arise. A discussion of these procedures raises provider awareness of how gender-diverse patients may present and improve their management. It is important to note that, as a private surgical practice without in-house mental health, primary care, and endocrinology care, there is variability in the quality of preoperative assessments of patients from various providers. There is no current standard assessment pathway for such patients, though we combat this by discussing each case in detail with the patient's outside providers, which is feasible given the relative rarity of these procedures.

Patient satisfaction rates after these procedures remain unknown. Patients have anecdotally expressed high satisfaction with their procedures postoperatively; however, no objective patient-reported outcome tool was utilized. Further studies with larger cohorts from multiple sites and objective

Downloaded from https://academic.oup.com/jsm/article/21/9/827/7748248 by University of California Library - Berkeley Library user on 20 November 2025

Figure 5. Removal of external genitalia and creation of perineal urethrostomy. (A) Patient who underwent removal of external genitalia and creation of perineal urethrostomy at 1-year follow-up. (B) Second patient at 1-year follow-up.

Table 1. Demographics and surgical outcomes of patients undergoing less commonly performed genital procedures.

	Phallus-preserving vaginoplasty	Vagina-preserving phalloplasty	Removal of genitalia and creation of perineal urethrostomy
Patients	3	9	4
Age at time of surgery, y	30 ± 6	35 ± 7	22 ± 6[a]
BMI, kg/m^2	23 ± 4	27 ± 5	NR
Assigned male at birth	3 (100)	0 (0)	4 (100)
Nonbinary gender identity	0 (0)	NR	2 (50)
Binary gender identity	3 (100)	NR	2 (50)
Follow-up, mo	12.4 ± 11.6	17.0 ± 8.1	8.0 ± 5.0
Complications	2 (67)	0 (0)	0 (0)
Hematoma[b]	0 (0)	0 (0)	0 (0)
Surgical site infection[c]	1 (33)	0 (0)	0 (0)
Wound dehiscence[d]	1 (33)	0 (0)	0 (0)
Rectal injury	0 (0)	0 (0)	0 (0)
Urethral injury	0 (0)	0 (0)	0 (0)
Patient-reported satisfaction[e]	3 (100)	NR	4 (100)

Values are n, mean ± SD, or n (%). Abbreviations: BMI, body mass index; NR, not recorded. [a]Data available for 2 patients only. [b]Requiring return to operating room or blood transfusion. [c]Requiring surgical drainage or antibiotics within 30 days of surgery. [d]Requiring dressing changes or return to operating room within 30 days of surgery. [e]Verbal patient reported satisfaction during clinic visit.

patient-reported outcomes are currently underway. While we posit that long-term quality of life will be improved and that patient satisfaction will be high following less commonly performed gender-affirming procedures, this may not always be the case.[24-27] Long-term follow up and evidence-based recommendations are required.

Much discussion about these procedures is yet to come. Ethical discussions, specific indications, a detailed report of complications in a sizeable cohort, and guidelines for insurance coverage have yet to be elucidated for these procedures. This report is not intended to comment on these important considerations. Ultimately, when these genital GASs are provided, the surgeon must be comfortable performing the procedure, providing fully informed consent to the patient including appropriate expectations setting, and participating in an interdisciplinary patient-centered decision-making process. A discussion of the patient's embodiment goals is necessary, and the surgeon and patient must agree that the procedure will help the patient achieve their goals.

Conclusions

Some gender-diverse patients may seek individually customized genital GASs. Surgical techniques should be chosen to best match each individual patient's embodiment goals with the ultimate purpose of reducing gender dysphoria. We present our operative techniques for individually customized gender-affirming genital procedures and provide an overview of potential complications and postoperative considerations. A full discussion of ethical justification for these procedures, quantifiable complication rates, satisfaction and reoperation rates, and indications for surgery are forthcoming. However, this preliminary report describes these procedures, which are already being performed, and educates healthcare providers who may encounter patients with a history of these procedures.

Gender and sexuality represent complex spectra that can intersect in many ways; individually customized genital construction allows a wide spectrum of sexual and identity outcomes to be met.

Downloaded from https://academic.oup.com/jsm/article/21/9/827/7748248 by University of California Library - Berkeley Library user on 20 November 2025

Author contributions

M.A. (Conceptualization-Equal, Data curation-Equal, Formal analysis-Equal, Funding acquisition-Equal, Investigation-Equal, Methodology-Equal, Project administration-Equal, Resources-Equal, Software-Equal, Supervision-Equal, Validation-Equal, Visualization-Equal, Writing – original draft-Equal, Writing – review & editing-Equal), S.R. (Conceptualization-Equal, Data curation-Equal, Formal analysis-Equal, Funding acquisition-Equal, Investigation-Equal, Methodology-Equal, Project administration-Equal, Resources-Equal, Software-Equal, Supervision-Equal, Validation-Equal, Visualization-Equal, Writing – original draft-Equal, Writing – review & editing-Equal), M.S. (Conceptualization-Equal, Methodology-Equal, Project administration-Equal, Supervision-Equal, Validation-Equal, Visualization-Equal, Writing – original draft-Equal, Writing – review & editing-Equal), A.A.A. (Conceptualization-Equal, Supervision-Equal, Visualization-Equal, Writing – review & editing-Equal), M. S. (Conceptualization-Equal, Data curation-Equal, Methodology-Equal, Project administration-Equal, Validation-Equal, Visualization-Equal, Writing – original draft-Equal), C.G.S. (Conceptualization-Equal, Investigation-Equal, Methodology-Equal, Supervision-Equal, Validation-Equal, Writing – original draft-Equal, Writing – review & editing-Equal), A.G. (Methodology-Equal, Writing – original draft-Equal, Writing – review & editing-Equal), S.D.M. (Conceptualization-Equal, Data curation-Equal, Methodology-Equal, Project administration-Equal, Supervision-Equal, Visualization-Equal, Writing – original draft-Equal, Writing – review & editing-Equal), J.H.P. (Supervision-Equal, Writing – review & editing-Equal), T.S. (Conceptualization-Equal, Data curation-Equal, Investigation-Equal, Project administration-Equal, Resources-Equal, Supervision-Equal, Visualization-Equal, Writing – original draft-Equal, Writing – review & editing-Equal).

Funding

No funding was received for this work.

Conflicts of Interest

No disclosures or conflicts of interest are reported by any of the authors.

References

1. Boas SR, Ascha M, Morrison SD, *et al*. Outcomes and predictors of revision labiaplasty and clitoroplasty after gender-affirming genital surgery. *Plast Reconstr Surg*. 2019;**144**(6):1451-1461. https://doi.org/10.1097/prs.0000000000006282
2. Massie JP, Morrison SD, Van Maasdam J, Satterwhite T. Predictors of patient satisfaction and postoperative complications in penile inversion vaginoplasty. *Plast Reconstr Surg*. 2018;**141**(6):911e-921e. https://doi.org/10.1097/prs.0000000000004427
3. Ainsworth TA, Spiegel JH. Quality of life of individuals with and without facial feminization surgery or gender reassignment surgery. *Qual Life Res*. 2010;**19**(7):1019-1024. https://doi.org/10.1007/s11136-010-9668-7
4. Klassen AF, Kaur M, Poulsen L, *et al*. Development of the BODY-Q chest module evaluating outcomes following chest contouring surgery. *Plast Reconstr Surg*. 2018;**142**(6):1600-1608. https://doi.org/10.1097/prs.0000000000004978
5. van de Grift TC, Elfering L, Greijdanus M, *et al*. Subcutaneous mastectomy improves satisfaction with Body and psychosocial function in trans men: findings of a cross-sectional study using the BODY-Q chest module. *Plast Reconstr Surg*. 2018;**142**(5):1125-1132. https://doi.org/10.1097/prs.0000000000004827
6. Morrison SD, Capitán-Cañadas F, Sánchez-García A, *et al*. Prospective quality-of-life outcomes after facial feminization surgery: an international multicenter study. *Plast Reconstr Surg*. 2020;**145**(6):1499-1509. https://doi.org/10.1097/prs.0000000000006837
7. Al-Tamimi M, Pigot GL, Elfering L, *et al*. Genital gender-affirming surgery in transgender men in the Netherlands from 1989 to 2018: the evolution of surgical care. *Plast Reconstr Surg*. 2020;**145**(1):153e-161e. https://doi.org/10.1097/prs.0000000000006385
8. Esmonde NO, Heston AL, Morrison T, *et al*. Providing gender confirmation surgery at an academic medical center: analysis of use, insurance payer, and fiscal impact. *J Am Coll Surg*. 2019;**229**(5):479-486. https://doi.org/10.1016/j.jamcollsurg.2019.07.002
9. Esmonde N, Heston A, Jedrzejewski B, *et al*. What is "non-binary" and what do I need to know? A primer for surgeons providing chest surgery for transgender patients. *Aesthet Surg J*. 2019;**39**(5):NP106-NP112. https://doi.org/10.1093/asj/sjy166
10. Coleman E, Radix AE, Bouman WP, *et al*. Standards of Care for the Health of Transgender and Gender Diverse People, Version 8. *Int J Transgend Health*. 2022;**23**(Suppl 1):S1-s259. https://doi.org/10.1080/26895269.2022.2100644
11. Mueller A, Quadros C, Schwarz K, *et al*. Rumination as a marker of psychological improvement in transsexual women postoperative. *Transgend Health*. 2016;**1**(1):274-278. https://doi.org/10.1089/trgh.2016.0029
12. Owen-Smith AA, Gerth J, Sineath RC, *et al*. Association between gender confirmation treatments and perceived gender congruence, Body image satisfaction, and mental health in a cohort of transgender individuals. *J Sex Med*. 2018;**15**(4):591-600. https://doi.org/10.1016/j.jsxm.2018.01.017
13. Bränström R, Pachankis JE. Reduction in mental health treatment utilization among transgender individuals after gender-affirming surgeries: a total population study. *Am J Psychiatry*. 2020;**177**(8):727-734. https://doi.org/10.1176/appi.ajp.2019.19010080
14. Wierckx K, Van Caenegem E, Elaut E, *et al*. Quality of life and sexual health after sex reassignment surgery in transsexual men. *J Sex Med*. 2011;**8**(12):3379-3388. https://doi.org/10.1111/j.1743-6109.2011.02348.x
15. Statistics Canada. Canada is the first country to provide census data on transgender and non-binary people. Accessed June 30, 2022. https://www150.statcan.gc.ca/n1/dailyquotidien/220427/dq220427b-eng.htm
16. James SE, Herman JL, Rankin S, Keisling M, Mottet L, Anafi M. The report of the 2015 U.S. *Transgender Survey*. 2016. Accessed June 30, 2022. https://transequality.org/sites/default/files/docs/usts/USTS-Full-Report-Dec17.pdf
17. Al-Tamimi M, Pigot GL, van der Sluis WB, *et al*. Colpectomy significantly reduces the risk of urethral fistula formation after urethral lengthening in transgender men undergoing genital gender affirming surgery. *J Urol*. 2018;**200**(6):1315-1322. https://doi.org/10.1016/j.juro.2018.07.037
18. Danker S, Esmonde N, Berli JU. "Staging" in phalloplasty. *Urol Clin North Am*. 2019;**46**(4):581-590. https://doi.org/10.1016/j.ucl.2019.07.011
19. Remington AC, Morrison SD, Massie JP, *et al*. Outcomes after phalloplasty: do transgender patients and multiple urethral procedures carry a higher rate of complication? *Plast Reconstr Surg*. 2018;**141**(2):220e-229e. https://doi.org/10.1097/prs.0000000000004061
20. Massie JP, Morrison SD, Wilson SC, Crane CN, Chen ML. Phalloplasty with urethral lengthening: addition of a vascularized bulbospongiosus flap from vaginectomy reduces postoperative urethral complications. *Plast Reconstr Surg*. 2017;**140**(4):551e-558e. https://doi.org/10.1097/prs.0000000000003697
21. Morrison SD, Shakir A, Vyas KS, Kirby J, Crane CN, Lee GK. Phalloplasty: a review of techniques and outcomes. *Plast Reconstr Surg*. 2016;**138**(3):594-615. https://doi.org/10.1097/prs.0000000000002518
22. Morrison SD, Chen ML, Crane CN. An overview of female-to-male gender-confirming surgery. *Nat Rev Urol*. 2017;**14**(8):486-500. https://doi.org/10.1038/nrurol.2017.64

Downloaded from https://academic.oup.com/jsm/article/21/9/827/7748248 by University of California Library - Berkeley Library user on 20 November 2025

23. Ettner FM. Primary care for the transgender and gender nonconforming patient. *Clin Plast Surg*. 2018;**45**(3):301-306. https://doi.org/10.1016/j.cps.2018.03.001
24. Massie JP, Morrison SD, Wilson SC, Crane CN, Chen ML. Phalloplasty with urethral lengthening: addition of a vascularized bulbospongiosus flap from vaginectomy reduces postoperative urethral complications. *Plast Reconst Surg*. 2017;**140**:551e. https://doi.org/10.1097/PRS.0000000000003697
25. Newfield E, Hart S, Dibble S, Kohler L. Female-to-male transgender quality of life. *Qual Life Res*. 2006;**15**(9):1447-1457. https://doi.org/10.1007/s11136-006-0002-3
26. Kuhn A, Bodmer C, Stadlmayr W, Kuhn P, Mueller MD, Birkhäuser M. Quality of life 15 years after sex reassignment surgery for transsexualism. *Fertil Steril*. 2009;**92**(5):1685-1689.e3. https://doi.org/10.1016/j.fertnstert.2008.08.126
27. De Cuypere G, T'Sjoen G, Beerten R, *et al*. Sexual and physical health after sex reassignment surgery. *Arch Sex Behav*. 2005;**34**(6):679-690. https://doi.org/10.1007/s10508-005-7926-5
28. Dhejne C, Lichtenstein P, Boman M, Johansson AL, Långström N, Landén M. Long-term follow-up of transsexual persons undergoing sex reassignment surgery: cohort study in Sweden. *PLoS One*. 2011;**6**(2):e16885. https://doi.org/10.1371/journal.pone.0016885

Downloaded from https://academic.oup.com/jsm/article/21/9/827/7748248 by University of California Library - Berkeley Library user on 20 November 2025