JOURNAL OF PLASTIC SURGERY AND HAND SURGERY
2018, VOL. 52, NO. 4, 210–216
https://doi.org/10.1080/2000656X.2018.1444616

ARTICLE

Vaginal reconstruction with the modified rectosigmoid colon: surgical technique, long-term results and sexual outcomes

Ömer Özkan[a], Özlenen Özkan[a], Anı Çinpolat[b], Nasuh Utku Doğan[c], Gamze Bektaş[b], Kemal Dolay[d]*, Alihan Gürkan[e], Cumhur Arıcı[d] and Selen Doğan[c]

[a]Department of Plastic, Reconstructive and Aesthetic Surgery, Akdeniz University Faculty of Medicine, Antalya, Turkey; [b]Private Clinic, Plastic, Reconstructive and Aesthetic Surgery, Antalya, Turkey; [c]Department of Obstetrics and Gynecology, Akdeniz University Faculty of Medicine, Antalya, Turkey; [d]Department of General Surgery, Akdeniz University Faculty of Medicine, Antalya, Turkey; [e]Antalya Private Memorial Hospital, General Surgery Unit, Antalya, Turkey

ABSTRACT

Although vaginal reconstructions with intestinal segments require particularly complex surgical procedures, this technique has become popular with respect to fairly good functional and esthetic outcomes. This study describes cases of vaginal reconstruction performed using a modified rectosigmoid colon held in an ischemic state in order to reduce secretion and denervated in order to prevent defecation problems. Vaginal reconstructions with rectosigmoid colon were performed on 43 patients. In this retrospective study, 34 patients had Müllerian agenesis, while nine had undergone male to female sex reassignment surgery in which adequate vaginal depth had not been achieved. A rectosigmoid colon with its vascular pedicle was used and left in an ischemic state. All nerve structures within the pedicle were excised intraoperatively. Follow-up period was between 12 and 60 months. Partial necrosis occurred in one patient which was reconstructed with local flap. Hematoma developed beneath the skin incision in two cases, but resolved with conservative treatment. A good esthetic outcome was achieved in all cases. Sexual function was assessed using the Female Sexual Function Index (FSFI) in 15 patients. Fourteen out of 15 patients scored above 26.5 on this scale and were determined as having no sexual dysfunction (FSFI score $\geq$26.5). In conclusion, vaginal reconstruction with denervated rectosigmoid held in an ischemic state appears to be a reasonable option among several available reconstruction techniques.

ARTICLE HISTORY
Received 25 May 2017
Revised 28 January 2018
Accepted 15 February 2018

KEYWORDS
Rectosigmoid colon; vaginal agenesis; vaginal reconstruction; vaginoplasty and bowel

Introduction

Several methods of vaginal reconstruction have been described in the literature. These range from non-surgical techniques, such as expansion of the vagina using a dilator to reconstructions with mucosal or skin grafts, skin flaps or intestinal segments [1–13]. Intestinal transfers offer a number of advantages over other methods, since they are robust, provide a stable vaginal wall, create a sufficient vaginal space for sexual relations, require no lubrication since they have their own secretions, require no dilator or stent use and provide a natural and esthetically pleasing appearance [14–18]. The intestinal segments most commonly used in vaginal reconstruction are the rectosigmoid, ileum and jejunum. Each has various advantages and disadvantages, depending on its anatomical and physiological characteristics. In terms of its location, retention of the vascular pedicle is the most important advantage of the rectosigmoid colon. Preservation of vascular pedicle is not always possible for ileal or jejunal segments which are generally transferred as free flaps [1,14–18].

The main disadvantage of vaginal reconstruction with intestinal segments is excessive secretion. The disadvantages of vaginal reconstructions using the rectosigmoid colon are donor site morbidity and defecation problems. In this study, long-term outcomeks of vaginal reconstruction using a denervated pedicled rectosigmoid colon held in an ischemic state was presented along with functional sexual evaluation.

Materials and methods

Vaginal reconstruction with a modified rectosigmoid colon was performed on 43 patients between June 2011 and May 2016 in Akdeniz University Faculty of Medicine and Private Memorial Hospital Antalya, Turkey in the Department of Plastic, Reconstructive and Aesthetic Surgery. Institutional Review Board approval was obtained for the study.

Nine out of 43 patients were transgender and the remainder of the study population consisted of Mayer–Rokitansky–Küster–Hauser (MRKH) patients. The mean ages (and range) of the transgender and MRKH patients were 40 (24–48) and 26.9 (17–43) years, respectively (Table 1).

All operations were performed in a coordinated manner by plastic surgeons, general surgeons and gynecologists. All patients underwent preoperative physical examination, routine blood tests and pelvic ultrasonography. Clinical data were obtained from electronic medical records and patients' private files.

Surgical technique

Patients were started on liquid food nutrition 3 days prior to surgery. Colonic cleansing was performed twice in the night and on the morning before surgery with oral and rectal sodium phosphate administration. Operations were performed under general anesthesia with the patient in the lithotomy position. First, a urinary catheter was inserted. The operation was commenced by

CONTACT Omer Ozkan omozkan@hotmail.com Akdeniz Universitesi Hastanesi, Dumlupinar Bul. B blok, Kat:2, Antalya, Turkey
*Present address: Istinye University, Faculty of Medicine, Department of General Surgery, Istanbul, Turkey.

© 2018 Acta Chirurgica Scandinavica Society

Table 1. Patient summary.

Patients	Age (years)	Etiology	Ischemic state (minute)	Excision of nerve	Complication	Follow up (month)
1	23	MRKHS	120	+	–	60
2	18	MRKHS	120	+	–	59
3	19	MRKHS	120	+	–	57
4	30	MRKHS	120	+	–	55
5	24	MRKHS	120	+	–	55
6	24	MRKHS	120	+	–	53
7	19	MRKHS	120	+	–	52
8	21	MRKHS	120	+	–	52
9	22	MRKHS	120	+	–	52
10	37	MRKHS	120	+	–	51
11	26	MRKHS	120	+	–	49
12	20	MRKHS	120	+	–	48
13	38	TG	120	+	–	48
14	18	MRKHS	120	+	–	47
15	44	TG	120	+	–	46
16	24	MRKHS	120	+	–	44
17	40	MRKHS	120	+	–	44
18	37	MRKHS	120	+	–	43
19	47	TG	120	+	–	42
20	19	MRKHS	120	+	–	42
21	20	MRKHS	120	+	–	41
22	34	MRKHS	120	+	–	38
23	48	TG	120	+	–	37
24	46	TG	120	+	Necrosis of distal flap	37
25	34	MRKHS	120	+	–	37
26	34	TG	120	+	–	34
27	24	TG	120	+	–	31
28	45	TG	120	+	Subcutaneous Hematoma	30
29	34	TG	120	+	–	30
30	27	MRKHS	60	+	–	28
31	17	MRKHS	60	+	–	27
32	43	MRKHS	60	+	–	27
33	35	MRKHS	60	+	–	26
34	31	MRKHS	60	+	Subcutaneous Hematoma	24
35	34	MRKHS	60	+	–	23
36	33	MRKHS	60	+	–	20
37	25	MRKHS	60	+	–	20
38	24	MRKHS	60	+	–	19
39	25	MRKHS	60	+	–	15
40	32	MRKHS	60	+	–	13
41	33	MRKHS	60	+	–	13
42	24	MRKHS	60	+	–	12
43	24	MRKHS	60	+	–	12

MRKHS: Mayer–Rokitansky–Küster–Hauser Syndrome; TG: Transgender.

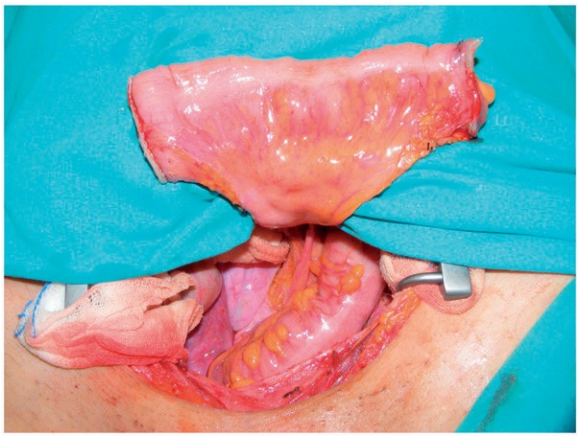

Figure 1. The rectosigmoid colon flap raised on its vascular pedicle.

general surgery team. Laparotomy was performed by Pfannenstiel incision, and a rectosigmoid colon section approximately 18–20 cm in length was prepared from the pedicle (Figure 1). The length of the rectosigmoid colon was adapted and a 2–3 cm section of the colon was excised as required.

The proximal part of the prepared rectosigmoid colon was closed with linear staples (Covidien, Mansfield, MA). The pedicle was kept in an ischemic state for 2 h in our first 20 patient series, followed by 1 h for the remaining patients (Figure 2). Ischemic state was created by obstructing the blood flow in the pedicle with the help of bulldog clamps. During ischemia, colonic anastomosis was performed by the general surgery team with the help of circular staples (Covidien, Mansfield, MA). All nerve structures within the pedicle were then exposed under a microscope. A section approximately 1 cm in length was resected and the remaining nerve endings were cauterized with bipolar cautery (Figures 3 and 4). Toward the end of the ischemia period, a vaginal pouch was established with blunt dissection, while protecting the bladder, urethra and rectum in collaboration with the gynecologic surgeons. At this time the bulldog clamps were removed and the prepared rectosigmoid flap was inserted into the created pouch. After passing the pouch, the proximal part was lightly sutured to the presacral peritoneum and to the mesoperitoneum along one lateral margin to prevent internal herniation. The distal part of the rectosigmoid flap was sutured to the neovaginal outlet using a z plasty technique in order to reduce the risk of future narrowing of the vaginal outlet (Figure 5).

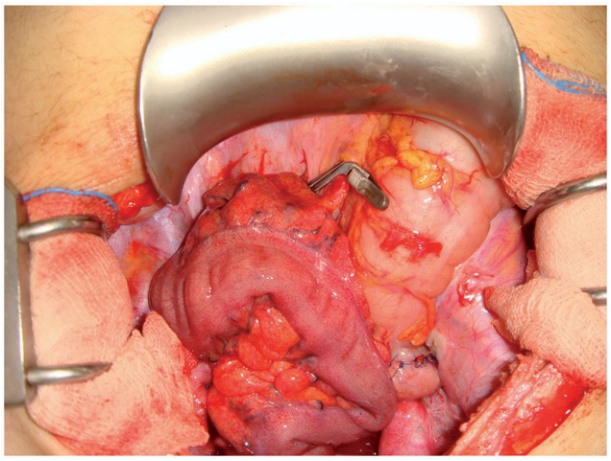

Figure 2. Appearance of the rectosigmoid flap in an ischemic state with a vascular clamp attached to the pedicle.

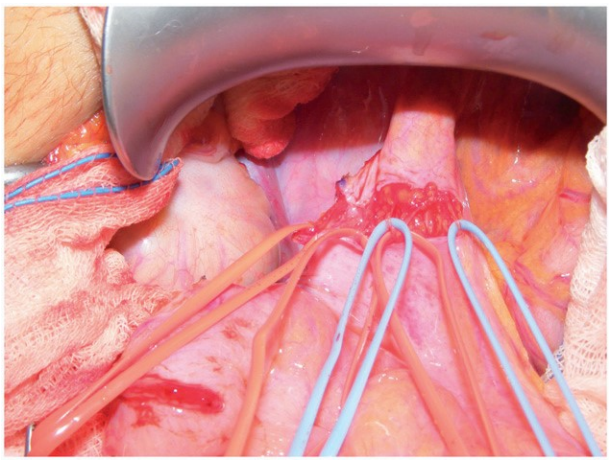

Figure 3. All nerve structures within the pedicle of the rectosigmoid flap were exposed.

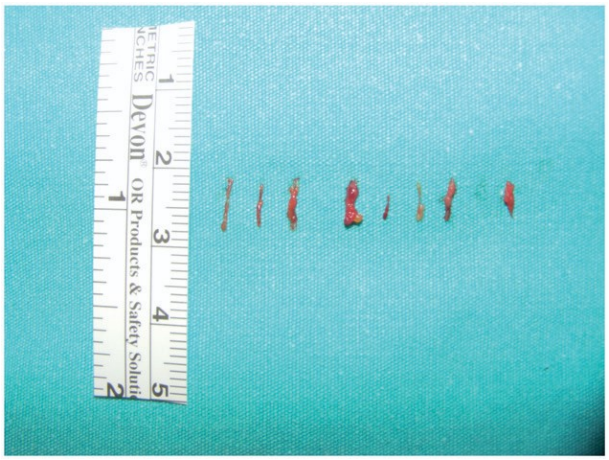

Figure 4. Excised nerve structures.

For transgender patients, all the vaginal remnants were removed in order to easily prepare a new, clear and fresh pouch. This method prevented potential contraction of the intraoitus.

At the end of the surgery, a 20 cm long colon segment elicited approximately 12–13 cm long neo-vagina due the adaptation in the back table and further contraction of the rectosigmoid segment after fixation to vaginal pouch.

Figure 5. Appearance of the distal part of the rectosigmoid flap sutured to the neovaginal outlet.

Flap retraction of 10–15% is expected and a further 2–3 cm flap length should be resected in order to adjust the neovagina to tailor the flap in terms of the position of the pedicle in the proximal and distal position and of fixation to intraoitus as well.

An intra-abdominal low-pressure silicon drain was installed, and the abdomen was closed with the placement of a subcutaneous hemovac drain. Vascular circulation of the flap was checked once a day by monitoring the color of the rectosigmoid neovagina by direct visual observation and also with a small diameter needle puncture to initiate bleeding when required. Patients were given 0.4 ml enoxaparin sodium once a day by subcutaneous injection for the first 2 days for prophylactic purposes, and patients were mobilized at the end of the second day. Cases were started on oral nutrition following spontaneous gas emission (Figures 6–8).

No post-operative neovaginal dilatation was performed or required. In order to prevent purse-string scarring, the inlet of the intraoitus was dissected such as to exceed the diameter of the rectosigmoid colon.

Sexual function was assessed using the Female Sexual Function Index (FSFI) which investigates sexual desire during relations, arousal, lubrication, orgasm, satisfaction and pain [19,20]. A score of 26.5 or more indicates normal sexual function (without any sexual dysfunction), while scores less than 26.5 indicate sexual dysfunction. Patients who had undergone surgery at least 1 year previously, with active sex lives and who volunteered to participate were included. Fifteen out of 43 patients fulfilled these criteria and were evaluated using FSFI.

Results

Vaginal reconstructions with pedicled rectosigmoid colon transfer were performed in 43 patients. The mean age was 29.6 with a

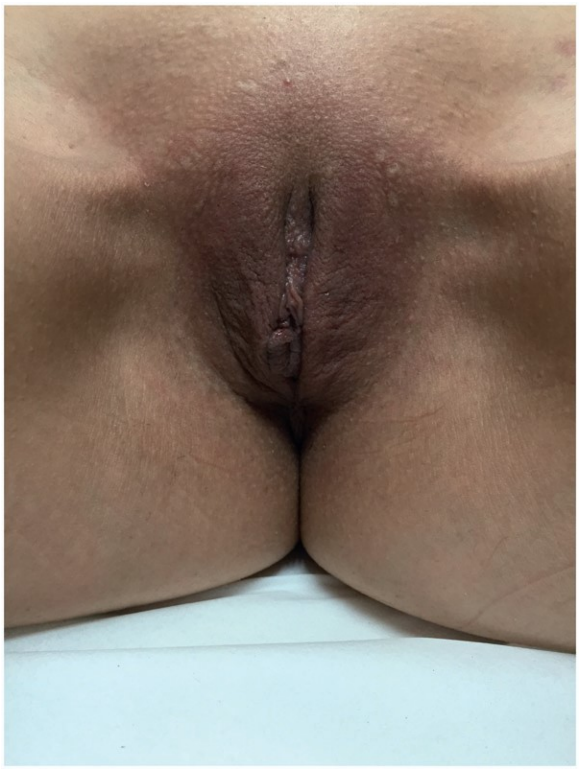

Figure 6. Appearance at 1 year postoperatively.

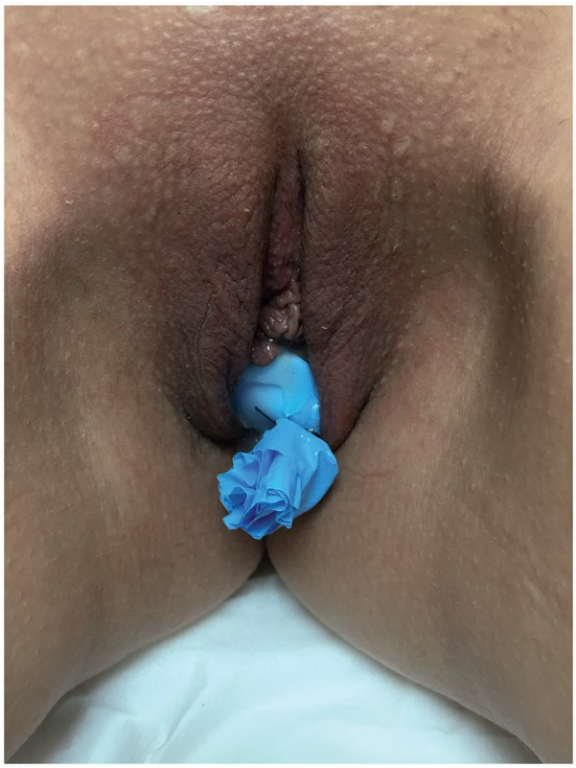

Figure 8. The vaginal prosthesis prepared for the same patient was used in order to show neovaginal depth.

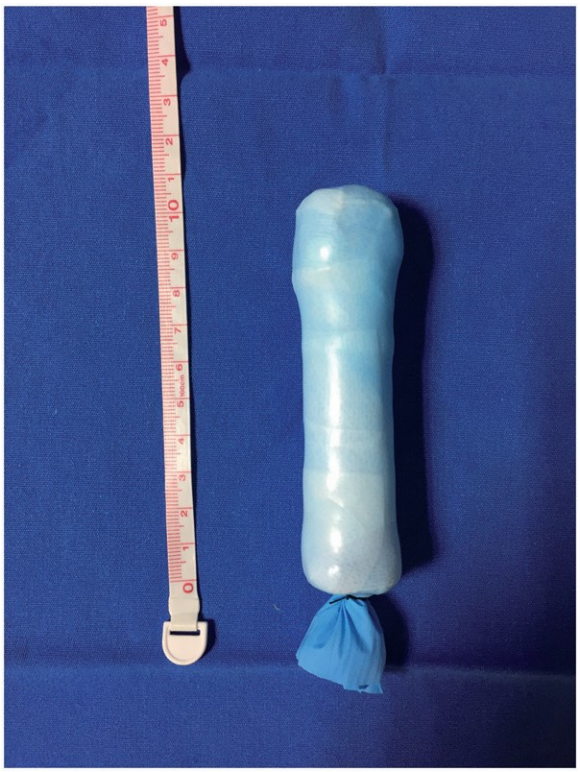

Figure 7. The prepared vaginal prosthesis.

range of 17 and 48 years. The etiology was MRKH syndrome in 34 patients, while nine patients had undergone male to female sex reassignment surgery in other institutions, but adequate vaginal depth had not been achieved. The mean ages (and range) of the transgender and MRKH patients were 40 (24–48) and 26.9 (17–43) years, respectively (Table 1). Development of the ovaries and secondary sex characteristics was normal in all cases of Müllerian agenesis.

A rudimentary uterus was present in all cases of Müllerian agenesis, while a normal uterus and cervical structure were present in one patient with accompanying uterovesical fistula. This patient had regular monthly periods, and in her detailed anamnesis it was revealed that bleeding was accompanied by urination which later proved to be related to a fistula tract between uterus and bladder. This fistula tract was excised intraoperatively. The proximal edge of the rectosigmoid colon was sutured to intact cervical opening and the distal end to intraoitus.

Operations lasted between 3 and 5 h, with a mean duration of 3.7 h. Patients were discharged between 4 and 7 days after surgery, with a mean of 4.4 days. Necrosis occurred in the distal part of the rectosigmoid flap in one patient. Total length of neovagina was 12 cm in this patient. Only the necrotic area was debrided without any intervention to remaining caudal part of the bowel and reconstruction was performed with bilaterally raised local skin flaps. Hematoma was observed beneath the abdominal incision in two patients, and this resolved with conservative treatment. No gastrointestinal or urinary system complications were observed in any patient. The follow-up ranged between 12 and 60 months (mean 38.2 months). No diversion colitis occurred and none of the patients required mucus evacuation follow-up period.

The mean neovaginal length was 11.7 ± 1.2 cm (range 7–13 cm), and the mean width was 3.5 ± 1.3 cm (range 3.1–3.9 cm). Sexual intercourse was satisfactory in all 42 patients (except one patient) at the end of the first postoperative month. The exception was a transgender patient who experienced distal flap necrosis in follow-up.

Good esthetic outcomes were achieved in all cases. All patients were satisfied with the newly created neo-vagina. No request for revision was received from any patient.

The mean score in 15 patients undergoing FSFI assessment was 29.5 (range 18–34.2).

Fourteen of the 15 patients completing the questionnaire scored above 26.5 in those completing the questionnaire. The patient with a low score was the one with distal flap necrosis described in detail above.

Discussion

Numerous techniques including non-surgical methods, minimally invasive methods, skin grafts, local flaps and intestinal flaps have been described to date for vaginal reconstruction [1]. Vaginal reconstruction with intestinal flaps, developed in order to meet these requirements, have successful functional and esthetic outcomes. Reconstructions with intestinal segments are durable, provide a stable vaginal wall and create sufficient vaginal space for sexual relations. Since the intestine is the tissue that most closely resembles the vagina in terms of color and appearance, it provides a natural appearance and this is esthetically superior to other reconstruction techniques. However, these methods all have their own particular disadvantages, depending on the intestinal segment used, as well as common disadvantages, such as requiring a complex surgical procedure and potentially high donor site morbidities and even mortality [15–17].

In our clinic, we had used initially jejunal free flaps for bowel vaginoplasty. Reconstruction with jejunal free flaps gives quite successful functional and esthetic results [18,21–23]. Significant advantages include the need for less resection than other intestinal segments, no need for preoperative intestinal cleansing, a comparatively more sterile surgical field than with distal segments, absence of defecation problems and the fact that another jejunal segment can be taken in the event of failure. The most significant disadvantage is hypersecretion [21–24]. Free transfer of intestinal flaps is thought to lead to less secretion than pedicled transfer since temporary ischemia during flap transfer compromises intestinal secretion functions [18]. In our study of 30 rat jejunums, we observed a decrease in goblet cells proportional to duration of ischemia in intestines subjected to varying periods of ischemia. Similarly, we determined that reperfusion of intestines exposed to ischemia reduced the number of goblet cells associated with reperfusion injury [24]. This information was then reflected in our clinical procedures, and we achieved a decrease in postoperative secretion complaints by subjecting the flap to a further 1 h of ischemia before anastomosis in our reconstructions with jejunal free flaps. However, the technique continued to pose disadvantages such as frequent flap monitoring requirements, difficulty of flap monitoring, prolonged surgery time and the need for a complex surgical procedure. There are some experimental data regarding the use of sigmoid flaps in rat models. Transfer of flaps in rat models altered the secretion characteristics of sigmoid colon in one study [25]. Taking these experimental animal data into account we then changed our policy, in favor of using pedicled rectosigmoid colon flap held in ischemic state.

The advantages of vaginal reconstruction with the rectosigmoid colon include the possibility of using a pedicled flap, provision of sufficient length, no need for a double lumen modification as with the jejunal flap since the lumen is wide, good trauma tolerance due to a thick wall structure, elimination of problems such as contraction and the requisite lubrication being supplied by mucus secretion [26–30]. The technique has been performed in various wide series to date, and good cosmetic results and a satisfactory sex life have been reported. Kwun Kim listed the advantages of rectosigmoid vaginoplasty as follows [27]:

1. No risk of contraction in the reconstructed vagina
2. Maintenance of vaginal width and length without the need for a vaginal stent
3. Presence of mucus secretion to facilitate sexual relations
4. Absence of unpleasant odors frequently reported with skin flaps and
5. A good cosmetic appearance and physical features similar to those of natural vaginal tissue.

Disadvantages include the need for intra-abdominal dissection and defecation problems. The intestinal transfer technique in which defecation problems occur due to distal intestinal segment resection is rectosigmoid colon transposition [26–30]. Tenesmus during sexual relations continues to be a frequently observed, albeit little discussed, problem. This is attributed to neural continuity being maintained inside the pedicled intestinal segment employed. This innervated intestinal segment may cause defecation stimuli associated with contraction during sexual relations. In order to overcome this problem, we used the modification of an enervated rectosigmoid colon segment in vaginal reconstruction. In order to terminate innervation, we excised the nerve fibers inside the pedicle of the raised colon segment. Dissection and excision of nerve fibers inside the pedicle under a microscope and the cauterization of the free ends with the help of bipolar cautery gives good and permanent results by eliminating the possibility of spontaneous regeneration. The point requiring particular care in this method is that since the arteries and veins running through the pedicle are very fine they may be confused with nerve fibers. Dissection must therefore be performed under a microscope or with a well-controlled loop. Another point is the sexual sensation. As the nerve fibers are dissected off the original location, tenesmus could be eliminated but the sensation remains intact. During our clinical observations and regular patient examinations, we also realized the presence of deep and superficial sensation and nociceptive sensation. This may be related to neural sprouting originating from surrounding tissues. Moreover, reinnervation of a transferred muscle tissues by neighboring native muscles, known as muscular neurotization, was reported clinically and experimentally in reconstructive surgical procedures such as lower lip reconstruction with free muscle flaps. The same mechanisms may also apply to sigmoid colon transfers [31,32].

We evaluated sexual outcomes using the FSFI questionnaire in 15 cases. We initially aimed to administer this questionnaire to all patients who had undergone surgery at least 1 year before the study and who had active sex lives, but some declined to respond, probably due to embarrassment or social reasons, and we only assessed 15 cases who were able to give explicit replies to all questions. Questionnaire scores were higher than 26.5 in all but one case, and those 14 patients were evaluated as having no sexual dysfunction. The relatively small proportion of patients responding to FSFI may represent one of the limitations of the current study together with relatively short follow-up time.

As described earlier, in our previous animal study we observed a decrease in goblet cells in intestines of animals subjected to varying periods of ischemia and these findings were extrapolated to our clinical procedures which yielded a decrease in postoperative secretion complaints in our reconstructions with jejunal free flaps. Unfortunately, however, we did not directly take serial biopsies from rectosigmoid neo-vaginas to determine changes in the number of Goblet cells. This may also be a relative drawback of our study.

Since vaginal reconstruction with the rectosigmoid colon requires laparotomy, there are potential risks concerning the

intra-abdominal region and the intestinal anastomosis performed. Minimally invasive methods such as laparoscopic sigmoid vaginoplasty are gaining popularity with all the advantages of endoscopic surgery such as smaller abdominal incisions, shorter hospital stay and less blood loss compared to conventional laparotomy [33]. In one of the largest series consisting of 42 patients, Bouman reported outcomes of transgender women with peno-scrotal hypoplasia undergoing primary total laparoscopic intestinal vaginoplasty [34]. In this prospective study, one patient had a lethal necrotizing fasciitis, three patients required re-laparoscopy for post-operative complications (one with anastomosis-leakage and two with intra-abdominal bleeding) and another patient experienced rectal injury which was handled intraoperatively. Laparoscopic approach seems to be a safe and feasible method for vaginal construction. However, there is no large-scale experience with endoscopic method. Moreover, we did not experience any intra or postoperative complications with laparotomy and its feasibilty has already been well recognized in the published literature [29,35].

Diversion colitis is another complication which could also be rarely observed after bowel vaginoplasty. Colitis could be observed 70–100% after colonic surgery but this complication was rarely reported after bowel vaginoplasties and the actual incidence is unknown [36,37]. In a recent study by van der Sluis, 64% of patients with bowel vaginoplasties presented with mild to moderate findings in colonoscopic follow-up of their bowel neovagina but most of the patients were symptom-free and these findings were only a colonoscopic diagnosis [37]. In a series of 42 transgender patients undergoing total laparoscopic vaginoplasties, two patients experienced mild colitis and required treatment [34]. In our study, we observed no diversion colitis since we did not need to perform routine colonoscopy of the neovagina. In addition, rare complications such as prolapse and development of adenocarcinoma in the vagina have also been reported [35,38]. Although donor site morbidity is potentially high, the relevant requirements for vaginal reconstruction are well met in the recipient site. Outcomes including a robust structure with a plentiful blood supply, long-term preservation of the aperture required for sexual relations, absence of dilation requirements, mucus productions providing lubrication, and a close to natural esthetic appearance are quite promising.

Conclusion

Vaginal reconstruction performed using rectosigmoid colon with nerve excision from the pedicle and temporary ischemia seems to be a reasonable option among several available alternative reconstruction techniques.

Acknowledgements

The authors would like to thank Harun Simsek, Polat Bicici, Seckin Aydın Savas and Kerim Unal for their scientific contributions and also Akdeniz University for their support for this paper.

Disclosure statement

None of the authors have any conflicts of interest to disclose.

References

[1] Ozkan O, Erman Akar M, Ozkan O, et al. Reconstruction of vaginal agenesis. Ann Plast Surg. 2011;66:673–678.

[2] Gollu G, Yildiz RV, Bingol-Kologlu M, et al. Ambiguous genitalia: an overview of 17 years' experience. J Pediatr Surg. 2007;42:840–844.

[3] Sohn M, Bosinski HA. Gender identity disorders: diagnostic and surgical aspects. J Sex Med. 2007;4:1193–1207. quiz 1208.

[4] Templeman CL, Lam AM, Hertweck SP. Surgical management of vaginal agenesis. Obstet Gynecol Surv. 1999;54:583–591.

[5] Mc IA. The treatment of congenital absence and obliterative conditions of the vagina. Br J Plast Surg. 1950; 2:254–267.

[6] Eldor L, Friedman JD. Reconstruction of congenital defects of the vagina. Semin Plast Surg. 2011;25:142–147.

[7] Davydov SN, Zhvitiashvili OD. Formation of vagina (colpopoiesis) from peritoneum of Douglas pouch. Acta Chir Plast. 1974;16:35–41.

[8] Carranza-Lira S, Sauer-Ramirez R, Bolivar-Flores YJ. Neovagina with cultured allogenic epidermal sheets. Eur J Obstet Gynecol Reprod Biol. 1999;82:77–79.

[9] Lin WC, Chang CY, Shen YY, et al. Use of autologous buccal mucosa for vaginoplasty: a study of eight cases. Hum Reprod. 2003;18:604–607.

[10] Small MP. Penile and scrotal inversion vaginoplasty for male to female transsexuals. Urology. 1987;29:593–597.

[11] Namba Y, Sugiyama N, Yamashita S, et al. Vaginoplasty with a pudendal-thigh flap in intersexuals. Acta Med Okayama. 2008;62:415–419.

[12] Morton KE, Davies D, Dewhurst J. The use of the fasciocutaneous flap in vaginal reconstruction. Br J Obstet Gynaecol. 1986;93:970–973.

[13] Williams EA. Vulva-vaginoplasty. Proc R Soc Med. 1970; 63:1046.

[14] Baldwin JF. XIV. The formation of an artificial vagina by intestinal trransplantation. Ann Surg. 1904;40:398–403.

[15] Hensle TW, Shabsigh A, Shabsigh R, et al. Sexual function following bowel vaginoplasty. J Urol. 2006;175:2283–2286.

[16] Schneider W, Nguyen-Thanh P, Dralle H, et al. Ileal J-pouch vaginoplasty: reconstruction of a physiologic vagina with an ileal J-pouch. Am J Obstet Gynecol. 2009;200:694 e1.

[17] Ozkan O, Akar ME, Ozkan O, et al. Microvascular augmented pedicled jejunum transfer for vaginal reconstruction using a laparoscopy-assisted technique. Microsurgery. 2008;28:671–675.

[18] Emiroglu M, Gultan SM, Adanali G, et al. Vaginal reconstruction with free jejunal flap. Ann Plast Surg. 1996;36:316–320.

[19] Rosen R, Brown C, Heiman J, et al. The Female Sexual Function Index (FSFI): a multidimensional self-report instrument for the assessment of female sexual function. J Sex Marital Ther. 2000;26:191–208.

[20] Verit FF, Verit A. Validation of the female sexual function index in women with chronic pelvic pain. J Sex Med. 2007;4:1635–1641.

[21] Sakurai H, Nozaki M, Sasaki K, et al. The use of free jejunal autograft for the treatment of vaginal agenesis: surgical methods and long-term results. Br J Plast Surg. 2000; 53:319–323.

[22] Ozkan O, Akar ME, Ozkan O, et al. The use of vascularized jejunum flap for vaginal reconstruction: clinical experience and results in 22 patients. Microsurgery. 2010;30:125–131.

[23] Erman Akar M, Ozkan O, Ozkan O, et al. Sexual function and long-term results following vaginal reconstruction with free vascular jejunal flap. J Sex Med. 2013;10:2849–2854.

[24] Ozkan O, Ozkan O, Bektas G, et al. The relationship between ischemia time and mucous secretion in vaginal reconstruction with the jejunal free flap: an experimental study on the rat jejunum. Ann Plast Surg. 2015;75:98–101.
[25] Kirpatovsky VI, Tillashajhov MN, Golovanov SA, et al. Comparative analysis of secretory and reabsorbing activity of ileal and sigmoid mucosa, employed for urinary bladder intestinoplasty. Bull Exp Biol Med. 2009;148:785–788.
[26] Yang B, Wang N, Zhang S, et al. Vaginal reconstruction with sigmoid colon in patients with congenital absence of vagina and menses retention: a report of treatment experience in 22 young women. Int Urogynecol J. 2013;24: 155–160.
[27] Kwun Kim S, Hoon Park J, Cheol Lee K, et al. Long-term results in patients after rectosigmoid vaginoplasty. Plast Reconstr Surg. 2003;112:143–151.
[28] Imparato E, Alfei A, Aspesi G, et al. Long-term results of sigmoid vaginoplasty in a consecutive series of 62 patients. Int Urogynecol J Pelvic J. 2007;18:1465–1469.
[29] Djordjevic ML, Stanojevic DS, Bizic MR. Rectosigmoid vaginoplasty: clinical experience and outcomes in 86 cases. J Sex Med. 2011;8:3487–3494.
[30] Hiroi H, Yasugi T, Matsumoto K, et al. Mucinous adenocarcinoma arising in a neovagina using the sigmoid colon thirty years after operation: a case report. J Surg Oncol. 2001;77:61–64.
[31] Must R. Experimental investigation of muscular neurotization in the rat. Muscle Nerve. 1987;10:530–536.
[32] Coskunfirat OK, Bektas G, Cinpolat A, et al. Experiences with functional gracilis muscle flap in lower lip reconstruction. Microsurgery. 2017;37:487–493.
[33] Kohler C, Klemm P, Schau A, et al. Introduction of transperitoneal lymphadenectomy in a gynecologic oncology center: analysis of 650 laparoscopic pelvic and/or paraaortic transperitoneal lymphadenectomies. Gynecol Oncol. 2004; 95:52–61.
[34] Bouman MB, van der Sluis WB, Buncamper ME, et al. Primary total laparoscopic sigmoid vaginoplasty in transgender women with penoscrotal hypoplasia: a prospective cohort study of surgical outcomes and follow-up of 42 patients. Plast Reconstr Surg. 2016;138:614e–623e.
[35] Kim SK, Park JW, Lim KR, et al. Is rectosigmoid vaginoplasty still useful? Arch Plast Surg. 2017;44:48–52.
[36] Whelan RL, Abramson D, Kim DS, et al. Diversion colitis. A prospective study. Surg Endosc. 1994;8:19–24.
[37] van der Sluis WB, Bouman MB, Meijerink W, et al. Diversion neovaginitis after sigmoid vaginoplasty: endoscopic and clinical characteristics. Fertil Steril. 2016;105: 834–839. e1.
[38] Kita Y, Mori S, Baba K, et al. Mucinous adenocarcinoma emerging in sigmoid colon neovagina 40 years after its creation: a case report. World J Surg Onc. 2015;13:213.

Copyright of Journal of Plastic Surgery & Hand Surgery is the property of Taylor & Francis Ltd and its content may not be copied or emailed to multiple sites or posted to a listserv without the copyright holder's express written permission. However, users may print, download, or email articles for individual use.