Int. J. Oral Maxillofac. Surg. 2012; 41: 885–894
http://dx.doi.org/10.1016/j.ijom.2012.04.024, available online at http://www.sciencedirect.com

International Journal of
Oral & Maxillofacial Surgery

Invited Review Paper
Cosmetic Surgery

Facial feminization surgery: current state of the art

K. Altman
Nuffield Health Brighton Hospital, Brighton, UK

K. Altman: Facial feminization surgery: current state of the art. Int. J. Oral Maxillofac. Surg. 2012; 41: 885–894. © 2012 International Association of Oral and Maxillofacial Surgeons. Published by Elsevier Ltd. All rights reserved.

Abstract. Facial feminization surgery (FFS) is a group of surgical procedures; the objectives of which are to change the features of a male face to that of a female face. This surgery does not aim to rejuvenate the face. FFS is carried out almost exclusively on transsexual women (males who are transitioning into females) and who have gender dysphoria. Some non-transsexual women may undergo some feminizing surgical procedures if they feel that they have male facial characteristics. Most transsexual women will have lived in role for sometime and they often undergo FFS before any other form of gender reassignment surgery as it assists them in passing as a female and integrating into everyday society. Various specific facial surgical procedures are utilized to feminize the face, often involving sculpture and contouring of the facial skeleton. These include correction of the hairline by scalp advance, contouring the forehead, brow lift, rhinoplasty, cheek implants, resection of the buccal fat pads of Bichat, lip lift and lip augmentation with dermis graft, mandible angle reduction and taper, genioplasty and thyroid shave. This article discusses the current state of the art in facial feminization surgery.

Keywords: transgender surgery; facial feminization surgery; forehead reduction; thyroid shave; facial contouring.

Accepted for publication 26 April 2012
Available online 6 June 2012

Facial feminization surgery (FFS) is a group of surgical procedures; the aim of which is to change the features of a male face to that of a female face. FFS was originally popularized and pioneered by Dr. Douglas Ousterhout of San Francisco, California, USA in the 1980s and 1990s.

Ousterhout examined several hundred dry skulls in the Atkinson skull collection at the University of San Francisco.[1] Characteristics identified in female and male skulls were identified in female patients demonstrating both male and female forehead features. Treatment protocols were produced based on these differing features and various surgical techniques developed, some of which were also performed in gender female patients who also requested improvement in their forehead contour. These procedures are especially useful in transsexual women in whom the forehead often requires contouring.

Female and male faces are quite different in terms of size and shape, but in feminizing the male face it is important to appreciate that the size of the face has to be in proportion to the rest of the body.[2]

Analysis of the female face demonstrates that it is more heart-shaped or triangular with the base of an inverted triangle being represented by a line drawn between the maximum prominence of each zygoma and the apex of the triangle being represented by the chin point. The female face is softer and more rounded or oval-shaped, with soft, round, curving forms. Male faces are more square and angulated with a strong jaw and chin often with an M-shaped hairline (Fig. 1a and b). The chin and lower jaw is usually longer in the male by as much as 20%[3] and is often, but not always, more prominent in profile.

The male forehead often exhibits significant frontal bossing, which may partly be due to a large frontal sinus, but may also be due to thick supra-orbital ridges. In addition, the angle formed at the glabella between the frontal area of the forehead and nose is often acute as opposed to in the female where it tends to be much more obtuse (Fig. 2).

Female eyebrows are arched, especially in the lateral third area and sit well above the superior orbital rim, while the male

0901-5027/080885 + 010 $36.00/0 © 2012 International Association of Oral and Maxillofacial Surgeons. Published by Elsevier Ltd. All rights reserved.

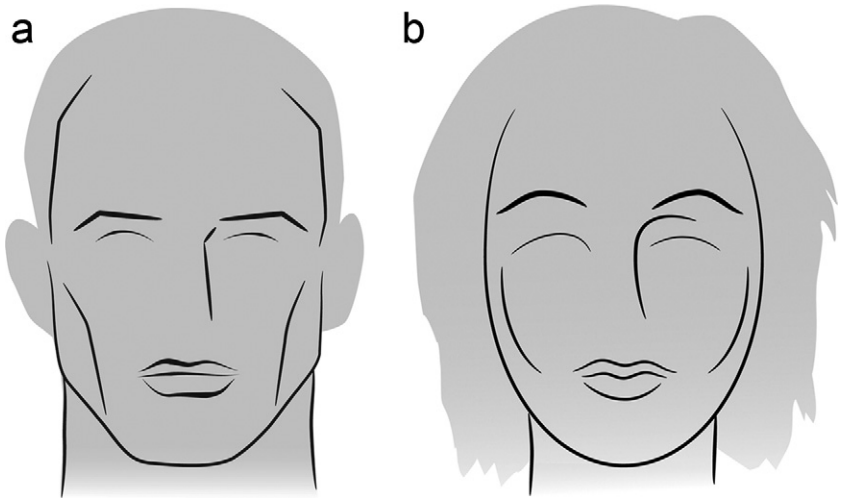

Fig. 1. (a and b) Line illustrations demonstrating the differences between male and female faces. The male face is square and angulated with sharp lines and a strong jaw, while the female face is curved, round, oval and heart-shaped with smooth lines and smaller overall.

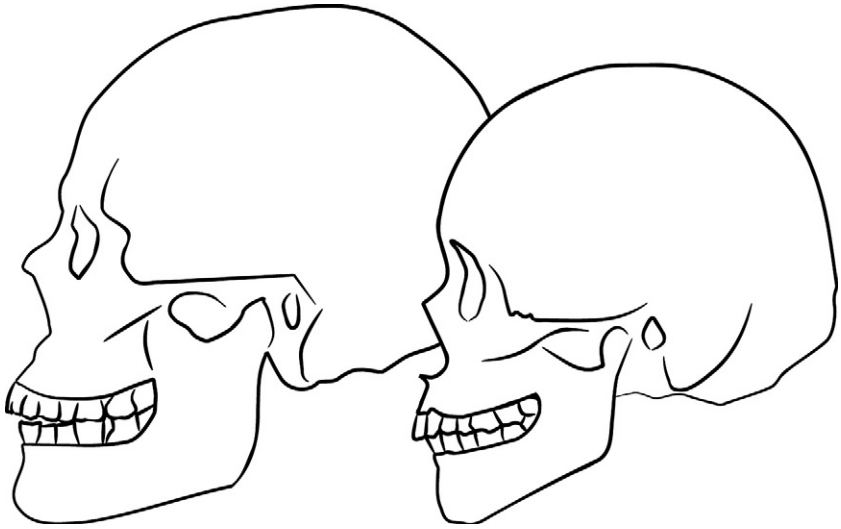

Fig. 2. Differences between male and female foreheads.

eyebrow is straighter and tends to sit at the level of the superior orbital rim.

Female noses are smaller and shorter with narrow bridges and narrow ala bases, often with upturning of the nasal tip giving rise to a more obtuse naso-labial angle.

Male cheeks are flat whereas female cheeks can be quite prominent, being further anterior and higher with some cheek hollowing beneath, which provides further accentuation.

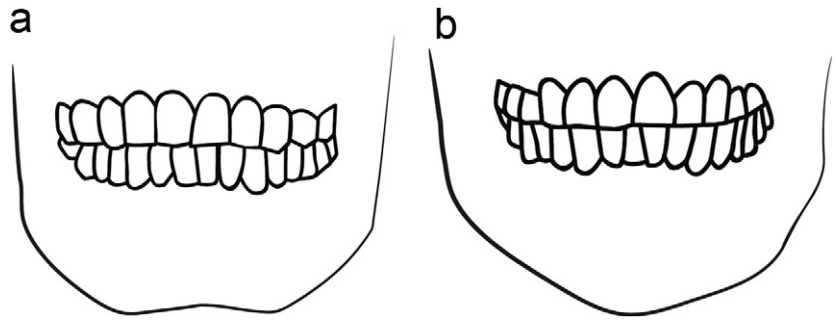

Fig. 3. (a and b) Differences between male and female chins.

Female upper lips are fuller and shorter with good show of the vermillion and a well-formed Cupid's bow. Maxillary tooth show is greater in females due to these features and characteristics.

Male chins are often long, square and angulated as opposed to female chins, which are shorter, narrower and more pointed (Fig. 3a and b).

The male mandible has a prominent angle with lipping of the bone due to the masseter muscle attachments and it is wider than in the female. The external oblique ridge is thick and the masseter muscle is bulkier.

The thyroid cartilage is more prominent in the male and at the notch forms an angle of 90° as opposed to the female where it forms an angle of 120°, which is the reason for it being less pronounced.[4] A prominent thyroid cartilage is an extremely masculine characteristic, hence the popularity of the thyroid shave in this group of individuals.

Surgical procedures

Numerous surgical procedures can feminize the face, including forehead reduction, hairline correction by scalp advance, brow lift, rhinoplasty, cheek implants, resection of the buccal fat pads of Bichat, lip lift and augmentation with dermis graft, genioplasty, angle shave and taper and thyroid shave. For the purposes of this paper only those procedures specific to FFS will be discussed in detail: forehead reduction, scalp advance, cheek implants, buccal fat pad removal, lip lift and dermis graft, genioplasty, angle shave and taper and thyroid shave. Many of these procedures can be undertaken all at once or individually, depending on the facial requirements of the particular patient.

Forehead reduction

Ousterhout analysed several hundred dry skulls for patterns of shape and recognized anthropological features that differentiated the female from the male skull. These differences were compared with patients with different patterns of facial contour. He classified forehead shape and contour into three distinct groups.[1]

Group I has mild to moderate excessive projection of the brow and abnormal bossing. There are no frontal sinuses, or the bone anterior to the frontal sinuses is so thick that its reduction will not compromise the sinus air space. The reduction is

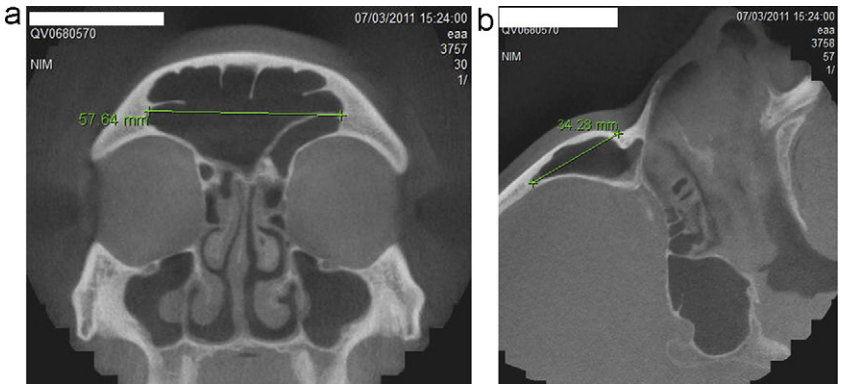

Fig. 4. (a and b) Cone-beam CT scans of frontal sinus showing preoperative planning measurements.

achieved simply with an acrylic burr in order to achieve the desired contour.

In Group II the brows are normal, mildly or moderately projected and there is thick bone anterior to the frontal sinuses. This bone can therefore be reduced as in Group I patients, but may become quite thin. When the bossing is reduced there may be a forehead concavity superior to the bossing, which may require filling with bone cement to feminize this area of the forehead. Ousterhout originally described the use of methylmethacrylate onlay implants in this group of patients.[5] This has now been superseded by the use of bone cement.

Group III patients have excessive brow fullness and the requirement for the anterior table of the frontal sinus to be set back into a more retruded position. The anterior table has to be osteotomized, reshaped and fixed with mini-plate osteosynthesis. Planning is undertaken by use of computerized tomography (CT) scanning or cone-beam CT to measure the dimensions of the sinus precisely to plan the osteotomy cuts (Fig. 4a and b). It must be borne in mind that the frontal sinus is not a symmetrical structure and one side may be larger than the other. In the glabella region the male profile characteristic is of an acute angle formed between the frontal sinus anterior wall and dorsum of the nose. This must be reduced to a more oblique angle to feminize this area of the face adequately. Therefore, for Group III cases, it is essential to osteotomize the inferior aspect of the anterior table of the frontal sinus precisely at the glabella and immediately above the radix area of the nose. In the author's experience, this group of patients forms the majority of cases requiring forehead contouring.

In all cases access is via a coronal flap. The main decision in terms of flap design is if a scalp advance to correct the hairline is required. If it is not, then a standard coronal incision is made in a 'stealth' fashion to disguise the resulting scalp scar. In patients requiring hairline correction a trichophytic[6,7] incision (as opposed to a pre-trichial incision) is made tangentially through the hair follicles 4–5 mm behind the hairline that will encourage hair growth through the resulting scar (Fig. 5a and b). The incision follows the temporal hairline, which often requires advancement and then runs in a posterior direction into the hair-bearing area and down towards the ears. The hair is not shaved in this group of patients, but is simply parted in the temple areas and tied up in bunches.

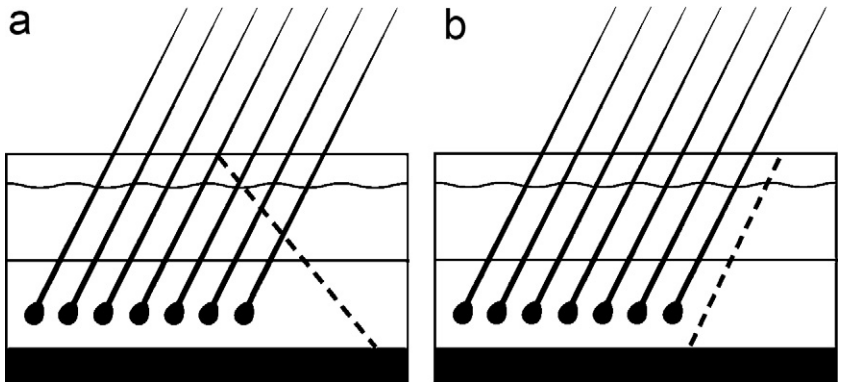

Fig. 5. (a) Trichophytic incision; note relationship of tangential incision to hair follicles. (b) Pre-trichial incision; note relationship of parallel incision to hair follicles.

Standard tumescent solution is injected into the scalp and the flap raised avoiding injury to the frontal branches of the facial nerve. The dissection proceeds in the subperiosteal plane approximately 4–5 cm superior to the glabella and the entire frontal area down to the glabella is exposed including the frontal processes of the zygomas and the superior orbital rims, dissecting 1 cm into the roof of each orbit. At this point in the dissection the supra-orbital nerves may need to be dissected or osteotomized out of their foramina in order to expose the entire superior orbital rims.

In Group I and II cases, extensive reduction of the bossing, including the frontal processes of the zygomas with an acrylic trimming burr on a fast motor is all that is required, but the addition of bone cement may be required in Group II cases. The lateral superior orbital rims are contoured to reduce any bony infringement and to expand the orbital perimeter.[8]

Group III cases all require osteotomy of the anterior table of the frontal sinus. The dimensions of the anterior table cuts are marked out on the bone from the known CT scan measurements, taking into account any asymmetry of the sinus. The cuts are made with a Toller fissure burr or sagittal saw inclined obliquely at an angle greater than 45° to the bone surface and facing towards the sinus at all times in order to ensure correct positioning. Once the cuts are completed, a fine osteotome is used to separate the anterior table from the forehead, with great care being taken not to fracture the bone plate.

The frontal sinus cavity is inspected and the lining preserved though the lining of the sinus is always torn in lifting out the bone plate, which is of no consequence. Bony septa on the inside of the anterior table are trimmed as are septa within the sinus cavity. All bone debris is thoroughly washed out with saline irrigation.

The anterior table is replaced with its inferior aspect placed into a retruded position in a 'tongue-and-groove' fashion, which very effectively eradicates the frontal bossing. The surrounding bone is contoured, but a precise fit is not required as steps or deficiencies cannot be appreciated on palpation via the scalp. On occasion the anterior table will itself need

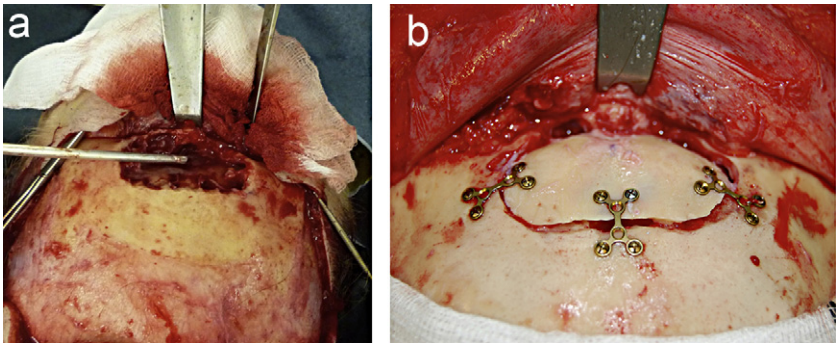

Fig. 6. Forehead III. Intraoperative photograph demonstrating (a) anterior table removed and underlying frontal sinus and (b) inset anterior table after preparation and fixation.

to be osteotomized transversely as the superior edge can otherwise protrude too far when the anterior table plate of bone is particularly large.[9]

Fixation is by means of titanium 1.3 mm mini-plate osteosynthesis using three X-shaped plates to stabilize the bone plate (Fig. 6a and b).

All groups of patients undergo orbital rim contouring in which the outer third of the superior orbital rim is reduced to increase the dimensions of the anterior orbital rim.[8]

Some authors advocate preservation of the periosteum overlying the anterior table bone plate and carrying out the dissection in the sub-galeal plane. While this will not aid in the revascularization of the bone plate, it is useful in employing a compression technique to flatten the bone plate rather than osteotomizing it and in so doing the periosteum adheres to the bone fragments, maintaining continuity. Preservation of the overlying periosteum also assists in fixation of the bone plate with sutures instead of mini-plate osteosynthesis.[10]

Appropriate postoperative antibiotics are prescribed. Patients are instructed not to blow their nose for 10 days postoperatively, otherwise air may be introduced into the frontal sinus leading to surgical emphysema and possible infection.

Scalp closure will be discussed under the section on scalp advance though the periosteum in forehead reduction cases is sutured back over the bone plate with 3/0 Vicryl Rapide suture (Ethicon Inc, Somerville, NJ, USA) to aid in revascularization.

Complications of the forehead reduction procedure include damage to the supra-orbital nerves causing scalp anaesthesia. Very rarely, the frontal branches of the facial nerves may be injured resulting in frontalis weakness or paralysis. Rarely, frontal sinus infection may occur. Eyelid bruising and oedema along with chemosis are common, but are temporary. The feared complication of total loss of the anterior table due to bone resorption or infection seems to pose negligible risk.

Brow-lift

Brow lifting is undertaken to raise the eyebrows to a more feminine position. The female brow is located above the supra-orbital ridge, whereas the male brow is at the level of the ridge. Elevating the brow opens up and freshens the eyes and significantly feminizes this area. In conjunction with orbital rim contouring, this is very effective. Upper lid blepharoplasty may complement this procedure.

The procedure is carried out via the coronal access for the forehead reduction procedure. Two bone bridges are drilled into the cranial vault a few centimetres superior to each brow and a size 0 Ethibond suture (Ethicon Inc., Somerville, NJ, USA) is secured to the dermis at a point one-third of the distance from the outer aspect of the brow. This is done using a large venous cannula introduced through the skin of the brow to the underside of the coronal flap The suture, having been secured under the bone bridge, is fed down the cannula needle and the cannula is then withdrawn to the dermis and reinserted at the same time picking up the dermis of the eyebrow. The suture is removed from the cannula needle and tension applied to ensure that the brow elevates and once confirmed the suture is tied with maximum tension tying a few secure knots in the knowledge that the brow will descend to a degree up to a few months postoperatively. Descent of the lift occurs because, over time, the suture causes the underlying bone of the convex shaped forehead it is in contact with to undergo resorption resulting in loss of tension in the suture.

The tight pull of the suture may cause some initial dimpling of the eyebrow at the site of insertion, but this is temporary due to future loss of height of the lift with some brow descent. Postoperative massage of the area is useful.

Scalp advance

A scalp advance may be required for male pattern temporal recession or a high forehead hairline.[6,7] It is important to assess scalp laxity to assess how far the scalp may be advanced. Tight scalps can be difficult to mobilize and may require more than one operative procedure to attain the desired amount of advancement. Further scalp advancement surgery if required is undertaken no sooner than a few months after the initial procedure.

Patients are also counselled that significant temporal recession may require hair transplantation. Hair transplantation, if required, should not be considered until a few months after the scalp advancement. For patients wearing hair-pieces with thin hair and who will continue to do so, scalp advance is clearly not required.

For scalp advancement, the hair is cleaned and parted or tied up in bunches with elastics. No hair is shaved. Standard tumescent solution is injected into the scalp and frontal skin. A trichophytic incision[6,7] is employed, bevelling the incision tangentially through the hair follicles and including the most anterior 2–3 follicular units. The incision is placed approximately 4–5 mm posterior to the hairline. The trichophytic incision aids re-growth of hair through the resulting scar, which gives an improved final aesthetic result. An incision in the temporal area is made parallel to the hair shafts and 2 cm posterior to the central attachment of the upper pole of the ear, where the hair grows in a posterior direction on both sides of the incision. Just above the ear, there is a transition zone in the direction of hair growth. Incisions and scalp excision in the transitional hair growth zone will create a parting of the hair and visibility of the scar whereas in the parallel growth zone more posterior they leave a well-hidden scar.[11] If the patient has a significant 'widow's peak' this is excised and not advanced. The scalp is raised in the subgaleal plane and with care Rainey clips do not need to be employed as they can traumatize the scalp edges by crushing. Haemostats are used on the posterior galeal free edge to aid in securing haemostasis during the procedure.

The scalp is undermined extensively back to the occiput and it is necessary to perform several parallel galeotomies whereby incisions are made just through the galea until the underlying scalp fat is

seen. In this way, the blood supply to the scalp flap is not compromised. Each incision in the galea results in 1–2 mm of scalp flap expansion.[6] Cats paw-type retractors are placed under the coronal flap and pulled for a few minutes to allow creep and advancement of the scalp. At this point the amount of forehead skin to be excised is determined prior to suturing, again using a bevelled incision to match that of the original scalp incision.

Vacuum drains are brought out above the ear through the posterior scalp flap on each side. They are tunnelled under a pericranial bridge to prevent migration and being potentially impaled by the scalp clips preventing their removal.[12] The galea is not sutured and 5/0 monofilament is used for the exposed part of the scalp incision while clips are used for those areas within the hairline. It is essential that the scalp is not sutured under tension. A head bandage is placed for 24 h and the vacuum drains removed at 48 h. After drain removal, normal hair washing may take place. Sutures and clips are removed at 7–10 days.

Patients are advised of potential complications including, thickened or stretched scar and telogen effluvium (acute hair loss).[7] The latter is more of a risk in thin scalps where the blood supply may be more tenuous. Patients may report finding more hair in their hair brush, but spontaneous recovery may be expected after 6 months.

Rhinoplasty

In cases requiring female feminizing surgery, the objectives are to perform a feminizing rhinoplasty (endonasal or open). In most cases it is necessary to reduce any dorsal hump and to narrow the nasal bridge by in-fracture of the nasal bones. The dorsum can remain straight in the female nose, but some individuals may request more curvature to the dorsum or a retroussé nose. Large nostrils can be reduced by skin excision at the nasal sill. It must be appreciated that the nose must fit the face, in the sense that a small nose will not look harmonious or in place on a large face however well it has been feminized. Importantly, rhinoplasty is often combined with forehead reduction in order to reduce the acute angle seen in profile between the frontal sinus bossing and the take-off angle of the nose in the male.

The general and specific complications of rhinoplasty are well covered in standard

Fig. 7. (a and b) Preoperative frontal and profile views prior to forehead III, brow lift, scalp advance, rhinoplasty, lip lift, lip dermis graft, angle shave and genioplasty. (c and d) Postoperative views of patient 1 month postoperatively.

Fig. 8. (a and b) Preoperative frontal and profile views prior to forehead III, brow lift, scalp advance, rhinoplasty, cheek implants, lip lift, angle shave, genioplasty and thyroid shave. (c and d) Postoperative views 3 months postoperatively.

texts on the subject. The standard rhinoplasty technique required for FFS cases will not be described further. If the open rhinoplasty technique is employed in conjunction with a lip lift, then the columnella skin flap can alternatively be raised from the nasal sill to incorporate the lip lift skin excision rather than from the normal mid-columnella area. Figures 7–9 show three patients who all had forehead III and rhinoplasty, including other procedures as part of their FFS.

Cheek implants

Augmentation of the cheeks is paramount in certain cases. Triangulation between the points of the cheeks and the chin, where the chin point forms the apex of the triangle and a line drawn between the lateral points of the cheeks forms the base of the triangle, gives a feminizing look to the lower two thirds of the face. This can be effectively achieved by augmenting the cheeks with implants.[13]

Medpor® (Stryker Corporation, Newnan, GA, USA) high-density polyethylene implants are useful and a few different malar shapes and sizes are available; they are easy to insert via the mouth. Silicone sizers are available to ensure the correct size is used before opening individual packs and the implants can be carved if desired. Following infiltration of local anaesthetic an adequately sized pocket must be dissected prior to placement including along the zygomatic arches to ensure the implants sit passively against the underlying bone. Achieving symmetry of the implants can be challenging. Once the operator is satisfied with the aesthetic appearance and fit, the implants, having been immersed in suitable antibiotic solution prior to insertion, are screwed into the underlying bone with two 2.0 mm titanium screws of at least 6.0 mm length each side to prevent migration and rotation. At the same time as providing cheek augmentation, cheek implants provide some degree of malar fat pad lifting.

Some surgeons advocate excision of the buccal fat pads of Bichat at the same time as cheek implants or as a separate procedure to hollow the sub-malar area. While the concept of buccal fat pad removal is understandable, in the author's experience this procedure is of limited benefit in producing the desired effect. The oral mucosa is closed with 3/0 Vicryl Rapide suture (Ethicon Inc.).

Complications of placing cheek implants include wrong size, asymmetry and positioning. Caution should be taken in individuals with thin skin in whom cheek implants, however well positioned, may look unsightly. On occasion the feathered edge of the implant overlying the zygomatic arch may appear prominent and require correction. Infection, while rare, may necessitate removal. Implants may migrate if they are not secured adequately. Anaesthesia in the distribution of the infraorbital nerves, which in most cases is temporary, may occur.

Fig. 9. (a and b) Preoperative frontal and profile views prior to forehead III, brow lift, scalp advance, rhinoplasty, lip lift, lip dermis graft and thyroid shave. (c and d) Postoperative views 3 months postoperatively.

Lip lift and dermis graft

Lip lift is commonly used in feminization of the face. Its aim is to shorten the lip in the area between the ala bases of the nose so the individual shows more of the maxillary tooth crowns. Additionally, the lip profile often changes in that a flat, long lip takes on a more curled appearance afterwards.

Following local anaesthesia, the procedure is accomplished by excising a premeasured ellipse of skin immediately adjacent to the nasal sill and between the ala bases, ensuring that the incision does not extend beyond this point in order for the resulting scar to be acceptable. The width of the ellipse depends on the amount of lip shortening required, but it is important not to over-resect and generally no more than 25% of the overall height of the lip from nasal sill to vermillion border is excised. Following bipolar cautery, the wound is sutured with 5/0 monofilament.

Dermis graft is used to plump up the vermillion border of the upper lip. The dermis may be harvested from the coronal flap and is tunnelled into the lip via three small incisions in the lip mucosa, two at the commissures and one in the midline. These are sutured with 3/0 Vicryl Rapide (Ethicon Inc.).

This procedure has few complications. Initially, lip swelling may be significant for a few days. If adequate care is not taken, it is possible to over- or under-excise the lip skin, giving a poor aesthetic result. Under-resection can easily be corrected by a further procedure. Rarely, wound breakdown can occur or the dermis graft can become infected.

Mandible angle shave and taper

An angulated mandible is an extremely masculine feature of the face and so in many cases the mandible needs to be contoured. The specific mandibular masculine features include a prominent, sharp mandibular angle. The angle is often too square and the lipping and associated masseter bulk lead to additional width to the mandible.[14]

Local anaesthetic is given and the procedure is performed via the mouth through an incision from high on the external oblique ridge to the first molar area. The entire angle and body of the mandible is widely exposed with great care being taken to strip off the pterygo-masseteric attachments completely at the lower border. It is essential to expose the entire lower border of the body, angle and ramus, as this manoeuvre protects against bleeding from inadvertent muscle damage by the drill.

Good retraction is vital. The cortical bone is significantly reduced, often exposing cancellous bone, with a high speed acrylic burr to reduce the prominence of the angle and external oblique ridge up to the mental foramen (Fig. 10a and b). Care must be taken not to expose tooth roots in the molar region and not to expose the

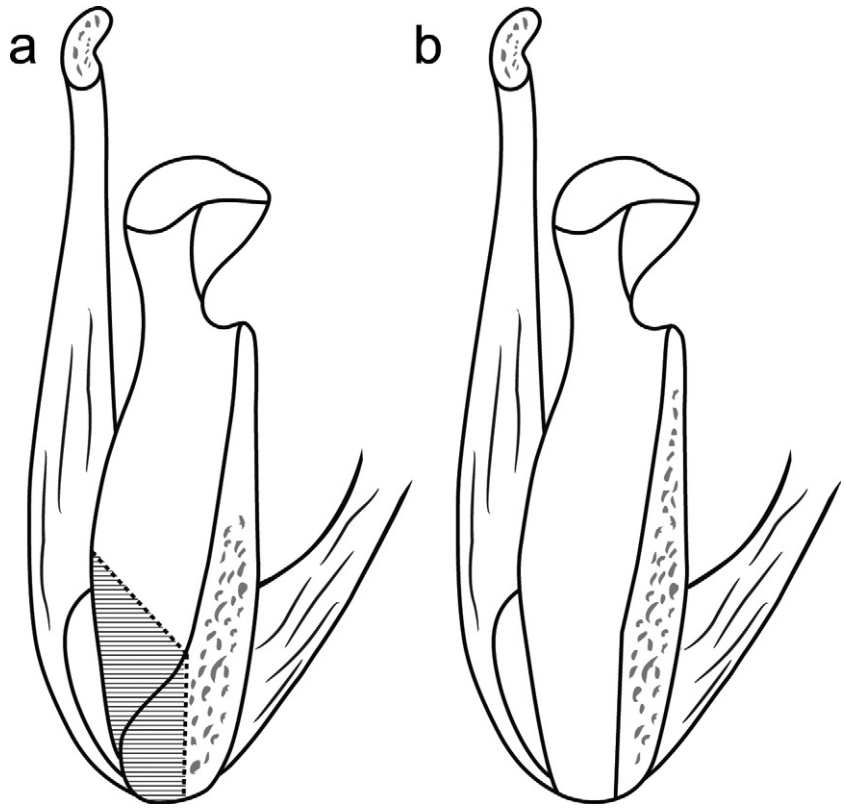

Fig. 10. (a and b) Angle shave by reducing the lipping at the mandibular angle and subsequent result (shading indicates area to be contoured).

inferior dental canal and as a consequence damage the inferior dental nerve.

When there is a significant mandibular angle present, the angle is osteotomized with reciprocating and oscillating saws to give this area a more rounded and softer appearance[15] (Fig. 11). This is a difficult procedure due to the limited access and visual appreciation of the cuts being made. Once the cut is made adequately with the saw the osteotomy is completed with a curved osteotome. This often results in the fragment to be removed springing medially due to its retained medial pterygoid muscle attachments. The fragment is retrieved by external digital pressure to redeliver it back to the buccal side of the mandible where it can be easily detached from the muscle and removed. Finally the lower border is smoothed off with the drill. Further width reduction, if desired, can be gained by antero-medial masseter muscle resection.[14,16] Masseteric atrophy is thought likely to occur as a result of the mandibular angle reduction,[14] which is a favourable effect and has been demonstrated in patients undergoing mandibular angle sagittal split osteotomy.[17]

Meticulous haemostasis is required and Yeates drains are placed internally without suturing and removed at 24 h. The mucosa is closed with 3/0 Vicryl Rapide sutures (Ethicon Inc.). External pressure may need to be employed in certain cases.

Patients may experience significant pain, swelling and bruising from this procedure. The initial swelling lasts for 2–3 weeks, but full resolution may not occur for at least 6 months. Inferior dental nerve sensory disturbance may result, but this is often temporary if it occurs at all. In addition, the marginal branch of the facial nerve may suffer from temporary palsy due to the retraction used during the procedure. Wound healing can be protracted and may lead to food accumulation in the cheeks and significant scar banding.

Genioplasty

The objectives of a feminizing genioplasty are to narrow an angulated masculine chin. It is often necessary to shorten the chin area vertically at the same time as narrowing it.[3] Chin osteotomies generally give far superior results than contouring the chin area.

Following local anaesthesia, a labial sulcus incision is made with subperiosteal dissection to expose the chin and lower border of the mandible to the first molar area. This procedure is often combined with an angle shave. The mental nerves are identified and protected. A reciprocating saw is used to make the osteotomy cuts to the lower border of the mandible in the first molar area. The vertical chin reduction, if required, is carried out by removing a pre-determined segment of bone depending on how much decrease in height is required.

In order to narrow the chin a mid-line block of pre-determined width is osteotomized and removed. The two remaining fragments of the chin are brought together in the midline and secured with a 1.3 mm X-shaped titanium mini-plate and two further 3-hole miniplates laterally to stabilize the fragments (Fig. 12a and b). If desired, the chin width posteriorly can be

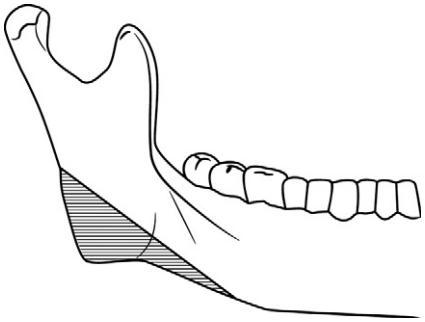

Fig. 11. Angle shave and osteotomy cuts to the angle of the mandible (shading).

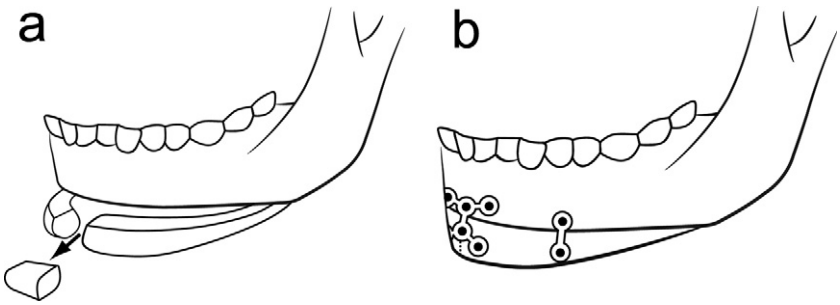

Fig. 12. (a and b) Chin width reduction and fixation.

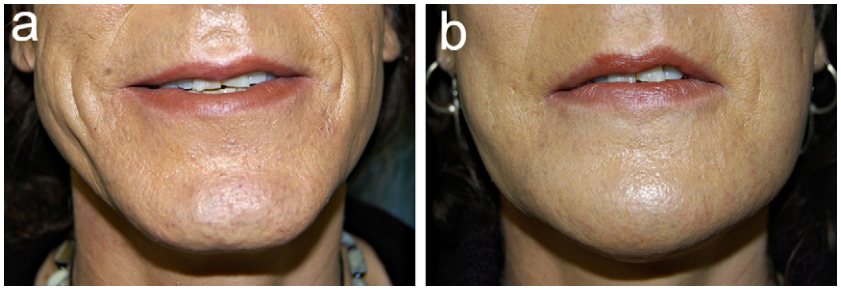

Fig. 13. (a) Preoperative photograph of angulated and wide chin. (b) Postoperative photograph 3 months postoperatively.

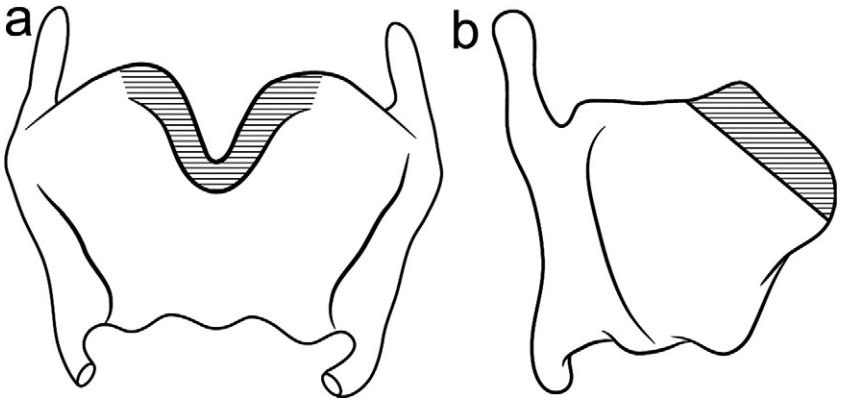

Fig. 14. (a and b) Thyroid cartilage, demonstrating the areas of resection in thyroid shave (shading).

further narrowed by fixing the tail ends of the genioplasty fragments in a more medial position. Closure of the mentalis muscle and mucosa is with 3/0 Vicryl Rapide suture (Ethicon Inc.) (Fig. 13a and b).

Complications of genioplasty include pain, swelling, bruising and sensory disturbance of the lip and chin area.

Thyroid shave (chondrolaryngoplasty)

The male thyroid cartilage is generally larger than that of the female and the laryngeal prominence, which is formed by the fusion of the anterior borders of the two thyroid cartilage laminae which diverge at an angle of approximately 90° in the male and 120° in the female where it is much less prominent.[4] In order to feminize the thyroid cartilage, the laryngeal prominence must be reduced in size to give it a more obtuse and softer angulation.

The approach to the cartilage is via a superiorly based 2 cm transverse neck incision in a suitable skin crease, based as high up as possible. To assess placement of the incision, the skin is gathered up inferiorly to the thyroid notch, which gives a good indication of accessibility to the notch and prominence following incision and dissection. Following local anaesthesia and mid-line dissection to the thyroid cartilage notch area, the laryngeal prominence is exposed. Using suitable retraction, the perichondrium is incised and dissected off to expose the laryngeal prominence and notch area. Care is taken to avoid entering the thyrohyoid membrane.[18] Rongeurs are used to nibble away the prominence and the superior aspects of the laminae until a satisfactory reduction and appearance is achieved (Fig. 14a and b). In the older individual, the thyroid cartilage is often ossified rather than cartilaginous and may require reduction taking great care with a small acrylic trimming burr.

At the end of the procedure, the perichondrium may be approximated with a 5/0 mono-filament resorbable suture along with a layered subcutaneous closure using 4/0 Vicryl Rapide (Ethicon Inc.) and a 3/0 mono-filament subcuticular suture, which is removed at 1 week. Drainage is not required (Fig. 15a and b).

Complications, though highly unusual, can include damage to the vocal cords and destabilization of the epiglottis. These rarely occur and are only possible if dissection has taken place on the inside of the thyroid laminae and when the perichondrium and the thyrohyoid membrane have been elevated beyond the level of the thyroepiglottic ligament. In most cases this dissection is not required.

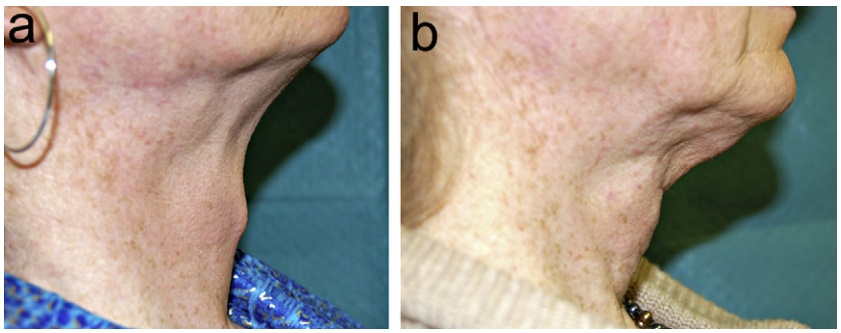

Fig. 15. (a) Preoperative profile view of thyroid shave. (b) Postoperative view 3 months postoperatively.

Discussion

FFS brings together a broad range of cranio-maxillofacial surgical procedures and techniques with the sole objective of converting a masculine face to a more feminine one. There is no attempt to convert the face into that of a fashion model as all that is usually desired by the individual is to pass as a female in everyday society and to integrate as well as possible into the community.

This can often be confounded by the general build and demeanour of the individual, with regard to how they dress and make up along with their poise and movements. Some individuals have voice coaching, while others have surgery to increase the pitch of their voice.

Ousterhout was the pioneer of FFS. He carried out anthropological studies on several hundred dried skulls at the Atkinson skull collection at the University of San Francisco identifying specific features and characteristics that differentiated male from female human skulls.[1] His findings permitted the development of surgical

techniques that were able to target those areas of the human skull and face that could be contoured in order to adequately feminize individuals undergoing these types of procedures.

Most transgender females presenting themselves for FFS have usually lived in role for a good period of time (so-called real life experience) and almost all are referred from physicians with specific experience in managing transgender patients. This surgery is not undertaken lightly. The author normally sees patients for a few consultations before surgery is undertaken. All patients are photographed and detailed informed consent for the procedures is taken.

It is especially important to warn these patients of temporary hair loss from scalp advance and hairline scarring along with long term swelling of the jaw line. Patients with a good head of hair will regard this as their most feminizing feature and so temporary hair loss will cause significant distress.[6]

It is entirely normal that these patients have their FFS before other surgical procedures, for example breast augmentation and gender reassignment surgery, because they need to integrate as women in everyday society and their facial appearance is essential for them to pass.

Most transgender patients take various hormones, including oestrogens such as estradiol, gonadorelin analogues and antiandrogens such as cyproterone. Spironolactone is often prescribed for its testosterone suppressant properties. Hormone medication is not stopped for patients undergoing FFS, but full venous thromboembolism assessment and prophylaxis is given for the procedure.

In terms of clinical effectiveness, there are no large studies looking at this aspect of care, but the author's experience suggests that patient satisfaction is generally high following these procedures.

Patients in the UK generally fund their FFS but certain health authorities may agree to fund this type of surgery if certain conditions are satisfied.

Many transgender women are very well educated and informed about FFS but some are not aware of the facial procedures available to them to aid in their transition. It behoves the medical profession, both in primary and secondary care settings, when caring for transgender women to be aware that FFS is available so that appropriate counselling, advice and referral is made when required.

The future of FFS depends on further development of the procedures currently undertaken and possible changes in approaches to funding. For public funding to become available, clinical effectiveness will have to be audited and presented to health authorities to justify the health gain and requirement for patients undergoing this type of surgery.

Conflict of interest

None declared.

Funding

None.

Ethical approval

Not required.

Acknowledgements. The author is grateful to Dr. Frans Noorman van der Dussen, Antwerp for mentoring him in the techniques of facial feminization surgery. He is also grateful to Jessica Turvey of the Clinical Media Centre, Brighton & Sussex University Hospitals NHS Trust for her work on the illustrations.

References

1. Ousterhout DK. Feminization of the forehead: contour changing to improve female aesthetics. *Plast Reconstr Surg* 1987;**79**: 701–11.
2. Kolar JC. Anthropological guidelines for aesthetic craniofacial surgery. In: Ousterhout DK, editor. *Aesthetic contouring of the craniofacial skeleton*. Boston/Toronto/London: Little, Brown and Company; 1991. p. 20–1.
3. Ousterhout DK, Feminization of the chin: a review of 485 consecutive cases.Salyer K, editor. *Craniofacial surgery*, vol. 10. Bologna, Italy: Medimond International Proceedings; 2003. p. 461–3.
4. Warwick R, Williams PL. *Gray's anatomy.* 35th ed. Edinburgh: Longman; 1973. p. 1174.
5. Ousterhout DK, Zlotolow IM. Aesthetic improvement of the forehead utilizing methylmethacrylate onlay implants. *Aesth Plast Surg* 1990;**14**:281–6.
6. Marten TJ. Hairline lowering during foreheadoplasty. *Plast Reconstr Surg* 1999;**103**: 224–36.
7. Ramirez AL, Ende KH, Kabaker SS. Correction of the high female hairline. *Arch Facial Plast Surg* 2009;**11**:84–90.
8. Flowers RS. Orbital rim contouring. In: Ousterhout DK, editor. *Aesthetic contouring of the craniofacial skeleton*. Boston/Toronto/London: Little, Brown and Company; 1991. p. 243–56.
9. Komuro Y, Nishida M, Imazawa T, Koga Y, Yanai A. Combined frontal bone reshaping and forehead lift for frontal sinus hypertrophy. *Aesth Plast Surg* 1999;**23**:361–3.
10. Rehman K-U, Johnston C, Monaghan A, Dover S. Management of the giant frontal sinus – a simple method to improve cosmesis. *Br J Oral Maxillofac Surg* 2009;**47**:54–5.
11. Flowers RS, Ceydeli A. The open coronal approach to forehead rejuvenation. *Clin Plast Surg* 2008;**35**:331–51.
12. Hodges S, Altman K. Simple manoeuvre to help stabilize drains when closing a coronal flap. *Br J Oral Maxillofac Surg* 2009;**47**:162.
13. Binder WJ. Submalar augmentation: An alloplastic method for aesthetic contouring of the midface. In: Ousterhout DK, editor. *Aesthetic contouring of the craniofacial skeleton*. Boston/Toronto/London: Little, Brown and Company; 1991. p. 347–70.
14. Ousterhout DK, Feminization of the mandibular body: a review of 688 consecutive cases.David DJ, editor. *Craniofacial surgery*, vol. 11. Bologna, Italy: Medimond International Proceedings; 2005. p. 135–7.
15. Chen X, Lin J, Shen J, Zhou Y, Wu X, Xu Y. Modification of square face in men. *Arch Facial Plast Surg* 2011;**13**:244–6.
16. Lorenz HP, Schendel SA, Facial bone sculpturing.Ward Booth P, Hausamen J-E, Schendel SA, editors. *Maxillofacial Surgery*, Vol. I. London: Churchill Livingstone; 1999. p. 1441–56.
17. Chai G, Zhang Y, Zhu M, Xiaofei M, Zheyuan Y, Xiongzheng M, et al. Evaluation of dynamic morphologic changes in the masseter muscle in patients undergoing mandibular angle sagittal split osteotomy: a report of 130 cases. *Arch Facial Plast Surg* 2011;**13**:301–4.
18. Wolfort FG, Dejerine ES, Ramos DJ, Parry RG. Chondrolaryngoplasty for appearance. *Plast Reconstr Surg* 1990;**86**:464–9.

Address:
Keith Altman
Nuffield Health Brighton Hospital
Warren Road
Woodingdean
BN2 6DX
UK
Tel.: +44 1273 627055
fax: +44 1273 627029
E-mail: keithaltman@oralsurgeons.plus.com