Cheek Augmentation Techniques

David M. Whitehead, MD, MS[a], Loren S. Schechter, MD, FACS[b,*]

KEYWORDS

• Cheek augmentation • Midface • Facial feminization • FFS • Filler • Fat grafting • Facial implant • Gender

KEY POINTS

- Sexual dimorphism of the lateral midface is primarily related to differences in the soft tissue rather than the underlying facial skeleton, and these soft tissue differences may be under hormonal control.
- Cheek augmentation can provide feminization by restoring youthful volume distribution within the aging midface.
- Surgical techniques can be directed at age-related changes in the facial skeleton, overlying soft tissue (eg, fat pads, fascia, skin), or both.
- Nonsurgical techniques can be used in isolation or in combination with surgical techniques.
- Caution should be exercised to avoid an "overfilled" appearance.

INTRODUCTION

Traditionally, gender-confirming procedures have focused on the breast and genitalia; however, the ability to socially transition may be most influenced by the face. Testosterone exposure leads to specific changes in the face within both the facial skeleton and overlying soft tissues. Facial feminization aims to reverse these changes, whether through surgical, nonsurgical (eg, injectables, skin-resurfacing), or nonmedical interventions (eg, cosmetics, hairpieces). Interventions include the goal of both reducing masculine features as well as providing a feminine appearance to the face. Distinct from feminizing procedures are those pertaining to rejuvenation. These interventions are aimed at reducing the effects of facial aging and may or may not be gender-specific.

The cheek encompasses the maxillary and zygomatic bones, as well as their overlying soft tissues, including the paranasal soft tissues. A feminine cheek is classically described as having higher and more prominent "cheekbones." Despite the use of the word "bones" in that term, it generally is used to refer to appearance of the soft tissues overlying the skeletal structures that make up the cheeks.

Several studies have sought to evaluate differences in the bony anatomy between male and female human faces (the terms male and female refer to individuals assigned to that sex at birth who subsequently underwent development into adulthood without the influence of exogenous hormones or an intersex state). An early cephalometric study demonstrated no significant difference in anterior bony malar projection between male and female participants,[1] represented by sella-nasion-orbitale (SNO) angle for the upper malar complex and pterygomaxillary vertical

Disclosures: Neither Dr D.M. Whitehead nor Dr L.S. Schechter (royalties from Elsevier publishing) have any financial conflicts of interest to declare.

[a] Division of Plastic Surgery, Department of Surgery, Northwell Health, 1991 Marcus Avenue, Suite 102, North New Hyde Park, NY 11042-2062, USA; [b] Private Practice, 9000 Waukegan Road, Suite 210, Morton Grove, IL 60053, USA

* Corresponding author.

E-mail address: lss@univplastics.com

Facial Plast Surg Clin N Am 27 (2019) 199–206

https://doi.org/10.1016/j.fsc.2018.12.003

1064-7406/19/© 2019 Elsevier Inc. All rights reserved.

to Key Ridge and Key Ridge to A point (PtV-KR/KR-A) ratio for the lower malar complex. SNO angle was also shown to be similar between male and female individuals with a negative vector orbital relationship as compared with males and female individuals with a positive vector orbital relationship.[2] However, a more recent computed tomography study revealed subtle, but significant differences, between male and female zygoma that were conserved across ethnic groups.[3] Specifically, the female orbital rim had a slightly less acute curve, the body of the zygoma was slightly shorter in a vertical dimension, and the zygomatic arch demonstrated less bowing.

Conversely, the soft tissue differences appear to be more pronounced. Using soft tissue markers with cephalometric analysis in white patients, it was found that the soft tissue orbital rim, "cheek bone" (right malar greatest projection at three-fourths frontal view intersected by a vertical line through the lateral canthus on full frontal view), alar base (deepest depression of the alar rim), and subpupil (directly below the neutral gaze position of the pupil at one-half the vertical distance between the soft tissue orbital rim and the alar base marker) was significantly more projected in female than in male individuals. The converse was true in other areas of the face.[4] Similar findings were encountered in male and female individuals of Japanese descent.[5] With regard to a potential difference in cheek height, a photographic study found no significant difference in the height of greatest malar projection on oblique view relative to lateral canthus and chin, a value found to be slightly lower than the golden ratio of 0.809.[6] Due to a generally shorter lower face in female individuals, this may make the malar prominence appear closer to the eye or "higher," but the ratio showed no difference.

As suggested by Hage and colleagues,[7] the difference between the projection of the male and female midface appears to be primarily related to fat distribution. Missing from the current literature is an analysis of the facial volume changes brought on by the initiation of cross-sex hormones. Various online forums and personal accounts by transwomen describe a softening and rounding of their cheeks with estrogen treatment. This facial skin itself appears to change, with a decrease in sebum production, hair shaft diameter, and hair density. Similarly, for individuals designated female at birth undergoing testosterone treatment, there is a significant increase in hair growth and sebum production.[8] An increase in facial fat in the malar area, possibly as a result of feminizing hormones, may explain why this area is not frequently concerning to many younger transwomen seeking feminizing procedures.

An additional focus of the midface for any woman, trans- or cis-, appears to be age. Significant changes in both the soft tissue of the face and its underlying skeletal support occur over time, leading to an aged appearance (**Figs. 1–3**).

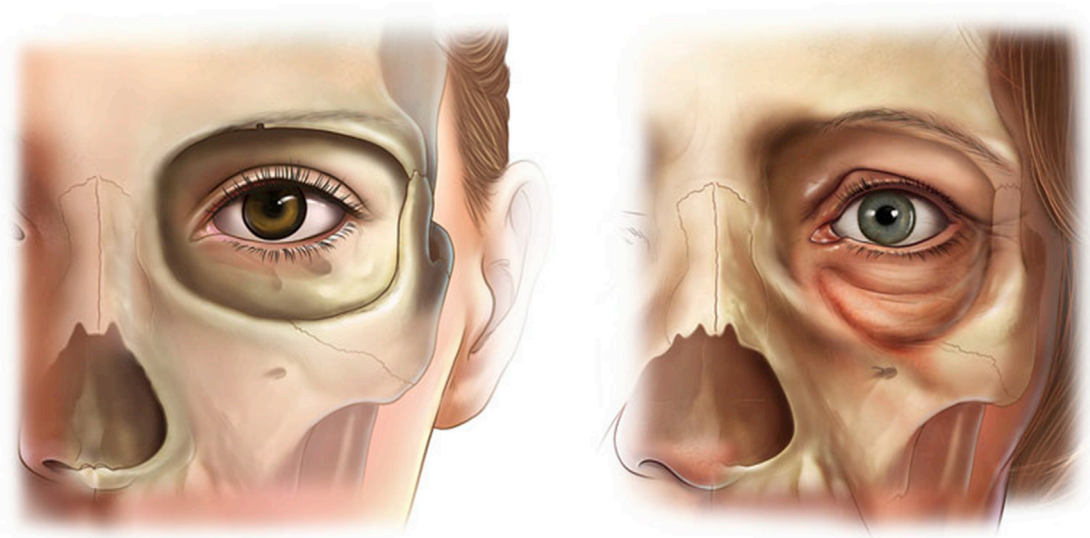

Fig. 1. Orbital and midfacial aging. This figure demonstrates a frontal view of the age-related changes in the facial skeleton. Note the bony resorption from the inferolateral orbit, pyriform aperture, and the maxilla overall. (*From* Mendelson B, Wong C-H. Changes in the facial skeleton with aging: implications and clinical applications in facial rejuvenation. Aesthetic Plast Surg 2012;36(4):754. Figure 1; with permission.)

Fig. 2. Orbital and midfacial aging. This figure demonstrates a lateral view of the age-related changes in the facial skeleton. Note the bony resorption from the maxilla. (*From* Mendelson B, Wong C-H. Changes in the facial skeleton with aging: implications and clinical applications in facial rejuvenation. Aesthetic Plast Surg 2012;36(4):756. Figure 4; with permission.)

In the facial skeleton, there is significant retrusion of the maxilla over time, even in dentulous patients.[9–11] This includes significant widening of the pyriform aperture.[12] Resorption of the maxilla appears to be greatest at its ascending portion and at the lower pyriform. Although the zygoma appears less susceptible to age-related losses, there is still significant resorption at the inferolateral orbit. These skeletal changes lead to loss of bony midface support, accelerating descent of the soft tissues of the midface, accentuating the nasolabial folds, and causing recession of the anterior nasal spine, retraction of the columella, leading to ptosis of the nasal tip and the appearance of nasal lengthening.[13]

Meanwhile, through the forces of gravity, muscular activity, and loss of tissue elasticity, there is loss of projection of the malar soft tissues.

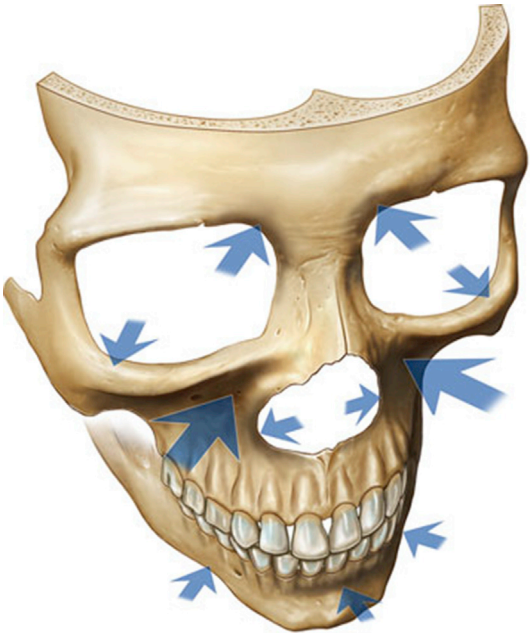

Fig. 3. Orbital and midfacial aging. Blue arrows demonstrate areas of bony resorption with advanced aging of the facial skeleton; larger arrows demonstrate areas of greater bone loss, clearly showing the maxilla as an area of significant resorption. (*From* Mendelson B, Wong C-H. Changes in the facial skeleton with aging: implications and clinical applications in facial rejuvenation. Aesthetic Plast Surg 2012;36(4):757. Figure 5; with permission.)

Descent of facial fat compartments (**Figs. 4** and **5**) (nasolabial, medial suborbicularis oculi, lateral suborbicularis oculi, medial cheek, and deep medial cheek), downward redistribution of volume and/or greatest sagittal diameter within the fat compartments (nasolabial and medial cheek), deflation and descent of the deep medial cheek fat compartment, as well as deflation of the buccal extension of the buccal fat pad have been documented.[14]

These 2 factors, skeletal and soft tissue, lend themselves to a variety of solutions. Although some obliquity to the malar eminence can be appealing,[15] overfilled cheeks or overprojected lateral zygomata can lead to an unnatural appearance. In fact, interzygomal distance is one of the least variable facial measurements within and between ethnic groups.[16]

TREATMENT OPTIONS

Injectable Dermal and Soft Tissue Fillers

Nonautologous fillers

A variety of commercially available dermal fillers have been used for augmentation of the midface. These include collagen-based fillers, volume replacement fillers such as hyaluronic acid, and biostimulatory fillers such as calcium hydroxyapatite and poly-L-lactic acid.[17]

The primary advantage of hyaluronic acid–based fillers is their temporary nature, as, over

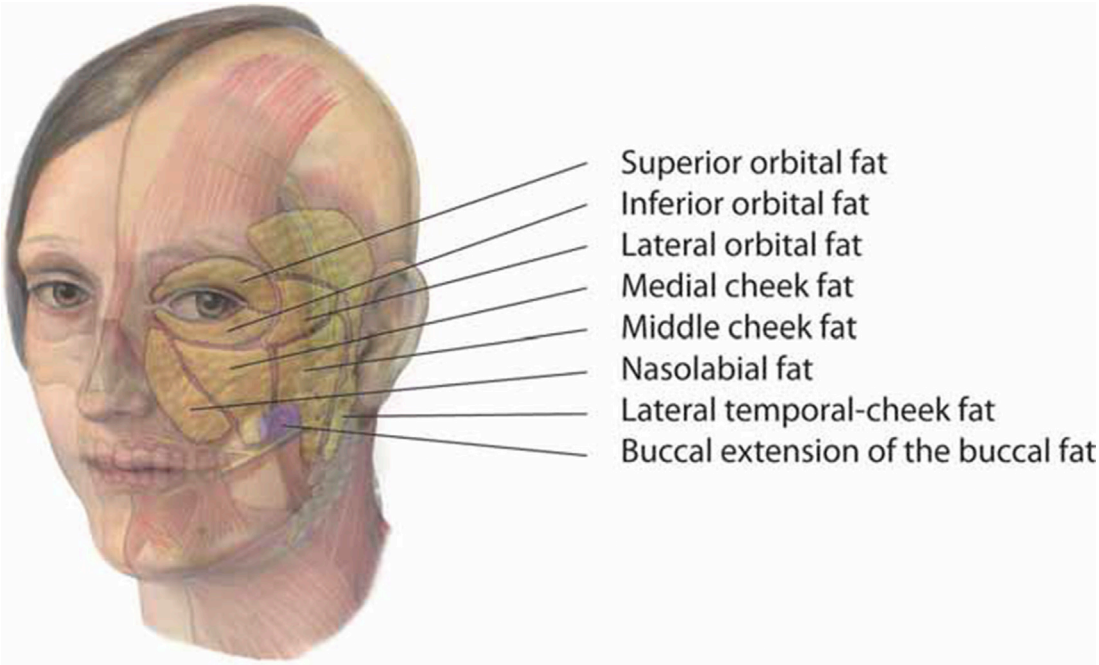

Fig. 4. Facial fat pads. Superficial fat pads of the face. (*From* Gierloff M, Stöhring C, Buder T, et al. Aging changes of the midfacial fat compartments: a computed tomographic study. Plast Reconstr Surg 2012;129(1):263. Figure 12; with permission)

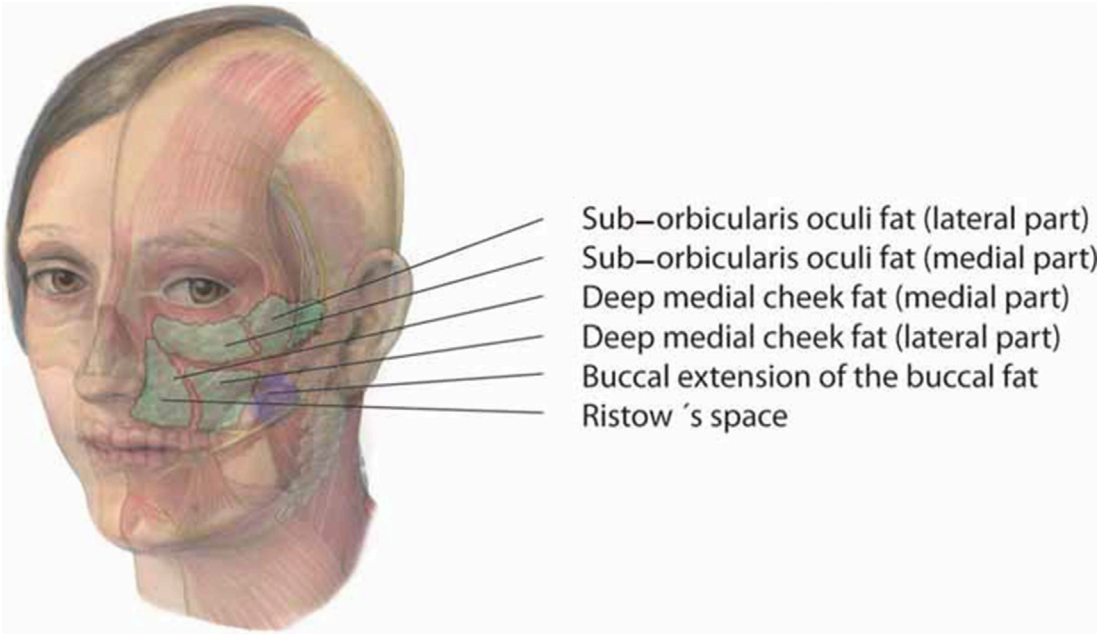

Fig. 5. Facial fat pads. Deep fat pads of the face. (*From* Gierloff M, Stöhring C, Buder T, et al. Aging changes of the midfacial fat compartments: a computed tomographic study. Plast Reconstr Surg 2012;129(1):263. Figure 13; with permission.)

time, they will get degraded, the rate of which is inversely proportional to the amount of cross-linking in the filler. They also may be rapidly degraded by hyaluronidase in the event of complications. Hyaluronic acid fillers have been used to augment the zygomaticomalar area, anteromedial cheek, and submalar areas using both subcutaneous and supraperiosteal injection sites. They also have been used to efface the nasolabial fold and tear trough. Patients have reported that they looked younger after treatment, which persisted, in some, for up to 2 years.[18] Superficial injection of a significant amount of hyaluronic acid can lead to a bluish tint to the skin that some attribute to the Tyndall effect.[19] This can be addressed with the use of hyaluronidase.

Coralline calcium hydroxyapatite has been used to augment the facial skeleton over the anterior maxilla, zygoma, and mandibular body. In one study, a precise subperiosteal pocket was dissected out in the area to be augmented via a small access incision, and a mixture of the porous, granular calcium hydroxyapatite with blood and a hemostatic agent was introduced into the pocket, which was then closed. This demonstrated stable volume enhancement, and with time, also demonstrated bone ingrowth into the deep portion of filler material.[20]

Poly-L-lactic acid, which stimulates fibroblasts to produce collagen, has long been used to help combat the appearance of human immunodeficiency virus (HIV)-mediated lipodystrophy but has gained acceptance for use in non-HIV patients as well. It can be placed subcutaneously to efface skin creases like the nasolabial fold, or for greater volumization when placed along the periosteum.[21]

Autologous fat

Autologous fat, typically procured from the thighs or the anterior abdominal wall, is a frequently used soft tissue filler. It can be used to address volume deficits or contour problems in the nasolabial, nasojugal, malar, or submalar areas when injected in a subcutaneous or preperiosteal manner.[22]

More recently, attention has been directed to the facial fat compartments of the midface.[14] Use of direct fat injection into the deep medial fat compartment has been shown to efface the nasolabial fold and produce a more youthful appearance to the anterior cheek.[23] Others have demonstrated improved malar fullness when selectively injecting the medial and lateral suborbicularis oculi fat pads in addition to the deep medial fat pad.[24] Some have favored injection of the nasolabial, deep medial cheek, medial suborbicularis oculi, Ristow space, upper lip submucosa, and buccal extension of the buccal fat pad, for a satisfied or mostly satisfied rate of 95%.[25] There is also some evidence that direct

injection into the buccal fat pad from an intraoral approach can effectively fill the midface.[26] The buccal fat pad has also been directly repositioned during LeFort I osteotomy to provide great fullness in the malar area.[27]

When injecting fat, it is expected that some resorption will likely occur. Traditional teaching suggests that 50% of the initial volume may be lost.[28,29] It is also taught that this figure can potentially be enhanced by grafting within highly vascular tissue, such as muscle. With less vascular tissue, it is unclear how predictable engraftment into the fat pads of the face may be, but some investigators demonstrate good, persistent results at 1 year.[25]

Potential complications of fillers

Caution should be used with fillers of any type, including fat. Intravascular filler injection in the midface can lead to soft tissue necrosis, blindness, and stroke. Intra-arterial filler injection can displace the blood and move as a pressure column up to the ciliary and retinal arteries, potentially leading to permanent blindness. If the column goes into the internal carotid artery, all structure that it supplies are at risk.[30] It is recommended that all injections be performed with a blunt cannula with, if possible, a sidefacing port.[23]

More common problems with injectable fillers include overfilling or underfilling, filling at an inappropriate tissue depth, filling at an inappropriate or suboptimal location, use of an inappropriate filler, as well as infectious or allergic complications. Many complications, if involving a hyaluronic acid–based filler, can be addressed, at least in part, with hyaluronidase. For other fillers, other strategies must be used.[31]

IMPLANTS

Given the skeletal contribution of loss of midface projection with age, some practitioners choose to use implants to augment the midfacial skeleton (**Fig. 6**), especially in individuals with negative vector orbital relationship for whom it can be said that

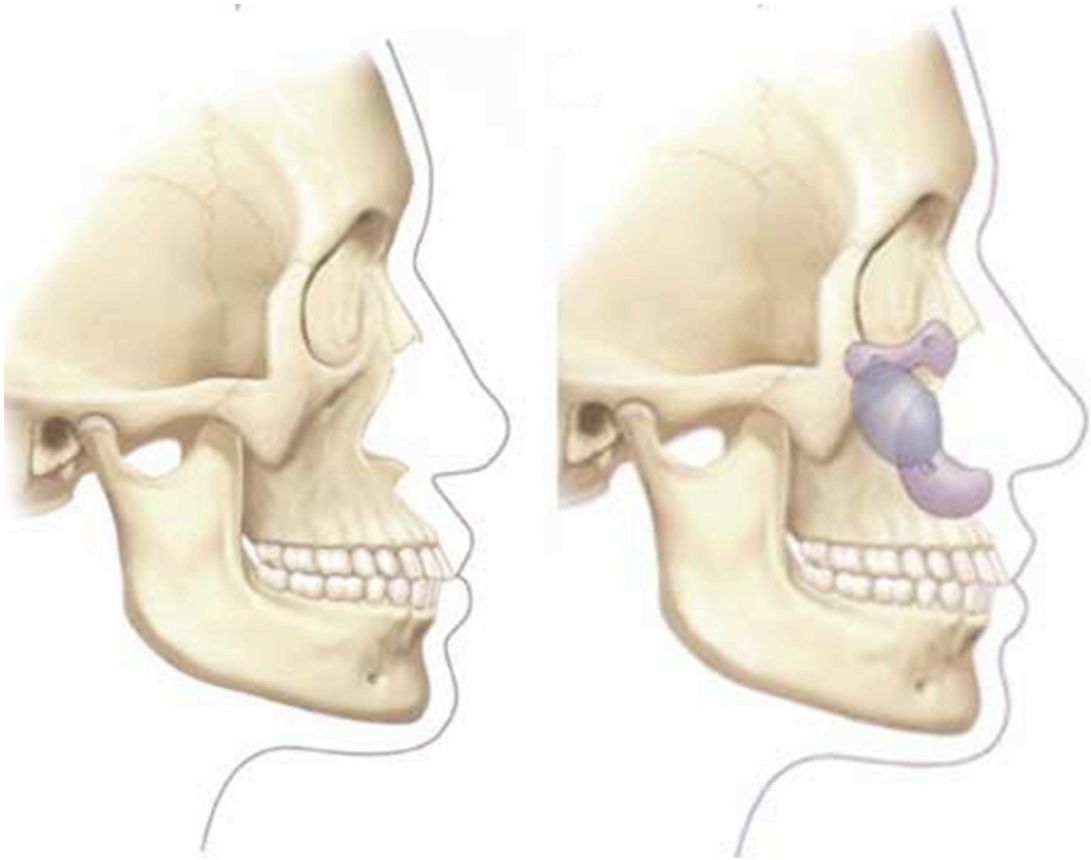

Fig. 6. Facial implants. This figure demonstrates a potential configuration of midface implants to enhance fullness of the cheek, including inferior orbital rim, malar eminence, and paranasal placement. (*Adapted from* Yaremchuk MJ. Making concave faces convex. Aesthetic Plast Surg 2005;29(3):142. Figure 1C and 1D; with permission.)

the descent of midfacial structures with age is accelerated.

The 2 most common implant types are silicone and porous polyethylene. Defenders of solid silicone facial implants suggest there are many advantages to this type implant. These include customizability through simple cutting of the implant with a scissor or a blade, easy removal, and potential for placement through a smaller access incision due to the flexibility of the material.[32] Those who prefer porous polyethylene implants favor their permanence through soft tissue integration (with decreased encapsulation), as well as their customizability both at the time of placement, and in the future, with the use of a burr.[33]

The infraorbital region may be addressed with an implant. An implant can help attenuate the tear trough, provide greater support to the lower lid and midface soft tissues, and potentially produce a positive vector relationship.[34] In addition, the anterolateral maxilla, lateral to the infraorbital foramen, also may be addressed with an implant. Here, the implant can help support the midmalar tissues, fill out the nasolabial fold, and reduce the prominence of the nose.[35,36] Implant placement also can be combined with soft tissue suspension to improve malar fullness.[33]

However, all types of facial implants can become infected and/or extrude. In addition, they can be associated with hematoma and/or persistent swelling. Encapsulation of the implants can lead to distortion of the overlying soft tissues. Furthermore, malpositioning is a possibility that can occur despite screw fixation. Many of these complications require subsequent removal of the implant, and all are important to discuss at the time of consultation and during the informed consent process.[37]

OTHER TECHNIQUES

Rhytidectomy to address skin excess can be a useful adjunct to the previously described techniques, likely as part of a staged approach.

In addition, some have suggested using an osteotomy with advancement of the zygomaticomalar complex, based on that of the LeFort III, for facial feminization.[38]

SUMMARY

The primary goal of midface procedures is feminization through volume augmentation. Additional, secondary benefits may include a rejuvenated appearance. Careful analysis of an individual's midface soft tissue structure and skeletal relationship can help dictate the treatment offered. Some individuals may benefit from injectable fillers or autologous fat grafting, whereas others may require a staged approach, using implant placement, fat grafting, and rhytidectomy.

REFERENCES

1. Scheideman GB, Bell WH, Legan HL, et al. Cephalometric analysis of dentofacial normals. Am J Orthod 1980;78(4):404–20.
2. Frey ST. New diagnostic tenet of the esthetic midface for clinical assessment of anterior malar projection. Angle Orthodontist 2013;83(5):790–4.
3. Schlager S, Rüdell A. Sexual dimorphism and population affinity in the human zygomatic structure—comparing surface to outline data. Anat Rec (Hoboken) 2017;300(1):226–37.
4. Arnett GW, Jelic JS, Kim J, et al. Soft tissue cephalometric analysis: diagnosis and treatment planning of dentofacial deformity. Am J Orthod Dentofacial Orthop 1999;116(3):239–53.
5. Shindoi JM, Matsumoto Y, Sato Y, et al. Soft tissue cephalometric norms for orthognathic and cosmetic surgery. J Oral Maxillofac Surg 2013;71(1):e24–30.
6. Kaptein YE, Kaptein JS, Markarian A. Vertical localization of the malar prominence. Plast Reconstr Surg Glob Open 2015;3(6). https://doi.org/10.1097/GOX.0000000000000383.
7. Hage JJ, Becking AG, de Graaf FH, et al. Gender-confirming facial surgery: considerations on the masculinity and femininity of faces. Plast Reconstr Surg 1997;99(7):1799.
8. Giltay EJ, Gooren LJG. Effects of sex steroid deprivation/administration on hair growth and skin sebum production in transsexual males and females. J Clin Endocrinol Metab 2000;85(8):2913–21.
9. Pessa JE, Zadoo VP, Mutimer KL, et al. Relative maxillary retrusion as a natural consequence of aging: combining skeletal and soft-tissue changes into an integrated model of midfacial aging. Plast Reconstr Surg 1998;102(1):205.
10. Mendelson BC, Hartley W, Scott M, et al. Age-related changes of the orbit and midcheek and the implications for facial rejuvenation. Aesthetic Plast Surg 2007;31(5):419–23.
11. Paskhover B, Durand D, Kamen E, et al. Patterns of change in facial skeletal aging. JAMA Facial Plast Surg 2017;19(5):413–7.
12. Shaw RBJ, Kahn DM. Aging of the midface bony elements: a three-dimensional computed tomographic study. Plast Reconstr Surg 2007;119(2):675.
13. Mendelson B, Wong C-H. Changes in the facial skeleton with aging: implications and clinical applications in facial rejuvenation. Aesthetic Plast Surg 2012;36(4):753–60.

14. Gierloff M, Stöhring C, Buder T, et al. Aging changes of the midfacial fat compartments: a computed tomographic study. Plast Reconstr Surg 2012; 129(1):263.
15. Paul MD. Morphologic and gender considerations in midface rejuvenation. Aesthet Surg J 2001;21(4): 349–53.
16. Fang F, Clapham PJ, Chung KC. A systematic review of inter-ethnic variability in facial dimensions. Plast Reconstr Surg 2011;127(2):874–81.
17. Lorenc ZP. Dermal and soft-tissue fillers: principles, materials, and techniques. In: Thorne CH, editor. Grabb and Smith's plastic surgery. 7th edition. Philadelphia: Lippincott Williams & Wilkins; 2014.
18. Few J, Cox SE, Paradkar-Mitragotri D, et al. A multicenter, single-blind randomized, controlled study of a volumizing hyaluronic acid filler for midface volume deficit: patient-reported outcomes at 2 years. Aesthet Surg J 2015;35(5):589–99.
19. Rootman DB, Lin JL, Goldberg R. Does the Tyndall effect describe the blue hue periodically observed in subdermal hyaluronic acid gel placement? Ophthalmic Plast Reconstr Surg 2014;30(6):524–7.
20. Huggins RJ, Mendelson BC. Biologic behavior of hydroxyapatite used in facial augmentation. Aesthetic Plast Surg 2017;41(1):179–84.
21. Rotunda AM, Narins RS. Poly-L-lactic acid: a new dimension in soft tissue augmentation. Dermatol Ther 2006;19(3):151–8.
22. Gamboa GM, Ross WA. Autologous fat transfer in aesthetic facial recontouring. Ann Plast Surg 2013; 70(5):513–6.
23. Rohrich RJ, Pessa JE, Ristow B. The youthful cheek and the deep medial fat compartment. Plast Reconstr Surg 2008;121(6):2107.
24. Schreiber JE, Terner J, Stern CS, et al. The boomerang lift: a three-step compartment-based approach to the youthful cheek. Plast Reconstr Surg 2018;141(4):910.
25. Wang W, Xie Y, Huang R-L, et al. Facial contouring by targeted restoration of facial fat compartment volume: the midface. Plast Reconstr Surg 2017; 139(3):563.
26. Cohen SR, Fireman E, Hewett S, et al. Buccal fat pad augmentation for facial rejuvenation. Plast Reconstr Surg 2017;139(6):1273e.
27. Hernández-Alfaro F, Valls-Ontañón A, Blasco-Palacio JC, et al. Malar augmentation with pedicled buccal fat pad in orthognathic surgery: three-dimensional evaluation. Plast Reconstr Surg 2015; 136(5):1063.
28. Peer LA. Loss of weight AND volume in human fat grafts: with postulation of A "cell survival theory." Plast Reconstr Surg 1950;5(3):217.
29. Bellini E, Grieco MP, Raposio E. The science behind autologous fat grafting. Ann Med Surg (Lond) 2017; 24:65–73.
30. Yoshimura K, Coleman SR. Complications of fat grafting: how they occur and how to find, avoid, and treat them. Clin Plast Surg 2015;42(3):383–8.
31. DeLorenzi C. Complications of injectable fillers, part I. Aesthet Surg J 2013;33(4):561–75.
32. Niamtu J. Essentials of cheek and midface implants. J Oral Maxillofac Surg 2010;68(6):1420–9.
33. Yaremchuk MJ. Making concave faces convex. Aesthetic Plast Surg 2005;29(3):141–7.
34. Yaremchuk MJ, Kahn DM. Periorbital skeletal augmentation to improve blepharoplasty and midfacial results. Plast Reconstr Surg 2009;124(6):2151.
35. Yaremchuk MJ, Vibhakar D. Pyriform aperture augmentation as an adjunct to rhinoplasty. Clin Plast Surg 2016;43(1):187–93.
36. Chao JW, Lee JC, Chang MM, et al. Alloplastic augmentation of the Asian face: a review of 215 patients. Aesthet Surg J 2016;36(8):861–8.
37. Rayess HM, Svider P, Hanba C, et al. Adverse events in facial implant surgery and associated malpractice litigation. JAMA Facial Plast Surg 2018;20(3):244–8.
38. Lundgren TK, Farnebo F. Midface osteotomies for feminization of the facial skeleton. Plast Reconstr Surg Glob Open 2017;5(1):e1210.