Chondrolaryngoplasty—Thyroid Cartilage Reduction

Angela Sturm, MD[a,b], Scott R. Chaiet, MD, MBA[c,*]

KEYWORDS

• Tracheal shave • Adam's apple • Thyroid notch • Chondrolaryngoplasty • Transgender • Transfeminine • Facial feminization surgery

KEY POINTS

- Chondrolaryngoplasty, or reduction in the thyroid cartilage, is the only treatment for an enlarged Adam's apple because the thyroid cartilage does not respond to gender-affirming hormonal therapy.
- Reconstructive procedures such as chondrolaryngoplasty are not optional in any meaningful sense but are understood to be medically necessary for the treatment of those with gender dysphoria.
- The chondrolaryngoplasty incision should be made cephalad to the thyroid cartilage in the cervicomental angle; a direct approach leaves a telltale neck scar, dangerously marking the patient's status, and it can scar to deeper structures, leading to a depressed scar that moves with swallowing or talking.
- Direct visualization with an endoscope combined with an external approach in reduction chondrolaryngoplasty can help to avoid damage to the vocal cord attachment as well as underreduction of the thyroid prominence.

INTRODUCTION

Pomus Adamus or Adam's apple, a prominent thyroid notch, is a result of the effect of testosterone on the thyroid cartilage of the larynx. Until puberty, the dimensions of the thyroid cartilage are similar in most larynges. After the increase in testosterone, the thyroid cartilage will grow larger and the superior aspect more prominent, both "masculine" physical characteristics. Many transfeminine patients find the Adam's apple distressing as an unwanted indication of that person's transgender status. In the facial feminization practice of Douglass Osterhout, MD, DDS, many sought their first surgical intervention for a prominent Adam's apple.[1] And in the 2015 US Transgender Survey, 4% of respondents with male on their original birth certificate had this procedure; however, 29% wanted the surgery 1 day while 29% were unsure.[2]

Chondrolaryngoplasty, or reduction in the thyroid cartilage, is the only treatment for those with gender dysphoria due to pomus Adamus because the thyroid cartilage does not respond to gender-affirming hormonal therapy such as soft tissue of the face. Pomus Adamus can not only be a large contributor to gender dysphoria but may also put that patient at risk for physical harm. In the 2015 US Transgender Survey, 48% of respondents experienced denial of equal treatment, verbal harassment, and/or were physically attacked

Disclosure Statement: The authors have nothing to disclose.

[a] Department of Otolaryngology–Head and Neck Surgery, University of Texas Medical Branch, 301 University Boulevard, Galveston, TX 77555-0521, USA; [b] Facial Plastic Surgery Associates, 6655 Travis Street, Suite 900, Houston, TX 77030, USA; [c] Division of Otolaryngology–Head and Neck Surgery, Department of Surgery, University of Wisconsin School of Medicine and Public Health, 600 Highland Avenue, CSC K4/7, Madison, WI 53792, USA

* Corresponding author.

E-mail address: chaiet@surgery.wisc.edu

Facial Plast Surg Clin N Am 27 (2019) 267–272

https://doi.org/10.1016/j.fsc.2019.01.005

1064-7406/19/© 2019 Elsevier Inc. All rights reserved.

because of being transgender. However, "those who said that others could usually or always tell that they were transgender (66%) were more likely to report having one or more of these experiences because of being transgender, in contrast to those who said that others could rarely or never tell that they were transgender (39%)."[2] So reducing the risk of being "outed" with surgery such as chondrolaryngoplasty effectively reduces harm in addition to treatment of gender dysphoria. In summary, chondrolaryngoplasty is an increasingly necessary operation in which surgeons should be competent.

EVALUATION

Chondrolaryngoplasty has been called various names throughout the literature including thyroid cartilage reduction, thyroid chondroplasty, laryngeal chondroplasty, and laryngochondroplasty. However, it is commonly called a tracheal shave; this is actually a misnomer and is a reduction of the thyroid cartilage rather than tracheal cartilage. Chondrolaryngoplasty is frequently requested by transfeminine patients but also anecdotally by cisgender men and even cisgender women. During the initial evaluation, patients may report the pomus Adamus causes gender dysphoria, a condition recognized in the Diagnostic and Statistical Manual of Mental Disorders, (DSM-5), published by the American Psychiatric Association. In its position statement for medical necessity for procedures such as chondrolaryngoplasty, the World Professional Association for Transgender Health states that the "medical procedures attendant to gender affirming/confirming surgeries are not "cosmetic" or "elective" or "for the mere convenience of the patient. These reconstructive procedures are not optional in any meaningful sense, but are understood to be medically necessary for the treatment of the diagnosed condition."[3]

Facial feminization surgery, an umbrella term that includes chondrolaryngoplasty, can significantly improve the quality of life for patients. In one review of patients who underwent facial feminization, all of the patients responded positively to a quality of life survey; when these patient outcomes were reviewed by 2 independent surgeons they were rated "very much improved" (87.8%) or "significantly improved" (12.1%).[4] Therefore, chondrolaryngoplasty should be viewed as medically necessary for gender dysphoria and can greatly improve quality of life.

ANATOMY

The thyroid cartilage is a shield-shaped structure composed of bilateral quadrilateral vertical laminae, which join together anteriorly forming a dihedral angle that is open posteriorly. The superior thyroid notch is formed by the fusion of the anterior borders of the 2 laminae. The anterior prominence of the thyroid cartilage is composed of the superior thyroid notch and the superior one-third of the laminae. Neck and pharyngeal muscles attach along the oblique line, lateral and posterior to the anterior prominence. Above the thyroid cartilage attaches the thyrohyoid membrane. The internal laryngeal nerve, a branch of the superior laryngeal nerve, penetrates the thyrohyoid membrane in its posterior half, cephalad to the superior laryngeal artery and vein and to the superior margin of the thyroid cartilage **Fig. 1**A. Care must be taken in this region as branches of this nerve supply sensation to the laryngeal structures above the glottis. The external branch of the superior laryngeal nerve descends along the posterior border of the thyroid cartilage, protected by the thyrohyoid muscle; the recurrent laryngeal nerve enters the larynx beneath the posteroinferior margin of the cricothyroid muscle.[5]

On the posterior thyroid cartilage lamina, the epiglottis inserts by means of the thyroepiglottic ligament well below the superior thyroid notch. Below this structure and protected by it are located the insertions of the false vocal cords and inferior to the false cords are the attachments

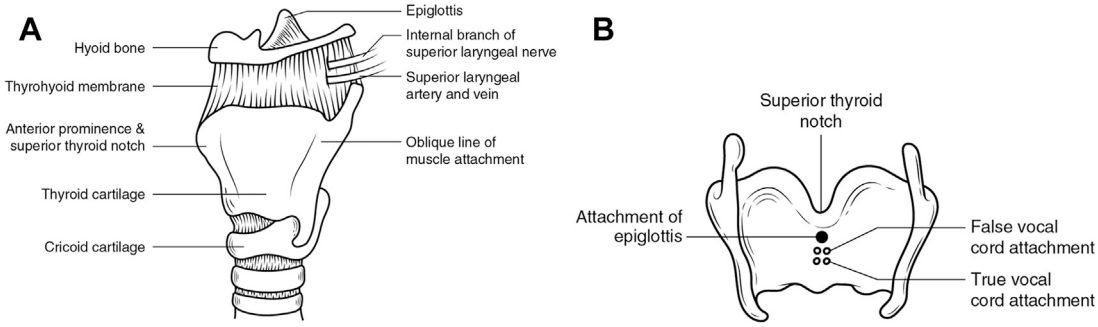

Fig. 1. (*A*) Laryngeal and thyroid cartilage anatomy, anterior view. (*B*) Laryngeal and thyroid cartilage anatomy, posterior view.

of the true vocal cords.[6] The attachment is referred to as the Broyle tendon.[6] The true vocal cords attach at the anterior commissure of the larynx to the posterior lamina of the thyroid cartilage approximately half way up the height of the cartilage according to topographic studies[6] (**Fig. 1**B). There is anatomic variation in the attachment that has also been described as between the superior one-third and inferior two-thirds of the posterior aspect of the thyroid cartilage, which is why determining the exact location of each patient's true vocal cords is critical.[7]

At puberty, testosterone enlarges the larynx significantly, particularly the thyroid cartilage. The anteroposterior diameter of the larynx nearly doubles.[8] The effect of testosterone also causes the anterior angle of fusion of the 2 laminae to be more acute at 90°, whereas the "female" larynx or those without significant testosterone influence are wider and closer to 120°. The larger size of the superior thyroid notch and acute angle of laminae cause anterior projection that becomes more visible at rest and with talking and swallowing.

PROCEDURE

Chondrolaryngoplasty was described by Wolfort and Parry in 1975.[5] The optimal result involves removal of all anteriorly projecting thyroid cartilage while minimizing the risk of destabilizing the attachment of the epiglottis by the thyroepiglottic ligament, and anterior commissure tendon, which could cause permanent change to deepen the patient's voice, a particularly concerning complication for transfeminine patients who do not desire a deeper, more masculine voice[9] (**Fig. 2**).

Chondrolaryngoplasty can be performed alone or in combination with other procedures. If alone, this is often performed as an outpatient surgery under local anesthesia, intravenous sedation, or general anesthesia with either endotracheal intubation or laryngeal mask airway depending on patient and surgeon preference. When performed with other procedures, chondrolaryngoplasty is frequently the first procedure performed.[1,9]

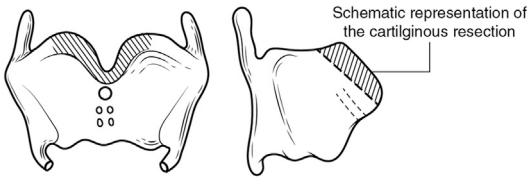

Fig. 2. Cartilage able to be excised in chondrolaryngoplasty surgery, with removal of all anteriorly projecting thyroid cartilage and preservation of the anterior commissure tendon.

The incision has been described directly over the thyroid cartilage; however, this leaves a telltale neck scar and can dangerously mark the patient's status. In addition, it can scar to deeper structures leading to a depressed scar that moves with swallowing or talking.[1] Therefore, it is recommended that the horizontal incision be made more cephalad in the cervicomental angle. Placement of the incision at this site reduces the chance of visibility and avoids the possibility of creating a retracted, mobile scar.[9] An anterior neck approach directly over the thyroid cartilage may be appropriate if other procedures are planned to modify the voice pitch[1,10] (**Fig. 3**).

After the skin incision is made, the subcutaneous plane is dissected. The anterior cervical vessels are identified and preserved if possible by lateral retraction; if necessary they are ligated and transected. The investing layer of the deep cervical fascia and then the middle cervical fascia are divided vertically.[5,11] The paired sternothyroid and thyrohyoid muscles are retracted laterally via a midline dissection plane. The superior one-third of the thyroid cartilage is exposed. The perichondrium is then incised along the superior rim of the thyroid laminae, with lateral dissection starting at a midpoint between the superior thyroid notch and oblique line proceeding to the thyroid notch medially[5] (**Fig. 4**A). A lateral dissection along the superior border can injure the superior laryngeal nerve, and care is also taken to stay on the rim with the incision to prevent entering the thyrohyoid membrane and preserve its attachment to the perichondrium of the posterior thyroid cartilage.[9,12]

A subperichondrial dissection is performed internally and externally using a Cottle elevator to reflect the perichondrium and expose the cartilage. The internal surface of the superior thyroid notch is elevated no farther inferiorly than the thyroepiglottic ligament; dissection beyond this point may destabilize the epiglottis and damage the vocal cord attachment. A curved hook can be

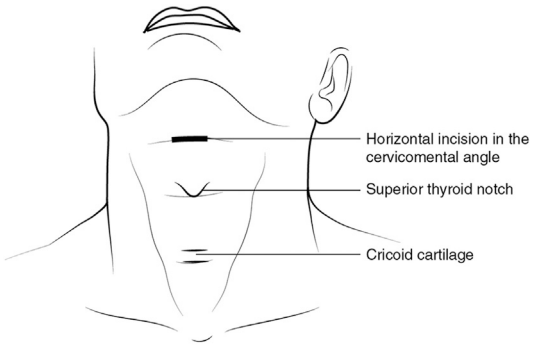

Fig. 3. Markings of skin incision, superior thyroid notch, and cricoid cartilage.

used on the posterior edge of the thyroid cartilage in the midline at the base of the notch to give superior-anterior retraction to perform anterior surface subperichondrial dissection.[9] Next, the superior thyroid notch, upper part of the laryngeal prominence, and prominent superior zone of the lateral laminae are excised by scalpel or rongeur. The surgeon should keep in mind that the procedure can become more challenging as people age and the cartilage ossifies requiring a saw or burrs. The internal structures are protected with an instrument such as a fine malleable retractor. The thyrohyoid membrane should be preserved because damage can place the superior laryngeal nerve in danger causing anesthesia of the larynx and possible aspiration[11] (**Fig. 4**B).

Removal of thyroid cartilage should be performed incrementally to achieve the appropriate contour. If using a rongeur, use extremely small bites to avoid fracturing the thyroid cartilage, particularly if there is ossification.[1] However, the safety of placing small holes through the laryngeal cartilage has been established.[13] The edges can be smoothed with a burr to refine the contouring, if necessary. Then, the perichondrium is sutured over the resected cartilage with a 5-0 Vicryl suture (**Fig. 4**C). The fascia of the neck is reapproximated and the skin incision is closed in layers.[7] A small rubber catheter for drainage is optional.[5] The incision can be covered with a small adhesive dressing or a compression dressing overnight.

Conrad and Spiegel recommend a combined endoscopic and external approach to reduction chondrolaryngoplasty to avoid damage to the vocal cord attachment as well as underreduction of the thyroid prominence.[6,9] To perform the endoscopic-assisted chondrolaryngoplasty, general anesthesia is recommended. The incision and approach are identical to what is described earlier. Once the perichondrium of the thyroid

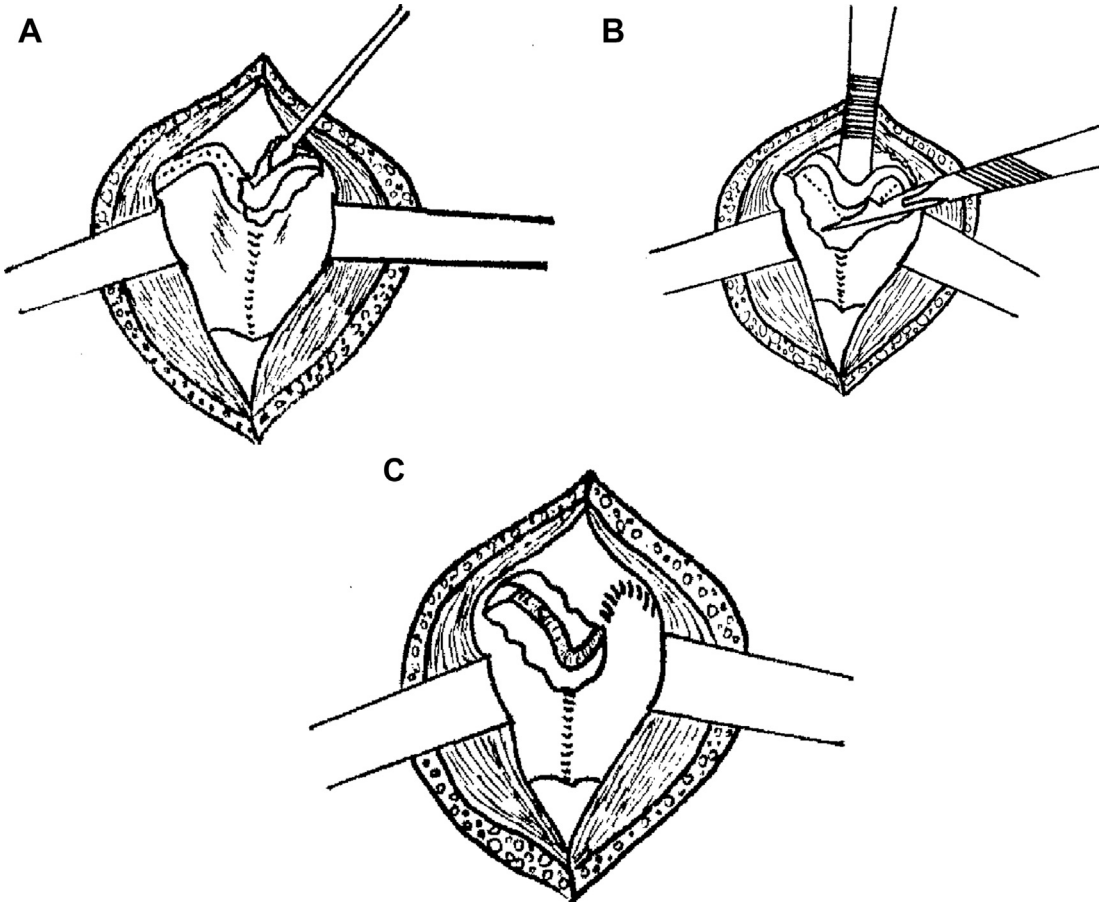

Fig. 4. (*A*) Retraction of sternothyroid and thyrohyoid muscles and incision of perichondrium. (*B*) Excision of the superior thyroid notch and anterior laryngeal prominence by scalpel and protection of internal structures. Excision may also be performed by rongeur, saw, or burrs. (*C*) The perichondrium is sutured over the resected cartilage followed by layered closure of fascia and skin. (*From* Giraldo F, de Grado J, Montes J. Aesthetic reductive thyroid chondroplasty. Int J Oral Maxillofac Surg 1997;26(1):21; with permission.)

cartilage is reflected, either a Keith needle or a 22 gauge needle is inserted through the cartilage into the laryngeal lumen a few millimeters above the midpoint of the anterior vertical height of the cartilage. Under direct visualization with an endoscope, the position of the needle in relation to the anterior commissure of the true vocal cords is verified (**Fig. 5**). At least 2 mm of cartilage above the superior surface of the true vocal cords should be left intact to provide support for the vocal cords and the thyroepiglottic ligament. Before removal, the external position of the marker needle is marked with a "V", with each limb in the vertical plane at a right angle to the anterior posterior line parallel to the vocal cords.

The patient can either be intubated with an endotracheal tube for the procedure and the needle is visualized with a laryngoscope[6] or the airway managed with a laryngeal mask airway (LMA) because the endotracheal tube can limit visualization of the anterior commissure and the needle.[9] If a laryngeal mask airway is used, a flexible laryngoscope is passed through the LMA for visualization. When combining chondrolaryngoplasty with other procedures, the LMA can be changed out for an endotracheal tube after the conclusion of the visualization portion of the chondrolaryngoplasty. The integrity of the vocal cords can be verified with a flexible laryngoscope at the conclusion of the cartilage excision or direct laryngoscopy at extubation.

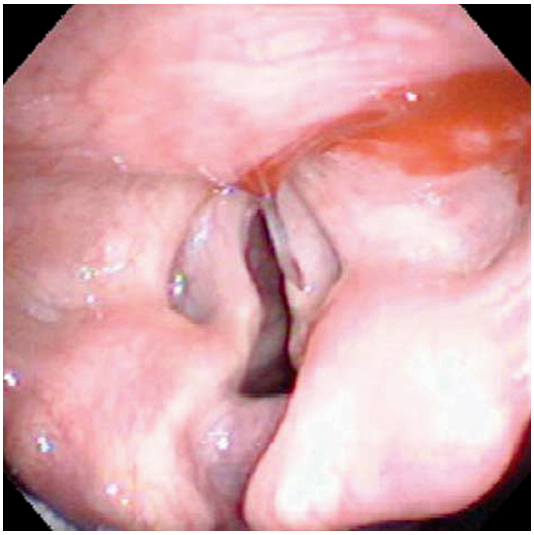

Fig. 5. Direct visualization with an endoscope of a needle inserted through the thyroid cartilage into the laryngeal lumen at least 2 mm above the superior surface of the true vocal folds. (*From* Spiegel JH, Rodriguez G. Chondrolaryngoplasty under general anesthesia using a flexible fiberoptic laryngoscope and laryngeal mask airway. Arch Otolaryngol Head Neck Surg 2008;134(7):704–8; with permission.)

MANAGING EXPECTATIONS

Overall patients are pleased with the outcome—up to 86% patient satisfaction rate.[10] If there is anteriorly projecting cartilage inferior to the level of the anterior commissure, a partial thickness shave may be possible in some situations; this does place the vocal cords at risk and leaving some thyroid cartilage in place is preferred.

Some patients have a large larynx and prominent superior thyroid notch. Because the larynx cannot be displaced posteriorly, these patients will likely have residual prominence of the larynx even after improving the contour of the thyroid cartilage. Because they will have a more feminine appearance but not ideal, the surgeon could proceed with appropriate patient expectations.[1] Mild edema of the cords is expected.[12] Also, the patient may have soft tissue edema for 3 to 6 months in the perioperative site camouflaging the final result, so should be counseled as such.[6]

MANAGEMENT OF COMPLICATIONS

Complications of chondrolaryngoplasty are rare. Conrad followed 10 patients for up to 2 years without complications.[6] Wolfort and colleagues[12] followed 31 patients up to 17 years and found the complications to be rare and usually transient with the most common being mild voice weakness; no patients experienced anesthesia of the larynx, neuralgia, or dysphagia. An anterior approach may lead to a wide, visible, retracted, or mobile neck scar that is extremely visible and can "out" the patient. Unsightly scars can be revised by excision and scar revision under local anesthesia. After excision of the scar, the layered closure is performed with either fat transfer or acellular dermis (eg, AlloDerm) is placed between the dermis and cervical fascia to prevent reformation of the scar tissue.[1] The appearance of the scar can also be improved with laser resurfacing.

Some patients may experience temporary narrowing of the vocal ranges and a sore throat that resolves in 3 to 4 days. Rarely, a patient may experience hoarseness that can last up to 6 months; Osterhout reported temporary lowering of the voice in 35% of his patients. This has historically been temporary. In the extremely rare occasion of disruption of the vocal cords, the change in voice could be permanent. Dysphagia could occur with disruption of the insertion of the epiglottis, although this has not been reported in the literature.

Endoscopic verification of the position of the vocal cords via a laryngeal mask airway provides excellent visualization of the anterior commissure

of the vocal cords. However, this does require exchange for a more definitive airway for a longer case and could lead to anesthetic complications or at least a risk. Furthermore, the thyroid cartilage excision could lead to blood in the airway causing vocal cord irritation, which in light anesthesia can lead to laryngospasm without a definitive airway mediated by superior laryngeal nerve stimulation.[14] Laryngospasm occurred once in the series by Spiegel. However, rescue treatment of propofol, a low dosage of depolarizing agent, or increasing the depth of anesthesia can be performed. Topical lidocaine on the vocal cords at the time of endoscopy can also help reduce this risk.[9]

SUMMARY

Chondrolaryngoplasty is a medically necessary procedure that can greatly affect quality of life, particularly in transfeminine patients. Complications are rare and knowledge of the laryngeal anatomy can make them even less common. Outcomes are generally good and patient satisfaction is high, particularly with proper patient selection and management of expectations.

REFERENCES

1. Ousterhout DK. Facial feminization surgery: a guide for the transgendered woman. Omaha (NE): Addicus Books; 2010.
2. James SE, Herman JL, Rankin S, et al. The report of the 2015 U.S. transgender survey. Washington, DC: National Center for Transgender Equality; 2016.
3. World Professional Association for Transgender Health. Position statement on medical necessity of treatment, sex reassignment, and insurance coverage in the U.S.A. 2016. Available at: https://www.wpath.org/newsroom/medical-necessity-statement. Accessed June 17, 2018.
4. Raffaini M, Magri AS, Agostini T. Full facial feminization surgery: patient satisfaction assessment based on 180 procedures involving 33 consecutive patients. Plast Reconstr Surg 2016;137(2):438–48.
5. Wolfort FG, Parry RG. Laryngeal chondroplasty for appearance. Plast Reconstr Surg 1975;56(4):371–4.
6. Conrad K, Yoskovitch A. Endoscopically facilitated reduction laryngochondroplasty. Arch Facial Plast Surg 2003;5(4):345–8.
7. Giraldo F, de Grado J, Montes J. Aesthetic reductive thyroid chondroplasty. Int J Oral Maxillofac Surg 1997;26(1):20–2.
8. Gray H, Warwick R, Williams PL. Gray's anatomy. Edinburgh: Churchill Livingstone; 1980. p. 1229–36.
9. Spiegel JH, Rodriguez G. Chondrolaryngoplasty under general anesthesia using a flexible fiberoptic laryngoscope and laryngeal mask airway. Arch Otolaryngol Head Neck Surg 2008;134(7):704–8.
10. Matai V, Cheesman AD, Clarke PM. Cricothyroid approximation and thyroid chondroplasty: a patient survey. Otolaryngol Head Neck Surg 2003;128(6):841–7.
11. Al-Jassim AHH, Lesser THJ. Reduction of Adam's apple for appearance. Indian J Otolaryngol Head Neck Surg 2006;58(2):172–3.
12. Wolfort FG, Dejerine ES, Ramos DJ, et al. Chondrolaryngoplasty for appearance. Plast Reconstr Surg 1990;86(3):464–9.
13. O'Leary MA, Grillone GA. Injection laryngoplasty. Otolaryngol Clin North Am 2006;39(1):43–54.
14. Suzuki M, Sasaki CT. Laryngeal spasm: a neurophysiologic redefinition. Ann Otol Rhinol Laryngol 1977;86(2):150–7.