Int. J. Oral Maxillofac. Surg. 2019; 48: 597–600
https://doi.org/10.1016/j.ijom.2018.10.003, available online at https://www.sciencedirect.com

International Journal of
Oral & Maxillofacial Surgery

Clinical Paper
Cosmetic Surgery

Mandibular feminization osteotomy—preliminary results

M. Y. Mommaerts[1], C. Voisin[2], J. Joshi Otero[1], N. A. J. Loomans[3]
[1]European Face Centre, Universitair Ziekenhuis Brussel, VUB, Brussels, Belgium; [2]Unité de Chirurgie Maxillo-Faciale, Université Libre de Bruxelles, Hôpital Ixelles Iris Sud, Brussels, Belgium; [3]Division of Oral and Maxillofacial Surgery, GZA Hospitals, Antwerp, Belgium

M. Y. Mommaerts, C. Voisin, J. Joshi Otero, N. A. J. Loomans: Mandibular feminization osteotomy—preliminary results. Int. J. Oral Maxillofac. Surg. 2019; 48: 597–600. © 2018 Published by Elsevier Ltd on behalf of International Association of Oral and Maxillofacial Surgeons.

Abstract. Strong mandibular angles and a heavy chin are perceived as masculine features, so surgical feminization of female or transgender faces may warrant mandibular base narrowing (borders and angles) and a reduction in chin width and height. With this in mind, we have devised an interdental midline osteotomy (triangular in shape and with a caudal base) to accompany a box-shaped impaction osteotomy of the chin symphysis and horizontal triangular resection of the lateral mandibular border. The reduction of the intergonial width and of the mandibular border and chin widths takes place upon closure of the midline defect. Between November 2016 and August 2017, five patients agreed to the mandibular feminization osteotomy and were followed up thereafter for 6–13 months. All expressed satisfaction with the results; no dental, periodontal, or temporomandibular joint-related complications were encountered. This technique is a viable alternative to buccal decortication, chin reduction osteotomy, and masseter reduction surgery.

Key words: osteotomy; mandible; chin.

Accepted for publication
Available online 17 October 2018

Attractive female faces have less vertical height than their male counterparts. The ideal sellion–menton to zygion–zygion distance ratios in women and men are 0.86 and 0.88, respectively (Bruges index)[1,2]. Alternatively put, the female facial height is considered ideal at 180% of interpupillary distance, compared with 210% in males[1]. The facial taper in frontal view is a four-point construct, based on the malar eminences and gonial angles. It is desirable for female forms to be tapered or trapezoidal, displaying an interzygomatic–intergonial ratio of 0.86; whereas a stronger gonial angle in men produces a ratio closer to 1[3]. Chin shape again is more trapezoidal in women, the submental plateau arcing into the mandibular body anterior to the canines. The squarer male chin is higher, and the contouring transition point between symphyseal plateau and body of the mandible typically occurs behind the canines.

In recent years, we have received requests not only from women, but also from a transvestite and a transgender woman to taper the lower jaw. However, the inferior alveolar nerve on occasion was far too lateral to endeavour buccal decortication in addition to gonial angle reduction and a narrowing/height reduction osteotomy of the chin. There were also issues with neutrocclusion, linguoversion of the lower molars (difficult to correct orthodontically), and reluctance to change malocclusion that prompted the decision not to aim for the modification of the 'Asian technique'[4].

The senior author (MM) has devised a complex chin osteotomy to address chin height and width, as well as mandibular border and gonial width, without affecting occlusion or temporomandibular joint

 © 2018 Published by Elsevier Ltd on behalf of International Association of Oral and Maxillofacial Surgeons.

(TMJ) function. Preliminary experience with this technique is reported here. A systematic review of the literature (unpublished) revealed that this technique has not been described before.

Materials and methods

The procedure was undertaken in five patients (four women, one man; age range 23–67 years) who were followed up postoperatively for 6–13 months. Concurrent treatments included malar valgisation osteotomies (two patients), blepharoplasty, rhinoplasty, earlobe reduction, and submental liposuction. The co-authors of this article were appropriately trained through a cadaveric demonstration by the senior author.

Technique

The clinically planned constriction was evaluated using computed tomography-derived simulations in ProPlan CMF (Materialise, Heverlee, Belgium). Condylar torque and dental cusp/fossa rotations were monitored. A three-dimensional fused deposition filament printer enabled prediction of the desired constriction from a model[5].

After infiltration of 1% lidocaine plus epinephrine, mixed 1:1 with saline solution, a lazy M-shaped incision was made, and the symphysis was degloved[6]. The midpoint between central incisor apices was determined by drilling (round drill bit, 1-mm diameter) at mid-root level until cementum and dentine were reached (translucent greyish halo with cream-coloured centre). This defect heals by secondary cementum repair, causing no real harm[7]. Using the same 1-mm drill bit, small cortical perforations were then made between the roots, parallel to the incisor axes, to a depth of 5 mm below the canine teeth apices. A small, thin Lindemann drill was used for complete buccolingual corticotomy of the anterior alveolus between the roots and the interdental crest; a horizontal osteotomy line was made 5 mm below the canines, making another horizontal line (depending on the required vertical impaction) adjacent to the first, so the ostectomized segment could be removed. Next, two vertical lines were created lateral to the others, using the small, thin Lindemann bur for scoring and a reciprocating saw with a disposable blade (Aesculap Inc. (B. Braun), Tuttlingen, Germany) for completion, thus setting the margins of the box osteotomy (Fig. 1). The reciprocating saw was used again to transect the lingual cortex in the middle, up to the level of the apices; a chisel (8-mm width) sufficed to complete

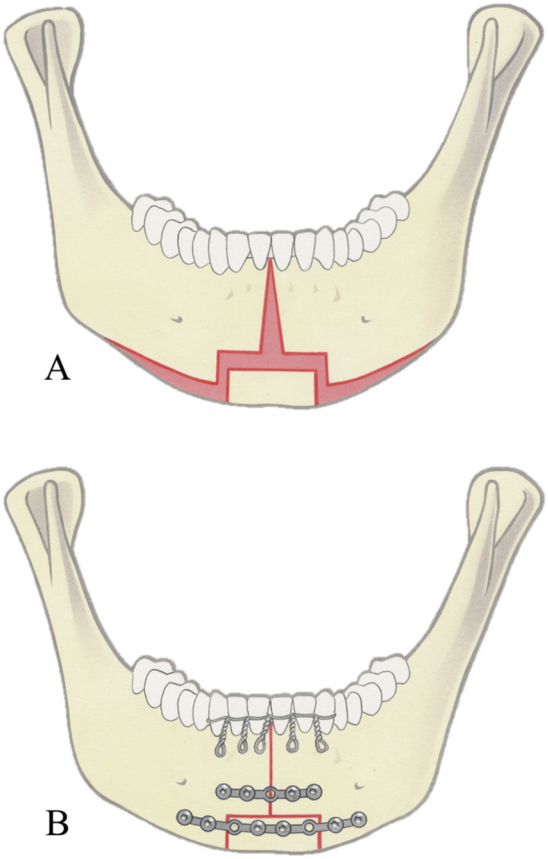

Fig. 1. Design of the mandibular feminization osteotomy: (A) bone for removal (in red); (B) post-construction view, with stabilization at three levels.

Fig. 2. Transgender female patient: (A) before any facial procedures; (B) after two reconstructive sessions: (1) frontal bossing reduction/brow lift/canthoplasty, rhinoplasty, malar valgisation osteotomies and anterior augmentation (hydroxyapatite/fibrin glue), and tracheal shave (February 29, 2016); (2) mandibular feminization osteotomy, rhinoplasty (supratip deformity correction), and submental liposuction (January 18, 2017).

the interdental osteotomy, applying torque at the anterior corticotomy line. An inferior-based triangle was then made, scoring each side of the osteotomy to avoid exposing the central incisor roots. Divergence recontouring was especially important over the lingual cortex, creating a void for appropriate angulation and hence mandibular constriction. The basal mandibular border lateral to the impaction chin ostectomy was also resected in a triangular shape (Fig. 1) and further contoured, using a Christmas tree-shaped bone bur. Stabilization of the segments was achieved by Obwegeser loop wiring of the front, using 0.4-mm soft Remanit (Dentaurum, Ispringen, Germany) and a rail of osteosynthesis plates.

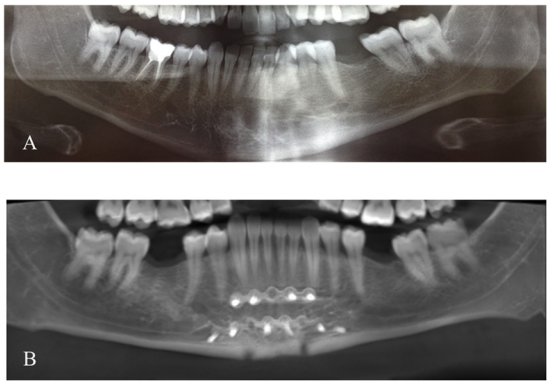

Fig. 3. Healing evidenced by radiographic examination: (A) panoramic radiograph obtained January 3, 2017, prior to mandibular feminization osteotomy; (B) panoramic radiograph reconstruction from cone beam computed tomography obtained April 28, 2017.

Results

All patients were satisfied with the reduction in intergonial width. There were no instances of pseudarthrosis, gingival recession, loss of papillae, central diastema, lateral malocclusion, or lost pulp vitality in the five patients treated. The reshaping procedure produced elegant contours (Figs 2 and 3). Panoramic radiographs and cone beam computed tomography (CBCT) evaluations showed excellent bony and acceptable periodontal conditions (Fig. 3).

Discussion

Femininity of the lower face is influenced by jaw-angle morphology, chin contour, and smile architecture. The male mandibular angle has a relatively larger surface area, allowing for wider attachment of the masseter muscle. Greater muscle mass in this region imbues a 'chiselled' jaw effect. Masseter muscle reduction and buccal decortication may narrow the intergonial distance and soften the contours[8]. However, masseter hypertrophy is often lacking, and decortication is thwarted by the presence of a buccally positioned inferior alveolar nerve. In such circumstances, the mandibular feminization osteotomy could be useful.

In this procedure, it is critical to maintain the integrity of gingival fibre attachments and not open the osteotomy gap to the oral cavity. It was surprising to witness a quick postoperative reduction in the central interdental diastema, arising during narrowing at the caudal level (see video, Supplementary Material). A similar event has transpired in the course of transmandibular distraction, due to the walking tooth phenomenon[9]. Even more curious was the fact that posterior occlusion could be maintained or quickly auto-corrected without the help of orthodontic treatment. Alexander et al. likewise have used a vertical complete midline symphyseal osteotomy to constrict the mandible, although in conjunction with bilateral split osteotomies to advance or setback the mandible and always with the goal of correcting transverse malocclusion[10]. The mandibular feminization osteotomy specifically addresses the width at the gonial angle, the mandibular border, and the anterior mandible, maintaining original occlusion. As reported by Alexander et al.[10], no TMJ or periodontal problems were manifested postoperatively in these patients. The bilateral vertical box-shaped ostectomy in the mandibular border at the transition between the anterior and lateral mandible aims to reduce the width, in conjunction with the triangular midline ostectomy. The technique of 'box genioplasty' was popularized in the UK by Velupillai Ilankovan, and published in

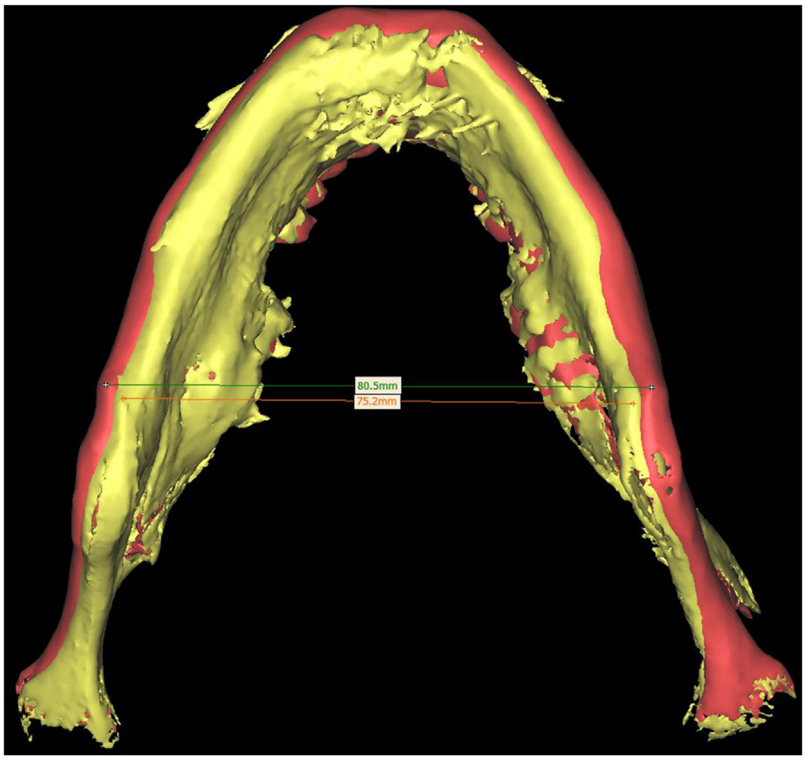

Fig. 4. Superimposition of submento-vertex views of the mandible (.STL files) of the patient case presented in Figs 2 and 3, before (red) and 4 months after (yellow) the narrowing osteotomy. The narrowing is depicted and was measured as >5 mm at the gonial angles.

abstract form by Colbert et al.[11,12] and Sykes et al.[13]. The unilateral box-shaped ostectomy in the anterior mandible manages centreline chin deformity. It does not narrow the chin or the mandible, including its gonial parts.

The lack of TMJ problems or loss of central incisor vitality is certainly of note. The latter was expected given our knowledge of transmandibular distraction with a midline split; in fact the lack of TMJ symptoms came as a surprise. The only effort made during surgery was to avoid lateral condylar displacement by manual pressure over the lateral aspect of the TMJs. Little medial displacement of the condyles was observed (Fig. 4). The quick reinstatement of comfortable lateral occlusion was also remarkable. Both observations merit attention in future efforts, striving to quantify changes in shape going forward.

This technique confers feminine proportions to a masculine mandible in a single reliable procedure and is deserving of further study. We encourage daring surgeons to examine condyle-to-fossa relationships, lateral occlusion, and midline crestal conditions on coronal CBCT scan slices.

Funding

None.

Competing interests

None.

Ethical approval

Not required as this was a retrospective study on recorded data without extra examinations. Patients consented.

Patient consent

Patient consent was obtained.

Appendix A. Supplementary data

Supplementary data associated with this article can be found, in the online version, at https://doi.org/10.1016/j.ijom.2018.10.003

References

1. Mommaerts MY, Moerenhout BA. Ideal proportions in full face front view, contemporary versus antique. *J Craniomaxillofac Surg* 2011;**39**:107–10.
2. Whitaker L. Facial proportions in aesthetic surgery. In: Farkas LG, Munro IR, editors. *Anthropometric facial proportions in medicine*. Springfield, IL: Charles C. Thomas; 1986. p. 103–11.
3. Mommaerts MY. The ideal male jaw angle—an internet survey. *J Craniomaxillofac Surg* 2016;**44**:381–91.
4. Li J, Hsu Y, Khadka A, Hu J, Wang Q, Wang D. Surgical designs and techniques for mandibular contouring based on categorisation of square face with low gonial angle in Orientals. *Br J Plast Surg* 2012;**65**:e1–8.
5. Otero JJ, Vijverman A, Mommaerts MY. Use of fused deposit modeling for additive manufacturing in hospital facilities: European certification directives. *J Craniomaxillofac Surg* 2017;**45**:1542–6.
6. Mommaerts MY, Van Hemelen G, Sanders K, Vander Sloten J, Van Brussel K, Abeloos JV, De Clercq CA, Neyt LF. High labial incision for genioplasty. *Br J Oral Maxillofac Surg* 1997;**35**:398–400.
7. Soares Correia PE, Wehrbein H, Mommaerts MY. Periodontal impact of surgically induced dental lesions in mandibular osteodistraction: an animal study. *J Craniomaxillofac Surg* 2009;**37**:174–81.
8. Mommaerts MY. The surgical art of facial makeover. *Chapter I: Jaw angle reduction*. 1st ed. Sint-Martens-Latem, Belgium: Orthoface; 2013: 233–8.
9. Mommaerts MY, Polsbroek R, Santler G, Correia PS, Abeloos JV, Ali N. Anterior transmandibular osteodistraction: clinical and model observations. *J Craniomaxillofac Surg* 2005;**33**:318–25.
10. Alexander CD, Bloomquist DS, Wallen TR. Stability of mandibular constriction with a symphyseal osteotomy. *Am J Orthod Dentofacial Orthop* 1993;**103**:15–23.
11. Colbert S, Seah TE, Ilankovan V, Bellis H. An alternative option to conventional genioplasty: box genioplasty. *Br J Oral Maxillofac Surg* 2011;**49S**:S1–25.
12. Colbert S, Seah TE, Ilankovan V, Bellis H. An alternative option to conventional genioplasty: box genioplasty. *International Conference on Oral and Maxillofacial Surgery* 2011. http://dx.doi.org/10.1016/j.ijom.2011.07.187. Abstract 186.
13. Sykes R, Sidebottom AJ, Sah S. Box genioplasty in the management of mandibular centreline chin deformity. *Br J Oral Maxillofac Surg* 2014;**52**:e43–74. http://dx.doi.org/10.1016/j.bjoms.2014.07.034.

Address:
Maurice Mommaerts
EFC
Universitair Ziekenhuis Brussel
VUB
Laarbeeklaan 101
B-1090 Brussels
Belgium
Tel.: +32 2 477 60 12
E-mail: Maurice.mommaerts@uzbrussel.be