Scandinavian Journal of Plastic and Reconstructive Surgery and Hand Surgery

ISSN: 0284-4311 (Print) Journal homepage: www.tandfonline.com/journals/iphs19

Long Term Follow up After Sex Reassignment Surgery

Jan Eldh Agnes Berg & Maria Gustafsson

To cite this article: Jan Eldh Agnes Berg & Maria Gustafsson (1997) Long Term Follow up After Sex Reassignment Surgery, Scandinavian Journal of Plastic and Reconstructive Surgery and Hand Surgery, 31:1, 39-45, DOI: 10.3109/02844319709010503

To link to this article: https://doi.org/10.3109/02844319709010503

Published online: 08 Jul 2009.

Submit your article to this journal

Article views: 478

View related articles

Citing articles: 2 View citing articles

Full Terms & Conditions of access and use can be found at
https://www.tandfonline.com/action/journalInformation?journalCode=iphs20

Scand J Plast Reconstr Hand Surg 31: 39–45, 1997

LONG TERM FOLLOW UP AFTER SEX REASSIGNMENT SURGERY

Jan Eldh, Agnes Berg and Maria Gustafsson

From the Department of Plastic and Reconstructive Surgery, Karolinska Hospital, Stockholm, Sweden

(Submitted for publication 8 January 1996)

Abstract. A long term follow up of 136 patients operated on for sex reassignment was done to evaluate the surgical outcome. Social and psychological adjustments were also investigated by a questionnaire in 90 of these 136 patients. Optimal results of the operation are essential for a successful outcome. Personal and social instability before operation, unsuitable body build, and age over 30 years at operation correlated with unsatisfactory results. Adequate family and social support is important for postoperative functioning. Sex reassignment had no influence on the person's ability to work.

Key words: transsexualism, sex reassignment, surgical technique, psychosocial adjustment, long term follow up.

Since the 1960s sex reassignment operations have been undertaken in Sweden, mainly at the Department of Plastic and Reconstructive Surgery, Karolinska Hospital, Stockholm.

Before the operation the applicant for sex reassignment is evaluated by the behavioural scientists (psychiatrists or psychologists (9)) and the diagnostic criteria and the standards of care outlined by the Harry Benjamin International Gender Dysphoria Association are followed (1).

The evaluation takes an extended period of time and varies from case to case; in practice it takes at least three years for an applicant to get permission to be operated on. During this time the applicant has successfully lived in the genetic other sex role for a long period. The permission is given by a group of experts at The National Board of Health and Welfare.

According to a law passed in 1972 only Swedish citizens are allowed to undergo sex reassignment in Sweden.

The aim of this follow up was to evaluate the outcome of sex reassignment surgery from the functional as well as the cosmetic point of view, including the time spent in hospital, the morbidity, and the patients' satisfaction rather than the social and psychological changes that may follow these complex procedures.

PATIENTS AND METHODS

The incidence of transsexualism in Sweden today is 0.14/100000 people over 15 years of age, and is equally common in men and women. Ninety-three male-to-female and 82 female-to-male transsexual patients underwent sex reassignment during the period 1965–1995 in Sweden. Twenty-two out of 175 (13%) were not born in Sweden but at the time of the operation they had become Swedish citizens.

One hundred and thirty-six patients were operated on at the Department of Plastic and Reconstructive Surgery, Karolinska Hospital, Stockholm.

The medical records of every patient were studied. Special attention was paid to the type and the number of operations, rate of complications, and time spent in hospital. Preoperative information such as family, social and psychological status, education, occupation, and working capacity were also recorded. For surgical assessment the patients were divided into two groups according to the surgical technique: those who were operated on before 1986 and those operated on from 1986–1995 (Table I). There were 72 patients (47 male-to-female and 25 female-to-male) in the earlier and 103 (46 male-to-female and 57 female-to-male) in the later group. All patients operated on between 1986–95 were operated on by the same surgeon. The age distribution of all patients was 20–67 years (mean 34).

Questionnaires were sent to the 136 patients who had been treated at the Karolinska Hospital and covered their opinion about the functional and cosmetic results of the operation, sexual function, and social adaptation, together with their family status, and working and economic circumstances. Ninety patients (66%) responded to the questionnaire

©1997 Scandinavian University Press. *ISSN 0284–4311*

either by mail or by personal interviews on request. Those patients who were seen also underwent a physical examination of the genitalia (Table I).

The follow up evaluation was done a mean of 5.8 years after operation (range 0.5–30).

Table I. *Patients operated on and assessed at long term follow up*

Patients operated on in Sweden (n = 175):	
Before 1986	
Male to female	47
Female to male	25
1986–1995	
Male to female	46
Female to male	57
Patients operated on at the Karolinska Hospital (n = 136):	
Responded to the questionnaire	90
Did not respond	30
Lost to follow up	10
Died	6

Surgical techniques

Creating the neovagina in male-to-female transsexuals is done by dissection of the rectovesical septum to separate the rectum from the urethra and the posterior wall of the urinary bladder. During the first 20 years the most common way of lining the wall of the neovagina was with a split thickness skin graft as described by McIndoe (11). In a few cases a penile flap was used. In two or more operations thereafter the vulva was constructed. A neoclitoris was not constructed.

In female-to-male transsexuals construction of the penis was done by a pedicled abdominal skin tube.

After 1985 the surgical technique was revised, improved, and successively changed from a multistage to a one stage procedure.

The neovagina now was lined with a penile flap alone or in combination with a scrotal flap, usually together with construction of a neoclitoris by preservation of a part of the glans penis as a neurovascular island flap. This method has recently been described (2).

The penis was constructed with a groin flap (10, 12) and prepared with an invaginated skin tube as a urinary conduit necessary for future construction of the neourethra in female-to-male patients (Table II).

RESULTS

Surgery

The total overall number of operations/patient (genital, breast, and laryngeal cartilage) was 8.1 (range 2–50) before 1986 and 3.1 (range 1–8) from 1986–1995. The median total stay in hospital was 80.0 days (range 10–489) and 25.4 days (range 7–84), divided into 6.9 admissions/patient (range 1–33) and 3.1 admissions (range 1–7), respectively (Table III).

Early postoperative complications. Early complications developed in 84 of the 175 patients (Table IV). In some instances patients had more than one complication. Infection and intestinal fistulation were common in the earlier

Table II. *Surgical techniques used in the 175 patients operated on in Sweden*

	Before 1986	1986–1995
Male to female	47	46
Skin graft	27	0
Penis–scrotal flap	0	35
Penile flap	8	10
No vagina	12	1
Neoclitoris	0	33
No neoclitoris	47	13
Reduction of laryngeal cartilage	3	10
Breast augmentation	5	4
Female to male	25	57
Abdominal flap	22	0
Groin flap	0	47
Free radial forearm flap	1	0
Penis/urethra complex	0	40
No penis	2	10
Mastectomy	25	0

Table III. *Details of hospital care in 175 patients*

	Before 1986 (n = 72)	1986–1995 (n = 103)
Median number of operations/patient	8.1	3.1*
Range	(2–50)	(1–8)
Median number of admissions/patient	6.9	3.1
Range	(1–33)	(1–7)
Median total stay in the hospital/patient (days)	80.0	25.4
Range	(10–489)	(7–84)

* Female to male: 3.8; male to female: 2.3.

group as was necrosis of the abdominal flaps for the penile construction.

Late postoperative complications. Late complications are shown in Table IV. Stenosis of the vagina, prolapse of the penile or scrotal flaps, and a too long urethral stump were the most common late complications.

Necessity for postoperative surgical correction. In 31 cases out of 175 (18%) surgical correction was required (Table V). Closure of rectovaginal or urethrovaginal fistulas were the main procedures in the earlier group while shortening of the urethra was most common in the later group.

As well as genital construction also reduction mammaplasty was required in almost all female-to-male cases, and augmentation mammaplasty in nine male-to-female cases. Resection of the laryngeal cartilage was required in 13 cases. Two patients underwent operations on the vocal cord to achieve a lighter tone of voice.

Physical follow up

Male-to-female genital construction

Neoclitoris. In 33 male-to-female transsexual patients the neoclitoris was constructed as described by Eldh (2), and 22 out of 33 patients reported good sexual sensation and achieved orgasm from the neoclitoris. Two patients experienced no erotic sensation but the clitoris was sensitive, while one patient had no sensation at all. Eight patients did not understand the question and were not able to answer.

Vagina. Eighteen patients of the 40 who were evaluated were contented with the depth, while 14 patients (12 in the earlier group) were moderately satisfied with the result of the operation because of insufficient depth and width of the neovagina. Eight patients did not answer the question.

Female-to-male genital surgery

Thirty-five of the 50 patients were satisfied with

Table IV. *Postoperative complications in 175 patients*

Figures are number (%) of patients.

	Before 1986 (n = 72)	1986–1995 (n = 103)
Early complications:	58 (80)	26 (25)
Haemorrhage or haematoma	14	10
Infection	21	12
Rectovaginal, perineal or urethrovaginal fistula	13	1
Partial necrosis of flap	10	3
Late complications:	27 (38)	20 (19)
Stenosis of vagina	17	4
Prolapse of scrotal flap	2	4
Long urethra	8	12

Table V. *Reasons for postoperative surgical correction*

	Before 1986 (n = 72)	1986–1995 (n = 103)
Shortening of the urethra	4	10
Cutting of the posterior vaginal commissure	2	4
Closure of the rectovaginal, perineal, or urethrovaginal fistula	7	0
Reconstruction of the neovagina	2	2
	15 (21)	16 (16)

the result of the operations, while seven patients in the earlier group were dissatisfied with the size or shape of the neopenis. Eight patients did not answer the question.

Evaluation of the questionnaire

Forty female-to-male and 50 male-to-female patients out of 136 responded to the questionnaire (66%) (Table I).

Sexual identity. Sixty-eight of these 90 patients had no identity problem (31 male-to-female and 37 female-to-male). Nine patients still had doubts about their sexual orientation. Five male-to-females and three female-to-males, respectively, were more than 30 years old at the time of the operation (mean age 39.6 years, range 30–47). Thirteen patients did not answer this question.

Sexual life. Regarding the sexual life, 22 of 40 (55%) male-to-female transsexual patients were quite satisfied, while 15 were dissatisfied with their sexual lives. Three patients in this group had no experience of sexual activity after the operation.

In female-to-male patients, 17 of 50 (34%) stated that their sexual lives were acceptable and 19 said they were non-existent. Fourteen patients did not answer the question.

Acceptance/support. Twenty-eight male-to-female, and 37 female-to-male patients were fully accepted by their families, friends, and other people. Nine and one, respectively, had the feeling that they were only partly accepted by those around them. One male-to-female patient was not accepted and had painful experiences which lead to inability to work. Fourteen did not answer the question.

Family status. Twenty-three of the 40 male-to-female patients (58%) and 23 out of 50 female-to-male ones (46%) were married or lived in a steady relationship (Table VI). In 13 and 15, respectively, the partners knew about the transsexual background of the patients. Forty-four people (17 male-to-female and 27 female-to-male) lived alone, quite isolated, without or with poor social relations and with only occasional single sexual contacts.

Employment. (Table VII). In eight out of 11 patients the reasons for the inability to work were psychological disorders such as depression, anorexia, or anxiety neurosis. Two of the patients had tried to commit suicide both before and after the operation, one of them on several occasions. Seven patients who were unable to work had never been employed and five had retired because of age (over 65) by the time of follow up (Table VII). Forty-two of 90 (47%) were fully or periodically dependent on social assistance at follow up. This can be compared with 37/90 patients (41%) before the sex reassignment operation.

Overall satisfaction with life. The patients

Table VI. *Social status of the 90 patients who answered the questionnaire*

Civil status	Male to female	Female to male
Married or steady relationship	23	23
Single occasion contacts/single or divorced	17	27

Table VII. *Postoperative working capacity compared with preoperative in the 90 patients who answered the questionnaire*

Employment status	Preoperatively	At follow up
Permanently employed	42	37
Unemployed	12	10
Disability pension	14	5
Early retirement	11	22
Retired	0	5
No information	11	11

were generally satisfied with the overall aesthetic appearance of their genitalia (Figs. 1 and 2). Sixty-four of the 74 patients (86.4%) who responded the questionnaire were content with their overall life-situation while 10 were discontented.

Two male-to-female and two female-to-male patients regret the sex reassignment operation and continued to live in their previous sexual appearance socially.

DISCUSSION

Genital reconstructions including a functional vagina and aesthetically acceptable female or male genitalia are delicate operations that need skill in surgical techniques as well as much experience of this kind of surgery. Lindemalm et al. (6) and Lundström et al. (8) found that a good surgical result is fundamental but it is not enough for a totally successful outcome.

According to Lundström and Wålinder (9) and Wålinder et al. (15) the prerequisites for a good outcome of sex reassignment are: a good surgical result, a stable personality, a correct diagnosis, adequate support from the family, body build appropriate to the new sex role, and young age (less than 30 years) at first medical contact. A multidisciplinary approch, the Gender Dysphoria Team, is recommended for management of this group of patients.

In this follow up we tried to evaluate more than the surgical results to include psychosocial and personal aspects. Knowing that many

Fig. 1. A representative patient 18 months after construction of a neovagina with clitoris.

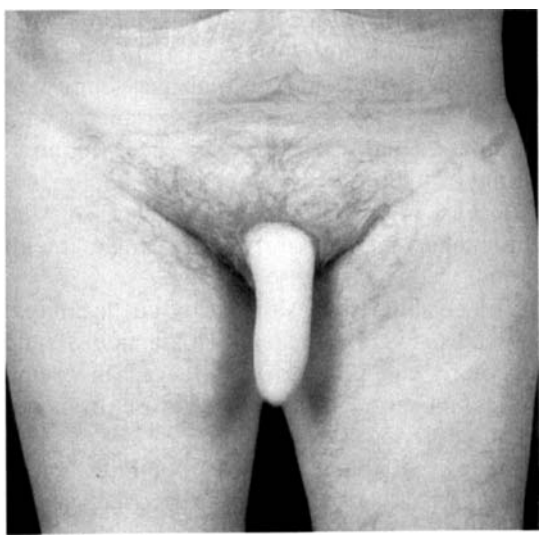

Fig. 2. A representative patient 12 months after phalloplasty; note the discrete donor site in left groin.

patients do not want any contact after the operation together with that fact that there are great difficulties in locating or keeping in touch with transsexual patients, a postoperatively 66% response to the questionnaire is a better result than we could have expected.

After 1985 the outcome of surgery became much better not only because of changes in management, but also because of improvements in surgical technique, preoperative planning, and postoperative treatment. Total time spent in hospital decreased dramatically after 1985 because the number of procedures was less and the rate of early and late postoperative complications dropped. Haemorrhage and haematoma were common in both groups, predominantly originating from the spongious tissue of the urethra. Infections occurred less often in the later group perhaps as a result of peroperative antibiotic prophylaxis. Serious complications like fistula formation and partial flap necrosis were rare after 1985, though they were common before then. The reason for the lower fistula rate in the later group may be ascribed to better anatomical knowledge of this region and a more precise surgical technique. There was only one rectovaginal fistula after 1985 and this fistula closed spontaneously.

Between 1986 and 1995 the neovaginal wall was usually constructed with peniscrotal flaps (2) and this usually lead to a good result with a deep and wide neovagina with a natural and sufficiently wide introitus. The penile flap alone used earlier often led to a high perineum with insufficient introitus which gave problems with intercourse and these patients later required cutting of the posterior vaginal commissure.

Because of this, nowadays we always split the penile tube a bit posteriorly and complete it with a small wedge-shaped scrotal flap.

The neoclitoris constructed by our technique (2) lead to wide functional satisfaction. In the neoclitoris the patients experienced the same erotic sensation on stimuli as arose from the penis before the operation.

Stenosis of the vagina was common before 1986, probably because of the frequent use of split thickness skin grafts.

It is extremely important to shorten the urethra as much as possible. Painful swelling of the urethral spongious tissue on sexual excitement because of a too long urethra was the most common late complication which needed secondary surgical correction in the later group. These complaints have led to a more aggressive excision of the spongious tissue around the urethral stump during recent years. The importance of this procedure confirms the observations of Karim et al. (4).

In female-to-male patients the construction of the penis-urethra complex with a groin flap was the main technique after 1985 and it was successively developed from an ordinary two stage groin flap to a one stage extended groin flap or iliac flap (5). Besides the sensibility the cosmetic result of this flap is well comparable with the result of a free flap and in addition the procedure is easier, less time consuming, and the donor site is well hidden by clothes.

The female-to-male patients were generally content with the aesthetic results but almost all expressed a strong wish to be able to void in a standing position. Some patients have been operated on by the method described by Hage et al. (3) with a vaginal flap for the fixed part of the urethra and this will now be the standard procedure.

As far as breast surgery is concerned it is always important to minimise the scars and by choosing a subcutaneous resection through a periareolar incision the best cosmetic result can be achieved.

Lindemalm et al. recommend care when considering patients over the age of 30 for sex reassignment (7). In our group there were only nine of 90 patients who had doubts about their sexual orientation. Eight of these nine were more than 30 years old at the time of the sex reassignment operation. Furthermore two male-to-female and two female-to-male patients who regretted the sex reassignment were more than 30 years old at the time of the operation.

Socially more than half the patients were married or lived in a permanent relationship but only 61% of partners knew about the patients' transsexual background. Patients with an unsuitable body build found it difficult to be accepted in their new sex roles and consequently to make social contacts.

Sixty-five of 90 (72%) of patients were fully

accepted by their families, friends, and other people. As far as employment was concerned the sex reassignment did not lead to any particular improvement. Patients who had disability pensions or who had retired early before the operation remained in the same state at follow up.

According to Sörensen (13, 14) suicide is proof that they regret the operation. In our series three people (two male to female and one female to male) committed suicide postoperatively because of depression and anxiety neurosis. All three had made many unsuccessful attempts at suicide before the operation.

Combining all the results, 86% (64/74) of those who responded to the questionnaire stated overall satisfaction with their new circumstances, which is quite a good outcome.

CONCLUSION

Optimal results from the operations are essential for a successful outcome. Modern surgical techniques can give good aesthetic and functional results.

Personal and social instability before operation correlated with an unsatisfactory outcome of sex reassignment.

Our experiences based on this relatively large series suggest that external factors such as adequate and convincing body appearance can be of vital importance for a successful outcome.

Adequate family and social support is central to postoperative functioning.

Sex reassignment had no influence on the patients' employment prospects.

REFERENCES

1. Benjamin H. The transsexual phenomenon. New York: The Julian Press, 1966.
2. Eldh J. Construction of a neovagina with preservation of the glans penis as a clitoris in male transsexuals. Plast Reconstr Surg 1992; 5: 895–903.
3. Hage JJ, Bouman FG, Bloem JJAM. Construction of the fixed part of the neourethra in female-to-male transsexuals: experience in 53 patients. Plast Reconstr Surg 1993; 5: 904–913.
4. Karim RB, Hage JJ, Bouman FG, Dekker JJML. The importance of near total resection of the corpus spongiosum and total resection of the corpora cavernosa in the surgery of male to female transsexuals. Ann Plast Surg 1991; 26: 554–557.
5. Lai C-S, Chou C-K, Yang C-C, Lin S-D. Immediate reconstruction of the penis with an iliac flap. Case report. Br J Plast Surg 1990; 43: 621–662.
6. Lindemalm G, Körlin D, Uddenberg N. Long term follow-up of sex change in 13 male-to-female transsexuals. Arch Sex Behav 1986; 15: 187–210.
7. Lindemalm G, Körlin D, Uddenberg N. Prognostic factors vs. outcome in male-to-female transsexualism. Acta Psychiatr Scand 1987; 75: 268–274.
8. Lundström B, Pauly I, Wålinder J. Outcome of sex reassignment surgery. Acta Psychiatr Scand 1984; 70: 289–294.
9. Lundström B, Wålinder J. Evaluation of candidates for sex reassignment. Nord Psykiatr Tidsskr 1985; 39: 225–228.
10. McGregor IA, Jackson IT. The groin flap. Br J Plast Surg 1972; 25: 3–16.
11. McIndoe A. The treatment of congenital absence and obliterative conditions of the vagina. Br J Plast Surg 1950; 2: 254–266.
12. Puckett CL, Montie JL. Construction of male genitalia in the transsexual, using a tubed groin flap for the penis and a hydraulic inflation device. Plast Reconstr Surg 1978; 4: 523–529.
13. Sörensen T. A follow-up study of operated transsexual males. Acta Psychiatr Scand 1981; 63: 486–503.
14. Sörensen T. A follow-up study of operated transsexual females. Acta Psychiatr Scand 1981; 64: 50–64.
15. Wålinder J, Lundström B, Thuwe I. Prognostic factors in the assessment of male transsexuals for sex reassignment. Br J Psychiatry 1978; 132: 16–20.

Correspondence to:
Jan Eldh, M.D., Ph.D.
Department of Plastic and Reconstructive Surgery
Karolinska Hospital
SE-171 76 Stockholm
Sweden
E-mail: uke@kir.ks.se