Journal of Cranio-Maxillo-Facial Surgery (2010) **38**, 416–422
© 2009 European Association for Cranio-Maxillo-Facial Surgery
doi:10.1016/j.jcms.2009.11.003, available online at http://www.sciencedirect.com

Contouring the forehead and rhinoplasty in the feminization of the face in male-to-female transsexuals

Rupert DEMPF, MD, DDS, PhD, Alexander W. ECKERT, MD, DDS, PhD

Department of Oral and Maxillofacial Plastic Surgery (Head of the Department: Johannes SCHUBERT, MD, DDS, PhD), Martin-Luther-University Halle-Wittenberg, Germany

SUMMARY. **Transsexualism is a gender identity disorder in which there is a strong and ongoing desire to live and be accepted as a member of the opposite sex. In male-to-female transsexuals with strong masculine facial features facial feminization surgery can be performed as part of gender reassignment. The male forehead has extensive supraorbital bossing, and above this there is often a flat area before the convex curvature of the upper forehead begins. In the female, the supraorbital bossing is considerably less, often nonexistent, and above this the flattening is usually less marked and more of a continuous mild curvature. The female nose is relatively smaller than the male nose. The glabellar and the nasolabial angle are less acute. The female nose is regarded as attractive if it shows a straight or mildly concave dorsum and an accented tip. We present a case of treatment of a 26-year-old male-to-female transsexual to demonstrate that contouring the forehead combined with a rhinoplasty can lead to significant feminization of the face. The procedures described seem to be safe and reliable. © 2009 European Association for Cranio-Maxillo-Facial Surgery**

Keywords: **gender identity disorder, feminization surgery, contouring the forehead, rhinoplasty**

INTRODUCTION

Transsexualism is a gender identity disorder (GID) in which there is a strong and ongoing desire to live and be accepted as a member of the opposite sex. Although awareness of the condition frequently begins in childhood, transsexualism is defined by the World Health Organization (WHO) as "a person who is at least eighteen years old, and who has wanted to belong to the other sex for at least two years". Cross-cultural studies in the United States and Great Britain have demonstrated a prevalence of GID of 1:50000, but these figures have been gradually rising (*Benjamin*, 1967; *Hoenig* and *Kenna*, 1974). The prevalence of GID rose in the Netherlands to 1:12900 for men and 1:30400 for women. The rise in the prevalence is possibly due to better acceptance by the public as well as a greater willingness for the transsexual to "come out" (*Gooren*, 1992). Transsexuals feel as if they are "trapped in the wrong body" and often wish to undergo surgical treatment to in order look more like a person of the opposite sex (*Kuiper* and *Cohen-Kettenis*, 1988). In many countries, transsexuals are now treated according to the Standards of Care of the Harry Benjamin International Gender Dysphoria Association, a professional organization in the field of transsexualism. Several studies indicate that gender reassignment therapy can be an effective treatment for the transsexual person because it can improve their subjective well-being (*Ross* and *Need*, 1989; *Eldh* et al., 1997; *Smith* et al., 2005).

To allow appropriate surgical procedures to be carried out to change the shape of a face to the characteristics of the desired sex, it is important to know and understand the anatomical differences between a masculine and a feminine face. Physical anthropologists and forensic pathologists are concerned with the identification and separation of the sex by skulls (*Stewart*, 1954; *Giles* and *Elliot*, 1963; *Giles*, 1964; *Snow* et al., 1970). Prior to computer and discrimination function analysis, these scientists primarily used three skeletal characteristics to separate the male from the female skull: the chin, the nose and the forehead.

The chin is, in general, more pointed in the female.

The nose has a more acute glabellar and nasolabial angle in the male than in the female. The male nose is often more prominent than the female nose and with a dorsal hump or with a straight dorsum. The female nose is regarded as attractive if it is a little bit smaller when compared to the male nose and shows a straight or mildly concave dorsum as well as an accented tip.

The forehead is perhaps the easiest to separate. The male forehead has extensive supraorbital bossing, and above this, there is often a flat area before the convex curvature of the upper forehead begins. In the female, the degree of supraorbital bossing is considerably less, frequently nonexistent, and above this, there is usually less flatness and more of a continuous mild curvature.

These different features between the forehead and the nose in male and female skulls and faces can be seen in Figs. 11–14.

Genital surgery can be an important part of gender reassignment, but it is not a major factor in a transsexual having difficulty obtaining social acceptance as a member of the opposite sex, however other body features can influence this.

The use of female hormones in male-to-female gender reassignment can soften the skin, increase breast size and change fat distribution and body hair (*Moore* et al., 2003). In many cases, depilation treatment of the beard is necessary and the adaptation of the pitch of the voice by a surgical procedure can be reasonable (*Neumann* et al., 2003).

As explained previously, facial dimensions and proportions are notably different between men and women (*Farkas*, 1994). Facial surgery plays an increasingly important role in the gender reassignment process, particularly in male-to-female transsexuals with a strong masculine appearance who may benefit from facial feminization surgery (FFS) (*Becking* et al., 1996).

FFS is the general term for a group of surgical procedures that are used in an attempt to alter the characteristics of the face in male-to-female transsexuals to make them appear more feminine. FFS includes soft tissue procedures, such as rhytidectomy, brow lift, cheek implantation, lip augmentation, as well as corrections of the facial skeleton or cartilage by rhinoplasty (*Noureai* et al., 2007), mandibular angle reduction, genioplasty, bimaxillary osteotomy, zygomatic onlay, zygomatic sandwich osteotomy (*Becking* et al., 2007) and frontal cranioplasty (*Ousterhout*, 1987; *Becking* et al., 2007). The greatest challenges in FFS are managing patient expectations and the selection of appropriate procedures.

In most plastic facial surgery, the aim is to improve the appearance of individuals without changing who they are. Patients state they want to "look like themselves, only younger" or "look like myself, only better". Patients seeking FFS wish to look dramatically different. They want a radical change to their appearance and frequently believe that FFS is their "ticket to a new life".

It is important from the outset that the surgeon reduces any unrealistic expectations the patient may have. He must find out from the patient which features of the face are felt to represent the wrong sex and whether there are suitable procedures to change them to achieve the desired result. He must consider the risks and benefits of the proposed procedures in order to formulate a treatment plan in conjunction with the patient. It is important that the patient is psychologically prepared for the dramatic changes that are intended, and also that they have a realistic expectation of the outcome.

We present a case of FFS which illustrates these elements of gender reassignment surgery.

CASE REPORT

A 26-year-old male-to-female transsexual, who had already had a change to her civil status, was referred to

Fig. 1 – A male-to-female transsexual with extensive frontal bossing and a masculine shape of the nose in lateral view from the right side.

Fig. 2 – The patient in frontal view.

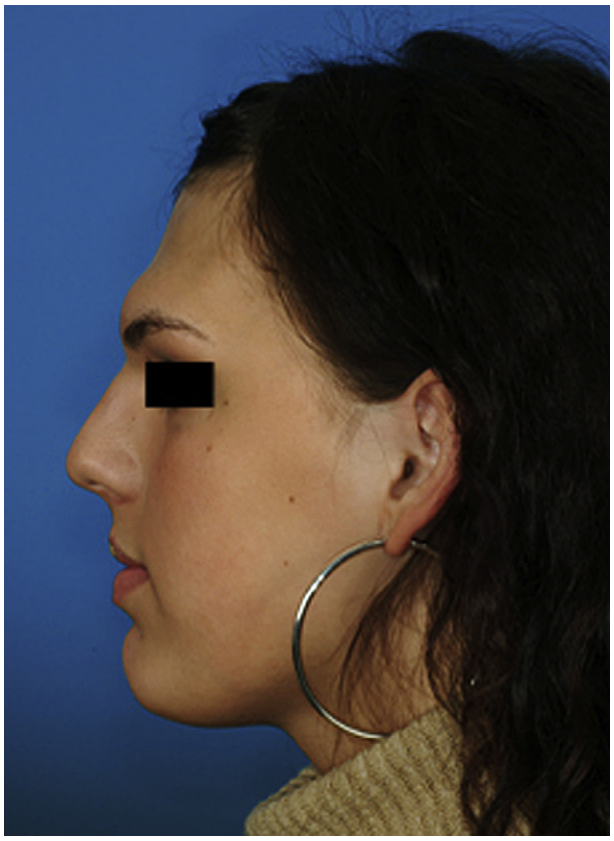

Fig. 3 – The patient in lateral view from the left side.

Fig. 4 – The patient in worm's eye view.

our department. Hormonal therapy, genital reassignment and breast augmentation had already been performed. She wished to change her very masculine facial features into more feminine ones. At her initial consultation she had a photo of a well known actress with her and she wanted to look as like her as possible following FFS. The patient is shown in the Figs. 1–4. In view of the patients lack of knowledge and understanding of the technical aspects of the surgical procedures that would be required, our first task was to convince the patient that she had unrealistic expectations and it would not

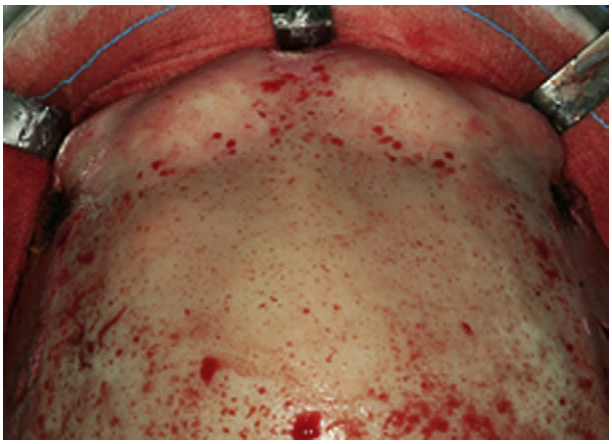

Fig. 5 – The exposed frontal bossing.

Fig. 6 – The anterior wall of the frontal sinus after moving backward and fixation with resorbable plates and screws.

be possible to make her look like the actress. Once she accepted this we photographed the patient and began to analyze which characteristics of her face were responsible for the masculine facial features. We jointly agreed that the extensive frontal bossing was the most strikingly masculine feature of her face. We also agreed that the nose was a little too big. We could not agree whether the chin was either too prominent or too wide.

Having explained to the patient that computer simulations can only be a rough indication of the outcome of surgery, we simulated the planned changes in forehead and nose using a computer programme designed for the purpose. Once we had agreed with the patient what was possible, we gave her some prints of the procedures and described the technical details of the operation to her. We arranged to see her again 2 weeks later. At the next consultation, the patient agreed with the planned changes to forehead and nose, but also said she wanted to have her chin narrowed. Because of the danger of numbness of the lower lip through injury to the mental nerves, she was persuaded against this.

A CT scan was carried to analyze the thickness of the skull bone and the dimension of the frontal sinus for

Fig. 7 – The patient after feminization of the forehead and the nose in lateral view from the right side.

Fig. 8 – The patient in frontal view.

surgical planning. Following this a date for admission for surgery was arranged.

The frontal bossing was reached via subperiosteal coronal approach (Fig. 5). Once fully exposed the borders of the frontal bossing were marked by perforations with a diamond burr. The burr holes were joined with each other and the anterior wall of the frontal sinus was mobilized and moved backwards on the mucosal pedicle until the planned feminine shape was achieved. The fragment then was stabilized by resorbable osteosynthesis plates (Fig. 6). Sharp edges were polished with a burr and the wound was closed. As well as softening the frontal bossing, the nasofrontal angle was increased from 110° to 130°.

A rhinoplasty was then carried out. By a transcolumellar approach and infracartilaginous incisions the soft tissue envelope was elevated and the dorsal hump was reduced with a rasp to achieve a feminine dorsum. Transcutaneous low to low lateral and median osteotomies and complete mobilization of the nasal bones were performed for narrowing the nasal pyramid. To reduce the width of the tip and to refine it, one third of the lateral crura of the alar cartilage was resected. Then interdomal and lateral crura spanning sutures were placed. For tip rotation and increasing the nasolabial angle from 95° to the desired 105° 2 mm of the upper half of the caudal septum were excised. After closure of all incisions intranasal splints and an external cast were placed (Figs. 7–10).

The postoperative course was uneventful. A pleasing aesthetic result was achieved. At her 6 weeks review the patient was very happy with the result. At the 12 and 24 months postoperative reviews the patient remained happy with the result and did not wish for any further surgery.

Note: The operation was carried out by the author in his former clinic, Department of Oral and Maxillofacial Surgery, Medical University Hannover, Germany, under the former Head of the Department: Jarg-Erich HAUSAMEN, MD, DDS, PhD.

DISCUSSION

FFS is not a well known area of surgical practice. If a surgeon begins to specialize in this area, he has to understand that, unlike in aesthetic surgery, patients are looking for surgery that will help to change their personality. Because of this the surgeon has a great responsibility to ensure that the patient has a realistic understanding of the scope and limitation of the possible surgical procedures. To ensure the surgeon can be confident he has fulfilled this responsibility we suggest the following approach:

Firstly, ensure that the patient meets the previously outlined definition of transsexualism according to the WHO.

Next the face of the patient must be analyzed carefully.

If this analysis shows one or more of the typically masculine features in a male-to-female transsexual, it is

Fig. 9 – The patient in lateral view from the left side.

Fig. 10 – The patient in worm's eye view.

important to decide if there is a suitable feminizing surgical procedure available for the desired outcome. In feminization of the forehead, the patients can be divided into two groups.

Group I includes patients with only slight supraorbital bossing, thick skull bone over the frontal sinus and/or absence of the frontal sinus. In these cases, correction can be done by bony reduction alone using a burr without entering the frontal sinus.

Fig. 11 – Female forehead. Note almost total absence of any supraorbital bossing and basically a continuous curve of the forehead in the female forehead. The photograph was done of a skull of the Meckel-anatomical collection and with friendly permission of the institute for anatomy and cell biology of the Martin-Luther University Halle-Wittenberg, Halle/Saale, Germany.

Fig. 12 – Male forehead. Note supraorbital bossing and flatness above the bossing in the male forehead. The photograph was done of a skull of the Meckel-anatomical collection and with friendly permission of the institute for anatomy and cell biology of the Martin-Luther University Halle-Wittenberg, Halle/Saale, Germany.

Group II includes those individuals in whom the frontal bossing is combined with relatively thin bone over the frontal sinuses, the sinuses being of normal or large size. In these individuals, the frontal sinus must be opened through a frontal bone osteotomy and the entire anterior sinus wall and the associated supraorbital rim set back and secured in position. We had obtained familiarity with this technique in the correction of a pneumosinus dilatans (*Dempf* et al., 2005).

Surgery in this group carries a higher risk than in Group 1 because of the potential for loss of the setback frontal bone. There are no reports in the literature of such loss following a FSS, but we know from experience in trauma that the loss of a frontal bone fragment is a rare complication.

In order to allocate the patients to one of the two groups and to plan the operation a CT scan is essential.

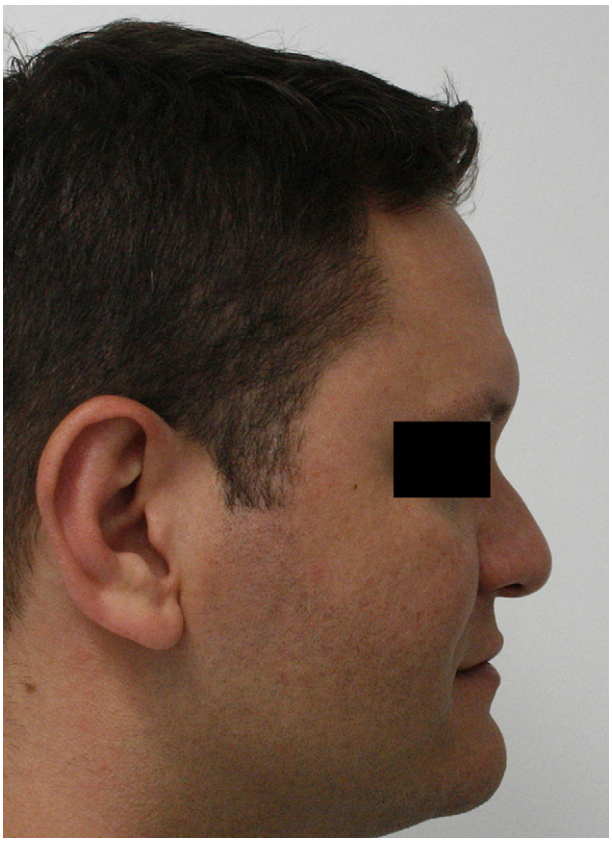

Fig. 13 – Male face. Note the differences between male an female face in the shape of the forehead. Note also the different glabellar and nasolabial angles and different shape of the nose. The photograph was done of one of the author's colleagues with his friendly permission.

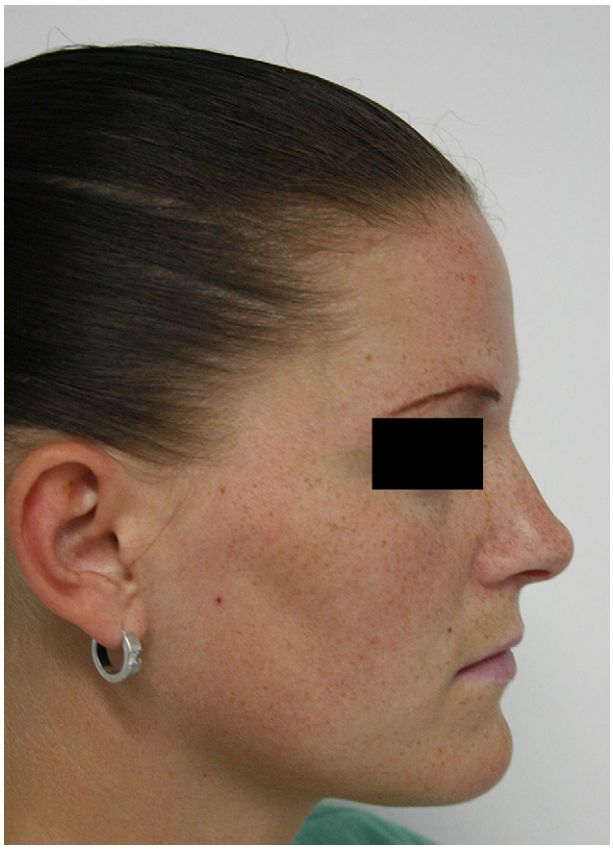

Fig. 14 – Female face. The photograph was done of a nurse of the department with her friendly permission.

The nose is the central structure of the face and plays an important role in the perception of femininity and attractiveness (*Baudouin* and *Tiberghien,* 2004). There is little information in the literature about the differences between the male and female nose information but there is general agreement that the linear dimensions and the bony framework of the female nose, are smaller than those of the male nose and that the nasofrontal and the nasolabial angle in female are higher than in male (*Habal*, 1990; *Daniel* and *Farkas*, 1994; *Farkas* et al., 1994; *Hage* et al., 1997).

Having analyzed these general characteristics, the wishes of the patient must be considered of before starting the detailed planning.

Finally, performing FFS at the end of the gender reassignment therapy helps to minimize the risk of failure.

CONCLUSION

If, in a male-to-female transsexual, the forehead and/or the nose shows the typical male features, we believe that contouring of the forehead and feminization rhinoplasty are save and reliable procedures as parts of gender reassignment.

The techniques used in feminization of the nose are inherently not different to standard procedures. In many of these cases, reduction and refining techniques and widening of the nasolabial angle as described in our case will lead to the wanted feminization. Here we agree with Noureai (*Noureai* et al., 2007) who also described techniques for feminization rhinoplasty in 12 cases. In the presented case, we would have found even more attractive some more tip projection and therefore the use of a tip graft was considered but the patient did not want any significant increase in her tip projection. She argued that a too pointed tip would not match to her appearance and she was happy with the result.

CONFLICT OF INTEREST

All authors disclose any financial and personal conflicts of interests.

References

Baudouin JY, Tiberghien G: Symmetry, averageness, and feature size in the facial attractiveness of women. Acta Psychol (Amst) 117: 313–332, 2004

Becking AG, Tuinzing DB, Hage JJ, Gooren LJ: Facial corrections in male to female transsexuals: a preliminary report on 16 patients. J Oral Maxillofac Surg 54: 413–418, 1996

Becking AG, Tuinzing DB, Hage JJ, Gooren LJ: Transgender feminization of the facial skeleton. Clin Plast Surg 34: 557–564, 2007

Benjamin H: The transsexual phenomenon. Trans NY Acad Sci 29: 428–434, 1967

Daniel RK, Farkas LG: Anthropometric measurements in rhinoplasty: a clinical approach. In: Farkas LG (ed.), Anthropometry of the head and face, New York: Raven Press, 139–150, 1994
Dempf R, Wenzel U, Gundlach KK: Pneumosinus dilatans frontalis: two case reports. J Craniomaxillofac Surg 33: 130–134, 2005
Eldh J, Berg A, Gustafsson M: Long-term follow up after sex reassignment surgery. Scand J Plast Reconstr Surg Hand Surg 31: 39–45, 1997
Farkas LG: Anthropometry of the head and face, New York: Raven Press, 1994
Farkas LG, Hreczko TA, Katic MJ: Craniofacial norms in North America Caucasians from birth (one year) to young adulthood. In: Farkas LG (ed.), Anthropometry of the head and face, New York: Raven Press, 241–335, 1994
Gooren LJ: Transsexualiteit I. Omschrijving, etiologie, hulpverlening. Ned Tijdschr Geneeskd 136: 1893–1895, 1992
Giles E: Sex determination by discriminant function analysis of the mandible. Am J Phys Anthropol 22: 129–135, 1964
Giles E, Elliot O: Sex determination by discriminant function analysis of crania. Am J Phys Anthropol 21: 53–68, 1963
Habal MB: Aesthetics of feminizing the male face by craniofacial contouring of the facial bones. Aesthetic Plast Surg 14: 143–150, 1990
Hage JJ, Becking AG, de Graaf FH, Tuinzing DB: Gender confirming facial surgery: considerations on masculinity and femininity of faces. Plast Reconstr Surg 99: 1799–1807, 1997
Hoenig J, Kenna JC: The prevalence of transsexualism in England and Wales. Br J Psychiatry 124: 181–190, 1974
Kuiper B, Cohen-Kettenis P: Sex reassignment surgery: a study on 141 Dutch transsexuals. Arch Sex Behav 17: 438–457, 1988
Moore E, Wisniewski A, Dobs A: Endocrine treatment of transsexual people: a review of treatment regimes, outcomes, and adverse effects. J Clin Endocrinol Metab 88: 3467–3473, 2003
Neumann K, Welzel C, Berghaus A: Operative Stimmerhöhung Mann Mann-zu-Frau-Transsexuellen. Eine übersicht der Ergebnisse mit eigener Technik. HNO 51: 30–37, 2003
Noureai SA, Randhawa P, Andrews PJ, Saleh HA: The role of nasal feminization rhinoplasty in male-to-female gender reassignment. Arch Facial Plast Surg 9: 318–320, 2007
Ousterhout DK: Feminization of the forehead: contour changing to improve female aestetics. Plast Reconstr Surg 79: 701–713, 1987
Ross MW, Need JA: Effects of adequacy of gender reassignment surgery on psychological adjustment: a follow-up of fourteen male-to-female patients. Arch Sex Behav 18: 145–153, 1989
Smith YL, Van Goozen SH, Kuiper AJ, Cohen-Kettenis PT: Sex reassignment: outcomes and predictors of treatment for adolescent and adult transsexuals. Psychol Med 35: 89–99, 2005
Snow CC, Gatliff BP, McWilliams KR: Reconstruction of facial features from the skull: an evaluation of its usefulness in forensic anthropology. Am J Phys Anthropol 33: 221–228, 1970
Stewart TD: Sex determination of the skeleton by guess and measurement. Am J Phys Anthropol 12: 385–389, 1954

Rupert DEMPF, MD, DDS, PhD
Department of Oral and Maxillofacial Plastic Surgery
Martin-Luther-University Halle-Wittenberg
Ernst-Grube-Straße 40
06120 Halle/Saale
Germany

Tel.: +49 345 557 5245
Fax: +49 345 557 5307
E-mail: rupert.dempf@medizin.uni-halle.de

Paper received 11 July 2009
Accepted 26 November 2009