Query: "Axial CT of the abdomen and retroperitoneum in an elderly patient"

```
Selected Concepts:

1. Feature 853
   Axial CT of the abdomen and
   retroperitoneum in an
   elderly patient
   (mean_act: 0.0518)

2. Feature 1202
   CT of the abdominal
   vasculature, bowel, and
   lumbar spine in a middle-
   aged female patient
   (mean_act: 0.0561)

3. Feature 6969
   Axial CT of the abdomen and
   retroperitoneum in a female
   patient
   (mean_act: 0.0328)
```

Rank 1: s1189
Sim score: 1.000
CT, axial, f, 41y

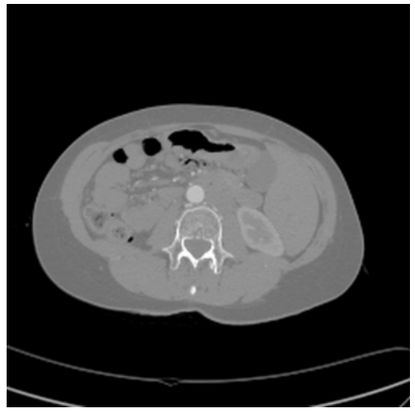

Rank 2: s0864
Sim score: 1.000
CT, axial, f, 57y

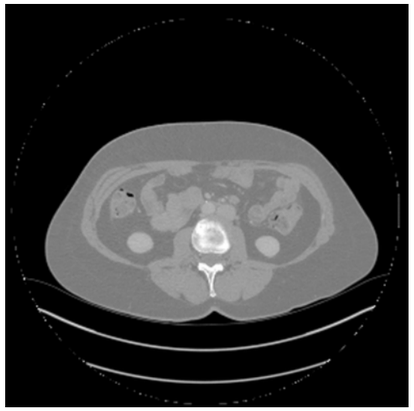

Rank 3: s0916
Sim score: 0.999
CT, axial, m, 65y

Rank 4: s0586
Sim score: 0.999
CT, axial, m, 58y

Rank 5: s0699
Sim score: 0.997
CT, axial, f, 80y

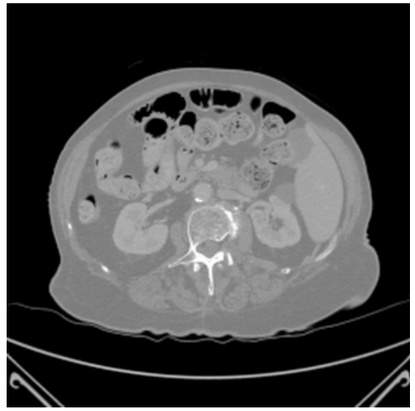

Rank 6: s0764
Sim score: 0.997
CT, axial, f, 75y

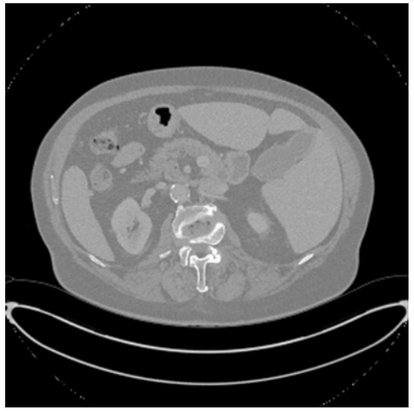

Rank 7: s1098
Sim score: 0.997
CT, axial, f, 56y

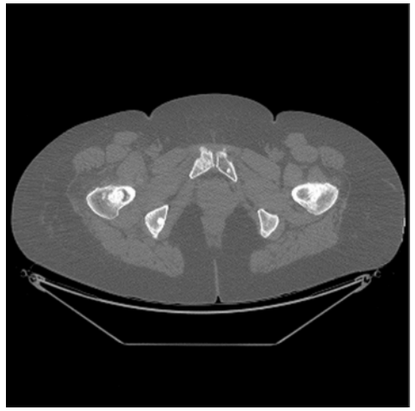
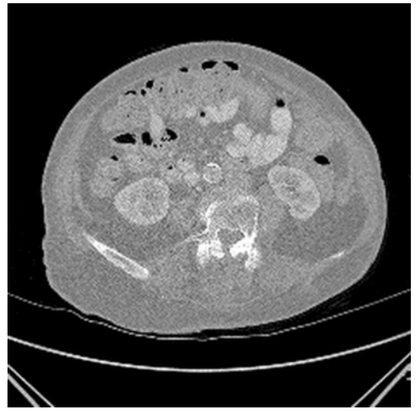
Rank 8: s0551
Sim score: 0.997
CT, axial, f, 82y