Deep Learning Detection of Penumbral Tissue on Arterial Spin Labeling in Stroke

Kai Wang, BS; Qinyang Shou, BS; Samantha J. Ma, MS; David Liebeskind, MD; Xin J. Qiao, MD, MS; Jeffrey Saver, MD; Noriko Salamon, MD, PhD; Hosung Kim, PhD; Yannan Yu, MD; Yuan Xie, MS; Greg Zaharchuk, MD, PhD; Fabien Scalzo, PhD; Danny J.J. Wang, PhD, MSCE

Background and Purpose—Selection of patients with acute ischemic stroke for endovascular treatment generally relies on dynamic susceptibility contrast magnetic resonance imaging or computed tomography perfusion. Dynamic susceptibility contrast magnetic resonance imaging requires injection of contrast, whereas computed tomography perfusion requires high doses of ionizing radiation. The purpose of this work was to develop and evaluate a deep learning (DL)–based algorithm for assisting the selection of suitable patients with acute ischemic stroke for endovascular treatment based on 3-dimensional pseudo-continuous arterial spin labeling (pCASL).

Methods—A total of 167 image sets of 3-dimensional pCASL data from 137 patients with acute ischemic stroke scanned on 1.5T and 3.0T Siemens MR systems were included for neural network training. The concurrently acquired dynamic susceptibility contrast magnetic resonance imaging was used to produce labels of hypoperfused brain regions, analyzed using commercial software. The DL and 6 machine learning (ML) algorithms were trained with 10-fold cross-validation. The eligibility for endovascular treatment was determined retrospectively based on the criteria of perfusion/diffusion mismatch in the DEFUSE 3 trial (Endovascular Therapy Following Imaging Evaluation for Ischemic Stroke). The trained DL algorithm was further applied on twelve 3-dimensional pCASL data sets acquired on 1.5T and 3T General Electric MR systems, without fine-tuning of parameters.

Results—The DL algorithm can predict the dynamic susceptibility contrast–defined hypoperfusion region in pCASL with a voxel-wise area under the curve of 0.958, while the 6 ML algorithms ranged from 0.897 to 0.933. For retrospective determination for subject-level endovascular treatment eligibility, the DL algorithm achieved an accuracy of 92%, with a sensitivity of 0.89 and specificity of 0.95. When applied to the GE pCASL data, the DL algorithm achieved a voxel-wise area under the curve of 0.94 and a subject-level accuracy of 92% for endovascular treatment eligibility.

Conclusions—pCASL perfusion magnetic resonance imaging in conjunction with the DL algorithm provides a promising approach for assisting decision-making for endovascular treatment in patients with acute ischemic stroke. **(*Stroke*. 2020;51:489-497. DOI: 10.1161/STROKEAHA.119.027457.)**

Key Words: arterial spin labeling ■ deep learning ■ magnetic resonance imaging ■ perfusion imaging ■ stroke

Downloaded from http://ahajournals.org by on February 16, 2020

Recent clinical trials have shown that acute ischemic stroke (AIS) patients with specific patterns of penumbral tissue—the volume of brain tissue that is ischemic but not yet infarcted—can benefit from endovascular reperfusion therapy beyond the typical 6-hour treatment window from symptom onset.[1,2] Computed tomography perfusion (CTP) imaging and dynamic susceptibility contrast (DSC) perfusion magnetic resonance imaging (MRI) are commonly used to estimate the penumbral tissue to select suitable patients with AIS for endovascular therapies. CTP is more commonly used in emergency settings because of its speed and accessibility. However, it requires a high dose of ionizing radiation because of the continuous radiograph exposure during the passage of iodinated contrast media, which has its own risk of allergic reactions (≈0.2% incidence).[3] There is also debate on the accuracy of CTP in delineating the infarct core of AIS.[4] Diffusion-weighted MRI is regarded as the imaging standard for defining the extent of infarct core. DSC perfusion MRI relies on the injection of gadolinium-based contrast agent that is not suitable for patients with renal dysfunction. As most patients with AIS are aged people presenting with vascular risks (eg, diabetes mellitus), a mandatory step (and additional

Received August 22, 2019; final revision received October 24, 2019; accepted November 14, 2019.

From the Stevens Neuroimaging and Informatics Institute, Keck School of Medicine of USC, Los Angeles (K.W., Q.S., S.J.M., H.K., D.J.J.W.); Department of Neurology (D.L., J.S., F.S.) and Department of Radiology (X.J.Q., N.S.), University of California, Los Angeles; and Department of Radiology, Stanford University, Palo Alto, CA (Y.Y., Y.X., G.Z.).

Guest Editor for this article was Seemant Chaturvedi, MD.

The online-only Data Supplement is available with this article at https://www.ahajournals.org/doi/suppl/10.1161/STROKEAHA.119.027457.

Correspondence to Danny J.J. Wang, PhD, MSCE, Laboratory of FMRI Technology, Mark and Mary Stevens Neuroimaging and Informatics Institute, Keck School of Medicine, University of Southern California, Los Angeles, CA. Email jwang71@gmail.com

© 2019 American Heart Association, Inc.

time) is required to rule out contraindications for gadolinium-based contrast agents for DSC perfusion MRI.

Arterial spin labeling (ASL) MRI techniques can provide cerebral blood flow (CBF) measures without the use of contrast agent, and it has been shown to provide largely consistent results with DSC perfusion MRI in delineating hypoperfused brain regions in AIS.[5,6] ASL may be particularly suitable for patients with renal dysfunction or vulnerable populations such as children and pregnant women who are at risk of strokes.[7,8] The scan time for ASL is generally on the order of ≈5 minutes with CBF maps generated almost immediately with vendor or custom software. However, the precise delineation of hypoperfusion lesion and penumbra in ASL images remains challenging because of the low signal-to-noise ratio and delayed arterial transit.

Recently, machine learning (ML) methods have been applied for the diagnosis and management of stroke, such as the prediction of clinical outcome of patients with AIS.[9,10] Machine learning models use algorithms to parse data, learn features from that data, and make informed decisions based on the learning with some user guidance. Deep learning (DL) is an advanced ML method that takes the intelligent decision-making one step further by using the neural network architecture resembling that is used for human visual perception.[11] DL is able to capture the hierarchical and complex features of the input image automatically and can identify, classify, and quantify patterns in medical images.[12,13] In this study, we developed and evaluated a DL-based algorithm to automatically identify the hypoperfusion lesion and penumbra in ASL images (in conjunction with diffusion MRI), using the perfusion lesions in DSC perfusion MRI as supervision.

Downloaded from http://ahajournals.org by on February 16, 2020

Methods

The original data that support the findings of this study are available from the corresponding author on request.

Patient Selection

The present study included data from 2 AIS cohorts: data from the first cohort were collected from June 2010 to September 2013 in a registry of patients evaluated with diffusion-perfusion MRI at the University of California, Los Angeles (UCLA) Medical Center. Data from the second cohort were collected from August 2014 to March 2018 at the Stanford University Medical Center. Patients with AIS were included in this study if (1) they were adults (aged >18 years); (2) they received an established clinical diagnosis of AIS; (3) ASL, DSC, and diffusion-weighted imaging (DWI) data were acquired; (4) acute ischemic lesion was detected in DWI; and (5) there was an absence of previous intracranial hemorrhage, brain surgery, or large territorial lesion. The Institutional Review Board of UCLA approved this study and waived requirement for informed consent. The Institutional Review Board of Stanford University approved this study, and informed consent was obtained from the participants.

MRI Protocols and Analysis

All MRIs of the UCLA cohort were performed on Siemens 1.5T Avanto or 3.0T TIM Trio systems (Erlangen, Germany). A pseudo-continuous ASL (pCASL) pulse sequence with background suppressed 3-dimensional GRASE (gradient and spin echo) readout was applied with the following parameters: repetition time (TR)/echo time (TE)/label time, 4000/22/1500 ms; field of view, 22 cm; matrix size, 64×64, 26×5 mm slices; postlabeling delay, 2000 ms; scan time, 4 to 5 minutes.[5,6] CBF maps were generated with custom software using Interactive Data Language (Boulder, CO) that included motion correction, pairwise subtraction between label and control images, averaging to generate the mean difference image, and the calculation of quantitative CBF maps.[5,6]

All MRIs of the Stanford cohort were acquired on GE 1.5T and 3.0T SIGNA systems (Milwaukee, WI) using a 3-dimensional pCASL sequence with fast-spin echo readout and stack-of-spirals readout trajectory. Imaging parameters were: TR/TE/label time, 4852/11/1500 ms; postlabeling delay, 2025 ms; field of view, 24 cm; matrix size, 64×64, 36×4 mm slices; scan time, ≈5 minutes. CBF maps were generated with vendor software.[14]

DSC images were acquired using a gradient-echo echo-planar imaging sequence with a timed contrast-bolus passage technique (0.1 mg/kg contrast administered intravenously at a rate of 5 mL/s), with a TR range of 1770 to 2890 ms and average TE of 44±10.4 ms; matrix, 128×128. Following motion correction and spatial smoothing, multiparametric perfusion maps including CBF, cerebral blood volume, time to the maximum of the tissue residue function (Tmax), and mean transit time were generated using a method based on block-circulant singular value decomposition implemented in the commercial software OLEA (La Ciotat, France) for the UCLA cohort. The RAPID software (iSchemaView, Inc, Menlo Park, CA)[15] was used for analyzing DSC data from the Stanford cohort.

DWIs were acquired with b value of 1000 s/mm^2, and range values of TR and TE were 3500 to 6000 and 78 to 118 ms, respectively. The matrix size was 128×128. Apparent diffusion coefficient (ADC) images were calculated with vendor software. ASL CBF and DSC images were coregistered with DWI in each subject using SPM12 (https://www.fil.ion.ucl.ac.uk/spm/software/spm12/) and normalized into the Montreal Neurological Institute template space using SPM12.

The flowchart for the training and evaluation of the DL algorithm is shown in Figure 1, which includes modules of data input, DL model architecture, and voxel-level and subject-level evaluation. The following describes each step in detail.

Creating Label Images of DSC Perfusion Lesion

All calculated Tmax maps, extracted arterial input function, and venous outflow function were inspected by an expert of perfusion MRI (D.J.J.W.). Data were excluded if the arterial input function failed to show clear bolus passage or there were severe motion artifacts. The Tmax maps generated by the OLEA software for the UCLA cohort often contained speckle noise or residual motion artifacts on brain edges; therefore, the following denoising steps were applied to reliably identify the perfusion lesions: (1) skull stripping using the BET program[16]; (2) brain segmentation using FSL FAST[17]; and ventricles masking with the segmented cerebrospinal fluid regions; (3) manually setting a bounding box to include perfusion lesions; and (4) applying a threshold with Tmax ≥6 seconds. The resultant binary maps were used as label images for training neural networks, with the foreground being hypoperfusion regions. For the Stanford cohort, the perfusion lesion with Tmax ≥6 seconds was automatically generated by the RAPID software. In previous MRI and positron emission tomography studies,[18,19] Tmax lesions >2 seconds often overestimated the volume of penumbral tissue, whereas stricter thresholds (>8 seconds) underestimated the volume of hypoperfused tissue. Based on these studies and recent clinical trials,[1,18,20] Tmax ≥6 seconds was chosen to define hypoperfusion lesions in this study.

Deep Neural Network Architecture and Training

The network used in this project was the Highres3Dnet,[21] which offers compact end-to-end 3-dimensional convolutional neural network structures that maintain high-resolution multiscale features (Figure 1). The Highres3Dnet was implemented using TensorFlow and NiftyNet.[22] It included 20 trainable layers with dilated convolution and dilating factors of 1, 2, and 4, respectively. Residual connections were used for every 2 convolution layers. The network was trained on 2 Nvidia GeForce GTX 1080 Ti GPUs. CBF and ADC images were used as input, and the label image from Tmax served as the supervision. Volumes (48×48×48; batch size, 4) were randomly extracted from 3-dimensional preprocessed input and label images

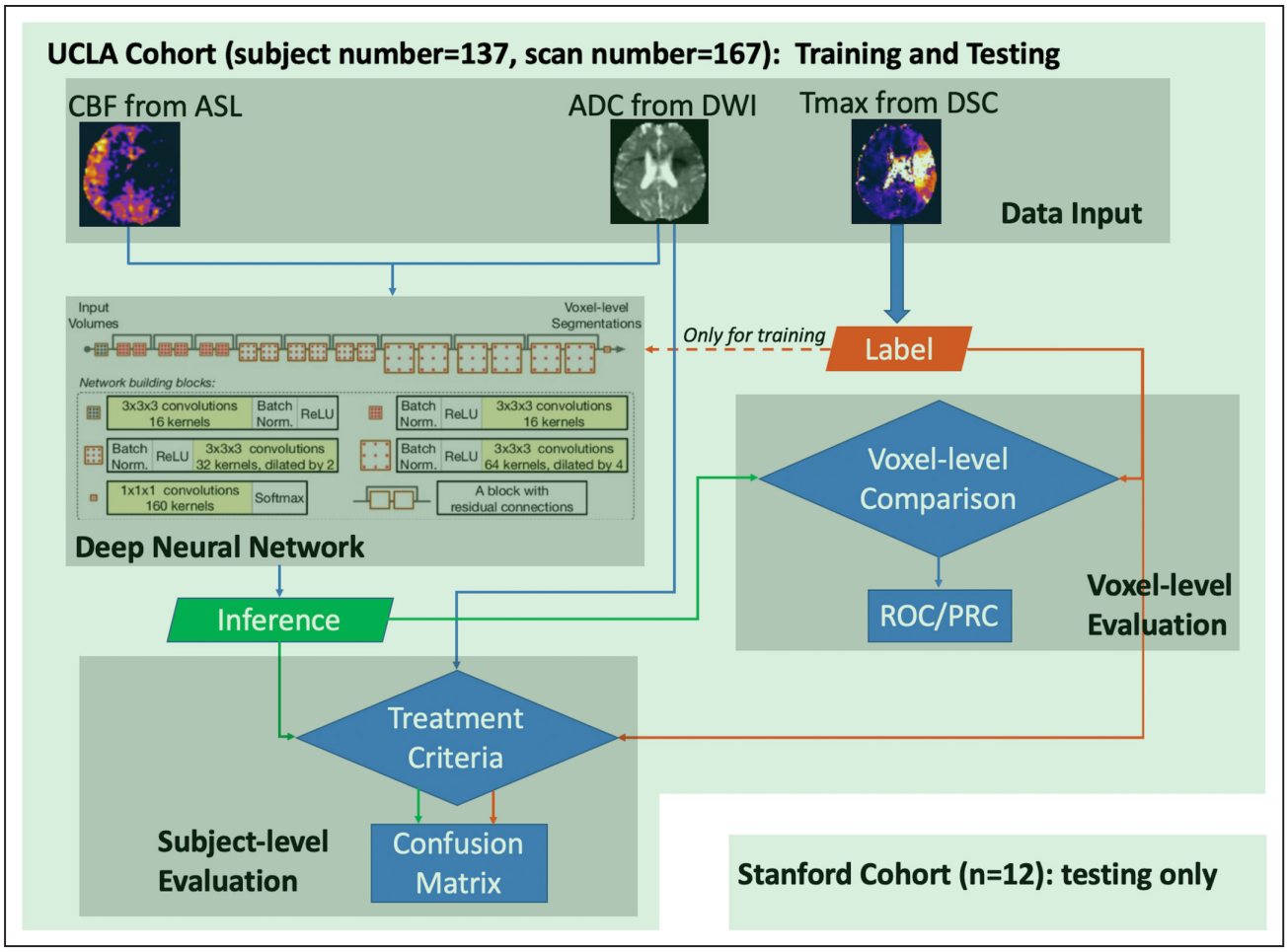

Figure 1. Flowchart of the training and evaluation of deep learning model. Dynamic susceptibility contrast (DSC) magnetic resonance imaging scans were first processed to generate parameter maps (cerebral blood flow [CBF], apparent diffusion coefficient [ADC], and time to the maximum of the tissue residue function [Tmax]), then the data were used to train the deep neural network. After training, inference was made and evaluated at voxel level and subject level. The University of California, Los Angeles (UCLA) cohort was used for both training and testing, whereas the Stanford cohort was only used for testing purposes. ASL indicates arterial spin labeling; DWI, diffusion-weighted imaging; PRC, precision-recall curve; ReLU, rectified linear unit; and ROC, receiver operating characteristic.

for training. Volume-level augmentation was used, including rotation with a random angle in the range of −10° to 10° for each of the 3 orthogonal planes and spatial rescaling with a random scaling factor in the range of 0.9 to 1.1. The Dice loss function[23] and Adam optimization method[24] (learning rate, 0.0001; $\beta1=0.9$; $\beta2=0.999$) were used. The total iteration number was set to 70 000 to enable the training process to reach steady state. The hyperparameters of the network (eg, layer number, volume size, and iteration number) were determined based on pretraining on a fixed validation data set.

We performed the 10-fold cross-validation, in which individuals from the UCLA cohort were first divided into 10 groups. For each fold of the cross-validation, 9 groups were used as the training set and the remaining one designated as the testing set. After the process was repeated 10×, the whole dataset was tested.

Machine Learning Models and Training

For comparison, 6 commonly used ML classifiers were trained on the same UCLA cohort, including linear regression classifier, ridge regression classifier, kernel ridge regression classifier, neural network classifier, Support Vector Machine with radial basis function, and random forest classifier.[25] The same 10-fold cross-validation scheme as used in the training of the DL model was applied: for each fold, ten thousand 13×13 patches were randomly selected from the training set, half of which the central voxel was positive voxels in the label image and the other half of which the central voxel was negative. Once the models were trained on the 10 000 patches, inference was determined voxel by voxel on the testing set, where the classifier utilized the 13×13 patch around the central voxel to be inferred.

DL Model Performance Assessment

The DL model performance was evaluated on a subset of the UCLA cohort, herein referred to as the evaluation cohort. The inclusion criteria for the evaluation cohort were adopted from the DEFUSE 3 trial (Endovascular Therapy Following Imaging Evaluation for Ischemic Stroke)[1]: patients who had an occlusion of the intracranial internal carotid artery or the proximal middle cerebral artery, and the last known well time was within 16 hours of the MRI. The performance assessment was done both at voxel level and subject level. For voxel-level evaluation, the Dice coefficient was first calculated between the inference and the Tmax label for each subject, and the group average Dice was subsequently calculated for all subjects of the evaluation cohort. Then, 100 000 voxels were randomly selected from the DSC perfusion maps of evaluation cohort, of which 50 000 were picked from positive voxels in the label images and the remaining 50 000 were negative voxels (to control for imbalanced positive and negative voxels in our data). Receiver operating characteristic (ROC) curves and precision-recall curves were calculated on the 100 000 voxels for the DL and 6 ML models, and the corresponding area under the curve (AUC) was calculated, respectively.

Subject-level performance assessment was based on the imaging criteria for endovascular thrombectomy of the DEFUSE 3 trial[1]: (1) the initial infarct volume (ischemic core), identified as regions of ADC $<620\times10^{-6}$ mm^2/s, is <70 mL[26]; (2) the volume of ischemic

Downloaded from http://ahajournals.org by on February 16, 2020

tissue is 1.8× the volume of initial infarct volume or more; (3) the volume of potentially reversible ischemia (penumbra) is ≥15 mL. For the evaluation cohort of patients with AIS, the endovascular treatment eligibility was determined first with ADC and DSC Tmax label maps, then with ADC images and predicted ASL hypoperfusion lesion from the trained model. Confusion matrices, as well as sensitivity, specificity, positive predictive value, negative predictive value, the total accuracy, and Cohen-κ coefficient, were also calculated[27] for the DL and 6 ML models, respectively.

The above subject-level evaluation used the optimal cutoff threshold determined by voxel-wise training/evaluation of the 6 ML methods, respectively, while 0.5 was used for the DL method. We further varied the threshold for binarizing the DL/ML model output and calculated the ROC curves for selecting subjects eligible for endovascular treatment within the evaluation cohort of patients with AIS.

Evaluation of the Generalizability of DL Model

To further test the generalizability of our DL model, we applied the DL model on the Stanford cohort. Inference was made based on the ADC and CBF maps, without fine-tuning model parameters. Since the 10 models built through the 10-fold validation generated 10 hypoperfusion lesion probability maps for an individual, we used the consensus map of the 10 predicted lesions for evaluation, which was generated by averaging the 10 probability maps of the 10 models and subsequently binarized with threshold of 0.5. Both voxel-level and subject-level evaluations with the same criteria as described above were performed, except that for voxel-level evaluation, a smaller number of voxels (10 000) was sampled because the data set was smaller compared with the UCLA dataset.

Results

Patients

For the UCLA cohort, a total of 167 image sets from 137 patients were included for network training (1.5T: n=93; 3T: n=74). Each patient had 1 to 3 MRIs. For the purpose of maximizing the training data sets and improving the robustness of the DL model when dealing with different subtypes of strokes, we used all available MRIs rather than only baseline scans or patients with anterior circulation stroke. For the Stanford cohort, 12 MRIs (1.5T: n=1; 3T: n=11) from 12 patients were randomly selected for the evaluation of the generalizability of DL model. The clinical and demographic information of the UCLA cohort and Stanford cohort is listed in Tables I and II in the online-only Data Supplement, respectively.

Neural Network Identification of ASL Hypoperfusion Lesions

Figure 2 shows 4 representative cases at 1.5T and 4 representative cases at 3T from the UCLA cohort, respectively. For each case, ADC, DSC Tmax, and ASL CBF maps are displayed in the first 3 columns, respectively. The predicted and Tmax label of perfusion lesions are overlaid on the T2-weighted image of DWI (the fourth column). At each field strength, 2 cases with predicted>Tmax label perfusion lesion (row 1, 2)

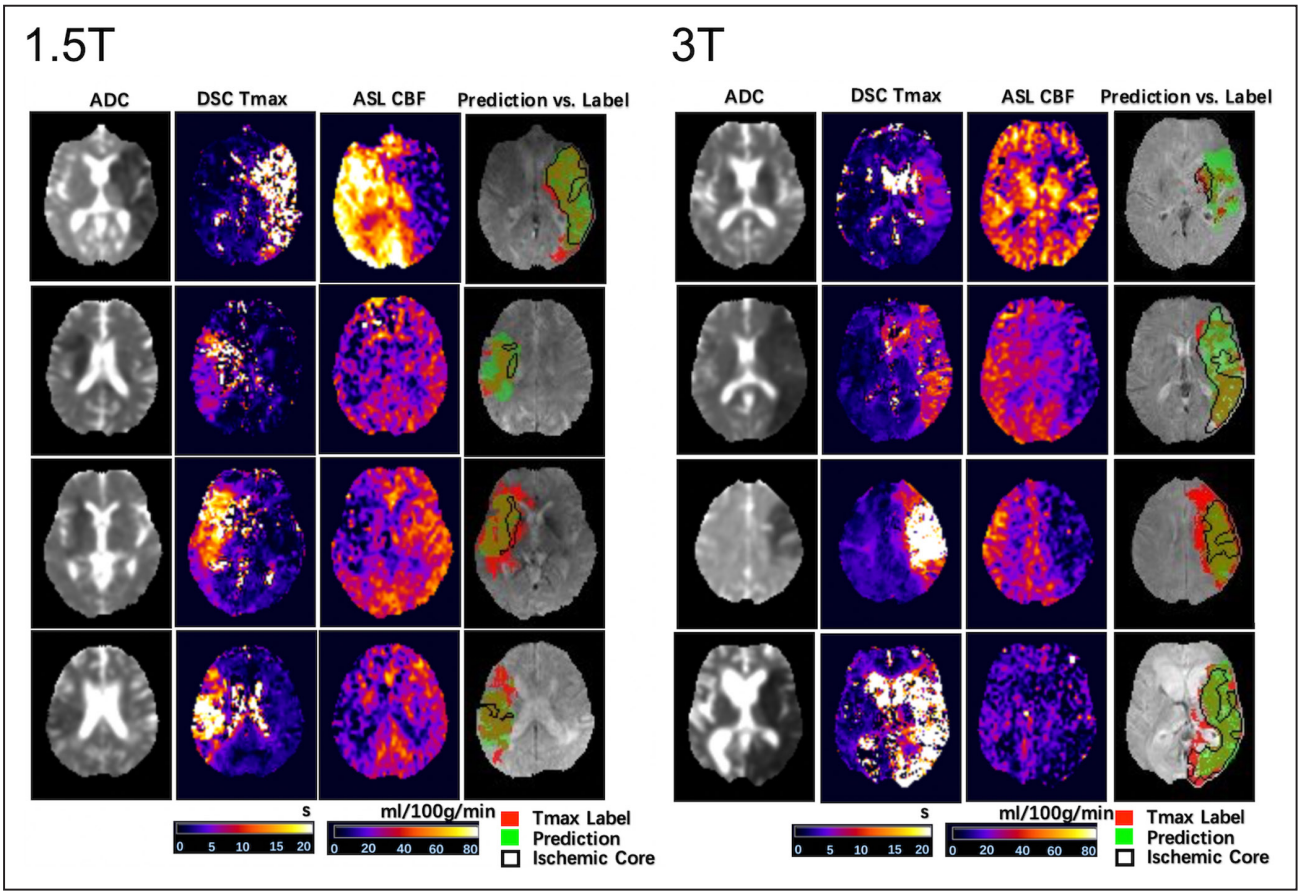

Figure 2. Four representative cases at each field strength showing the input images, label, and inference. For each case, apparent diffusion coefficient (ADC), dynamic susceptibility contrast (DSC) time to the maximum of the tissue residue function (Tmax), and arterial spin labeling (ASL) cerebral blood flow (CBF) are displayed in the first 3 columns, respectively. The predicted and Tmax label of perfusion lesions are overlaid on the T2-weighted image of diffusion-weighted imaging. At each field strength, 2 cases with predicted >Tmax label perfusion lesion and 2 cases with predicted <Tmax label are shown. Only the second case of 1.5T was misclassified.

Downloaded from http://ahajournals.org by on February 16, 2020

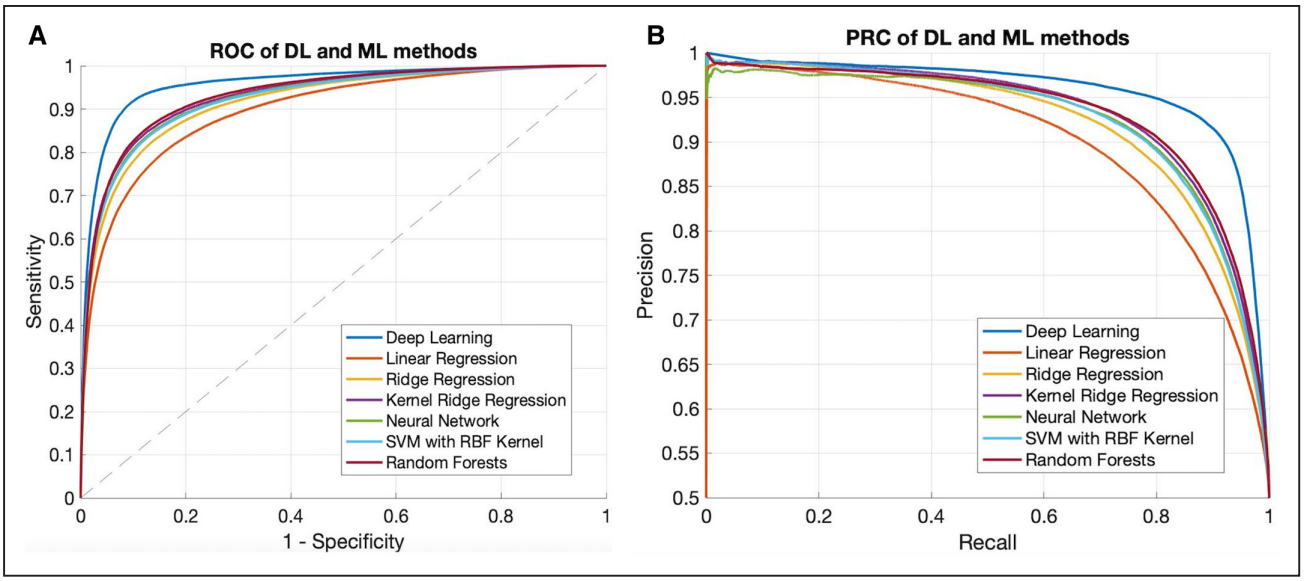

Figure 3. Voxel-level evaluation performance comparison of DL and ML models. **A**, Receiver operating characteristic (ROC) of the deep learning (DL) model and machine learning (ML) models on the evaluation voxel set. With area under the curve (AUC) of 0.958, DL model showed significantly superior performance (P<0.001) compared with traditional ML models (AUC, 0.897, 0.918, 0.930, 0.925, 0.924, and 0.933 for the 6 methods in the legend, respectively). **B**, Precision-recall curves of the DL model and ML models. Significantly superior performance of the DL model was confirmed by precision-recall curve (AUC, 0.957; P<0.001), compared with 6 ML models (AUC, 0.790, 0.802, 0.809, 0.804, 0.806, and 0.932), respectively. PRC indicates precision-recall curve; RBF, radial basis function; and SVM, Support Vector Machine.

and 2 cases with predicted<Tmax label (row 3, 4) are shown. Only the second case of 1.5T was misclassified. Overall, the network could identify the perfusion lesion defined by Tmax images although there were discrepancies between the lesion volumes of ASL and DSC MRI.

Evaluation of DL Prediction Accuracy

Thirty-eight patients with AIS of the UCLA cohort with large vessel occlusion in the anterior circulation met the inclusion criteria of DEFUSE 3, which served as the evaluation cohort. For voxel-level evaluation, the group average Dice coefficient was 0.47±0.23. The ROC curves showed that our DL model was able to achieve significantly superior performance compared with the 6 traditional ML methods (P<0.001). The AUC of our DL model was 0.958, whereas the AUC of the 6 ML models varied from 0.897 to 0.933 (Figure 3A). The precision-recall curves showed similar results with the DL model yielding the highest AUC of 0.957, while the AUC of the 6 ML models varied from 0.790 to 0.932 (P<0.001; Figure 3B).

Subject-level evaluation was performed according to the imaging criteria for endovascular thrombectomy of the DEFUSE 3 trial. The sensitivity, specificity, positive predictive value, negative predictive value, and Cohen-κ coefficient were 0.89, 0.95, 0.94, 0.90, and 0.84, respectively (the corresponding confusion matrix is shown in Table III in the online-only Data Supplement). The accuracy was 0.92 (95% CI, 0.79–0.98). In comparison, the accuracy, sensitivity, specificity, positive predictive value, negative predictive value, and Cohen-κ coefficient (Table IV in the online-only Data Supplement), were also calculated for the 6 ML methods. The highest accuracy among the 6 ML models was 0.84 (95% CI, 0.69–0.94). When the cutoff threshold was varied to generate ROC curves, although without significant differences, the DL model still yielded the highest AUC of 0.950, while the AUC of ML algorithms ranged from 0.915 to 0.949.

Cross-Validation on Stanford Cohort

Our pretrained DL models were tested on the 12 patients of the Stanford cohort scanned on GE 1.5T and 3T MR scanners, without any fine-tuning of parameters. The results from the consensus maps of the 10 models are reported here. Three cases are shown in Figure 4 with the same layout as Figure 2 (2 correctly and 1 incorrectly classified for treatment). The average Dice coefficient was 0.43±0.25. Voxel-level evaluation showed that the AUC of the ROC and precision-recall curve was 0.942 (Figure 5A) and 0.931 (Figure 5B), respectively. Only 1 among the 12 tested subjects was classified incorrectly (the corresponding confusion matrix is shown in Table V in the online-only Data Supplement). Subject-level evaluation yielded an accuracy of 0.92 (95% CI, 0.62–0.99), with sensitivity, specificity, positive predictive value, and negative predictive value of 0.75, 1.00, 1.00, and 0.89, respectively. Prediction of subject-level treatment eligibility in the Stanford cohort was highly reproducible as all the 10 DL models trained on the UCLA cohort yielded the same accuracy of 0.92.

The bottom row of Figure 4 shows the case that was incorrectly classified for treatment eligibility. The DL model still identified hypoperfusion lesions on ASL CBF; however, the hyperperfusion signals (arrow) likely arising from delayed arterial transit effects restricted the predicted lesion volume to be below the threshold for perfusion/diffusion mismatch.

Discussion

Recent randomized clinical trials have consistently reported positive outcomes by utilizing CTP and DSC MRI to identify and quantify the penumbral tissue, using automated postprocessing

Downloaded from http://ahajournals.org by on February 16, 2020

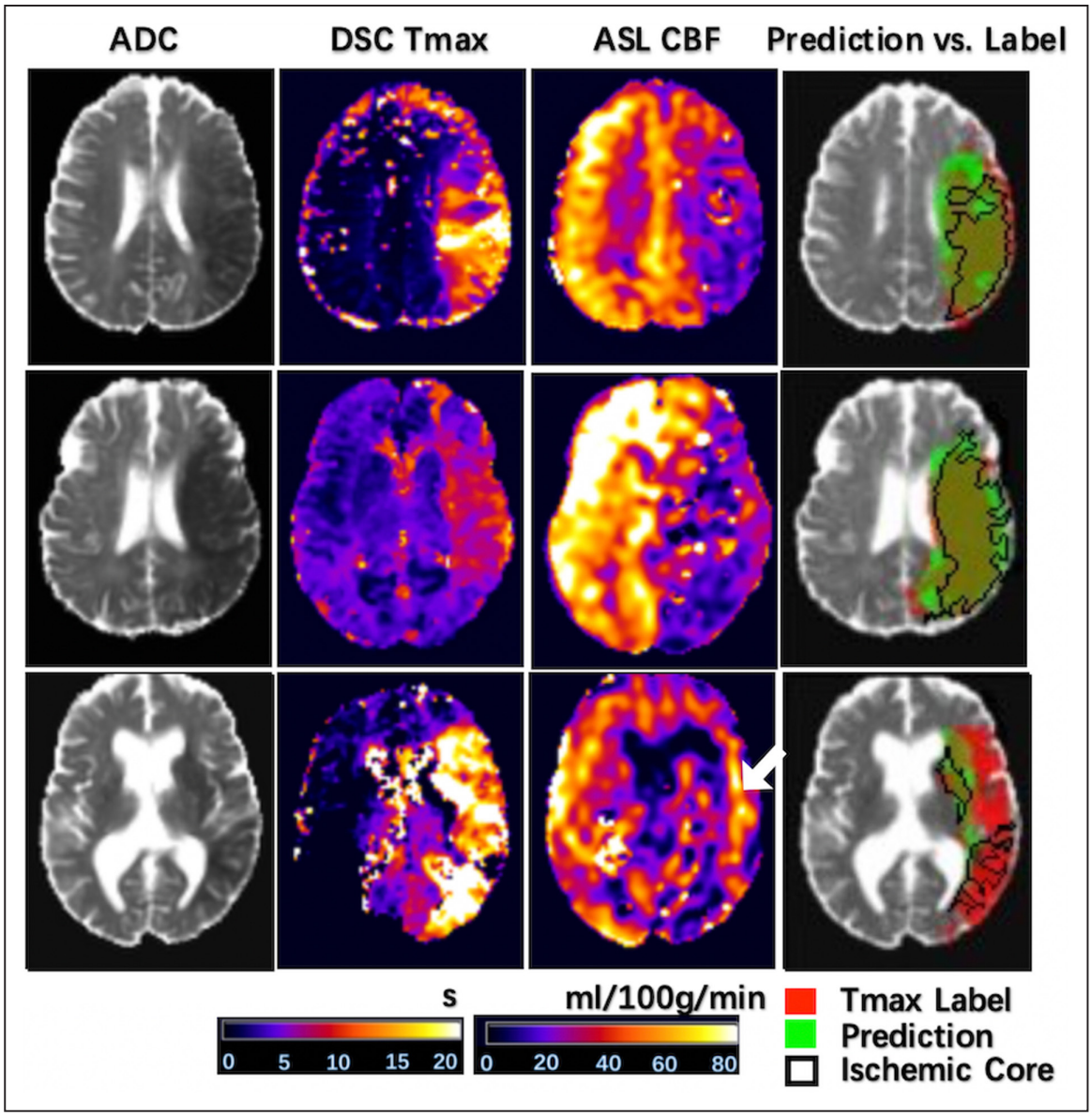

Figure 4. Three representative cases of the Stanford cohort showing the input images, inference, and label. The same layout is used as in Figure 2. The first two were correctly classified, whereas the third one was misclassified. The arrow indicates hyperperfusion signal likely arising from delayed arterial transit effects. ADC indicates apparent diffusion coefficient; ASL, arterial spin labeling; CBF, cerebral blood flow; DSC, dynamic susceptibility contrast; and Tmax, time to the maximum of the tissue residue function.

Downloaded from http://ahajournals.org by on February 16, 2020

software such as RAPID.[1,2,28–30] In this project, we trained DL models to assist the decision-making for endovascular thrombectomy with noncontrast ASL images, using the hypoperfusion lesion observed on DSC MRI as the label. The DL models were able to consistently achieve an accuracy of 92% for imaging-based criteria for endovascular therapy in 2 independent cohorts of AIS patients scanned on Siemens and GE MRI scanners at 1.5T and 3T. If verified in randomized clinical trials, DL-based algorithms may have several advantages compared with existing methods using CTP and DSC MRI. With the proposed method, any AIS patients including the elderly, children, and pregnant women can be evaluated, as long as they do not have contraindications for MRI. As diffusion MRI is considered the gold standard for delineating the infarct core, an entirely noninvasive MRI protocol including ASL perfusion and diffusion MRI could potentially improve the diagnostic accuracy and ischemic tissue characterization for AIS patients compared with CTP. Past studies have shown that the infarct cores identified by diffusion MRI and CTP often do not match each other.[31,32] Because patients with AIS regularly undergo multiple MRIs without concerns of ionizing radiation, ASL scans can be repeated as often as required to follow disease progression. With sufficient clinical evidence, the proposed method may extend the treatment window to subacute stages and may assist in the management of reperfusion injury.[33,34]

DL-based prediction of hypoperfusion lesions is instantaneous (<1 s/subject), while the postprocessing of CTP and DSC MRI takes a few minutes using RAPID software[35]; although the net time for CTP and DSC MRI scanning is only 1 to 2 minutes, additional time and staffing is required for the preparation of

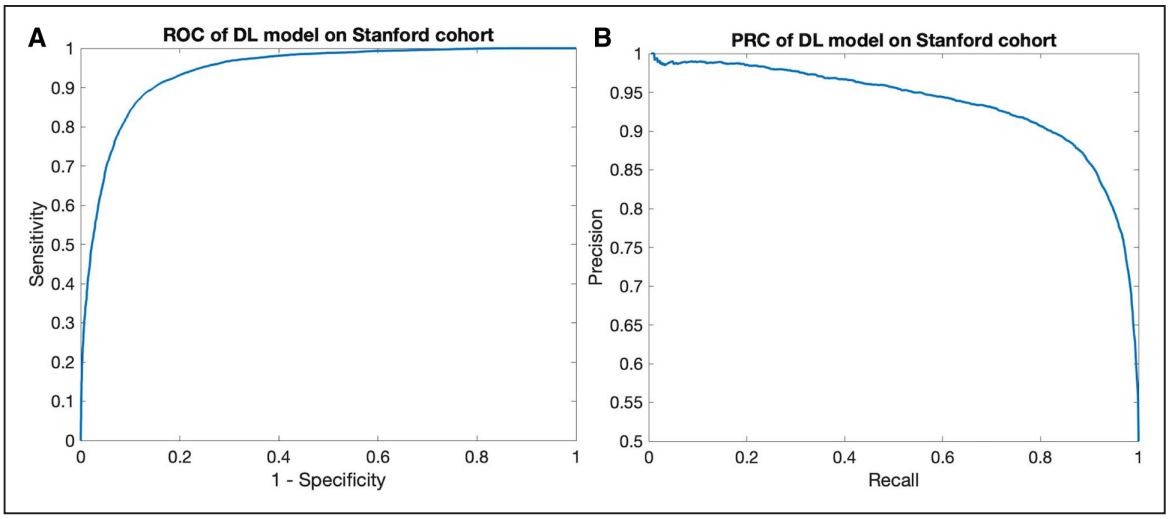

Figure 5. Voxel-level evaluation performance of deep learning (DL) model on the Stanford cohort. Receiver operating characteristic (ROC) curve (**A**) and Precision-recall curve (**B**) on evaluation voxel set of the Stanford cohort. Without any parameter fine-tuning, our DL model achieved reasonable performance on the 10 000-voxel evaluation set, with area under the curve of 0.942 for the ROC curve and 0.931 for the precision-recall curve (PRC).

contrast injection and in the case of DSC MRI, to rule out contraindications for gadolinium-based contrast agents. Therefore, the total time for ASL scanning (≈5 minute), CBF calculation (seconds), and DL prediction of penumbra (<1 second) could be shorter than that required for CTP and DSC MRI scanning and postprocessing. It is worth noting that fast ASL scanning within 1 to 2 minutes is feasible with DL-based denoising.[36,37] The potentially lower overhead for time and management of patient safety with the proposed method could be clinically significant in AIS treatment, given that time is brain.

Machine learning and in particular, DL algorithms are ideally suited for ASL imaging in stroke. Although ASL has been shown to provide largely consistent results with DSC MRI in delineating hypoperfused brain regions in AIS,[5,6] in practice, ASL at a single postlabeling delay (eg, 2 seconds) tends to overestimate hypoperfusion lesion volume due to delayed arterial transit effects. On the contrary, delayed arterial transit effects in ASL images may indicate collateral flow.[38] However, there are no objective criteria for their radiographic definition and interpretation. The low signal-to-noise ratio of ASL images also makes it difficult to determine the boundary of the hypoperfusion lesion. Although often criticized as a black box, advanced ML and DL algorithms offer powerful tools to extract complex features from multidimensional data without explicit characterization of these features. In the present study, our DL model apparently realized multiple functions including denoising of ASL images, integration with diffusion MRI, and segmentation of hypoperfusion lesions. The DL algorithm outperformed 6 ML methods that were trained on the same data set acquired on Siemens MR scanners, and it was demonstrated that the DL algorithm can be generalized to an independent data set collected on GE MR scanners. Although different commercial software packages (OLEA and RAPID) were used to generate the Tmax label of hypoperfusion lesions in the 2 cohorts, respectively, our DL model was able to achieve a high accuracy of 92% in both cohorts. As a further validation, the mean pCASL CBF values increase from the infarct core, to the predicted penumbral tissue, and to the contralateral region at both 1.5T and 3T (Table VI in the online-only Data Supplement). These results strongly indicate that the proposed DL model is well suited and valid for identifying hypoperfusion lesions on ASL images in patients with AIS, for 2 main field strengths and MRI platforms used clinically.

In the present study, we trained 10 models using the 167 image sets of the UCLA cohort with 10-fold validation. When evaluated on the Stanford cohort, the consensus or averaged probability map from the 10 models yielded a significantly higher AUC of ROC (0.942) compared with the 10 individual models (AUC of ROC, 0.897±0.050), while the subject-level treatment eligibility results remain the same (0.92) for all the models. Therefore, although additional time (≈8 s/subject) and storage (≈140 MB in total) is needed for 10 models, we recommend using the averaged result of the 10 models for future applications.

It is important to note that the clinical decision to proceed with endovascular thrombectomy is not only based on the imaging criteria of diffusion-perfusion mismatch but also on the individual patient's medical history and clinical condition. While the ASL perfusion DL model cannot and should not be used independently for treatment decision-making, interventionists may consider utilizing it to supplement their assessment of stroke and treatment planning, when imaging with completely noninvasive MRI.

There are a few limitations and future directions of the present study. The detected hypoperfusion lesions on ASL did not match completely with that of DSC MRI with a moderate Dice coefficient of 0.47 in the UCLA cohort and 0.43 in the Stanford cohort. We noticed that the Dice coefficients were lower in patients with smaller hypoperfusion lesions due to their sensitivity to the mismatch between ASL and DSC MRI. There were 4 of a total of 50 cases that were incorrectly classified for treatment eligibility, as shown in the bottom row of Figure 4. This discrepancy may arise from different mechanisms of ASL and DSC perfusion weighted imaging, which merits further research in larger cohorts. The performance

Downloaded from http://ahajournals.org by on February 16, 2020

of our DL model is likely to be further improved with larger training data sets, as well as by integrating other clinical information such as demographics, electronic medical records, biomarkers, and real-time continuous monitoring using wearables.[39] Although we did not adjust our DL model to test the Stanford data (due to small sample size and also to avoid bias), it is also possible to fine-tune the model with a few cases when dealing with MRI data from different vendors. Finally, future clinical studies are needed to evaluate how well the DL penumbra can predict follow-up infarct in AIS patients when there is lack of reperfusion.

Conclusions

With a high accuracy of 92% for imaging-based criteria for endovascular treatment in 2 independent cohorts of AIS patients and superior performance compared with ML methods, the proposed ASL perfusion DL model may provide a promising approach for assisting decision-making for endovascular treatment in patients with AIS.

Acknowledgments

We thank Drs Yonggang Shi and Ben Duffy for helpful discussions.

Sources of Funding

This work was supported by National Institutes of Health grants UH2-NS100614, R01EB028297, and R01NS066506.

Disclosures

Dr Zaharchuk received research support from GE Healthcare, Bayer, and Nvidia and has equity interest in Subtle Medical. D.J.J. Wang received consulting fees from Bioclinica, Parexel, and Translational MRI and has equity interest in Translational MRI. Dr Liebeskind received consulting fees from Cerenovus, Genentech, Medtronic, and Stryker. Dr Kim is funded by the BrightFocus Foundation grant (A2019052S).

References

1. Albers GW, Marks MP, Kemp S, Christensen S, Tsai JP, Ortega-Gutierrez S, et al; DEFUSE 3 Investigators. Thrombectomy for stroke at 6 to 16 hours with selection by perfusion imaging. *N Engl J Med*. 2018;378:708–718. doi: 10.1056/NEJMoa1713973
2. Bouslama M, Haussen DC, Grossberg JA, Dehkharghani S, Bowen MT, Rebello LC, et al. Computed tomographic perfusion selection and clinical outcomes after endovascular therapy in large vessel occlusion stroke. *Stroke*. 2017;48:1271–1277. doi: 10.1161/STROKEAHA.116.015636
3. Bottinor W, Polkampally P, Jovin I. Adverse reactions to iodinated contrast media. *Int J Angiol*. 2013;22:149–154. doi: 10.1055/s-0033-1348885
4. Schaefer PW, Souza L, Kamalian S, Hirsch JA, Yoo AJ, Kamalian S, et al. Limited reliability of computed tomographic perfusion acute infarct volume measurements compared with diffusion-weighted imaging in anterior circulation stroke. *Stroke*. 2015;46:419–424. doi: 10.1161/STROKEAHA.114.007117
5. Wang DJ, Alger JR, Qiao JX, Gunther M, Pope WB, Saver JL, et al; UCLA Stroke Investigators. Multi-delay multi-parametric arterial spin-labeled perfusion MRI in acute ischemic stroke - comparison with dynamic susceptibility contrast enhanced perfusion imaging. *Neuroimage Clin*. 2013;3:1–7. doi: 10.1016/j.nicl.2013.06.017
6. Wang DJ, Alger JR, Qiao JX, Hao Q, Hou S, Fiaz R, et al; UCLA Stroke Investigators. The value of arterial spin-labeled perfusion imaging in acute ischemic stroke: comparison with dynamic susceptibility contrast-enhanced MRI. *Stroke*. 2012;43:1018–1024. doi: 10.1161/STROKEAHA.111.631929
7. Moatti Z, Gupta M, Yadava R, Thamban S. A review of stroke and pregnancy: incidence, management and prevention. *Eur J Obstet Gynecol Reprod Biol*. 2014;181:20–27. doi: 10.1016/j.ejogrb.2014.07.024
8. Kupferman JC, Zafeiriou DI, Lande MB, Kirkham FJ, Pavlakis SG. Stroke and hypertension in children and adolescents. *J Child Neurol*. 2017;32:408–417. doi: 10.1177/0883073816685240
9. Asadi H, Dowling R, Yan B, Mitchell P. Machine learning for outcome prediction of acute ischemic stroke post intra-arterial therapy. *PLoS One*. 2014;9:e88225. doi: 10.1371/journal.pone.0088225
10. van Os HJA, Ramos LA, Hilbert A, van Leeuwen M, van Walderveen MAA, Kruyt ND, et al. Predicting outcome of endovascular treatment for acute ischemic stroke: potential value of machine learning algorithms. *Frontiers in Neurology*. 2018;9:784. doi: 10.3389/fneur.2018.00784
11. LeCun Y, Bengio Y, Hinton G. Deep learning. *Nature*. 2015;521:436–444. doi: 10.1038/nature14539
12. Zaharchuk G, Gong E, Wintermark M, Rubin D, Langlotz CP. Deep learning in neuroradiology. *AJNR Am J Neuroradiol*. 2018;39:1776–1784. doi: 10.3174/ajnr.A5543
13. Shen D, Wu G, Suk HI. Deep learning in medical image analysis. *Annu Rev Biomed Eng*. 2017;19:221–248. doi: 10.1146/annurev-bioeng-071516-044442
14. Zaharchuk G, El Mogy IS, Fischbein NJ, Albers GW. Comparison of arterial spin labeling and bolus perfusion-weighted imaging for detecting mismatch in acute stroke. *Stroke*. 2012;43:1843–1848. doi: 10.1161/STROKEAHA.111.639773
15. Straka M, Albers GW, Bammer R. Real-time diffusion-perfusion mismatch analysis in acute stroke. *J Magn Reson Imaging*. 2010;32:1024–1037. doi: 10.1002/jmri.22338
16. Smith SM. Fast robust automated brain extraction. *Hum Brain Mapp*. 2002;17:143–155. doi: 10.1002/hbm.10062
17. Zhang Y, Brady M, Smith S. Segmentation of brain MR images through a hidden Markov random field model and the expectation-maximization algorithm. *IEEE Trans Med Imaging*. 2001;20:45–57. doi: 10.1109/42.906424
18. Olivot JM, Mlynash M, Thijs VN, Kemp S, Lansberg MG, Wechsler L, et al. Optimal Tmax threshold for predicting penumbral tissue in acute stroke. *Stroke*. 2009;40:469–475. doi: 10.1161/STROKEAHA.108.526954
19. Takasawa M, Jones PS, Guadagno JV, Christensen S, Fryer TD, Harding S, et al. How reliable is perfusion MR in acute stroke? Validation and determination of the penumbra threshold against quantitative PET. *Stroke*. 2008;39:870–877. doi: 10.1161/STROKEAHA.107.500090
20. Davis SM, Donnan GA, Parsons MW, Levi C, Butcher KS, Peeters A, et al; EPITHET Investigators. Effects of alteplase beyond 3 h after stroke in the Echoplanar Imaging Thrombolytic Evaluation Trial (EPITHET): a placebo-controlled randomised trial. *Lancet Neurol*. 2008;7:299–309. doi: 10.1016/S1474-4422(08)70044-9
21. Li WQ, Wang GT, Fidon L, Ourselin S, Cardoso MJ, Vercauteren T. On the compactness, efficiency, and representation of 3D convolutional networks: brain parcellation as a pretext task. *Lect Notes Comput Sc*. 2017;10265:348–360
22. Gibson E, Li W, Sudre C, Fidon L, Shakir DI, Wang G, et al. NiftyNet: a deep-learning platform for medical imaging. *Comput Methods Programs Biomed*. 2018;158:113–122. doi: 10.1016/j.cmpb.2018.01.025
23. Milletaride F, Navab N, Ahmadi SA. V-net: Fully convolutional neural networks for volumetric medical image segmentation. *Int Conf 3d Vision*. 2016:565–571
24. Diederik P. Kingma JB. Adam: A method for stochastic optimization. *Proceedings of the 3rd International Conference on Learning Representations (ICLR)*; 2015 May 7-9; San Diego, California (CA): ICLR; 2015.
25. McKinley R, Hung F, Wiest R, Liebeskind DS, Scalzo F. A machine learning approach to perfusion imaging with dynamic susceptibility contrast MR. *Front Neurol*. 2018;9:717. doi: 10.3389/fneur.2018.00717
26. Purushotham A, Campbell BC, Straka M, Mlynash M, Olivot JM, Bammer R, et al. Apparent diffusion coefficient threshold for delineation of ischemic core. *Int J Stroke*. 2015;10:348–353. doi: 10.1111/ijs.12068
27. Stehman SV. Selecting and interpreting measures of thematic classification accuracy. *Remote Sens Environ*. 1997;62:77–89
28. Saver JL, Goyal M, Bonafe A, Diener HC, Levy EI, Pereira VM, et al; SWIFT PRIME Investigators. Stent-retriever thrombectomy after intravenous t-PA vs. t-PA alone in stroke. *N Engl J Med*. 2015;372:2285–2295. doi: 10.1056/NEJMoa1415061
29. Campbell BC, Mitchell PJ, Kleinig TJ, Dewey HM, Churilov L, Yassi N, et al; EXTEND-IA Investigators. Endovascular therapy for ischemic stroke with perfusion-imaging selection. *N Engl J Med*. 2015;372:1009–1018. doi: 10.1056/NEJMoa1414792
30. Goyal M, Demchuk AM, Menon BK, Eesa M, Rempel JL, Thornton J, et al; ESCAPE Trial Investigators. Randomized assessment

Downloaded from http://ahajournals.org by on February 16, 2020

of rapid endovascular treatment of ischemic stroke. *N Engl J Med*. 2015;372:1019–1030. doi: 10.1056/NEJMoa1414905

31. Copen WA, Morais LT, Wu O, Schwamm LH, Schaefer PW, González RG, et al. In acute stroke, can CT perfusion-derived cerebral blood volume maps substitute for diffusion-weighted imaging in identifying the ischemic core? *PLoS One*. 2015;10:e0133566. doi: 10.1371/journal.pone.0133566
32. Copen WA, Yoo AJ, Rost NS, Morais LT, Schaefer PW, González RG, et al. In patients with suspected acute stroke, CT perfusion-based cerebral blood flow maps cannot substitute for DWI in measuring the ischemic core. *PLoS One*. 2017;12:e0188891. doi: 10.1371/journal.pone.0188891
33. Yu S, Ma SJ, Liebeskind DS, Yu D, Li N, Qiao XJ, et al. ASPECTS-based reperfusion status on arterial spin labeling is associated with clinical outcome in acute ischemic stroke patients. *J Cereb Blood Flow Metab*. 2018;38:382–392. doi: 10.1177/0271678X17697339
34. Yu S, Liebeskind DS, Dua S, Wilhalme H, Elashoff D, Qiao XJ, et al; UCLA Stroke Investigators. Postischemic hyperperfusion on arterial spin labeled perfusion MRI is linked to hemorrhagic transformation in stroke. *J Cereb Blood Flow Metab*. 2015;35:630–637. doi: 10.1038/jcbfm.2014.238
35. Campbell BC, Parsons MW. Imaging selection for acute stroke intervention. *Int J Stroke*. 2018;13:554–567. doi: 10.1177/1747493018765235
36. Kim KH, Choi SH, Park SH. Improving arterial spin labeling by using deep learning. *Radiology*. 2017:171154
37. Gong E, Pauly J, Zaharchuk G. Boosting SNR and/or resolution of arterial spin label (asl) imaging using multi-contrast approaches with multi-lateral guided filteranddeepnetworks. *Proc ISMRM*. 2017;25:3983
38. Zaharchuk G, Do HM, Marks MP, Rosenberg J, Moseley ME, Steinberg GK. Arterial spin-labeling MRI can identify the presence and intensity of collateral perfusion in patients with moyamoya disease. *Stroke*. 2011;42:2485–2491. doi: 10.1161/STROKEAHA.111.616466
39. Saber H, Somai M, Rajah GB, Scalzo F, Liebeskind DS. Predictive analytics and machine learning in stroke and neurovascular medicine. *Neurol Res*. 2019;41:681–690. doi: 10.1080/01616412.2019.1609159

Downloaded from http://ahajournals.org by on February 16, 2020