2 3 4 5 6 7 8 9 10 11 12 13 14 15 16 17 18 19 20 21 22 23 24 25 26 27 28 29 30 31 32 33 34 35 36 37 38 39 40 41

A 24-year-old male presents to your office complaining of lower abdominal discomfort. Physical examination reveals right-sided testicular enlargement that feels like a 'bag of worms' when the patient stands up. The venous blood from the affected testicle drains directly into the:

- A. Right internal iliac vein [10%]
- B. Inferior mesenteric vein [3%]
- C. Right renal vein [14%]
- D. Hemiazygous vein [1%]
- ✔ E. Inferior vena cava [70%]

Explanation:

User Id: 477875

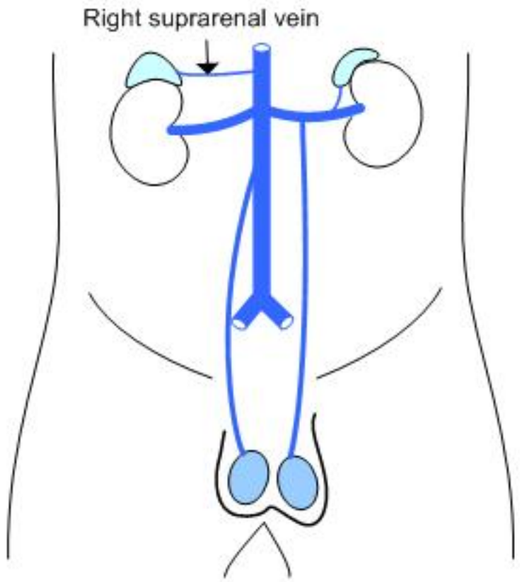

This patient has a varicocele of the right testicle, as indicated by the 'bag of worms' texture of the scrotum on the affected side. This texture is produced by the reticular network of veins that drain the testicles, the

www.zeallsoft.com

2 3 4 5 6 7 8 9 10 11 12 13 14 15 16 17 18 19 20 21 22 23 24 25 26 27 28 29 30 31 32 33 34 35 36 37 38 39 40 41

A 24-year-old male presents to your office complaining of lower abdominal discomfort. Physical examination reveals right-sided testicular enlargement that feels like a 'bag of worms' when the patient stands up. The venous blood from the affected testicle drains directly into the:

- A. Right internal iliac vein [10%]
- B. Inferior mesenteric vein [3%]
- C. Right renal vein [14%]
- D. Hemiazygous vein [1%]
- ✔ E. Inferior vena cava [70%]

Explanation:

User Id: 477875

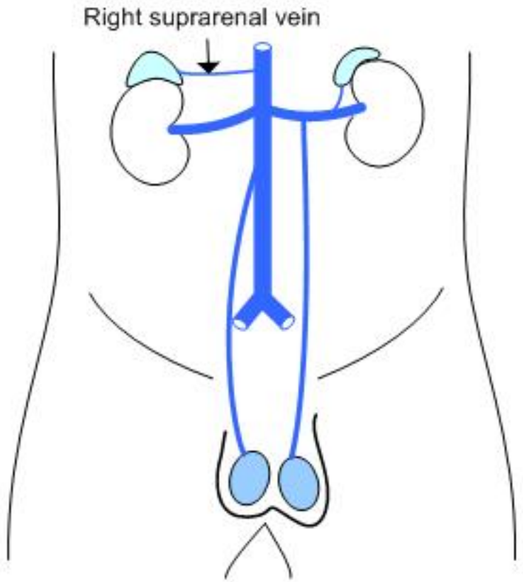

This patient has a varicocele of the right testicle, as indicated by the 'bag of worms' texture of the scrotum on the affected side. This texture is produced by the reticular network of veins that drain the testicles, the

2
3
4
5
6
7
8
9
10
11
12
13
14
15
16
17
18
19
20
21
22
23
24
25
26
27
28
29
30
31
32
33
34
35
36
37
38
39
40
41

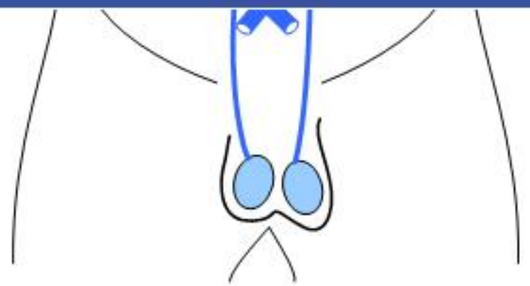

This patient has a varicocele of the right testicle, as indicated by the 'bag of worms' texture of the scrotum on the affected side. This texture is produced by the reticular network of veins that drain the testicles, the pampiniform plexus. Failure of the venous valves leads to pooling of blood in the testicles due to their dependent location, causing varicoceles. Varicoceles can also result from upstream compression of the veins that drain the testes by abdominal or pelvic masses or other forces.

Recall that the venous drainage of the testes is not bilaterally symmetric. The right testicular vein drains into the inferior vena cava (IVC) whereas the left testicular vein drains into the left renal vein which drains into the IVC. The left testicle is more commonly affected by varicocele, perhaps because the left renal vein passes between the aorta and the superior mesenteric artery (SMA), and enlargement or hardening of the SMA may cause compression of the left renal vein and pooling of blood in the left testicle.

(Choice A) The right internal iliac vein receives drainage from the pelvic viscera and genitalia (other than the gonads) and the gluteal region and regions served by the pudendal circulation.

(Choice B) The inferior mesenteric vein drains the structures of the hindgut.

(Choice C) The right renal vein drains only the right kidney. The right suprarenal gland drains directly into the IVC as opposed to the left suprarenal gland, which drains primarily into the left renal vein.

(Choice D) The hemiazygous vein drains blood from the posterior walls of the thorax and abdomen. Together with the azygous vein and accessory hemiazygous vein, the hemiazygous vein provides an alternate pathway for blood to return to the heart bypassing the IVC.

Educational Objective:
The right testicular vein drains directly into the IVC while the left testicular vein drains into the left renal vein.

Time Spent: 17 seconds

Copyright © USMLEWorld,LLC.

Last updated: [1/26/2012]

2, 3, 4, 5, 6, 7, 8, 9, 10, 11, 12, 13, 14, 15, 16, 17, 18, 19, 20, 21, 22, 23, 24, 25, 26, 27, 28, 29, 30, 31, 32, 33, 34, 35, 36, 37, 38, 39, 40, 41

A surgeon transplants a donor kidney into a 45-year-old patient with end-stage renal disease. The upper 1/3 of the ureter of the transplanted kidney is retained and attached to the recipient patient's bladder. However, soon after transplantation, the ureter becomes necrotic. Which of the following arteries is the major source of blood supply to the upper ureter?

- A. Common iliac artery [8%]
- B. Phrenic artery [2%]
- C. Internal iliac artery [20%]
- ✔ D. Renal artery [52%]
- E. Lumbar arteries [8%]
- F. Superior vesical artery [9%]

Explanation: **User Id: 477875**

In a kidney transplant operation, the native kidneys are typically left in place, and the donor kidney is placed retroperitoneally in the right iliac fossa. Blood supply to the donor organ is typically established by anastomosing the donor renal artery with the recipient's external iliac artery. Similarly, the donor renal vein is connected to the recipient's external iliac vein. The proximal 1/3 of the donor ureter is preserved and used to establish continuity from the collecting system of the kidney to the recipient's bladder. This portion of the ureter receives its blood supply from branches of the renal artery. (More distally, the ureters are supplied by branches from the aorta and iliac, gonadal and vesical arteries.) Ureteric ischemia occurs in approximately 2% of renal transplant patients.

(Choice A) Small branches from the common iliac artery may supply the ureter's midportion.

2 3 4 5 6 7 8 9 10 11 12 13 14 15 16 17 18 19 20 21 22 23 24 25 26 27 28 29 30 31 32 33 34 35 36 37 38 39 40 41

E. Lumbar arteries [8%]

F. Superior vesical artery [9%]

Explanation: **User Id: 477875**

In a kidney transplant operation, the native kidneys are typically left in place, and the donor kidney is placed retroperitoneally in the right iliac fossa. Blood supply to the donor organ is typically established by anastomosing the donor renal artery with the recipient's external iliac artery. Similarly, the donor renal vein is connected to the recipient's external iliac vein. The proximal 1/3 of the donor ureter is preserved and used to establish continuity from the collecting system of the kidney to the recipient's bladder. This portion of the ureter receives its blood supply from branches of the renal artery. (More distally, the ureters are supplied by branches from the aorta and iliac, gonadal and vesical arteries.) Ureteric ischemia occurs in approximately 2% of renal transplant patients.

(Choice A) Small branches from the common iliac artery may supply the ureter's midportion.

(Choice B) The inferior phrenic arteries are branches of the aorta that supply the diaphragm and provide branches to the suprarenal glands. These arteries do not supply the ureters.

(Choice C) An alternate method of providing blood supply to a transplanted kidney is end-to-end anastomosis with the internal iliac artery. The internal iliac artery does not directly contribute to the blood supply of the ureter.

(Choice E) The lumbar arteries, like the intercostal arteries, arise directly from the aorta to supply the lumbar vertebrae and surrounding structures. They do not supply the ureters.

(Choice F) The superior vesical artery is a branch of the internal iliac artery that supplies blood to the superior portion of the urinary bladder. It also provides branches to the distal ureter.

Educational Objective:
The proximal 1/3 of the ureter receives its blood supply from branches of the renal artery. For this reason, this portion of the donor ureter is typically viable after renal transplantation.

Time Spent: 2 seconds Copyright © USMLEWorld,LLC. Last updated: [11/10/2011]

2, 3, 4, 5, 6, 7, 8, 9, 10, 11, 12, 13, 14, 15, 16, 17, 18, 19, 20, 21, 22, 23, 24, 25, 26, 27, 28, 29, 30, 31, 32, 33, 34, 35, 36, 37, 38, 39, 40, 41

A 54-year-old woman comes to the physician complaining of difficulty hearing for the past few weeks. During the neurologic examination, the physician assesses her hearing using a vibrating tuning fork. She appreciates a loud tone when the handle of the tuning fork is placed on her left mastoid process but hears a softer tone when the tines are placed near her left external auditory meatus. When the handle is placed on the middle of her forehead, she hears the vibration better in her left ear than her right. This patient is most likely experiencing which of the following types of hearing loss?

- A. Conductional loss in both ears [1%]
- ✔ B. Conductional loss in left ear [63%]
- C. Conductional loss in right ear [8%]
- D. Sensorineural loss in both ears [2%]
- E. Sensorineural loss in left ear [18%]
- F. Sensorineural loss in right ear [7%]

Explanation:

User Id: 477875

Type of hearing loss	Rinne test	Weber test	Possible causes
Conductive	Abnormal in affected ear (bone > air)	Localizes to affected ear	Cerumen impaction, cholesteatoma, otosclerosis, external or middle ear tumors, tympanic membrane rupture, severe otitis media
Sensorineural	Normal in both ears (air > bone)	Localizes to unaffected ear	Meniere's disease, acoustic neuroma, presbycusis, ototoxic drugs (eg, aminoglycosides)

2
3
4
5
6
7
8
9
10
11
12
13
14
15
16
17
18
19
20
21
22
23
24
25
26
27
28
29
30
31
32
33
34
35
36
37
38
39
40
41

Hearing loss is classified as either conductive (obstruction of external sound vibrations to the inner ear) or sensorineural (involving the inner ear, cochlea, or auditory nerve). The Rinne and Weber tests can be used to help determine the type of hearing loss.

The Rinne test compares the perceived sound produced by a vibrating tuning fork when the stem is placed on the mastoid bone (bone conduction) versus when the tines are held near the external auditory meatus (air conduction). Air-conducted sound is normally louder and heard longer than bone-conducted sound. The Rinne test is considered positive (normal) if the sound is heard best at the external auditory meatus and negative (abnormal) if the patient hears the vibration better at the mastoid. An abnormal Rinne test suggests conductive hearing loss.

The Weber test also helps differentiate between conductive and sensorineural hearing loss. It is performed by placing a vibrating tuning fork on the middle of forehead equidistant from both ears. The vibration is normally heard equally in both ears; vibration heard louder in 1 ear indicates an abnormal test. Conductive hearing loss causes lateralization to the affected ear as the conduction deficit masks the ambient noise in the room, allowing the vibration to be better heard. In contrast, sensorineural hearing loss causes lateralization to the unaffected ear as the unimpaired inner ear can better sense the vibration.

The Rinne test is abnormal in this patient's left ear, and the Weber test lateralizes to her left ear. These findings suggest conductive hearing loss in the left ear.

(Choice A) Conductional loss in both ears would result in an abnormal Rinne test bilaterally and a normal Weber test.

(Choice C) Conductional loss in the right ear would result in an abnormal Rinne test on the right and a Weber test that lateralizes to the right.

(Choice D) Sensorineural loss in both ears would result in a normal Rinne test bilaterally and a normal Weber test.

(Choice E) Sensorineural loss in the left ear would result in a normal Rinne test bilaterally and a Weber test that lateralizes to the right.

(Choice F) Sensorineural loss in the right ear would result in a normal Rinne test bilaterally and a Weber test that lateralizes to the left.

Educational objective:

2 3 4 5 6 7 8 9 10 11 12 13 14 15 16 17 18 19 20 21 22 23 24 25 26 27 28 29 30 31 32 33 34 35 36 37 38 39 40 41

conduction). Air-conducted sound is normally louder and heard longer than bone-conducted sound. The Rinne test is considered positive (normal) if the sound is heard best at the external auditory meatus and negative (abnormal) if the patient hears the vibration better at the mastoid. An abnormal Rinne test suggests conductive hearing loss.

The Weber test also helps differentiate between conductive and sensorineural hearing loss. It is performed by placing a vibrating tuning fork on the middle of forehead equidistant from both ears. The vibration is normally heard equally in both ears; vibration heard louder in 1 ear indicates an abnormal test. Conductive hearing loss causes lateralization to the affected ear as the conduction deficit masks the ambient noise in the room, allowing the vibration to be better heard. In contrast, sensorineural hearing loss causes lateralization to the unaffected ear as the unimpaired inner ear can better sense the vibration.

The Rinne test is abnormal in this patient's left ear, and the Weber test lateralizes to her left ear. These findings suggest conductive hearing loss in the left ear.

(Choice A) Conductional loss in both ears would result in an abnormal Rinne test bilaterally and a normal Weber test.

(Choice C) Conductional loss in the right ear would result in an abnormal Rinne test on the right and a Weber test that lateralizes to the right.

(Choice D) Sensorineural loss in both ears would result in a normal Rinne test bilaterally and a normal Weber test.

(Choice E) Sensorineural loss in the left ear would result in a normal Rinne test bilaterally and a Weber test that lateralizes to the right.

(Choice F) Sensorineural loss in the right ear would result in a normal Rinne test bilaterally and a Weber test that lateralizes to the left.

Educational objective:
Conductive hearing loss (bone conduction > air conduction): abnormal Rinne test (in affected ear) and Weber test localizes to affected ear.

Sensorineural hearing loss (air conduction > bone conduction): normal Rinne test and Weber test localizes to unaffected ear.

Time Spent: 1 seconds

Copyright © USMLEWorld,LLC.

Last updated: [12/27/2012]

Super Screen Capture - Unregistered
FullScreen Window Scroll Shape Feedback Picker Video Audio Manager Options Buy Now
End Block

2 3 4 5 6 7 8 9 10 11 12 13 14 15 16 17 18 19 20 21 22 23 24 25 26 27 28 29 30 31 32 33 34 35 36 37 38 39 40 41

A 62-year-old man comes to the physician complaining of double vision. He first noticed mild difficulty focusing his eyes about 3 weeks ago and his symptoms have progressively worsened. The patient's other medical problems include metastatic prostate cancer. On neurologic examination, he is unable to adduct his left eye, and stimulation of the left cornea does not elicit a corneal reflex. A lesion involving which of the following anatomical structures is most likely responsible for this patient's symptoms?

- A. Inferior orbital fissure [8%]
- B. Optic canal [9%]
- ✔ C. Superior orbital fissure [69%]
- D. Foramen rotundum [8%]
- E. Foramen lacerum [2%]
- F. Foramen ovale [4%]

Explanation: **User Id: 477875**

This patient's diplopia is caused by his inability to adduct his left eye. Eye adduction depends on the oculomotor nerve (CN III) and the medial rectus muscle. The oculomotor nerve originates in the oculomotor nucleus of the midbrain, emerges from the anterior midbrain, and enters the orbit through the superior orbital fissure. The patient also has loss of the corneal reflex on the left side. The sensory limb of the corneal reflex is mediated by the nasociliary branch of the first division of the trigeminal nerve (CN V_1). The motor component of the corneal reflex is carried primarily by the temporal branch of the facial nerve (CN VII). Like the oculomotor nerve, the nasociliary nerve enters the orbit through the superior orbital fissure. Thus, a lesion involving the superior orbital fissure would cause the described deficits.

The trochlear nerve (CN IV), abducens nerve (CN VI), and superior ophthalmic vein also enter the orbit via the superior orbital fissure.

(Choice A) The maxillary division of the trigeminal nerve (CN V_2), the infraorbital vessels, and branches from the sphenopalatine ganglion pass through the inferior orbital fissure but do not enter the orbit.

(Choice B) The optic canal is medial to the superior orbital fissure and transmits only the optic nerve (CN II) and ophthalmic artery.

2
3
4
5
6
7
8
9
10
11
12
13
14
15
16
17
18
19
20
21
22
23
24
25
26
27
28
29
30
31
32
33
34
35
36
37
38
39
40
41

F. Foramen ovale [4%]

Explanation: **User Id: 477875**

This patient's diplopia is caused by his inability to adduct his left eye. Eye adduction depends on the oculomotor nerve (CN III) and the medial rectus muscle. The oculomotor nerve originates in the oculomotor nucleus of the midbrain, emerges from the anterior midbrain, and enters the orbit through the superior orbital fissure. The patient also has loss of the corneal reflex on the left side. The sensory limb of the corneal reflex is mediated by the nasociliary branch of the first division of the trigeminal nerve (CN V_1). The motor component of the corneal reflex is carried primarily by the temporal branch of the facial nerve (CN VII). Like the oculomotor nerve, the nasociliary nerve enters the orbit through the superior orbital fissure. Thus, a lesion involving the superior orbital fissure would cause the described deficits.

The trochlear nerve (CN IV), abducens nerve (CN VI), and superior ophthalmic vein also enter the orbit via the superior orbital fissure.

(Choice A) The maxillary division of the trigeminal nerve (CN V_2), the infraorbital vessels, and branches from the sphenopalatine ganglion pass through the inferior orbital fissure but do not enter the orbit.

(Choice B) The optic canal is medial to the superior orbital fissure and transmits only the optic nerve (CN II) and ophthalmic artery.

(Choice D) The foramen rotundum transmits the maxillary division of the trigeminal nerve (CN V_2) from within the skull to the pterygopalatine fossa. From there, it courses through the inferior orbital fissure to appear on the face at the infraorbital foramen as the infraorbital nerve.

(Choice E) The foramen lacerum is occluded by cartilage. The internal carotid artery courses just superior to the foramen lacerum in the lacerum portion of the carotid canal.

(Choice F) The mandibular branch of the trigeminal nerve (CN V_3) passes through the foramen ovale.

Educational objective:
The oculomotor nerve (CN III), ophthalmic nerve (CN V_1) branches, trochlear nerve (CN IV), abducens nerve (CN VI), and superior ophthalmic vein enter the orbit via the superior orbital fissure.

Time Spent: 1 seconds Copyright © USMLEWorld,LLC. Last updated: [5/14/2013]

www.zeallsoft.com

2 3 4 5 6 7 8 9 10 11 12 13 14 15 16 17 18 19 20 21 22 23 24 25 26 27 28 29 30 31 32 33 34 35 36 37 38 39 40 41

A 52-year-old man is brought to the emergency department for repeated vomiting that began 2 hours ago. His vomit is dark brown and has a granular consistency. The patient has a history of dyspepsia after meals, for which he takes over-the-counter antacids. Physical examination reveals mild epigastric tenderness. Endoscopy shows a deep, bleeding ulcer on the posterior wall of the duodenal bulb. This ulcer has most likely penetrated which of the following arteries?

- A. Common hepatic [3%]
- B. Right gastroepiploic [9%]
- C. Left gastric [5%]
- ✔ D. Gastroduodenal [60%]
- E. Inferior pancreaticoduodenal [14%]
- F. Splenic [2%]
- G. Superior mesenteric [7%]

Explanation:

User Id: 477875

Stomach vasculature

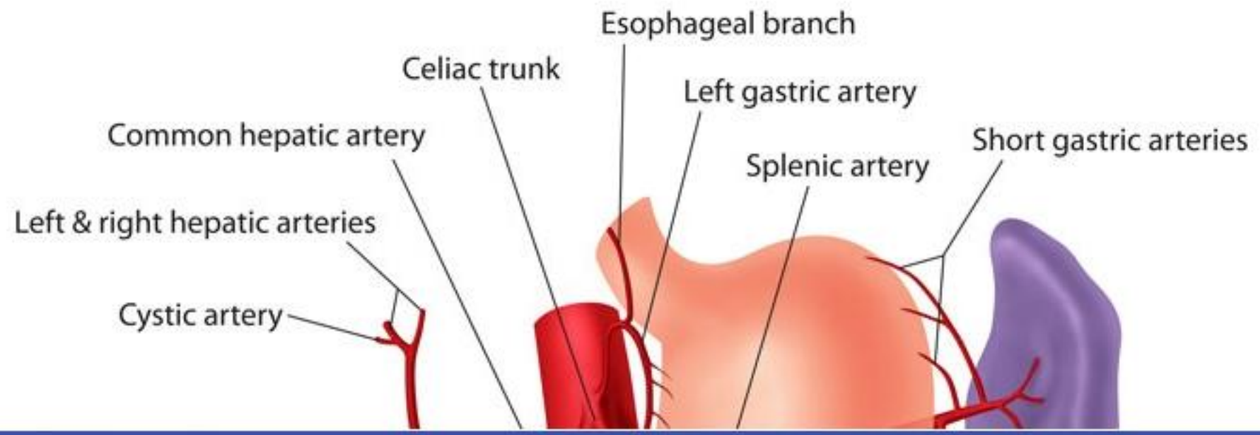

www.zeallsoft.com

2 3 4 5 6 7 8 9 10 11 12 13 14 15 16 17 18 19 20 21 22 23 24 25 26 27 28 29 30 31 32 33 34 35 36 37 38 39 40 41

Stomach vasculature

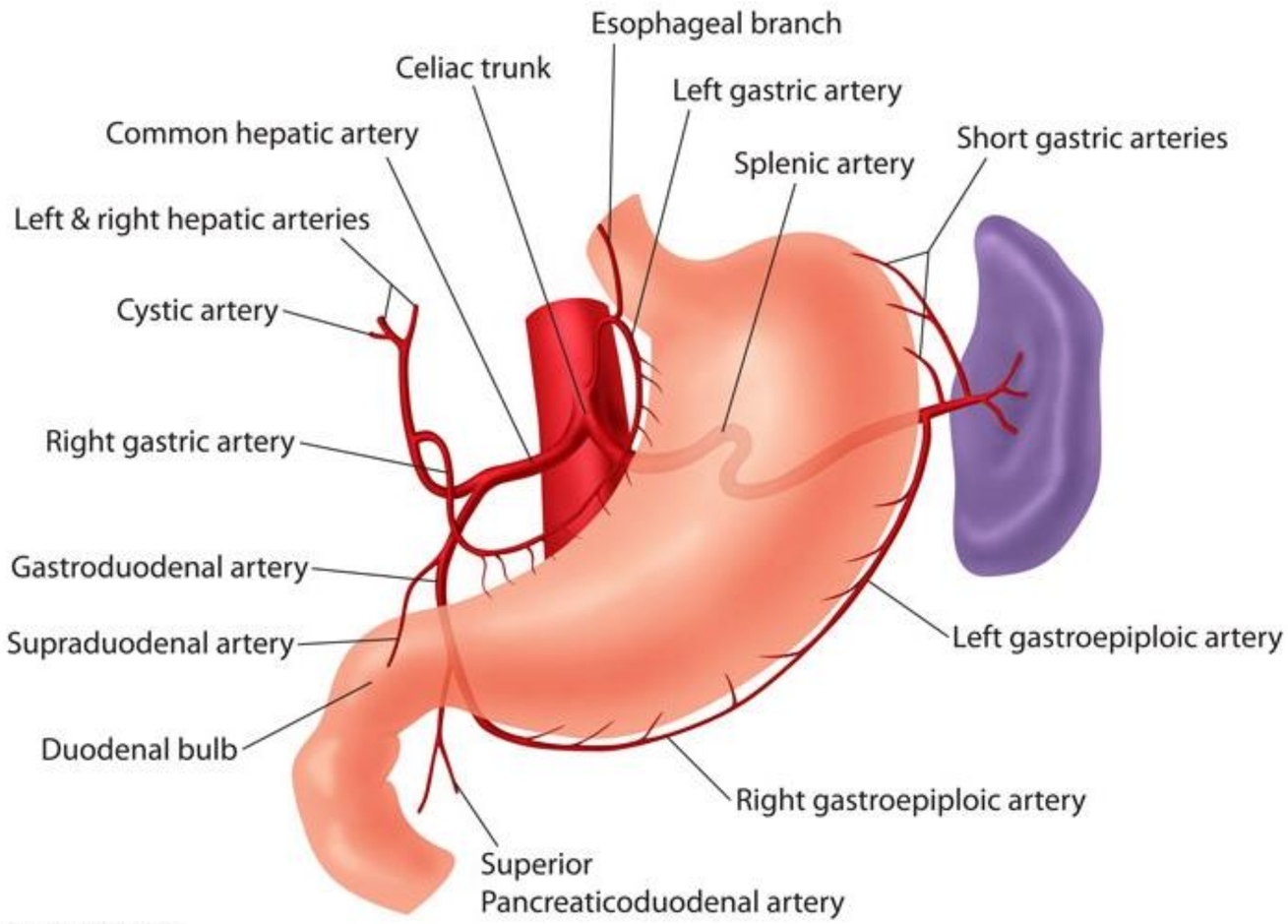

© USMLEWorld, LLC

Duodenal ulcers are more common than gastric ulcers and tend to occur anteriorly. Ulcers located on the anterior wall of the duodenal bulb are more prone to perforation; those on the posterior wall are more likely to cause hemorrhage.

2
3
4
5
6
7
8
9
10
11
12
13
14
15
16
17
18
19
20
21
22
23
24
25
26
27
28
29
30
31
32
33
34
35
36
37
38
39
40
41

© USMLEWorld, LLC

Duodenal ulcers are more common than gastric ulcers and tend to occur anteriorly. Ulcers located on the anterior wall of the duodenal bulb are more prone to perforation; those on the posterior wall are more likely to cause hemorrhage.

These complications are explained by the relationship of the duodenal bulb to adjacent organs. The bulb begins at the pylorus, ends at the neck of the gallbladder, and rests posterior to the gallbladder and liver. The gastroduodenal artery, common biliary duct, and portal vein lie posterior to the duodenal bulb; the head of the pancreas is located inferiorly. When an ulcer penetrates the posterior duodenal wall, it is likely to erode into the gastroduodenal artery.

The gastroduodenal artery arises from the common hepatic artery and perfuses both the pylorus and the proximal part of the duodenum. Damage to the gastroduodenal artery can cause significant upper gastrointestinal bleeding.

(Choice A) The common hepatic artery arises from the celiac trunk and bifurcates into the proper hepatic and gastroduodenal arteries. It passes superior to the duodenal bulb and is not eroded by duodenal ulcers.

(Choices B and C) The right gastroepiploic and left gastric arteries supply blood to the stomach. They do not lie in close proximity to the duodenal bulb.

(Choice E) The inferior pancreaticoduodenal artery is a branch of the superior mesenteric artery. It supplies blood to the lower duodenum and to the head of the pancreas. This artery has no close relation to the duodenal bulb.

(Choice G) The superior mesenteric artery lies anterior to the transverse part of the duodenum. It arises from the anterior surface of the abdominal aorta and supplies the intestine from the duodenum up to the distal one-third of the transverse colon.

Educational objective:
The gastroduodenal artery lies along the posterior wall of the duodenal bulb and is likely to be eroded by posterior duodenal ulcers. Ulceration into the gastroduodenal artery can be a source of life-threatening hemorrhage.

Time Spent: 1 seconds

Copyright © USMLEWorld,LLC.

Last updated: [12/18/2012]

www.zeallsoft.com

2
3
4
5
6
7
8
9
10
11
12
13
14
15
16
17
18
19
20
21
22
23
24
25
26
27
28
29
30
31
32
33
34
35
36
37
38
39
40
41

A 67-year-old woman comes to the physician complaining of a decrease in vision in her right eye that she noticed a week ago. She says that her sight in her right eye is "narrower" than in her left and seems to be "directed more towards the right." Her past medical history is significant for hypertension, type 2 diabetes mellitus, and hyperlipidemia. She also suffers from intermittent claudication and has had 2 prior episodes of transient vision loss in her right eye. Visual field testing reveals a right nasal hemianopia. CT scan of the head shows a calcified right internal carotid artery. Which of the following portions of the visual pathway is most likely disrupted in this patient?

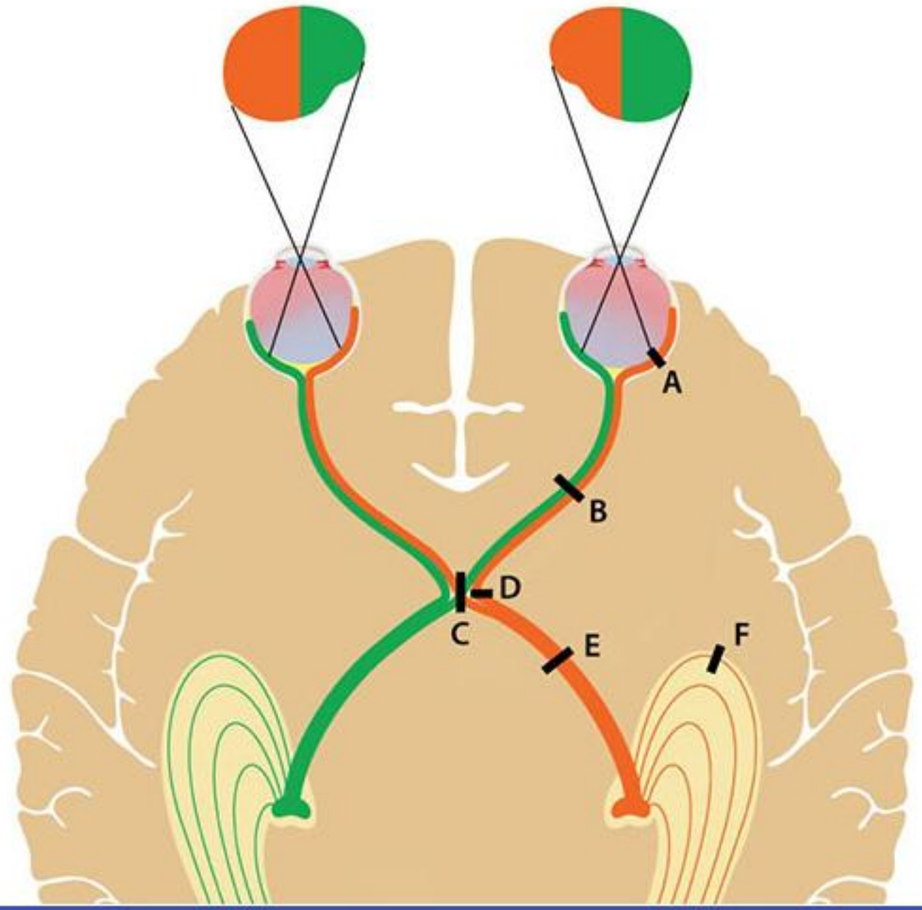

www.zeallsoft.com

2
3
4
5
6
7
8
9
10
11
12
13
14
15
16
17
18
19
20
21
22
23
24
25
26
27
28
29
30
31
32
33
34
35
36
37
38
39
40
41

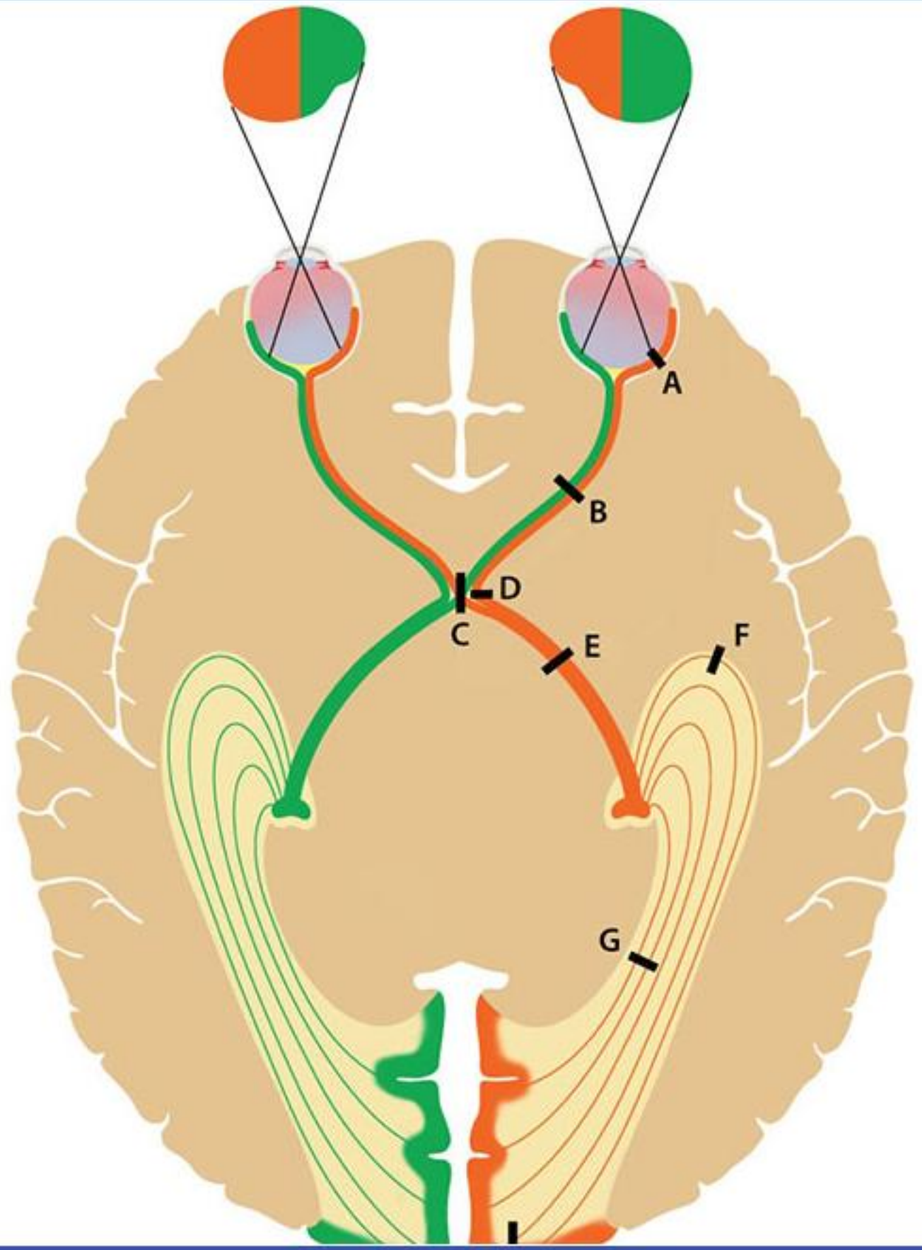

Topic : Nasal Hemianopsia
Division : Head and neck
Test Id : 17504943

www.zeallsoft.com

2
3
4
5
6
7
8
9
10
11
12
13
14
15
16
17
18
19
20
21
22
23
24
25
26
27
28
29
30
31
32
33
34
35
36
37
38
39
40
41

A. A [46%]
B. B [6%]
C. C [1%]
✔ D. D [34%]
E. E [7%]
F. F [4%]
G. G [1%]
H. H [1%]

Explanation:

User Id: 477875

Visual field defect	Location of lesion	Possible causes
A. Monocular scotoma 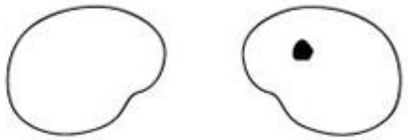	Partial lesion in the retina, optic disk, optic nerve	Macular degeneration, optic neuritis
B. Right anopia 	Right optic nerve	Retinal artery or central retinal vein occlusion
C. Bitemporal hemianopia 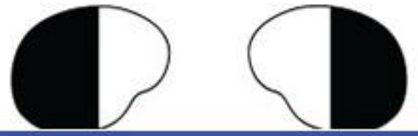	Optic chiasm	Pressure exerted by a pituitary tumor, craniopharyngioma, aneurysm of anterior communicating artery

2 3 4 5 6 7 8 9 10 11 12 13 14 15 16 17 18 19 20 21 22 23 24 25 26 27 28 29 30 31 32 33 34 35 36 37 38 39 40 41

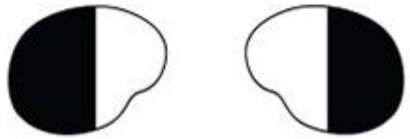	optic chiasm	Pituitary tumor, craniopharyngioma, aneurysm of anterior communicating artery
D. Right nasal hemianopia 	Right peri-chiasmal lesion	Calcification or aneurysm of the internal carotid artery impinging on uncrossed, lateral retinal fibers
E. Left homonymous hemianopia 	Right optic tract or optic radiation	Optic tract: occlusion of anterior choroidal artery Optic radiation: occlusion of a middle cerebral artery branch or lesion involving posterior limb of internal capsule
F. Left homonymous superior quadrantanopia ("pie in the sky") 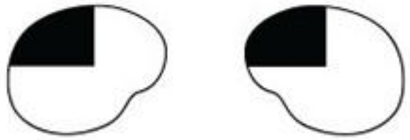	Right temporal lobe (Meyer's loop)	Lesion or stroke involving temporal lobe
G. Left homonymous inferior quadrantanopia ("pie on the floor")	Right parietal lobe (dorsal optic radiation)	Lesion or stroke involving parietal lobe

2, 3, 4, 5, 6, 7, 8, 9, 10, 11, 12, 13, 14, 15, 16, 17, 18, 19, 20, 21, 22, 23, 24, 25, 26, 27, 28, 29, 30, 31, 32, 33, 34, 35, 36, 37, 38, 39, 40, 41

F. Left homonymous superior quadrantanopia ("pie in the sky") 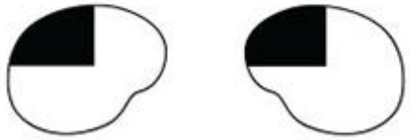	Right temporal lobe (Meyer's loop)	Lesion or stroke involving temporal lobe
G. Left homonymous inferior quadrantanopia ("pie on the floor") 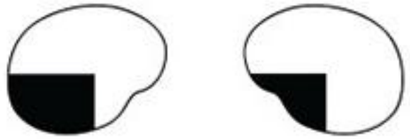	Right parietal lobe (dorsal optic radiation)	Lesion or stroke involving parietal lobe
H. Left homonymous hemianopia with macular sparing 	Right primary visual cortex (occipital lobe)	Occlusion of posterior cerebral artery. Macula is spared due to collateral blood from the middle cerebral artery

© USMLEWorld, LLC

Humans have a maximum horizontal **field of view** of about 200 degrees with both eyes. The central 120 degrees make up the binocular field of view (stereoscopic vision), with 2 side fields of about 40 degrees seen by only 1 eye (monoscopic vision). Unilateral visual defects within the binocular field of view (such as unilateral nasal hemianopia) may be masked due to compensation by the normal eye and go unnoticed by the patient.

Light from the nasal visual field strikes the temporal side of each retina, and optic nerve fibers from the temporal part of the retina travel laterally through the optic chiasm to pass into the ipsilateral optic tract.

2 3 4 5 6 7 8 9 10 11 12 13 14 15 16 17 18 19 20 21 22 23 24 25 26 27 28 29 30 31 32 33 34 35 36 37 38 39 40 41

H. Left homonymous hemianopia with macular sparing 	Right primary visual cortex (occipital lobe)	Occlusion of posterior cerebral artery. Macula is spared due to collateral blood from the middle cerebral artery

© USMLEWorld, LLC

Humans have a maximum horizontal **field of view** of about 200 degrees with both eyes. The central 120 degrees make up the binocular field of view (stereoscopic vision), with 2 side fields of about 40 degrees seen by only 1 eye (monoscopic vision). Unilateral visual defects within the binocular field of view (such as unilateral nasal hemianopia) may be masked due to compensation by the normal eye and go unnoticed by the patient.

Light from the nasal visual field strikes the temporal side of each retina, and optic nerve fibers from the temporal part of the retina travel laterally through the optic chiasm to pass into the ipsilateral optic tract. Lesions involving the lateral aspects of the optic chiasm can cause nasal hemianopia by damaging these uncrossed, temporal retinal fibers. Aneurysm or atherosclerotic calcification of the internal carotid artery can induce a nasal defect by laterally impinging on the optic chiasm.

This patient's history of transient right-sided vision loss and head CT findings are consistent with significant right internal carotid artery atherosclerosis. Thus, extrinsic compression of the optic chiasm by the right internal carotid artery is the most likely cause of her symptoms.

(Choice A) A lesion involving the retina is more likely to produce a focal monocular scotoma than nasal hemianopia, since the lesion would need to involve the entire temporal hemiretina in the latter.

Educational objective:
Aneurysm or atherosclerotic calcification of the internal carotid artery can laterally impinge on the optic chiasm. This can cause nasal hemianopia by damaging uncrossed optic nerve fibers from the temporal portion of the ipsilateral retina.

Time Spent: 10 seconds

Copyright © USMLEWorld,LLC.

Last updated: [5/9/2013]

www.zeallsoft.com

2 3 4 5 6 7 8 9 10 11 12 13 14 15 16 17 18 19 20 21 22 23 24 25 26 27 28 29 30 31 32 33 34 35 36 37 38 39 40 41

A 55-year-old man comes to the physician because of swelling in his groin that he first noticed 2 weeks ago. Physical examination shows a bulge above the inguinal ligament that increases in size when the patient is asked to cough. He is referred to a surgeon and scheduled to undergo elective laparoscopic hernia repair. Which of the following landmarks will best aid the surgeon in distinguishing an indirect from a direct inguinal hernia?

- ✔ A. Inferior epigastric vessels [78%]
- B. Cooper's ligament [3%]
- C. Femoral vein [4%]
- D. Transversalis fascia [5%]
- E. Rectus muscle sheath [2%]
- F. Spermatic cord [7%]

Explanation:

User Id: 477875

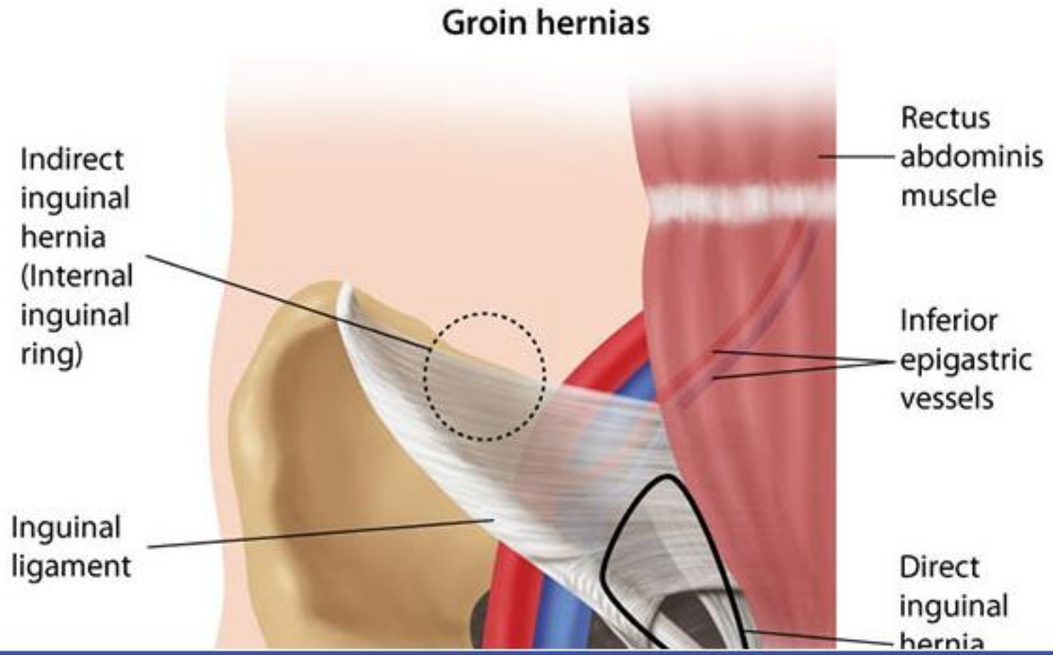

2 3 4 5 6 7 8 9 10 11 12 13 14 15 16 17 18 19 20 21 22 23 24 25 26 27 28 29 30 31 32 33 34 35 36 37 38 39 40 41

Explanation:

User Id: 477875

Groin hernias

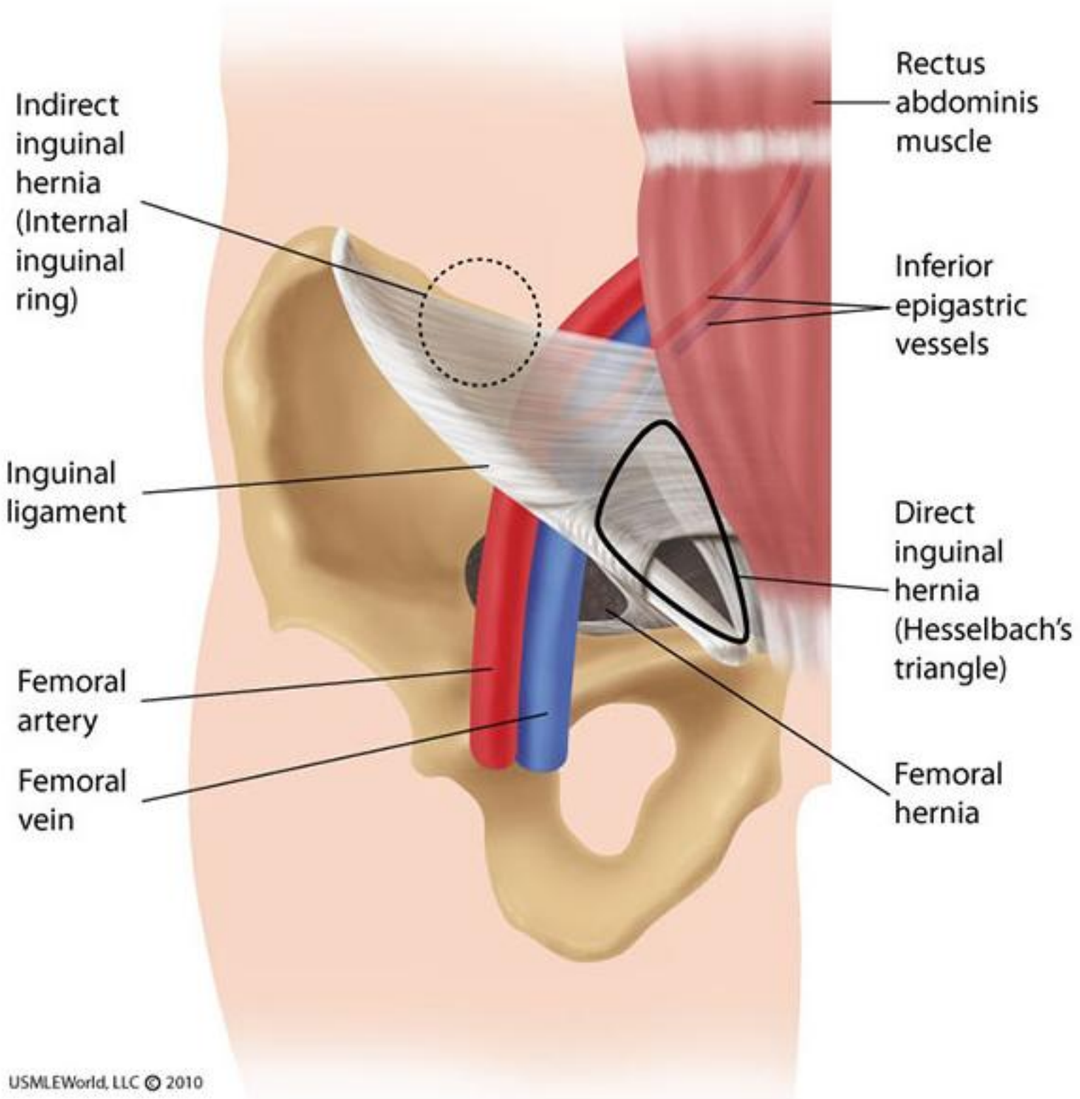

2
3
4
5
6
7
8
9
10
11
12
13
14
15
16
17
18
19
20
21
22
23
24
25
26
27
28
29
30
31
32
33
34
35
36
37
38
39
40
41

Inguinal hernias are common in men, and 25% will be found to have an inguinal hernia during their lifetime (versus 2% of women). In contrast to femoral hernias, inguinal hernias are located above the inguinal ligament. The inferior epigastric vessels serve as an anatomic landmark that can be used to distinguish between direct and indirect inguinal hernias. These vessels are clearly visible on the anterior abdominal wall during laparoscopic hernia repair.

Type of hernia	Site of protrusion	Lower border	Medial border	Lateral border
Direct inguinal	Hesselbach triangle	Inguinal ligament	Rectus abdominis muscle	Inferior epigastric vessels
Indirect inguinal	Deep inguinal ring	Inguinal ligament	Inferior epigastric vessels	

© USMLEWorld, LLC

Indirect inguinal hernias are more common than direct and tend to appear on the right side. They occur due to failure of the processus vaginalis to obliterate, allowing abdominal contents to protrude through the deep inguinal ring. Abdominal contents follow the path of the inguinal canal and may exit through the external inguinal ring into the scrotum. On examination, these hernias can be detected by deep palpation of the external ring with the tip of the finger.

Direct inguinal hernias protrude through Hesselbach's triangle, a weak spot of the anterior abdominal wall. Hesselbach's triangle is bounded by the rectus abdominis muscle medially, inferior epigastric vessels laterally, and inguinal ligament inferiorly. Compared to indirect inguinal hernias, direct hernias are less prone to incarceration due to their wide neck. It is also uncommon for them to descend into the scrotum as there is no direct path. Direct inguinal hernias are best felt with the pulp of the examiner's finger on deep palpation.

(Choice B) Cooper's (pectineal) ligament will be posterior to a femoral hernia.

2 3 4 5 6 7 8 9 10 11 12 13 14 15 16 17 18 19 20 21 22 23 24 25 26 27 28 29 30 31 32 33 34 35 36 37 38 39 40 41

			muscle	vessels
Indirect inguinal	Deep inguinal ring	Inguinal ligament	Inferior epigastric vessels	

© USMLEWorld, LLC

Indirect inguinal hernias are more common than direct and tend to appear on the right side. They occur due to failure of the processus vaginalis to obliterate, allowing abdominal contents to protrude through the deep inguinal ring. Abdominal contents follow the path of the inguinal canal and may exit through the external inguinal ring into the scrotum. On examination, these hernias can be detected by deep palpation of the external ring with the tip of the finger.

Direct inguinal hernias protrude through Hesselbach's triangle, a weak spot of the anterior abdominal wall. Hesselbach's triangle is bounded by the rectus abdominis muscle medially, inferior epigastric vessels laterally, and inguinal ligament inferiorly. Compared to indirect inguinal hernias, direct hernias are less prone to incarceration due to their wide neck. It is also uncommon for them to descend into the scrotum as there is no direct path. Direct inguinal hernias are best felt with the pulp of the examiner's finger on deep palpation.

(Choice B) Cooper's (pectineal) ligament will be posterior to a femoral hernia.

(Choice C) The femoral vein will be lateral to a femoral hernia.

(Choice D) The transversalis fascia lies posteriorly to indirect inguinal hernias.

(Choice E) The rectus abdominis muscle sheath is medial to direct inguinal hernias.

(Choice F) Indirect inguinal hernial sacs are located along the anteromedial aspect of the spermatic cord.

Educational objective:
Indirect inguinal hernias are located lateral to the inferior epigastric vessels. They can continue into the scrotum and are felt by deep palpation of the external inguinal ring with the tip of the finger. In contrast, direct inguinal hernias are located medially to the inferior epigastric vessels. They do not protrude into the scrotum and are best felt with the pulp of the finger.

Time Spent: 2 seconds Copyright © USMLEWorld,LLC. Last updated: [2/5/2013]

2 3 4 5 6 7 8 9 10 11 12 13 14 15 16 17 18 19 20 21 22 23 24 25 26 27 28 29 30 31 32 33 34 35 36 37 38 39 40 41

A 52-year-old male presents to your office with a painless mass in his groin. On physical examination, you palpate several hard lymph nodes in the right inguinal area. Lymph node biopsy reveals malignant cells that most likely originated from the:

- A. Testes [26%]
- B. Prostate [23%]
- C. Bladder [7%]
- ✔ D. Anal canal [38%]
- E. Sigmoid colon [6%]

Explanation: **User Id: 477875**

This patient has palpable firm superficial inguinal lymph nodes. The superficial inguinal lymph nodes drain all cutaneous lymph from the umbilicus to the feet, including the external genitalia and anus (up to the beginning of the rectum, the dentate line), but excluding the posterior calf, which drains to the popliteal lymph nodes. The superficial inguinal lymph nodes lie in a region bounded by the inguinal ligament, sartorius muscle, and adductor longus muscle, and overlie the femoral nerve, artery and vein.

(Choice A) In general, lymph vessels follow the paths of the arteries and veins supplying a particular structure. The testes receive their blood supply from the testicular arteries, which arise directly from the abdominal aorta just inferior to the renal arteries. The lymph vessels that drain the testes follow a path from the testes to the abdominal aortic lymph nodes.

(Choice B) Lymph from the prostate drains primarily to the internal iliac nodes, but also to the external iliac nodes and sacral nodes (minor pathways).

(Choice C) Lymph from the superior portion of the bladder drains to the external iliac nodes while lymph from the inferior portion of the bladder drains to the internal iliac nodes.

(Choice E) Lymph from the sigmoid colon drains to the inferior mesenteric lymph nodes.

Educational Objective:
All skin from the umbilicus down, including the anus (up to the dentate/pectinate line) but excluding the

2
3
4
5
6
7
8
9
10
11
12
13
14
15
16
17
18
19
20
21
22
23
24
25
26
27
28
29
30
31
32
33
34
35
36
37
38
39
40
41

palpate several hard lymph nodes in the right inguinal area. Lymph node biopsy reveals malignant cells that most likely originated from the:

- A. Testes [26%]
- B. Prostate [23%]
- C. Bladder [7%]
- ✔ D. Anal canal [38%]
- E. Sigmoid colon [6%]

Explanation: **User Id: 477875**

This patient has palpable firm superficial inguinal lymph nodes. The superficial inguinal lymph nodes drain all cutaneous lymph from the umbilicus to the feet, including the external genitalia and anus (up to the beginning of the rectum, the dentate line), but excluding the posterior calf, which drains to the popliteal lymph nodes. The superficial inguinal lymph nodes lie in a region bounded by the inguinal ligament, sartorius muscle, and adductor longus muscle, and overlie the femoral nerve, artery and vein.

(Choice A) In general, lymph vessels follow the paths of the arteries and veins supplying a particular structure. The testes receive their blood supply from the testicular arteries, which arise directly from the abdominal aorta just inferior to the renal arteries. The lymph vessels that drain the testes follow a path from the testes to the abdominal aortic lymph nodes.

(Choice B) Lymph from the prostate drains primarily to the internal iliac nodes, but also to the external iliac nodes and sacral nodes (minor pathways).

(Choice C) Lymph from the superior portion of the bladder drains to the external iliac nodes while lymph from the inferior portion of the bladder drains to the internal iliac nodes.

(Choice E) Lymph from the sigmoid colon drains to the inferior mesenteric lymph nodes.

Educational Objective:
All skin from the umbilicus down, including the anus (up to the dentate/pectinate line) but excluding the posterior calf, drains to the superficial inguinal lymph nodes.

Time Spent: 1 seconds

Copyright © USMLEWorld,LLC.

Last updated: [7/7/2010]

Super Screen Capture - Unregistered
FullScreen Window Scroll Shape Polygon Picker Video Audio Manager Options Buy Now

www.zeallsoft.com

2
3
4
5
6
7
8
9
10
11
12
13
14
15
16
17
18
19
20
21
22
23
24
25
26
27
28
29
30
31
32
33
34
35
36
37
38
39
40
41

A 45-year-old patient presents with vague abdominal pain and undergoes CT imaging of the abdomen (see slide below). Which of the following labeled organs is supplied by an artery of the foregut although it is not a foregut derivative?

A. A [11%]
B. B [8%]
C. C [10%]
D. D [18%]
✔ E. E [53%]

2
3
4
5
6
7
8
9
10
11
12
13
14
15
16
17
18
19
20
21
22
23
24
25
26
27
28
29
30
31
32
33
34
35
36
37
38
39
40
41

A. A [11%]
B. B [8%]
C. C [10%]
D. D [18%]
✔ E. E [53%]

Explanation: **User Id: 477875**

The **"E"** above labels the spleen, a mesoderm-derived organ that originates from the dorsal mesentery. The spleen receives its blood supply from the splenic artery, which is a branch of the celiac trunk, the primary artery of the foregut. The foregut includes the esophagus through the second part of the duodenum, the liver **(Choice A)**, the gallbladder, and a portion of the pancreas. Unlike the spleen, the pancreas and liver develop as outpouchings of the primitive gut tube during embryogenesis.

(Choice A) The liver is an endoderm-derived foregut structure that forms from a diverticulum of the primitive gut tube within the ventral mesentery. Its main arterial supply is the proper hepatic artery, a branch of the celiac trunk.

(Choice B) The kidneys are retroperitoneal organs derived from the mesoderm. They are not derived from the gut.

(Choice C) The first 2/3 of the transverse colon is considered part of the midgut, and the last 1/3 is part of the hindgut. The superior mesenteric artery supplies the midgut portion of the transverse colon via the middle colic artery while the inferior mesenteric artery supplies the distal portion via the left colic artery. These vessels anastomose via the marginal artery.

(Choice D) The pancreas is an endoderm-derived structure of the foregut and midgut. It receives blood from the superior and inferior pancreaticoduodenal arteries as well as other arterial branches of the celiac trunk and superior mesenteric artery.

Educational Objective:
The spleen is not a gut derivative; it forms from the mesodermal dorsal mesentery. The splenic artery, however, is a branch of the celiac trunk (the primary blood supply of the foregut).

Time Spent: 3 seconds Copyright © USMLEWorld,LLC. Last updated: [7/7/2010]

www.zeallsoft.com

2
3
4
5
6
7
8
9
10
11
12
13
14
15
16
17
18
19
20
21
22
23
24
25
26
27
28
29
30
31
32
33
34
35
36
37
38
39
40
41

A 36-year-old man is rushed to the emergency department after the sudden onset of shortness of breath and difficulty swallowing. He has visited the emergency department several times before for food and skin allergies. He is unconscious on arrival. Examination shows excessive accessory respiratory muscle use and edematous swelling of his face, lips, and tongue. There is also scattered urticaria over his upper body. Attempts at intubation are unsuccessful due to massive soft tissue edema involving his pharynx. A decision is made to perform an emergency cricothyrotomy. The incision made during this procedure will most likely pass through which of the following structures?

- A. Buccopharyngeal fascia and platysma [2%]
- B. Platysma and thyroid isthmus [4%]
- C. Pretracheal fascia and cricoid cartilage [32%]
- D. Pretracheal fascia and prevertebral fascia [2%]
- ✔ E. Superficial cervical fascia and cricothyroid membrane [59%]

Explanation:

User Id: 477875

Palpation of cricothyroid membrane

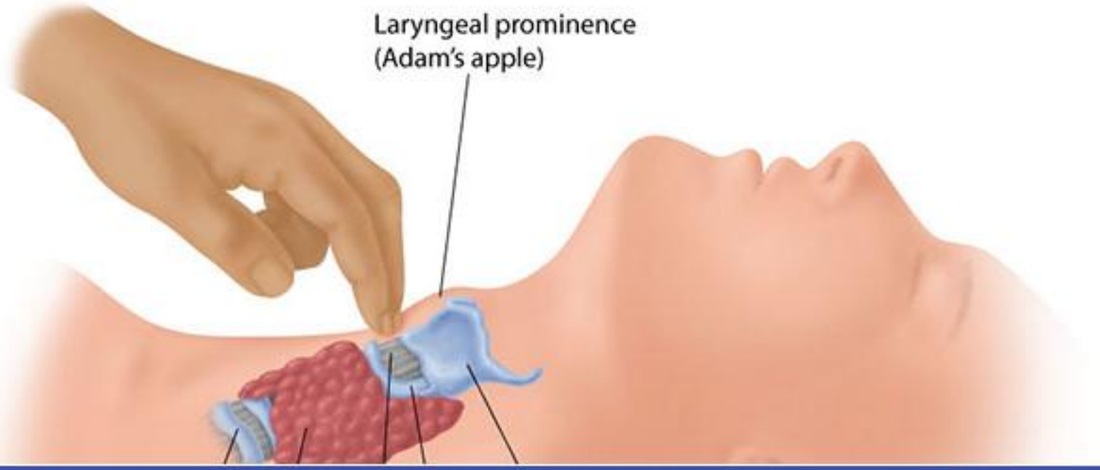

www.zeallsoft.com

2
3
4
5
6
7
8
9
10
11
12
13
14
15
16
17
18
19
20
21
22
23
24
25
26
27
28
29
30
31
32
33
34
35
36
37
38
39
40
41

Palpation of cricothyroid membrane

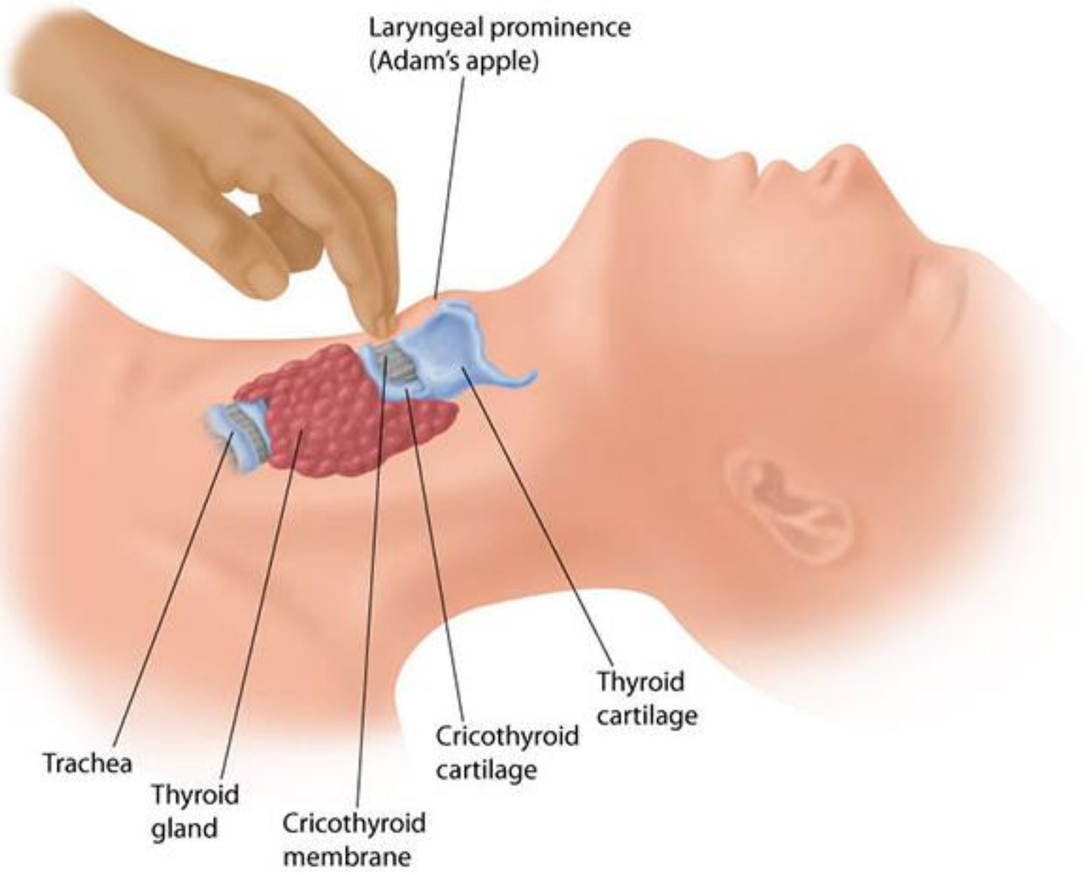

Cricothyrotomy

www.zeallsoft.com

2
3
4
5
6
7
8
9
10
11
12
13
14
15
16
17
18
19
20
21
22
23
24
25
26
27
28
29
30
31
32
33
34
35
36
37
38
39
40
41

Cricothyrotomy

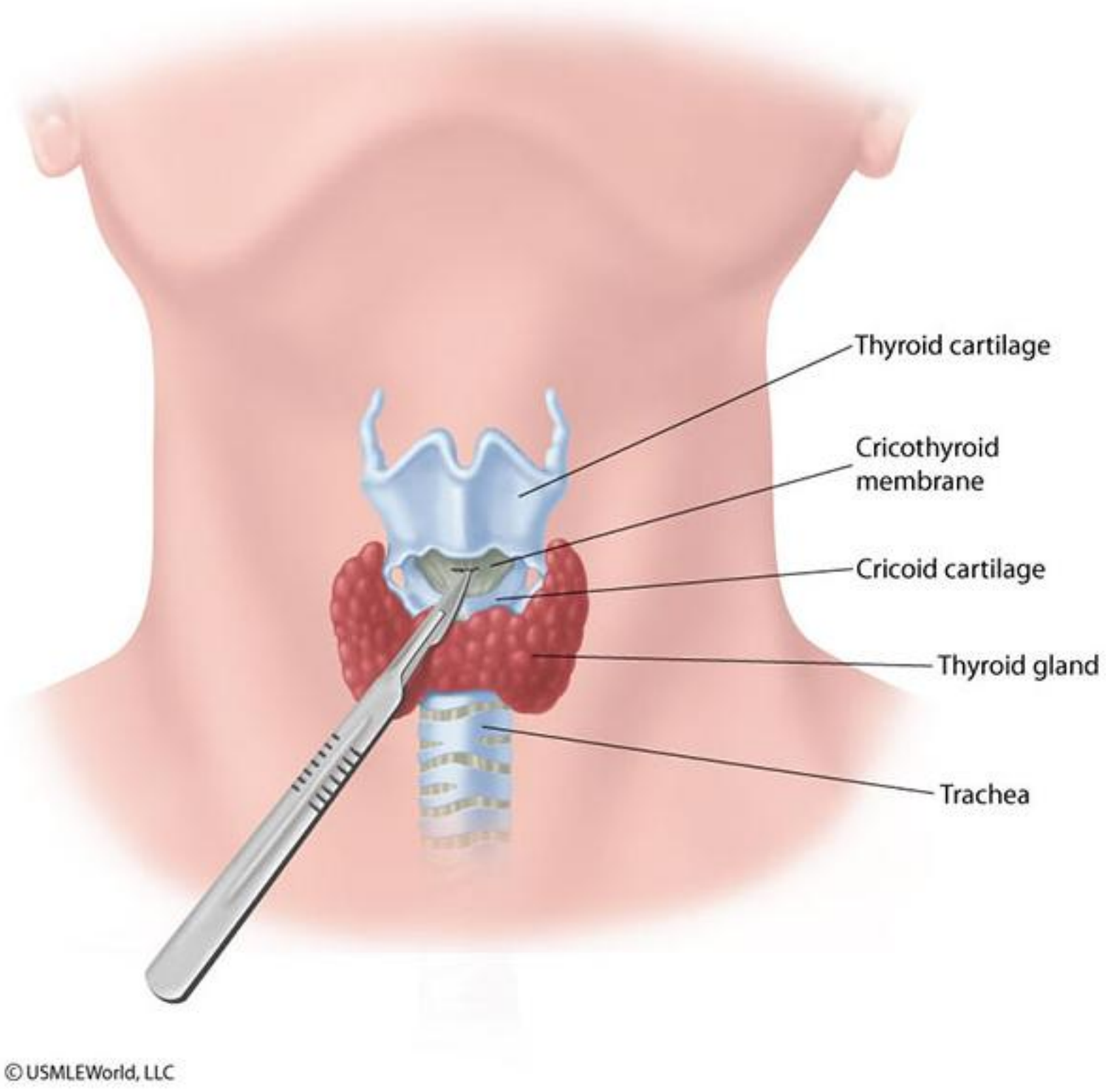

© USMLEWorld, LLC

2
3
4
5
6
7
8
9
10
11
12
13
14
15
16
17
18
19
20
21
22
23
24
25
26
27
28
29
30
31
32
33
34
35
36
37
38
39
40
41

© USMLEWorld, LLC

This patient is experiencing acute, life-threatening laryngeal edema as part of an anaphylactic reaction precipitated by exposure to an allergen. Laryngeal edema can initially present with throat tightness, difficulty swallowing, dyspnea, and hoarseness. However, the condition can **quickly** progress to compromise the airway and cause asphyxiation.

Cricothyrotomy is indicated when an emergency airway is required and orotracheal or nasotracheal intubation is either unsuccessful or contraindicated (eg, due to massive hemorrhage, vomiting, facial trauma, or airway obstruction). The procedure establishes an airway through the placement of a tube between the cricoid and thyroid cartilages and requires an incision though the following structures:

1. Skin
2. Superficial cervical fascia (including subcutaneous fat and platysma muscle)
3. Investing and pretracheal layers of the deep cervical fascia
4. Cricothyroid membrane

(Choice A) The buccopharyngeal fascia extends from the carotid sheath to invest the pharyngeal constrictor muscles. This fascial layer lies anterior to the prevertebral fascia, forming the retropharyngeal space between them. Infections involving the retropharyngeal space can extend directly into the superior mediastinum and cause acute necrotizing mediastinitis.

(Choices B and C) The cricoid cartilage lies inferior to the thyroid cartilage at the level of C6 vertebra and the thyroid isthmus lies inferior to the cricoid cartilage. The cricothyrotomy incision does not pierce these structures.

(Choice D) The **deep cervical fascia** is composed of three layers: investing, pretracheal, and prevertebral. The prevertebral layer of the deep fascia is not penetrated during cricothyrotomy.

Educational objective:
Cricothyrotomy is indicated when an emergency airway is required and orotracheal or nasotracheal intubation is either unsuccessful or contraindicated. The cricothyrotomy incision passes through the superficial cervical fascia, pretracheal fascia, and the cricothyroid membrane.

Time Spent: 2 seconds

Copyright © USMLEWorld,LLC.

Last updated: [3/25/2013]

2 3 4 5 6 7 8 9 10 11 12 13 14 15 16 17 18 19 20 21 22 23 24 25 26 27 28 29 30 31 32 33 34 35 36 37 38 39 40 41

A 51-year-old woman comes to the physician complaining that the right side of her face has felt "funny" for the past 12 hours. Her past medical history is significant for type 2 diabetes mellitus. Physical examination reveals asymmetry of her face when she smiles, puffs out her cheeks, and closes her eyes tightly. There is also effacement of the right nasolabial fold, and her mouth is drawn toward the left side. Which of the following additional findings is most likely associated with this patient's condition?

- A. Attenuated sense of touch on the right side of face [15%]
- ✔ B. Decreased tearing from the right eye [50%]
- C. Failure to elevate the palate when saying "ah" [9%]
- D. Inability to sweat on the right side of face [16%]
- E. Loss of taste sensation from the posterior 1/3 of the tongue [9%]

Explanation: **User Id: 477875**

This patient's presentation is consistent with Bell's palsy, an idiopathic paresis of the facial nerve. To understand the pathophysiology of Bell's palsy, it is important to understand the function of the facial nerve (CN VII). The facial nerve is a mixed nerve, consisting of the following:

1. Motor output to the facial muscles
2. Parasympathetic innervation to the lacrimal, submandibular, and sublingual salivary glands
3. Special afferent fibers for taste from the anterior 2/3 of the tongue
4. Somatic afferents from the pinna and external auditory canal

Patients with Bell's palsy typically present with sudden onset of unilateral facial paralysis. Specific findings include impaired eye closure, eyebrow sagging, inability to smile and frown on the affected side, disappearance of the nasolabial fold, and the mouth being drawn to the non-affected side. Patients afflicted with Bell's palsy may also have decreased tearing, hyperacusis, and/or loss of taste sensation over the anterior two-thirds of the tongue.

(Choice A) Trigeminal nerve (CN V) somatic afferents are responsible for providing general sensation over the face; the motor branch of the trigeminal nerve (V_3) innervates the muscles of mastication and the tensor tympani.

2 3 4 5 6 7 8 9 10 11 12 13 14 15 16 17 18 19 20 21 22 23 24 25 26 27 28 29 30 31 32 33 34 35 36 37 38 39 40 41

(CN VII). The facial nerve is a mixed nerve, consisting of the following:

1. Motor output to the facial muscles
2. Parasympathetic innervation to the lacrimal, submandibular, and sublingual salivary glands
3. Special afferent fibers for taste from the anterior 2/3 of the tongue
4. Somatic afferents from the pinna and external auditory canal

Patients with Bell's palsy typically present with sudden onset of unilateral facial paralysis. Specific findings include impaired eye closure, eyebrow sagging, inability to smile and frown on the affected side, disappearance of the nasolabial fold, and the mouth being drawn to the non-affected side. Patients afflicted with Bell's palsy may also have decreased tearing, hyperacusis, and/or loss of taste sensation over the anterior two-thirds of the tongue.

(Choice A) Trigeminal nerve (CN V) somatic afferents are responsible for providing general sensation over the face; the motor branch of the trigeminal nerve (V_3) innervates the muscles of mastication and the tensor tympani.

(Choice C) Palate elevation and the gag reflex involve the glossopharyngeal (CN IX) and vagus (CN X) nerves.

(Choice D) Horner's syndrome occurs due to interruption of sympathetic innervation and clinically presents with ptosis, miosis, anhydrosis, and enophthalmos. Post-synaptic sympathetic axons travel in a perivascular plexus along the carotid arteries to reach and innervate the face.

(Choice E) Taste sensation from the posterior 1/3 of the tongue is provided by the glossopharyngeal nerve (CN IX).

Educational objective:
In addition to unilateral facial paralysis, patients with Bell's palsy may experience decreased tearing, hyperacusis, and/or loss of taste sensation over the anterior two-thirds of the tongue.

References:

1. Seventh cranial neuropathy.

Time Spent: 5 seconds

Copyright © USMLEWorld,LLC.

Last updated: [12/26/2012]

www.zeallsoft.com

2
3
4
5
6
7
8
9
10
11
12
13
14
15
16
17
18
19
20
21
22
23
24
25
26
27
28
29
30
31
32
33
34
35
36
37
38
39
40
41

A 30-year-old male presents to the emergency room after being involved in a street fight. There is significant soft tissue swelling around the left eye.

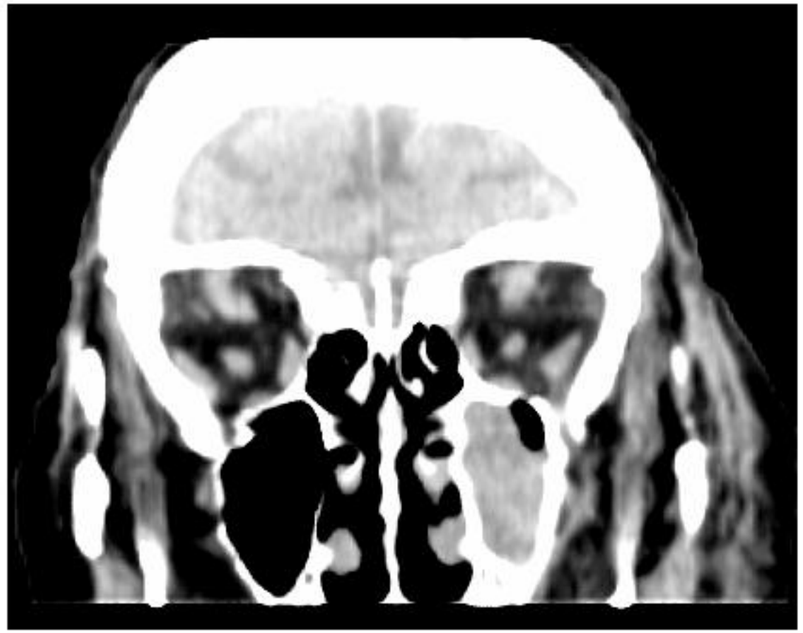

The imaging study above reveals a left orbital floor fracture with fluid accumulation in the:

- A. Ethmoid cells [3%]
- ✔ B. Maxillary sinus [89%]
- C. Frontal sinus [2%]
- D. Sphenoid sinus [4%]
- E. Inferior conchae [1%]

Explanation:

User Id: 477875

2 3 4 5 6 7 8 9 10 11 12 13 14 15 16 17 18 19 20 21 22 23 24 25 26 27 28 29 30 31 32 33 34 35 36 37 38 39 40 41

A. Ethmoid cells [3%]

✔ B. Maxillary sinus [89%]

C. Frontal sinus [2%]

D. Sphenoid sinus [4%]

E. Inferior conchae [1%]

Explanation: **User Id: 477875**

The orbit is bound superiorly by the thick orbital plate of the frontal bone and laterally by the thick bone of the zygoma and greater and lesser sphenoid wings. In contrast, the orbital floor is composed of a very thin layer of bone that separates the orbit from the air-filled maxillary sinus. Similarly, the orbit's medial wall is composed of the thin ethmoid and lacrimal bones, which separate it from the ethmoid air cells.

Blunt trauma to the eye causes a rapid increase in pressure that typically does not rupture the globe but is transmitted posteriorly into the orbit. The weakest plates of bone in the orbit, the medial and inferior walls, are common sites of fracture. Fracture is typically evident on radiographic imaging, and fluid (blood) can usually be visualized in the normally air-filled adjacent sinuses. On the right side of the image above (corresponding to the patient's left side), the maxillary sinus (below the orbital floor) is filled with fluid.

(Choice A) The ethmoid air cells are medial to the orbit. Here they are unaffected, but they can be affected in blowout fractures of the orbit's medial wall.

(Choice C) The frontal sinus is not pictured above. It lies in the medial part of the supraorbital frontal bone.

(Choice D) The sphenoid sinuses (not pictured above) lie anterior to the optic chiasm and are not in close relation to the orbit.

(Choice E) The inferior nasal conchae form part of the nasal turbinate system. They are not air-filled sinuses.

Educational Objective:
Blunt trauma to the globe can cause orbital blowout fractures. These fractures most commonly involve the medial or inferior orbital walls, because the bone bordering the ethmoid and maxillary sinuses is thin.

Time Spent: 3 seconds Copyright © USMLEWorld,LLC. Last updated: [7/7/2010]

2, 3, 4, 5, 6, 7, 8, 9, 10, 11, 12, 13, 14, 15, 16, 17, 18, 19, 20, 21, 22, 23, 24, 25, 26, 27, 28, 29, 30, 31, 32, 33, 34, 35, 36, 37, 38, 39, 40, 41

A 32-year-old female presents to your office with severe nausea and recurrent bilious vomiting. Her symptoms initially began as postprandial epigastric pain and early satiety, but have progressed over the last two weeks. She works as an actress, and tells you that her symptoms only started when she "landed a role in a soap opera" and was inspired to lose 25 lbs. on a "crash diet". On physical exam, her abdomen is tender and slightly distended with high-pitched bowel sounds. Concerned about a small bowel obstruction, you admit the patient to the hospital. A laparotomy is performed, and it is observed that the angle between her superior mesenteric artery and her aorta is significantly decreased. Which of the following structures is most likely to be obstructed by the artery?

- A. Ascending portion of the duodenum [6%]
- B. Descending portion of the duodenum [11%]
- C. Duodenal bulb [7%]
- D. Duodenojejunal flexure [20%]
- E. Gastric antrum [3%]
- ✔ F. Transverse portion of the duodenum [54%]

Explanation: **User Id: 477875**

The superior mesenteric artery (SMA) leaves the aorta at the level of L1 and supplies the intestine from the duodenum and pancreas to the left colic flexure. The transverse portion of the duodenum lies horizontally at the level of L3, between the aorta and superior mesenteric artery. Normally, the SMA and aorta form an approximately 45 degree angle. If this angle diminishes to less than 20 degrees, the transverse portion of the duodenum can get entrapped between the SMA and aorta, leading to symptoms of partial small bowel obstruction. This condition is called superior mesenteric artery syndrome.

Superior mesenteric artery syndrome
Anterior view

www.zeallsoft.com

2
3
4
5
6
7
8
9
10
11
12
13
14
15
16
17
18
19
20
21
22
23
24
25
26
27
28
29
30
31
32
33
34
35
36
37
38
39
40
41

Superior mesenteric artery syndrome
Anterior view

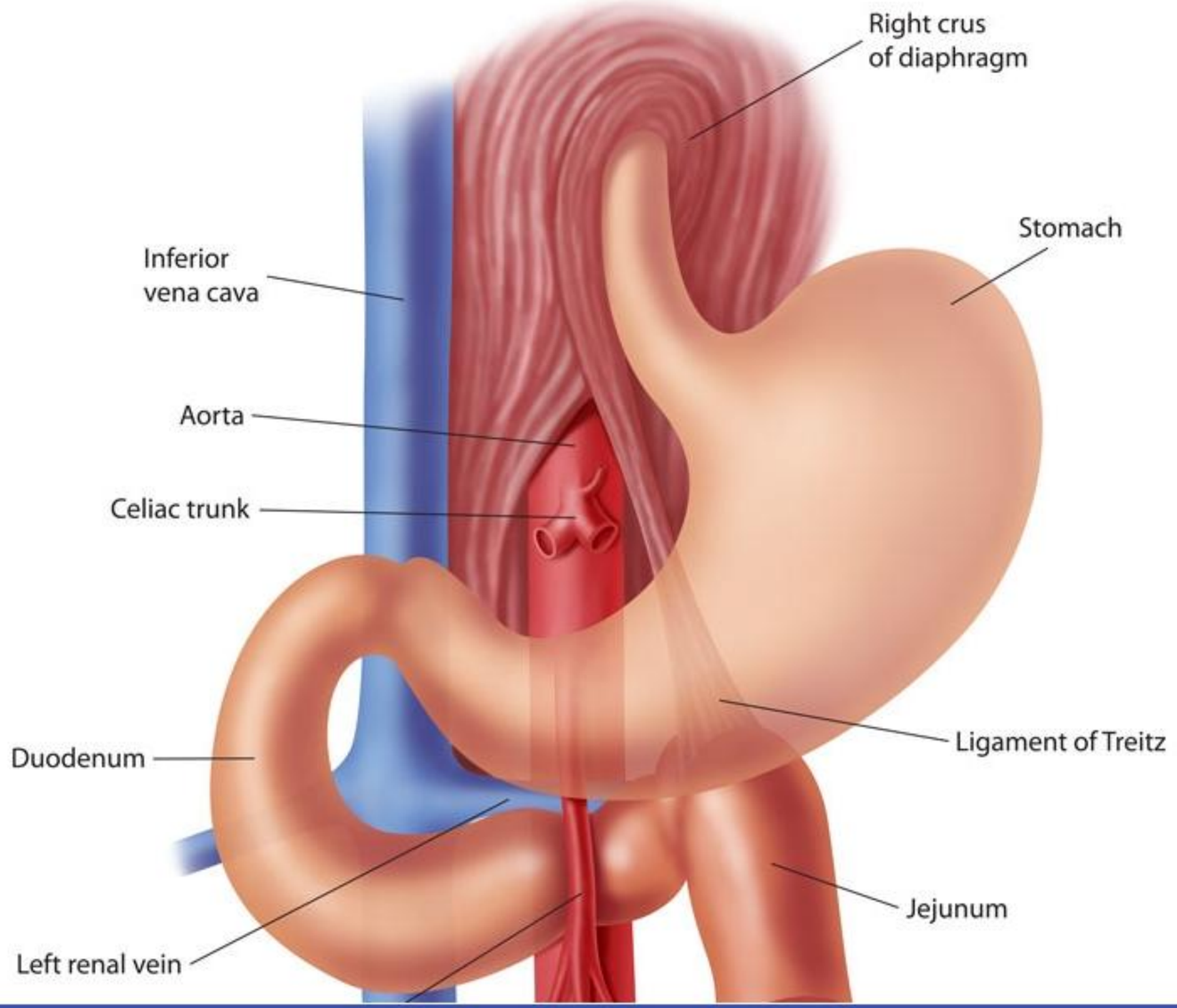

2 3 4 5 6 7 8 9 10 11 12 13 14 15 16 17 18 19 20 21 22 23 24 25 26 27 28 29 30 31 32 33 34 35 36 37 38 39 40 41

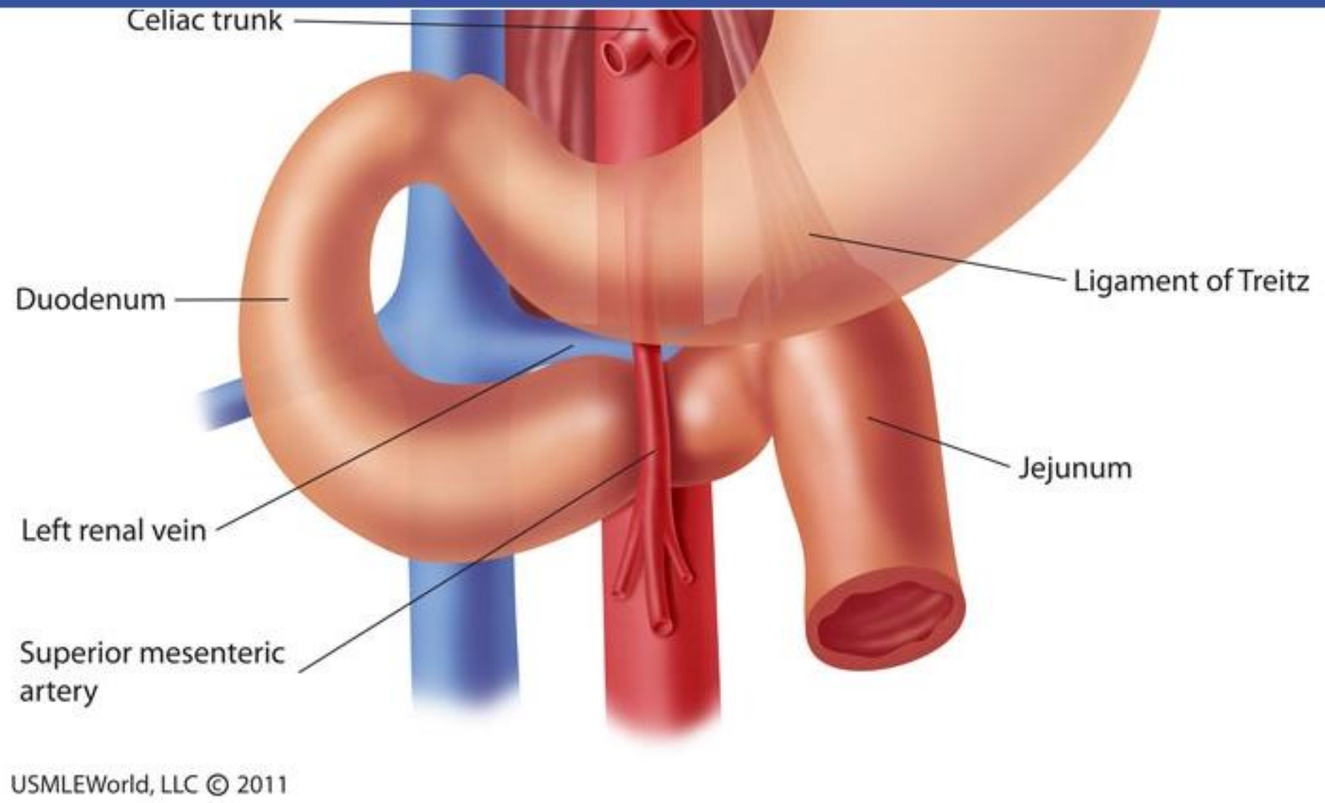

Narrowing of the aortomesenteric angle can occur with any condition that causes **diminished mesenteric fat**, including low body weight, recent weight loss, severe burns or other inducers of catabolism, and prolonged bed rest. It can also occur with pronounced lordosis or after surgical correction of scoliosis, as this procedure lengthens the spine resulting in decreased mobility of the SMA.

Educational Objective:
Superior mesenteric artery syndrome occurs when the transverse portion of the duodenum is entrapped between the SMA and aorta, causing symptoms of partial intestinal obstruction. This syndrome occurs when the aortomesenteric angle critically decreases, secondary to diminished mesenteric fat, pronounced lordosis, or surgical correction of scoliosis.

Time Spent: 2 seconds

Copyright © USMLEWorld,LLC.

Last updated: [1/16/2013]

www.zeallsoft.com

2
3
4
5
6
7
8
9
10
11
12
13
14
15
16
17
18
19
20
21
22
23
24
25
26
27
28
29
30
31
32
33
34
35
36
37
38
39
40
41

A 48-year-old male presents to your office with recent weight loss and vague abdominal pain. He admits to drinking alcohol regularly, but denies any past medical problems. A 72-hour stool collection reveals excessive excretion of neutral fat. Involvement of which of the following structures is most likely responsible for this patient's symptoms?

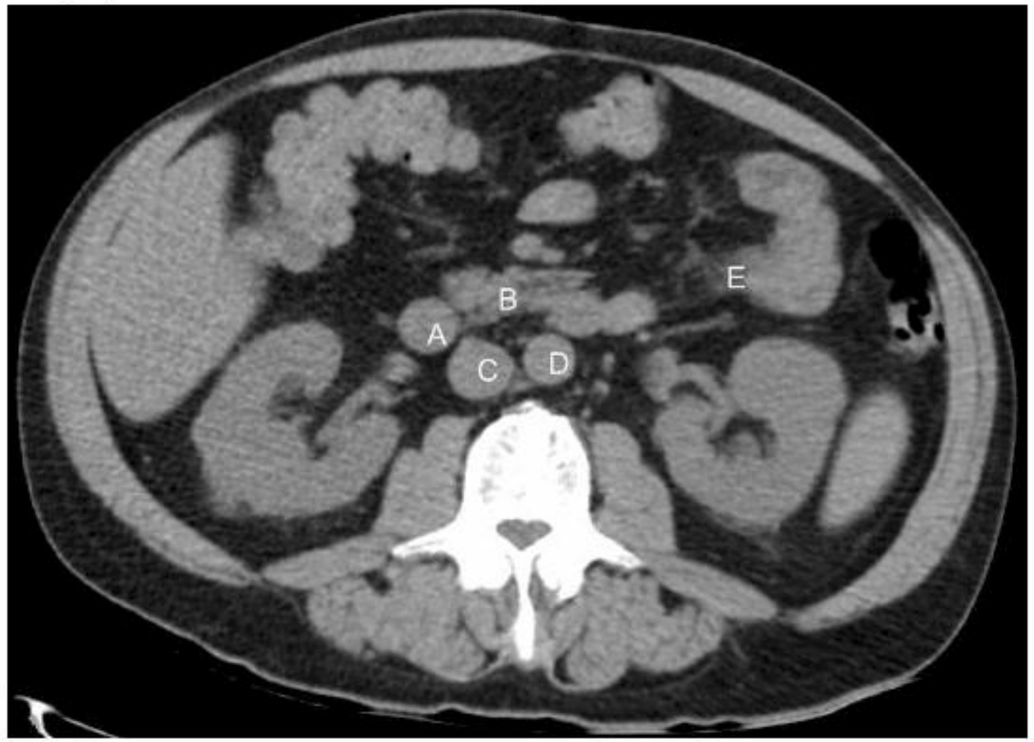

A. A [3%]
✔ B. B [87%]
C. C [1%]
D. D [1%]
E. E [8%]

2, 3, 4, 5, 6, 7, 8, 9, 10, 11, 12, 13, 14, 15, 16, 17, 18, 19, 20, 21, 22, 23, 24, 25, 26, 27, 28, 29, 30, 31, 32, 33, 34, 35, 36, 37, 38, 39, 40, 41

- ✔ B. B [87%]
- C. C [1%]
- D. D [1%]
- E. E [8%]

Explanation: **User Id: 477875**

The patient described in the question stem is suffering from exocrine pancreatic insufficiency, which is evidenced by his body's inability to normally metabolize fat. People who suffer from chronic pancreatitis, often caused by alcoholism, have severe abdominal pain, stool that floats in the toilet bowl (due to excess fat content), and weight loss.

The head, neck, and body of the pancreas are retroperitoneal, while the tail is peritoneal. The head of the pancreas lies in the curve of the duodenum and overlies the L2 vertebra. The body overlies the L1 and L2 vertebrae and makes contact posteriorly with the aorta, the superior mesenteric vessels, and the left kidney. The tail of the pancreas courses within the splenorenal ligament alongside the splenic vessels.

(Choice A) This structure is the second (descending) part of the duodenum.

(Choice C) This structure is the inferior vena cava (IVC). The IVC lies on the right side of the vertebrae in a retroperitoneal position.

(Choice D) This structure labels the abdominal aorta. The aorta in this region lies on the left side of the vertebrae in a retroperitoneal position.

(Choice E) These structures are loops of the jejunum. At this level in the abdominal cavity, loops of small bowel represent jejunum. If this CT slice were of the inferior (lower) abdomen, the small bowel would more likely be the ileum.

Educational Objective:
On abdominal CT scans, the pancreas can be identified by its head in close association with the second part of the duodenum; by its body overlying the left kidney, aorta, IVC and superior mesenteric vessels; and also by the tail lying in the splenorenal ligament.

Time Spent: 2 seconds Copyright © USMLEWorld,LLC. Last updated: [7/7/2010]

2, 3, 4, 5, 6, 7, 8, 9, 10, 11, 12, 13, 14, 15, 16, 17, 18, 19, 20, 21, 22, 23, 24, 25, 26, 27, 28, 29, 30, 31, 32, 33, 34, 35, 36, 37, 38, 39, 40, 41

A 34-year-old male with a squamous cell carcinoma undergoes surgical neck dissection. While attempting to ligate the inferior thyroid artery, the surgeon accidentally damages a nerve that lies in close proximity to it. Which of the following nerves was most likely damaged?

- A. Superior laryngeal nerve [13%]
- ✔ B. Recurrent laryngeal nerve [79%]
- C. Ansa cervicalis [3%]
- D. Hypoglossal nerve [2%]
- E. Accessory nerve [2%]

Explanation: **User Id: 477875**

The inferior thyroid artery arises from the thyrocervical trunk, a branch of the subclavian artery. Along with the superior thyroid arteries (branches of the external carotid arteries), the inferior thyroid arteries provide blood to the thyroid gland and other structures of the anterior neck.

From the thyrocervical trunk, the inferior thyroid artery courses deep to the vagus nerve, common carotid artery and internal jugular vein before turning toward the thyroid. Just before meeting the thyroid gland, this artery courses just superficial to the recurrent laryngeal nerve. The recurrent laryngeal nerve is a branch of the vagus nerve that loops below the aortic arch on the left and below the subclavian artery on the right to provide motor innervation to the muscles of the larynx (all except the cricothyroid muscle). Unilateral injury to this nerve causes hoarseness; bilateral injury causes respiratory difficulty due to airway obstruction by immobile vocal folds.

(Choice A) The superior laryngeal nerve is a branch of the vagus nerve that gives off internal and external branches. The superior thyroid artery courses with the external branch of this nerve; ligation of this artery

2 3 4 5 6 7 8 9 10 11 12 13 14 15 16 17 18 19 20 21 22 23 24 25 26 27 28 29 30 31 32 33 34 35 36 37 38 39 40 41

Explanation: **User Id: 477875**

The inferior thyroid artery arises from the thyrocervical trunk, a branch of the subclavian artery. Along with the superior thyroid arteries (branches of the external carotid arteries), the inferior thyroid arteries provide blood to the thyroid gland and other structures of the anterior neck.

From the thyrocervical trunk, the inferior thyroid artery courses deep to the vagus nerve, common carotid artery and internal jugular vein before turning toward the thyroid. Just before meeting the thyroid gland, this artery courses just superficial to the recurrent laryngeal nerve. The recurrent laryngeal nerve is a branch of the vagus nerve that loops below the aortic arch on the left and below the subclavian artery on the right to provide motor innervation to the muscles of the larynx (all except the cricothyroid muscle). Unilateral injury to this nerve causes hoarseness; bilateral injury causes respiratory difficulty due to airway obstruction by immobile vocal folds.

(Choice A) The superior laryngeal nerve is a branch of the vagus nerve that gives off internal and external branches. The superior thyroid artery courses with the external branch of this nerve; ligation of this artery during surgery may damage the external laryngeal nerve.

(Choice C) The ansa cervicalis is a loop of the cervical plexus that receives contributions from C1, C2 and C3. It courses deep to the sternocleidomastoid muscle and loops around the internal jugular vein. Branches from the ansa cervicalis innervate the sternohyoid, sternothyroid and omohyoid muscles.

(Choice D) The hypoglossal nerve (CN XII) exits the cranium through the hypoglossal canal and innervates all of the intrinsic muscles of the tongue except the palatoglossus.

(Choice E) The spinal accessory nerve (CN XI) exits the jugular foramen and courses on top of the levator scapulae muscle to innervate the sternocleidomastoid and trapezius muscles on either side.

Educational Objective:
The recurrent laryngeal nerve travels in close approximation to the inferior thyroid artery and can be injured in surgical procedures of the anterior neck (e.g. thyroidectomy), resulting in laryngeal muscle paralysis, hoarseness and dyspnea.

Time Spent: 1 seconds Copyright © USMLEWorld,LLC. Last updated: [7/7/2010]

2 3 4 5 6 7 8 9 10 11 12 13 14 15 16 17 18 19 20 21 22 23 24 25 26 27 28 29 30 31 32 33 34 35 36 37 38 39 40 41

A left-sided mass identified on an abdominal CT image in a 54-year-old male compresses the renal vein. Based on these CT scan findings, which of the following would you expect most in this patient?

- A. Esophageal varices [3%]
- B. Rectal varices [4%]
- ✔ C. Varicocele [80%]
- D. Left-sided ankle swelling [6%]
- E. Periumbilical venous distention [7%]

Explanation:

User Id: 477875

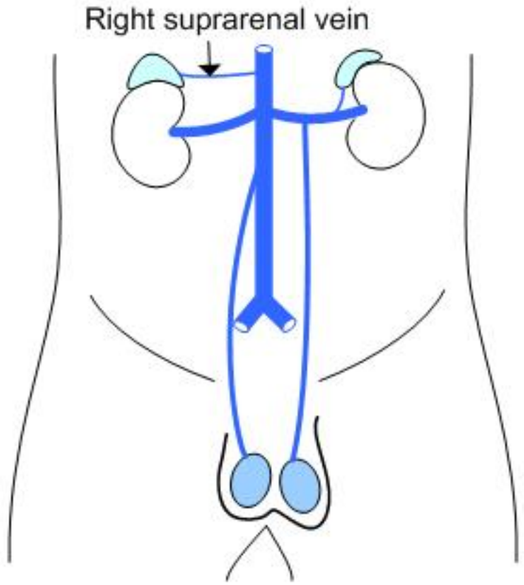

A left-sided abdominal mass compressing the left renal vein would be expected to cause venous hypertension, varicosities, and edema in any upstream structures. In contrast to the right renal vein, the left renal vein drains the left suprarenal gland and the left gonad in addition to the kidney. The renal veins do not

2
3
4
5
6
7
8
9
10
11
12
13
14
15
16
17
18
19
20
21
22
23
24
25
26
27
28
29
30
31
32
33
34
35
36
37
38
39
40
41

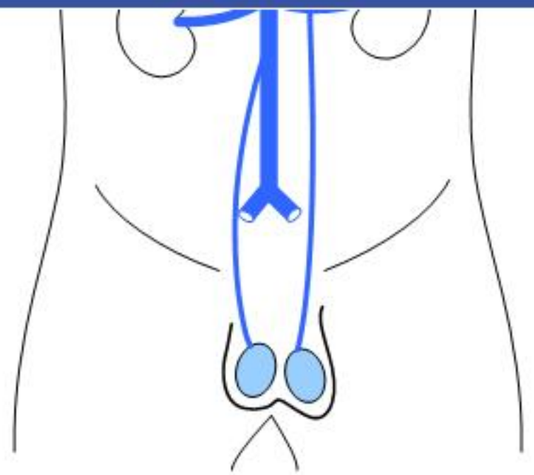

A left-sided abdominal mass compressing the left renal vein would be expected to cause venous hypertension, varicosities, and edema in any upstream structures. In contrast to the right renal vein, the left renal vein drains the left suprarenal gland and the left gonad in addition to the kidney. The renal veins do not participate in portal circulation. The patient described in the case above is a male, so venous hypertension due to obstruction of the left renal vein would eventually cause incompetence of the valves of the testicular veins and engorgement of the pampiniform plexus of veins around the testis, leading to a left-sided varicocele. Varicocele is most common on the left side due to this anatomy. Varicocele arising from idiopathic failure of the valves of the testicular vein is generally left untreated unless it becomes symptomatic or is felt to be causing problems with fertility.

(Choices A, B and E) Esophageal varices, rectal varices, and periumbilical venous distension are all signs of portal venous hypertension. The renal veins are not a part of the portal system.

(Choice D) Unilateral left-sided ankle swelling can result from many causes including obstruction of the left common iliac vein, left external iliac vein, left femoral vein, or any of the other major veins of the left leg.

Educational Objective:
The left gonadal (testicular or ovarian) vein drains into the left renal vein, commonly leading to left-sided varicoceles in males with obstructions of the left renal vein. The right gonadal vein drains directly into the inferior vena cava.

Time Spent: 2 seconds

Copyright © USMLEWorld,LLC.

Last updated: [7/7/2010]

2, 3, 4, 5, 6, 7, 8, 9, 10, 11, 12, 13, 14, 15, 16, 17, 18, 19, 20, 21, 22, 23, 24, 25, 26, 27, 28, 29, 30, 31, 32, 33, 34, 35, 36, 37, 38, 39, 40, 41

A 54-year-old female with chronic pelvic pain is found to have a right-sided ovarian mass. After the initial evaluation, surgery is planned to remove the mass. To avoid excessive bleeding during the surgery the surgeon should ligate which of the following structures?

- A. Round ligament [23%]
- ✔ B. Suspensory ligament [44%]
- C. Ovarian ligament [22%]
- D. Transverse cervical ligament [5%]
- E. Mesosalpinx [6%]

Explanation: **User Id: 477875**

The ovaries are the female gonadal organs, located in the pelvis. The ovaries are covered by the mesovarium, which extends to form the broad ligament of the uterus. The uterine tube, ovarian ligament, round ligament of the uterus, and a portion of the suspensory ligament of the ovary are also surrounded by the broad ligament. The nerves, arteries, veins, and lymphatics supplying the ovary are all delivered by the suspensory ligament of the ovary.

The ovarian blood supply is provided by the ovarian arteries, which arise from the abdominal aorta bilaterally. The right ovarian vein drains into the inferior vena cava and the left ovarian vein drains into the left renal vein. The parasympathetic innervation of the ovary is derived from the vagus nerve. The ureters course retroperitoneally in close association with the gonadal vessels. A common complication in surgeries ligating the ovarian vasculature in the suspensory ligament is accidental ligation of the ureter.

(Choice A) There are two major 'round ligaments' in the body: the round ligament of the uterus and the round ligament of the liver. The round ligament of the uterus courses through the inguinal canal and links the horns of the uterus to the external genitalia. It contains the artery of Sampson which rarely is a source of a major bleeding.

2 3 4 5 6 7 8 9 10 11 12 13 14 15 16 17 18 19 20 21 22 23 24 25 26 27 28 29 30 31 32 33 34 35 36 37 38 39 40 41

E. Mesosalpinx [6%]

Explanation: **User Id: 477875**

The ovaries are the female gonadal organs, located in the pelvis. The ovaries are covered by the mesovarium, which extends to form the broad ligament of the uterus. The uterine tube, ovarian ligament, round ligament of the uterus, and a portion of the suspensory ligament of the ovary are also surrounded by the broad ligament. The nerves, arteries, veins, and lymphatics supplying the ovary are all delivered by the suspensory ligament of the ovary.

The ovarian blood supply is provided by the ovarian arteries, which arise from the abdominal aorta bilaterally. The right ovarian vein drains into the inferior vena cava and the left ovarian vein drains into the left renal vein. The parasympathetic innervation of the ovary is derived from the vagus nerve. The ureters course retroperitoneally in close association with the gonadal vessels. A common complication in surgeries ligating the ovarian vasculature in the suspensory ligament is accidental ligation of the ureter.

(Choice A) There are two major 'round ligaments' in the body: the round ligament of the uterus and the round ligament of the liver. The round ligament of the uterus courses through the inguinal canal and links the horns of the uterus to the external genitalia. It contains the artery of Sampson which rarely is a source of a major bleeding.

(Choice C) The ovarian ligament carries no named blood vessels. It courses from the uterine pole of the ovary to the body of the uterus just below the uterine tubes.

(Choice D) The transverse cervical ligament, also known as the cardinal ligament, extends from the cervix and lateral fornix of the vagina to the lateral pelvic walls. The uterine artery courses in this tissue and requires ligation during radical hysterectomy.

(Choice E) The mesosalpinx is the region of the broad ligament of the uterus that lies between the uterine tube and the ovary.

Educational Objective:
The nerves and vessels supplying the ovary are delivered through the suspensory ligament of the ovary.

Time Spent: 1 seconds Copyright © USMLEWorld,LLC. Last updated: [11/10/2011]

2
3
4
5
6
7
8
9
10
11
12
13
14
15
16
17
18
19
20
21
22
23
24
25
26
27
28
29
30
31
32
33
34
35
36
37
38
39
40
41

A 56-year-old female with a long history of gallstones presents to the emergency room complaining of cramping mid-abdominal pain, abdominal distention and vomiting for the last 12 hours. Abdominal X-ray reveals air in the gallbladder and biliary tree. In which of the following sites is a gallstone most likely lodged?

- A. Cystic duct [13%]
- B. Common bile duct [35%]
- C. Duodenum [15%]
- D. Jejunum [4%]
- ✔ E. Ileum [32%]

Explanation: **User Id: 477875**

This patient is most likely suffering from gallstone ileus, a condition that occurs in patients with longstanding cholelithiasis (often middle-aged to elderly females). A large (typically 2.5 cm or greater) gallstone causes the formation of a cholecystenteric fistula between the gallbladder and adjoining gut tissue due to persistent pressure on these tissues. The fistula ultimately allows passage of the gallstone into the small bowel, and the resulting communication between the gallbladder and small bowel allows intestinal gas to enter the gallbladder and biliary tree. Often this gas can be observed on abdominal X-rays.

After entering the small bowel, the gallstone typically passes freely through the duodenum, jejunum and ileum until it encounters the ileocecal valve. The ileocecal valve typically handles material in a liquid state, and the large gallstones associated with gallstone ileus are generally unable to pass through this valve. Obstruction of the small bowel at the ileocecal valve leads to the classic signs and symptoms of small bowel obstruction including abdominal pain and distention, vomiting, tenderness to palpation and tinkling bowel sounds.

The diagnosis can be made with an upper GI series to demonstrate the cholecystenteric fistula and small bowel obstruction. Treatment is by surgical removal of the offending stone. Cholecystectomy and repair of the fistula are rarely necessary.

(Choices A and B) Obstruction of the cystic duct or common bile duct by a gallstone is referred to as choledocolithiasis. This can lead to biliary colic, jaundice and cholangitis. Signs and symptoms of cholangitis include fever, right upper quadrant abdominal pain, and an inspiratory pause during right upper quadrant palpation (Murphy's sign). Free air is typically not seen in the biliary tree. Right upper quadrant ultrasound will

2
3
4
5
6
7
8
9
10
11
12
13
14
15
16
17
18
19
20
21
22
23
24
25
26
27
28
29
30
31
32
33
34
35
36
37
38
39
40
41

E. ileum [32%]

Explanation: **User Id: 477875**

This patient is most likely suffering from gallstone ileus, a condition that occurs in patients with longstanding cholelithiasis (often middle-aged to elderly females). A large (typically 2.5 cm or greater) gallstone causes the formation of a cholecystenteric fistula between the gallbladder and adjoining gut tissue due to persistent pressure on these tissues. The fistula ultimately allows passage of the gallstone into the small bowel, and the resulting communication between the gallbladder and small bowel allows intestinal gas to enter the gallbladder and biliary tree. Often this gas can be observed on abdominal X-rays.

After entering the small bowel, the gallstone typically passes freely through the duodenum, jejunum and ileum until it encounters the ileocecal valve. The ileocecal valve typically handles material in a liquid state, and the large gallstones associated with gallstone ileus are generally unable to pass through this valve. Obstruction of the small bowel at the ileocecal valve leads to the classic signs and symptoms of small bowel obstruction including abdominal pain and distention, vomiting, tenderness to palpation and tinkling bowel sounds.

The diagnosis can be made with an upper GI series to demonstrate the cholecystenteric fistula and small bowel obstruction. Treatment is by surgical removal of the offending stone. Cholecystectomy and repair of the fistula are rarely necessary.

(Choices A and B) Obstruction of the cystic duct or common bile duct by a gallstone is referred to as choledocolithiasis. This can lead to biliary colic, jaundice and cholangitis. Signs and symptoms of cholangitis include fever, right upper quadrant abdominal pain, and an inspiratory pause during right upper quadrant palpation (Murphy's sign). Free air is typically not seen in the biliary tree. Right upper quadrant ultrasound will reveal stones in the biliary ducts.

(Choices C and D) The caliber of the duodenum and jejunum is typically sufficient to allow the passage of the larger gallstones that cause gallstone ileus.

Educational Objective:
Gallstone ileus results from the passage of a large gallstone (typically greater than 2.5 cm) through a cholecystenteric fistula into the small bowel where it ultimately causes obstruction at the ileocecal valve. Gas is seen within the gallbladder and biliary tree on abdominal X-ray due to the presence of the fistula, and patients present with signs and symptoms of small bowel obstruction.

Time Spent: 1 seconds Copyright © USMLEWorld,LLC. Last updated: [7/7/2010]

2 3 4 5 6 7 8 9 10 11 12 13 14 15 16 17 18 19 20 21 22 23 24 25 26 27 28 29 30 31 32 33 34 35 36 37 38 39 40 41

A 52-year-old male has had a chronic cough with occasional low-volume hemoptysis for the past three weeks. He is a two pack-per-day cigarette smoker, and drinks three to four cans of beer on weekends. Physical examination reveals right-sided face and right arm swelling and engorgement of subcutaneous veins on the right side of the neck. Which of the following veins is most likely obstructed in this patient?

- A. Internal jugular [5%]
- B. External jugular [7%]
- C. Subclavian [19%]
- ✔ D. Brachiocephalic [32%]
- E. Superior vena cava [34%]
- F. Axillary [2%]

Explanation: **User Id: 477875**

This patient has symptoms consistent with an obstructed right brachiocephalic (innominate) vein. This may be the result of external compression, as by an apical lung tumor, or thrombotic occlusion, as can occur when a central catheter has been in place for an extended period of time. The right brachiocephalic vein is formed by the union of the right subclavian vein and the right internal jugular vein. The right external jugular vein drains into the right subclavian, so obstruction of the right brachiocephalic will cause venous congestion of structures drained by the external jugular. It is important to note that the right brachiocephalic vein also drains the right lymphatic duct, which drains lymph from the right upper extremity, the right face and neck, the right hemithorax, and the right upper quadrant of the abdomen.

(Choice A) The internal jugular vein drains the brain and superficial face and neck. Obstruction of the internal jugular would not cause arm swelling.

(Choice B) The external jugular vein drains the scalp and portions of the lateral face.

(Choices C and F) The subclavian vein is the continuation of the axillary vein. Both drain blood from the upper extremity.

(Choice E) Superior vena cava syndrome results when the superior vena cava is obstructed. The signs and symptoms of SVC syndrome are similar to those described here, except that both sides of the face, neck and

2 3 4 5 6 7 8 9 10 11 12 13 14 15 16 17 18 19 20 21 22 23 24 25 26 27 28 29 30 31 32 33 34 35 36 37 38 39 40 41

B. External jugular [7%]
C. Subclavian [19%]
✔ D. Brachiocephalic [32%]
E. Superior vena cava [34%]
F. Axillary [2%]

Explanation: **User Id: 477875**

This patient has symptoms consistent with an obstructed right brachiocephalic (innominate) vein. This may be the result of external compression, as by an apical lung tumor, or thrombotic occlusion, as can occur when a central catheter has been in place for an extended period of time. The right brachiocephalic vein is formed by the union of the right subclavian vein and the right internal jugular vein. The right external jugular vein drains into the right subclavian, so obstruction of the right brachiocephalic will cause venous congestion of structures drained by the external jugular. It is important to note that the right brachiocephalic vein also drains the right lymphatic duct, which drains lymph from the right upper extremity, the right face and neck, the right hemithorax, and the right upper quadrant of the abdomen.

(Choice A) The internal jugular vein drains the brain and superficial face and neck. Obstruction of the internal jugular would not cause arm swelling.

(Choice B) The external jugular vein drains the scalp and portions of the lateral face.

(Choices C and F) The subclavian vein is the continuation of the axillary vein. Both drain blood from the upper extremity.

(Choice E) Superior vena cava syndrome results when the superior vena cava is obstructed. The signs and symptoms of SVC syndrome are similar to those described here, except that both sides of the face, neck and chest and both arms would be involved.

Educational Objective:
The brachiocephalic vein drains the ipsilateral jugular and subclavian veins. The bilateral brachiocephalic veins combine to form the SVC. Brachiocephalic vein obstruction causes symptoms similar to those seen in SVC syndrome, but on just one side of the body.

Time Spent: 1 seconds Copyright © USMLEWorld,LLC. Last updated: [7/7/2010]

www.zeallsoft.com

2 3 4 5 6 7 8 9 10 11 12 13 14 15 16 17 18 19 20 21 22 23 24 25 26 27 28 29 30 31 32 33 34 35 36 37 38 39 40 41

A 47-year-old morbidly obese woman comes to the physician seeking advice regarding weight loss. She has tried diet and exercise a number of times without success. Her other medical problems include type 2 diabetes mellitus and obstructive sleep apnea. Her body mass index is 43 kg/m². After a discussion about available surgical options, she expresses interest in the adjustable gastric band, an inflatable silicone device that is placed around the cardiac part of the stomach. In order to encircle the stomach, the band must pass through which of the following structures?

- A. Falciform ligament [5%]
- B. Gastrocolic ligament [16%]
- C. Greater omentum [21%]
- ✔ D. Lesser omentum [55%]
- E. Splenorenal ligament [3%]

Explanation:

User Id: 477875

Greater & lesser omentum

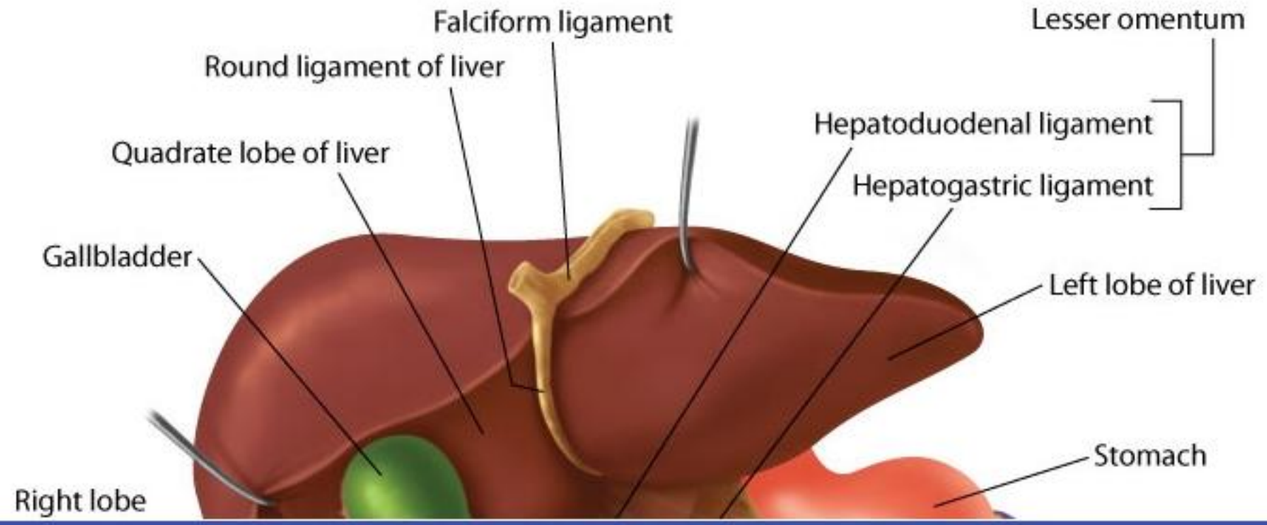

www.zeallsoft.com

2
3
4
5
6
7
8
9
10
11
12
13
14
15
16
17
18
19
20
21
22
23
24
25
26
27
28
29
30
31
32
33
34
35
36
37
38
39
40
41

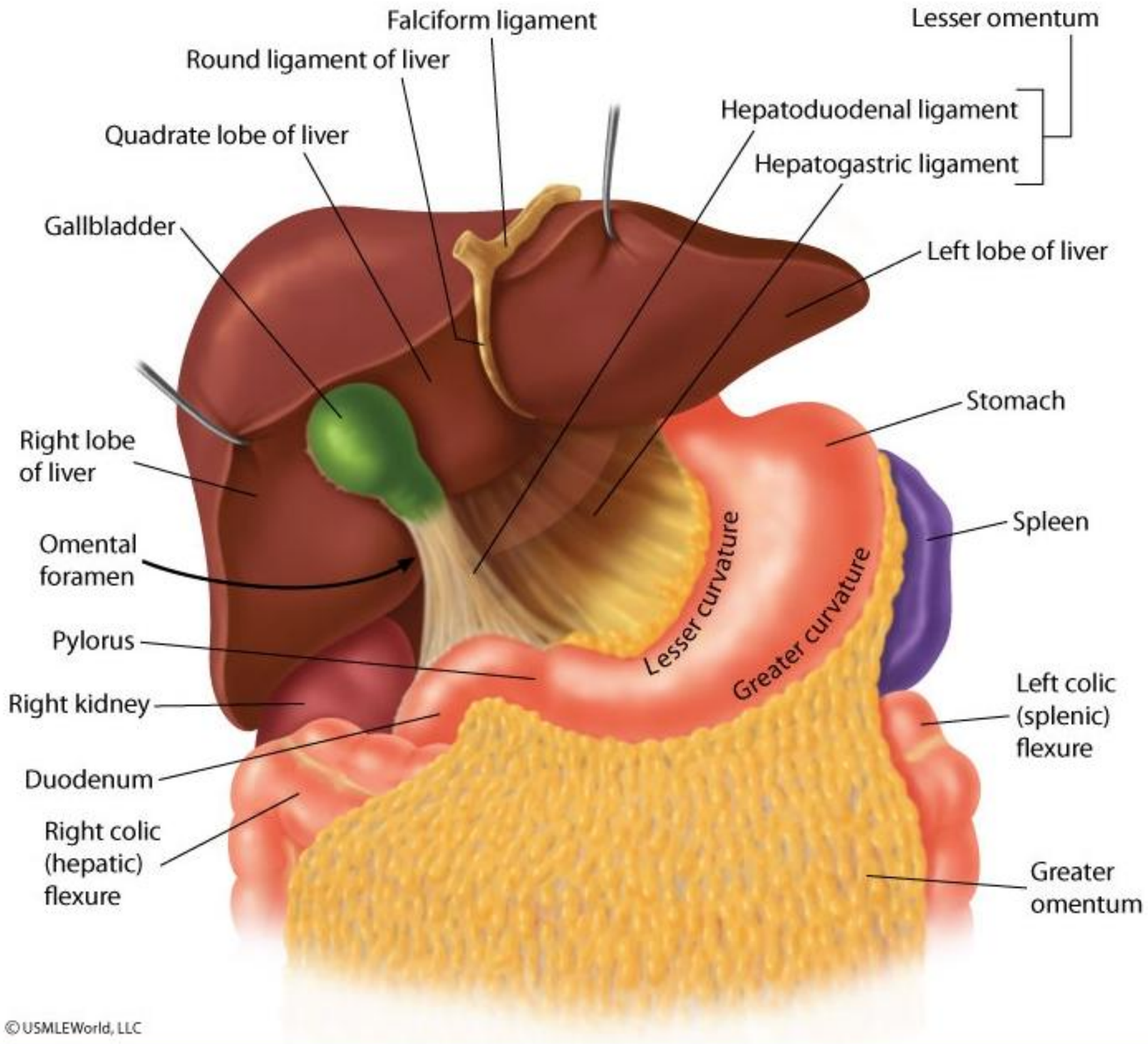

2 3 4 5 6 7 8 9 10 11 12 13 14 15 16 17 18 19 20 21 22 23 24 25 26 27 28 29 30 31 32 33 34 35 36 37 38 39 40 41

© USMLEWorld, LLC

Adjustable gastric banding is a type of restrictive bariatric surgery designed for obese patients. The adjustable gastric band is an inflatable silicone device placed around the gastric cardia. It is intended to slow the passage of food, increasing satiety and limiting the amount of food consumed. To encircle the upper stomach, the gastric band must pass through the lesser omentum.

The lesser omentum is a double layer of peritoneum that extends from the liver to the lesser curvature of the stomach and the beginning of the duodenum. Anatomically, the lesser omentum is divided into 2 ligaments:

1. Hepatogastric ligament: the portion connecting to the lesser curvature of the stomach
2. Hepatoduodenal ligament: the portion connecting to the duodenum

Between the 2 layers of the lesser omentum, close to the right-sided free margin, lie the hepatic artery, common bile duct, portal vein, lymphatics, and hepatic plexus. The right and left gastric arteries and gastric veins also lie between the 2 layers, near where the lesser omentum attaches to the stomach.

(Choice A) The falciform ligament attaches the liver to the anterior body wall. It is a derivative of the embryonic ventral mesentery and contains the round ligament, the remnant of the fetal umbilical vein.

(Choices B and C) The greater omentum is a large fold of visceral peritoneum that extends from the greater curvature of the stomach, travels inferiorly over the small intestine, and then reflects on itself and ascends to encompass the transverse colon before reaching the posterior abdominal wall. The gastrocolic ligament is the section that stretches from the greater curvature of the stomach to the transverse colon. It forms part of the anterior wall of the lesser sac and is often divided during surgery to provide access to the anterior pancreas and posterior wall of the stomach.

(Choice E) The splenorenal ligament is derived from the peritoneum and lies between the left kidney and the spleen. It contains the splenic vessels and the tail of the pancreas.

Educational objective:
The lesser omentum is a double layer of peritoneum that extends from the liver to the lesser curvature of the stomach and the beginning of the duodenum. It is divided into the hepatogastric and hepatoduodenal ligaments.

Time Spent: 1 seconds

Copyright © USMLEWorld,LLC.

Last updated: [1/17/2013]

2, 3, 4, 5, 6, 7, 8, 9, 10, 11, 12, 13, 14, 15, 16, 17, 18, 19, 20, 21, 22, 23, 24, 25, 26, 27, 28, 29, 30, 31, 32, 33, 34, 35, 36, 37, 38, 39, 40, 41

A 65-year-old woman comes to the emergency department for nausea, vomiting, and abdominal pain that began about 6 hours ago. She also complains of vague pelvic pain over the last few months, but says her pain has never been this severe. Her temperature is 38.4° C (101° F), blood pressure is 141/90 mm Hg, pulse is 92/min, and respirations are 18/min. Physical examination shows a moderately distended abdomen. There is a tender bulge below the inguinal ligament, just lateral to the pubic tubercle. The overlying skin is erythematous. Which of the following structures is most likely immediately lateral to the bulge?

- A. Inferior epigastric vessels [22%]
- B. Cooper's ligament [3%]
- ✔ C. Femoral vein [63%]
- D. Transversalis fascia [3%]
- E. Rectus muscle sheath [2%]
- F. Round ligament [6%]

Explanation:

User Id: 477875

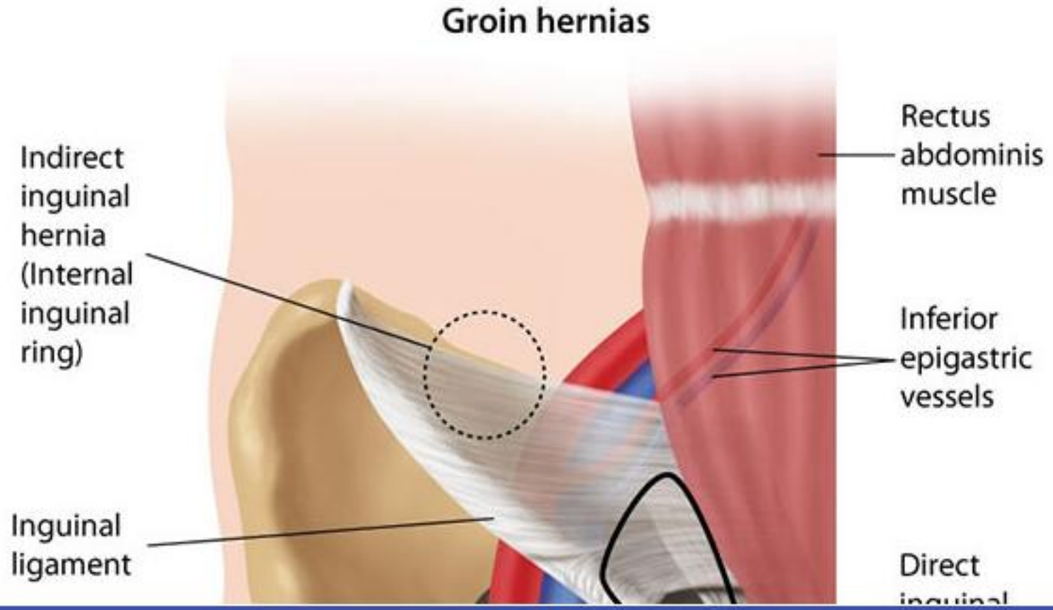

www.zeallsoft.com

2
3
4
5
6
7
8
9
10
11
12
13
14
15
16
17
18
19
20
21
22
23
24
25
26
27
28
29
30
31
32
33
34
35
36
37
38
39
40
41

Groin hernias

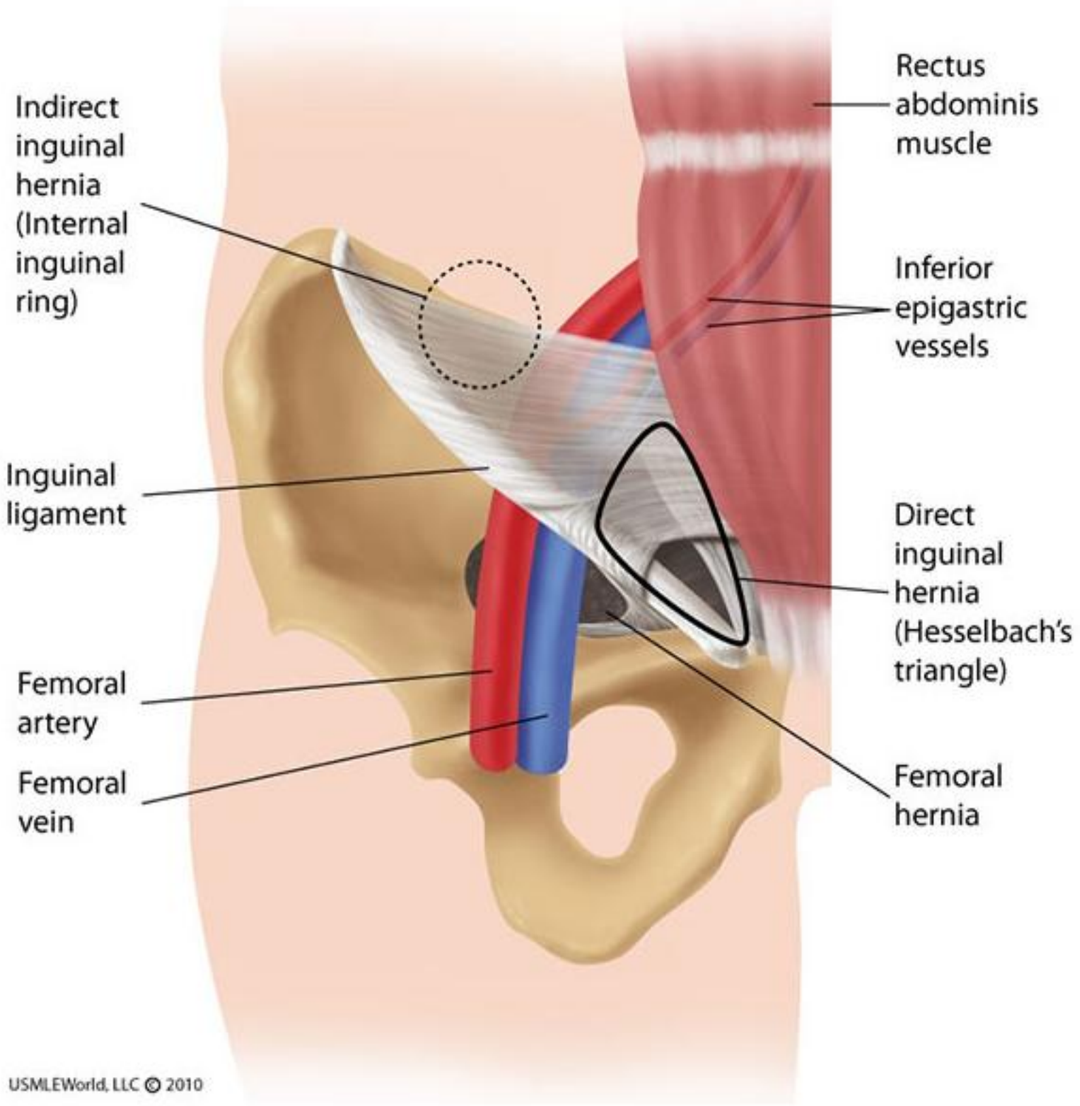

There are 3 types of **groin hernias**: direct inguinal, indirect inguinal, and femoral. Direct and indirect inguinal hernias occur above the inguinal ligament; femoral hernias are located below it.

2
3
4
5
6
7
8
9
10
11
12
13
14
15
16
17
18
19
20
21
22
23
24
25
26
27
28
29
30
31
32
33
34
35
36
37
38
39
40
41

There are 3 types of **groin hernias**: direct inguinal, indirect inguinal, and femoral. Direct and indirect inguinal hernias occur above the inguinal ligament; femoral hernias are located below it.

Femoral hernias protrude through the femoral ring, which can widen and become lax with age. They are lateral to the pubic tubercle and lacunar ligament and medial to the femoral artery and vein. Femoral hernias are more common in women and tend to occur on the right side. Femoral hernias may present with upper thigh, groin, or pelvic discomfort.

Because the femoral canal is small, femoral hernias are prone to **incarceration**. Incarcerated hernias cannot be reduced; if a segment of bowel is present in the hernia sac, incarceration can cause bowel obstruction (nausea/vomiting/abdominal pain and distention). Impaired blood flow to contents trapped in the hernia sac occurs a few hours after incarceration, causing **strangulation**. Ischemia and necrosis of the contents of the hernia sac occur, which may lead to systemic symptoms such as fever.

(Choice A) Direct inguinal hernias lie medial to the inferior epigastric vessels, and indirect inguinal hernias are lateral to the vessels.

(Choice B) The pectineal (Cooper's) ligament is a thickened part of the pectineal fascia. It overlies the pectineal ridge of the pubic bone and is located posteriorly to the femoral canal.

(Choice D) The transversalis fascia is found between the transversalis muscle and the extraperitoneal fat. It forms the posterior wall of the inguinal canal. The deep inguinal ring is an opening in the transversalis fascia and is the site of protrusion of indirect inguinal hernias.

(Choice E) The rectus muscle sheath forms the medial border of Hesselbach's triangle. Direct inguinal hernias are located just lateral to the rectus abdominis muscle sheath.

(Choice F) The round ligament in women is homologous to the spermatic cord in men. It leaves the pelvis through the deep inguinal ring and passes through the inguinal canal.

Educational objective:
Femoral hernias are inferior to the inguinal ligament, lateral to pubic tubercle, and medial to the femoral vein. They can present with groin discomfort or manifest with a bulge on the upper thigh. Incarceration and strangulation are common complications of femoral hernias.

Time Spent: 2 seconds

Copyright © USMLEWorld,LLC.

Last updated: [2/5/2013]

www.zeallsoft.com

2 3 4 5 6 7 8 9 10 11 12 13 14 15 16 17 18 19 20 21 22 23 24 25 26 27 28 29 30 31 32 33 34 35 36 37 38 39 40 41

A 47-year-old male comes to your office complaining of dysphagia. He says that it feels like food is "sticking in his throat", and that the "sticking" feeling has persisted over the last month. He has changed his diet to accommodate his symptoms and now only consumes liquid foods. The patient has a long history of postprandial heartburn that sometimes awakens him from sleep. He has treated his heartburn with over the counter antacids in the past, but says he experiences only partial relief. Which of the following structures in the computed tomography (CT) image below is responsible for this patient's symptoms?

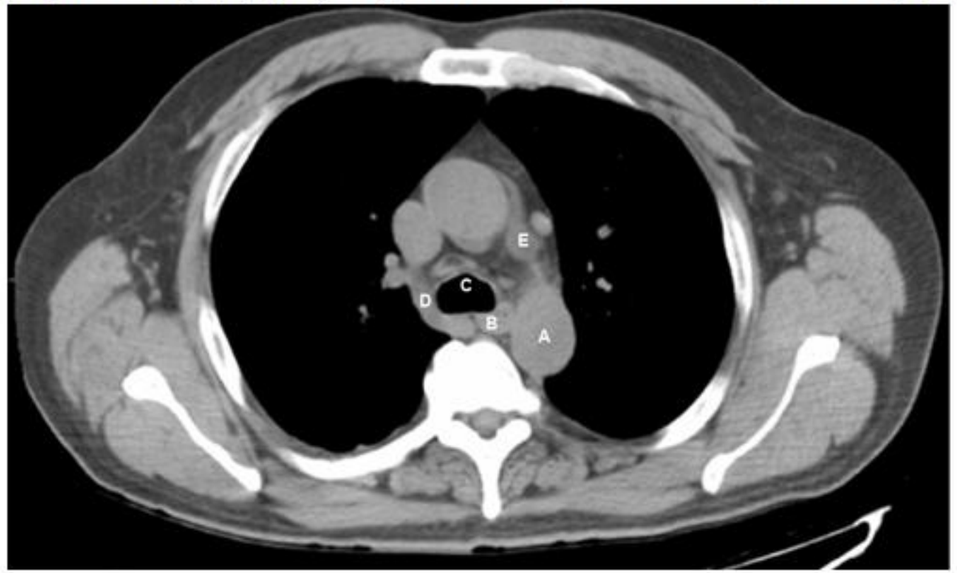

- A. A [6%]
- ✔ B. B [57%]
- C. C [25%]
- D. D [7%]
- E. E [5%]

Explanation:

User Id: 477875

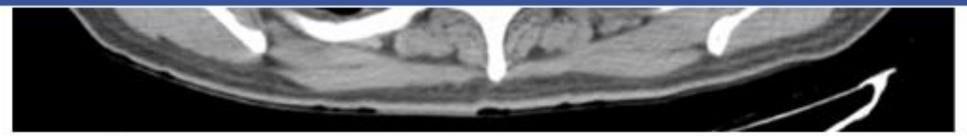

- A. A [6%]
- ✔ B. B [57%]
- C. C [25%]
- D. D [7%]
- E. E [5%]

Explanation: **User Id: 477875**

AA- Ascending aorta DA- Descending aorta SVC- Superior vena cava

This patient suffers from gastroesophageal reflux disease (GERD), a condition that affects the esophagus. Dysphagia is common in patients with longstanding GERD, and can be caused by impaired peristalsis or esophageal inflammation, stricture, or malignancy. In the thorax, the esophagus courses between the trachea and the vertebral bodies and is typically collapsed with no visible lumen. The trachea **(Choice C)** serves as a good landmark here because the radiolucency of the air in this structure allows one to differentiate it from the esophagus posteriorly and the great vessels anteriorly.

(Choice A) This is the descending aorta.

(Choice D) This is the arch of the azygos vein.

(Choice E) This is a section of the left pulmonary artery.

Educational Objective:
The esophagus is located between the trachea and the vertebral bodies in the superior thorax. It is typically collapsed with no visible lumen on CT images of the chest.

Time Spent: 13 seconds Copyright © USMLEWorld,LLC. Last updated: [2/19/2013]

2 3 4 5 6 7 8 9 10 11 12 13 14 15 16 17 18 19 20 21 22 23 24 25 26 27 28 29 30 31 32 33 34 35 36 37 38 39 40 41

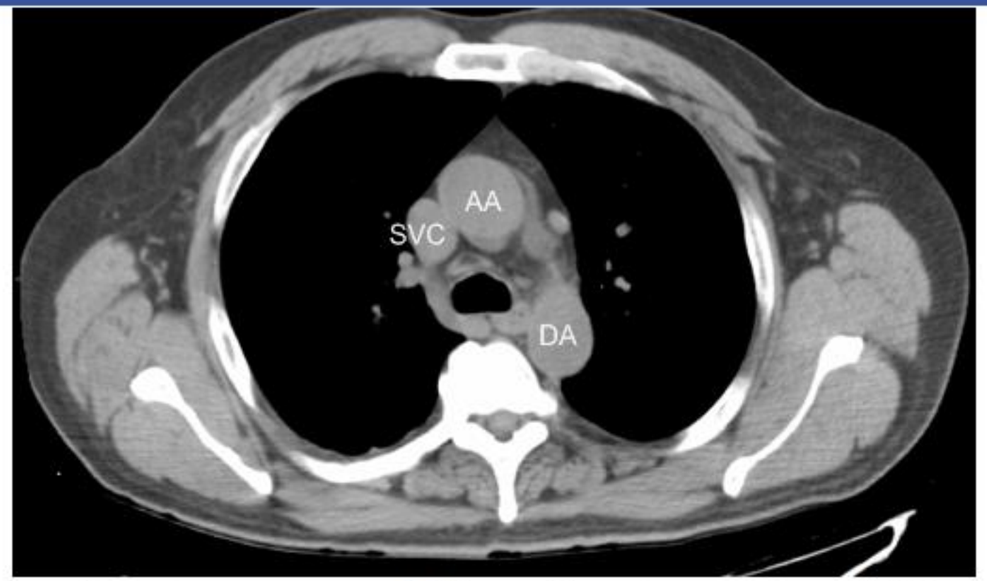

AA- Ascending aorta DA- Descending aorta SVC- Superior vena cava

This patient suffers from gastroesophageal reflux disease (GERD), a condition that affects the esophagus. Dysphagia is common in patients with longstanding GERD, and can be caused by impaired peristalsis or esophageal inflammation, stricture, or malignancy. In the thorax, the esophagus courses between the trachea and the vertebral bodies and is typically collapsed with no visible lumen. The trachea **(Choice C)** serves as a good landmark here because the radiolucency of the air in this structure allows one to differentiate it from the esophagus posteriorly and the great vessels anteriorly.

(Choice A) This is the descending aorta.

(Choice D) This is the arch of the azygos vein.

(Choice E) This is a section of the left pulmonary artery.

Educational Objective:
The esophagus is located between the trachea and the vertebral bodies in the superior thorax. It is typically collapsed with no visible lumen on CT images of the chest.

Time Spent: 13 seconds Copyright © USMLEWorld,LLC. Last updated: [2/19/2013]

www.zeallsoft.com

2 3 4 5 6 7 8 9 10 11 12 13 14 15 16 17 18 19 20 21 22 23 24 25 26 27 28 29 30 31 32 33 34 35 36 37 38 39 40 41

A 45-year-old male is brought to the ER after a motor vehicle accident. He is diagnosed with a left hemothorax and a pelvic fracture. The patient is unable to void and complains of a sensation of full bladder. Foley catheter placement is attempted, but the patient complains of pain with the procedure and only blood without urine passes out of the catheter. The patient is likely to have an injury of which of the following labeled structures:

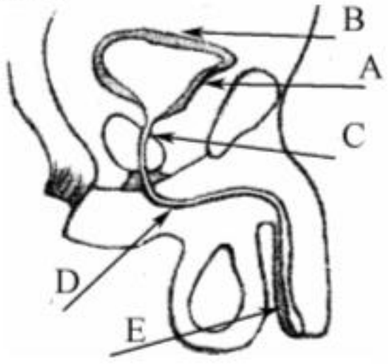

- A. A [11%]
- B. B [6%]
- ✔ C. C [41%]
- D. D [37%]
- E. E [4%]

Explanation:

User Id: 477875

2
3
4
5
6
7
8
9
10
11
12
13
14
15
16
17
18
19
20
21
22
23
24
25
26
27
28
29
30
31
32
33
34
35
36
37
38
39
40
41

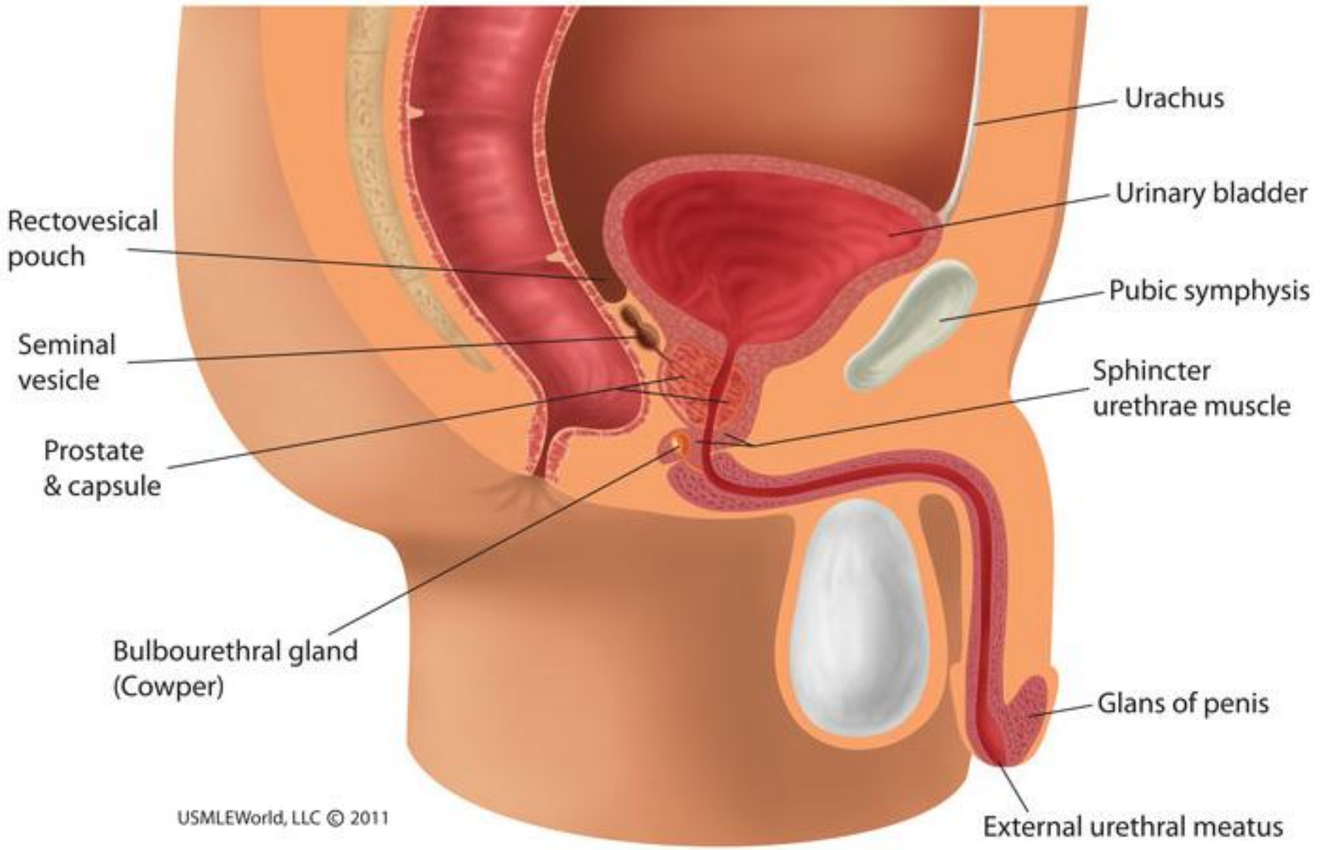

Inability to void despite sensation of a full bladder in this scenario suggests urethral trauma. If urethral injury is suspected, placement of a Foley catheter is contraindicated and should not have been attempted in this patient as it can worsen the urethral injury. Given that no urine was obtained with Foley placement, it is likely that it is passed into the periurethral tissues and not the bladder. In trauma situations, it is important to evaluate for the presence of blood at the urethral meatus or a high riding, boggy prostate as these are both suggestive of urethral injury. If there is any concern for urethral injury, a retrograde urethrogram should be performed before placement of the Foley catheter.

Urethral injuries most commonly occur in males because of their longer urethral length. Urethral injuries are

2
3
4
5
6
7
8
9
10
11
12
13
14
15
16
17
18
19
20
21
22
23
24
25
26
27
28
29
30
31
32
33
34
35
36
37
38
39
40
41

Inability to void despite sensation of a full bladder in this scenario suggests urethral trauma. If urethral injury is suspected, placement of a Foley catheter is contraindicated and should not have been attempted in this patient as it can worsen the urethral injury. Given that no urine was obtained with Foley placement, it is likely that it is passed into the periurethral tissues and not the bladder. In trauma situations, it is important to evaluate for the presence of blood at the urethral meatus or a high riding, boggy prostate as these are both suggestive of urethral injury. If there is any concern for urethral injury, a retrograde urethrogram should be performed before placement of the Foley catheter.

Urethral injuries most commonly occur in males because of their longer urethral length. Urethral injuries are divided into those affecting the anterior and posterior urethra. The posterior urethra is located above the urogenital diaphragm while the anterior urethra lies below it. The posterior urethra is further divided into the prostatic and membranous segments while the anterior urethra is divided into bulbous and penile segments. Pelvic fractures commonly cause a hematoma below the prostate with upward displacement of the gland. Rupture of the posterior urethra occurs because it is firmly connected to both the prostate and the pubic arch.

(Choice A) Bladder wall ruptures can also occur with pelvic fractures. Injury of the anterior bladder wall is more common and is usually associated with extraperitoneal leakage of urine. This patient's sensation of a full bladder makes bladder rupture less likely since urine should be leaking out as opposed to accumulating within the bladder.

(Choice B) Superior bladder wall ruptures can occur in abdominal trauma when the bladder is full. In these injuries, leakage of urine occurs into the intraperitoneal cavity. Cystography, either with fluoroscopy or CT, is used to diagnose these injuries. Differentiation from an extraperitoneal bladder rupture is important because intraperitoneal bladder ruptures are treated surgically while extraperitoneal ruptures are managed conservatively.

(Choice D) This urethral segment is known as the bulbous urethra. This form of urinary tract injury most frequently occurs due to a saddle injury where the perineum is struck forcefully. Common mechanisms include falling on the crossbar of the bicycle or on the top of the fence.

(Choice E) This segment is known as the penile urethra, and injury to this portion is most common in penetrating trauma or instrumentation.

Educational objective:
Injury to the posterior urethra is associated with pelvic fracture whereas anterior urethral injury most commonly occurs in straddle injuries. Inability to void with a sensation of a full bladder, a high riding boggy

2
3
4
5
6
7
8
9
10
11
12
13
14
15
16
17
18
19
20
21
22
23
24
25
26
27
28
29
30
31
32
33
34
35
36
37
38
39
40
41

prostatic and membranous segments while the anterior urethra is divided into bulbous and penile segments. Pelvic fractures commonly cause a hematoma below the prostate with upward displacement of the gland. Rupture of the posterior urethra occurs because it is firmly connected to both the prostate and the pubic arch.

(Choice A) Bladder wall ruptures can also occur with pelvic fractures. Injury of the anterior bladder wall is more common and is usually associated with extraperitoneal leakage of urine. This patient's sensation of a full bladder makes bladder rupture less likely since urine should be leaking out as opposed to accumulating within the bladder.

(Choice B) Superior bladder wall ruptures can occur in abdominal trauma when the bladder is full. In these injuries, leakage of urine occurs into the intraperitoneal cavity. Cystography, either with fluoroscopy or CT, is used to diagnose these injuries. Differentiation from an extraperitoneal bladder rupture is important because intraperitoneal bladder ruptures are treated surgically while extraperitoneal ruptures are managed conservatively.

(Choice D) This urethral segment is known as the bulbous urethra. This form of urinary tract injury most frequently occurs due to a saddle injury where the perineum is struck forcefully. Common mechanisms include falling on the crossbar of the bicycle or on the top of the fence.

(Choice E) This segment is known as the penile urethra, and injury to this portion is most common in penetrating trauma or instrumentation.

Educational objective:
Injury to the posterior urethra is associated with pelvic fracture whereas anterior urethral injury most commonly occurs in straddle injuries. Inability to void with a sensation of a full bladder, a high riding boggy prostate, and blood at the urethral meatus are all suggestive of urethral injury particularly in the presence of a pelvic fracture. A retrograde urethrogram should be performed before Foley catheter placement if there is concern for a urethral injury.

References:

1. **Diagnosis and classification of urethral injuries.**
2. **Blunt urethral injury: results of initial management.**

Time Spent: 3 seconds

Copyright © USMLEWorld,LLC.

Last updated: [1/10/2013]

2 3 4 5 6 7 8 9 10 11 12 13 14 15 16 17 18 19 20 21 22 23 24 25 26 27 28 29 30 31 32 33 34 35 36 37 38 39 40 41

A 56-year-old male is undergoing evaluation for fatigue, vague abdominal discomfort, and bloody stools. Colonoscopy reveals a mass in the descending colon. Surgical removal of the mass requires proper ligation of the:

- A. Celiac trunk [1%]
- B. Superior mesenteric artery [4%]
- ✔ C. Inferior mesenteric artery [91%]
- D. Internal iliac artery [3%]
- E. External iliac artery [1%]

Explanation: **User Id: 477875**

This patient has a tumor in the descending colon. The distal 1/3 of the transverse colon, descending colon, sigmoid colon, and rectum are all hindgut derivatives. Hindgut structures receive arterial blood from the inferior mesenteric artery (IMA), a branch of the aorta. These structures are drained by the inferior mesenteric vein (IMV), which does *not* course with the IMA. The IMV drains blood from the hindgut into the splenic vein, which drains into the portal vein.

(Choice A) The celiac trunk supplies blood to most foregut structures with the exception of the mouth, pharynx and proximal esophagus. The foregut encompasses all structures from the mouth to the second part of the duodenum. Foregut derivatives include the liver, pancreas, and gallbladder.

(Choice B) The superior mesenteric artery supplies blood to the midgut, which spans from the third part of the duodenum to the proximal 2/3 of the transverse colon.

(Choice D) The internal iliac artery supplies portions of the gut through branches like the middle rectal artery and the inferior rectal artery (a branch of the pudendal artery, which arises from the internal iliac artery).

(Choice E) Branches of the external iliac artery supply the lower extremity and anterior abdominal wall.

Educational Objective:
The hindgut encompasses the distal 1/3 of the transverse colon, the descending colon, the sigmoid colon, and the rectum. These structures receive their main arterial blood supply from the inferior mesenteric artery.

2 3 4 5 6 7 8 9 10 11 12 13 14 15 16 17 18 19 20 21 22 23 24 25 26 27 28 29 30 31 32 33 34 35 36 37 38 39 40 41

A 56-year-old male is undergoing evaluation for fatigue, vague abdominal discomfort, and bloody stools. Colonoscopy reveals a mass in the descending colon. Surgical removal of the mass requires proper ligation of the:

- A. Celiac trunk [1%]
- B. Superior mesenteric artery [4%]
- ✔ C. Inferior mesenteric artery [91%]
- D. Internal iliac artery [3%]
- E. External iliac artery [1%]

Explanation: **User Id: 477875**

This patient has a tumor in the descending colon. The distal 1/3 of the transverse colon, descending colon, sigmoid colon, and rectum are all hindgut derivatives. Hindgut structures receive arterial blood from the inferior mesenteric artery (IMA), a branch of the aorta. These structures are drained by the inferior mesenteric vein (IMV), which does *not* course with the IMA. The IMV drains blood from the hindgut into the splenic vein, which drains into the portal vein.

(Choice A) The celiac trunk supplies blood to most foregut structures with the exception of the mouth, pharynx and proximal esophagus. The foregut encompasses all structures from the mouth to the second part of the duodenum. Foregut derivatives include the liver, pancreas, and gallbladder.

(Choice B) The superior mesenteric artery supplies blood to the midgut, which spans from the third part of the duodenum to the proximal 2/3 of the transverse colon.

(Choice D) The internal iliac artery supplies portions of the gut through branches like the middle rectal artery and the inferior rectal artery (a branch of the pudendal artery, which arises from the internal iliac artery).

(Choice E) Branches of the external iliac artery supply the lower extremity and anterior abdominal wall.

Educational Objective:
The hindgut encompasses the distal 1/3 of the transverse colon, the descending colon, the sigmoid colon, and the rectum. These structures receive their main arterial blood supply from the inferior mesenteric artery.

Time Spent: 1 seconds Copyright © USMLEWorld,LLC. Last updated: [11/10/2011]

2, 3, 4, 5, 6, 7, 8, 9, 10, 11, 12, 13, 14, 15, 16, 17, 18, 19, 20, 21, 22, 23, 24, 25, 26, 27, 28, 29, 30, 31, 32, 33, 34, 35, 36, 37, 38, 39, 40, 41

A 62-year-old man comes to the physician because of intermittent groin pain. He is a construction worker and says that the pain is worse when lifting heavy loads and after a long day of working. Physical examination shows a bulge above the inguinal ligament. The bulge increases in size when he bears down. A groin ultrasound reveals that the mass originates medial to the inferior epigastric vessels. This patient's condition is most likely caused by which of the following?

- ✔ A. Breakdown of the transversalis fascia [44%]
- B. Failure of the internal inguinal ring to close [8%]
- C. Patent processus vaginalis [8%]
- D. Weakness of the rectus abdominis muscle [35%]
- E. Widening of the femoral ring [5%]

Explanation:

User Id: 477875

Groin hernias

Type	Most common presentation	Anatomy
Indirect inguinal	Male infants	Enters internal inguinal ring lateral to inferior epigastric vessels. Caused by persistent processus vaginalis & failure of internal inguinal ring to close.
Direct inguinal	Older men	Bulges through Hesselbach's triangle, medial to inferior epigastric vessels, to reach external inguinal ring. Caused by weakness of the

2 3 4 5 6 7 8 9 10 11 12 13 14 15 16 17 18 19 20 21 22 23 24 25 26 27 28 29 30 31 32 33 34 35 36 37 38 39 40 41

Explanation:

User Id: 477875

Groin hernias		
Type	**Most common presentation**	**Anatomy**
Indirect inguinal	Male infants	Enters internal inguinal ring lateral to inferior epigastric vessels. Caused by persistent processus vaginalis & failure of internal inguinal ring to close.
Direct inguinal	Older men	Bulges through Hesselbach's triangle, medial to inferior epigastric vessels, to reach external inguinal ring. Caused by weakness of the transversalis fascia.
Femoral	Women	Protrudes through the femoral ring, medial to the femoral vessels & inferior to the inguinal ligament.

© USMLEWorld, LLC

Direct and indirect inguinal hernias are both located above the inguinal ligament. Direct inguinal hernias protrude through **Hesselbach's triangle**, which is formed by the inguinal ligament inferiorly, the inferior epigastric vessels laterally, and the rectus abdominus muscle medially. The transversalis fascia forms the floor of the triangle, and defects or weakness involving the transversalis fascia can lead to protrusion of abdominal contents through Hesselbach's triangle into the inguinal canal. Failure of this fascial layer is most often due to acquired connective tissue abnormalities or chronic abdominal wall injury. Thus, direct inguinal hernias are more common in the elderly.

2
3
4
5
6
7
8
9
10
11
12
13
14
15
16
17
18
19
20
21
22
23
24
25
26
27
28
29
30
31
32
33
34
35
36
37
38
39
40
41

Femoral	Women	Protrudes through the femoral ring, medial to the femoral vessels & inferior to the inguinal ligament.

© USMLEWorld, LLC

Direct and indirect inguinal hernias are both located above the inguinal ligament. Direct inguinal hernias protrude through **Hesselbach's triangle**, which is formed by the inguinal ligament inferiorly, the inferior epigastric vessels laterally, and the rectus abdominus muscle medially. The transversalis fascia forms the floor of the triangle, and defects or weakness involving the transversalis fascia can lead to protrusion of abdominal contents through Hesselbach's triangle into the inguinal canal. Failure of this fascial layer is most often due to acquired connective tissue abnormalities or chronic abdominal wall injury. Thus, direct inguinal hernias are more common in the elderly.

Direct inguinal hernias do not pass through the deep inguinal ring but pass only through the superficial inguinal ring. As a result, they are covered only by the external spermatic fascia, in contrast to indirect inguinal hernias, which are covered by all 3 spermatic fascial layers.

(Choices B and C) Indirect inguinal hernias are the most common type of groin hernia in both sexes. They frequently occur in infants, children, and young adults due to failure of the processus vaginalis to obliterate and the internal inguinal ring to close. Indirect inguinal hernias protrude through the internal inguinal ring, lateral to the inferior epigastric vessels.

(Choice D) The rectus abdominis muscle forms the medial border of Hesselbach's triangle. Direct inguinal hernias are located lateral to the rectus abdominis muscle.

(Choice E) Femoral hernias occur below the inguinal ligament and protrude through the femoral ring, which is medial to the femoral sheath and lateral to the lacunar ligament. The femoral sheath contains the femoral artery and femoral vein.

Educational objective:
Direct hernias occur most commonly in older men and are caused by weakness of the transversalis fascia in Hesselbach's triangle. They are medial to the inferior epigastric vessels, protrude only through the external inguinal ring, and are covered by the external spermatic fascia.

Time Spent: 2 seconds

Copyright © USMLEWorld,LLC.

Last updated: [2/19/2013]

2, 3, 4, 5, 6, 7, 8, 9, 10, 11, 12, 13, 14, 15, 16, 17, 18, 19, 20, 21, 22, 23, 24, 25, 26, 27, 28, 29, 30, 31, 32, 33, 34, 35, 36, 37, 38, 39, 40, 41

A 52-year-old man is brought to the emergency department for hematemesis that began 1 hour earlier. He has regularly consumed large amounts of alcohol for the last 20 years and has been hospitalized numerous times due to ethanol intoxication. Physical examination shows jaundice and scleral icterus. Examination of his abdomen reveals a palpable spleen and moderate ascites. Endoscopy shows bleeding esophageal varices. This patient's bleeding most likely resulted from chronic shunting of portal blood to the systemic circulation through which of the following veins?

- ✔ A. Left gastric [67%]
- B. Middle colic [1%]
- C. Paraumbilical [6%]
- D. Right gastroepiploic [9%]
- E. Splenic [8%]
- F. Superficial epigastric [10%]

Explanation:

User Id: 477875

Portacaval anastomoses		
Clinical manifestation	**Portal circulation**	**Systemic circulation**
Esophageal varices	Left gastric vein	Esophageal vein
Hemorrhoids	Superior rectal vein	Middle & inferior rectal veins
Caput medusae	Paraumbilical veins	Superficial & inferior epigastric veins

© USMLEWorld, LLC

2
3
4
5
6
7
8
9
10
11
12
13
14
15
16
17
18
19
20
21
22
23
24
25
26
27
28
29
30
31
32
33
34
35
36
37
38
39
40
41

Caput medusae	Paraumbilical veins	Superficial & inferior epigastric veins

© USMLEWorld, LLC

This patient has numerous cirrhotic stigmata including ascites, jaundice, and splenomegaly. An important cause of cirrhosis-related morbidity and mortality is the development of variceal hemorrhaging as a direct consequence of portal hypertension.

Cirrhosis (of any type) represents the endstage of progressive hepatic fibrosis. It is characterized by distortion of the hepatic architecture and formation of regenerative nodules. Cirrhosis is the most common cause of portal hypertension, which arises from increased resistance to portal flow at the hepatic sinusoids. Chronic portal hypertension leads to dilation of small, pre-existing vascular channels between the portal and systemic circulations. These dilated collateral vessels (portosystemic anastomoses) commonly form in the anterior abdomen (**caput medusae**), lower rectum (hemorrhoids), and inferior end of the esophagus (esophageal varices).

Treatment sometimes includes inserting a transjugular intrahepatic portosystemic shunt (TIPS) between the portal vein and hepatic vein percutaneously, relieving portal hypertension by shunting blood to the systemic circulation.

(Choice B) The middle colic vein drains the transverse colon.

(Choice D) The right gastroepiploic vein drains venous blood from the lower parts of the antero-superior and postero-inferior surfaces of the stomach. It runs from left to right along the greater curvature of the stomach.

(Choice E) The splenic vein drains blood from the spleen. It joins with the superior mesenteric vein to form the hepatic portal vein. Patients with portal hypertension can develop splenomegaly due to congestion of the splenic red pulp.

Educational objective:
In cirrhosis, portal hypertension arises from increased resistance to portal flow at the hepatic sinusoids. This causes increased pressure in the portosystemic collateral veins within the lower end of esophagus, anterior abdomen, and lower rectum. Dilation of these collaterals is responsible for the esophageal varices, caput medusae, and hemorrhoids commonly seen in cirrhotic patients.

Time Spent: 1 seconds

Copyright © USMLEWorld,LLC.

Last updated: [12/3/2012]

2 3 4 5 6 7 8 9 10 11 12 13 14 15 16 17 18 19 20 21 22 23 24 25 26 27 28 29 30 31 32 33 34 35 36 37 38 39 40 41

A 23-year-old Caucasian female is brought to the ER unconscious after a motor vehicle accident. A linear skull fracture in the area of junction of frontal, parietal, temporal, and sphenoid bones is seen on X-ray. A branch of which of the following arteries is most likely severed in this patient?

- A. Occipital [3%]
- ✔ B. Maxillary [38%]
- C. Ophthalmic [9%]
- D. Middle cerebral [35%]
- E. Sphenopalatine [6%]
- F. Facial [7%]

Explanation: **User Id: 477875**

The patient described in the question stem has suffered a fracture where the frontal, parietal, temporal, and sphenoid bones meet in the skull. This site is known as the pterion and is medically relevant due to the fact that the bone is thin in this region and the middle meningeal artery courses within the skull deep to this point. As such, fractures to this region of the skull are at risk of damaging the middle meningeal artery and causing an epidural hematoma. Epidural hematomas require prompt treatment because they are under systemic arterial pressure and can expand rapidly leading to transtentorial herniation and palsy of the oculomotor nerve.

The middle meningeal artery is a branch of the maxillary artery, which itself is a branch of the external carotid artery.

(Choice A) The occipital artery arises opposite the facial artery from the external carotid, coursing posteriorly instead of anteriorly. This vessel serves the posterior scalp and the sternocleidomastoids.

(Choice C) The ophthalmic artery is the first branch of the internal carotid artery, serving the eye and orbital contents as well as the eyelids, forehead, nose, and nasal mucosa. The internal carotid artery has no branches in the neck.

(Choice D) The middle cerebral artery is a branch of the internal carotid artery and supplies much of the parietal and temporal regions of the brain. Injury to this artery or its branches can cause a subarachnoid or

2 3 4 5 6 7 8 9 10 11 12 13 14 15 16 17 18 19 20 21 22 23 24 25 26 27 28 29 30 31 32 33 34 35 36 37 38 39 40 41

Explanation: User Id: 477875

The patient described in the question stem has suffered a fracture where the frontal, parietal, temporal, and sphenoid bones meet in the skull. This site is known as the pterion and is medically relevant due to the fact that the bone is thin in this region and the middle meningeal artery courses within the skull deep to this point. As such, fractures to this region of the skull are at risk of damaging the middle meningeal artery and causing an epidural hematoma. Epidural hematomas require prompt treatment because they are under systemic arterial pressure and can expand rapidly leading to transtentorial herniation and palsy of the oculomotor nerve.

The middle meningeal artery is a branch of the maxillary artery, which itself is a branch of the external carotid artery.

(Choice A) The occipital artery arises opposite the facial artery from the external carotid, coursing posteriorly instead of anteriorly. This vessel serves the posterior scalp and the sternocleidomastoids.

(Choice C) The ophthalmic artery is the first branch of the internal carotid artery, serving the eye and orbital contents as well as the eyelids, forehead, nose, and nasal mucosa. The internal carotid artery has no branches in the neck.

(Choice D) The middle cerebral artery is a branch of the internal carotid artery and supplies much of the parietal and temporal regions of the brain. Injury to this artery or its branches can cause a subarachnoid or intracerebral hemorrhage.

(Choice E) The sphenopalatine artery is a branch of the third part of the maxillary artery that supplies much of the nasal mucosa. It anastomoses with branches of the ophthalmic and facial arteries within the anterior part of the nasal septum in a region known as Kiesselbach's plexus – a frequent site of nosebleeds.

(Choice F) The facial artery is a branch of the external carotid artery that courses over the mandible anterior to the insertion of the masseter muscle to supply the oral region and nose as well as the buccal region of the cheeks.

Educational Objective:
The middle meningeal artery is a branch of the maxillary artery that enters the skull at the foramen spinosum and courses intracranially deep to the pterion. Skull fractures at this site may cause laceration of this vessel, leading to an epidural hematoma.

Time Spent: 1 seconds Copyright © USMLEWorld,LLC. Last updated: [1/10/2013]

2 3 4 5 6 7 8 9 10 11 12 13 14 15 16 17 18 19 20 21 22 23 24 25 26 27 28 29 30 31 32 33 34 35 36 37 38 39 40 41

A patient drinking hot tea at a restaurant experiences a burning sensation at the tip of his tongue. This sensation is transmitted by which of the following?

- ✔ A. Trigeminal nerve [67%]
- B. Chorda tympani [17%]
- C. Glossopharyngeal nerve [9%]
- D. Hypoglossal nerve [5%]
- E. Vagus nerve [2%]

Explanation: **User Id: 477875**

The innervation of the tongue is complex because it involves motor, general somatic sensory and special sensory functions. Somatic sensation includes pain, touch, temperature and pressure, the same sensations felt by the skin. The lingual nerve, a branch of the mandibular division of the trigeminal nerve (CN V_3), provides somatic sensory innervation to the anterior 2/3 of the tongue. CN V_3 also provides somatic sensory innervation to the skin of the face. The glossopharyngeal (CN IX) nerve provides somatic sensory innervation to the posterior 1/3 of the tongue.

(Choice B) The chorda tympani is a branch of the facial nerve that passes along the deep surface of the tympanic membrane and through the petrotympanic fissure before merging with the lingual nerve to deliver taste sensation to the anterior 2/3 of the tongue.

(Choice C) The glossopharyngeal nerve (CN IX) delivers somatic sensory and taste innervation to the posterior 1/3 of the tongue.

(Choice D) The hypoglossal nerve (CN XII) innervates all intrinsic muscles of the tongue except the palatoglossus muscle, which is innervated by the vagus nerve (CN X).

(Choice E) The vagus nerve (CN X) innervates the palatoglossus muscle and carries taste signals from the pharynx and epiglottis. It does not carry taste signals from the tongue, however.

Educational Objective:

2 3 4 5 6 7 8 9 10 11 12 13 14 15 16 17 18 19 20 21 22 23 24 25 26 27 28 29 30 31 32 33 34 35 36 37 38 39 40 41

B. Chorda tympani [17%]

C. Glossopharyngeal nerve [9%]

D. Hypoglossal nerve [5%]

E. Vagus nerve [2%]

Explanation: **User Id: 477875**

The innervation of the tongue is complex because it involves motor, general somatic sensory and special sensory functions. Somatic sensation includes pain, touch, temperature and pressure, the same sensations felt by the skin. The lingual nerve, a branch of the mandibular division of the trigeminal nerve (CN V_3), provides somatic sensory innervation to the anterior 2/3 of the tongue. CN V_3 also provides somatic sensory innervation to the skin of the face. The glossopharyngeal (CN IX) nerve provides somatic sensory innervation to the posterior 1/3 of the tongue.

(Choice B) The chorda tympani is a branch of the facial nerve that passes along the deep surface of the tympanic membrane and through the petrotympanic fissure before merging with the lingual nerve to deliver taste sensation to the anterior 2/3 of the tongue.

(Choice C) The glossopharyngeal nerve (CN IX) delivers somatic sensory and taste innervation to the posterior 1/3 of the tongue.

(Choice D) The hypoglossal nerve (CN XII) innervates all intrinsic muscles of the tongue except the palatoglossus muscle, which is innervated by the vagus nerve (CN X).

(Choice E) The vagus nerve (CN X) innervates the palatoglossus muscle and carries taste signals from the pharynx and epiglottis. It does not carry taste signals from the tongue, however.

Educational Objective:
A branch of the mandibular division of the trigeminal nerve (CN V_3) provides somatic sensory innervation to the anterior 2/3 of the tongue. The chorda tympani branch of the facial nerve provides taste sensation from the anterior 2/3 of the tongue. The glossopharyngeal nerve (CN IX) provides somatic sensory and taste innervation to the posterior portion of the tongue.

Time Spent: 1 seconds Copyright © USMLEWorld,LLC. Last updated: [7/7/2010]

2, 3, 4, 5, 6, 7, 8, 9, 10, 11, 12, 13, 14, 15, 16, 17, 18, 19, 20, 21, 22, 23, 24, 25, 26, 27, 28, 29, 30, 31, 32, 33, 34, 35, 36, 37, 38, 39, 40, 41

A 65-year-old female is evaluated for progressive dyspnea and cardiomegaly. She also complains of occasional dysphagia. Her dysphagia is potentially explained by enlargement of the:

- A. Right ventricle [6%]
- B. Right atrium [16%]
- C. Left ventricle [8%]
- ✔ D. Left atrium [67%]
- E. Pulmonary artery [3%]

Explanation:

User Id: 477875

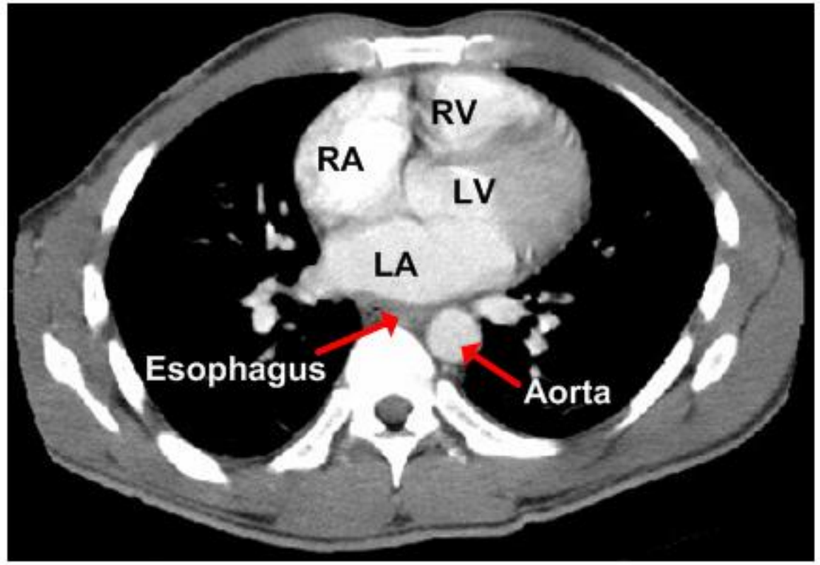

Given her history of dyspnea and cardiomegaly, this patient's dysphagia may be secondary to a cardiac cause. Cardiovascular dysphagia is uncommon, but when it does occur, it is usually the result of left atrial enlargement. (The left atrium is located posteriorly, directly overlying the esophagus.) Left atrial enlargement

2 3 4 5 6 7 8 9 10 11 12 13 14 15 16 17 18 19 20 21 22 23 24 25 26 27 28 29 30 31 32 33 34 35 36 37 38 39 40 41

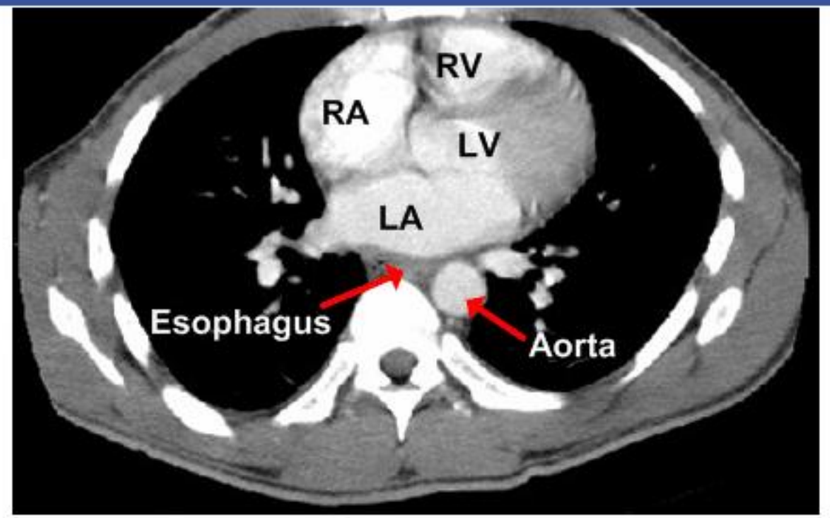

Given her history of dyspnea and cardiomegaly, this patient's dysphagia may be secondary to a cardiac cause. Cardiovascular dysphagia is uncommon, but when it does occur, it is usually the result of left atrial enlargement. (The left atrium is located posteriorly, directly overlying the esophagus.) Left atrial enlargement most commonly occurs in the setting of mitral stenosis and left ventricular failure. Increasing pressures in the left atrium cause distention of this chamber and pressure on the underlying esophagus.

(Choice A) The right ventricle is located on the right lateral aspect of the heart and abuts the right lung.

(Choice B) The right atrium is located on the anterior and superior right aspect of the heart and receives blood from the inferior and superior venae cavae as well as the coronary sinus.

(Choice C) The left ventricle is located on the left lateral side of the heart and abuts the left lung.

(Choice E) The pulmonary artery emerges from the right ventricle and branches into the right and left pulmonary arteries below the arch of the aorta.

Educational Objective:
Cardiovascular dysphagia can result from pressure on the esophagus by a dilated left atrium. The left atrium is commonly enlarged in patients with mitral stenosis and left ventricular failure.

Time Spent: 1 seconds

Copyright © USMLEWorld,LLC.

Last updated: [1/9/2013]

www.zeallsoft.com

2
3
4
5
6
7
8
9
10
11
12
13
14
15
16
17
18
19
20
21
22
23
24
25
26
27
28
29
30
31
32
33
34
35
36
37
38
39
40
41

A 55-year-old man is brought to the emergency department with profuse vomiting. Over the last hour, he has vomited large amounts of bright red blood. His past medical history is significant for long-term use of antacids. The patient's blood pressure is 70/40 mm Hg and pulse is 120/min. He dies 1 hour after admission despite resuscitation efforts. Autopsy shows a deep peptic ulcer localized proximally on the lesser curvature of the stomach. The ulcer most likely penetrated which of the following arteries?

- A. Common hepatic [2%]
- B. Right gastroepiploic [11%]
- ✔ C. Left gastric [66%]
- D. Gastroduodenal [12%]
- E. Inferior pancreaticoduodenal [1%]
- F. Splenic [7%]
- G. Superior mesenteric [1%]

Explanation:

User Id: 477875

Stomach vasculature

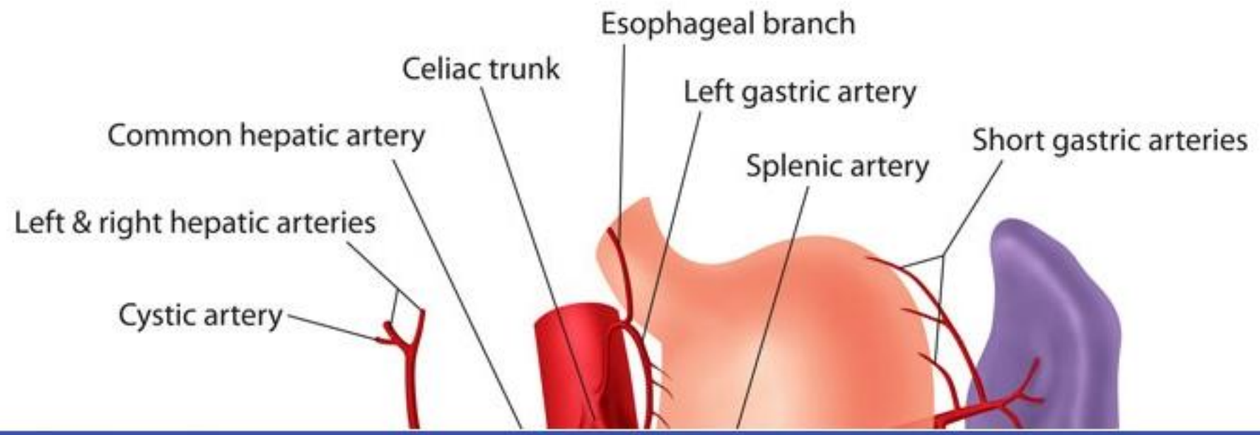

2
3
4
5
6
7
8
9
10
11
12
13
14
15
16
17
18
19
20
21
22
23
24
25
26
27
28
29
30
31
32
33
34
35
36
37
38
39
40
41

Stomach vasculature

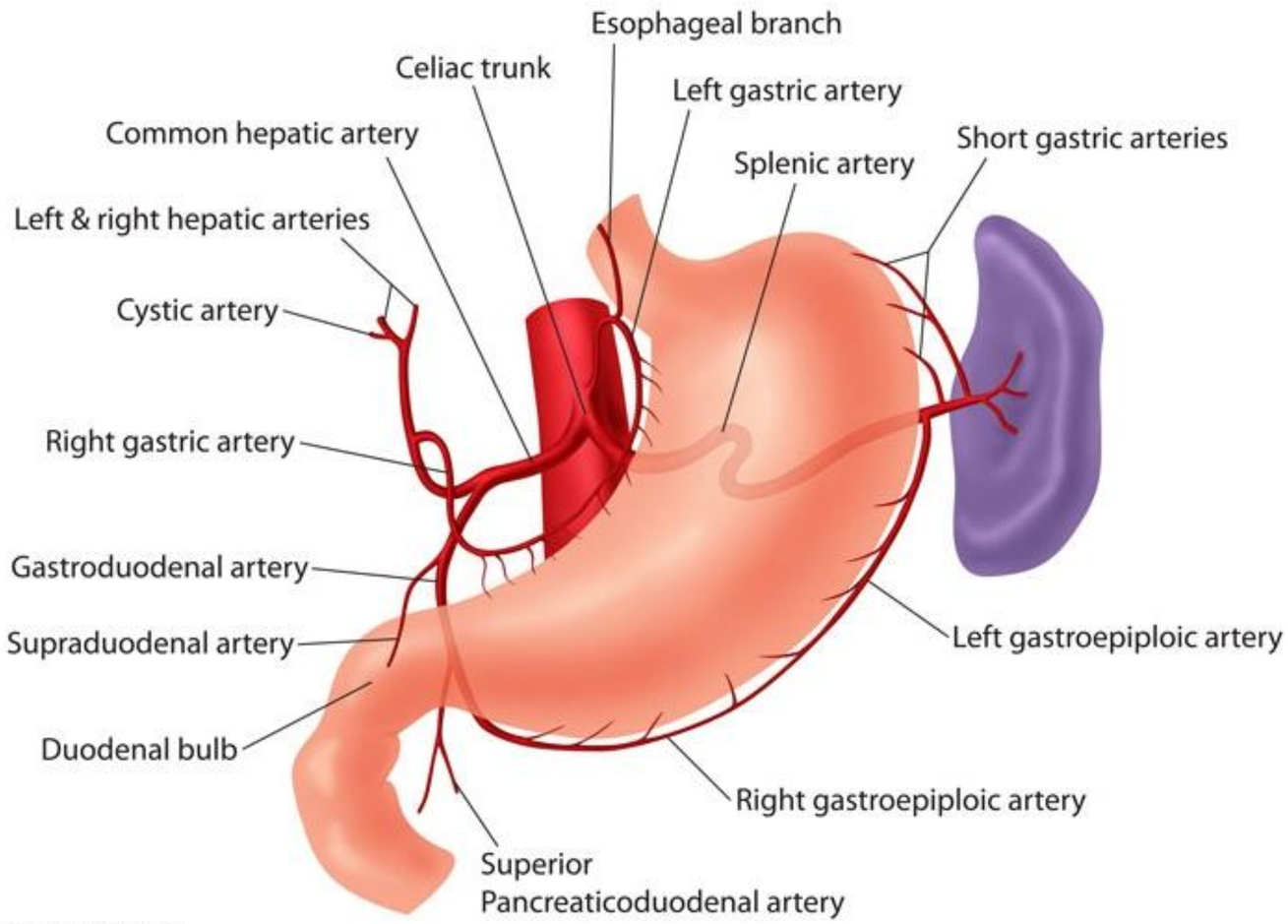

© USMLEWorld, LLC

Most gastric ulcers arise along the lesser curvature of the stomach. They are usually located at the transitional zone between the acid-secreting epithelium of the gastric corpus and gastrin-producing epithelium of the antrum. Glands in the corpus contain parietal cells that produce HCl and intrinsic factor; mucosal

2
3
4
5
6
7
8
9
10
11
12
13
14
15
16
17
18
19
20
21
22
23
24
25
26
27
28
29
30
31
32
33
34
35
36
37
38
39
40
41

© USMLEWorld, LLC

Most gastric ulcers arise along the lesser curvature of the stomach. They are usually located at the transitional zone between the acid-secreting epithelium of the gastric corpus and gastrin-producing epithelium of the antrum. Glands in the corpus contain parietal cells that produce HCl and intrinsic factor; mucosal glands in the antrum contain G-cells that secrete gastrin. The predilection of ulcers for the transitional zone may be due to the microenvironment having an optimal pH for *Helicobacter pylori* proliferation, or perhaps non-optimal local conditions induce the expression of inflammatory bacterial stress proteins.

A number of arteries supply the stomach:

Anatomic area	Supplying artery	Source artery
Proximal lesser curvature	Left gastric	Celiac
Distal lesser curvature	Right gastric	Proper hepatic ← common hepatic ← celiac
Proximal greater curvature	Left gastroepiploic	Splenic ← celiac
Distal greater curvature	Right gastroepiploic	Gastroduodenal ← common hepatic ← celiac
Proximal greater curvature above splenic artery	Short gastric arteries	Splenic ← celiac

The left and right gastric arteries run along and perfuse the lesser curvature of the stomach. They are likely to be penetrated by ulcers, leading to hemorrhage.

(Choice A) The common hepatic artery perfuses the liver, gallbladder, pylorus, duodenum, and pancreas. It arises from the celiac trunk and ends when it bifurcates into the proper hepatic and gastroduodenal arteries.

(Choice B) The right gastroepiploic artery arises from gastroduodenal artery and perfuses the distal greater curvature of the stomach. Gastric ulcers do not commonly occur in the greater curvature.

(Choice D) The gastroduodenal artery supplies blood to the pylorus and the proximal part of the duodenum. Ulcers in the posterior duodenal bulb can erode into the gastroduodenal artery and cause

2 3 4 5 6 7 8 9 10 11 12 13 14 15 16 17 18 19 20 21 22 23 24 25 26 27 28 29 30 31 32 33 34 35 36 37 38 39 40 41

Distal lesser curvature	Right gastric	Proper hepatic ← common hepatic ← celiac
Proximal greater curvature	Left gastroepiploic	Splenic ← celiac
Distal greater curvature	Right gastroepiploic	Gastroduodenal ← common hepatic ← celiac
Proximal greater curvature above splenic artery	Short gastric arteries	Splenic ← celiac

The left and right gastric arteries run along and perfuse the lesser curvature of the stomach. They are likely to be penetrated by ulcers, leading to hemorrhage.

(Choice A) The common hepatic artery perfuses the liver, gallbladder, pylorus, duodenum, and pancreas. It arises from the celiac trunk and ends when it bifurcates into the proper hepatic and gastroduodenal arteries.

(Choice B) The right gastroepiploic artery arises from gastroduodenal artery and perfuses the distal greater curvature of the stomach. Gastric ulcers do not commonly occur in the greater curvature.

(Choice D) The gastroduodenal artery supplies blood to the pylorus and the proximal part of the duodenum. Ulcers in the posterior duodenal bulb can erode into the gastroduodenal artery and cause bleeding.

(Choices E and G) The superior mesenteric and inferior pancreaticoduodenal arteries do not perfuse the stomach.

(Choice F) The splenic artery arises from the celiac trunk and supplies blood to the spleen. It is separated from the posterior wall of the stomach by the pancreas and is only rarely penetrated by gastric ulcers.

Educational objective:
The great majority of gastric ulcers occur over the lesser curvature of the stomach, at the border between acid-secreting and gastrin-secreting mucosa. The left and right gastric arteries run along the lesser curvature and are likely to be penetrated by ulcers, causing gastric bleeding.

Time Spent: 2 seconds

Copyright © USMLEWorld,LLC.

Last updated: [12/18/2012]

www.zeallsoft.com

2 3 4 5 6 7 8 9 10 11 12 13 14 15 16 17 18 19 20 21 22 23 24 25 26 27 28 29 30 31 32 33 34 35 36 37 38 39 40 41

An 8-year-old male is brought to your office because of an enlarged right testicle. Transillumination reveals a fluid accumulation within the scrotum. This fluid accumulation is most likely confined to the:

- A. External spermatic fascia [4%]
- B. Cremasteric fascia [4%]
- C. Internal spermatic fascia [5%]
- D. Tunica albuginea [12%]
- ✔ E. Tunica vaginalis [74%]

Explanation:

User Id: 477875

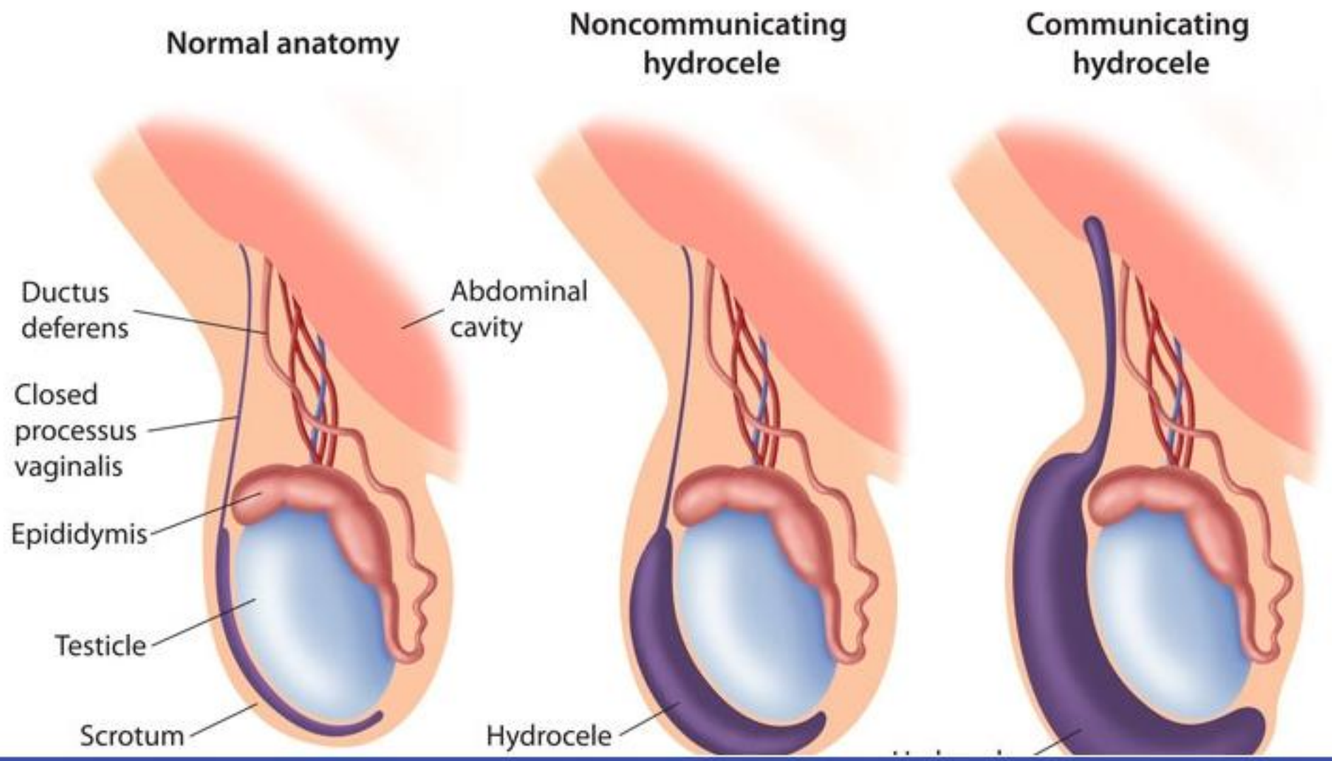

2
3
4
5
6
7
8
9
10
11
12
13
14
15
16
17
18
19
20
21
22
23
24
25
26
27
28
29
30
31
32
33
34
35
36
37
38
39
40
41

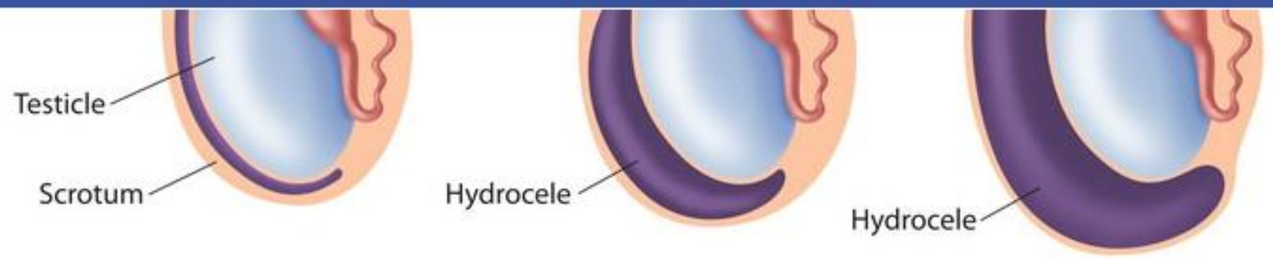

USMLEWorld, LLC © 2011

This patient's clinical presentation is consistent with hydrocele. Hydrocele occurs when serous fluid collects within the tunica vaginalis.

During embryogenesis, the testis descends through the inguinal canal, drawing a diverticulum of peritoneum into the scrotum as it descends. This peritoneal tissue is known as the processus vaginalis. Normally, the communication between the processus vaginalis and the peritoneum is obliterated, and the tunica vaginalis is the tissue that remains overlying the testis and epididymis. Congenital hydrocele, as described in the question stem, results when the processus vaginalis remains patent, allowing fluid from the peritoneum to accumulate in the scrotum.

(Choice A) The external spermatic fascia is derived from the aponeurosis of the external oblique abdominal muscle. This is the outermost layer of the spermatic cord and lies deep to the dartos muscle and scrotal fascia.

(Choice B) The cremasteric fascia arises from the internal oblique abdominal muscle and aponeurosis.

(Choice C) The internal spermatic fascia is derived from the transversalis fascia. This layer immediately overlies the spermatic cord and tunica vaginalis.

(Choice D) The tunica albuginea is the fibrous tissue that overlies the corpus spongiosum and corpora cavernosa of the penis.

Educational Objective:
Testicular hydrocele results when serous fluid accumulates within the tunica vaginalis. The tunica vaginalis is embryologically derived from the peritoneum; when it remains in communication with the peritoneum, a communicating hydrocele results.

Time Spent: N/A

Copyright © USMLEWorld,LLC.

Last updated: [1/17/2013]

2 3 4 5 6 7 8 9 10 11 12 13 14 15 16 17 18 19 20 21 22 23 24 25 26 27 28 29 30 31 32 33 34 35 36 37 38 39 40 41

A 39-year-old female is brought to the emergency room after a motor vehicle collision. Upon arrival she is determined to be stable, but complains of mild abdominal pain. CT scan of the abdomen reveals a retroperitoneal hematoma. Trauma of which of the following anatomic structures is most likely responsible for this finding?

- A. Abdominal aorta [21%]
- B. Transverse colon [6%]
- C. Liver [3%]
- D. Spleen [32%]
- ✔ E. Pancreas [37%]

Explanation: **User Id: 477875**

The retroperitoneum is the space located behind the peritoneal cavity. It includes the following structures:

1. Major vessels: abdominal aorta, inferior vena cava and their branches.
2. Solid organs: pancreas (except the tail), kidneys, adrenal glands.
3. Hollow organs: parts 2 & 3 and a portion of part 4 of the duodenum, the ascending and descending colon (secondarily retroperitoneal), rectum, ureters and bladder.
4. Vertebral column and pelvic muscles.

Retroperitoneal hematomas are commonly associated with abdominal and pelvic trauma; they develop in up to half of patients with blunt abdominal trauma. Pancreatic injury with formation of a retroperitoneal hematoma can occur due to severe blunt or penetrating abdominal trauma. It can frequently be caused by direct abdominal blows from malpositioned seat belts or by steering wheels during automobile collisions. Pancreatic injury can cause mild symptoms or be asymptomatic. An abdominal CT scan should be performed in stable patients with blunt abdominal trauma to exclude the possibility of retroperitoneal hematoma.

(Choice A) Though the abdominal aorta is a retroperitoneal structure, rupture of the abdominal aorta would

2, 3, 4, 5, 6, 7, 8, 9, 10, 11, 12, 13, 14, 15, 16, 17, 18, 19, 20, 21, 22, 23, 24, 25, 26, 27, 28, 29, 30, 31, 32, 33, 34, 35, 36, 37, 38, 39, 40, 41

D. Spleen [32%]

✔ E. Pancreas [37%]

Explanation: **User Id: 477875**

The retroperitoneum is the space located behind the peritoneal cavity. It includes the following structures:

1. Major vessels: abdominal aorta, inferior vena cava and their branches.
2. Solid organs: pancreas (except the tail), kidneys, adrenal glands.
3. Hollow organs: parts 2 & 3 and a portion of part 4 of the duodenum, the ascending and descending colon (secondarily retroperitoneal), rectum, ureters and bladder.
4. Vertebral column and pelvic muscles.

Retroperitoneal hematomas are commonly associated with abdominal and pelvic trauma; they develop in up to half of patients with blunt abdominal trauma. Pancreatic injury with formation of a retroperitoneal hematoma can occur due to severe blunt or penetrating abdominal trauma. It can frequently be caused by direct abdominal blows from malpositioned seat belts or by steering wheels during automobile collisions. Pancreatic injury can cause mild symptoms or be asymptomatic. An abdominal CT scan should be performed in stable patients with blunt abdominal trauma to exclude the possibility of retroperitoneal hematoma.

(Choice A) Though the abdominal aorta is a retroperitoneal structure, rupture of the abdominal aorta would most likely result in massive and rapid blood loss leading to hemorrhagic shock.

(Choices B, C and D) The transverse colon, liver, and spleen are intraperitoneal organs. Lacerations or rupture of these organs can occur in blunt abdominal trauma, but these injuries would lead to hemoperitoneum (free blood in the peritoneal space) not retroperitoneal hematoma.

Educational Objective:
Retroperitoneal hematoma in a stable patient is likely to occur due to pancreatic injury. It may present with mild symptoms, be asymptomatic or be masked by symptoms from other injuries related to trauma. Abdominal CT is the diagnostic modality of choice. Frequently nonexpanding hematomas in this location will be treated conservatively (i.e. non-operatively).

Time Spent: 1 seconds Copyright © USMLEWorld,LLC. Last updated: [7/7/2010]

www.zeallsoft.com

2
3
4
5
6
7
8
9
10
11
12
13
14
15
16
17
18
19
20
21
22
23
24
25
26
27
28
29
30
31
32
33
34
35
36
37
38
39
40
41

A 31-year-old man comes to the emergency department complaining of right-sided scrotal pain and swelling that has gradually worsened over the last 3 days. His temperature is 38.3 C (101 F). On physical examination, his right hemiscrotum is warm, tender, and erythematous. The cremasteric reflex is present. A scrotal ultrasound reveals a fluid collection consistent with a superficial scrotal abscess. Which of the following lymph node groups is most likely to be tender and swollen?

- A. Common iliac [3%]
- B. Inferior mesenteric [2%]
- C. Infraclavicular [0%]
- D. Para-aortic [26%]
- ✔ E. Superficial inguinal [68%]

Explanation:

User Id: 477875

Lymph vessels & nodes of male genitalia

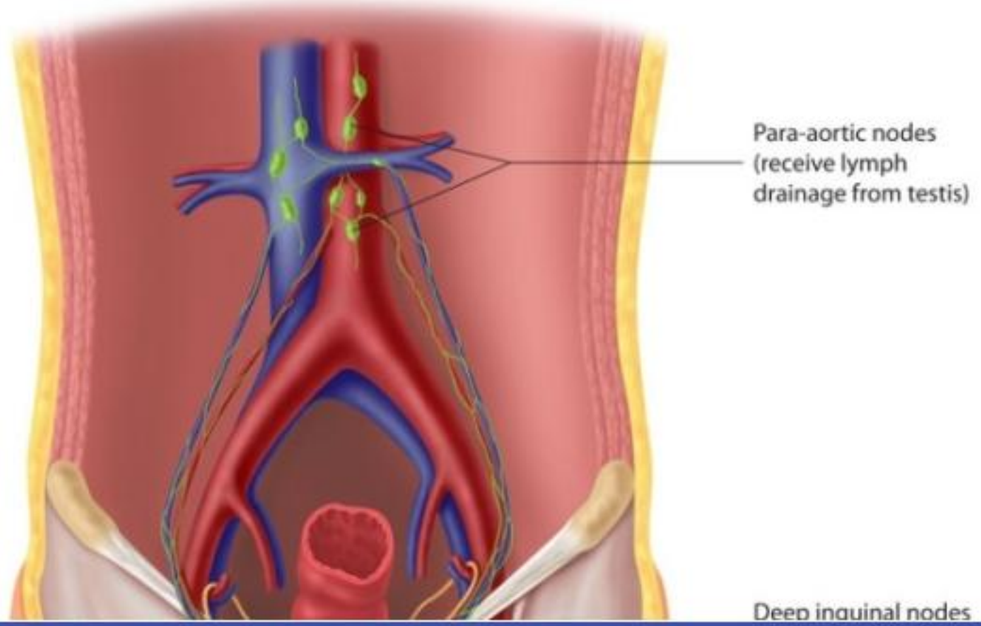

www.zeallsoft.com

2
3
4
5
6
7
8
9
10
11
12
13
14
15
16
17
18
19
20
21
22
23
24
25
26
27
28
29
30
31
32
33
34
35
36
37
38
39
40
41

Lymph vessels & nodes of male genitalia

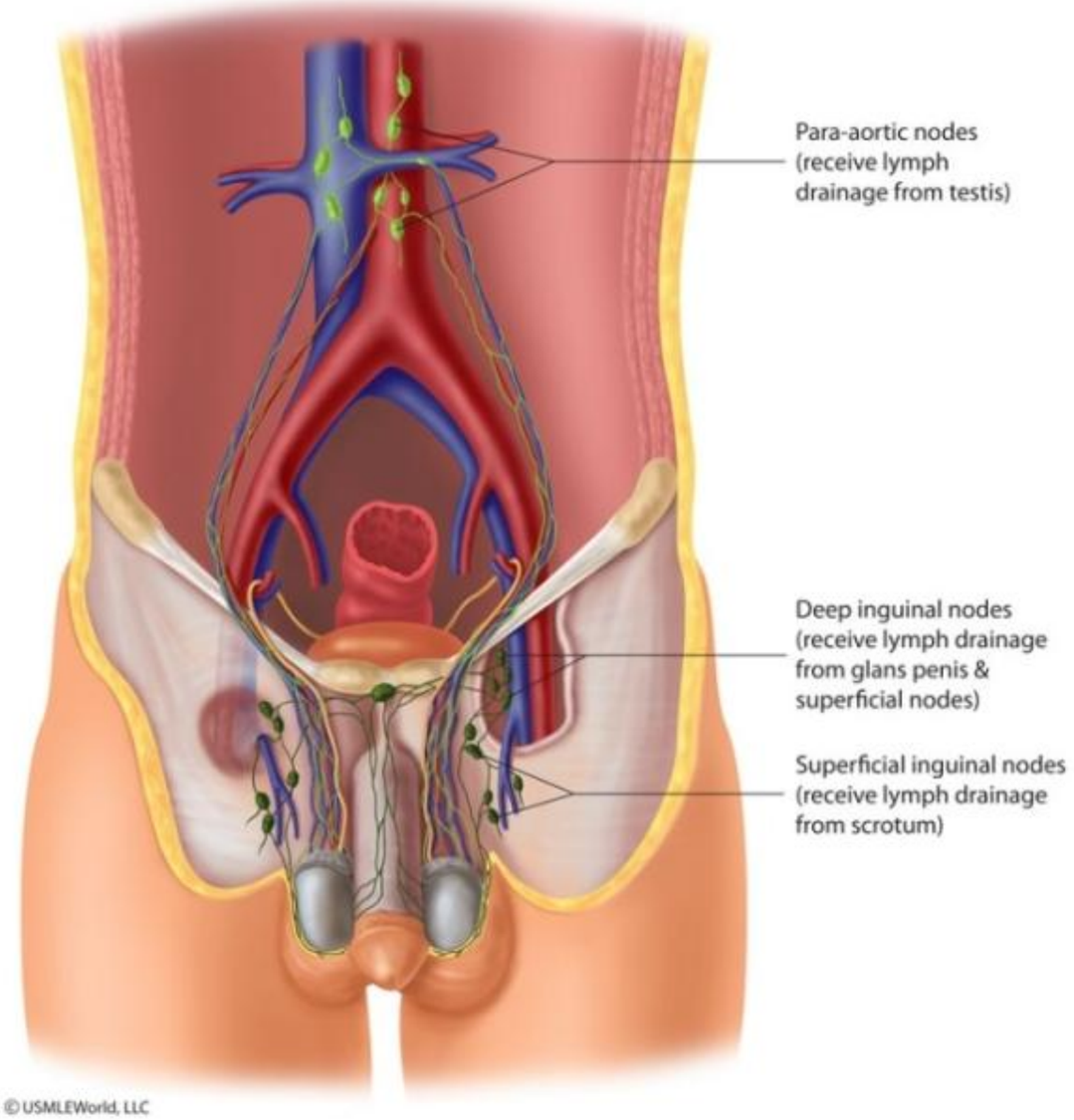

Lymphatic drainage of the scrotum occurs via the superficial inguinal lymph nodes. These lymph nodes drain

2
3
4
5
6
7
8
9
10
11
12
13
14
15
16
17
18
19
20
21
22
23
24
25
26
27
28
29
30
31
32
33
34
35
36
37
38
39
40
41

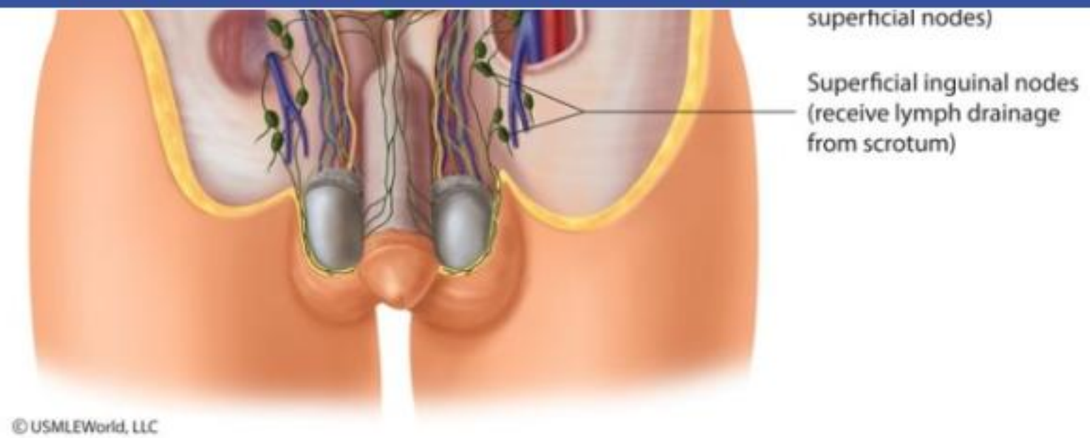

Lymphatic drainage of the scrotum occurs via the superficial inguinal lymph nodes. These lymph nodes drain nearly all cutaneous lymph from the umbilicus to the feet, including the external genitalia and anus (up to the dentate line). The exceptions are the testis, glans penis, and the cutaneous portion of the posterior calf. Lymph from the testes drains directly into the para-aortic (retroperitoneal) lymph nodes **(Choice D)**. Lymph from the glans penis and the cutaneous portion of the posterior calf drains into the deep inguinal lymph nodes. The superficial inguinal lymph nodes also drain into the deep inguinal lymph nodes.

(Choice A) The common iliac nodes are located alongside the common iliac artery and drain the internal and external iliac nodes. The external iliac nodes receive lymph from the deep inguinal lymph nodes.

(Choice B) The inferior mesenteric nodes drain the structures supplied by branches of the inferior mesenteric artery (eg, the left colic, sigmoid, and superior rectal arteries). Thus, these nodes drain the descending and sigmoid colon as well as the upper part of the rectum, and their efferents drain into the pre-aortic nodes.

(Choice C) Infraclavicular lymph nodes are found beside the cephalic vein between the pectoralis major and deltoid, immediately below the clavicle. They drain lymph from portions of the upper limb and breast.

Educational objective:
Due to its intra-abdominal origin, lymphatic drainage of the testis is to the para-aortic lymph nodes. In contrast, lymph drainage from the scrotum goes into the superficial inguinal lymph nodes.

Time Spent: 1 seconds

Copyright © USMLEWorld,LLC.

Last updated: [2/21/2013]

2, 3, 4, 5, 6, 7, 8, 9, 10, 11, 12, 13, 14, 15, 16, 17, 18, 19, 20, 21, 22, 23, 24, 25, 26, 27, 28, 29, 30, 31, 32, 33, 34, 35, 36, 37, 38, 39, 40, 41

A 34-year-old woman comes to the physician complaining of double vision. She first experienced difficulty focusing her eyes while at work yesterday. Upon waking up this morning, her symptoms had progressed to frank diplopia. Her past medical history is insignificant. A complete physical examination is performed, including a full neurologic assessment. Shining light into her right eye causes constriction of her right pupil, but not the left pupil. Shining light into her left eye causes constriction of only her right pupil. Which of the following additional physical examination findings is likely to be found in this patient?

- A. Absence of the left corneal reflex [19%]
- ✔ B. Drooping of the left eyelid [54%]
- C. Inability to close the left eye [5%]
- D. Inward deviation of the left eye [13%]
- E. Visual loss in the left eye [9%]

Explanation:

User Id: 477875

Pupillary light reflex

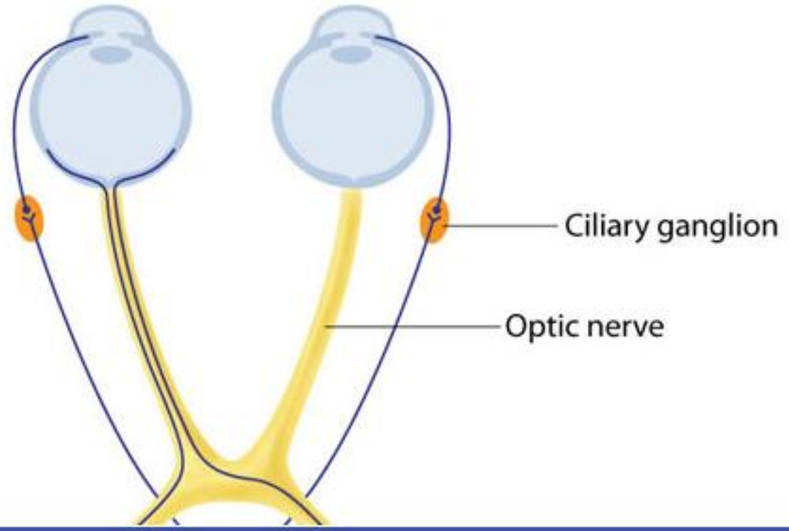

www.zeallsoft.com

2
3
4
5
6
7
8
9
10
11
12
13
14
15
16
17
18
19
20
21
22
23
24
25
26
27
28
29
30
31
32
33
34
35
36
37
38
39
40
41

Pupillary light reflex

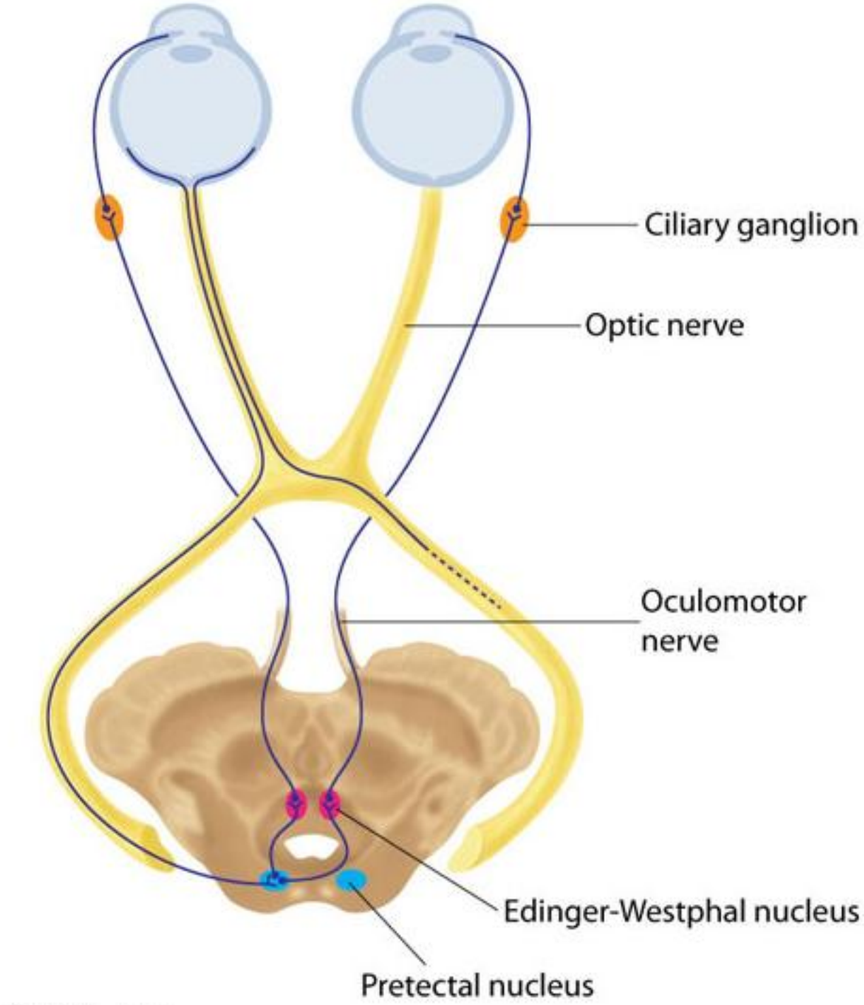

© USMLEWorld, LLC

2 3 4 5 6 7 8 9 10 11 12 13 14 15 16 17 18 19 20 21 22 23 24 25 26 27 28 29 30 31 32 33 34 35 36 37 38 39 40 41

The pupillary light reflex is assessed by shining light in an eye and observing the response in that eye (direct) as well as the opposite eye (consensual). The optic nerve (CN II) is responsible for the afferent limb of this reflex; the oculomotor nerve (CN III) is responsible for the efferent limb. In this patient, the right CN II and right CN III are functional as there was a direct response seen when light was shined into the right eye. In addition, the left CN II is also functional as a consensual response occurred when light was shined into the left eye. However, constriction of the left pupil was not seen in either circumstance. Thus, this patient's lesion most likely involves her left CN III.

The symptoms of CN III palsy relate to the function of CN III:

1. A somatic component innervates the inferior, superior, and medial rectus; inferior oblique; and levator palpebrae muscles. Ptosis occurs due to paralysis of the levator palpebrae, and the unopposed action of the lateral rectus (CN VI) and superior oblique (CN IV) muscles leads to a "down-and-out" gaze.
2. Parasympathetic fibers of CN III innervate the iris sphincter and ciliary muscle. Paralysis of these fibers causes a fixed, dilated pupil and loss of accommodation.

CN III palsy can result from lesions anywhere along the nerve's path from the oculomotor nucleus in the midbrain to the extraocular muscles within the orbit. The most dreaded cause of isolated acute third nerve palsy is an actively enlarging intracranial aneurysm (at risk of imminent rupture).

(Choice A) Absence of the corneal reflex can result from lesions involving CN V_1 (afferent limb) or CN VII (efferent limb).

(Choice C) A lesion involving the left CN VII would result in inability to close the left eye.

(Choice D) Inward deviation of the left eye would result from a CN VI lesion and the resultant unopposed action of CN III.

(Choice E) The left CN II is functional as it was able to produce a consensual response in the right eye.

Educational objective:
The pupillary light reflex is assessed by shining light in an eye and observing the response in that eye (direct) and the opposite eye (consensual). The optic nerve (CN II) is responsible for the afferent limb of the pupillary reflex, and the oculomotor nerve (CN III) is responsible for the efferent limb.

2, 3, 4, 5, 6, 7, 8, 9, 10, 11, 12, 13, 14, 15, 16, 17, 18, 19, 20, 21, 22, 23, 24, 25, 26, 27, 28, 29, 30, 31, 32, 33, 34, 35, 36, 37, 38, 39, 40, 41

A 65-year-old male presents to your office complaining of hearing loss. An audiogram shows impaired hearing of low-frequency sounds. Sensory cells close to which of the following structures are most likely affected in this patient?

- A. Cochlear base [33%]
- B. Oval window [17%]
- C. Round window [12%]
- ✔ D. Helicotrema [27%]
- E. Stapes [9%]

Explanation:

User Id: 477875

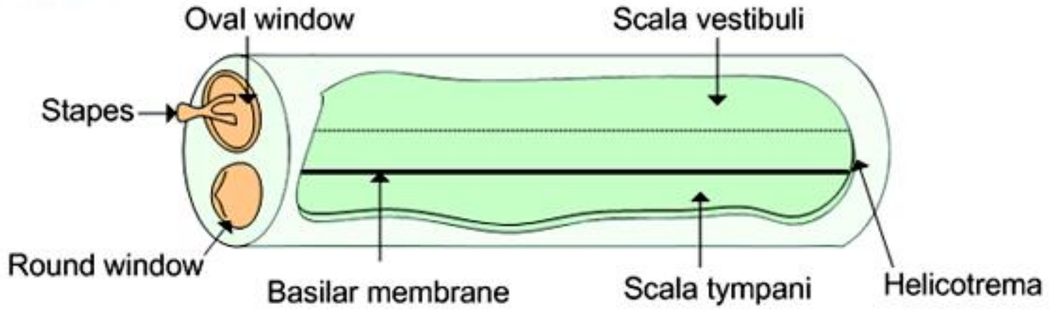



2 3 4 5 6 7 8 9 10 11 12 13 14 15 16 17 18 19 20 21 22 23 24 25 26 27 28 29 30 31 32 33 34 35 36 37 38 39 40 41

Explanation:

User Id: 477875

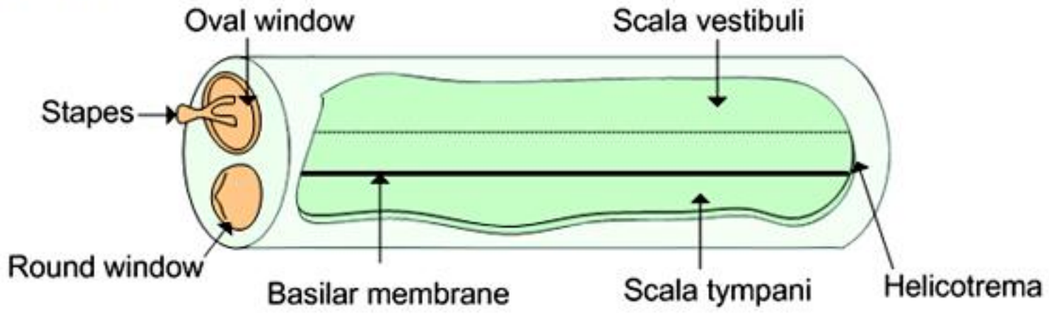

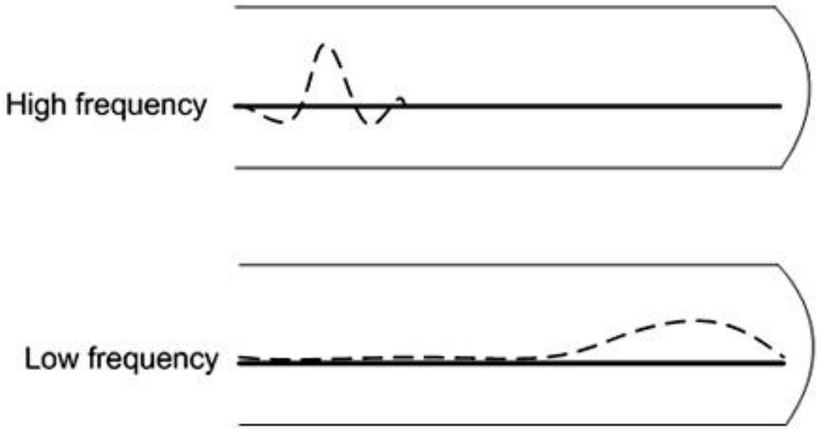

The inner ear is a fluid-filled site encased in bone that houses the cochlea, the semicircular canals, and the vestibule. The cochlea is a cone-shaped spiraling structure. The base of the cochlea is the widest section of the cone, and it lies near the oval and round windows. The apex of the cochlea is the tip of the cone, which lies near the helicotrema. The cochlea is composed of three spiraling fluid-filled ducts known as the scala vestibuli, the scala media, and the scala tympani. The scala media lies between the scala vestibuli and the scala tympani. Both the scala vestibuli and the scala tympani are filled with perilymph, which has a high sodium concentration, while the scala media is filled with endolymph having a high potassium concentration. The scala media is separated from the scala tympani by the basilar membrane. The scala media is also unique in that it houses the tectorial membrane and the organ of Corti. The organ of Corti is the specific site

2
3
4
5
6
7
8
9
10
11
12
13
14
15
16
17
18
19
20
21
22
23
24
25
26
27
28
29
30
31
32
33
34
35
36
37
38
39
40
41

The inner ear is a fluid-filled site encased in bone that houses the cochlea, the semicircular canals, and the vestibule. The cochlea is a cone-shaped spiraling structure. The base of the cochlea is the widest section of the cone, and it lies near the oval and round windows. The apex of the cochlea is the tip of the cone, which lies near the helicotrema. The cochlea is composed of three spiraling fluid-filled ducts known as the scala vestibuli, the scala media, and the scala tympani. The scala media lies between the scala vestibuli and the scala tympani. Both the scala vestibuli and the scala tympani are filled with perilymph, which has a high sodium concentration, while the scala media is filled with endolymph having a high potassium concentration. The scala media is separated from the scala tympani by the basilar membrane. The scala media is also unique in that it houses the tectorial membrane and the organ of Corti. The organ of Corti is the specific site where sound is transduced into the nervous system.

The transduction of mechanical auditory forces into nervous impulses occurs in the organ of Corti by the following steps. First, sound reaches the middle ear by vibrating the tympanic membrane. This vibration is transferred to the oval window by the ossicles. Vibration of the oval window causes movement of the perilymph in the scala vestibuli, which is transmitted to the scala tympani. Perilymph movement in the scala tympani, in turn, causes the flexible basilar membrane to vibrate. Vibration of the basilar membrane causes bending of the cilia of the hair cells as fluid runs past the rigid tectorial membrane. Hair cell bending causes oscillating hyperpolarization and depolarization, thus creating nervous impulses from sound. At the base of the cochlea, the basilar membrane is thin and rigid and best responds to high frequency sound. The basilar membrane at the apex of the cochlea, near the helicotrema, is large and flexible, so it best responds to low frequency sounds. The helicotrema is the site where the scala vestibuli and the scala tympani meet.

(Choices A, B and C) The cochlear base lies near the round and oval windows; this segment of the cochlea best responds to high-frequency sound. Older adults do suffer from high-frequency hearing loss much more often than low-frequency loss. The oval window transmits vibration to the scala vestibuli, which communicates with the scala tympani at the helicotrema, which then transmits vibration to the round window. As the oval window moves inward, the round window moves outward.

(Choice E) The stapes is one of the ossicles of the middle ear. The other two are the malleus and incus.

Educational Objective:
Low-frequency sound is best detected at the apex of the cochlea near the helicotrema. High-frequency sound is best detected at the base of the cochlea near the oval and round windows.

Time Spent: 1 seconds Copyright © USMLEWorld,LLC. Last updated: [11/10/2011]

2, 3, 4, 5, 6, 7, 8, 9, 10, 11, 12, 13, 14, 15, 16, 17, 18, 19, 20, 21, 22, 23, 24, 25, 26, 27, 28, 29, 30, 31, 32, 33, 34, 35, 36, 37, 38, 39, 40, 41

A 54-year-old female undergoes thyroidectomy for several thyroid nodules that were suspicious for malignancy on fine needle aspiration. While ligating the superior thyroid artery, the surgeon accidentally severs a nearby nerve. Which of the following muscles is denervated as a result of this injury?

- A. Thyroarytenoid [6%]
- B. Lateral cricoarytenoid [13%]
- C. Posterior cricoarytenoid [8%]
- ✔ D. Cricothyroid [69%]
- E. Aryepiglotticus [3%]

Explanation: **User Id: 477875**

The superior thyroid artery, a branch of the external carotid artery, and the inferior thyroid artery, a branch of the thyrocervical trunk, provide the blood supply to the thyroid and parathyroid glands. The superior thyroid artery, superior thyroid vein, and external branch of the superior laryngeal nerve course together in a neurovascular triad that originates superior to the thyroid gland and lateral to the thyroid cartilage. Because the external branch of the superior laryngeal nerve courses just deep to the superior thyroid artery, it is at risk of injury during thyroidectomy. The cricothyroid muscle is the only muscle innervated by this nerve. The remaining laryngeal muscles are innervated by the recurrent laryngeal nerves, which also provide sensory innervation to the larynx below the vocal folds. The internal branch of the superior laryngeal nerve does not innervate any muscles, but provides sensory innervation to the laryngeal mucosa above the vocal folds.

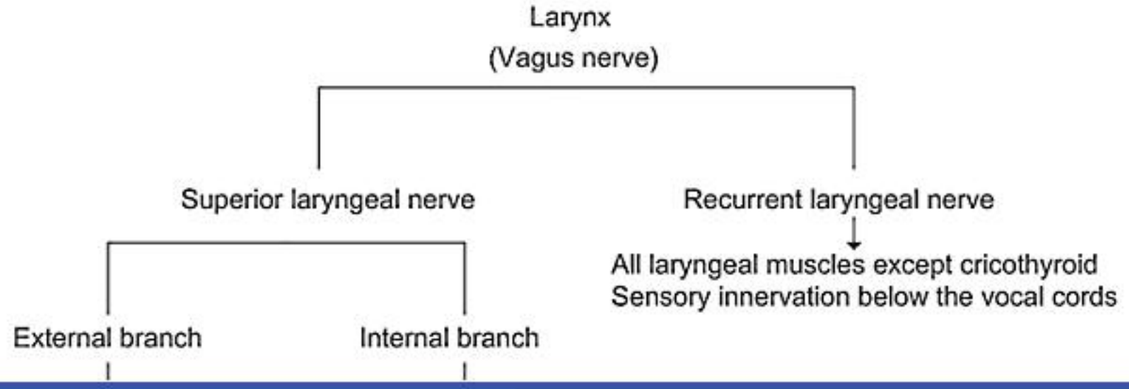

2, 3, 4, 5, 6, 7, 8, 9, 10, 11, 12, 13, 14, 15, 16, 17, 18, 19, 20, 21, 22, 23, 24, 25, 26, 27, 28, 29, 30, 31, 32, 33, 34, 35, 36, 37, 38, 39, 40, 41

D. Cricothyroid [65%]

E. Aryepiglotticus [3%]

Explanation: **User Id: 477875**

The superior thyroid artery, a branch of the external carotid artery, and the inferior thyroid artery, a branch of the thyrocervical trunk, provide the blood supply to the thyroid and parathyroid glands. The superior thyroid artery, superior thyroid vein, and external branch of the superior laryngeal nerve course together in a neurovascular triad that originates superior to the thyroid gland and lateral to the thyroid cartilage. Because the external branch of the superior laryngeal nerve courses just deep to the superior thyroid artery, it is at risk of injury during thyroidectomy. The cricothyroid muscle is the only muscle innervated by this nerve. The remaining laryngeal muscles are innervated by the recurrent laryngeal nerves, which also provide sensory innervation to the larynx below the vocal folds. The internal branch of the superior laryngeal nerve does not innervate any muscles, but provides sensory innervation to the laryngeal mucosa above the vocal folds.

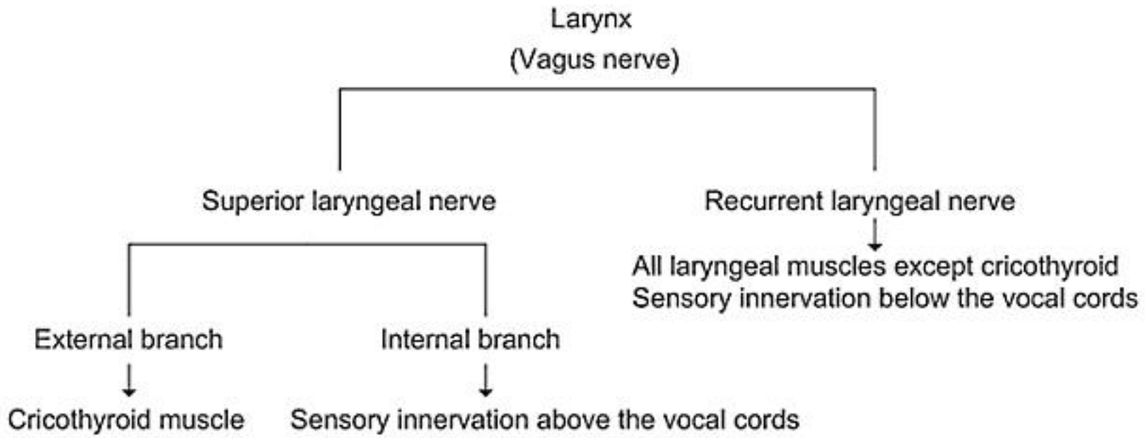

(Choices A, B, C and E) These muscles are all innervated by the recurrent laryngeal nerve.

Educational Objective:
The external branch of the superior laryngeal nerve is at risk of injury during thyroidectomy due to its proximity to the superior thyroid artery and vein. This nerve innervates the cricothyroid muscle.

Time Spent: 1 seconds

Copyright © USMLEWorld,LLC.

Last updated: [1/31/2013]

2
3
4
5
6
7
8
9
10
11
12
13
14
15
16
17
18
19
20
21
22
23
24
25
26
27
28
29
30
31
32
33
34
35
36
37
38
39
40
41

A 56-year-old man comes to the physician complaining of early satiety, nausea, and vague epigastric pain for the past 4 months. He has a 36-pack-year smoking history and admits to drinking alcohol daily for the past 15 years. On physical examination, the patient appears thin and cachectic. Palpation of his abdomen reveals splenomegaly. Abdominal CT scan shows a large irregular mass extending posteriorly from the greater curvature of the stomach, impinging on the splenic artery and vein as they pass below. Tissues supplied by which of the following arteries would most likely be affected by compression of the splenic artery?

- A. Gastroduodenal [5%]
- B. Left gastroepiploic [34%]
- C. Right gastric [6%]
- D. Right gastroepiploic [6%]
- ✔ E. Short gastric [50%]

Explanation:

User Id: 477875

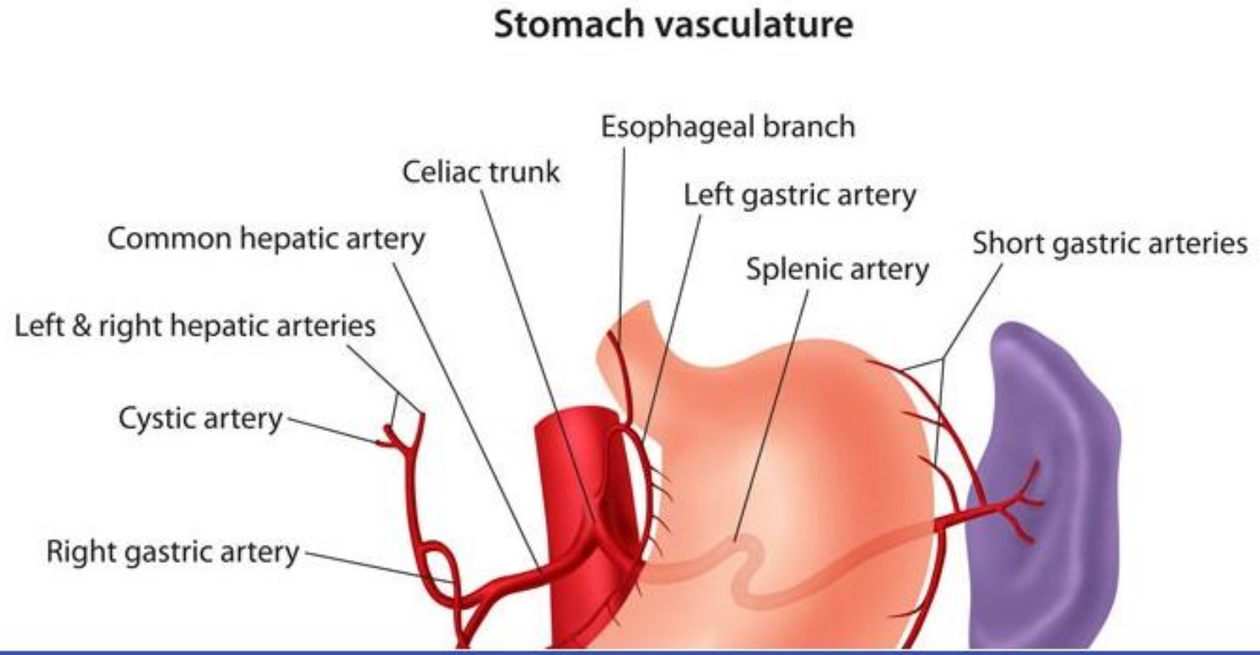

2
3
4
5
6
7
8
9
10
11
12
13
14
15
16
17
18
19
20
21
22
23
24
25
26
27
28
29
30
31
32
33
34
35
36
37
38
39
40
41

Explanation:

User Id: 477875

Stomach vasculature

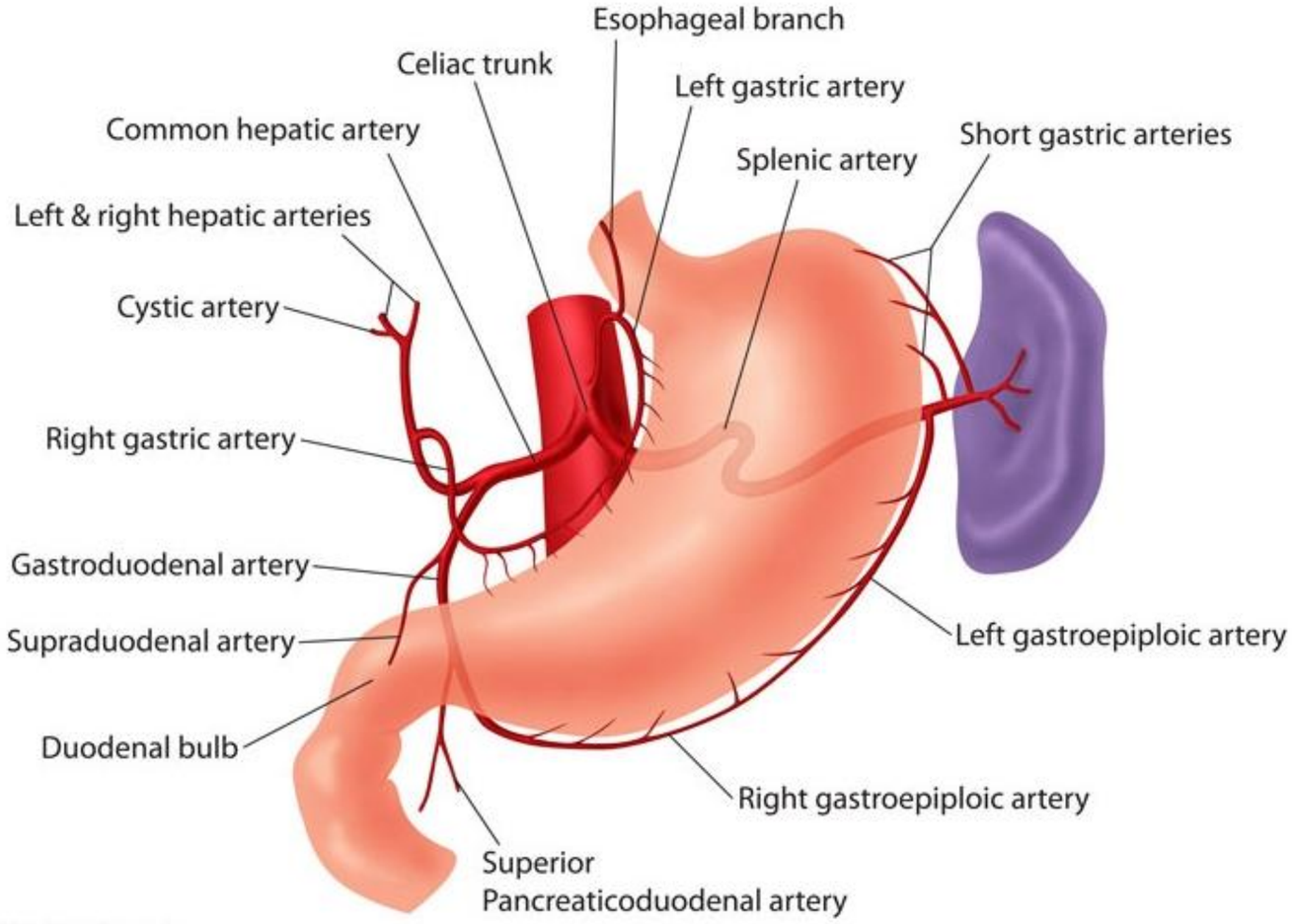

© USMLEWorld, LLC

The splenic artery originates from the celiac artery and courses superior to the pancreas. Along its route, it

2
3
4
5
6
7
8
9
10
11
12
13
14
15
16
17
18
19
20
21
22
23
24
25
26
27
28
29
30
31
32
33
34
35
36
37
38
39
40
41

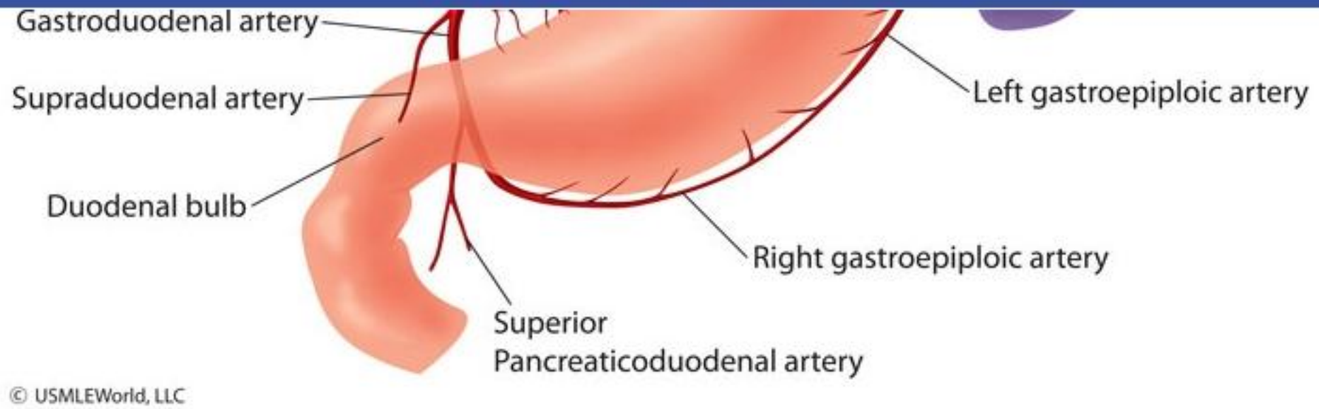

The splenic artery originates from the celiac artery and courses superior to the pancreas. Along its route, it gives off **several branches** to the stomach and pancreas before reaching the spleen. The short gastric arteries and the left gastroepiploic artery arise from the splenic artery immediately after it passes the greater curvature of the stomach. The short gastric arteries have very poor anastomoses, and the tissue supplied by them is vulnerable to ischemic injury following splenic artery blockage. In contrast, tissues supplied by the left gastroepiploic artery can be alternatively supplemented by its strong anastomotic connection with the right gastroepiploic artery **(Choice B)**.

(Choice A) The gastroduodenal artery supplies blood to the pylorus and the proximal part of the duodenum. It arises from the common hepatic artery.

(Choice C) The right gastric artery supplies blood to the distal lesser curvature of the stomach. It arises from the proper hepatic artery.

(Choice D) The right gastroepiploic artery arises from the gastroduodenal artery and perfuses the distal greater curvature of the stomach. It forms an anastomosis with the left gastroepiploic artery.

Educational objective:
The splenic artery originates from the **celiac artery** and gives off several branches to the stomach and pancreas (pancreatic, short gastric, and left gastroepiploic arteries) before finally reaching the spleen. Due to poor anastomoses, the gastric tissue supplied by the short gastric arteries is vulnerable to ischemic injury following splenic artery blockage.

Time Spent: 3 seconds

Copyright © USMLEWorld,LLC.

Last updated: [1/7/2013]

2, 3, 4, 5, 6, 7, 8, 9, 10, 11, 12, 13, 14, 15, 16, 17, 18, 19, 20, 21, 22, 23, 24, 25, 26, 27, 28, 29, 30, 31, 32, 33, 34, 35, 36, 37, 38, 39, 40, 41

A 63-year-old male complains of having to "strain" on urination. The patient feels much better several weeks after starting doxazosin. Involvement of which of the following structures is most likely responsible for this patient's symptoms?

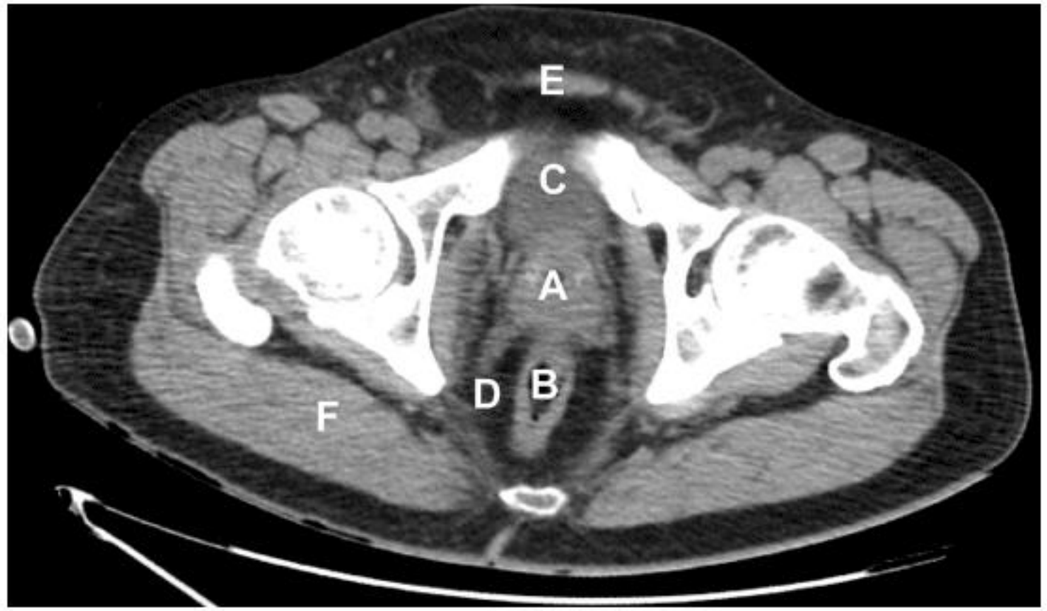

- ✔ A. A [67%]
- B. B [8%]
- C. C [18%]
- D. D [5%]
- E. E [2%]
- F. F [1%]

Explanation: **User Id: 477875**

The patient described in the question stem is suffering from symptoms of benign prostatic hyperplasia (BPH). On autopsy, this condition is present in >90% of men aged eighty and above. Urinary complaints are

2, 3, 4, 5, 6, 7, 8, 9, 10, 11, 12, 13, 14, 15, 16, 17, 18, 19, 20, 21, 22, 23, 24, 25, 26, 27, 28, 29, 30, 31, 32, 33, 34, 35, 36, 37, 38, 39, 40, 41

- ✔ A. A [67%]
- B. B [8%]
- C. C [18%]
- D. D [5%]
- E. E [2%]
- F. F [1%]

Explanation: **User Id: 477875**

The patient described in the question stem is suffering from symptoms of benign prostatic hyperplasia (BPH). On autopsy, this condition is present in >90% of men aged eighty and above. Urinary complaints are the primary symptoms in BPH, including urinary hesitancy, urgency, frequency, incomplete voiding, post-void leakage of urine, and nocturia. Diagnosis is made from the history and physical, including the digital rectal exam.

Medical treatment of BPH is with α-adrenergic blockers, which relax the smooth muscle in the bladder neck, or with 5-α reductase inhibitors, which reduce hormonal influence on the prostate by preventing the conversion of testosterone to dihydrotestosterone. In the pelvic CT "slice" given in the question stem, the prostate is labeled "(A)." At this level of sectioning, the prostate is located posterior to the pubic symphysis and anterior to the anal canal "(B)."

(Choice C) C is the distal end of bladder.

(Choice D) D labels the ischioanal fossa.

(Choice E) E is the rectus abdominus muscle.

(Choice F) F is the gluteus maximus muscle.

Educational Objective:
BPH is a common, age-related condition that causes urinary symptoms and can be medically treated with α-adrenergic blockers or 5-α reductase inhibitors. The prostate is located between the pubic symphysis and the anal canal in inferior sections of the pelvis on CT scan.

2
3
4
5
6
7
8
9
10
11
12
13
14
15
16
17
18
19
20
21
22
23
24
25
26
27
28
29
30
31
32
33
34
35
36
37
38
39
40
41

A 40-year-old nulligravid female presents to your office complaining of left-sided pelvic pain that has been getting worse over the last 2 months. She says that she experiences the pain everyday and that its intensity does not vary based upon her menstrual cycle. She has also noticed an increase in abdominal size despite a recent decrease in her appetite. Pelvic exam reveals an irregularly shaped, fixed adnexal mass. One week later, the patient undergoes surgery for removal of a large ovarian neoplasm. The surgeon can palpate the left ureter immediately lateral to which of the following structures?

- A. Gonadal vein [21%]
- B. External iliac artery [6%]
- C. Inferior vena cava [3%]
- ✔ D. Internal iliac artery [26%]
- E. Uterine artery [44%]

Explanation:

User Id: 477875

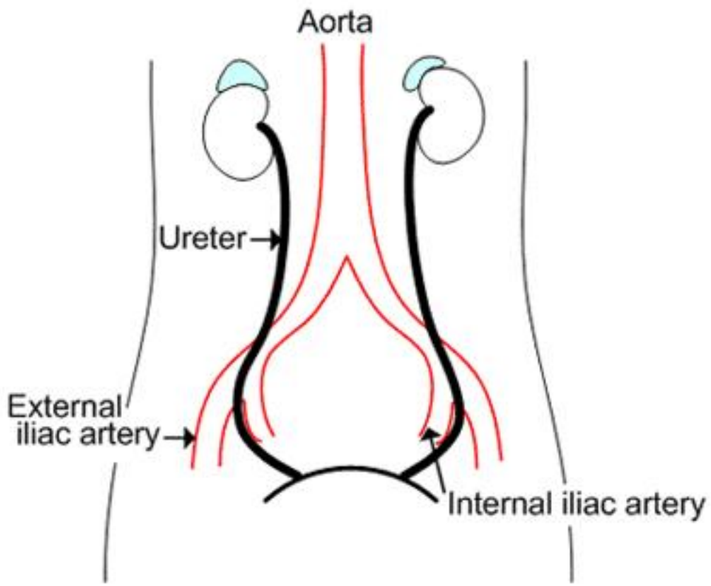

There are a few important landmarks to keep in mind when asked about the ureters. The ureters originate

2
3
4
5
6
7
8
9
10
11
12
13
14
15
16
17
18
19
20
21
22
23
24
25
26
27
28
29
30
31
32
33
34
35
36
37
38
39
40
41

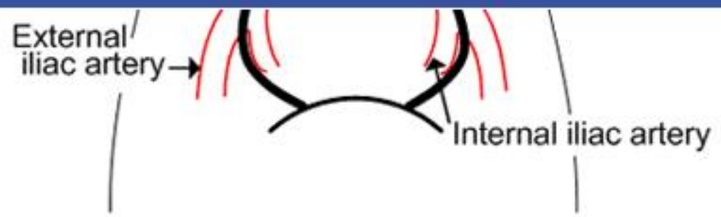

There are a few important landmarks to keep in mind when asked about the ureters. The ureters originate bilaterally at the renal pelvis and course within the retroperitoneum inferiorly toward the bladder, initially on top of the psoas muscles. Midway from the kidney to the pelvic inlet the gonadal artery and vein cross over the anterior surface of the ureter ("water under the bridge"). The ureters then gain access to the pelvis by crossing over the anterior surface of the external iliac artery and vein (or slightly higher, at the bifurcation of the common iliac vessels, as often the case with the left ureter). At this point, the ureter is medial to the gonadal vessels and lateral to the internal iliac vessels. The ureters then course through the uterosacral ligament just deep to the uterine vessels in the female before gaining access to the bladder. Due to their course and close proximity to other structures, the ureters are at particular risk of injury during surgery in the pelvis.

(Choice A) As mentioned, the gonadal vessels cross over the ureters on both the right and the left side within the abdominal retroperitoneum before the ureters enter the pelvis. In the male, the gonadal vessels never enter the true pelvis; they course around the pelvic brim before entering the deep ring of the inguinal canal. The ureters enter the true pelvis medial to the ovarian vessels in the female.

(Choice B) The ureters course over the anterior surface of the external iliac artery just after the common iliac artery splits into its internal and external branches (the left ureter more commonly crosses over the common iliac vessels at its bifurcation). After coursing over the common/external iliac artery, the ureter is considered to be in the pelvis and lies medial to the external iliac vessels.

(Choice C) The left ureter lies some distance from the inferior vena cava as the IVC rests on the right half of the vertebral bodies and the abdominal aorta lies on the left half of the vertebral bodies.

(Choice E) In the female, before gaining access to the bladder, the ureter must course within the uterosacral ligament together with the uterine, vaginal, and inferior vesical arteries. The ureter lies medial and deep to the uterine artery within this ligament. The uterine artery then crosses over the anterior surface of the ureter ("water under the bridge") on its way to the uterus.

Educational Objective:
The ureters cross *over* the common/external iliac vessels and *under* the gonadal vessels (and ovarian

2
3
4
5
6
7
8
9
10
11
12
13
14
15
16
17
18
19
20
21
22
23
24
25
26
27
28
29
30
31
32
33
34
35
36
37
38
39
40
41

A 56-year-old male with recent recurrent vomiting and weight loss is found to have a malignancy originating from the third part of the duodenum. Which of the following structures is at greatest risk for direct penetration by tumor?

- A. Common bile duct [12%]
- B. Ureter [5%]
- ✔ C. Superior mesenteric artery [53%]
- D. Portal vein [9%]
- E. Gastroduodenal artery [21%]

Explanation:

User Id: 477875

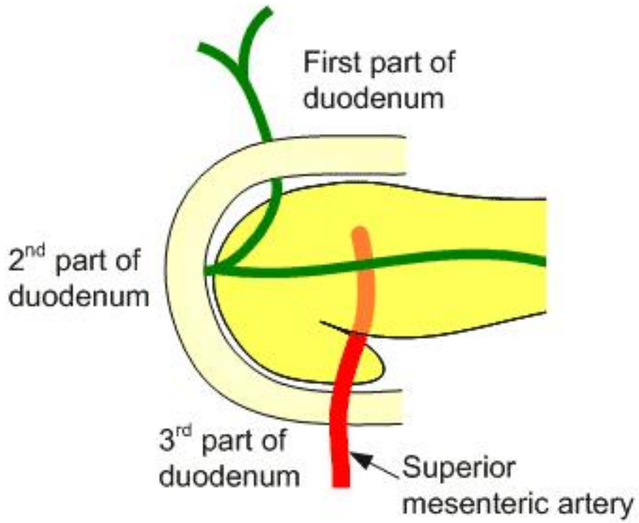

The first part of the duodenum, the portion emerging from the pylorus of the stomach, is horizontally oriented and overlies the first lumbar vertebra. It is the only part of the duodenum that is not retroperitoneal. The second part of the duodenum courses inferiorly from the level of L1 to L3. This part of the duodenum is in close relation to the head of the pancreas. The ampulla of Vater, the site where the pancreatic and common bile ducts provide their secretions, is in the second part of the duodenum. The third part of the duodenum

2
3
4
5
6
7
8
9
10
11
12
13
14
15
16
17
18
19
20
21
22
23
24
25
26
27
28
29
30
31
32
33
34
35
36
37
38
39
40
41

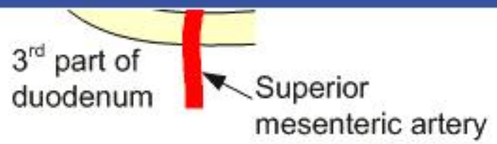

The first part of the duodenum, the portion emerging from the pylorus of the stomach, is horizontally oriented and overlies the first lumbar vertebra. It is the only part of the duodenum that is not retroperitoneal. The second part of the duodenum courses inferiorly from the level of L1 to L3. This part of the duodenum is in close relation to the head of the pancreas. The ampulla of Vater, the site where the pancreatic and common bile ducts provide their secretions, is in the second part of the duodenum. The third part of the duodenum courses horizontally over the third lumbar vertebra, abdominal aorta, and inferior vena cava. It is in close association with the uncinate process of the pancreas and the superior mesenteric artery and vein, which puts these structures at high risk for direct invasion by a tumor in the third part of the duodenum. The fourth part of the duodenum courses superiorly and to the left of the L2 and L3 vertebrae and becomes the jejunum past the ligament of Treitz.

(Choice A) The common bile duct is formed when the common hepatic bile duct and the cystic duct join in the porta hepatis region of the hepatogastric ligament. This common bile duct courses inferiorly, posterior to the pylorus and within the head of the pancreas to drain into the second part of the duodenum.

(Choice B) The left ureter has no relation to the duodenum. The right ureter courses retroperitoneally posterior to the second part of the duodenum for a short length.

(Choice D) The portal vein is formed retroperitoneally, posterior to the pancreas at the level of the first lumbar vertebra, by the fusion of the superior mesenteric and splenic veins. The portal vein is not in contact with the duodenum at any point.

(Choice E) The gastroduodenal artery arises from the common hepatic artery and courses inferiorly, posterior to the first part of the duodenum where it then splits into the anterior superior pancreaticoduodenal artery and the right gastroepiploic artery.

Educational Objective:
The third part of the duodenum courses horizontally across the abdominal aorta and inferior vena cava at the level of the third lumbar vertebra. Here it is in close association with the uncinate process of the pancreas and the superior mesenteric vessels.

Time Spent: 2 seconds

Copyright © USMLEWorld,LLC.

Last updated: [7/7/2010]

2
3
4
5
6
7
8
9
10
11
12
13
14
15
16
17
18
19
20
21
22
23
24
25
26
27
28
29
30
31
32
33
34
35
36
37
38
39
40
41

A 34-year-old male presents to your office complaining of decreased hearing in both ears. He is a rock musician and has been spending a lot of time in his studio recently. Where is the most likely location of ear injury in this patient?

- A. Tympanic membrane [21%]
- B. Middle ear ossicles [12%]
- C. Round window [6%]
- ✔ D. Organ of Corti [52%]
- E. Cupula [3%]
- F. Auditory nerve [5%]

Explanation: **User Id: 477875**

Transduction of mechanical auditory forces into nerve impulses occurs in the organ of Corti by the following steps: 1) Sound reaches the middle ear by vibrating the tympanic membrane. 2) This vibration is transferred to the oval window by the ossicles. 3) Vibration of the oval window causes vibration of the basilar membrane, which in turn causes bending of the hair cell cilia against the tectorial membrane. 4) Hair cell bending causes oscillating hyperpolarization and depolarization of the auditory nerve, thus creating nerve impulses from sound.

Noise-induced hearing loss results from trauma to the stereociliated hair cells of the organ of Corti. Prolonged exposure to noises greater than 85 dB can cause distortion or fracture of the stereocilia due to shearing forces against the tectorial membrane. High-frequency hearing is lost first, regardless of the frequency of the sound causing the damage. Initial damage causes loss of hearing at frequencies of approximately 4000 Hz (speech frequencies = 500-3000 Hz). The acoustic reflex dampens the effects of prolonged loud noise by causing the stapedius and tensor tympani muscles to contract, lessening the responsiveness of the ossicles to sound.

(Choice A) Perforation or rupture of the tympanic membrane can occur with infection, trauma, pressure changes when the eustachian tube is blocked, or sudden very loud noises. Rupture of the tympanic membrane causes conductive hearing loss.

(Choice B) Defects of the middle ear ossicles such as otosclerosis can cause conductive hearing loss

2
3
4
5
6
7
8
9
10
11
12
13
14
15
16
17
18
19
20
21
22
23
24
25
26
27
28
29
30
31
32
33
34
35
36
37
38
39
40
41

Explanation: **User Id: 477875**

Transduction of mechanical auditory forces into nerve impulses occurs in the organ of Corti by the following steps: 1) Sound reaches the middle ear by vibrating the tympanic membrane. 2) This vibration is transferred to the oval window by the ossicles. 3) Vibration of the oval window causes vibration of the basilar membrane, which in turn causes bending of the hair cell cilia against the tectorial membrane. 4) Hair cell bending causes oscillating hyperpolarization and depolarization of the auditory nerve, thus creating nerve impulses from sound.

Noise-induced hearing loss results from trauma to the stereociliated hair cells of the organ of Corti. Prolonged exposure to noises greater than 85 dB can cause distortion or fracture of the stereocilia due to shearing forces against the tectorial membrane. High-frequency hearing is lost first, regardless of the frequency of the sound causing the damage. Initial damage causes loss of hearing at frequencies of approximately 4000 Hz (speech frequencies = 500-3000 Hz). The acoustic reflex dampens the effects of prolonged loud noise by causing the stapedius and tensor tympani muscles to contract, lessening the responsiveness of the ossicles to sound.

(Choice A) Perforation or rupture of the tympanic membrane can occur with infection, trauma, pressure changes when the eustachian tube is blocked, or sudden very loud noises. Rupture of the tympanic membrane causes conductive hearing loss.

(Choice B) Defects of the middle ear ossicles such as otosclerosis can cause conductive hearing loss.

(Choice C) The round window lies between the middle and inner ear and moves outward when the stapes causes the oval window to move inward and vice versa.

(Choice E) The cupula lies at the apex of the cochlea and houses the cells that sense rotation.

(Choice F) The auditory nerve transmits sound impulses to the brainstem via the 8th cranial nerve. Defects in this nerve can result from trauma, mass effect, demyelination, or local inflammatory processes, and can cause nerve-based hearing loss.

Educational Objective:
Prolonged exposure to loud noises causes hearing loss due to damage of the stereociliated hair cells of the organ of Corti.

Time Spent: 9 seconds Copyright © USMLEWorld,LLC. Last updated: [7/7/2010]