Journal of Plastic, Reconstructive & Aesthetic Surgery (2017) **70**, 529—538

JPRAS
An International Journal of Surgical Reconstruction
www.JPRASurg.com

Review

Systematic review of hyperbaric oxygen therapy for the treatment of radiation-induced skin necrosis

Zachary Borab [a], Michael D. Mirmanesh [b,*], Madeleine Gantz [a], Alessandro Cusano [b], Lee L.Q. Pu [b]

[a] *Drexel University College of Medicine, Philadelphia, PA, USA*
[b] *Division of Plastic Surgery, University of California Davis, Sacramento, CA, USA*

Received 23 June 2016; accepted 30 November 2016

KEYWORDS
Hyperbaric oxygen therapy;
Radiation injury;
Radiotherapy;
Soft tissue injury;
Radionecrosis;
Skin necrosis

Summary Every year, 1.2 million cancer patients receive radiation therapy in the United States. Late radiation tissue injury occurs in an estimated 5—15% of these patients. Tissue injury can include skin necrosis, which can lead to chronic nonhealing wounds. Despite many treatments available to help heal skin necrosis such as hyperbaric oxygen therapy, no clinical guidelines exist and evidence is lacking. The purpose of this review is to identify and comprehensively summarize studies published to date to evaluate the effectiveness of hyperbaric oxygen therapy for the treatment of radiation-induced skin necrosis. Adhering to PRISMA guidelines, a systematic review of currently published articles was performed, evaluating the use of hyperbaric oxygen to treat skin necrosis.

Eight articles were identified, including one observational cohort, five case series, and two case reports. The articles describe changes in symptoms and alteration in wound healing of radiation-induced skin necrosis after treatment with hyperbaric oxygen therapy. Hyperbaric oxygen therapy is a safe intervention with promising outcomes; however, additional evidence is needed to endorse its application as a relevant therapy in the treatment of radiation-induced skin necrosis.
© 2016 British Association of Plastic, Reconstructive and Aesthetic Surgeons. Published by Elsevier Ltd. All rights reserved.

* Corresponding author. UC Davis Division of Plastic Surgery, 2221 Stockton Blvd, Room 2125, Sacramento, CA, 95816, USA.
E-mail address: mmirmanesh@ucdavis.edu (M.D. Mirmanesh).

http://dx.doi.org/10.1016/j.bjps.2016.11.024
1748-6815/© 2016 British Association of Plastic, Reconstructive and Aesthetic Surgeons. Published by Elsevier Ltd. All rights reserved.

Contents

Introduction . . . 530
Methods . . . 531
Search strategy . . . 531
Study selection . . . 531
Data extraction and assessment of study quality . . . 531
Analysis . . . 531
Results . . . 531
Literature search . . . 531
Risk of bias . . . 531
Intervention details . . . 532
Outcome assessments . . . 533
Discussion . . . 533
Summary of main results . . . 533
Completeness and applicability of results . . . 534
Agreement with similar studies . . . 534
Implications for future research and practice . . . 535
Preferred treatment strategy . . . 537
Conclusion . . . 537
Funding disclosure . . . 537
Acknowledgments . . . 537
Supplementary data . . . 537
References . . . 537

Introduction

Radiation therapy is used in approximately half of the 1.2 million cases of invasive cancer diagnosed in the United States every year.[1] Although the objective of radiotherapy is to destroy malignant cells, the surrounding normal tissue within the field of radiation can suffer both acute and chronic damage. Acute damage usually resolves after therapy is completed, but chronic damage can develop months or years later and is collectively known as late radiation tissue injury (LRTI). Clinical sequelae of LRTI include soft tissue fibrosis, skin atrophy, epithelial ulceration, skin necrosis, fistula formation, major vessel rupture, and impaired wound healing.[2] Most commonly, LRTI occurs after radiation to the head and neck, breast, chest wall, and pelvic areas as patients with cancer in these sites respond to radiation and are likely to survive longer, thus increasing the window for LRTI to become clinically evident. The incidence of LRTI varies by radiation dosage, patient age, and anatomical site; however, it has generally been shown to affect between 5 and 15% of long time cancer survivors.[3–5]

Existing treatments for LRTI skin necrosis have largely been unsatisfactory. Conservative treatments may include the use topical retinoids, hydrocolloid dressings, tetrachlorodecaoxide dressings, topical thrombocytic growth factors, pentoxifylline, alpha-tocopherol, interferon-gamma, and/or topical superoxide dismutase.[6,7] Surveillance swabs to identify infection also play an important role. Conservative measures may be sufficient for early superficial injury, but their role in LRTI is limited as early surgical intervention is critically important.[7] Surgical excision is the first-line treatment, and options include primary closure and use of local flaps, skin grafts, and microvascular free flaps. Because of the damaged state of the wound bed including increased fibrosis, poor vascularity, and poor granulation tissue formation, there is a high rate of failure when reconstructive technique depends on local blood flow. This may leave patients disfigured and at risk of complications including wound infection and dehiscence due to the poor vasculature of the tissue.[8] Microvascular surgery and replacement of the damaged tissue with distant healthy tissue in the form of a musculocutaneous, fasciocutaneous, or free flap is a treatment route that can help fill the defect but also relies on anastomosing the flap to potentially damaged vessels. This may lead to further complications and is therefore not currently viewed as a first-line option for all patients.[9]

Hyperbaric oxygen therapy (HBOT) is a commonly described adjunctive treatment used for LRTI. The treatment involves breathing in 100% oxygen at pressures greater than 1 atmosphere absolute (ATA) in an airtight chamber. Although the mechanism of action of hyperbaric oxygen in irradiated tissue has not been clearly identified, it is postulated that the resultant increase in local oxygen tension enhances angiogenesis, collagen formation, and antimicrobial defense.[10] HBOT regimens vary, but they are typically administered as follows: the chamber is pressurized to 2.0–2.5 ATA, treatment lasts for 60–120 min, the patient is treated daily for 30–60 sessions, and treatment is continued depending on patient response.[11] Although HBOT has been used for LRTI since 1975, there are very few

clinical studies in the literature that specifically address skin necrosis.[12] "Soft tissue injury" is a descriptor of LRTI that is often used in case series and semi-quantitative reviews; however, outcome measures specifically addressing wound healing in patients with skin necrosis have not been sufficiently studied.

The aim of this study is to provide a thorough analysis of the literature regarding the use of a HBOT regimen for the treatment of LRTI skin necrosis, a complication secondary to cancer treatment, to evaluate healing rates and guide surgeons in HBOT's clinical role, and to propose methods for further investigation.

Methods

Search strategy

This review was conducted according to guidelines set forth in the Preferred Reporting Items for Systematic Reviews and Meta-analysis (PRISMA).[13]

A literature search was conducted to identify all articles involving the use of hyperbaric oxygen to treat radiation-induced skin necrosis. PubMed, MEDLINE via OVID, EMBASE, Web of Science, and Cochrane Central Register of Controlled Trials were searched using the headings and keyword terms: ("Hyperbaric Oxygenation" OR hyperbaric OR hbo OR hbot) AND (Radiotherapy OR radiation OR lrti OR "Radiation Injury") AND ("Soft Tissue Injuries" OR "Therapy, Soft Tissue" OR skin necrosis OR necrosis OR radionecrosis OR radiodermatitis OR "late radiation tissue injury."). Refer to the Appendix for table of complete search strategies. A manual search of relevant articles found from review citations was also performed. The final search was performed in May 2016. In the event that an article was selected for inclusion but raw data was not published, considerable effort was made to contact the corresponding author.

Study selection

Two reviewers (ZB and MM) independently evaluated studies, and a third reviewer (MG) resolved any discrepancies for inclusion. After identifying the relevant studies through title and abstract information, studies were selected for inclusion after full text evaluation. Inclusion criteria were participants with LRTI of skin or cutaneous tissue following cancer treatment; interventions accepted were HBOT regimens (100% oxygen, 2.0—3.0 ATA, 30—120 min, 5—7 times weekly); any comparison group using standard wound care or surgical flaps was accepted. Outcome measures were 1) complete resolution and 2) symptomatic improvement of skin necrosis. Because of the paucity of literature, all study design types were eligible for inclusion in this review. Articles from any country of origin were acceptable but limited to those published in the English language. Exclusion criteria were articles on HBOT that were used to treat other radiation-induced injuries (e.g., bladder, prostate, jaw) that did not stratify skin as a specific treatment area. Additionally, if multiple publications were from the same group, only studies that reported data from nonoverlapping time periods were included.

Data extraction and assessment of study quality

Two authors (ZB and MM) independently extracted data using a template data extraction sheet, with a third (MG) serving as a tiebreaker when consensus was not achieved. Information gathered included study characteristics and patient demographics. Primary outcome was incidence of complete wound healing with intervention and secondary outcome was incidence of symptomatic improvement with intervention. Studies were rated on methodological quality according to the American Society of Plastic Surgery's Levels of Evidence rating scale, and risk of bias for included articles was assessed using the Newcastle—Ottawa quality assessment scale.[14]

Analysis

A detailed narrative systematic review of the included study outcome measures was undertaken. The primary outcome measure was incidence of complete wound healing and secondary outcome measure was symptomatic improvement of skin necrosis symptoms after HBOT. The number of patients recorded at follow-up was used as the denominator instead of the enrollment number. Because of overall study heterogeneity and lack of adequate control groups, a formal statistical meta-analysis was not performed; however, pooled rates of each outcome measure were calculated with the available data from observational studies using Microsoft Excel (Redmond, WA).

Results

Literature search

The primary search resulted in 517 articles. Of those, 125 duplicates were removed, leaving 392 articles. After screening by title and abstract for articles that satisfy the inclusion criteria, 38 articles remained, and full text was reviewed. Of these, eight met the inclusion criteria and were included in this systematic review (Table 1). The PRISMA search flow diagram is presented in Figure 1.

The eight studies (1 uncontrolled observation cohort, 5 case series, and 2 case reports) included 720 patients who received HBOT for radiation-induced skin necrosis.[15—22] Sites of skin necrosis included lower extremity, buttocks, scrotum, abdomen, chest wall, upper extremity, and head and neck. Four of the studies provided the radiation dose details that caused skin necrosis; these ranged from 3000 to 8500 cGy (see Table 2).

Risk of bias

Despite an extensive search, no randomized controlled trials (RCTs) were found. Because of the nature of the study designs, the majority of studies were at high risk for bias. All studies but one were at high risk for observer-expectancy bias.[15] Four studies provided adequate outcome data to be at low risk for attrition bias.[17—19,21] Four studies were at high risk for procedure bias.[15—18] The overall Newcastle—Ottawa quality assessment scale scores are provided in Table 1.

Table 1 Included study characteristics.

References	Study type	Malignancy site	n	Level of evidence[a]	NOS[b]
Niezgoda et al. (2016)	Uncontrolled observational cohort	Various	608	III	6
Feldmeier et al. (1995)	Case series	Chest wall	6	IV	5
Feldmeier et al. (1996)	Case series	Abdomen, pelvic	19	IV	4
Feldmeier et al. (2000)	Case series	Extremities	13	IV	5
Bui et al. (2004)	Case series	H&N, pelvic	14	IV	6
Hampson et al. (2012)	Case series	Various	58	IV	6
Korpinar et al. (2006)	Case report	Pelvic	1	V	4
Uzun et al. (2013)	Case report	Chest wall	1	V	4

H&N = Head and neck.
[a] Assigned using American Society of Plastic Surgery's Levels of Evidence rating scale.
[b] Assigned using Newcastle—Ottawa quality assessment scale.

Intervention details

All the 709 patients included in this study received HBOT. The HBOT regimens were at 2.0—2.4 ATA for 90 min, 5 days per week, with a range of 7—95 sessions and median of 32 sessions per patient (Table 2). Standard wound care was continued in all the studies and included wet-to-dry dressing changes, sharp debridement, antibiotics, and boric acid powder. Once a viable wound base was established, patients either received no further treatment and were allowed to heal by secondary intention or underwent delayed primary closure using various surgical techniques (split-thickness skin grafts, full-thickness skin grafts, local advancement flaps, or artery-based flaps).

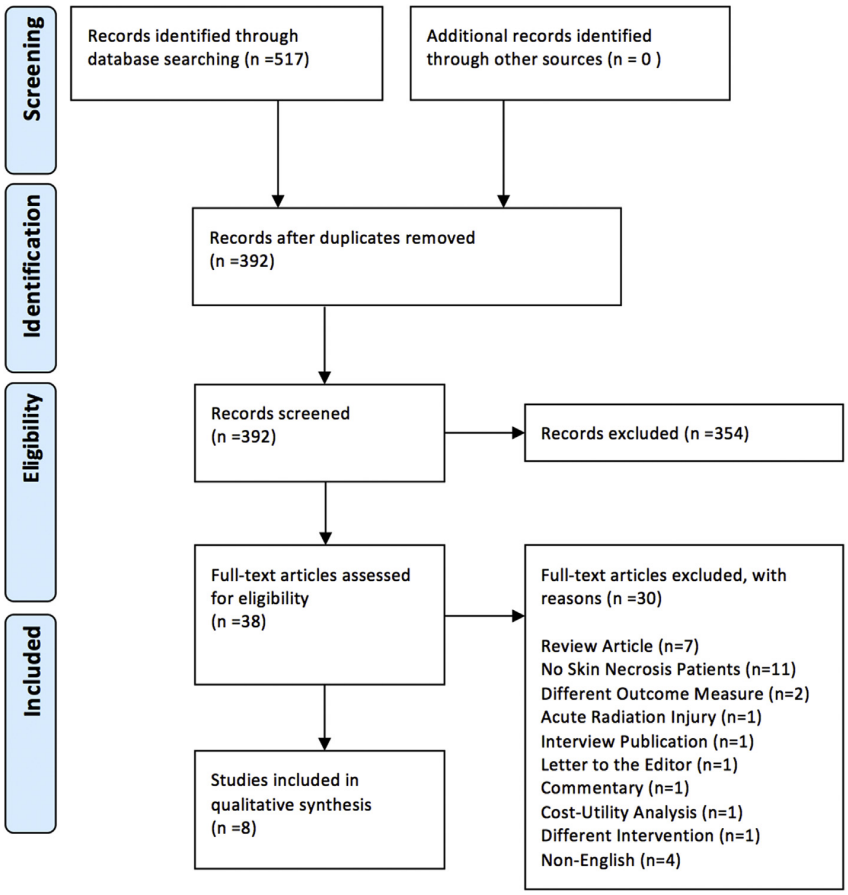

Figure 1 PRISMA flow diagram identifying the included studies.

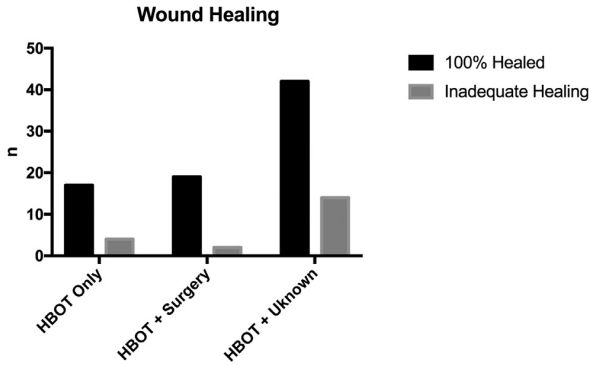

Figure 2 Grouped column chart summary of data pooled from included studies that reported wound healing outcomes. Columns indicate if HBOT was used alone, as an adjunct to surgery, or unknown if not specifically stated in the study. LRTI = late radiation tissue injury; HBOT = hyperbaric oxygen therapy.

Outcome assessments

This review included a total of 720 patients with radiation-induced skin necrosis. Six studies provided the primary outcome measure of interest, i.e., complete wound healing after HBOT (98 patients).[16–20,22] Pooled together, the rate of complete wound healing was 79.6% (78/98) (Figure 2).

Two studies provided the secondary outcome measures of interest, i.e., symptomatic improvement of skin necrosis after HBOT (622 patients).[15,21] Pooled together, the rate of symptomatic improvement was 86% (535/622). Further analysis revealed that the rate of complete resolution of pain symptoms was 30% (187/622), wound healing symptoms was 30% (187/622), and wound drainage symptoms was 39% (243/622).

Discussion

Summary of main results

HBOT appears to increase the capacity of radiation-induced skin necrosis to achieve healing and decrease associated

Table 2 Details of included articles.

References	HBOT intervention	Study strengths	Study weaknesses	Clinical outcome measures
Niezgoda et al. (2016)	2.3 ATA, 90 min, median 30 sessions (range 1–90, IQR 18), mean 2.1 months	Patients specifically stratified to dermal soft tissue radionecrosis, large sample size (n = 608)	No control group, lack of statistical significance, incomplete patient data	Pain relief, improved wound healing symptoms, improved wound drainage
Feldmeier et al. (1995)	2.4 ATA, 90 min, median 25 sessions (range 8–33)	Clearly defines subgroups and surgical intervention, applied RTOG score	No control group	Improved total wound healing
Feldmeier et al. (1996)	2.4 ATA, 90 min, median 31 sessions (range 4–64), 5 per week	Clearly defines subgroups and surgical intervention, applied RTOG score, includes wound measurements	No control group	Improved total wound healing
Feldmeier et al. (2000)	2.4 ATA, 90 min, median 41 Session (range 1–95), daily	Clearly defines subgroups and surgical intervention, includes wound measurements	No control group.	Improved total wound healing
Bui et al. (2004)	2.4 ATA, 100 min, mean 33.1 sessions (range 15–60), 5 per week	Objective measure of symptoms (by questionnaire), applied RTOG score	Retrospective questionnaire recall bias potential, no control group	Improved symptom severity
Hampson et al. (2012)	2.36 ATA, 90 min, mean 42 sessions (range 19–60), 5 per week	Implemented symptom scoring system		Improved total wound healing
Korpinar et al. (2006)	2.0 ATA, 60 min, 57 sessions, 5 days per week	Objective LENT-SOMA score	Small n (n = 1)	Improved LENT-SOMA, transcutaneous oxygen, improved total wound healing
Uzun et al. (2013)	2.4 ATA, 120 min, 40 sessions		Small n (n = 1), subjective outcome measure	Improved total wound healing

ATA = atmosphere absolute; IQR = interquartile range; LENT-SOMA = late effects of normal tissue-subjective, objective, management, analytic; RTOG = Radiation Therapy Oncology Group.

symptoms. Although studies detailing the therapeutic value of HBOT are limited in number and quality, the majority of available literature has reported positive results. This review highlights the outcomes of these articles, which are often excluded from systematic reviews and meta-analysis. Although conclusions cannot be drawn from level III—V evidence, pooled together, these studies portray a sound association between HBOT and radiation-induced skin necrosis wound healing.

Completeness and applicability of results

Six studies reported complete wound healing as the primary outcome measure.[16—20,22] Feldmeier et al. described 23 patients who had radiation-induced chest wall necrosis. Of those patients, six had only soft tissue necrosis, and two of these six (33%) healed with HBOT alone. The other four patients required additional surgical flap coverage but also healed completely.[16] In another article, Feldmeier et al. reported radiation injuries to the abdomen and pelvis. In this series, 19 patients had skin necrosis and received HBOT, and 15/19 (79%) showed complete wound healing. Eleven patients healed without the need for surgical intervention.[17] A third article by Feldmeier et al. described 13 patients who received HBOT for nonhealing necrotic wounds of extremities in previously irradiated fields. The success rate of HBOT was 11/13 (85%), with seven requiring surgical intervention to achieve complete wound healing.[18] Hampson et al. described 58 patients with cutaneous radionecrosis wounds who received HBOT. Two independent physicians graded outcomes with a positive result categorized as resolved (90—100% improved) or significantly improved (50—89%). After HBOT, 76% of the patients had positive results, with 15/58 (26%) resolved and 29/58 (50%) significantly improved. This study did not mention surgical interventions or its role in categorizing complete wound healing.[19] Korpinar et al. reported a case involving a large necrotic abdominal wall wound. After 46 sessions of HBOT, the wound was clean with suitable granulation tissue and was surgically closed without complication.[20] Uzun et al. reported a case of nonhealing skin necrosis of the left scapula that was treated with HBOT for 3 months and ultimately closed in delayed primary fashion.[22]

Two of the studies that reported symptomatic improvement as an outcome measure used two different scoring symptoms, and neither study had a control arm.[15,21] Niezgoda et al. performed a retrospective uncontrolled observational cohort study that included 2358 patients with radiation-induced injuries. Of these, 608 patients had injuries consistent with dermal soft tissue radionecrosis (STRN). The authors reported that 100% of the STRN patients had pain, fistula/wound, and wound drainage symptoms prior to HBOT. They used the symptom score 1 = worse, 2 = no change, 3 = improved, and 4 = resolved. After HBOT, the mean improvement score for STRN was 3.16 ± 0.649, and 86.7% patients had experienced either improved or resolved symptoms; this was a patient-reported scale.[21] Bui et al. described a series of 45 patients who received HBOT for radiation injuries to various tissues. Of these, 14 patients had radiation-induced skin necrosis. The Radiation Therapy Oncology Group (RTOG) criteria were used to measure symptom severity before and after treatment. Of those with skin injury, 8/14 (57%) showed improvement post-HBOT, 5/14 (36%) did not respond to HBOT, and one patient relapsed. In addition, Bui et al. reported that HBOT-related complications were hearing difficulties 10/45 (22%), vision problems 3/45 (6.7%), and epistaxis 1/45 (2.2%). Most of these problems resolved within the duration of the study, although two patients with accelerated cataract formation underwent corrective surgery. This study was limited by a lack of follow-up and relying on telephone to evaluate some patients.[15]

Supplemental information such as surgical intervention before or after HBOT was available only for 50 patients, all in the complete wound healing outcome group. Therefore, of the remaining 670 patients included in this article, it is unknown whether surgical intervention was involved in the healing process. This knowledge is vital to define the role of HBOT as a definitive or adjunctive treatment for LRTI skin necrosis. Moreover, the majority of the included studies were at high risk of procedure bias because patients often received other interventions in addition to HBOT. Growth factors, steroids, diet counseling, smoking counseling, pentoxifylline, and vitamin E were for the most part left uncontrolled, thereby substantially increasing the risk for procedure bias. Because this review was limited to studies that had outcome measures for cutaneous damage and because of a relative paucity in the literature on this subject, we were forced to report using lower quality papers.

Agreement with similar studies

The majority of the HBOT literature is focused on the treatment of radiation injuries in specific anatomic areas. Most often, the subgroups are head and neck, osteoradionecrosis, urinary bladder, bowel, and the broadly defined "soft tissue." In 2016 an update from an earlier Cochrane systematic review and meta-analysis was performed on the subject of HBOT for radiation injuries. This review included 14 RCTs and concluded that HBOT was associated with improved outcomes in LTRI of the head and neck, anus, and rectum but did not show efficacy in neurological tissue. They found that HBOT increases mucosal coverage in osteoradionecrosis of the jaw (risk ratio 1.3; $p = 0.003$) compared with controls. They also showed an increased risk of wound breakdown following surgical intervention without HBOT (risk ratio 4.2; $p = 0.04$). Neither the Cochrane review nor any of the RCTs included LRTI skin necrosis as a tissue subgroup. Thus, they were unable to make a recommendation for skin necrosis treatment.[11] Another systematic review performed by Hoggan et al. included 41 articles. This review had broader inclusion criteria and included six RCTs, four nonrandomized comparative studies, and 30 noncomparative studies. This review found that HBOT may offer clinical benefits for radiation proctitis and LTRI of the head and neck. However, they stressed that the efficacy of HBOT is not equivalent among tissue types.[23]

On clinicaltrials.gov, there are currently seven clinical trials registered that involve HBOT and LRTI; however, none

Table 3 Suggestions to improve future trials.

Domain	Purpose/notes
Study design	
Multicenter RCT	Clear randomization process and double blinding
Population	
LRTI skin necrosis Pts	Clear allocation concealment and blinding. Adequately powered
Intervention Details	
HBOT	2.4 ATA, 90 min, 5 days/wk, >30 sessions
Control	1.1 ATA 90 min, 5 days/wk, >30 sessions
Surgery (yes/no)	Document procedure
Wound Care	Document all
Measures	
Necrosis location	Define anatomic area. Avoid using term "soft tissue"
Radiation Dose	
Time to LRTI	
Necrosis Dimensions	Document length × width × depth
Necrosis severity	RTOG score
LRTI morbidity	LENT-SOMA scale
Complete healing	Use dimensions to provide % healed
Complete Healing	Document time to complete healing and number of HBOT sessions
HBOT complications	Document all and follow-up for resolution
Quality of life	Use validated assessment tool (SF-12 or other)
Evaluation	
Pre-HBOT	Document baseline measures (blinded)
Intra-HBOT	Document any change in measures (blinded)—every 20th session
Post HBOT	Document final measures (blinded)—immediate and at 6 months

RCT = randomized controlled trial; LRTI = late radiation tissue injury; SF-12 = short form health survey 12; RTOG = Radiation Therapy Oncology Group.

of these have outcome measures that quantify skin necrosis healing in the study protocols. Presently, no RCT has tested the efficacy of HBOT in the treatment of LRTI skin necrosis, and no evidence-based protocol has been established.

Implications for future research and practice

Although advances have been made in targeted radiation therapy and the rate of severe adverse effects has decreased, the total number of patients who suffer from these adverse effects remains the same. This is due to an increased number of patients undergoing radiation treatment and is related to longer survival times.[24] As patients are surviving cancer longer, they may begin to reveal the true incidence of LRTI. In addition, the severity of late effects does not correlate with acute skin reaction, and the late effects often serve to limit dose toxicity. The threshold dose of LRTI varies but has been reported at a minimum dose of 6000—8000 cGy, which can be exceeded by standard radiation therapy.[25,26] Future studies need to examine the risk factors associated with the development of LRTI and possible ways to prevent it from occurring. Because radioprotection is not yet perfected, we will need therapies that act to reverse LRTI.

The pathogenesis of LRTI is progressive in nature. Ionizing radiation causes direct and indirect damage to cells within the field. Direct damage to genomic DNA can overcome cellular repair mechanisms, accumulate with mitosis, and eventually lead to cell death. Indirect damage arises from the creation of toxic peroxides and free radicals from the reaction of cellular and interstitial water with radiation.[27] Fibroblasts are also affected by this damage, and their resulting signaling and matrix deposition dysfunction may impair wound healing.[28,29] In the skin, these mechanisms result in dermal fibrosis, fragmentation of elastin fibers, loss of rete pegs, fibrotic changes surrounding arterioles, dehiscence of endothelial cells, and an increased propensity for small vessels to form microthombi.[30] Over time, these changes can lead to the deterioration of the soft tissue by reduction in vascularity and replacement of healthy tissues with dense fibrotic tissue. It is believed that the driver of this process is a lack of oxygen delivery due to a decrease in the number and quality of blood vessels supplying the field. Eventually, a critical point is reached when the tissue cannot maintain any amount of normal function, leading to break down and ulcer formation, often termed "radionecrosis," which can cause extreme local pain. This process can be exacerbated or even uncovered by surgical intervention because of additional interruptions to the blood supply and decreased ability to form granulation tissue.[3]

Despite a lack of high-quality evidence, HBOT has been used for radiation injuries since 1975.[12] The treatment takes advantage of Henry's law, which states the amount of gas dissolved in a liquid is equal to the partial pressure of the gas exerted on the surface of the liquid. Thus, by increasing the partial pressure of oxygen in the chamber, significantly more oxygen can be dissolved in blood (without the aid of hemoglobin), and because it is in the form of a solution, it can reach damaged areas that a red blood cell may not be able to. Although the exact mechanism of action has not been clearly identified, HBOT most likely aids in the process of healing through multiple mechanisms. The steep oxygen gradient from healthy to irradiated tissue and increased inspired oxygen can be a powerful inducer of angiogenesis.[31] HBOT is the only treatment that was proven to increase the number of blood vessels in radiation-damaged tissue. Marx et al. showed increased vascular density in irradiated rabbits treated with HBOT compared to controls.[10] Increased oxygen delivery can also enhance leukocyte function and allow for a boost in wound-healing potential and possible risk reduction in bacterial infection.[32] Study models have

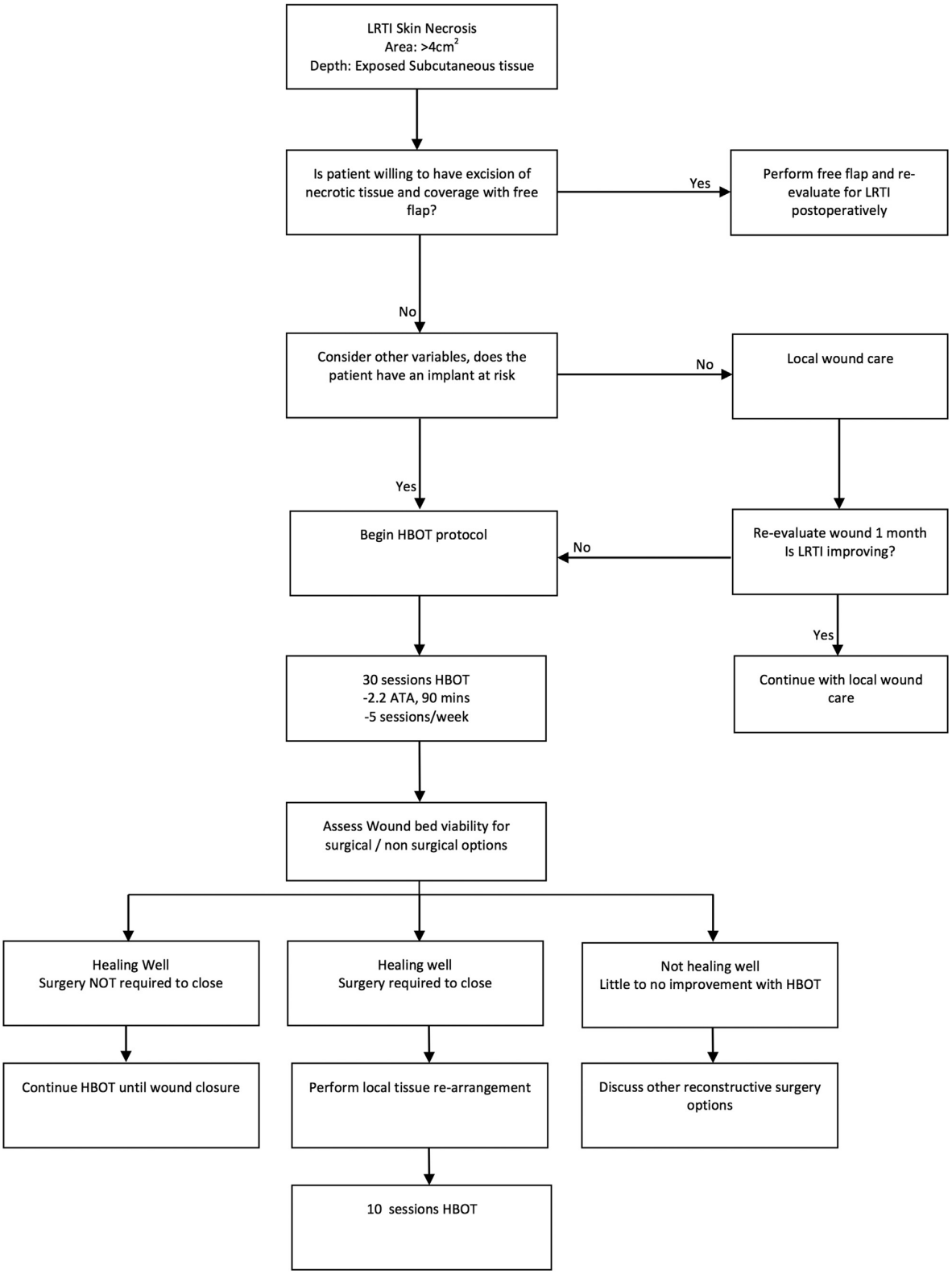

Figure 3 Author's proposed treatment algorithm for late radiation tissue injury with HBOT. LRTI = late radiation tissue injury; HBOT = hyperbaric oxygen therapy.

shown that HBOT can reverse the effects of LRTI by inducing fibroblast proliferation and angiogenesis in a variety of tissues; the exception being neurological tissue, which remained resistant.[10,33] Feldmeier et al. displayed decreased fibrosis in the intestinal wall of irradiated mice treated with HBOT compared to controls.[34]

We have summarized all articles relevant to this topic, with inclusion criteria being necessarily broad to capture all possible articles. With the association between HBOT and LRTI skin necrosis being highlighted, we hope to emphasize that evidence for this subject is minimal and much exploration needs to be undertaken in the future. Further clinical trials with larger recruitment and carefully planned intervention and outcome measures are needed in the future. A well-planned trial as highlighted in Table 3 would be the first of its kind and serve to answer many questions about HBOT and LRTI skin necrosis.

Preferred treatment strategy

The senior author has been treating LRTI skin necrosis with and without HBOT for over 10 years. Although not evidenced based, we have developed a treatment strategy that encompasses the indications for HBOT and a protocol to guide therapy. Indications to begin HBOT largely depend on factors such as the size of the LRTI, the availability and consent for a free flap, and the presence of an implant (Figure 3). Once LRTI skin necrosis is diagnosed and reaches a significant size, the clinician should begin to consider the reconstructive options. If the patient is amenable to undergoing free flap surgery and the surgeon has this technique available as an option, then the damaged tissue should be excised and a healthy recipient vessel should be identified to be anastomosed to an autologous free tissue flap. Because the area in question will be excised in its entirety, there is usually little role for HBOT here. If for some reason free flaps are not an option, then the presence of an implant and its risk for exposure and infection is a factor that should be considered. If an implant is not present, then we proceed with standard local wound care for 1 month. If there is no improvement, then we avail the option to begin adjunctive HBOT for these patients as it is covered by Medicare and most other insurances. However, if an implant is present and is considered to be at risk, we recommend to begin the HBOT protocol immediately. The protocol consists of 30 HBOT sessions with periodic minor debridements, followed by a reassessment of the wound. If significant progress is made and there is a chance for healing by delayed primary intention, then HBOT is continued until wound closure. If after 30 sessions, the wound bed appears healthy but will require local tissue rearrangement to obtain soft tissue coverage, then surgery is planned, performed, and followed by 10 HBOT sessions. Finally, if after 30 sessions the wound looks the same or worse, then the patient should be educated on the necessity of a free flap.

Conclusion

HBOT has been used to treat LRTI skin necrosis despite insufficient evidence for its application. Although it has been proven to be a safe intervention, its efficacy for treating different types of damaged tissue is not consistent. We have reported a general trend of HBOT success for LRTI skin necrosis, but our review is limited by the quality of studies included. A well-designed randomized clinical trial that measures the efficacy of HBOT alone in treating LRTI skin necrosis is needed to validate this intervention and develop an evidence-based protocol.

Funding disclosure

None.

Acknowledgments

None.

Appendix A. Supplementary data

Supplementary data related to this article can be found at http://dx.doi.org/10.1016/j.bjps.2016.11.024.

References

1. Jemal A, Thomas A, Murray T, Thun M. Cancer statistics. *CA Cancer J Clin* 2002;**2002**(52):23—47.
2. Marks JE, Freeman RB, Lee F, Ogura JH. Pharyngeal wall cancer: an analysis of treatment results complications and patterns of failure. *Int J Radiat Oncol Biol Phys* 1978;**4**:587—93.
3. Rubin P. The Franz Buschke lecture: late effects of chemotherapy and radiation therapy: a new hypothesis. *Int J Radiat Oncol Biol Phys* 1984;**10**:5—34.
4. Thompson IM, Middleton RG, Optenberg SA, et al. Have complication rates decreased after treatment for localized prostate cancer? *J Urol* 1999;**162**:107—12.
5. Flannigan RK, Baverstock RJ. Management of post-radiation therapy complications among prostate cancer patients: a case series. *Can Urol Assoc J* 2014;**8**:E632—6.
6. Berger ME, Christensen DM, Lowry PC, Jones OW, Wiley AL. Medical management of radiation injuries: current approaches. *Occup Med (Lond)* 2006;**56**:162—72.
7. Muller K, Meineke V. Advances in the management of localized radiation injuries. *Health Phys* 2010;**98**:843—50.
8. Stone HB, Coleman CN, Anscher MS, McBride WH. Effects of radiation on normal tissue: consequences and mechanisms. *Lancet Oncol* 2003;**4**:529—36.
9. Mulholland S, Boyd JB, Mccabe S, et al. Recipient vessels in head and neck microsurgery radiation effect and vessel access. *Plastic Reconstr Surg* 1993;**92**:628—32.
10. Marx RE, Ehler WJ, Tayapongsak P, Pierce LW. Relationship of oxygen dose to angiogenesis induction in irradiated tissue. *Am J Surg* 1990;**160**:519—24.
11. Bennett MH, Feldmeier J, Hampson NB, Smee R, Milross C. Hyperbaric oxygen therapy for late radiation tissue injury. *Cochrane Database Syst Rev* 2016;**4**. CD005005.
12. Mainous EG, Hart GB. Osteoradionecrosis of the mandible. Treatment with hyperbaric oxygen. *Arch Otolaryngol* 1975; **101**:173—7.
13. Moher D, Liberati A, Tetzlaff J, Altman DG, Group P. Preferred reporting items for systematic reviews and meta-analyses: the PRISMA statement. *Int J Surg* 2010;**8**:336—41.
14. Wells GA, Shea B, D OC. The Newcastle-Ottawa Scale (NOS) for assessing the quality of nonrandomised studies in meta-analyses. 2011.

15. Bui QC, Lieber M, Withers HR, et al. The efficacy of hyperbaric oxygen therapy in the treatment of radiation-induced late side effects. *Int J Radiat Oncol Biol Phys* 2004;**60**:871—8.
16. Feldmeier JJ, Heimbach RD, Davolt DA, et al. Hyperbaric oxygen as an adjunctive treatment for delayed radiation injury of the chest wall: a retrospective review of twenty-three cases. *Undersea Hyperb Med* 1995;**22**:383—93.
17. Feldmeier JJ, Heimbach RD, Davolt DA, et al. Hyperbaric oxygen an adjunctive treatment for delayed radiation injuries of the abdomen and pelvis. *Undersea Hyperb Med* 1996;**23**: 205—13.
18. Feldmeier JJ, Heimbach RD, Davolt DA, et al. Hyperbaric oxygen in the treatment of delayed radiation injuries of the extremities. *Undersea Hyperb Med* 2000;**27**:15—9.
19. Hampson NB, Holm JR, Wreford-Brown CE, Feldmeier J. Prospective assessment of outcomes in 411 patients treated with hyperbaric oxygen for chronic radiation tissue injury. *Cancer* 2012;**118**:3860—8.
20. Korpinar S, Cimsit M, Cimsit B, Bugra D, Buyukbabani N. Adjunctive hyperbaric oxygen therapy in radiation-induced non-healing wound. *J Dermatol* 2006;**33**:496—7.
21. Niezgoda JA, Serena TE, Carter MJ. Outcomes of radiation injuries using hyperbaric oxygen therapy: an observational cohort study. *Adv Skin Wound Care* 2016;**29**:12—9.
22. Uzun G, Candas F, Mutluoglu M, Ay H. Successful treatment of soft tissue radionecrosis injury with hyperbaric oxygen therapy. *BMJ Case Rep* 2013;**2013**.
23. Hoggan BL, Cameron AL. Systematic review of hyperbaric oxygen therapy for the treatment of non-neurological soft tissue radiation-related injuries. *Support Care Cancer* 2014;**22**: 1715—26.
24. Karasawa K. Problems after radiation therapy. *Gan To Kagaku Ryoho* 2014;**41**:27—30.
25. Rosen EM, Fan S, Goldberg ID, Rockwell S. Biological basis of radiation sensitivity. Part 1: factors governing radiation tolerance. *Oncology (Williston Park)* 2000;**14**:543—50.
26. Rosen EM, Fan S, Goldberg ID, Rockwell S. Biological basis of radiation sensitivity. Part 2: cellular and molecular determinants of radiosensitivity. *Oncology (Williston Park)* 2000; **14**:741—57 [discussion 57—8, 61—6].
27. Xu Y, Parmar K, Du F, Price BD, Sun Y. The radioprotective agent WR1065 protects cells from radiation damage by regulating the activity of the Tip60 acetyltransferase. *Int J Biochem Mol Biol* 2011;**2**:295—302.
28. Rudolph R, Tripuraneni P, Koziol JA, McKean-Matthews M, Frutos A. Normal transcutaneous oxygen pressure in skin after radiation therapy for cancer. *Cancer* 1994;**74**:3063—70.
29. Rudolph R, Arganese T, Woodward M. The ultrastructure and etiology of chronic radiotherapy damage in human skin. *Ann Plast Surg* 1982;**9**:282—92.
30. Guelinckx PJ, Boeckx WD, Fossion E, Gruwez JA. Scanning electron microscopy of irradiated recipient blood vessels in head and neck free flaps. *Plast Reconstr Surg* 1984;**74**:217—26.
31. Knighton DR, Silver IA, Hunt TK. Regulation of wound-healing angiogenesis-effect of oxygen gradients and inspired oxygen concentration. *Surgery* 1981;**90**:262—70.
32. Park MK, Myers RA, Marzella L. Oxygen tensions and infections: modulation of microbial growth, activity of antimicrobial agents, and immunologic responses. *Clin Infect Dis* 1992;**14**: 720—40.
33. Hunt TK, Pai MP. The effect of varying ambient oxygen tensions on wound metabolism and collagen synthesis. *Surg Gynecol Obstet* 1972;**135**:561—7.
34. Feldmeier JJ, Jelen I, Davolt DA, et al. Hyperbaric oxygen as a prophylaxis for radiation-induced delayed enteropathy. *Radiother Oncol* 1995;**35**:138—44.