International Journal of Surgery 40 (2017) 1–7

Contents lists available at ScienceDirect

International Journal of Surgery

journal homepage: www.journal-surgery.net

Review

Efficacy and safety of acellular dermal matrix in diabetic foot ulcer treatment: A systematic review and meta-analysis

Xiaoshuang Guo [a, 1], Dali Mu [a, *, 1], Fuqiang Gao [b, 1]

[a] Breast Plastic and Reconstructive Surgery Center, Plastic Surgery Hospital, and the Plastic Surgery Institute, Chinese Academy of Medical Sciences, Peking Union Medical College, 33# Badachu Road, Shijingshan District, 100144, Beijing, People's Republic of China

[b] Department of Orthopedic Surgery, China-Japan Friendship Hospital, 2# Yinghua Dongjie Road, Chaoyang District, 100029, Beijing, People's Republic of China

HIGHLIGHTS

- Acelluar dermal matrix may accelerate the healing velocity of uninfected, non-ischemic, full-thickness diabetic foot ulcer.
- Compared with standard of care, the utility of acellular dermal matrix generates no more complications.
- Acellular dermal matrix is a promising method in treating refractory diabetic foot ulcer.

ARTICLE INFO

Article history:
Received 25 October 2016
Received in revised form
5 February 2017
Accepted 8 February 2017
Available online 14 February 2017

Keywords:
Diabetic foot ulcer
Acellular matrix
Standard of care
Meta-analysis
Randomized controlled trial

ABSTRACT

Background: Diabetic foot ulcer(DFU) is a chronic, refractory disease in need of multidisciplinary endeavour, miscellaneous strategies have been adopted to address this annoying issue, including acellular dermal matrix(ADM)/negative pressure wound therapy/standard of care (SOC) etc. However, consensus has not been reached. As a promising procedure, the efficacy and safety of ADM remains controversial. We therefore performed a meta-analysis of randomized controlled trials (RCTs) to compare the efficacy and safety of acellular dermal matrix to standard of care in DFU.

Methods: Databases, including Pubmed, Medline, Embase and Cochrane library were searched to identify RCTs comparing ADM to SOC in DFU patients. The outcomes mainly included complete wound healing, mean time to heal and adverse events.

Results: A total of 632 DFU patients from 6 RCTs were subjected to meta-analysis. The results showed that compared with the merely SOC, the complete healing rate in ADM group was higher both at 12 weeks [risk ratio (RR) 2.31, 95% confidence interval (CI) 1.42 to 3.76] and 16 weeks [RR 1.57, 95% CI 1.28 to 1.93]. The mean time to complete wound healing was shorter in ADM group [MD = −2.98, 95% CI: −5.15 to −0.82]. The occurrence of adverse event in both groups showed no significant difference [RR 0.98, 95% CI 0.58 to 1.67].

Conclusion: Compared with standard of care, acellular dermal matrix may accelerate the healing velocity of uninfected, non-ischemic, full-thickness diabetic foot ulcer. Acellular dermal matrix showed superiority compared with standard of care alone, while generating no more complications.

© 2017 IJS Publishing Group Ltd. Published by Elsevier Ltd. All rights reserved.

1. Introduction

According to a global estimation, In 2013, 382 million people had diabetes; this number is expected to rise to 592 million by 2035 [1]. The lifetime incidence of DFU, which may cost as much as $28000 at the first 2 years after diagnosis, in patients with diabetes could be as high as 25% [2,3]. DFU is a chronic, refractory and easy-to-recur disease in need of multidisciplinary endeavour. Also, DFU is the principal cause of hospitalization and non-traumatic lower extremity amputation [4]. The subsequent mental impair is also very conspicuous and requires public concern [5].

The standard of care for DFU consists of several conventional

* Corresponding author.
E-mail addresses: gxsinjnu@126.com (X. Guo), doctormu2015@163.com (D. Mu), gaofuqiang@bjmu.edu.cn (F. Gao).

[1] These authors contributed equally to this work and should be considered co-first authors.

http://dx.doi.org/10.1016/j.ijsu.2017.02.008
1743-9191/© 2017 IJS Publishing Group Ltd. Published by Elsevier Ltd. All rights reserved.

treatments, they are sharp debridement, daily wound care dressings, offloading, infection control, glucose control and adequate perfusion [6]. The reported healing rate varied from 20.0% to 46.2% [7,8]. In one meta-analysis, the pooled healing rate of SOC is 24% at 12 weeks [9], which is far from reaching satisfactory expectation. In recent years, several new modalities such as negative pressure therapy, topical therapies, hyperbaric oxygen therapy, growth factors, bioengineered skin substitutes, electrophysical therapy bring about new opportunities for DFU patients, however consensus has not been reached [6]. The reported healing rate using ADM could be up to 80% at 12 weeks [10]. It suggests that ADM may be a promising method for DFU. In recent 2 years, 3 new RCTs published which help us regain a new understanding of this relatively new but not prevalent method. Our cliché on the utility of ADM in DFU may change.

ADM has long been used as soft tissue replacement and commonly be used in the field of wound healing and tissue repair and reconstruction [11]. Extracellular matrix (ECM) is critical in wound healing, as it could provide structural support and signals to modulate cellular responses [12]. Commonly, donor skin is decellularized using a proprietary process, preserving structure and bioactive agents within the dermal matrix that may support host cell repopularization [13]. Possible mechanism may be providing a barrier against contamination, promoting revascularization, increasing cell regeneration, containing moist wound environment [14–17]. Several published articles have evaluated in clinical trials and demonstrated its success in accelerating the healing rate [7,8,17]. Some published articles have already proved its efficacy and safety in third degree burns, scar reconstruction, acute and chronic wounds [17,18]. However, whether ADM is more effective than SOC alone in DFU is still lack of adequate high-level evidence. Thus, we conducted this meta-analysis of RCTs to determine whether ADM is superior to SOC for the DFU. This article does not aim to analyze the difference between various ADM products.

2. Materials and methods

This meta-analysis was performed in accordance with the Preferred Reporting Items for Systematic Reviews and Meta-Analyses (PRISMA) [19] reporting guidelines for the conduct of meta-analysis of intervention trials.

2.1. Search strategy

Pubmed, Medline, Embase and Cochrane library were searched up to August 2016 for comparative studies involving ADM in the management of DFU. The search terms were as follows: “acellular matrix”, “acellular dermal graft tissue”, “decellularized dermal scaffold”, “diabetic foot”, “foot ulcer”, “dysvascular foot”. We only included English-language articles. Reference lists of all eligible studies and relevant reviews were manually searched for any additional trials.

2.2. Inclusion criteria and study selection

We identified RCTs comparing ADM to SOC in DFU. Any type of RCTs consisted of more than 10 participants per group were included. Outcomes included the healing rate, time to heal, wound area reduction and adverse events. Articles that reported at least one outcome were included and those without the outcome measures of interest were excluded. Non-RCT, retrospective studies, letters, comments, editorials and guidelines were excluded.

2.3. Data abstraction and quality assessment

Two authors independently reviewed all titles and abstracts of studies identified by the above searches. Full texts of any potentially useful studies were reviewed, and disagreements were resolved by discussion. Data on patient characteristics (age, wound size, and other baseline characteristics), intervention and outcomes were extracted in duplicate by the two authors, using a standardized form. Data in other forms (i.e. median, interquartile range, mean ± 95% CI, diagram) were converted to mean ± SD according to Cochrane Handbook [20]. If the data were not reported numerically, we extracted them by manual measurements from the published figures.

Two authors independently assessed the risk of bias of the included studies, based on the following items: random sequence generation, allocation concealment, blinding, incomplete outcome data, selective outcome reporting and other sources of bias [20]. Disagreement was resolved by the third author. The quality of evidence of outcomes was judged according to the modified Jadad scale [21]. Two authors independently evaluated five factors (generation of allocation sequence, allocation concealment, investigator blindness, description of withdrawals and drop-outs, efficacy of randomization).

2.4. Statistical analysis

All calculations were performed using Revman 5.3 software. Mean difference (MD) with 95% confidence interval (95% CI) was calculated for the continuous data and risk ratios (RR) with 95% CI for the dichotomous data. Heterogeneity among studies was estimated using I [2] statistic and substantial heterogeneity was represented by an I^2 value > 50%. A fixed effects model was used if the heterogeneity test did not reveal statistical significance ($I^2 < 50\%$, $P > 0.1$). Otherwise, we adopted the random effects model. $P < 0.05$ was considered to be statistically significant. Sensitivity analysis was performed to explore the impact of an individual study by deleting one study each time.

3. Results

3.1. Search results

The initial search yielded 266 citations, of which 7 were excluded due to duplication. After screening the titles and abstracts, 247 studies were excluded based on the inclusion criteria, while 6 studies were excluded after reading the full texts for the following reasons: lack of controlled study [22–24]; retrospective study [25]; SOC is not the control group [26]; skin substitute consisted of cellular components [27]. Finally, 6 RCTs [7,8,17,28–30] involving 632 patients were eligible for data extraction and meta-analysis (Fig. 1). Of these 632 patients, 330 patients belonged to the ADM group and 302 to the SOC group.

3.2. Study characteristics and quality assessment

The characteristics of the included studies are presented in Table 1. The studies were published between 2004 and 2015. A total of 632 DFU patients were performed in the 6 RCTs. The sample size of the studies ranged from 14 to 154 patients. Only one study lasts for 4 weeks, two studies investigated for 12 weeks, while three studies conducted for 16 weeks. All studies compared ADM plus SOC with SOC only. The baseline characteristics between the two groups were well matched in each study.

Five studies [7,8,17,28,29] reported the number of complete wound healing in 12 weeks, one study [30] estimated the possible

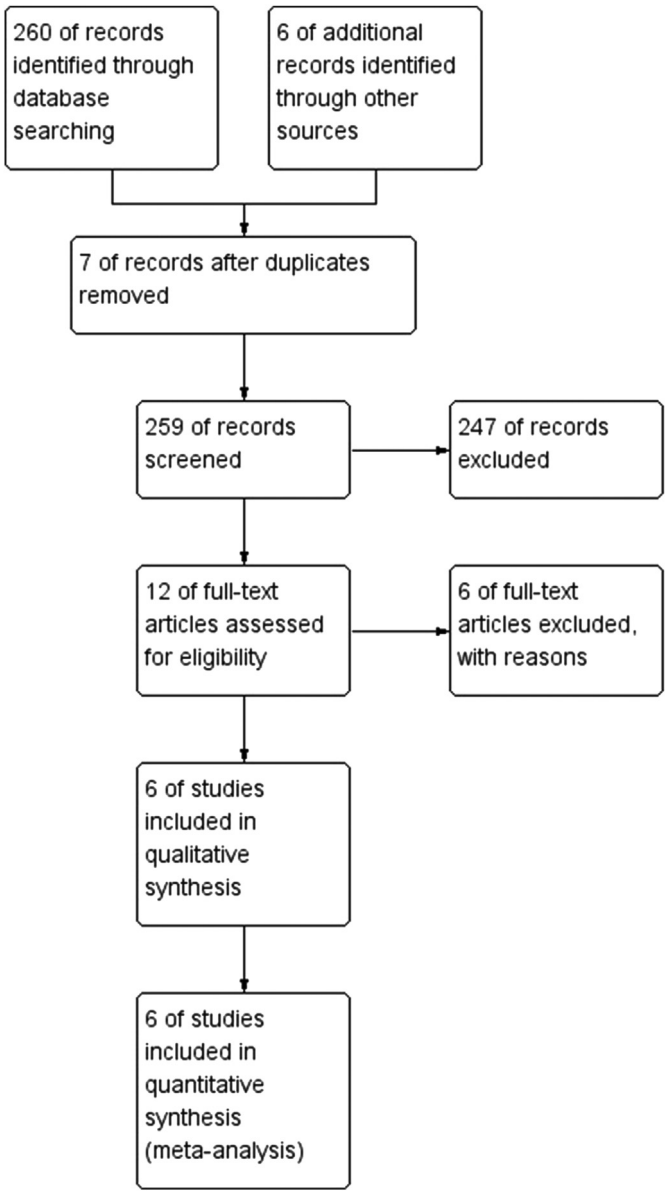

Fig. 1. Study flow diagram.

wound healing in 12 weeks according to the healing rate in the first 4 weeks, three studies [17,28,29] reported the number of complete wound healing in 16 weeks. Time to heal was reported in all studies, but only 4 studies [7,8,29,30]were eligible for meta-analysis. Adverse events such as infection, amputation, seroma were reported in all studies. Outcomes of wound area reduction, healing rate, quality of life were reported, yet these outcomes were not analyzed owing to insufficient data.

Risk of bias in the included studies is shown in Fig. 2. Among the included studies, all were described as being randomized but only one study described the use of paper block system. One study reported allocation concealment. The numbers and reasons for withdrawals and clinically relevant outcomes were reported in all studies. Two studies reported blindness merely to assessors, as the ADM was easily to be recognized during the application by the study stuff. Given the intrinsic characteristic of such RCTs, double blindness was hard to obtain, thus in modified Jadad scoring, blindness does not take into account by rating each study a "2" score.

4. Results of the meta-analysis

4.1. Complete wound healing

Five studies [7,8,17,28,29] with 592 DFUs reported the number of complete wound healing in 12 weeks, one study [30] containing 40 DFUs estimated the possible wound healing in 12 weeks according to the healing rate in the first 4 weeks. The complete healing rate in ADM group was higher than SOC group [risk ratio (RR) 2.31, 95% confidence interval (CI) 1.42 to 3.76; Fig. 3]. Deleting the 4-week study would not change the result of this meta-analysis [RR 1.94, 95% CI 1.26 to 2.98]. There was, however, moderate heterogeneity between studies ($I^2 = 68\%$, $P = 0.01$), thus, random effects model was used.

As to the 16 weeks investigation after treatment consisting of 217 DFUs, there still displayed a conspicuous superiority compared to the SOC group [RR 1.57, 95% CI 1.28 to 1.93; Fig. 4]. As the heterogeneity was limited ($I^2 = 37\%$, $P = 0.21$)), fixed effect model was used.

4.2. Time to heal

All studies reported time to heal, however only 4 studies with 193 DFUs contained suitable data for meta-analysis, while the rest

Table 1
Basic information about included studies; RCT: randomized controlled trail; DFU: diabetic foot ulcer; N: not mentioned; ADM: acellular dermal matrix; SOC: standard of care.

Study	Modified Jadad score	Study design	Study duration (weeks)	Wound	Wound size (cm^2)	Off loading	Treatment	No of patients	Age
Zelen 2016 [39]	9	RCT	12	DFU (University of Texas grade1-2)	4.7 ± 5.2	Yes	ADM(HR-ADM)+SOC	20	61.5
					2.7 ± 2.3	Yes	SOC(alginate + debridement)	20	57.1
Walter 2016 [33]	5	RCT	16	DFU (Wagner ulcer classification 1–2)	3.6 ± 4.2	Yes	ADM(D-ADM)+SOC	52	58.0
					3.3 ± 2.5		ADM(Graftjacket)+SOC	23	58.7
					3.1 ± 3.0		SOC(Advanced moist therapy)	56	57.1
Driver 2015 [5]	9	RCT	12	DFU (Wagner scale 1–2)	3.5 ± 2.5	Yes	ADM(IDRT)+SOC	154	55.8
					3.7 ± 2.7	Yes	SOC(0.9% sodium chloride gel/foam/ gauze + debridement)	153	57.3
Reyzelman 2009 [22]	5	RCT	12	DFU (University of Texas grade1-2)	3.6 ± 4.3	Yes	ADM(Graftjacket)+SOC	47	55.4
					5.1 ± 4.8	Yes	SOC(alginate/hydrocolloids/hydrogel/ foam + debridement)	39	58.9
Brigido 2006 [26]	5	RCT	4	DFU (Wagner scale 2)	N	Yes	ADM(Graftjacket) +SOC	14	61.4
					N	Yes	SOC(Wound gel with gauze dressings + debridement)	14	66.2
Brigido 2004 [21]	5	RCT	16	DFU (Wagner scale 2)	9.7	Yes	ADM(Graftjacket) +debridement	20	55.4
					5.4	Yes	SOC(Wound gel with gauze dressings + debridement)	20	58.9

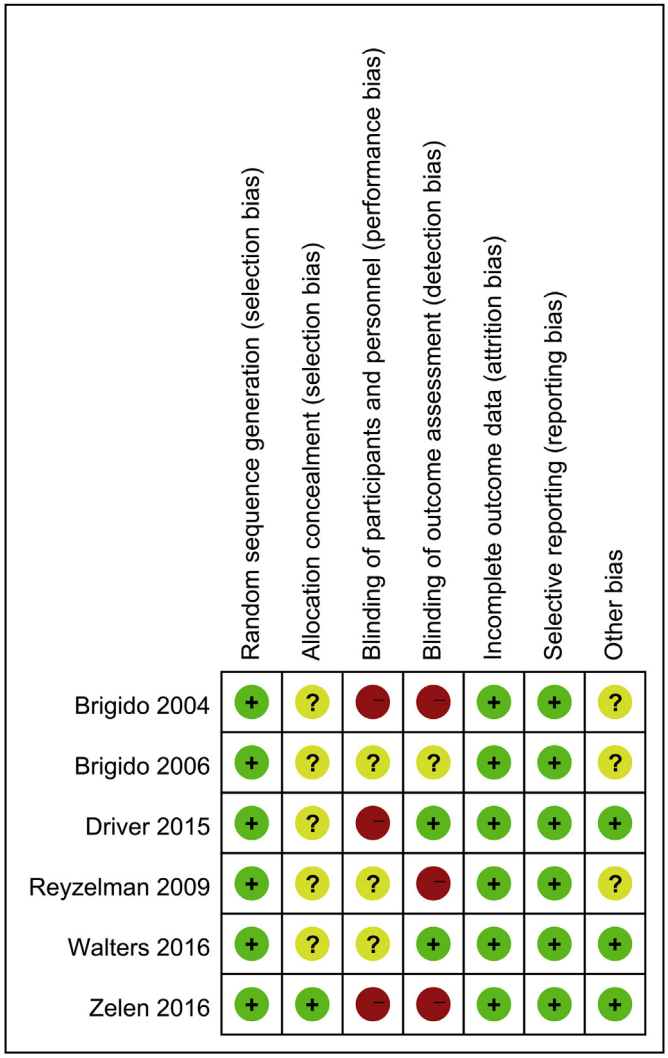

Fig. 2. Risk of bias.

studies were lack of standard deviation. The pooled outcome by using random-effects model yielded an obvious effect in favor of the ADM group [MD = −2.98, 95% CI: −5.15 to −0.82, P = 0.007; Fig. 5]. One study [7] had a great influence on the heterogeneity (before, $I^2 = 77\%$, P = 0.005; after, $I^2 = 50\%$, P = 0.14), after deleting this study, the pooled outcome didn't change too much [MD = −2.04, 95% CI: −3.78 to −0.29, P = 0.02].

4.3. Adverse events

All studies reported the adverse events encountered during the trial. Most of the complications were infection, amputation, seroma, immune response, graft resorption, graft nonintegration, etc. We only pooled the adverse events related to ADM usage and DFU, such as infection, amputation and seroma. There were no significant differences in adverse events between ADM and SOC group during the follow-up ranged from 4 to 16 weeks [RR 0.98, 95% CI 0.58 to 1.67; Fig. 6]. As the heterogeneity was limited ($I^2 = 0\%$, P = 0.91)), fixed effect model was used.

4.4. Healing rate/wound area reduction/quality of life

Two studies reported healing rate [17,30], wound healing rate in ADM group ranged from 3.4 to 7.2% compared with 1.0–4.8% in SOC group. Two studies [28,30] reported wound area reduction, it ranged from 73.1 to 91.4% in ADM group compared with 34.2–80.3% in SOC group. Only one study [17] reported the elevated score of quality of life metrics in ADM group assessed by the Short Form Health Survey.

5. Sensitivity analysis

Sensitivity analysis investigating the influence of a single study on the overall outcome was estimated by omitting 1 study in each turn. Adverse events in the ADM group were not significantly different from that in the SOC group when omitting anyone of the studies. However when removing one study conducted by Zelen [7] and recalculating the remaining study, heterogeneity changed from severe to moderate (before, $I^2 = 77\%$, P = 0.005; after, $I^2 = 50\%$, P = 0.14). The results of sensitivity analysis of complete wound healing, adverse events were not materially differentiated compared with those of the original analysis.

6. Discussion

To our knowledge, this is the first meta-analysis of RCTs comparing the efficacy and safety of ADM in the management of DFU. Six studies satisfied our inclusion criteria. Four studies were multicenter RCTs, two studies were single-center RCTs. Inclusion and exclusion criteria were similar within the included studies. Participants in every study were diabetic foot ulcer with adequate vascular perfusion. All recruited patients had full-thickness ulcer which corresponded to Wagner Grade 2 or University of Texas Grade 1 to 2 and showed no significant healing after conventional treatment for at least 6 weeks before the trial, thus they could be defined as refractory DFU. Infection or ulcer containing the tendon, bone was excluded. Patients in experimental group underwent a

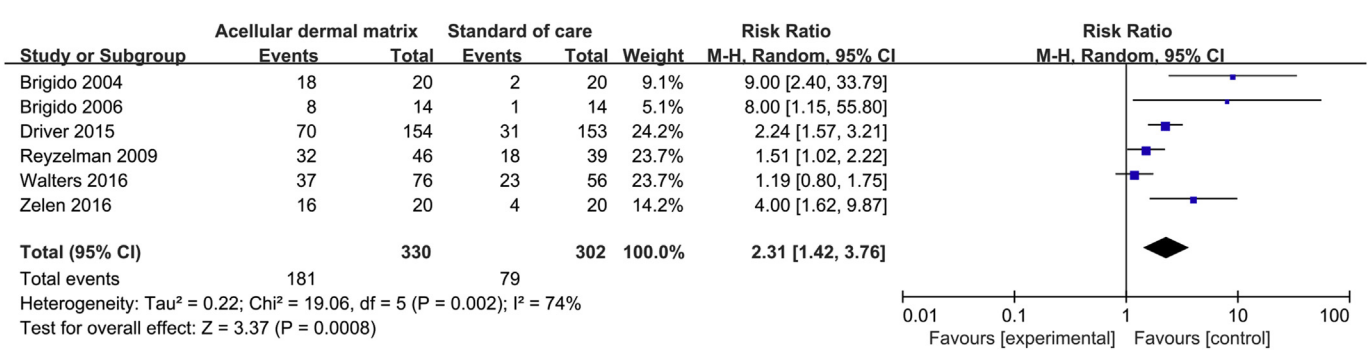

Fig. 3. Complete wound healing at 12 weeks.

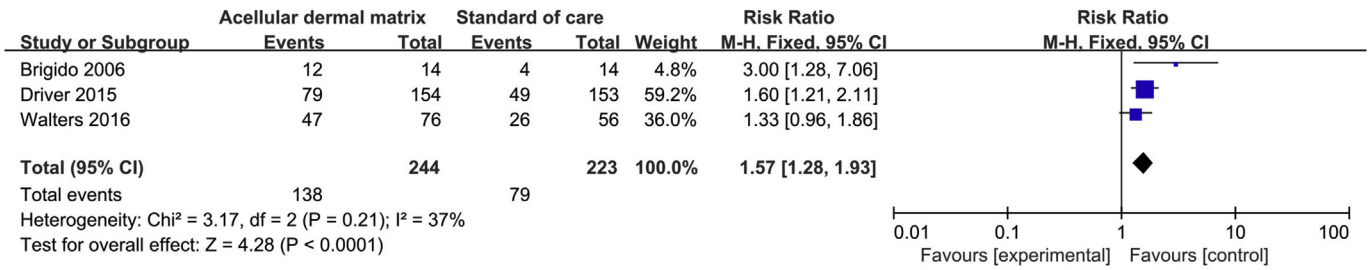

Fig. 4. Complete wound healing at 16 weeks.

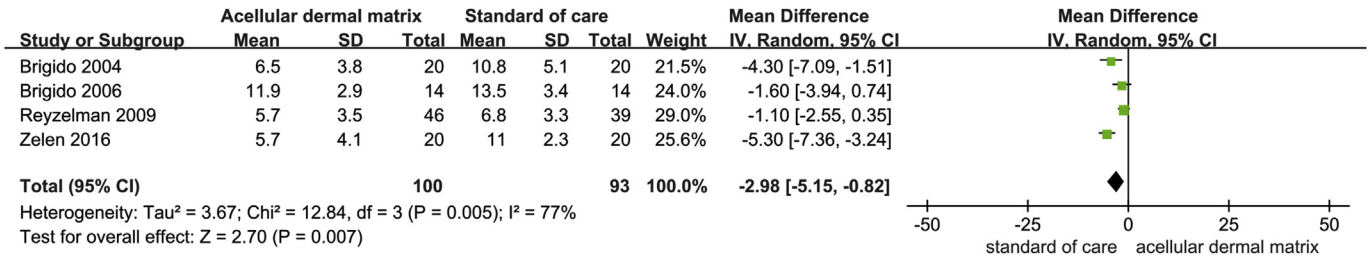

Fig. 5. Time to heal.

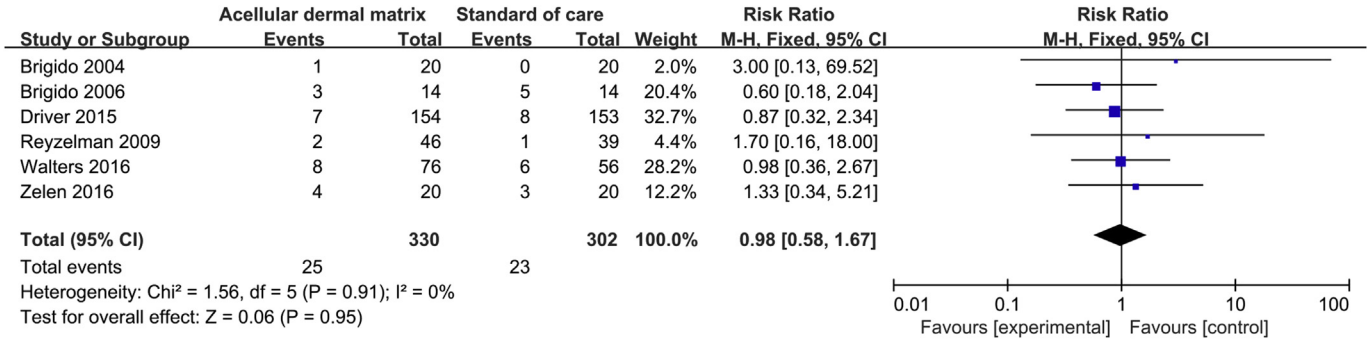

Fig. 6. Adverse event.

specific ADM plus the SOC, while patients in control group received merely SOC. SOC refers to the combination of several routine methods, they were sharp debridement, glucose control, infection control, off-loading, and daily dressing change.

The pooled results indicated that ADM may help accelerating the healing velocity of foot ulcer in patients who have diabetes. The complete wound healing in ADM group is 1.57 times more than SOC group at 16 weeks, and 2.31 times at 12 weeks. Sensitivity assessment implied that elimination of any study would not reverse the original outcome. ADM showed superior advantages to conventional treatment, standard of care, meanwhile, generated no more complications [RR 0.98, 95% CI 0.58 to 1.67]. Many surgeons is not willing to use ADM in case of infection transmission and immunogenicity [31]. However, in this first pooled analysis of adverse event, the ADM group showed no statistic difference compared with SOC group. Additionally, the "time to heal" is reduced by using ADM [MD = −2.56, 95% CI: −3.55 to −1.57, P < 0.001]. Although sensitivity analysis confirmed the stability of the pooled result of "time to heal", when omitting Zelen's [7] study, homogeneity increased considerably. This may be explained by the different duration of the follow-up because the "time to heal" estimation was largely based on the trend of healing rate. The diagram delineated the healing process was in opposite "S" curve, thus the wound healed faster at first and then slowed down. Zelen [7] conducted a 16 weeks trial while the other three studies [8,32,33] included in this analysis only lasted for up to 12 weeks. If we remove the 16-week study, the homogeneity wound increased. However, the 16-week study wouldn't be eliminated, for a prolonged study was more likely to close the reality.

Different commercial products of ADM were included in this meta-analysis, including DermACELL, Graftjacket, Integra Dermal Regeneration Template(IDRT), human reticular acellular dermis matrix(HR-ADM), ADM is human-derived in five studies and animal-derived in one study [17]. If omitting the animal-derived one, human-derived ADM still show superiority to SOC group in complete healing rate at 12 weeks[RR 2.55, 95% CI 1.30 to 4.99] and no difference in adverse event[RR 1.04, 95% CI 0.56 to 1.94]. As all products were manufactured under parallel process and played similar roles in wound healing, they were assessed as a whole.

According to risk of bias and modified Jadad score, the strength of evidence is moderate, as most of the trials related to commercial corporations which may especially reduce the publication of negative outcomes, what's more, blindness of investigator only described in two studies owing to the intrinsic character of such trial——ADM is easily to be found on the wound bed. Except for the blindness, the quality of these clinical trials was well controlled.

Given that the above mentioned two shortcomings could not be easily overcame in recent years, although ranked as moderate, this evidence is still recommendable and could provide meaningful suggestions for clinical treatment of DFU.

Reyzelman A.M. et al. [34] conducted a literature review and analysis of one specific human acellular dermal wound matrix(-Graftjacket) in 2015, three studies containing 154 DFUs were included. On account of insufficient data, merely two assessment indicator—time to heal, proportion of wounds that healed—were analyzed with two studies involved in each one. The pooled average time to heal for ADM group is around 2–7 weeks shorter than that reported by previous retrospective studies [22,25]. Santema T.B. et al. [35] reported a systematic review about skin substitute. Bio-engineered or artificial skin, autografts, allografts or xenografts were defined as skin substitute in this review. 17 studies were included and pooled analysis showed the healing rate was increased and amputation rate was reduced by using skin substitute. As far as I know, although several published articles have proved the advantages of acellular/cellular skin substitute in the healing of DFU [10,27,36,37], they actually acts in different ways not only physically but also biomechanically. ADM is produced by decelluarizing an autologous or xenologous skin and retaining insoluable molecules such as elastin, collagen, fibronectin [13]. It serves as a scaffold and may provide signals that can promote proliferation, cell attachment, migration etc [11,12]. Cellular dermal matrix is usually made up of extracellular matrix, viable cells, growth factors, etc [10,37,38]. Being damaged by consistent inflammation, chronic wound is known to be lack of growth factors, stem cell, proteases etc [39]. Cellular dermal matrix is believed to address this defect. As to clinical application, mostly ADM is used 1 or 2 times, while cellular skin substitute is reported to be 4 to 8 times due to short shelf-life, death of live cell [31,36,40]. In Santema's review, no further information about the difference between cellular and acellular skin substitute was mentioned. Accounting for their difference in physical mechanism and clinical application, it's advisable for us to conduct respective summary. What's more, studies which are pertinent to ADM were not fully included and two new studies published this year.

The present study has some limitations. First, publication bias may be the most important limitation, as majority of the studies were related to corresponding corporations. Second, there was a lack of uniform ADM product, the variation of different kind of dressing products might also be a problem. Third, on behalf of the patients, principal investigators had the right to adopt a second ADM in Walter's [28] study, thus a better outcome may generate. Fourth, the sample size of each included study was relatively small. Fifth, data was insufficient for total analysis. Observation indicators were limited to 16 weeks, with no long-term follow-up. Further studies are needed to clarify the long-term outcomes and recurrence rate. Finally, the cost-efficiency should also take into account, further RCTs about the total expense are needed to illustrate the clinical value of such method.

7. Conclusion

Compared with standard of care, ADM may help accelerating the healing velocity of uninfected, non-ischemic, full-thickness foot ulcer in patients who have diabetes. ADM plus SOC showed superior advantages compared with merely conventional treatment, at the same time, generated no more complications. However, due to the variations and limited statistics in the included studies, more large-sample and high-quality clinical trials and systemic reviews on the cost-efficiency, long-term follow-up are needed in the future to demonstrate the efficacy and safety of ADM in DFU treatment.

Ethical approval

None.

Sources of funding

None.

Author contribution

Xiaoshuang Guo: Main author of this article. She collected and analyzed the data. She wrote the manuscript.

Dali Mu and Fuqiang Gao were involved in the data searching and analyzing process.

Dali Mu: He was the corresponding author.

Conflict of interest statement

None.

Research registration unique identifying number (UIN)

reviewregistry143.

Guarantor

Dali Mu.

References

[1] L. Guariguata, D.R. Whiting, I. Hambleton, J. Beagley, U. Linnenkamp, J.E. Shaw, Global estimates of diabetes prevalence for 2013 and projections for 2035, Diabetes Res. Clin. Pract. 103 (2) (Feb 2014) 137–149.
[2] N. Singh, D.G. Armstrong, B.A. Lipsky, Preventing foot ulcers in patients with diabetes, JAMA 293 (2) (Jan 12 2005) 217–228.
[3] S.D. Ramsey, K. Newton, D. Blough, et al., Incidence, outcomes, and cost of foot ulcers in patients with diabetes, Diabetes Care 22 (3) (Mar 1999) 382–387.
[4] J.B. Rice, U. Desai, A.K. Cummings, H.G. Birnbaum, M. Skornicki, N.B. Parsons, Burden of diabetic foot ulcers for medicare and private insurers, Diabetes Care 37 (3) (2014) 651–658.
[5] K. Winkley, D. Stahl, T. Chalder, M.E. Edmonds, K. Ismail, Quality of life in people with their first diabetic foot ulcer: a prospective cohort study, J. Am. Podiatric Med. Assoc. 99 (5) (Sep-Oct 2009) 406–414.
[6] L.R. Braun, W.A. Fisk, H. Lev-Tov, R.S. Kirsner, R.R. Isseroff, Diabetic foot ulcer: an evidence-based treatment update, Am. J. Clin. Dermatol. 15 (3) (Jul 2014) 267–281.
[7] C.M. Zelen, D.P. Orgill, T. Serena, et al., A prospective, randomised, controlled, multicentre clinical trial examining healing rates, safety and cost to closure of an acellular reticular allogenic human dermis versus standard of care in the treatment of chronic diabetic foot ulcers, Int. Wound J. (Apr 12 2016) 1–9, http://dx.doi.org/10.1111/iwj.12600.
[8] A. Reyzelman, R.T. Crews, J.C. Moore, et al., Clinical effectiveness of an acellular dermal regenerative tissue matrix compared to standard wound management in healing diabetic foot ulcers: a prospective, randomised, multicentre study, Int. Wound J. 6 (3) (Jun 2009) 196–208.
[9] D.J. Margolis, J. Kantor, J.A. Berlin, Healing of diabetic neuropathic foot ulcers receiving standard treatment. A meta-analysis, Diabetes Care. 22 (5) (May 1999) 692–695.
[10] C.M. Zelen, L. Gould, T.E. Serena, M.J. Carter, J. Keller, W.W. Li, A prospective, randomised, controlled, multi-centre comparative effectiveness study of healing using dehydrated human amnion/chorion membrane allograft, bio-engineered skin substitute or standard of care for treatment of chronic lower extremity diabetic ulcers, Int. Wound J. 12 (6) (Dec 2015) 724–732.
[11] L.A. Jansen, P. De Caigny, N.A. Guay, W.C. Lineaweaver, K. Shokrollahi, The evidence base for the acellular dermal matrix AlloDerm: a systematic review, Ann. Plastic Surg. 70 (5) (May 2013) 587–594.
[12] R.S. Kirsner, G. Bohn, V.R. Driver, et al., Human acellular dermal wound matrix: evidence and experience, Int. Wound J. 12 (6) (Dec 2015) 646–654.
[13] T.T. Nyame, H.A. Chiang, D.P. Orgill, Clinical applications of skin substitutes, Surg. Clin. North Am. 94 (4) (Aug 2014) 839–850.
[14] I.V. Yannas, J.F. Burke, Design of an artificial skin. I. Basic design principles, J. Biomed. Mater. Res. 14 (1) (Jan 1980) 65–81.
[15] N.S. Moiemen, E. Vlachou, J.J. Staiano, Y. Thawy, J.D. Frame, Reconstructive surgery with Integra dermal regeneration template: histologic study, clinical evaluation, and current practice, Plastic Reconstr. Surg. 117 (7 Suppl) (Jun

2006) 160S–174S.
[16] R. Stern, M. McPherson, M.T. Longaker, Histologic study of artificial skin used in the treatment of full-thickness thermal injury, J. Burn Care Rehab. 11 (1) (Jan-Feb 1990) 7–13.
[17] V.R. Driver, L.A. Lavery, A.M. Reyzelman, et al., A Clinical Trial of Integra Template for Diabetic Foot Ulcer Treatment, vol. 23(6), Wound Repair and Regeneration: Official Publication of the Wound Healing Society [and] the European Tissue Repair Society, Nov-Dec 2015, pp. 891–900.
[18] D.M. Heimbach, G.D. Warden, A. Luterman, et al., Multicenter postapproval clinical trial of Integra dermal regeneration template for burn treatment, J. Burn Care Rehab. 24 (1) (Jan-Feb 2003) 42–48.
[19] D. Moher, A. Liberati, J. Tetzlaff, D.G. Altman, P. Group, Preferred reporting items for systematic reviews and meta-analyses: the PRISMA statement, PLoS Med. 6 (7) (Jul 21 2009) e1000097.
[20] G.S. Higgins JPT, Cochrane handbook for Systematic Reviews of Interventions Version 5.1.0, 2011.
[21] R. Banares, A. Albillos, D. Rincon, et al., Endoscopic treatment versus endoscopic plus pharmacologic treatment for acute variceal bleeding: a meta-analysis, Hepatology 35 (3) (Mar 2002) 609–615.
[22] B.R. Martin, M. Sangalang, S. Wu, D.G. Armstrong, Outcomes of allogenic acellular matrix therapy in treatment of diabetic foot wounds: an initial experience, Int. Wound J. 2 (2) (Jun 2005) 161–165.
[23] P. Rupert, Human acellular dermal wound matrix for complex diabetic wounds, J. Wound care. 25 (4) (Apr 2016). S17–18, S20-11.
[24] M. Yao, K. Attalla, Y. Ren, M.A. French, V.R. Driver, Ease of use, safety, and efficacy of integra bilayer wound matrix in the treatment of diabetic foot ulcers in an outpatient clinical setting: a prospective pilot study, J. Am. Podiatric Med. Assoc. 103 (4) (Jul-Aug 2013) 274–280.
[25] C.L. Winters, S.A. Brigido, B.A. Liden, M. Simmons, J.F. Hartman, M.L. Wright, A multicenter study involving the use of a human acellular dermal regenerative tissue matrix for the treatment of diabetic lower extremity wounds, Adv. Skin Wound Care 21 (8) (Aug 2008) 375–381.
[26] Z. Hu, J. Zhu, X. Cao, et al., Composite skin grafting with human acellular dermal matrix scaffold for treatment of diabetic foot ulcers: a randomized controlled trial, J. Am. Coll. Surg. 222 (6) (Jun 2016) 1171–1179.
[27] J.S. Steinberg, M. Edmonds, D.P. Hurley Jr., W.N. King, Confirmatory data from EU study supports Apligraf for the treatment of neuropathic diabetic foot ulcers, J. Am. Podiatric Med. Assoc. 100 (1) (Jan-Feb 2010) 73–77.
[28] J. Walters, S. Cazzell, H. Pham, D. Vayser, A. Reyzelman, Healing rates in a multicenter assessment of a sterile, room temperature, acellular dermal matrix versus conventional care wound management and an active comparator in the treatment of full-thickness diabetic foot ulcers, Eplasty 16 (2016) e10.
[29] B. SA, The use an acellular dermal regenerative tissue matrix in the treatment of lower extremity wounds: a prospective 16-week pilot study, Int. Wound J. (3) (2006) 181–187.
[30] RC BSBSL, Effective management of major lower extremity wounds using an acellular regenerative tissue matrix: a pilot study, Orthopedics 27 (2004) s145–s149.
[31] T. Hodgkinson, A. Bayat, Dermal substitute-assisted healing: enhancing stem cell therapy with novel biomaterial design, Archives Dermatol. Res. 303 (5) (Jul 2011) 301–315.
[32] S.A. Brigido, The use of an acellular dermal regenerative tissue matrix in the treatment of lower extremity wounds: a prospective 16-week pilot study, Int. Wound J. 3 (3) (Sep 2006) 181–187.
[33] S.A. Brigido, S.F. Boc, R.C. Lopez, Effective management of major lower extremity wounds using an acellular regenerative tissue matrix: a pilot study, Orthopedics 27 (1 Suppl) (Jan 2004) s145–149.
[34] A.M. Reyzelman, I. Bazarov, Human acellular dermal wound matrix for treatment of DFU: literature review and analysis, J. Wound Care 24 (3) (Mar 2015), 128; 129–134.
[35] T.B. Santema, P.P. Poyck, D.T. Ubbink, Skin grafting and tissue replacement for treating foot ulcers in people with diabetes, Cochrane Database Syst. Rev. 2 (2016) CD011255.
[36] L.A. Lavery, J. Fulmer, K.A. Shebetka, et al., The efficacy and safety of Grafix((R)) for the treatment of chronic diabetic foot ulcers: results of a multicentre, controlled, randomised, blinded, clinical trial, Int. Wound J. 11 (5) (Oct 2014) 554–560.
[37] C.M. Zelen, T.E. Serena, L. Gould, et al., Treatment of chronic diabetic lower extremity ulcers with advanced therapies: a prospective, randomised, controlled, multi-centre comparative study examining clinical efficacy and cost, Int. Wound J. 13 (2) (Apr 2016) 272–282.
[38] A. Veves, V. Falanga, D.G. Armstrong, M.L. Sabolinski, Apligraf Diabetic Foot Ulcer S. Graftskin, a human skin equivalent, is effective in the management of noninfected neuropathic diabetic foot ulcers: a prospective randomized multicenter clinical trial, Diabetes Care 24 (2) (Feb 2001) 290–295.
[39] G.S. Schultz, J.M. Davidson, R.S. Kirsner, P. Bornstein, I.M. Herman, Dynamic Reciprocity in the Wound Microenvironment, vol. 19(2), Wound Repair and Regeneration: Official Publication of the Wound Healing Society [and] the European Tissue Repair Society, Mar-Apr 2011, pp. 134–148.
[40] W.A. Marston, J. Hanft, P. Norwood, R. Pollak, Dermagraft Diabetic Foot Ulcer Study G. The efficacy and safety of Dermagraft in improving the healing of chronic diabetic foot ulcers: results of a prospective randomized trial, Diabetes Care 26 (6) (Jun 2003) 1701–1705.