International Journal of Dermatology

Review

Clinical features of shiitake dermatitis: a systematic review

Austin H. Nguyen[1], MS, Maria I. Gonzaga[2], BS, Victoria M. Lim[1], BS, Michael J. Adler[3], MD, Mario V. Mitkov[4], MD, and Mark A. Cappel[4], MD

[1]Creighton University School of Medicine, Omaha, NE, USA, [2]Department of Biology, Frank R. Seaver College of Science and Engineering, Loyola Marymount University, Los Angeles, CA, USA, [3]Portland Dermatology Clinic, Portland, OR, USA, and [4]Department of Dermatology, Mayo Clinic Florida, Jacksonville, FL, USA

Correspondence
Austin H. Nguyen, MS
Creighton University School of Medicine
2500 California Plaza
Omaha
NE 68102
USA
E-mail: austinhnguyen@gmail.com

Funding: None.

Conflicts of interest: None

Summary

Shiitake dermatitis is a rare cutaneous reaction to lentinan, a polysaccharide component in the cell walls of shiitake mushrooms (*Lentinula edodes*). Herein, we systematically review the case report and case series English-language literature on shiitake dermatitis, which refers to a total of 50 patients (38 males, 12 females; mean age: 44.58 years). The majority of cases occurred after the consumption of raw mushrooms, whereas 22% of cases were caused by the eating of lightly or undercooked mushrooms. The most common clinical presentations, localized symptoms, and systemic findings include linear flagellated dermatitis (98%), pruritus (78%), and fever, diarrhea, and mucosal ulcers, respectively. The diagnosis of this entity continues to be based on clinical findings as laboratory abnormalities, and the findings of skin biopsies and patch/prick tests are nonspecific and inconsistent. The condition is self-limiting, resolving in approximately 12.5 d without treatment. Based on the included case reports, it appears that medical treatment may slightly shorten the course of disease (to 9–11 d, varying by therapy) but should be considered on an individual patient basis. However, the treatment of symptoms, reassurance, and the avoidance of re-exposure are sufficient treatment recommendations for this condition.

Introduction

The shiitake mushroom (*Lentinula edodes*) is the second most commonly consumed mushroom worldwide and has grown to become a globally and extensively used multipurpose ingredient. In Asian cuisine, the shiitake mushroom is consumed fresh, dried, or cooked in a variety of dishes. Shiitake is also consumed in a pickled form. In Eastern alternative medicine, dried shiitake or extracts are thought to help with a host of conditions, including arthralgia, myalgia, fatigue, cardiopulmonary health, and even cancer.[1] However, such effects have varied levels of supporting scientific evidence. According to the US Department of Agriculture, US production of shiitake mushrooms in 2014–2015 amounted to 10.5 million pounds of shiitake mushrooms, representing US$32.6 million of revenue.[2] Evidently, this mushroom is extensively consumed, making associated reactions a public health concern. Because the mushroom is a common ingredient in Chinese and Japanese cuisine, the first documented reactions to these mushrooms were noted in Eastern Asia. However, the adoption of Asian cuisines worldwide has expanded the susceptible population and the subsequent need for awareness of shiitake-induced reactions.

Shiitake mushroom-induced toxicoderma, otherwise known as shiitake dermatitis, presents as a striking flagellate erythematous eruption in susceptible patients after the consumption of large amounts of raw or undercooked shiitake mushrooms. The eruption is believed to be attributable to either a toxic or hypersensitivity response to lentinan, a polysaccharide component found within the mushroom cell wall.[3] Lentinan is heat-labile, and thus eruptions are frequently noted in patients who have consumed inadequately cooked mushrooms. Interestingly, in trials investigating the possible anti-tumor effects of lentinan, nine of 519 patients went on to develop shiitake dermatitis-like cutaneous symptoms,[4] further implicating lentinan as the causative agent of the eruption.

The first case of shiitake dermatitis was noted in 1977 by Nakamura.[5] Since then, varying presentations and manifestations of the disease have been reported. As recent mushroom consumption is an overlooked detail in patient history, shiitake dermatitis is frequently misdiagnosed by any provider unfamiliar with this condition. The disease is self-limiting, and hence diagnostic procedures and treatments may be unnecessary and may even exacerbate symptoms. Herein, we seek to consolidate current understandings of the disease.

Materials and methods

The National Library of Medicine's PubMed database was systematically searched (to July 2015) for articles pertaining

 © 2017 *The International Society of Dermatology*

to the topic of shiitake dermatitis. The search terms used were "shiitake" with "dermatitis" and "toxicoderma". Search results were cross-checked with the Web of Science database using the same search terms. Article titles and abstracts were screened, and the full texts of all possibly relevant articles were retrieved to allow their evaluation for inclusion and the extraction of data. Exclusion criteria denied the inclusion of articles not written in English, conference abstracts, studies not performed in primary human subjects, and studies with inadequate patient data. Articles discussing cases of allergic contact dermatitis in response to shiitake mushroom exposure were not included. Additionally, cases of systemic symptoms (i.e. asthma or gastrointestinal distress) without dermatologic manifestations were not included.

Results

The initial search of PubMed and Web of Science returned 97 articles (Fig. 1). Twenty-nine articles were included, comprising a total of 50 cases of patients with shiitake dermatitis.[4,6–33] Articles consisted of case reports (24 patients) and case series (26 patients). A summary of the study characteristics and patient population pooled for this review is described in Table 1.

Etiology

All included cases resulted after the oral consumption of shiitake mushroom in various forms, including raw ($n = 26$) and lightly or undercooked (including in soups and stir fries, $n = 10$). In three cases, the subjects had not experienced any reactions to the consumption of shiitake mushrooms prior to the reported incident: one case had previously consumed roasted mushrooms, and another reported no reaction after consuming shiitake mushrooms as recently as 2 weeks previously.[6,28] Two cases reported recurring symptoms before diagnosis (at 1 year and 16 years, respectively).[7,9] One subject reported the daily consumption of raw mushrooms for 2 weeks prior to onset.[33] No reports investigated genetic predisposition or familial patterns of shiitake dermatitis (Table 2).

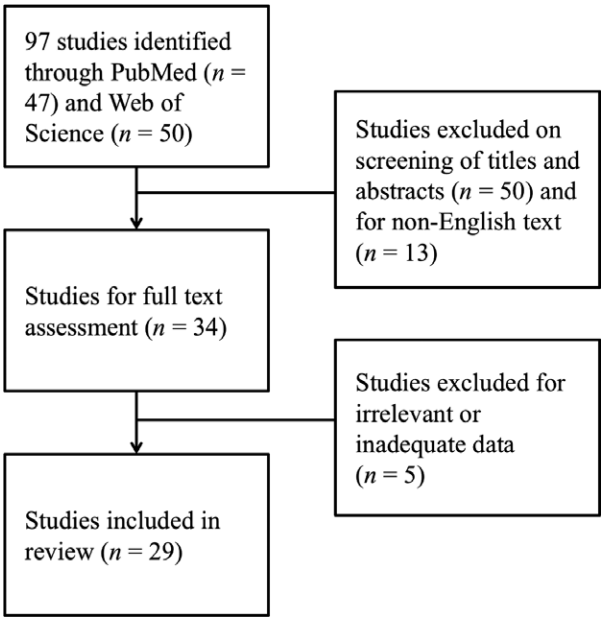

Figure 1 A systematic search of PubMed and Web of Science returned 97 articles. After screening of titles and abstracts and a full text review, a total of 29 articles were included in this review

Demographics

The mean patient age was 44.58 years (range: 25–86 years). Incidence was more common in males at a 3 : 1 ratio (38 males, 12 females). The highest number of cases was reported in France, as documented in a systematic retrospective study on shiitake dermatitis ($n = 15$) carried out through the French Poison Control Centers.[22] Other countries with high numbers of cases included the USA ($n = 9$), Germany ($n = 8$), and the UK ($n = 6$). Asian cases are likely to be under-represented because non-English-language articles were excluded from this review (Table 1).

Clinical presentation

The classically associated linear flagellate dermatitis was present in 98% of cases. The majority of lesions were described as papular or urticarial (80%), with 78% of cases having associated pruritus. Additional signs included associated petechiae (14%) or purpura (2%), plaques (6%), burning sensation (2%), blanching (2%), and pustules (2%). Interestingly, one case (2%) was

Table 1 Study characteristics ($n = 29$)

Country	Studies, *n* (cases, *n*)
Austria	1 (1)
Brazil	2 (2)
China	1 (1)
Czech Republic	1 (1)
France	3 (17)
Germany	6 (8)
Italy	1 (2)
Japan	1 (1)
Poland	1 (1)
Singapore	1 (1)
United Kingdom	6 (6)
United States	5 (9)
Study design	
Case reports	24 patients
Case series	5 (2, 3, 3, 3, 15 patients)
Demographics ($n = 50$)	
Total patients, *n*	50
Male, *n* (%)	38 (76.0%)
Age, years, mean (range)	44.58 (25–86)

© 2017 The International Society of Dermatology

13654632, 2017, 6, Downloaded from https://onlinelibrary.wiley.com/doi/10.1111/ijd.13433 by University Of Toronto Libraries, Wiley Online Library on [06/07/2023]. See the Terms and Conditions (https://onlinelibrary.wiley.com/terms-and-conditions) on Wiley Online Library for rules of use; OA articles are governed by the applicable Creative Commons License

described as morbilliform in presentation. Systemic signs and symptoms were less common and included fever (6%), diarrhea (4%), paresthesia of the hands (2%), urticarial dermographism (2%), mouth ulcer/mucosal involvement (4%), dysphagia (2%), and conjunctivitis (2%).

Nearly all cases involved the trunk, and the majority of patients had upper and/or lower limb involvement (70% and 66%, respectively). Involvement of the face and neck was less common (22% and 12%, respectively), and only two or three cases involved the hands and feet. The average time to onset of symptoms was 42.4 h (range: 2–120 h) after the consumption of shiitake mushrooms (Table 2).

Workup

Biopsy was performed in 19 cases (Table 3). Histologic examination generally consisted of spongiosis, with dermal edema and occasional hyper- or parakeratosis. Lymphocytic perivascular infiltration (with occasional lymphocytic exocytosis) was generally seen with eosinophils and occasionally neutrophils. Keratinocyte necrosis was seen in a minority of cases. Interestingly, one case was uniquely described as lichenoid eczematous dermatitis.

Laboratory workup was performed in nearly half of cases ($n = 22$). Of note, three patients presented with blood cell count abnormalities, including eosinophilia ($n = 2$), neutrophilia ($n = 2$), and leukocytosis ($n = 1$). Additionally, values that were elevated included those for C-reactive protein (CRP) ($n = 2$), serum immunoglobulin E (IgE) ($n = 3$), and lactate dehydrogenase ($n = 1$). Specific tests for allergy were not frequently performed. Skin tests were inconsistent indicators of shiitake dermatitis: patch testing demonstrated one positive result of the two performed, and prick testing demonstrated two positive results of the four performed. Oral rechallenge induced symptoms in all patients tested ($n = 3$).

Table 2 Characteristics of clinical presentations of shiitake dermatitis

Exposure to mushrooms ($n = 46$), n (%)	
Raw	26 (56.5%)
Lightly or undercooked	10 (21.7%)
Powder (medicinal)	1 (2.2%)
Large amount	2 (4.3%)
Log-grown	1 (2.2%)
Dried	4 (8.7%)
Time to onset, h, ($n = 43$) mean (range)	42.4 (2–120)
Cutaneous manifestations ($n = 50$), n (%)	
Flagellate/linear	49 (98.0%)
Urticarial papules	40 (80.0%)
Pruritus	39 (78.0%)
Petechiae	7 (14.0%)
Plaques	3 (6.0%)
Distribution ($n = 50$), n (%)	
Back	45 (90.0%)
Abdomen/chest	43 (86.0%)
Upper extremity	35 (70.0%)
Lower extremity	33 66.0%)
Face	11 (22.0%)
Neck	6 (12.0%)
Hands	3 (6.0%)
Feet	2 (4.0%)

n-values represent cases for which adequate data were reported.

Treatment

In general, shiitake dermatitis was self-limiting, and treatment was focused on symptomatic management. A total of 31 patients were prescribed corticosteroids (topical, $n = 14$; systemic, $n = 8$; not all studies specified which), and 21 patients received antihistamines. Of those receiving treatment, 13 cases were reported to have no relief of symptoms, and one patient reported worsening of symptoms.[17] Twelve patients received no treatment. Other treatment approaches included polidocanol and psoralen ultraviolet A (PUVA) therapy. One patient attempted treatment with valacyclovir without relief, prior to a diagnosis being established. Treatment modality was not reported in two cases. All cases resulted in complete resolution (two cases did not report outcomes or were lost from follow-up) within an average of 10.74 d (range: 2–35 d; adequate data in 37 cases). The average time to resolution in cases not receiving treatment was 12.5 d (range: 7–28 d; $n = 8$). In subjects receiving steroid monotherapy, the average time to resolution was 11.2 d (range: 2–35 d; $n = 19$) in patients receiving topical formulations and 9.3 d (range: 7–14 d; $n = 4$) in those receiving systemic steroids. The mean time to resolution in subjects receiving antihistamine and steroid combination therapy was 10.4 d (range: 2–21 d; $n = 17$). No cases reported antihistamine monotherapy.

Table 3 Histology and management of shiitake dermatitis

	***n* (%)**
Biopsy findings ($n = 19$)	
Lymphoid infiltrate	17 (89.5%)
Eosinophils	12 (63.2%)
Epidermal spongiosis	11 (57.9%)
Dermal edema	11 (57.9%)
Hyper-/parakeratosis	6 (31.6%)
Lymphocyte exocytosis	5 (26.3%)
Neutrophils	3 (15.8%)
Keratinocyte necrosis	3 (15.8%)
Management ($n = 47$)	
No treatment given	12 (25.5%)
Worsening or no relief with treatment	14 (40.0%)[a]
Corticosteroid	31 (88.6%)[a]
Antihistamine	21 (60.0%)[a]

[a]Of those given treatment ($n = 35$).

© 2017 *The International Society of Dermatology*

13654632, 2017, 6, Downloaded from https://onlinelibrary.wiley.com/doi/10.1111/ijd.13433 by University Of Toronto Libraries, Wiley Online Library on [06/07/2023]. See the Terms and Conditions (https://onlinelibrary.wiley.com/terms-and-conditions) on Wiley Online Library for rules of use; OA articles are governed by the applicable Creative Commons License

Discussion

The overall clinical picture of shiitake dermatitis is fairly consistent. The condition presents approximately 40 h after the consumption of shiitake mushrooms with pruritic, linear, erythematous, urticarial papules and plaques (flagellate erythema), and the subsequent development of linear gray–brown patches (flagellate hyperpigmentation) (Fig. 2). The differential diagnosis primarily includes bleomycin-induced flagellate hyperpigmentation and dermatomyositis flagellate erythema. However, manifestations can vary in presentation and may also include phytophotodermatitis, digitate dermatosis and, rarely, morbilliform drug eruption.[16]

Shiitake dermatitis occurs in a unique clinical setting in which presumably genetically susceptible individuals are exposed to large amounts of uncooked or undercooked mushrooms: a total of 36 of the eruptions included in our review material occurred in this setting.[6,7,12,14–16,18–23,26,30,33] This introduces the concept that inadequate cooking is a possible determinant of the occurrence of shiitake dermatitis. Shiitake mushrooms contain a β-glucan in their cell walls called lentinan, which is heat-labile.[3] Further experiments have substantiated this theory, demonstrating a cutaneous response to the consumption of shiitake mushrooms cooked at 100 °C but not to those cooked at 150 °C, a finding that associates the inherent properties of lentinan with the clinicopathologic features of shiitake dermatitis.[26]

Some authors claim that lentinan produces a predictable and dose-dependent response, representing a toxic mechanism,[4,9,34] whereas others postulate an unpredictable, immune-mediated response, occurring in genetically predisposed individuals, independently of dose, representing a hypersensitivity mechanism.[26,28] In support of the hypersensitivity theory, Corazza *et al.*[26] demonstrated positive patch testing in a patient previously diagnosed with shiitake dermatitis using mushrooms cooked at 100 °C for 15 min, an irreproducible result when performed in five healthy, unsensitized volunteers.

Figure 2 Shiitake dermatitis. Typical presentations of flagellate dermatitis occurring after the consumption of shiitake mushrooms. (Courtesy of Michael J. Adler, MD)

13654632, 2017, 6, Downloaded from https://onlinelibrary.wiley.com/doi/10.1111/ijd.13433 by University Of Toronto Libraries, Wiley Online Library on [06/07/2023]. See the Terms and Conditions (https://onlinelibrary.wiley.com/terms-and-conditions) on Wiley Online Library for rules of use; OA articles are governed by the applicable Creative Commons License

Conversely, the fact that this rash usually occurs after the ingestion of large amounts of raw mushroom and not after limited exposures suggests that there may be a dose-dependent effect, which is consistent with a toxic mechanism.[7,18,19,28] However, we favor a hypersensitivity reaction and postulate that genetically susceptible individuals with certain human leukocyte antigen (HLA) alleles require exposure to large amounts of lentinan in order to be sensitized. This phenomenon has been noted in the sensitization process of individuals using squaric acid, in which the cutaneous hypersensitivity reaction has been found to be dose-dependent.[35] Furthermore, recent studies have identified certain HLA alleles and cytokine profiles that render hosts prone to producing cutaneous hypersensitivity responses to given antigens.[36,37] Although no specific HLA allele(s) have been identified in those who mount a hypersensitivity response to shiitake mushrooms, it is plausible to infer that an association may exist.

Lentinan has also been shown to induce interleukin-1 (IL-1), IL-2, and tumor necrosis factor-α (TNF-α) secretion, nitric oxide release, vasodilation, and hemorrhage, skewing the immune system towards a Th1-type response.[38–43] Rats treated with oral lentinan for 4 weeks exhibited a significantly higher T cell level, helper T cell level and helper to suppressor T cell ratio, and a significantly lower suppressor T cell level than did the control group.[44] Lentinan has also been studied as adjuvant therapy for immune stimulation in cancer patients. Treatment of digestive cancer patients with lentinan increased blood CD4+ interferon-γ+ (IFN-γ+) T cell percentages, while decreasing levels of IL-4 and IL-6 expressing T cells.[45] These immune-modulating properties of lentinan are suggestive of a Th1 hypersensitivity mechanism underlying shiitake dermatitis (Fig. 3).

The distribution of linear, flagellate papules and vesicles is likely to be Koebner-induced,[34] a phenomenon characterized by the reproduction of lesions after trauma to the skin. Although

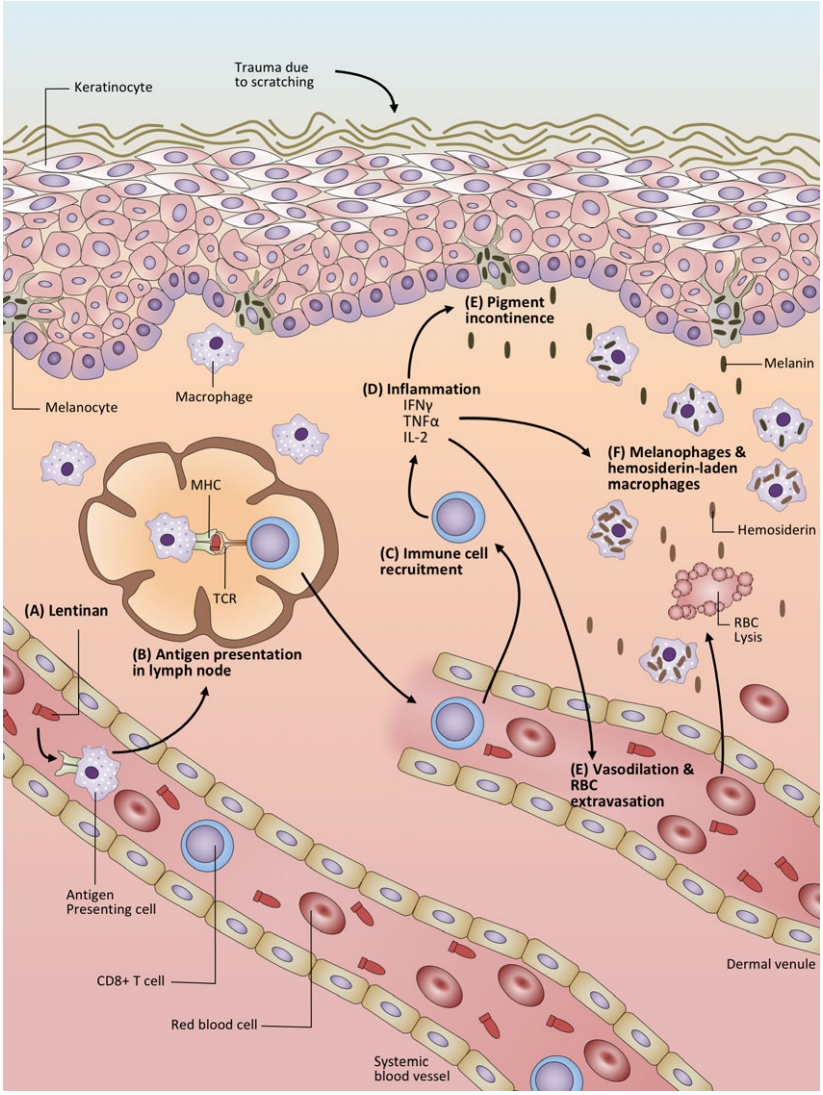

Figure 3 Proposed mechanism of Th1-type hypersensitivity induced by lentinan in shiitake dermatitis. At (a), high levels of ingested lentinan enter the bloodstream, where lentinan becomes bound to macrophages via MHC-1. (b) The macrophage–MHC-1–lentinan complex migrates to lymph nodes, in which lentinan is presented to CD8+ T lymphocytes, which then (c) become activated and enter circulation. CD8+ lymphocytes home to sites of cutaneous scratching and trauma, where they (d) secrete interferon-γ (IFN-γ), tumor necrosis factor-α (TNF-α), and interleukin-2 (IL-2) through a Th1-mediated inflammatory cascade, which further propagates dermal inflammation. (e) The Th1 inflammatory cascade, together with cutaneous trauma and scratching, induce vasodilation, red blood cell extravasation, and dropout of melanin from the basal layer of the epidermis (pigment incontinence). (f) During the post-inflammatory resolution phase, macrophages engulf extracellular melanin and hemosiderin, the manifestation of which corresponds to the clinical brown–gray flagellate pigmentation of shiitake dermatitis

 © 2017 *The International Society of Dermatology*

13654632, 2017, 6, Downloaded from https://onlinelibrary.wiley.com/doi/10.1111/ijd.13433 by University Of Toronto Libraries, Wiley Online Library on [06/07/2023]. See the Terms and Conditions (https://onlinelibrary.wiley.com/terms-and-conditions) on Wiley Online Library for rules of use; OA articles are governed by the applicable Creative Commons License

some reports were unable to reproduce lesions by scratching,[9] Ade *et al.*[28] were able to clearly demonstrate the cutaneous reproduction of patients' initials 44 h after rechallenge with mushrooms, without the involvement of protected skin. Ade *et al.*[28] proposed that timing is a critical element and that the most intense eruptions occur while scratching during periods of high lentinan serum levels. Furthermore, minor trauma, such as scratching, is thought to increase vascular permeability. Together with high serum levels, this could allow greater cutaneous lentinan deposition and thus leukocyte activation and inflammation in these areas.[46] The residual post-inflammatory hyperpigmentation is thought to result from superficial dermal deposition of melanin (pigment incontinence from the epidermis) and hemosiderin (red blood cell extravasation from inflamed blood vessels).[28] This is also consistent with proposed mechanisms of bleomycin-induced flagellate erythema.[46]

Treatment of shitake dermatitis is focused on symptom management, although simple reassurance without treatment is likely to be sufficient in most cases. In fact, 28% of the patients referred to in the present review material reported no alleviation of symptoms with treatment and even the worsening of symptoms in one case. Treatment generally consisted of antihistamines and topical steroids, although systemic steroids may be considered. Based on the case reports included, it appears that the average time to clearance is shorter in patients treated with systemic steroids (9.3 d; range: 7–14 d) compared with patients who receive no treatment (12.5 d; range: 7–28 d). However, this has not been substantiated by controlled trials, and these reports are not sufficiently powered to warrant the recommendation of systemic steroids in all patients with shiitake dermatitis. Therapy options should be tailored on a case-by-case basis, and systemic steroids should be regarded as an option for patients with the most severe symptoms. Interestingly, Scheiba *et al.*[12] reported the use of balneo–PUVA therapy in a patient presenting with shiitake dermatitis. Complete resolution was seen at 10 d after ingestion (4–5 d after the initiation of therapy). In the context of the average of 10.74 d (range: 2–35 d) to resolution identified in the present review, the benefits of the use of PUVA therapy in the treatment of shiitake dermatitis are unclear.

Conclusions

Shiitake dermatitis is a rare condition presenting with pruritic, linear, erythematous, urticarial papules and plaques approximately 40 h after the ingestion of large amounts of raw shiitake mushrooms, which resolves with flagellate hyperpigmentation. It is thought to be caused by a hypersensitivity reaction to lentinan, contained in shiitake mushrooms. Generally, the findings of laboratory studies are not significant and are nonspecific. Biopsy is generally not necessary as a thorough evaluation of patient history and physical examination are sufficient for clinical diagnosis. The condition is self-limiting, although treatment with steroids and antihistamines may expedite the course of disease and/or alleviate symptoms.

References

1 Money NP. Are mushrooms medicinal? *Fungal Biol* 2016; **120**: 449–453.
2 US Department of Agriculture National Agricultural Statistics Service. *Mushrooms*. Washington, DC: USDA NASS 2015.
3 Wang X, Xu X, Zhang L. Thermally induced conformation transition of triple-helical lentinan in NaCl aqueous solution. *J Phys Chem B* 2008; **112**: 10343–10351.
4 Hanada K, Hashimoto I. Flagellate mushroom (shiitake) dermatitis and photosensitivity. *Dermatology* 1998; **197**: 255–257.
5 Nakamura T. Toxicoderma canned by shiitake (lentinus edodes). *Japanese Journal of Clinical Dermatology* 1977; **31**: 65–68.
6 Lippert U, Martin V, Schwertfeger C, *et al.* Shiitake dermatitis. *Br J Dermatol* 2003; **148**: 178–179.
7 Mak RKH, Wakelin SH. Shiitake dermatitis: the first case reported from a European country. *Br J Dermatol* 2006; **154**: 800–801.
8 Soo JK, Pearson IC, Misch KJ. A case of flagellation. *Clin Exp Dermatol* 2007; **32**: 339–340.
9 Garg S, Cockayne SE. Shiitake dermatitis diagnosed after 16 years!. *Arch Dermatol* 2008; **144**: 1241–1242.
10 Carlson S, Stuckert J, Nedorost S. Shiitake mushroom dermatitis. *Dermatitis* 2010; **21**: 290–291.
11 Girard C, Bessis D. Flagellate dermatitis. *Arch Dermatol* 2010; **146**: 1306.
12 Scheiba N, Andrulis M, Helmbold P. Treatment of shiitake dermatitis by balneo PUVA therapy. *J Am Acad Dermatol* 2011; **65**: 453–455.
13 Loo HV, Oon HH. Flagellate dermatitis following consumption of shiitake mushroom. *Dermatol Rep* 2011; **3**: 47–48.
14 Talour K, Abasq C, Sassolas B, *et al.* DRESS-like syndrome induced by shiitake mushroom. *Eur J Dermatol* 2011; **21**: 640–641.
15 Poppe LM, Anders D, Kneitz H, *et al.* Flagellate dermatitis caused by shiitake mushrooms. *An Bras Dermatol* 2012; **87**: 463–465.
16 Adler MJ, Larsen WG. Clinical variability of shiitake dermatitis. *J Am Acad Dermatol* 2012; **67**: e140–e141.
17 Ricar J, Pizinger K, Cetkovska P. Shiitake dermatitis: A distinctive clinical entity. *Int J Dermatol* 2013; **52**: 1620–1621.
18 Hamer S, Rabindranathnambi R. A wide-spread flagellate dermatitis. *BMJ Case Rep* 2013; **2013**: pii: bcr2012007682.
19 Adriano AR, Acosta ML, Azulay DR, *et al.* Shiitake dermatitis: The first case reported in Brazil. *An Bras Dermatol* 2013; **88**: 423–425.
20 Chu EY, Anand D, Dawn A, *et al.* Shiitake dermatitis: A report of 3 cases and review of the literature. *Cutis* 2013; **91**: 287–290.
21 Wang AS, Barr KL, Jagdeo J. Shiitake mushroominduced flagellate erythema: A striking case and review of the literature. *Dermatol Online J* 2013; **19**: 5.
22 Boels D, Landreau A, Bruneau C, *et al.* Shiitake dermatitis recorded by French Poison Control Centers – new case series with clinical observations. *Clin Toxicol* 2014; **52**: 625–628.
23 Karanovic S, George S, Topham E. Don't miss shiitake dermatitis: A case report. *Br J Gen Pract* 2014; **64**: 426–427.

© 2017 *The International Society of Dermatology*

13654632, 2017, 6, Downloaded from https://onlinelibrary.wiley.com/doi/10.1111/ijd.13433 by University Of Toronto Libraries, Wiley Online Library on [06/07/2023]. See the Terms and Conditions (https://onlinelibrary.wiley.com/terms-and-conditions) on Wiley Online Library for rules of use; OA articles are governed by the applicable Creative Commons License

24 Czarnecka AB, Kreft B, Marsch WC. Case report: Flagellate dermatitis after consumption of shiitake mushrooms. *Postepy Dermatol Alergol* 2014; **3**: 187–190.
25 Tan Q, Tan C. Log-grown shiitake is perhaps the real cause for shiitake dermatitis. *J Eur Acad Dermatol Venereol* 2016; **30**: 197–198.
26 Corazza M, Zauli S, Ricci M, *et al.* Shiitake dermatitis: Toxic or allergic reaction? *J Eur Acad Dermatol Venereol* 2015; **29**: 1449–1451.
27 Baran W, Batycka-Baran A, Maj J, *et al.* Shiitake dermatitis – now also in Poland. *Acta Derm Venereol* 2015; **95**: 102–103.
28 Ade R, Sukut C, Wiser HJ, *et al.* Case report: Shiitake dermatitis demonstrating Koebner phenomenon. *Int J Dermatol* 2015; **54**: e179–e181.
29 Hamer SE, Kulkarni K, Cohen SN. Shiitake dermatitis with oral ulceration and pustules. *Clin Exp Dermatol* 2015; **40**: 332–333.
30 de Mendonca CN, Caves e Silva PM, Regazzia Avelleira JC, *et al.* Shiitake dermatitis. *An Bras Dermatol* 2015; **90**: 276–278.
31 Hiernickel C, Metz S, Elsner P. Shiitake dermatitis: An impressive case report. *J Dtsch Dermatol Ges* 2015; **13**: 455–456.
32 Ugur U, Linkner RV. Case letter: Shiitake mushroom dermatitis. *Cutis* 2015; **95**: 11–12.
33 Kopp T, Mastan P, Mothes N, *et al.* Systemic allergic contact dermatitis due to consumption of raw shiitake mushroom. *Clin Exp Dermatol* 2009; **34**: 910–913.
34 Curnow P, Tam M. Contact dermatitis to shiitake mushroom. *Australas J Dermatol* 2003; **44**: 155–157.
35 Camouse MM, Swick AR, Ryan CA, *et al.* Determination of *in vivo* dose response and allergen-specific T cells in subjects contact-sensitized to squaric acid dibutyl ester. *Dermatitis* 2008; **19**: 95–99.
36 Pirmohamed M, Ostrov DA, Park BK. New genetic findings lead the way to a better understanding of fundamental mechanisms of drug hypersensitivity. *J Allergy Clin Immunol* 2015; **136**: 236–244.
37 Salvador F, Sanchez-Montalva A, Martinez-Gallo M, *et al.* Evaluation of cytokine profile and HLA association in benznidazole related cutaneous reactions in patients with Chagas disease. *Clin Infect Dis* 2015; **61**: 1688–1694.
38 Takatsuki F, Namiki R, Kikuchi T, *et al.* Lentinan augments skin reaction induced by bradykinin: Its correlation with vascular dilatation and hemorrhage responses and antitumor activities. *Int J Immunopharmacol* 1995; **17**: 465–474.
39 Zhou LD, Zhang QH, Zhang Y, *et al.* The shiitake mushroom-derived immuno-stimulant lentinan protects against murine malaria blood-stage infection by evoking adaptive immune-responses. *Int Immunopharmacol* 2009; **9**: 455–462.
40 Kim SP, Park SO, Lee SJ, *et al.* A polysaccharide isolated from the liquid culture of *Lentinus edodes* (shiitake) mushroom mycelia containing black rice bran protects mice against salmonellosis through upregulation of the Th1 immune reaction. *J Agric Food Chem* 2014; **62**: 2384–2391.
41 Chen HL, Li DF, Chang BY, *et al.* Effects of lentinan on broiler splenocyte proliferation, interleukin-2 production, and signal transduction. *Poult Sci* 2003; **82**: 760–766.
42 Shimojoh M, Kojima T, Nakajima K, *et al.* Branched chitins as nonnatural immunomodulatory biopolymers: secretions of TNF-α and NO by direct stimulation of macrophages. *Biomacromolecules* 2010; **11**: 1212–1216.
43 Murata Y, Shimamura T, Tagami T, *et al.* The skewing to Th1 induced by lentinan is directed through the distinctive cytokine production by macrophages with elevated intracellular glutathione content. *Int Immunopharmacol* 2002; **2**: 673–689.
44 Hanahue H, Tokuda Y, Machimura T, *et al.* Effects of oral lentinan on T cell subsets in peripheral venous blood. *Clin Ther* 1989; **11**: 614–622.
45 Yoshino S, Tabata T, Hazama S, *et al.* Immunoregulatory effects of the antitumor polysaccharide lentinan on Th1/Th2 balance in patients with digestive cancers. *Anticancer Res* 2000; **20**: 4707–4711.
46 Eungdamrong J, McLellan B. Flagellate erythema. *Dermatol Online J* 2013; **19**: 12.

 © 2017 *The International Society of Dermatology*

13654632, 2017, 6, Downloaded from https://onlinelibrary.wiley.com/doi/10.1111/ijd.13433 by University Of Toronto Libraries, Wiley Online Library on [06/07/2023]. See the Terms and Conditions (https://onlinelibrary.wiley.com/terms-and-conditions) on Wiley Online Library for rules of use; OA articles are governed by the applicable Creative Commons License