View metadata, citation and similar papers at core.ac.uk

brought to you by CORE

provided by University of Southern Denmark Research Output

Syddansk Universitet

Specific skin signs as a cutaneous marker of diabetes mellitus and the prediabetic state

Salman Bustan, Rewend; Wasim, Daanyaal; Yderstræde, Knud Bonnet; Bygum, Anette

Published in:
Danish Medical Journal

Publication date:
2017

Document version
Publisher's PDF, also known as Version of record

Document license
CC BY-NC

Citation for pulished version (APA):
Salman Bustan, R., Wasim, D., Yderstræde, K. B., & Bygum, A. (2017). Specific skin signs as a cutaneous marker of diabetes mellitus and the prediabetic state: a systematic review. Danish Medical Journal, 64(1), [A5316].

General rights
Copyright and moral rights for the publications made accessible in the public portal are retained by the authors and/or other copyright owners and it is a condition of accessing publications that users recognise and abide by the legal requirements associated with these rights.

- Users may download and print one copy of any publication from the public portal for the purpose of private study or research.
- You may not further distribute the material or use it for any profit-making activity or commercial gain
- You may freely distribute the URL identifying the publication in the public portal ?

Take down policy
If you believe that this document breaches copyright please contact us providing details, and we will remove access to the work immediately and investigate your claim.

Download date: 12. aug.. 2017

Specific skin signs as a cutaneous marker of diabetes mellitus and the prediabetic state – a systematic review

Rewend Salman Bustan[1], Daanyaal Wasim[1], Knud Bonnet Yderstræde[2] & Anette Bygum[1]

ABSTRACT

INTRODUCTION: Diabetes mellitus and the prediabetic state are associated with a number of skin manifestations. This study is a systematic review of the following manifestations: acanthosis nigricans (AN), skin tags (ST), diabetic dermopathy (DD), rubeosis faciei (RF), pruritus (PR), granuloma annulare (GA), necrobiosis lipoidica (NL), scleroedema diabeticorum (SD) and bullosis diabeticorum (BD). These conditions possibly relate to underlying diabetogenic mechanisms. Our aim was to determine whether skin signs are feasible as cutaneous markers for the prediabetic or diabetic state.

METHODS: Data were collected from the databases PubMed, Embase and Cochrane. Articles were excluded if the populations presented with comorbidities or received treatment with drugs affecting the skin. Also, animal studies, studies with poor methodology and pilot studies were excluded.

RESULTS: Among the 34 included original articles, an association with diabetes was shown as follows: in eight articles with AN, five articles with ST, three articles with GA, two articles with NL, PR and SD respectively and in one article with RF. Three papers indirectly showed an association of DD with diabetes. Association between bullous skin lesions and diabetes was only documented by case reports and case series.

CONCLUSION: The results indicate a benefit of diabetes screening in individuals presenting with AN, ST or BD. Further studies are required to enlighten a possible association with RF, GA, SD or NL. Until such studies are available, it is advisable to screen individuals with the skin lesions presented by measuring their glycated haemoglobin.

Cutaneous manifestations are seen in a minimum of 30% of diabetics during the course of their illness, and some may even appear before the diagnosis of diabetes mellitus (DM) is confirmed [1-4]. Besides being markers of DM, skin signs may possibly play a central role in reducing the complications associated with diabetes as they may improve the motivation of patients and physicians towards disease management [5, 6]. Epidemiological data strongly suggest that type 2 diabetes mellitus (T2DM) is expanding at an epidemic rate; and it has been estimated that the number of diabetics will reach 250-300 million globally by 2025 [7].

The aim of this study was to determine whether skin signs are feasible as cutaneous markers for the prediabetic state as well as overt DM.

METHODS

A systematic search was conducted to identify any specific cutaneous manifestations of DM (**Figure 1**A). For this purpose, the databases PubMed, Embase and Cochrane were used. The search strategy is shown in Figure 1B. The search was conducted in accordance with the PRISMA guidelines and following the PICO model [8], and the final search date was 5 November 2015. We excluded studies of populations with confounding conditions like malignancies, thyroiditis, gestational diabetes and treatment with drugs affecting the skin. We also excluded animal studies, studies with poor methodology, pilot studies and studies focusing on more than one cutaneous manifestation. The included articles were screened for relevant cross-references. The selection process resulted in a total of 34 articles (**Table 1**).

RESULTS

Acanthosis nigricans

Acanthosis nigricans (AN) was first recognised in 1889 by a German dermatologist [9]. Initially, AN was thought to appear among obese and overweight individuals, but it was later clarified that the condition was linked to increased levels of insulin, which stimulates keratinocytes and dermal fibroblasts through insulin-like growth factor (IGF) [6, 10, 11]. As a consequence, thickened and hyperpigmented velvety skin develops in body folds, mostly the axillae and flexural areas of the posterior neck (**Figure 2**A and Figure 2B). The literature supports a higher frequency of AN among the darker-skin coloured populations [6, 10-13]. It is more difficult to detect AN in fair-skinned people, where the condition may go undetected until overt DM develops. Mostly, the posterior neck and intertriginous areas are involved, but it can also be observed on the knuckles or elbows. AN is often seen in cases of hyperinsulinaemia, and therefore it may also be considered a cutaneous manifestation of the prediabetic state [11, 13]. Studies repeatedly find a higher frequency of AN among females [12-15], and one

SYSTEMATIC REVIEW

1) Department of Dermatology and Allergy Centre, Odense University Hospital
2) Department of Endocrinology, Odense University Hospital, Denmark

Dan Med J 2017;64(1):A5316

study found it to be an independent risk factor for insulin resistance in overweight Hispanic children [16]. Weight-loss along with increased physical activity alleviates the condition by reducing the circulating insulin level [6, 17]. Assigning the diagnosis of AN and emphasising its relation to insulin resistance and possible ways to improve the condition may motivate patients to improve their lifestyle [11]. Screening for AN is a non-invasive procedure, and suggested optimal screening is initiated at the age of five and repeated every second year for individuals with multiple risk factors such as a family history of T2DM, ethnicity and obesity [13]. It is also important to keep in mind that there are other aetiologies to AN, including malignancies [6, 10].

Skin tags

These common skin lesions were first described in relation to DM in 1951 [18]. Skin tags (ST), also named acrochordons, appear as small and soft skin tumours which are often located on the lateral aspects of the neck, back, axilla, trunk and face (Figure 2B) [19]. Of the fibroepithelial tumours of the skin, ST are considered the most common [20]. Hyperinsulinaemia stimulates the IGF-I receptor, which has a tissue proliferative effect resulting in ST.

Therefore, individuals with ST are observed to have hyperinsulinaemia and glycated haemoglobin (HbA_{1c}) levels at the high end of the normal range [21]. There are significantly more ST cases in the diabetic population than among normoglycaemic individuals [20]. As with AN, the ST population presents with a significantly higher body mass index (BMI), especially when their medical history indicates the presence of additional diabetogenic risk factors [19, 20]. A positive correlation has been found between the total number of ST and mean fasting plasma glucose. Patients with more than 30 ST are at an increased risk of developing DM, and females with ST beneath their breasts are particularly prone to developing DM [19]. It seems that ST may have a higher prognostic value for DM than obesity [19]. It is important to stress that hypertension, hyperlipidaemia, atherosclerosis and AN appear at a much higher rate in the ST population [21-23].

Diabetic dermopathy

The condition was first described by the Swedish physician Hans Melin in 1964 [24] and named diabetic dermopathy (DD) by Binkley in 1965 [25]. This manifestation, also named *shin spots*, is the most common cutaneous manifestation of DM and it is almost considered pathognomonic [26]. It has been reported in up to 55% of patients, most frequently in males [27-30]. DD is observed on the pretibial skin as asymmetric, bilateral atrophic and hyperpigmented round-to-oval macules and is diagnosed clinically (Figure 2C). Studies suggest that DD has a microangiopathic origin [27], which should

FIGURE 1

A. Literature selection process. **B.** Terms included in the search strategy adjusted for the different databases.

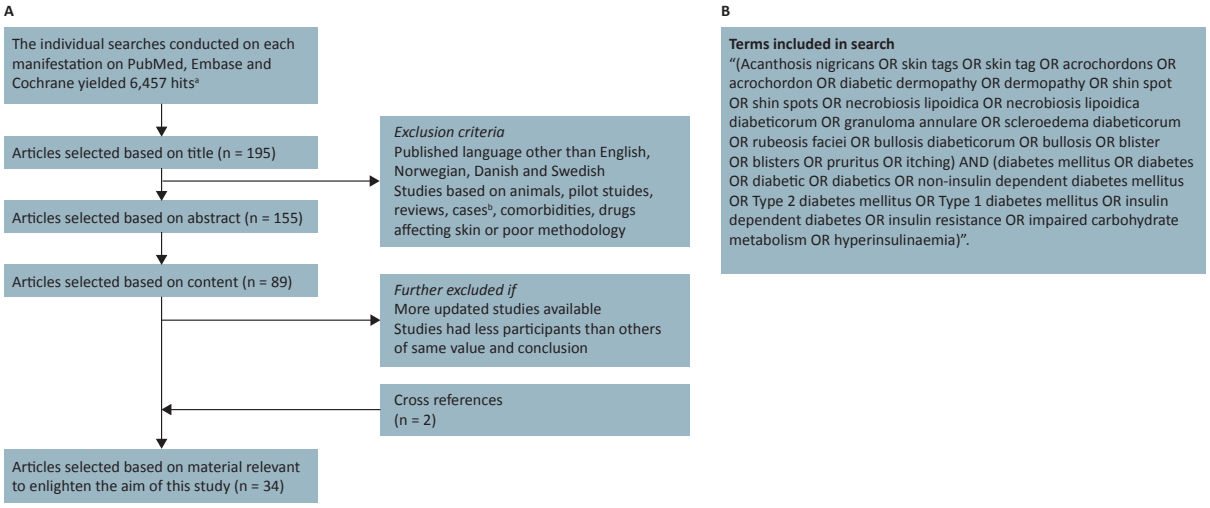

a) The amount of hits contains several duplicates.
b) Bullosis diabeticorum was described in case studies only.

alert physicians to investigate for other diabetic complications related to the microvasculature including retinopathy and peripheral neuropathy. Additionally, neuropathy may be an aetiologic factor and it has been postulated that patients with peripheral neuropathy are more prone to trauma, leading to the development of DD lesions [29]. The reduced pain sensation may explain why individuals with these lesions tend to neglect the presence their lesions. DD has been reported to be associated with a number of other diabetic complications, which warrants further investigation [27]. Although DD is said to be pathognomonic for DM, it should be kept in mind that prolonged intake of certain medications such as iron-containing drugs, antimalarials and quinolones may lead to lesions imitating DD [27, 31].

Rubeosis faciei

First described in the early 19th century as a characteristic reddening of the face (Figure 2D) [32], this manifestation is particularly prevalent among diabetic Ashkenazi Jews [33]. In a recent study, the prevalence of rubeosis faciei (RF) was found to be 7% in patients with type 1 diabetes mellitus (T1DM) [34]. The condition can be exacerbated by hypertension, and the underlying mechanism is suggested to be diabetic microangiopathy, which results in dilatation of superficial veins. The degree of RF reflects the incidence of DM, and also the severity of microangiopathy [33]. As with ST, many patients with RF might go undiagnosed.

Pruritus

This manifestation presents itself as localised or generalised itching without visible primary skin lesions [35]. Generalised pruritus (PR) has been reported in up to 50% of patients with DM [36, 37] and can be an initial symptom of DM [38]. Many diabetics have involvement of the genital and truncal areas [37, 39]. There seems to be a correlation between postprandial glucose and generalised PR in patients with DM; however, no relationship between HbA_{1c} levels and generalised itching has been found [37]. Diabetic smokers are predisposed to developing PR to a higher degree than non-diabetic smokers [35]. Additionally, PR is a marker for polyneuropathy as it appears among patients who lack the Achilles tendon reflex or patients who present with numbness of their soles and palms [39].

Granuloma annulare

Colcott Fox was the first to describe granuloma annulare (GA) in 1895 [40]. GA may be generalised or localised, and the generalised distribution seems to be more prevalent in diabetics [41-43]. The skin lesions of GA are typically symmetrically distributed along the distal region of the extremities and sun-exposed skin areas [41].

! KEY POINTS

The prevalence of diabetes mellitus is increasing.

Skin tags and acanthosis nigricans are both linked to hyperinsulinemia, which is observed in the prediabetic state.

Bullosis diabeticorum, diabetic dermopathy and scleroedema diabeticorum are more commonly seen in long-standing diabetes.

Patients presenting with diabetic dermopathy should be examined for other diabetic microangiopathies including retinopathy and nephropathy.

Early detection and intervention of cutaneous manifestations may improve the prognosis of diabetes.

Identifying these specific cutaneous manifestations should prompt screening for prediabetes and diabetes.

The papular eruption gradually expands with skin-coloured or red borders, creating a central involuted crater (Figure 2E and Figure 2F). GA was found to be more prevalent among adult females [43].

The similarities with necrobiosis lipoidica (NL) are striking, why many have hypothesised that GA is seen prior to this skin disorder [43]. Nevertheless, several studies have failed to show an association between GA and DM [44-46]. Even so, it has been recommended that all individuals presenting with GA should be screened for DM, and it was also suggested that individuals above the age of 30 years with generalised GA should be screened annually [42].

Necrobiosis lipoidica

This condition was originally described by Erich Urbach in 1932 [47]. As mentioned above, NL can resemble GA and is commonly associated with DM [43]. The pathogenesis is not clear, but may be explained by microangiopathic changes and hypoxia [48-50], although an antibody-mediated vasculitis has also been suggested [51]. The lesions exhibit the Koebner phenomenon and are usually painless although some patients may experience itching or pain, especially if the skin lesions ulcerate [52]. Studies from the 1960s showed that more than 60% of patients with NL had DM and 42% of NL patients were undiagnosed diabetics [52, 53]. Subsequent studies, however, have found a less obvious correlation [54]. The typical lesion is a sharply defined atrophic telangiectatic plaque with a glazed content of yellow-brown colour. NL is most commonly located pretibially (Figure 2G), and in 80% of cases it will have a bilateral distribution. Usually, diabetics develop lesions in their fourth decade of life [54]. The prevalence of NL among diabetics is 0.3%, and the condition is more frequent among women. Forty-three percent of the patients who have this condition have a family history of DM [53, 54].

Scleroedema diabeticorum

The first full clinical description of this scleroederma-like

TABLE 1

An overview of the included studies.

Reference	Manifestation	Study design	Participants, n
Akpinar & Dervis, 2012 [20]	Skin tags	Case-control	192 cases 104 controls
Allen & Hadden, 1970 [64]	Bullosis diabeticorum	Case series	5
Bahadursingh et al, 2014 [12]	Acanthosis nigricans	Cross-sectional	311
Basarab et al, 1995 [62]	Bullosis diabeticorum	Case report and literature review	1
Brickman et al, 2007 [7]	Acanthosis nigricans	Cross-sectional	618
Brugler et al, 2011 [29]	Diabetic dermopathy	Case-control	25 cases with T1DM and DD Control groups: 58 with T1DM without diabetic dermopathy and 67 non-diabetics
Cole et al, 1983 [57]	Scleredema diabeticorum	Prospective study	484
Demir & Demir, 2002 [22]	Skin tags	Cross-sectional	120
Gannon & Lynch, 1994 [45]	Granuloma annulare	Prospective study	23
Gitelson & Wertheimer-Kaplinski, 1965 [33]	Rubeosis faciei	Cross-sectional	150 participants of which 35 were examined during summer
Grandhe et al, 2005 [10]	Acanthosis nigricans	Case-control	150 case 150 controls
Haim et al, 1973 [41]	Granuloma annulare	Case-control	52 cases 52 controls
Kidd et al, 1985 [42]	Granuloma annulare	Case-control	15 cases 14 controls
Kluczynik et al, 2012 [14]	Acanthosis nigricans	Cross-sectional	194
Ko et al, 2013 [35]	Pruritus	Cross-sectional	385
Kobaissi et al, 2004 [16]	Acanthosis nigricans	Cross-sectional	131
Kong et al, 2010 [11]	Acanthosis nigricans	Cross-sectional	1,730
Lipsky et al, 2000 [65]	Bullosis diabeticorum	Case series	12
Mobacken et al, 1970 [44]	Granuloma annulare	Case-control	30 localized granuloma annulare, 3 disseminated granuloma annulare, 9 necrobiosis lipoidica
Muhlemann & Williams, 1984 [43]	Granuloma annulare	Retrospective study	557
Muller & Winkelmann, 1966 [49]	Necrobiosis lipoidica	Cohort	171 necrobiosis lipoidica diabeticorum participants, 111 diabetics and 60 non-diabetics
Nebesio et al, 2002 [46]	Granuloma annulare	Case-control	50 cases 50 controls
Neilly et al, 1986 [37]	Pruritus	Case-control	300 cases 100 control
O'Toole et al, 1999 [54]	Necrobiosis lipoidica	Retrospective study	65
Rasi et al, 2007 [19]	Skin tags	Cross-sectional	104 cases 94 controls
Sari et al, 2010 [21]	Skin tags	Case-control	113 cases 31 controls
Sattar et al, 1988 [56]	Scleroedema diabeticorum	Case-control	100 diabetic cases 100 non-diabetic controls
Shah et al, 2014 [23]	Skin tags	Case-control	110 cases with 1-2 acrochordons 110 controls
Shemer et al, 1998 [28]	Diabetic dermopathy	Cross-sectional	173
Stoddart et al, 2002 [13]	Acanthosis nigricans	Cross-sectional	2,205
Vieira et al, 2013 [15]	Acanthosis nigricans	Cross-sectional	118
Wigington et al, 2004 [27]	Diabetic dermopathy	Cross-sectional	61
Yamaoka et al, 2009 [39]	Pruritus	Cross-sectional	2,656 outpatients 499 inpatients
Zhang et al, 2013 [63]	Bullosis diabeticorum	Case report and literature review	1

DM = diabetes mellitus; HbA_{1c} = glycated haemoglobin; HOMA-IR = homeostatic model assessment – insulin resistance; T1 = type 1; T2 = type 2.

CONTINUES »

TABLE 1, CONTINUED

Table 1, continued.

Location & ethnicity	Comment
Turkey & -	Oral glucose tolerance test Hypertension, metabolic syndrome and DM were seen more frequently in patients with skin tags
Northern Ireland & -	5 diabetic patients with disease duration varying 3-19 yrs Mostly poorly controlled DM, presenting with bullous skin lesions consistent with bullosis diabeticorum
West Indies & 61.1% East Indians, 24.4% African, 14.5% mixed	Acanthosis nigricans higher prevalence among overweight individuals with central obesity, hypercholesterolaemia and hypertension
United Kingdom & -	84-yr-old T2DM woman with several diabetic complications Gliclazide used as antidiabetic treatment
Chicago & African American and Hispanic	Significant association between acanthosis nigricans and DM
Omaha, Nebraska, California & -	Depicts lower blood flow in diabetic dermopathy patients compared with controls
California & -	DM participants underwent punch biopsies Scleredema diabeticorum was more prevalent as necrobiosis lipoidica and diabetic dermopathy
Turkey & -	Fasting serum glucose and in some cases oral glucose tolerance test Skin tags associated with DM
Minnesota & -	HbA_{1c} was normal in participants and no correlation was found
Israel & Ashkenazi originating from Eastern and Central Europe and America, Sephardi from Spain, North-Africa, Balkans and Turkey, and Orientals from Iraq, Persia and Yemen	Oral glucose tolerance test was applied Positive correlation between rubeosis faciei and DM
India & Indian	Darker skin yields a higher risk of acanthosis nigricans
Israel & Eastern European origin	Higher prevalence of granuloma annulare among the diabetic individuals.
Colorado & -	The oral glucose tolerance test, fasting plasma glucose, 2-h plasma glucose, 1-h serum insulin and the area under the curve were all significantly higher in granuloma annulare patients
Brazil & 36.1% white, 63.4% brown-skinned, 0.5% indigenous	HOMA-IR used Supports the finding of an acanthosis nigricans association with DM Darker skin coloured people are more prone for developing acanthosis nigricans
Taiwan & -	Used a blinded observer Increased postprandial glucose among the pruritus participants, however, HbA_{1c} was normal
California & Hispanic	Insulin sensitivity was measured, acanthosis nigricans associated to DM, however, obesity is a primary risk factor
New Mexico & 41.3%, Hispanic, 30.7%, non-Hispanic, 20.9%, African American, 7.1% other	Fasting blood glucose along with HOMA-IR used to evaluate the carbohydrate metabolism Showed a positive correlation of acanthosis nigricans to DM
Seattle & -	8-yr follow-up of 12 diabetic patients with bullosis diabeticorum All had similar skin lesions Is in accordance with other reports
Sweden & -	The oral glucose tolerance test and cortisone-glucose tolerance test was performed No significant relation between granuloma annulare and DM
United Kingdom & -	The use of questionnaire and retrospective evaluation of answers 6 out of 88 non-insulin-dependent DM participants had granuloma annulare
Minnesota & -	Oral glucose- and cortisone glucose tolerance were used Necrobiosis lipoidica shown associated with DM and a prediabetic state
Indianapolis & -	Medical records with information on blood glucose measurements, HbA_{1c} and earlier DM diagnosis was reviewed for each participant T2DM seen in 9% of cases No statistical significant correlation was observed
Scotland & -	Found significantly more vaginal pruritus among DM
Ireland & -	Applied glucose tolerance test Found that 11% of the formerly diagnosed diabetics presented with necrobiosis lipoidica at diagnosis 5% had impaired glucose tolerance at time of presentation
Iran & -	2-h fasting glucose test applied Skin tags individuals at higher risk for developing DM
Turkey & -	Oral glucose tolerance test and fasting plasma insulin levels were applied Skin tags individuals more prone to having insulin and lipid disorders
Kuwait & -	3 fasting blood glucose measurements on different days Skin pressure test and some performed skin biopsies scleroedema diabeticorum patients had longer duration of DM
India & -	Serum fasting plasma glucose and 2 h oral glucose tolerance tests performed DM risk increased in skin tags individuals
Israel & -	Prevalence of diabetic dermopathy patients increased with the amount of diabetic complications observed
Oklamaha & Cherokee American Indian	Fasting blood glucose and plasma insulin levels were measured Acanthosis nigricans positively associated with DM
Brazil & 33.9% whites, 66.1% non-whites	Methods applied were fasting blood glucose levels, plasma insulin, HOMA-IR and Insulin-CT method of radioimmunoassay of CIS Bio international Acanthosis nigricans was associated with high mean levels of insulin
California & -	HbA_{1c} measurements and ultrasound-Doppler used to determine blood flow in lesions Abnormal blood flow suggesting microangiopathy
Japan & -	Study applied HbA_{1c}, Achilles tendon reflex, patient medical history Truncal pruritus significantly more common among DM individuals
New Zealand & -	56-yr-old male patient with DM complicated with retinopathy, nephropathy and neuropathy, presented with bullous skin lesion

FIGURE 2

Skin manifestations of diabetes and prediabetes. Acanthosis nigricans of the neck, the most common localisation (**A**). Multiple skin tags with underlying acanthosis nigricans on the lateral aspect of the neck (**B**). Diabetic dermopathy on the shin (**C**). Rubeosis faciei with reddening of the cheeks and the back of the nose (**D**). Disseminated granuloma annulare on the arm (**E**) and a more localised form on the hand (**F**). Necrobiosis lipoidica on the shin (**G**) and an ulcerated variant (**H**). Scleroedema diabeticorum of the back and shoulders (**I**) and an individual with "prayer sign" (**J**). Diabetic bullae on the shin (**K**) and the toes (**L**).

disease is attributed to Buschke in 1902 [55]. The condition manifests by severe permanent thickening of the skin of the posterior neck and upper back. Typically, the skin thickening develops over years and presents like peau d'orange, resulting in decreased sensation to pain and touch in the affected areas (Figure 2I) [56, 57]. Scleroedema diabeticorum (SD) is primarily seen in individuals with long-standing DM. The prevalence of SD among T2DM patients is approximately 2.5% [57]. On the other hand, more than 90% of those with this lesion have DM. A suggested mechanism is the effect of hyperglycaemia on collagen in the skin, where skin biopsies of diabetics show skin thickening with swollen collagen [56]. One consequence of the thickened skin is a reduced range of motion especially affecting the upper back, shoulder and posterior neck [56, 57]. Others are particularly affected on their hands and fingers [58]. In these patients, the condition can easily be demonstrated by the "prayer sign", where patients are asked to oppose the two hands firmly (Figure 2J) [59, 60]. It is important to distinguish SD from scleroedema Buschke, even though some may use the terms interchangeably. Scleroedema Buschke is usually used to describe a post-infectious condition, which is self-limiting [56].

Bullosis diabeticorum

The formation of bullae in diabetics was first observed in 1930 [61]. The condition is not inflammatory, but may relate to neuropathy or vascular insufficiency [62]. Bullosis diabeticorum (BD) is described as resembling a blister secondary to a burn, without the erythematous surrounding. The condition usually appears spontaneously overnight, excluding minor trauma as the causative mechanism, and the bullae vary in size from 0.5-10 cm^2 containing sterile fluid (Figure 2K and Figure 2L) [62-64]. BD is considered a benign lesion with total remission within 5-10 weeks. During the healing process, the fluid leaks leaving a darkened crust over the affected area which dissolves spontaneously. Most frequently, it is observed as a unilateral lesion involving the foot. Nonetheless, bilateral affections as well as multiple lesions have been reported, and other regions such as the trunk, arms and hands can be affected. The prevalence is 0.16% in tertiary care centres, and there is a higher prevalence among males with a median age of 65 years [62-64]. Typically, patients have longstanding T1DM. However, it has also been recognised as a prediabetic manifestation. This rare lesion should be identified by physicians and lead to appropriate intervention to avoid further complications. There is a risk of developing secondary infection, which may complicate the condition, leading to a prolonged healing time [65]. Patients often describe the onset of symptoms as a burning sensation that later fades away. Recurrence is often observed. It is

important to exclude other bullous entities, making BD a diagnosis of exclusion.

DISCUSSION

Skins signs are observed among diabetics with variable duration and also in the prediabetic state. AN is often seen early in the course of the disease, especially when an individual has additional risk factors for developing DM, including obesity. The majority of included studies use HbA_{1c}, fasting plasma glucose measurements and homeostatic model assessment. Regardless of the methods applied, there is overall agreement that AN is significantly associated with DM [10, 12, 16]. Kobaissi and coworkers diverted from the other studies by applying a computer programme (MINMOD) to the obtained blood samples to define insulin sensitivity [16]. They found a stronger correlation with obesity, and they therefore suggested that obesity should be a marker for DM. Detection of AN has also been shown to encourage discussion between the patient and the clinician leading to earlier intervention [5]. Screening is recommended due to its inexpensive and non-invasive nature [11, 16].

ST and AN are frequently found among diabetics and prediabetics and can co-occur. An Iranian case-control study conducted among 104 patients with ST and 94 BMI-matched controls showed a higher frequency of DM in patients with ST [19]. The study found a significant correlation between 30 or more ST and risk of impaired carbohydrate metabolism. Akpinar and coworkers did not manage to reproduce a statistically significant difference between patients with ST and controls using fasting plasma glucose levels [20]. The discrepancy may be due to the fact that Rasi and coworkers included participants with 3 ST or more in their cross-sectional study making them more likely to document significant differences. Demir & Demir found a significant correlation of ST with hyperinsulinaemia rather than overt DM [22].

We identified no original studies focusing on DD and its relation to DM, which may be taken to underscore the fact that the manifestation is acknowledged as pathognomic for DM. Studies on DD lack consistency in their methodological approach and clarification of the underlying pathophysiology [27, 28, 31]. All the diabetics with dermopathic lesions in the included studies showed underlying microangiopathy. Thus, an indirect correlation can be deduced from the included studies, as well as DD's function as a marker for diabetic complications resulting from microangiopathy.

Manifestations like RF are easy to recognise when the patient is first seen. While prevalence studies show a tendency for RF to occur among diabetics, evidence of a direct correlation is still lacking. Skin colour, ambient temperature, hormonal factors and other skin diseases such as rosacea may influence facial redness. Further studies are required to elucidate the pathophysiology of this phenomenon.

PR is an unspecific symptom and could be related to other causes including, fungal infections. In a Taiwanese study, postprandial glucose was found to be significantly elevated among patients with generalised PR. To the best of our knowledge, this is the only study to date reporting on this relation. In contrast, in a cross-sectional study from the UK including 100 diabetics with PR [37], no correlation between generalised PR and DM could be demonstrated. However, there was a positive correlation with vulvar PR. Both studies had shortcomings in relation to testing for autonomic neuropathy, which may influence perspiration and the perception of sensory signals. A matter of concern is the difference in terminology and the methods used in the two studies. Even though there are disputes regarding the correlation of PR to DM, it would be beneficial for physicians to include DM among their differential diagnoses when presented with a patient having unexplained generalised PR. A thorough investigation of any diabetic person presenting with PR is advised as this diffuse symptom is also seen with other diseases such as thyroid disorders and lymphoma [66].

There is also a dispute regarding the relation between GA and DM as recent studies have been unable to reproduce the results shown by earlier studies [46]. The reason for the inconsistency between the results achieved in the studies may be that different definitions and investigations of DM were used as some used fasting plasma glucose and others used HbA_{1c}. Another point of interest is the variable phenotypical presentation of GA. It seems to be the generalised form that is linked to DM [41, 45]. In summary, there is an insufficient amount of studies to properly support any statements regarding the degree of correlation between GA and DM.

NL has been linked to DM in earlier studies [53, 54]. However, in later studies, participants with NL did not suffer from DM. The study by O'Toole et al therefore raises the question whether NL is a cutaneous manifestation "of the past" [54]. However, physicians should still be aware of this manifestation and its occurrence among diabetics. There seems to be no recent studies on this subject.

SD is rarely seen nowadays. It is mainly reported among obese diabetics with poorly controlled DM sampled from highly selected populations, e.g. diabetes clinics [56, 57]. Thus, the reported prevalence may be higher than among the general diabetic population. Nonetheless, the collected data support the notion that SD develops from prolonged exposure of high blood glucose on collagen in the skin leading to thickening of the skin.

In contrast to some of the other manifestations, BD is specifically reported among diabetics, indicating a strong clinical correlation. The occurrence of BD among

diabetics is possibly under-recognised as all publications on this subject are seemingly case reports or smaller case series. A critique of some of these reports is that many of the subjects present with comorbidities that may contribute to the development of bullae.

Besides these classically described diabetes markers, there is increasing knowledge of a correlation between psoriasis and T2DM [67]. A systematic review and meta-analysis from 2013 suggests an association between diabetes and psoriasis and psoriatic arthritis. It should be noted that the heterogeneity of the included studies raises questions with respect to extrapolation of their results. Nonetheless, the evidence to date indicates that physicians should screen patients with psoriasis for diabetes [68].

Strengths and limitations

To the best of our knowledge, this is the first systematic review aiming to investigate the role of the different skin lesions as markers for the prediabetic state or overt DM. The literature search presents an updated picture of the available evidence and reveals some issues that require further investigation.

A general critique, which applies to many of the studies, is sampling bias. Thus, many of the participants were selected from diabetic clinics or other tertiary units. Another major critique is the lack of blinding of physicians and participants which may both entail further bias. An additional important difference is the use of inconsistent and incompatible methods. Even though current studies are likely to provide an updated view, it is important to keep in mind that the older studies better reflect the poorly controlled diabetics.

CONCLUSION

The most recent studies demonstrate a strong association between DM and the entities of ST and AN. The remaining presented manifestations require further investigation inasmuch as newer studies cannot reproduce previous results. However, lack of evidence should not prevent physicians from screening patients, as this is a low-cost measure and as early detection is beneficial. The management of DM has improved markedly over the years, and better glycaemic control results in a reduction of complications.

Recognition of cutaneous markers enables an earlier diagnosis of undiagnosed DM and recognition of suboptimal management of known disease. Thus, the presented skin sigsns should lead to a DM-focused diagnostic evaluation.

CORRESPONDENCE: *Rewend Salman Bustan.* E-mail: rsa-5@hotmail.com
ACCEPTED: 27 October 2016
CONFLICTS OF INTEREST: Disclosure forms provided by the authors are available with the full text of this article at www.danmedj.dk

LITERATURE

1. Braverman IM. Cutaneous manifestations of diabetes mellitus. Med Clin North Am 1971;55:1019-29.
2. Paron NG, Lambert PW. Cutaneous manifestations of diabetes mellitus. Prim Care 2000;27:371-83.
3. Huntley AC. The cutaneous manifestations diabetes mellitus J Am Acad Dermatol 1982;7:427-55.
4. Allen GE. Diabetes and the skin. Pract 1969;203:189-93.
5. Kong AS, Williams RL, Smith M et al. Acanthosis nigricans and diabetes risk factors: prevalence in young persons seen in southwestern US primary care practices. Ann Fam Med 2007;5:202-8.
6. Brickman WJ, Binns HJ, Jovanovic BD et al. Acanthosis nigricans: a common finding in overweight youth. Pediatr Dermatol 2007;24:601-6.
7. Kapitel 11 fra Folkesundhedsrapporten Danmark 2007. www.si-folkesundhed.dk/upload/kap_11_diabetes.pdf (29 Apr 2016).
8. Moher D, Liberati A, Tetzlaff J et al. Preferred reporting items for systematic reviews and meta-analyses: the PRISMA statement. J Clin Epidemiol 2009; 62:1006-12.
9. Pollitzer S. Acanthosis nigricans: a symptom of a disorder of the abdominal sympathetic. JAMA 1909;53:1369-73.
10. Grandhe NP, Bhansali A, Dogra S et al. Acanthosis nigricans: relation with type 2 diabetes mellitus, anthropometric variables, and body mass in Indians. Postgrad Med J 2005;81:541-4.
11. Kong AS, Williams RL, Rhyne R et al. Acanthosis nigricans: high prevalence and association with diabetes in a practice-based research network consortium – a primary care multi-ethnic network (PRIME Net) study. J Am Board Fam Med 2010;23:476-85.
12. Bahadursingh S, Mungalsingh C, Seemungal T et al. Acanthosis nigricans in type 2 diabetes: prevalence, correlates and potential as a simple clinical screening tool – a cross-sectional study in the Caribbean. Diabetol Metab Syndr 2014;9:77.
13. Stoddart ML, Blevins KS, Lee ET et al. Association of acanthosis nigricans with hyperinsulinemia compared with other selected risk factors for type 2 diabetes in Cherokee Indians: the Cherokee Diabetes Study. Diab Care 2002;25:1009-14.
14. Kluczynik CE, Mariz LS, Souza LC et al. Acanthosis nigricans and insulin resistance in overweight children and adolescents. An Bras Dermatol 2012;87:531-7.
15. Vieira CE, Mariz LS, Medeiros CC et al. Nursing care in childcare services: acantose nigricans as a marker for metabolic risk. Rev Lat Am Enfermagem 2013;21:1220-7.
16. Kobaissi H, Weigensberg MJ, Ball GD et al. Relation between acanthosis nigricans and insulin sensitivity in overweight Hispanic children at risk for type 2 diabetes. Diab Care 2004;27:1412-6.
17. Al-Mutairi N. Associated cutaneous diseases in obese adult patients: a prospective study from a skin referral care center. Med Princ Pract 2011;20:248-52.
18. Touraine A. A new hereditary chain; cutaneous fibromas, diabetes, obesity. Ann Dermatol Syphiligr (Paris) 1951;78:409-16.
19. Rasi A, Soltani-Arabshahi R, Shahbazi N. Skin tag as a cutaneous marker for impaired carbohydrate metabolism: a case-control study. Int J Dermatol 2007;46:1155-9.
20. Akpinar F, Dervis E. Association between acrochordons and the components of metabolic syndrome. Eur J Dermatol 2012;22:106-10.
21. Sari R, Akman A, Alpsoy E et al. The metabolic profile in patients with skin tags. Clin Exp Med 2010;10:193-7.
22. Demir S, Demir Y. Acrochordon and impaired carbohydrate metabolism. Acta Diabet 2002;39:57-9.
23. Shah R, Jindal A, Patel N. Acrochordons as a cutaneous sign of metabolic syndrome: a case-control study. Ann Med Health Sci Res 2014;4:202-5.
24. Melin H. An atrophic circumscribed skin lesion. Acta Med Scand 176:1-75.
25. Binkley GW. Dermopathy in the diabetic syndrome. Arch Dermatol 1965;92:625-34.
26. Morgan AJ, Schwartz RA. Diabetic dermopathy: a subtle sign with grave implications. J Am Acad Dermatol 2008;58:447-51.
27. Wigington G, Ngo B, Rendell M. Skin blood flow in diabetic dermopathy. Arch Dermatol 2004;140:1248-50.
28. Shemer A, Bergman R, Linn S et al. Diabetic dermopathy and internal complications in diabetes mellitus. Int J Dermatol 1998;37:113-5.
29. Brugler A, Thompson S, Turner S et al. Skin blood flow abnormalities in diabetic dermopathy. J Am Acad Dermatol 2011;65:559-63.
30. Vijayasingam SM, Thai AC, Chang HL. Non-infective skin associations of diabetes mellitus. Ann Acad Med Singapore 1988;17:526-35.
31. McCash S, Emanuel PO. Defining diabetic dermopathy. J Dermatol 2011;38:988-92.
32. Von Noorden C, Isaac S. Die Zuckerkrankheit und ihre Behandlung. Berlin: Springer, 1927:279.
33. Gitelson S, Wertheimer-Kaplinski N. Color of the face in diabetes mellitus; observation on a group of patients in Jerusalem. Diabetes 1965;14:201-8.
34. Pavlovic MD, Milenkovic T, Dinic M et al. The prevalence of cutaneous manifestations in young patients with type 1 diabetes. Diab Care 2007;30:1964-7.
35. Ko MJ, Chiu H, Jee S et al. Postprandial blood glucose is associated with generalized pruritus in patients with type 2 diabetes. Eur J Dermatol 2013;23:688-93.

36. Al-Mutairi N, Zaki A, Sharma AK et al. Cutaneous manifestations of diabetes mellitus. Study from Farwaniya hospital, Kuwait. Med Princ Pract 2006;15: 427-30.
37. Neilly JB, Martin A, Simpson N et al. Pruritus in diabetes mellitus: investigation of prevalence and correlation with diabetes control. Diab Care 1986;9:273-5.
38. Hillson RM, Hockaday TD, Newton DJ et al. Delayed diagnosis of non-insulin-dependent diabetes is associated with greater metabolic and clinical abnormality. Diab Med 1985;2:383-6.
39. Yamaoka H, Sasaki H, Yamasaki H et al. Truncal pruritus of unknown origin may be a symptom of diabetic polyneuropathy. Diab Care 2009;33:150-5.
40. Fox CT. Ringed eruption of the fingers. Br J Dermatol 1895;7:91-5.
41. Haim S, Friedman-Birnbaum R, Haim N et al. Carbohydrate tolerance in patients with granuloma annulare. Study of fifty-two cases. Br J Dermatol 1973;88:447-51.
42. Kidd GS, Graff GE, Davies BF et al. Glucose tolerance in granuloma annulare. Diab Care 1985;8:380-4.
43. Muhlemann MF, Williams DR. Localized granuloma annulare is associated with insulin-dependent diabetes mellitus. Br J Dermatol 1984;111:325-9.
44. Mobacken H, Gisslen H, Johannison G. Granuloma annulare. Acta Dermatovener 1970;50:440-4.
45. Gannon TF, Lynch PJ. Absence of carbohydrate intolerance in granuloma annulare. J Am Acad Dermatol 1994;30:662-3.
46. Nebesio CL, Lewis C, Chuang TY. Lack of an association between granuloma annulare and type 2 diabetes mellitus. Br J Dermatol 2002;146:122-4.
47. Urbach E. Beiträge zu einer phyiologischen und pathologischen Chemie der Haut. Archiv fûr Dermat Und Syph 1932;166:273-85.
48. Boateng B, Hiller D, Albrecht HP et al. Cutaneous microcirculation in pretibial necrobiosis lipoidica. Comparative measurements of laser doppler flux and partial pressure of oxygen in patients and in healthy volunteers. Hautarzt 1993;44:581-6.
49. Muller SA, Winkelmann RK. Necrobiosis lipoidica diabeticorum histo-pathologic study of 98 cases. Arch Dermatol 1966;94:1-10.
50. Ngo B, Wigington G, Hayes K et al. Skin blood flow in necrobiosis lipoidica diabeticorum. Int J Dermatol 2008;47:354-8.
51. Quimby SR, Muller SA, Schroeter AL. The cutaneous immunopathology of necrobiosis lipoidica diabeticorum. Arch Dermatol 1988;124:1364-71.
52. Reid SD, Ladizinski B, Lee K et al. Update on necrobiosis lipoidica: a review of etiology, diagnosis, and treatment options. J Am Acad Dermatol 2013; 69:783-91.
53. Muller SA, Winkelmann RK. Necrobiosis lipoidica diabeticorum. A clinical and pathological investigation of 171 cases. Arch Dermatol 1966;93:271-81.
54. O'Toole EA, Kennedy U, Nolan JJ et al. Necrobiosis lipoidica: only a minority of patients have diabetes mellitus. Br J Dermatol 1999;140:283-6
55. Buschke A. Ueber Scleroedem. Berl Klin Wochenscher 1902;39:955-7.
56. Sattar MA, Diab S, Sugathan TN et al. Scleroedema diabeticorum: a minor but often unrecognized complication of diabetes mellitus. Diabet Med 1988;5:465-8.
57. Cole GW, Headley J, Skowsky R. Scleredema diabeticorum: a common and distinct cutaneous manifestation of diabetes mellitus. Diab Care 1983;6: 189-92.
58. Yosipovitsch G, Hodak E, Vardi P et al. The prevalence of cutaneous manifestations in IDDM patients and their association with diabetes risk factors and microvascular complications. Diab Care 1998;21:506-9.
59. Sawatkar GU, Kanwar AJ, Dogra S et al. Spectrum of cutaneous manifestations of type 1 diabetes mellitus in 500 South Asian patients. Br J Dermatol 2014;171:1402-6.
60. Papanas N, Maltezos E. The diabetic hand: a forgotten complication? J Diab Complic 2010;24:154-62.
61. Kramer D. Early warning signs of impending gangrene in diabetes mellitus. Med J Records 1930;132:338-42.
62. Basarab T, Munn SE, McGrath J et al. Bullosis diabeticorum. A case report and literature review. Clin Exp Dermatol 1995;20:218-20.
63. Zhang AJ, Garret M, Miller S. Bullosis diabeticorum: case report and review. N Z Med J 2013;126:91-4.
64. Allen GE, Hadden DR. Bullous lesions of the skin in diabetes (bullosis diabeticorum). Br J Derm 1970;82:216.
65. Lipsky BA, Baker PD, Ahroni JH. Diabetic bullae: 12 cases of a purportedly rare cutaneous disorder. Int J Dermatol 2000;39 196-200.
66. Lyell A. The itching patient. A review of the causes of pruritus. Scott Med J 1972;17:334-7.
67. Gyldenløve M, Knop FK, Vilsbøll T et al. Psoriasis er forbundet med type 2 diabetes. Ugeskr Læger 2013;175:652-4.
68. Coto-Segura P, Eiris-Salvado N, Gonzalez-Lara L et al. Psoriasis, psoriatic arthritis and type 2 diabetes mellitus: a systematic review and meta-analysis. Br J Dermatol 2013;169:783-93.