Annales de chirurgie plastique esthétique (2017) 62, 274—294

Available online at
ScienceDirect
www.sciencedirect.com

Elsevier Masson France
EM|consulte
www.em-consulte.com

GENERAL REVIEW

Non-surgical treatments for hidradenitis suppurativa: A systematic review

Procédures non chirurgicales dans la prise en charge de l'hidrosadénite suppurative : revue systématique de la littérature

E. Robert [a], F. Bodin [a], C. Paul [b], M.-P. Konstantinou [b], Y. Gall [b], J.-L. Grolleau [c], J. Laloze [c], B. Chaput [c,*]

[a] *Department of plastic surgery, Strasbourg university hospitals, university of Strasbourg, 67091 Strasbourg, France*
[b] *Department of dermatology, Rangueil-Larrey hospital, Paul-Sabatier university, 31059 Toulouse, France*
[c] *Department of plastic, reconstructive and aesthetic surgery, Rangueil hospital, 1, avenue Jean-Poulhès, 31059 Toulouse, France*

Received 11 December 2016; accepted 28 March 2017

KEYWORDS
Verneuil's disease;
Antibiotics;
Biologic therapies;
Systematic review

Summary
Introduction. — The management of *hidradenitis suppurativa* is multidisciplinary, involving general measures, medical treatment and surgery. Non-surgical treatments, often first-line procedures, mainly concern forms of low-to-moderate severity or, conversely, very severe forms in non-operable patients or those refusing surgery. While many treatments have been attempted, few randomized controlled trials have been conducted, so the choice of treatments is most often based on the personal experience of the clinicians. The objective of this systematic review is to propose a synthetic analysis of the currently available non-surgical procedures.
Methods. — This systematic review of the literature was conducted in accordance with the PRISMA criteria. We searched for articles in the Medline®, *PubMed Central*, *Embase* and *Cochrane* databases published between January 2005 and September 2015.
Results. — Sixty-four articles were included. They generally had a low level of evidence; indeed, the majority of them were retrospective observational studies. They involved biotherapy (44%), dynamic phototherapy (16%), antibiotics (11%), Laser (8%), retinoids (6%) and immunosuppressive therapies, anti-inflammatory drugs, zinc, metformin, gammaglobulins and fumarates.
Conclusions. — None of the non-surgical treatments can treat all stages of the disease and

* Corresponding author. Department of plastic and reconstructive surgery, Rangueil university hospital, avenue du Professeur-Jean-Poulhes, 31000 Toulouse, France.
E-mail address: benoitchaput31@gmail.com (B. Chaput).

http://dx.doi.org/10.1016/j.anplas.2017.03.012
0294-1260/© 2017 Elsevier Masson SAS. All rights reserved.

offer long-term remission. Antibiotics and biotherapy seem to have real effectiveness but their effect remains suspensive and the disease is almost certain to reappear once they are stopped. As regards antibiotics, no association has shown their superiority in a study with a high level of evidence. And while some biotherapies seem quite effective, due to their side effects they should be reserved for moderate-to-severe, resistant or inoperable forms of the disease. Randomized controlled studies are needed before valid conclusions can be drawn. In the resistant or disabling forms, it is consequently advisable to orientate to the greatest possible extent towards radical surgery, which is the only treatment allowing hope for cure.
© 2017 Elsevier Masson SAS. All rights reserved.

MOTS CLÉS
Maladie de Verneuil ;
Hidrosadénite suppurée ;
Antibiotique ;
Biothérapie ;
Revue systématique

Résumé
Introduction. — La prise en charge de l'hidrosadénite suppurative doit être pluridisciplinaire associant des mesures générales, des traitements médicaux et de la chirurgie. Les traitements non chirurgicaux, souvent de première intention, concernent surtout les formes débutantes à modérées ou à l'inverse les formes très sévères chez les patients non opérables ou refusant la chirurgie. De nombreux traitements ont été essayés mais peu d'études randomisées contrôlées ont été menées, le choix des traitements repose donc le plus souvent sur l'expérience personnelle du clinicien. L'objectif de cette revue systématique est de proposer une analyse synthétique des procédures non chirurgicales disponibles à l'heure actuelle.
Méthodes. — Cette revue systématique de la littérature a été conduite selon les critères PRISMA. Nous avons recherché les articles publiés de 2005 à septembre 2015 dans les bases de données Medline®, *PubMed Central*, *Embase* et *Cochrane*.
Résultats. — Soixante-quatre articles ont été inclus. Ces articles avaient le plus souvent un faible niveau de preuve, il s'agissait en effet majoritairement d'études observationnelles rétrospectives. Ils concernaient les biothérapies (44 %), les photothérapies dynamiques (16 %), les antibiotiques (11 %), les traitements par Laser (8 %), les rétinoïdes (6 %) les traitements hormonaux (5 %), puis les immunosuppresseurs, les anti-inflammatoires, le zinc, la metformine, les gammaglobulines et les fumarates.
Conclusions. — Aucun traitement non chirurgical ne permet de traiter tous les stades de la maladie avec une rémission sur le long terme. Les antibiotiques et les biothérapies semblent avoir une réelle efficacité mais leur effet reste suspensif et la maladie réapparaît de façon quasi certaine à leur arrêt. Concernant les antibiotiques, aucune association n'a montré sa supériorité au travers d'une étude de haut niveau de preuve. Certaines biothérapies semblent très efficaces mais leurs effets secondaires doivent les faire réserver aux formes modérées à sévères, résistantes ou inopérables. Des études contrôlées randomisées sont nécessaires pour pouvoir tirer des conclusions valides. Dans les formes résistantes ou invalidantes, il convient ainsi de s'orienter autant que possible vers le traitement chirurgical radical qui est le seul à permettre une guérison de la maladie.
© 2017 Elsevier Masson SAS. Tous droits réservés.

Introduction

Also known as Verneuil's disease and acne inversa, hidradenitis suppurativa is a chronic inflammatory skin disease characterized by recurrent abscesses in areas of the body containing numerous apocrine sweat glands [1].

Studies have reported a prevalence of approximately 1% in the global population [2], with predominant occurrence in women [3] (3 women for 1 man). While the pathophysiology of this disease has yet to be clearly elucidated, several pathogenic factors are apparently contributory: follicullar obstruction, chronic inflammation, bacteria and their biofilm and, finally, immune system abnormalities [4—7]. The pathology is frequently associated with obesity and smoking as well as autoimmune diseases such as spondylarthropathies or Crohn's disease [8]. The psychosocial impact of these chronic inflammatory lesions is the main source of what can be considered as a handicap [9].

That said, severe complications are few and far between. After several years of development, for example, chronic lesions can become cancerous in the form of epidermoid or squamous cell carcinomas [10]. Extreme cases may be marked by the appearance of a lymphedema, scrotal elephantiasis [11], urinary or digestive fistulas.

Surgical treatment by wide excision of cutaneous or subcutaneous tissue represents the only way to eradicate the disease [12]. As an operation applying classical techniques of plastic surgery (controlled wound healing, grafts, flaps) [13], its main and major drawback resides in its ''heaviness'', and it is generally addressed only to the most highly developed forms.

Non-surgical treatments mainly concern forms of the disease of mild-to-moderate severity or, conversely, very severe forms in non-operable patients or those refusing surgery. While many treatments have been attempted, few randomized controlled trials have been conducted,

and the choice of treatments is most often based on the personal experience of a clinician.

We have carried out a systematic review of the articles published over a very recent 10-year period on non-surgical treatments of hidradenitis suppurativa, our objective being to propose a synthetic analysis of the currently available non-surgical disease management procedures.

Material and methods

This systematic review was carried out according to the recommendations (version 5.1.0) of the *Cochrane handbook for systematic reviews of interventions* and in accordance with the preferred reporting items for systematic reviews and meta-analysis (PRISMA) criteria [14].

Research strategy

We searched for articles published between January 2005 and September 2015 in the electronic data bases Medline®, *PubMed Central*, *Embase* and *Cochrane*. In this research, we sued the English-language keywords *''hidradenitis suppurativa''*, *''acne inversa''* and *''Verneuil's disease''*. The articles were selected irrespective of language, and all resources were used in order to find a French or English version of the article, or to get hold of a translation.

Inclusion criteria

We included all original articles pertaining to non-surgical treatment for Verneuil's disease published between 1 January 2005 and 30 September 2015 and comprising controlled trials and prospective or retrospective observational studies involving at least four patients. Case reports, reviews of the literature, discussions, commentaries, letters to the authors and editorials were excluded.

Data collection

The extracted data provided precise information on authors, publication date, type of study, number of cases and type of treatment, as well as duration of administration and follow-up, modality of evaluation (scale used), results and complications. Since heterogeneity and subjectivity rendered it difficult to analyze the results, as a means of harmonization we devised a simple scale ranging from 0 to +++: 0: no improvement; +: mild improvement; ++: significant improvement; +++: complete improvement/remission.

Results

Through our research strategy, we identified 873 articles (Fig. 1). Once the titles had been reviewed, 119 references for non-surgical treatments were studied and 64 articles were finally included. More often than not, these articles had a low level of evidence according to the criteria of the *Oxford centre for evidence-based medicine* [15], and a majority of them were retrospective observational studies.

The 64 publications represented a total number of 1368 patients. An overwhelming majority of the articles dealt with biotherapies (44%), dynamic phototherapies (16%), antibiotics (11%), Laser treatments (8%), retinoids

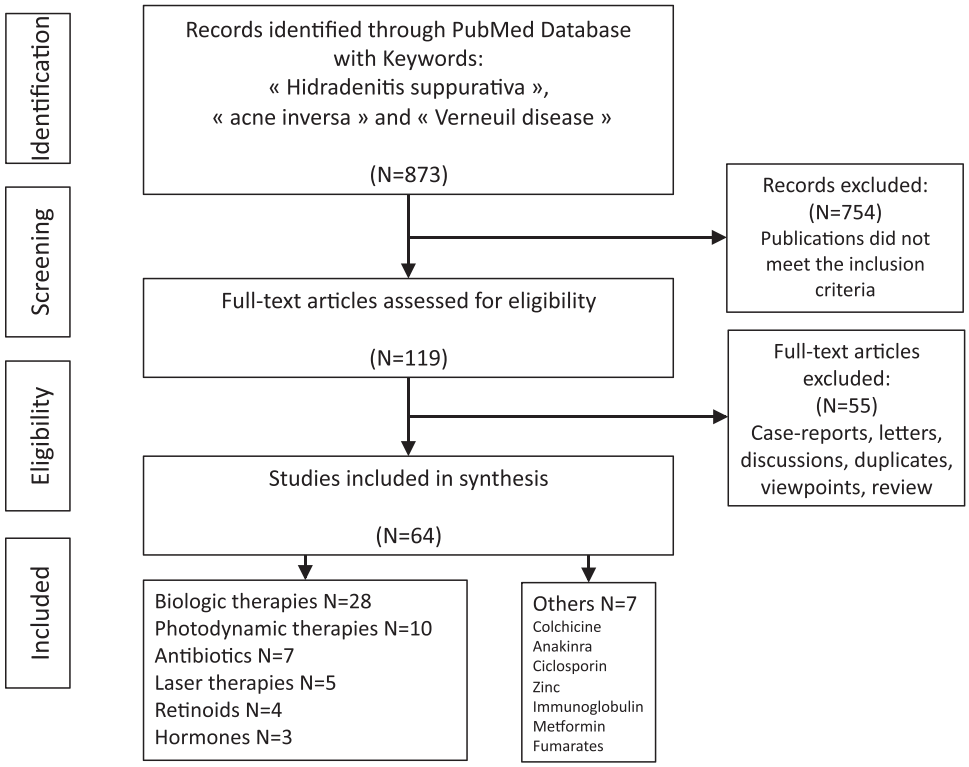

Figure 1 Flowchart.

(6%) and hormonal treatments (5%). The remaining studies (10%) dealt with immunosuppressors, anti-inflammatory drugs, zinc, metformin, gammaglobulins and fumarates.

Biotherapies

Anti-TNFα drugs are monoclonal antibodies or soluble receptors specifically targeting tumor necrosis factor alpha, a proinflammatory cytokine. They have received marketing authorization according to specialty for the treatment of chronic inflammatory diseases such as rheumatoid polyarthritis, psoriasis, ankylosing spondylitis and Crohn's disease; they have also been used without marketing authorization for a large number of other pathologies, particularly hidradenitis suppurativa [16]. While adalimumab was awarded a European recommendation in 2015 and French marketing authorization (AMM) in 2016 for treatment of hidradenitis suppurativa, up until now it has not entitled users to any reimbursement. And the high cost of this treatment (presently 10,000 €) remains an obstacle to its generalized prescription.

Biotherapies concern the drugs occasioning the largest number of studies over recent years (28 out of 64) (Table 1). The most widely studied are infliximab, adalimumab and etanercept. Only four of these studies have been placebo-controlled [17—20]:

- fifteen articles concern infliximab. It is administered by infusion at a dose of 5 mg/kg at weeks 0, 2 and 6 and then once every 4 to 8 weeks over a lapse of time ranging from a few months to more than 7 years. Even though it yields little remission, a partial response very often occurs (71% to 100%). While the one published randomized controlled study [20] reports only 7% remission, 88% of the patients were responders. On the other hand, when a dose is administered once every 8 weeks, its efficacy seems to subside after around 8 months [21,22]. More frequent infusions, taking place every 4 weeks, seem associated with better control over time [23]. That said, while tolerance is relatively satisfactory, albeit with a few minor infections, several severe side effects have been deplored (one colon cancer [24], one Hodgkin's lymphoma [23], two severe neuropathies [22,24], two serious allergic reactions [22,24]);
- eleven articles discuss adalimumab. The schema applied in France by *Haute Autorité de santé* (French health authority) consists in an initial dose of 160 mg on D1, 80 mg on D15, and then 40 mg each week as of D29 with efficacy assessment at 12 weeks. The results are far more varied than those for infliximab, with a partial response rate ranging from 10 to 100%. There exist two randomized controlled studies:
  - the study by Kimball et al. [17] is the more powerful, with 154 patients included; while the response rate was rather low (17% moderate to significant improvement) for a single weekly dose, improvement was significant compared to a placebo control (4%; $P = 0.025$),
  - the study by Miller et al. [18] also showed significant improvement following 6 weeks of treatments vs. placebo ($P = 0.024$), but after 3 months, the beneficial effects had completely disappeared. The problem of relapse likewise appears in the other studies, with recurrence of the disease between 11 weeks [25] and 9.5 months [26] after treatment cessation. That said, tolerance seems satisfactory, albeit with some minor infections [17,18];
- ten articles have dealt with etanercept. Usual dosage is 50 mg a week during 12 weeks. Results are inconsistent and often involve small-scale series: 100% response rates for some patients [27—30] but 71% of poor or non-existent responses for Lee [31] in 15 patients. The one randomized controlled trial by Adams et al. showed that in comparison with a placebo, etanercept had no significant efficacy [19]. On the other hand, tolerance is relatively satisfactory, albeit with some minor infections and local reactions at the injection site [19,28,29,31];
- a 2007 study was devoted to efalizumab, a biotherapy targeting the adhesion molecule CD11a [32]. There was no response from any of the five patients, and the side effects were quite considerable (anemia, weight loss and one case of breast cancer). Having been associated with progressive multifocal leukoencephalpathy, in 2009 efalizumab was withdrawn from the market;
- two other molecules (certolizumab [16], an anti-TNF alpha antibody; and ustekinumab [33], an anti-IL12/23 antibody) have been tested. When consulting the aforementioned publications analyzing several different molecules, we found that only two patients had used certolizumab and ustekinumab, and it was therefore impossible to draw any conclusion.

The tolerance profile of biotherapies in treatment of hidradenitis suppurativa is generally favorable. That said, minor adverse effects frequently occur: headaches, flu-like syndromes, tiredness, and injection site reaction. More serious reactions have only occasionally been reported: bacterial and viral infections [26,34], neurological disorders [16,24,27], hépatitis [35], lupus [35], severe allergies [22,24], as well as a number of cancers: (breast [32], lung [34], skin [34,36], colon [24], lymphoma [23]). The degree to which the treatment might be responsible for occurrence of these cancers is difficult to establish. Recent meta-analyses have not associated biotherapies with an increased risk of cancer [37,38]. The relevant data nonetheless confirm the importance of a pre-treatment assessment allowing for screening of infections or latent cancers susceptible to being reactivated. On the other hand, no reactivation of latent tuberculosis, classically described in conjunction with anti-TNFα drugs, has been reported.

From a medico-economic standpoint, it should be pointed out that in France, notwithstanding the market authorization obtained in May 2016 for moderate-to-severe hidradenitis suppurativa in the event of insufficient response to conventional systemic treatment, no reimbursement is given for anti-TNFα prescription. According to the HAS, the medical service it renders does not suffice to justify financal coverage.

Adalimumab has also received a recommendation [39] from the European Medicines Agency; dated 25 June 2015, it pertains to the extension of authorized HUMIRA®/adalimumab use to adults suffering from moderate-to-severe hidradenitis suppurativa. Last but not least, in the United States, in September 2015, the Food and Drug Administration (FDA) authorized its use in cases of hidradenitis suppurativa [40].

Table 1 Biologic therapies.

Reference Author, year, journal	LoE	Number of cases	Type of treatment (number of cases)	Duration of treatment (months)	Follow-up	Scale used	Results (HS = Hurley Stage) +++ complete improvement ++ significant improvement + mild improvement 0 poor or no improvement	Complications
Sbidian et al., 2015, Br J Dermatol [35]	4	67	Infliximab 5 mg/kg (57) Adalimumab 40 mg ev. 2w (7) Etanercept 50 mg × 2/w (2)	NA	7	NA	HS 2—3: 12% +++; 46% ++/+; 42% 0 ADA > IFX et ETA	6% severe: 1 hepatitis 1 lupus 1 urinary infection 1 pulmonary embolism
Sand and Thomsen, 2015, Dermatol Ther [16]	4	29	Adalimumab, etanercept, infliximab, certolizumab (various combination)	13	NA	NA	Resistant HS 3: 52% +++/++/+	Total 31% Severe 27%: 5 infections 1 visual disturb 1 sebopsoriasis 1 neurologic symptom.
Zhang et al., 2014, Br J Dermatol [34]	4	22	Infliximab (15) Adalimumab (7) (various plans)	1—36	1—36	Patient report	HS 2—3: 50% ++; 17%+; 33% 0 (global) 73% ++/+ infliximab 43%++/+ adalimumab	41% 3 Inf. site reac., 2 fatigue, 1 HSV rec. 1 grave anaph 1 hearth failure 1 lung cancer (†) 1 metastasis SCC (†)
Moriarty et al., 2014, Br J Dermatol [23]	4	11	Infliximab 5 mg/kg (w0.2 + ev.4w)	49	60	DLQI VAS PCA	Resistant HS 3: 100% ++/+ (initial) 82% ++/+ at 60 months (ev.4w)	82% (9/11): 8 infections 1 hodgkin lymphoma
Martin-Ezquerra et al., 2014, J Eur Acad Dermatol Venereol [33]	4	19	Adalimumab (9) Infliximab (7) Ustekinumab (2) Etanercept (1)	12	NA	PCA VAS	Resistant HS 2—3: 15.7% +++; 55% ++/+; 32% 0 (global)	11% 1 infusion site reaction 1 hypertriglyceridemia
Chinniah and Cains, 2014, Australas J Dermatol [27]	4	6	Adalimumab (3) Etanercept (1) Infliximab (4)	NA	NA	NA	HS 3: Adalimumab 2/3 +++/++/+ Etanercept 1/1 +++/++/+ Infliximab 3/4 +++/++/+	1 neurological symptoms
Kimball et al., 2012, Ann Intern Med [17]	1b	154	Adalimumab 40 mg/w or 40 mg ev. 2w vs placebo	12	12	PGA	Resistant HS 2—3: 17% ++/+(weekly). $P = 0.025$ vs placebo 10% ++/+(eow)	Global 64% or 71%. Serious (6% or 8%): infection, anemia

Table 1 (*Continued*)

Reference Author, year, journal	LoE	Number of cases	Type of treatment (number of cases)	Duration of treatment (months)	Follow-up	Scale used	Results (HS = Hurley Stage) +++ complete improvement ++ significant improvement + mild improvement 0 poor or no improvement	Complications
Lesage et al., 2012, Eur J Dermatol [36]	4	10	Infliximab 5 mg/kg (w0,2,6 + ev.4w)	12	12	DLQI	Resistant HS 2—3: 100% ++/+	60% (6/10): 4 × minor infection 1 hepatitis 1 keratoacanthoma
Sotiriou et al., 2012, J Drugs Dermatol [25]	4	15	Adalimumab 80 mg w0 + 40 mg weekly	6	12	Sartorius, VAS, DLQI	HS 2—3: Significant improvement during treatment Relapse 11w after cessation	NA
Paradela et al., 2012, J Dermatolog Treat [21]	4	10	Infliximab 5 mg/kg (w0,2,6 + ev.8w)	11	NA	Recurrence	Resistant HS 2—3: 80% ++/+ 50% relapse after 8 m	No life-threatening complication
Van Rappard et al., 2012, J Dermatolog Treat [87]	4	20	Infliximab (10) 5 mg/kg w0,2,6 Adalimumab (10) 40 mg ev. 2w	1.5	12	Sartorius, DLQI, PGA, PaGA	Resistant HS 2—3: Sartorius score reduction IFX > ADA	NA
Miller et al., 2011, Br J Dermatol [18]	1b	21	Adalimumab 80 mg w0, 40 mg ev. 2w vs placebo	3	6	Sartorius, HSS, VAS, DLQI,	HS 2—3: Significant improvement vs placebo Effect disappear 3 months post-treat	Mild infections
Delage et al., 2011, Acta Derm Venereol [88]	4	7	Infliximab 5 mg/kg (w0,2,6 + ev. 8w)	10	18	DLQI, PaGA	Resistant HS 2—3: 71% (5/7) ++; 14% +; 14% 0	29% (2/7): 1 skin eruption 1 cervical abscess
Amano et al., 2010, Int J Dermatol [89]	4	10	Adalimumab 160 mg w0, 80 mg w1, 40 mg ev.2w	3	3 + 1 w	HSSI, VAS, DLQI, PGA	Resistant HS 2—3: 60%+ 40% 0	0
Arenbergerova et al., 2010, Int J Dermatol [26]	4	8	Adalimumab 80 mg w0, 40 mg w1, 40 mg ev. 2w	12	24	VAS	Resistant HS 2—3: 100% ++ 63% relapse at 9.5 m	1 EBV reactivation
Adams et al., 2010, Arch Dermatol [19]	1b	20	Etanercept 50 mg × 2/w vs placebo	24	24	PGA, PaGA, DLQI	HS 2—3: No significant efficacy of etanercept vs placebo	No severe complication (mild injection site reactions)
Grant et al., 2010, J Am Acad Dermatol [20]	1b	38	Infliximab 5 mg/kg (w 0,2,6,14,22) vs placebo	7	12—14	HSSI, DLQI, VAS, PGA	Resistant HS 2—3: (PGA) 7% +++; 47% ++; 34%+ 12% 0 Improvement in pain, severity, QoL ($P < 0.05$) vs placebo	Influenza-like syndrome

Table 1 (*Continued*)

Reference Author, year, journal	LoE	Number of cases	Type of treatment (number of cases)	Duration of treatment (months)	Follow-up	Scale used	Results (HS = Hurley Stage) +++ complete improvement ++ significant improvement + mild improvement 0 poor or no improvement	Complications
Pelekanou et al., 2010, Exp Dermatol [90]	4	10	Etanercept 50 mg/w	3	36	Recurrence, sartorius	60% ++; 30%+; 10% 0 30% long term remission	1 abscess
Blanco et al., 2009, Arch Dermatol [91]	4	6	Adalimumab 40 mg ev. 2w	22	22	DLQI,	Resistant HS 3: 100% ++	1 facial cellulitis
Sotiriou et al., 2009, Acta Derm Venereol [28]	4	4	Etanercept 25 mg × 2/w	6	9	Sartorius, DLQI	Resistant HS 2—3: 100% ++	1 mild injection site reaction
Lee et al., 2009, J Am Acad Dermatol [31]	4	15	Etanercept 50 mg/w	3	4	PGA, DLQI	HS 2—3: 29% ++; 29%+ 42% 0	No serious event, 14/15 mild complication (infections)
Brunasso et al., 2008, Br J Dermatol [92]	4	7	Infliximab 5 mg/kg (w0,2,6 + ev 8w) max 14×/72w	14	27	Sartorius, VAS, DLQI	Resistant HS 2—3: 100% ++/+; 0% 0 Improvement decrease linearly in time	1/7 global
Giamarellos-Bourboulis et al., 2008, Br J Dermatol [29]	4	10	Etanercept 50 mg/w	3	6	Sartorius, VAS	60% ++, 40%+	1/10 infection
Mekkes and Bos, 2008, Br J Dermatol [22]	4	10	Infliximab 5 mg/kg (w0,2,6)	1.5	12	PaGA, DLQI	Resistant HS 2—3: 30% (3/10) +++; 40% ++; 30%+ 0% 0 Recurrence: 8.5 months	30%: 1 neuropathy 1 anaphylactic shock 1 myalgia fever
Strober et al., 2007, J Am Acad Dermatol [32]	4	5	Efalizumab 0.7 mg/kg w0,1 + 1 mg/kg w2—11	3	3-6	Lesion count	Resistant HS: 0% +++/++/+; 100% 0	1 breast cancer 1 weight loss + anemia
Fernandez-Vozmediano and Armario-Hita, 2007, Dermatology [93]	4	6	Infliximab 5—10 mg/kg (w0,2,6 + ev 4w)	NA	6	PGA	Resistant HS 3: 67% (4/6) ++; 33%+ 0% 0	17%: 1 headache
Fardet et al., 2007, J Am Acad Dermatol [24]	4	7	Infliximab 5 mg/kg (w0,2,6,10)	1.5—2.5	2.5	Sartorius, PaGA, PGA, Skindex29	Resistant HS 3: 29% (2/7) ++; 43%+ 29% 0	43%: 1 neuropathy 1 colon cancer 1 severe allergy
Cusack and Buckley, 2006, Br J Dermatol [30]	4	6	Etanercept 25 mg × 2/w	6	3—6	DLQI	Resistant HS 3: 100% ++ (mean improvement 60%)	1 mild infection

PGA: physician's global assessment; PaGA: patients' global assessment; DLQI: dermatology life quality index; VAS: visual analogue scale of pain intensity; PCA: physician's clinical assessment; HSSI: HS severity index; HS: Hurley stage.

Antibiotherapies

Seven articles have studied the efficacy of systemically administered antibiotics (Table 2). The ineffectiveness of local antibiotics on deep lesions (abscesses, nodules, fistulas) is long since established; according to Clemmensen [41], they only yield improvement for superficial pustules. Hidradenitis suppurativa may be defined not as an infectious disease, but rather as a chronic inflammatory disease in which polymorphic bacterial flora [42] dominated by coagulase-negative staphylococci (*epidermidis, haemolyticus, hominis, lugdunensis*) and the anaerobic equivalent of staphylococci (*propinobecterium, fusobacterium, bacteroides*...) possess an important proinflammatory role that has yet to be clearly elucidated.

In addition to eradicating bacteria, antibiotics are highly likely to possess a complex role as immunomodulators (mainly on T lymphocytes), which might — to some extent — explain their action [43,44].

The diversity and particularity of these bacterial strains impose a broad-spectrum and combined treatment so as to avoid the development of resistances during prolonged periods of use.

More specifically, in 2006, the association of clindamycin and rifampicin was studied for the first time by Mendoça [45] in an evaluation of this dual therapy as treatment of another pathology, *folliculitis decalvans*. Dosage was 600 mg a day for each of the molecules during 10 weeks. Out of 14 patients, 10 (71%) benefited from complete remission with 1 to 4 years of follow-up, and due to diarrheas, the 4 others could not finish treatment. In addition to these generally satisfactory results, other teams attested to the efficacy of this association on hidradenitis suppurativa ; out of 116 patients, Gener et al. observed complete or significant improvement in 66%, with a decrease of the median Sartorius score from 29 to 14.5 in 10 weeks ($P < 0.001$) [44]. Van der Zee et al. reported comparable efficacy, with a response rate of 82% and a remission rate of 47%. They also studied dual therapy duration without finding any difference between a small treatment (fewer than 10 weeks) and treatment lasting at least 10 weeks [43]. And in 2014, applying the usual schema, Bettoli reported no less than 85% of good responders [46]. The main complications of this association consist in the digestive symptoms (nauseas, abdominal pains, diarrhea) reported in 13 to 43% of patients.

Another multi-drug regimen was analyzed by Join-Lambert et al. [47] in a retrospective study: rifampicin 10 mg/kg, moxifloxacin 400 mg and metronidazol 500 mg × 3 a day, administered in tritherapy for 6 weeks and subsequently in dual therapy without metronidazol as long as improvement remained palpable. While the complete remission rate was very good (57%), treatment duration was rather long (1 to 7 months), with frequent occurrence of digestive complications (64%) and candidosis.

Dapsone (sulfate family) has also been studied. Its multiple properties are once antibiotic and anti-inflammatory. Over the last 10 years, two retrospective studies have been published. In a small series (5 cases), Kaur et al. reported a 100% response rate with no remissions [48]. In 2011, Yazdaniar et al. emphasized its limited efficacy, with only a 38% response rate, and no remission in 24 patients [49].

Dynamic phototherapy or photodynamic therapy (PDT)

Dynamic phototherapy consists in the association of a photosensitizing molecule with a light source possibly provoking cell damage. In and of itself, the photosensitizer is not toxic, but it has the capacity to absorb a photon whose length is adapted to its properties, thereby provoking a series of photo-oxidative reactions leading to local tissue damage in its immediate surroundings. The light source may be monochromatic (Laser or a less powerful light-emitting diode: LED) or polychromatic (intense pulsed light: IPL).

Application of this technique in treatment of hidradenitis suppurativa has been imagined by analogy with the satisfactory results observed in open-label studies on PDT in the treatment of acne, a disease with similar pathogenesis. Its efficacy is based on the hypothesis that as with acne, follicular obstruction occurs in hidradenitis suppurativa. The photosensitizer and the light facilitate destruction of the hair follicle, thereby reducing follicular obstruction and sebum retention and possibly also having an antibacterial and immunomodulatory effect.

The conventionally applied schema for acne treatment includes application of 5-aminolevulinic acid (ALA, the photosensitizer) as a 20% concentrate ointment acting on lesions for 45 minutes to 3 hours. It is followed by irradiation with monochromatic red light (Laser or LED 633 nm) or polychromatic (pulsated light) that contains in its spectrum a number of photons at 633 nm that serve as activators of ALA. Sessions are renewed ever 1 to 4 weeks for 1 to 2 months.

The studies having applied this schema to the disease presently under consideration [50—53] have yielded disparate results (Table 3): While Sotiriou et al. [52] et Strauss et al. [53] report no efficacy, Andino-Navarrete et al. [50] found significant improvement in the five patients studied, and the positive effect persisted 8 weeks after treatment cessation. Similarly, Calzavara-Pinton et al. [51] reported 83% (5 out of 6) patients as responders, but only one of the responses was reiterated subsequent to cessation. ALA tolerance was relatively satisfactory, notwithstanding local reactions including pain and virtually systematic cutaneous burns.

The lesser efficacy of this treatment compared to that observed in its use against acne can be explained by the depth of the lesions characterizing hidradenitis suppurativa. The photosensitizer does not penetrate inside the fistulas and the red light is not embedded at more than 1 cm inside the tissues.

To avoid this handicap, Valderes-Nargenes et al. [54] used the classic ALA + red light combination, but treatment was intralesional. When the photosensitizer is injected in the fistulas and light is brought into them using optical fiber, the efficacy of PDT is enhanced. Out of 27 patients, 96% were responders, while 78% showed significant or complete improvement at 6 months after only one or two sessions.

Other photosensitizers have been tested (Table 3):

- methylene blue gel: used by ten patients, it yielded significant improvement in 80% of the cases [55]. It seems well-tolerated;

Table 2 Systemic antibiotics.

Reference Author, year, journal	LoE	Number of cases	Type of treatment	Duration of treatment (months)	Follow-up (months)	Classification used	Results (HS = Hurley Stage) +++ complete improvement ++ significant improvement + mild/moderate improvement 0 poor or no improvement	Complications
Bettoli et al., 2014, J Eur Acad Dermatol Venereol [46]	4	23	Clindamycin 600 + rifampicin 600	2.5	2.5	Sartorius score, number of exacerbation	HS 1—3:46% reduction of sartorius score ($P < 0.01$), 60% reduction of exacerbation ($P < 0.001$) 85% +++/++; 15% + /0	Digestive symptoms: 13%
Yazdanyar et al., 2011, Dermatology [49]	4	24	Dapsone 100 (50—200)	1—48	NA	PGA	HS 1—3: 25% (6/24) ++; 13%+ 62% 0	46%: nausea, dizziness, tiredness, headache
Join-Lambert et al., 2011, Dermatology [47]	4	28	Rifampicin 10 mg/kg+ Moxifloxacin 400+ Metronidazole 500 × 3	1.5	2—6	HSS	HS 1—3: 57% (16/28) +++; 43% ++/+ (HS 1/2/3 = 100/80/12%: $P = 0.01$)	Digestive symptoms 64%, vaginal candidosis 35% (female), tendinitis (14%)
Van der Zee et al., 2009, Dermatology [43]	4	34	Clindamycin + Rifampicin (different dosages)	Different duration	±12	PGA	HS 1—3: 47% +++; 35%+++; 18% 0	Global 38%
Gener et al., 2009, Dermatology [44]	4	116	Clindamycin 600+ Rifampicin 600	2.5	NA	Sartorius, Skindex	HS 1—3: 11% +++; 55% ++; 27%+ 7% 0 Decrease Sartorius $P < 0.001$, 14.5 vs 29	Digestive symptoms 14% Skin eruption 1%
Kaur and Lewis, 2006, J Dermatol Treat [48]	4	5	Dapsone 25—150	1—3	24	PaGA	100% (5/5) ++/+	0%
Mendonça and Griffiths, 2006, Br J Dermatol [45]	4	14	Clindamycin 600+ Rifampicin 600	2.5	12—48	NA	71% (10/14) +++ No recurrence for 1—4 y	Diarrhea 43%

PGA: physician's global assessment; PaGA: patients' global assessment; HS: Hurley stage.

Table 3 Photodynamic therapies.

Reference Author, year, journal	LoE	Number of cases	Type of treatment	Duration of treatment (months)	Follow-up (months)	Classification used	Conclusion	Complications
Fadel and Tawfik, 2015, Clin Exp Dermatol [55]	4+	10	Methylene blue 0.01% gel (niosomal or free) + IPL 630 nm ev. 2 w	6	12	HS-LASI	Resistant HS 1—3: 80% ++; 10%+ 10% 0 Niosomal MB > free MB ($P < 0.01$)	0
Valadares-Nargenes et al., 2015, Br J Dermatol [54]	4	27	Intralesional 5-aminolaevulinic acid 1% + intralesional laser 633 nm diode 3 h later	1 or 2 times	6	Sartorius scale	37% +++; 41% ++; 19%+ 4% 0	Pain, erythema, swelling 1 influenza-like illness
Andino-Navarrete et al., 2013, Actas Dermosifiliogr [50]	4	5	5-aminolaevulinic acid 20% +635 nm red light source 1.5 h later, ev. 1—2w	1—2	2	Sartorius scale, DLQI, VAS	Resistant HS 2—3: 100% ++ Effect persists after 8 w	2/5 (40%) mild burning sensation
Calzavara-Pinton et al., 2013, Photochem Photobiol Sci [51]	4	6	Methyl aminolevulinate 1 mm layer + 635 nm red light or polychromatic source, ev. 2—4w	#2	2.6	PGA	33% ++; 50%+ 17% 0 17% (1 case) persistent response	100% pain or burning during treatment
Highton et al., 2011, Plastic Reconstr Surg [57]	2b	18	IPL 420 nm 2 ×/w	1	12	Sartorius, PaGA	HS 2—3: 17% +++; 59% ++; 24%+ 0 Severity score −55% (m0), −56% (m3), −44% (m6), −33% (m12 after treatment) Significant compared to no IPL ($P < 0.001$)	Minimal discomfort 0 complication
Schweiger et al., 2011, J Drugs Dermatol [94]	4	12	5-aminolevulinic acid 20% + blue light source or IPL 45′ after, 1 ×/w	1	4—14	Sartorius, DLQI	25% +++; Efficacity during treatment but partial relapse after end	Tolerance: blue light > IPL
Shareef and Dawe, 2011, Br J Dermatol [56]	4	13	PUVA therapy: 8-methoxypsoralen bath + UVA 2 x/w with rising dose	3	3	DLQI,	Resistant HS: 36% +++/++; 32%+ 32% 0	15% 1 erythema 1 claustrophobia
Sotiriou et al., 2009, Clin Exp Dermatol [52]	4	5	5-aminolevulinic acid 20% + red light 570—670 nm 3 h later 4 treatment ev 2 w	2	4	Sartorius, VAS, DLQI	0%+++/++; 100%+0	100% superficial burn
Passeron et al., 2009, J Dermatolog Treat [58]	4	4	Pulsed dye laser mediated PDT (PDL-PDT)	NA	3	NA	0% ++/+; 100% 0	100% intense pain
Strauss et al., 2005, Br J Dermatol [53]	4	4	Aminolaevulinic acid 20% + red light (laser 633 nm or broadband 570-670 nm) × 1/w	1	2	Sartorius, VAS	0% ++/+; 100% 0	100% superficial burn

PGA: physician's global assessment; PaGA: patients' global assessment; DLQI: dermatology life quality index; VAS: visual analogue scale of pain intensity; HS: Hurley stage; HS-LASI: HS lesion area severity index.

- psoralen bath solution, with activation by ultraviolet A (Balneo PUVA therapy used in psoriasis treatment): Its efficacy is low; among 13 patients, a third of the results were good to excellent, a third of the results were average, and a third of the results were nil [56]. That much said, tolerance was very good.

Highton et al. [57] studied pulsed light alone in intensive use (2 times a week for 1 month) in 18 patients. The results were encouraging (complete or partial improvement: 76%), and tolerance was excellent. Lastly, Passeron et al. [58] explored the use of PDT by pulsed dye Laser (PDT) and obtained no positive result.

To conclude, it is difficult to harmonize the different results in view of developing a relevant treatment plan. That much said, the absence of any severe adverse effect should allow experienced teams to apply these treatments in cases of hidradenitis suppurativa resistant to conventional treatments, even if the efficacy of the different PDTs has yet to be conclusively proven.

Retinoids

The retinoid class of drugs comprises different molecules derived from vitamin A (retinol) such as acitretin and isotretinoin. Their regulatory action on keratinocyte growth and/or sebaceous gland maturation explains their use in numerous cutaneous conditions including psoriasis and acne. The pathogenesis common to acne and hidradenitis suppurativa, follicular occlusion, has prompted several teams to test the efficacy of retinoids in hidradenitis suppurativa patients (Table 4).

Questions regarding isotretinoin were settled for once and for all in 2009 by Soria et al. [59]. While highly effective for acne, the molecule is almost totally ineffective for hidradenitis suppurativa, with a mere 16% of responders among 88 treated patients. The explanation of this failure is pharmacological; it is on the size and the secretion of the sebaceous glands that isotretinoin has a predominant effect; in the disease under consideration in this review, serum secretion does not increase.

As for acitretin, which has received market authorization for psoriasis treatment, lichen planus and severe keratinization disorders, subsequent to previous case reports over the past 10 years it has been studied by two teams [60,61]. In a retrospective study, Boer et al. reexamined 12 patients having been treated for 9 to 12 months with a mean dose of 0.59 mg/kg/day. Efficacy was satisfactory: responses in 100% of the cases, significant improvement in 75%, and an effect that persisted after treatment cessation [61]. Matusiak et al. reapplied this protocol (0.5—0.6 mg/kg/day for 9 months) in a prospective study of 17 patients. While efficacy remained satisfactory (responses in 65% of the cases, including 53% of major or complete improvement), the effect did not prove durable [60].

All of the retinoids have frequent adverse effects; while none of the latter are truly serious, many are quite bothersome: practically constant cutaneomucosal xerosis, loss of hair, headaches, tinnitus, depressions and lipid disorders have all been reported, at times occasioning the suspension of treatments. The other factor militating against the use of retinoids is their teratogenic effect, which has led to restrictions on prescriptions for women of childbearing age. Acitretin has a rather short half-life, limited to a few days, but it accumulates in adipose tissue. And when alcohol is present, a metabolite with a very long half-life (175 days), etretinate, is produced [62]. During treatment and over the 2 years following cessation, reliable contraceptive precautions are mandatory [63].

That is why, in 2015, a retinoid with a shorter half-life (2—10 hours), alitretinoin, which has been given market authorization for hand eczema, was tested by the team of Verdolini [64] in an open study involving 14 patients. While contraception in women remains indispensable, pregnancy can be envisioned as soon as 1 month after the end of treatment. Its efficacy seems comparable to that of acitretin, with improvement in 78.5% of the patients. However, the molecule is pronouncedly less affordable; in France, the daily cost of treatment is ten times higher than with acitretin.

Anti-androgens

Hormonal influences in hidradenitis suppurativa have been suggested due to a number of relevant factors: female predominance, association with the polycystic ovary syndrome (hyperproduction of androgens) and hirsutism, diminution of symptoms after menopause and presence of androgen receptors in the apocrine sweat glands (Table 5).

During the 1980s, several studies [65—67] highlighted the benefits provided by cyproterone acetate and estrogens in treatment of hidradenitis suppurativa. In a study published in 2007, Kraft [68] reported that 55% of women were responders to cyproterone acetate.

Another anti-androgen drug, finasteride (inhibitor of 5-α reductase), also used in treatment of benign prostatic hyperplasia and androgenetic alpoecia, has been studied by Joseph et al. [69]. They pointed to complete remission or partial improvement in 86% of the patients under consideration, but there were only seven of them.

Lastly, spironolactone, which is better known as a potassium-sparing diuretic, also possesses anti-androgenic activity. Lee et al. [70] studied in 20 female patients their daily intake of 100 mg of spironolactone, and efficacy was excellent: 85% of responders, including 55% of complete remission with satisfactory tolerance.

Notwithstanding the limited populations and the diversity of existing molecules studied, anti-androgens seem effective enough. However, these molecules are addressed primarily to women; as for men, they are often subject to debilitating adverse effects (decline in libido, impotency, gynecomastia...).

Anti-inflammatory drugs

Hidradenitis suppurativa is a chronic inflammatory disease characterized by deregulation of the innate and adaptive immune system. That is the main reason why numerous immunosuppressive and immunomodulatory treatments have been studied (Table 6).

Cyclosporin A is an inhibitor of the calcineurin routinely used as an anti-rejection treatment. It specifically targets lymphocytes, of which a large number are likely to be present in damaged follicles [71]. A single retrospective series [72] has explored this molecule in refractory hidradenitis

Table 4 Retinoids.

Reference Author, year, journal	LoE	Number of cases	Type of treatment	Duration of treatment (months)	Follow-up (months)	Classification used	Conclusion	Complications
Verdolini et al., 2015, G Ital Dermatol Venereol [64]	4	14	Alitretinoin 10 mg/d	6	6	Sartorius, DLQI	Resistant HS: 78.5% +++/++/+; 11.5% 0	NA
Matusiak et al., 2014, Br J Dermatol [60]	4	17	Acitretin 0.5—0.6 mg/kg/d	9	9	HSSI, HSS, PGA, DLQI	Resistant HS 2-3: 6% +++; 47% ++; 12%+ 35% 0 No long-lasting effectiveness	3 severe dermatitis 1 hair loss 1 visual acuity decrease
Boer and Nazari, 2011, Br J Dermatol [61]	4	12	Acitretin 0.59 mg/kg/d	9—12	48	VAS, PGA	Resistant HS 2—3: 75% ++; 25%+; 0% 0 75% long lasting effect (6—45 months)	100%: 100%Cheilitis 3 hair loss 1 depression and fatigue 1 ear buzzing 1 headache 5 lipid elevation
Soria et al., 2009, Dermatology [59]	4	88	Isotretinoin 44 mg/kg/d	8	NA	PaGA	16% ++/+; 84% 0	NA

PGA: physician's global assessment; PaGA: patients' global assessment; DLQI: dermatology life quality index; VAS: visual analogue scale of pain intensity; HSSI: HS severity index; HS: Hurley stage.

Table 5 Antiandrogenes.

Reference Author, year, journal	LoE	Number of cases	Type of treatment	Duration of treatment (months)	Follow-up (months)	Classification used	Conclusion	Complications
Lee and Fischer, 2015, Australas J Dermatol [70]	4	20	Spironolactone 100 mg/d	3	3	PGA	Female patient with HS 1—3: 55% +++; 30% ++/+; 15% 0	1 dizziness
Kraft and Searles, 2007, J Cutan Med Surg [68]	4	64	Cyproterone acetate (2—25 mg/d)	NA	NA	NA	Female patient HS: 55%+++/++/+; 45% 0	NA
Joseph et al., 2005, J Dermatol Treat [69]	4	7	Finasteride 5 mg/d	NA	8—24	NA	Resistant HS: 43% +++; 43% ++/+; 14% 0	2/7 breast enlargement

PGA: physician's global assessment; HS: Hurley stage.

Table 6 Anti-inflammatory drugs.

Reference Author, year, journal	LoE	Number of cases	Type of treatment	Duration of treatment (months)	Follow-up (months)	Classification used	Conclusion	Complications
Anderson et al., 2016, J Dermatol Treat [72]	4	18	Cyclosporin A 2.0—3.5 mg/kg/d	0.5—24	NA	PGA	Resistant HS 2—3: 11% ++; 39% + 50% 0	61%: 4 digestive symptoms 3 headache palpitation, tiredness...
Leslie et al., 2014, Am Acad Dermatol [73]	4	6	Anakinra SC 100 mg/d	2	4	Sartorius scale, PGA, VAS, SF36, DLQI	HS 2—3: 83% ++; 17% + 0% 0 at treatment end 100% 0, 2 months later	100% injection-site reaction
Van der Zee and Prens, 2011, Dermatology [74]	4	8	Colchicine 0.5 mg × 2—3/d	1—4	1—4	PGA	Resistant HS: 0%+++/++; 38%+; 62% 0	3/8 digestive symptoms

PGA: physician's global assessment; DLQI: dermatology life quality index; VAS: visual analogue scale of pain intensity; HS: Hurley stage; SF36: short-form (36) health survey.

suppurativa in 18 patients. Dosage was between 2.0 and 3.5 mg/kg by day over a period ranging from 15 days to 2 years. While response rate was 50%, only in 11% of cases did pronounced improvement occur, and tolerance was mediocre (digestive problems, headaches, high blood pressure, palpitations, fatigue...).

Anakinra is an antagonist of interleukin 1 (IL-1) receptors that is used as a drug of last resort in cases of rheumatoid polyarthritis and in a number of orphan diseases (cryopyrinopathies). On this subject, all we have found is a series of six cases published in 2014 by Leslie et al. [73]. After 2 months of treatment (100 mg/day), 100% of the patients were responders, with pronounced improvement 83% of the time. Tolerance was very good. Unfortunately, 2 months after the end of treatment, all of the disease's parameters of activity had reverted to their initial values. Lengthier treatment regimens must consequently be tested.

Colchicine is an anti-inflammatory drug (inhibition of the polynuclear neutrophils by disorganization of their cytoskeleton) that is routinely used not only in treatment of gout, but also in cases of inherited diseases and Behçet's disease. Suspicion of physiopathogenesis common to these pathologies and hidradenitis suppurativa led Van der Zee's team to try to assess the efficacy of colchicine [74] at the dose usually prescribed in treatment of gout attacks (1 to 1.5 mg/day) for 1 to 4 months. Most of the patients (5 out of 8) noted no change, and the other saw only slight improvement. In addition, digestive tolerance was poor; in 3 out of the 8 cases (38%), discomforting symptoms appeared (nauseas, diarrhea). Colchicine is consequently not a treatment of choice for hidradenitis suppurativa.

Zinc

Zinc gluconate is used as a second-line treatment in cases of minimum-to-moderate inflammatory acne at doses of 30 to 60 mg/day. By extrapolation, in an open study, the Brocard team assessed the efficacy of high-dose (90 mg/day) zinc gluconate treatment in 22 Hurley stage I or stage II patients [75] (Table 7). In all cases, their symptoms were alleviated, and 36% of them enjoyed complete remission. But when the doses were diminished, recurrences invariably occurred. According to Brocard et al., the efficacy of zinc salts in treatment of acne and hidradenitis suppurativa is due to their multiple, anti-androgenic anti-inflammatory properties. And so, on the basis of a single open study, zinc gluconate may be considered as a potentially effective treatment option in cases of mild-to-moderate hidradenitis suppurativa. Indeed, even though its action may seem merely suspensive, due to its good tolerance profile (only minor digestive problems) its prolonged use may be envisioned.

Metformin

Metformin is a major oral antidiabetic drug whose action consists in diminishing insulin resistance. The team led by Verdolini took note of the importance of excess weight, glucose intolerance, diabetes and polycystic ovary syndrome (hyperandrogenism and insulin resistance) in hidradenitis suppurativa patients (Table 8). In an open study, a dose of 1000 to 1500 mg of Metformin a day was administered to 25 patients for 6 months [76]. Among their patients, 76%

Table 7 Zinc gluconate.

Reference Author, year, journal	LoE	Number of cases	Type of treatment	Duration of treatment (months)	Follow-up (months)	Classification used	Conclusion	Complications
Brocard et al., 2007, Dermatology [75]	4	22	Zinc gluconate 90 mg/d	NA	24	PGA	Resistant HS 1—2: 36%+++; 72%++/+; 0% 0 Suppressive action	18% digestive symptoms (diarrhea, oesophagitis, nausea, abdominal distension)

PGA: physician's global assessment; HS: Hurley stage.

Table 8 Metformin.

Reference Author, year, journal	LoE	Number of cases	Type of treatment	Duration of treatment (months)	Follow-up (months)	Classification used	Conclusion	Complications
Verdolini et al., 2013, J Eur Acad Dermatol Venereol [76]	4	25	Metformin 1000—1500 mg/d	6	6	Sartorius, DLQI	Resistant HS: 48% ++; 28%+; 24% 0	Minor digestive disturbance at the beginning

DLQI: dermatology life quality index; HS: Hurley stage.

were responders, with 48% of them presenting pronounced improvement (50% Sartorius score diminution); tolerance was excellent (some minor digestive discomfort). Even though its mechanism of action on hidradenitis suppurativa has yet to be fully elucidated, its efficacy is apparently due to both lowered insulin resistance and its anti-androgenic effect. To summarize, metformin seems to have a positive impact on hidradenitis suppurativa symptoms; moreover, its safety for use over lengthy periods of time has been clearly and repeatedly established, a factor of major importance in treatment of a chronic disease. Last but not least, it is quite inexpensive. However, no other study has confirmed these encouraging results.

Fumarates

Monomethyl and dimethyl fumarate are fungicides used in industry to protect manufactured products from mold or mildew. They are also used in some countries as an oral treatment for psoriasis by means of an anti-inflammatory and immunomodulatory mechanism. By analogy with this widespread form of dermatosis, Deckers et al. [77] studied fumaric acid salts in cases of hidradenitis suppurativa according to the same dose-escalation protocol (from 30 to 720 mg/day for 9 weeks) as in treatment of psoriasis (Table 9). The results were disappointing inasmuch as only two out of seven patients experienced major improvement, while one had minor improvement and the four others either remained unchanged, or else suffered aggravated symptoms. Moreover, tolerance was very poor, with numerous adverse effects (digestive, cutaneous, general...).

Intramuscular immuno-globulins

Multivalent human immuno-globulins (antibodies) are frequently used in treatment to induce passive humoral immunity in immuno-depressed patients; they are also employed due to their immunomodulatory properties in patients with autoimmune diseases. Their impact could be of interest with regard to hidradenitis suppurativa. In his Seoul ward, Goo reviewed all patients being treated with human immuno-globulins for suppurative cutaneous pathologies [78] (Table 10). Five had hidradenitis suppurativa. With one intramuscular injection of approximately 0.15 mL/kg a month, four of them presented pronounced improvement > 50%, while the fifth remained stationary. Tolerance was relatively satisfactory, albeit with some pain at the injection site. However, the high cost of the treatment was a major obstacle. As no specific prospective study on hidradenitis suppurativa has been conducted, the above observations have yet to be confirmed.

Laser

Laser therapies constitute an approach-situated midway between conventional surgery and classic systemic treatments (Table 11).

Laser CO_2 has a thermic effect. It emits coherent infrared radiation with a wave-length of 10.6 μm. The main target, known as the chromophore, is water (and, consequently, living tissue). It functions either by directly vaporizing the lesions, which are removed by layers of variable thickness (simple opening/deroofing or total ablation) or using a scalpel with which large sections of diseased tissues are

Table 9 Fumarates.

Reference Author, year, journal	LoE	Number of cases	Type of treatment	Duration of treatment (months)	Follow-up (months)	Classification used	Conclusion	Complications
Deckers et al., 2015, Br J Dermatol [77]	4	7	Fumarates Progressive 30 to 720 mg/d	7–12	7–12	PGA	Resistant HS 2–3: 29% ++; 14%+; 57% 0	85% flushing 57% digestive symptoms 43% fatigue + pruritus, disagreeable skin sensation, lymphopenia, increased creatinine

PGA: physician's global assessment; HS: Hurley stage.

Table 10 Gamma-globulines.

Reference Author, year, journal	LoE	Number of cases	Type of treatment	Duration of treatment (months)	Follow-up (months)	Classification used	Conclusion	Complications
Goo et al., 2007, Br J Dermatol [78]	4	5	IM human immunoglobulin 1×/m	1–15 (3.5 m)	NA	PGA	80%++; 20% 0	50% injection site pain Erythema

PGA: physician's global assessment.

Table 11 LASER therapies.

Reference Author, year, journal	LoE	Number of cases	Type of treatment	Duration of treatment (months)	Follow-up (months)	Classification used	Conclusion	Complications
Mikkelsen et al., 2015, Dermatol Surg [79]	4	58	CO_2 laser evaporation	x1	25.7	Recurence, satisfaction	71% +++; 24% ++/+; 5% 0 29% recurrence at 12.7 m	NA
Jain and Jain, 2012, J Cutan Aesthet Surg [83]	4	4	Combined 1064 nm Nd:YAG laser + CO_2 laser 15d later	0.5	12	None	100% +++	0
Mahmoud et al., 2010, J Am Acad Dermatol [82]	2b	22	Long-pulsed Nd:YAG laser x4 ev. month	4	6	Sartorius	HS 2: 90% ++/+; 10% 0 Sartorius score—72% ($P < 0.001$) at m.6	40% mild pain
Hazen and Hazen, 2010, Dermatol Surg [80]	4	61	CO_2 laser excision and marsupialization	1—2x	1—19 years	NA	99% +++; 1% ++/+	NA
Madan et al., 2008, Br J Dermatol [81]	4	9	CO_2 laser (LA or GA), evaporation and excision	x1	12	PaGA	Resistant HS: 78% +++; 22% ++	± pain 2/9 scar contracture 1/9 wound dehiscence

PaGA: patients' global assessment; HS: Hurley stage.

removed. It also has a local hemostatic effect. All in all, Laser CO_2 possesses an ablative mechanism of action identical to that of surgery permitting a more targeted peripheral and in-depth approach. As with surgery, there is a single intervention, under anesthesia that may be local, but it is general when extended areas are involved. Then, lesions are followed in controlled healing.

In three studies [79—81], its efficacy was clearly established, with 71 [79] to 99% [80] of cure. After more than 2 years of follow-up in 58 patients, Mikkelsen [79] reported a mean yearly 29% recurrence rate. The only side effects with Laser consisted in non-specific postoperative pain.

The other type of Laser having been studied is long pulse Nd:YAG (*neodymium-doped yttrium aluminum garnet*). The chromophore is melanin. It is used as depilatory Laser with the objective of destroying the pilosebaceous follicle by photothermal effect. Its justification resides in the follicular origin of hidradenitis suppurativa. Mahmoud et al. [82] tested it over a month in four spaced-out sessions. While he achieved no complete remission, partial improvement occurred in 90% of the subjects, with a significantly lowered Sartorius score (72% decrease) at 6 months. The only adverse effect was moderate pain during the sessions.

Association of depilatory Nd:YAG Laser with Laser CO_2 deroofing in two separate sessions was tested by Jain and Jain [83]; while the cure rate was 100%, there were only four patients.

These instrumental techniques seem to have some effectiveness, without any systemic adverse effect. Laser CO_2 represents an alternative to surgery; it spares undamaged tissues between the lesions and provides hemostasis for small-scale blood vessels. Laser Nd:YAG is relatively non-invasive and could be associated with other systemic medical therapies in view of avoiding recourse to radical treatment; that much said, further studies are necessary, and the most deep-seated lesions are more difficultly accessible to the above-mentioned therapeutic approaches.

Discussion

Hidradenitis suppurativa management is highly complex, and no single treatment successfully addresses all stages of the disease and achieves long-term remission. Hygienic and dietary measures (tobacco cessation and weight loss) are of core importance for all patients [84].

While the literature includes numerous studies and clinical cases, articles with a high level of evidence are few and far between. It is nonetheless possible to draw a distinction between two groups of therapeutics:

- well-documented treatments with several powerful studies, some of which are controlled;
- poorly documented treatments with one or two studies having a low level of evidence, not allowing for a conclusion to be reached.

Among the treatments having been studied, those most frequently found in our review of the literature are: antibiotics, biotherapy, retinoids and instrumental techniques by dynamic phototherapy or Laser.

Firstly, there are antibiotics, of which the long history is closely associated with the theory of infectious disease. A large number of open studies have involved a sum total of 244 patients [43—49]. The level of evidence for this type of treatment is III. The most common regimen consists in an association of orally administered rifampicin 600 mg/d and clindamycin 600 mg/d during a 10-week cure, of which the efficacy has been demonstrated in four studies [43—46] in 187 patients with a significant to complete response rate ranging from 66 to 85%. However, none of these studies were controlled, and only the series of Bettoli et al. [46] was prospective. Another problematic area involves drug interactions with the enzymatic induction effect of rifampicin, effect which may lead to clindamycin degradation [85]. As concerns tolerance, digestive symptoms were frequent but by no means severe. No *Clostridium difficile* colitis appears to have occurred notwithstanding the frequent association of this ailment with clindamycin, probably due to the fact that rifampicin generally combats this species of bacteria. The other drug association (rifampicin + moxifloxacin + metronidazole) did not show any superiority, nor did dapsone. In practice, no high-level study as either confirmed the efficacy of antibiotics or determined an optimal association of drugs. Treatment has consequently remained largely empirical.

Secondly, there are biotherapies, for which the interesting results are supported by four placebo-controlled studies [17—20] with 1b level of evidence and by numerous cohort studies cumulatively involving more than 500 patients. Infliximab (Remicade®) and adalimumab, (Humira®) seem active with regard to severe and resistant forms. While infliximab is generally more effective, adalimumab possesses a better risk profile (no serious adverse effect), and is the only biotherapy approved by the health authorities in European countries and the United States. Etanercept (Enbrel®) seems less effective; a controlled study did not show its superiority to a placebo [19]. In point of fact, all published studies of biotherapies show a loss of efficacy after prolonged treatment or recurrence a longer or shorter period of time after treatment cessation [18—20,25].

TNFα blockers may consequently be said to act suspensively, but the suspension can last for several months, and even years. Their benefit is hardly negligible with regard to severe or inoperable forms, or in the event of surgery refusal. That said, the problem with biotherapies relates to their side effects, and it is of primordial importance to closely assess the benefit-risk equation and to inform the patient. As regards long-term adverse effects, we do not yet have sufficient critical perspective. To conclude, biotherapies should be reserved for the most severe forms, for forms having proven resistant to other treatments, and for situations when surgery is out of the question.

Thirdly, there are oral (*per os*) retinoids. While isotretinoin is lacking in efficacy for hidradenitis suppurativa, two studies on a combined total of 29 patients [60,61] have shown improvement due to acitretin in moderate-to-severe cases. The drawbacks of retinoids comprise the usual adverse effects (cutaneous xerosis) and teratogenicity.

Fourthly and lastly, instrumental treatments have been widely studied over recent years. Classical dynamic phototherapy associating a red light and topical aminolevulinic acid (ALA) seem to have been of limited efficacy in four low-power cohort studies [50—53] that included a combined total of 20 patients. Administered in fistulas, the same association seems to have been more effective; a single non-controlled

prospective study by Valadares-Nargenes et al. [54] involved no less than 27 patients. As for the other combinations having been studied, they are likewise lacking in conclusive proof.

As reported by Mamoud et al. [82], epilatory Laser (long pulse Nd:YAG) produced rather constant improvement in 22 patients, and ablative CO_2 Laser possesses efficacy highlighted in two large-scale cohorts (58 and 61 subjects) [79,80]. Its mode of action seems quite close to that of surgery.

The other treatments are only sparsely documented:

- zinc gluconate and metformin, both of which are inexpensive and well-tolerated, could be effective with regard to mild-to-moderate forms, but there has been only one published study on the subject, involving respectively 22 and 25 patients [75,76];
- hormonal treatments (spironolactone, finasteride and cyproterone acetate), which are not to be used by men on account of their adverse effects on sexuality, seem relatively effective, but there has been only one published study on each of the three molecules [68—70];
- an atypical anti-inflammatory treatment, anakinra was shown to be effective, but only on a small series (6 patients) [73];
- immunoglobulins have also brought about a high response rate, but only on a small series (5 cases) [78]. Moreover, they (IM) are complicated to use and remain quite expensive;
- the other therapies (fumarates, colchicin, cyclosporin) have no demonstrated effectiveness at all. And even the most effective medical treatments seem merely suspensive. In order to avoid recurrence over the long haul, only excision of the lesions, whether surgical or instrumental (Laser CO_2) is fully conclusive.

It is possible to determine a treatment plan according to the relevant data in the literature and the existing European recommendations [86] (Fig. 2), to the severity of the disease and to its degree of extension:

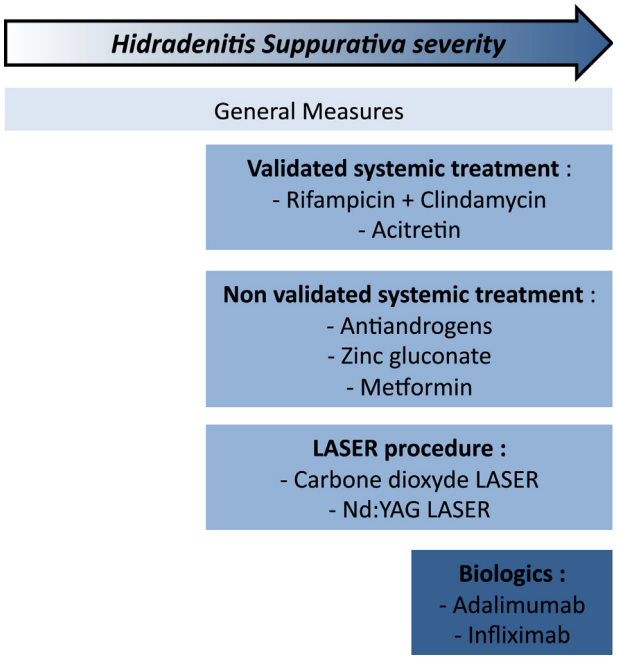

Figure 2 Treatment choices in Hidradenitis suppurativa.

- antibiotics, retinoids and LASERs can be used during moderate stages of the disease, with a low-to-medium level of evidence;
- metformin and zinc can be tested alone or in combination with other treatments due to their excellent tolerance and to the low degree of risk connected with their intake, but with a low level of evidence;
- hormonal treatments are to be reserved for women presenting signs of hyperandrogenism. Their level of evidence is low;
- biotherapies must be limited to forms of the disease that are either resistant to conventional treatments or inoperable. Adalimulab recently received French marketing authorization in this indication;
- on the other hand, isolated lesions are to be treated by surgical or instrumental exeresis;
- extended lesions are to be initially managed by systemic treatments.

Limits of the study

The scope of these recommendations is limited by the weakness of available proof. Existing studies are anything but numerous. They generally incorporate few subjects and are lacking in stratification by stage of severity; moreover, their methods of evaluation are heterogeneous and hardly comparable. There exist few randomized controlled studies, and most published cohort studies are retrospective. Due to the major heterogeneity of treatment protocols and methods of evaluation, no meta-analysis can be carried out. In the future, authors should attempt to standardize their ways of assessing response to treatment.

Conclusion

Non-surgical management of hidradenitis suppurativa remains complicated in the absence of a validated effective treatment. While some medical therapeutics such as antibiotics and biotherapies have shown real effectiveness, their effects remain suspensive; upon cessation, the disease almost certainly reappears. As regards antibiotics, no association has demonstrated their superiority in a study with a high level of evidence. While some biotherapies seem highly effective, the perspective of side effects is such that they must be reserved for moderate-to-severe, resistant, or inoperable forms of the disease. Randomized controlled studies are needed before valid conclusions can be reasonably drawn. As for resistant or debilitating forms of the disease, it is necessary to recommend radical surgical treatment, which offers the one and only pathway towards cure.

Funding

The authors received no funding support for this article.

Ethical approval

Not applicable.

Disclosure of interest

The authors declare that they have no competing interest.

References

[1] Jemec G, Revuz J, Leyden J. Hidradenitis suppurativa. Berlin: Springer-Verlag; 2006.
[2] Revuz J, Canoui-Poitrine F, Wolkenstein P. Prevalence and factors associated with hidradenitis suppurativa: results from two case-control studies. J Am Acad Dermatol 2008;59:596—601.
[3] Micheletti R. Hidradenitis suppurativa: current views on epidemiology, pathogenesis, and pathophysiology. Semin Cutan Med Surg 2014;33(3 Suppl.):48—50.
[4] Prens E, Deckers I. Pathophysiology of hidradenitis suppurativa: an update. J Am Acad Dermatol 2015;73(5 Suppl. 1):8—11.
[5] Yu C, Cook M. Hidradenitis suppurativa: a disease of follicular epithelium, rather than apocrine glands. Br J Dermatol 1990;122:763—9.
[6] Kelly G, Sweeney C, Tobin A, Kirby B. Hidradenitis suppurativa: the role of immune dysregulation. Int J Dermatol 2014;53:1186—96.
[7] Kathju S, Lasko L, Stoodley P. Considering hidradenitis suppurativa as a bacterial biofilm disease. FEMS Immunol Med Microbiol 2012;65:385—9.
[8] Kohorst J, Kimball A, Davis M. Systemic associations of hidradenitis suppurativa. J Am Acad Dermatol 2015;73(5 Suppl. 1):27—35.
[9] Esmann S, Jemec G. Psychosocial impact of hidradenitis suppurativa: a qualitative study. Acta Derm Venereol 2011;91:328—32.
[10] Lavogiez C, Delaporte E, Darras-Vercambre S. Clinicopathological study of 13 cases of squamous cell carcinoma complicating hidradenitis suppurativa. Dermatology 2010;220:147—53.
[11] Alharbi B, Shlash A, Bedaiwi K, Hooti Q, Almohaisen A, Shlash S, et al. Scroto-perineal hidradenitis suppurativa complicated by giant scrotal elephantiasis. Urol Ann 2015;7(2):265—7.
[12] Mullins J. Hidradenitis suppurativa. In: Conn J, editor. Current therapy. Philadelphia: WB Saunders; 1972. p. 592—3.
[13] Rompel R, Petres J. Long-term results of wide surgical excision in 106 patients with hidradenitis suppurativa. Dermatol Surg 2000;26:638—43.
[14] Moher D, Liberati A, Tetzlaff J, Altman D, Group P. Preferred reporting items for systematic reviews and meta-analyses: the PRISMA statement. Int J Surg 2010;8:336—41.
[15] OCEBM levels of evidence working group. ''The Oxford 2011 levels of evidence''. Oxford centre for evidence-based medicine. http://www.cebm.net/index.aspx?o=5653.
[16] Sand F, Thomsen S. Off-label use of TNF-alpha inhibitors in a dermatological university department: retrospective evaluation of 118 patients. Dermatol Ther 2015.
[17] Kimball A, Kerdel F, Adams D, Mrowietz U, Gelfand J, Gniadecki R, et al. Adalimumab for the treatment of moderate to severe Hidradenitis suppurativa: a parallel randomized trial. Ann Intern Med 2012;157(12):846—55.
[18] Miller I, Lynggaard C, Lophaven S, Zachariae C, Dufour D, Jemec G. A double-blind placebo-controlled randomized trial of adalimumab in the treatment of hidradenitis suppurativa. Br J Dermatol 2011;165(2):391—8.
[19] Adams D, Yankura J, Fogelberg A, Anderson B. Treatment of hidradenitis suppurativa with etanercept injection. Arch Dermatol 2010;146(5):501—4.
[20] Grant A, Gonzalez T, Montgomery M, Cardenas V, Kerdel F. Infliximab therapy for patients with moderate to severe hidradenitis suppurativa: a randomized, double-blind, placebo-controlled crossover trial. J Am Acad Dermatol 2010;62(2):205—17.
[21] Paradela S, Rodriguez-Lojo R, Fernández-Torres R, Arévalo P, Fonseca E. Long-term efficacy of infliximab in hidradenitis suppurativa. J Dermatolog Treat 2012;23(4):278—83.
[22] Mekkes J, Bos J. Long-term efficacy of a single course of infliximab in hidradenitis suppurativa. Br J Dermatol 2008;158(2):370—4.
[23] Moriarty B, Jiyad Z, Creamer D. Four-weekly infliximab in the treatment of severe hidradenitis suppurativa. Br J Dermatol 2014;170(4):986—7.
[24] Fardet L, Dupuy A, Kerob D, Levy A, Allez M, Begon E, et al. Infliximab for severe hidradenitis suppurativa: transient clinical efficacy in 7 consecutive patients. J Am Acad Dermatol 2007;56(4):624—8.
[25] Sotiriou E, Goussi C, Lallas A, Chovarda E, Apalla Z, Lazaridou E, et al. A prospective open-label clinical trial of efficacy of the every week administration of adalimumab in the treatment of hidradenitis suppurativa. J Drugs Dermatol 2012;11(5 Suppl.):s15—20.
[26] Arenbergerova M, Gkalpakiotis S, Arenberger P. Effective long-term control of refractory hidradenitis suppurativa with adalimumab after failure of conventional therapy. Int J Dermatol 2010;49(12):1445—9.
[27] Chinniah N, Cains G. Moderate to severe hidradenitis suppurativa treated with biological therapies. Australas J Dermatol 2014;55(2):128—31.
[28] Sotiriou E, Apalla Z, Ioannidos D. Etanercept for the treatment of hidradenitis suppurativa. Acta Derm Venereol 2009;89(1):82—3.
[29] Giamarellos-Bourboulis E, Pelekanou E, Antonopoulou A, Petropoulou H, Baziaka F, Karagianni V, et al. An open-label phase II study of the safety and efficacy of etanercept for the therapy of hidradenitis suppurativa. Br J Dermatol 2008;158(3):567—72.
[30] Cusack C, Buckley C. Etanercept: effective in the management of hidradenitis suppurativa. Br J Dermatol 2006;154(4):726—9.
[31] Lee R, Dommasch E, Treat J, Sciacca-Kirby J, Chachkin S, Williams J, et al. A prospective clinical trial of open-label etanercept for the treatment of hidradenitis suppurativa. J Am Acad Dermatol 2009;60(4):565—73.
[32] Strober B, Kim C, Siu K. Efalizumab for the treatment of refractory hidradenitis suppurativa. J Am Acad Dermatol 2007;57(6):1090—1.
[33] Martin-Ezquerra G, Masferrer E, Masferrer-Niubo? M, Ferran M, Sánchez-Regana M, Collgros H, et al. Use of biological treatments in patients with hidradenitis suppurativa. J Eur Acad Dermatol Venereol 2015;29(1):56—60.
[34] Zhang J, Reeder V, Hamzavi I. Use of biologics in the treatment of hidradenitis suppurativa: a review of the Henry Ford Hospital experience. Br J Dermatol 2014;171(6):1600—2.
[35] Sbidian E, Hotz C, Seneschal J. Antitumour necrosis factor-(therapy for hidradenitis suppurativa: results from a national cohort study between 2000 and 2013. Br J Dermatol 2016;174(3):667—70.
[36] Lesage C, Adnot-Desanlis L, Perceau G, Bonnet M, Palot JP, Bernard P, et al. Efficacy and tolerance of prolonged infliximab treatment of moderate-to-severe forms of hidradenitis suppurativa. Eur J Dermatol 2012;22(5):640—4.
[37] Mariette X, Matucci-Cerinic M, Pavelka K, Taylor P, van Vollenhoven R, Heatley R, et al. Malignancies associated with tumour necrosis factor inhibitors in registries and prospective observational studies: a systematic review and meta-analysis. Ann Rheum Dis 2011;70(11):1895—904.
[38] Shelton E, Laharie D, Scott F, Mamtani R, Lewis J, Colombel J, et al. Cancer recurrence following immune-suppressive therapies in patients with immune-mediated diseases: a systematic review and meta-analysis. Gastroenterology 2016.
[39] European medicines agency. First medicine recommended for approval for hidradenitis suppurativa. Press Office. 25 June

2015. http://www.ema.europa.eu/docs/en_GB/document_library/Press_release/2015/06/WC500188809.pdf.
[40] Department of health and human services. Food and Drug Administration Silver Spring MD 20993. http://www.accessdata.fda.gov/drugsatfda_docs/appletter/2015/125057Orig1s393ltr.pdf.
[41] Clemmensen O. Topical treatment of hidradenitis suppurativa with clindamycin. Int J Dermatol 1983;22(5):325—8.
[42] Oprica C, Nord C. Bacteriology of Hidradenitis Suppurativa. In: Jemec G, Revuz J, Leyden J, editors. Hidradenitis suppurativa. Berlin: Springer Verlag; 2006. p. 86—94.
[43] Van der Zee H, Boer J, Prens E, Jemec G. The effect of combined treatment with oral clindamycin and oral rifampicin in patients with hidradenitis suppurativa. Dermatology 2009;219(2):143—7.
[44] Gener G, Canoui-Poitrine F, Revuz J, Faye O, Poli F, Gabison G, et al. Combination therapy with clindamycin and rifampicin for hidradenitis suppurativa: a series of 116 consecutive patients. Dermatology 2009;219(2):148—54.
[45] Mendonça C, Griffiths C. Clindamycin and rifampicin combination therapy for hidradenitis suppurativa. Br J Dermatol 2006;154(5):977—8.
[46] Bettoli V, Zauli S, Borghi A, Toni G, Minghetti S, Ricci M, et al. Oral clindamycin and rifampicin in the treatment of hidradenitis suppurativa-acne inversa: a prospective study on 23 patients. J Eur Acad Dermatol Venereol 2014;28(1):125—6.
[47] Join-Lambert O, Coignard H, Jais JP, Guet-Revillet H, Poirée S, Fraitag S, et al. Efficacy of rifampin-moxifloxacin-metronidazole combination therapy in hidradenitis suppurativa. Dermatology 2011;222(1):49—58.
[48] Kaur M, Lewis H. Hidradenitis suppurativa treated with dapsone: a case series of five patients. J Dermatolog Treat 2006;17(4):211—3.
[49] Yazdanyar S, Boer J, Ingvarsson G, Szepietowski J, Jemec G. Dapsone therapy for hidradenitis suppurativa: a series of 24 patients. Dermatology 2011;222(4):342—6.
[50] Andino Navarrete R, Hasson Nisis A, Parra Cares J. Effectiveness of 5-aminolevulinic acid photodynamic therapy in the treatment of hidradenitis suppurativa: a report of 5 cases. Actas Dermosifiliogr 2014;105(6):614—7.
[51] Calzavara-Pinton P, Rossi M, Aronson E, Sala R, Italian group for photodynamic therapy. A retrospective analysis of real-life practice of off-label photodynamic therapy using methyl aminolevulinate (MAL-PDT) in 20 Italian dermatology departments. Part 1: inflammatory and aesthetic indications. Photochem Photobiol Sci 2013;12(1):148—57.
[52] Sotiriou E, Apalla Z, Maliamani F, Ioannides D. Treatment of recalcitrant hidradenitis suppurativa with photodynamic therapy: report of five cases. Clin Exp Dermatol 2009;34(7):e235—6.
[53] Strauss R, Pollock B, Stables G, Goulden V, Cunliffe W. Photodynamic therapy using aminolaevulinic acid does not lead to clinical improvement in hidradenitis suppurativa. Br J Dermatol 2005;152(4):803—4.
[54] Valladares-Narganes L, Rodriguez-Prieto M, Blanco-Suárez M, Rodriguez-Lage C, Garcia-Doval I. Treatment of hidradenitis suppurativa with intralesional photodynamic therapy using a laser diode attached to an optical cable: a promising new approach. Br J Dermatol 2015;172(4):1136—9.
[55] Fadel M, Tawfik A. New topical photodynamic therapy for treatment of hidradenitis suppurativa using methylene blue niosomal gel: a single-blind, randomized, comparative study. Clin Exp Dermatol 2015;40(2):116—22.
[56] Shareef M, Dawe R. Bath psoralen plus ultraviolet A for hidradenitis suppurativa: a review of 13 patients. Br J Dermatol 2011;164(4):895—6.
[57] Highton L, Chan W, Khwaja N, Laitung J. Treatment of hidradenitis suppurativa with intense pulsed light: a prospective study. Plast Reconstr Surg 2011;128(2):459—65.
[58] Passeron T, Khemis A, Ortonne J. Pulsed dye laser-mediated photodynamic therapy for acne inversa is not successful: a pilot study on four cases. J Dermatolog Treat 2009;20(5):297—8.
[59] Soria A, Canoui-Poitrine F, Wolkenstein P, Poli F, Gabison G, Pouget F, et al. Absence of efficacy of oral isotretinoin in hidradenitis suppurativa: a retrospective study based on patients' outcome assessment. Dermatology 2009;218(2):134—5.
[60] Matusiak L, Bieniek A, Szepietowski J. Acitretin treatment for hidradenitis suppurativa: a prospective series of 17 patients. Br J Dermatol 2014;171(1):170—4.
[61] Boer J, Nazary M. Long-term results of acitretin therapy for hidradenitis suppurativa. Is acne inversa also a misnomer? Br J Dermatol 2011;164(1):170—5.
[62] DiGiovanna J, Zech L, Ruddel M, Gantt G, Peck G. Etretinate. Persistent serum levels after long-term therapy. Arch Dermatol 1989;125:246—51.
[63] ANSM. Point d'information; 2014, http://ansm.sante.fr/S-informer/Points-d-information-Points-d-information/Soriatane-acitretine-Renforcement-des-mesures-de-minimisation-du-risque-teratogene-Point-d-Information.
[64] Verdolini R, Simonacci F, Menon S, Pavlou P, Mannello B. Alitretinoin: a useful agent in the treatment of hidradenitis suppurativa, especially in women of child-bearing age. G Ital Dermatol Venereol 2015;150(2):155—62.
[65] Sawers R, Randall V, Ebling F. Control of hidradenitis suppurativa in women using combined antiandrogen (cyproterone acetate) and estrogen therapy. Br J Dermatol 1986;115:269—74.
[66] Stellon A, Wakeling M. Hidradenitis suppurativa associated with use of oral contraceptives. BMJ 1989;298(6665):28—9.
[67] Mortimer P, Dawber R, Gales M. A double-blind controlled cross-over trial of cyproterone acetate in females with hidradenitis suppurativa. Br J Dermatol 1986;115:263—8.
[68] Kraft J, Searles G. Hidradenitis suppurativa in 64 female patients: retrospective study comparing oral antibiotics and antiandrogen therapy. J Cutan Med Surg 2007;11(4):125—31.
[69] Joseph M, Jayaseelan E, Ganapathi B, Stephen J. Hidradenitis suppurativa treated with finasteride. J Dermatolog Treat 2005;16(2):75—8.
[70] Lee A, Fischer G. A case series of 20 women with hidradenitis suppurativa treated with spironolactone. Australas J Dermatol 2015;56(3):192—6.
[71] Boer J, Weltevreden E. Hidradenitis suppurativa or acne inversa. A clinicopathological study of early lesions. Br J Dermatol 1996;135:721—5.
[72] Anderson M, Zauli S, Bettoli V, Boer J, Jemec G. Cyclosporine treatment of severe Hidradenitis suppurativa — A case series. J Dermatolog Treat 2016;27(3):247—50.
[73] Leslie K, Tripathi S, Nguyen T, Pauli M, Rosenblum M. An open-label study of anakinra for the treatment of moderate to severe hidradenitis suppurativa. J Am Acad Dermatol 2014;70(2):243—51.
[74] Van der Zee H, Prens E. The anti-inflammatory drug colchicine lacks efficacy in hidradenitis suppurativa. Dermatology 2011;223(2):169—73.
[75] Brocard A, Knol A, Khammari A, Dréno B. Hidradenitis suppurativa and zinc: a new therapeutic approach. A pilot study. Dermatology 2007;214(4):325—7.
[76] Verdolini R, Clayton N, Smith A, Alwash N, Mannello B. Metformin for the treatment of hidradenitis suppurativa: a little help along the way. J Eur Acad Dermatol Venereol 2013;27(9):1101—8.
[77] Deckers I, van der Zee H, Balak D, Prens E. Fumarates, a new treatment option for therapy-resistant hidradenitis suppurativa: a prospective open-label pilot study. Br J Dermatol 2015;172(3):828—9.

[78] Goo B, Chung H, Chung W, Chung K. Intramuscular immunoglobulin for recalcitrant suppurative diseases of the skin: a retrospective review of 63 cases. Br J Dermatol 2007;157(3):563—8.
[79] Mikkelsen P, Dufour D, Zarchi K, Jemec G. Recurrence rate and patient satisfaction of CO_2 laser evaporation of lesions in patients with hidradenitis suppurativa: a retrospective study. Dermatol Surg 2015;41(2):255—60.
[80] Hazen P, Hazen B. Hidradenitis suppurativa: successful treatment using carbon dioxide laser excision and marsupialization. Dermatol Surg 2010;36(2):208—13.
[81] Madan V, Hindle E, Hussain W, August P. Outcomes of treatment of nine cases of recalcitrant severe hidradenitis suppurativa with carbon dioxide laser. Br J Dermatol 2008;159(6):1309—14.
[82] Mahmoud B, Tierney E, Hexsel C, Pui J, Ozog D, Hamzavi I. Prospective controlled clinical and histopathologic study of hidradenitis suppurativa treated with the long-pulsed neodymium: yttrium-aluminium-garnet laser. J Am Acad Dermatol 2010;62(4):637—45.
[83] Jain V, Jain A. Use of lasers for the management of refractory cases of hidradenitis suppurativa and pilonidal sinus. J Cutan Aesthet Surg 2012;5(3):190—2.
[84] Sartorius K, Emtestam L, Jemec G. Objective scoring of hidradenitis suppurativa reflecting the role of tobacco smoking and obesity. Br J Dermatol 2009;161:831—9.
[85] Join-Lambert O, Ribadeau-Dumas F, Jullien V, Kitzis MD, Jais JP, Coignard-Biehler H, et al. Dramatic reduction of clindamycin plasma concentration in hidradenitis suppurativa patients treated with the rifampicin-clindamycin combination. Eur J Dermatol 2014;24(1):94—5.
[86] Zouboulis C, Desai N, Emtestam L, Hunger R, Ioannides D, Juhász I, et al. European S1 guideline for the treatment of hidradenitis suppurativa/acne inversa. J Eur Acad Dermatol Venereol 2015;29(4):619—44.
[87] Van Rappard D, Leenarts M, Meijerink-van't Oost L, Mekkes J. Comparing treatment outcome of infliximab and adalimumab in patients with severe hidradenitis suppurativa. J Dermatolog Treat 2012;23(4):284—9.
[88] Delage M, Samimi M, Atlan M, Machet L, Lorette G, Maruani A. Efficacy of infliximab for hidradenitis suppurativa: assessment of clinical and biological inflammatory markers. Acta Derm Venereol 2011;91(2):169—71.
[89] Amano M, Grant A, Kerdel F. A prospective open-label clinical trial of adalimumab for the treatment of hidradenitis suppurativa. Int J Dermatol 2010;49(8):950—5.
[90] Pelekanou A, Kanni T, Savva A, Mouktaroudi M, Raftogiannis M, Kotsaki A, et al. Long-term efficacy of etanercept in hidradenitis suppurativa: results from an open-label phase II prospective trial. Exp Dermatol 2010;19(6):538—40.
[91] Blanco R, Martinez-Taboada V, Villa I, González-Vela M, Fernández-Llaca H, Agudo M, et al. Long-term successful adalimumab therapy in severe hidradenitis suppurativa. Arch Dermatol 2009;145(5):580—4.
[92] Brunasso A, Delfino C, Massone C. Hidradenitis suppurativa: are tumour necrosis factor-alpha blockers the ultimate alternative? Br J Dermatol 2008;159(3):761—3.
[93] Fernández-Vozmediano J, Armario-Hita J. Infliximab for the treatment of hidradenitis suppurativa. Dermatology 2007;215(1):41—4.
[94] Schweiger E, Riddle C, Aires D. Treatment of hidradenitis suppurativa by photodynamic therapy with aminolevulinic acid: preliminary results. J Drugs Dermatol 2011;10(4):381—6.