European Journal of Obstetrics & Gynecology and Reproductive Biology 214 (2017) 131–139

Contents lists available at ScienceDirect

European Journal of Obstetrics & Gynecology and Reproductive Biology

journal homepage: www.elsevier.com/locate/ejogrb

Maternal and perinatal outcomes in pregnancy-associated melanoma. Report of two cases and a systematic literature review

Elsa Mendizábal, Juan De León-Luis*, Natalia R. Gómez-Hidalgo, Laura Joigneau, Pilar Pintado, Patricia Rincón, Virginia Ortega, Santiago Lizarraga

Department of Obstetrics and Gynecology, Hospital General Universitario Gregorio Marañón, Spain

ARTICLE INFO

Article history:
Received 26 December 2016
Received in revised form 1 April 2017
Accepted 9 April 2017
Available online xxx

Keywords:
Pregnancy associated melanoma
Perinatal outcome
Systematic review

ABSTRACT

Objetives: Melanoma is one of the most frequent malignancies during gestation. However, oncological and perinatal management is still challenging. Our first objective is to describe the cases of pregnancy-associated melanoma (PAM) diagnosed in our centre between January-2004 and May-2015. Secondly, to perform a systematic review of the published articles analysing the maternal-perinatal outcomes of patients diagnosed with PAM.

Design, population and methods: Obstetrical, oncological and perinatal variables were recorded in the case series. For the systematic review we include all published articles assessing the obstetric and neonatal outcomes in PAM cases in Pubmed, Web of Knowledge and Cochrane Library. The search was restricted to articles published in English, between January-2004 and May-2015. Study characteristics, oncological and maternal-perinatal variables were recorded in the systematic review.

Results: Two patients were found: the first case presents a newly diagnosed metastatic melanoma at 26-weeks of gestation with fatal maternal and neonatal outcome. The second case presents a patient with metastatic melanoma who got pregnant during her treatment. For the systematic review we found 25 articles, providing data from 489 patients. Maternal-perinatal outcomes, including termination of pregnancy rates, vary depending on the country, gestational age and tumour stage at diagnosis. PAM is usually detected at advanced stages, even with metastasis affecting the placenta and the foetus.

Conclusions: When diagnosed at early stages, melanoma does not seem to alter the evolution of gestation, whereas patients with advanced stages of melanoma frequently deliver prematurely, by caesarean section, with lower neonatal weight, higher neonatal morbidity and mortality rates.

© 2017 Elsevier B.V. All rights reserved.

Introduction

Melanoma is the most common malignancy in women between 25 and 29 years of age [1] and one of the most commonly diagnosed malignancies during pregnancy, along with breast cancer, cervical cancer, leukaemia and lymphoma [2–5]. Pregnancy-associated melanoma (PAM) is reported between 2.8 and 5.0 per 100,000 pregnancies [6], and approximately 35% of women with melanoma are of childbearing age [2]. The incidence of melanoma is rapidly rising and it is foreseen that 1 out of 68 Americans born in 2002 will develop an invasive melanoma during their lifetime [7].

Most of the publications on PAM are retrospective and analyze the effect of gestation on the course of melanoma, the maternal prognosis and the survival. However, there are few publications evaluating the effect of melanoma on the course of pregnancy and on the obstetrical and perinatal outcomes.

The aims of our study are, firstly to describe the maternal and perinatal outcomes of two pregnant patients diagnosed with PAM in our Department; and secondly to perform a systematic review of the literature to assess the effect of melanoma on the course of pregnancy.

Methods

Study population

We retrospectively collected the records of women who were diagnosed with PAM in the Department of Obstetrics and Gynaecology in Gregorio Marañon University General Hospital

* Corresponding author at: Maternal Fetal Medicine Unit, Department of Obstetrics and Gynecology, Hospital General Universitario Gregorio Marañón, Calle O'Donnell, 48, Planta 0, Bloque C. 28009, Madrid, Spain.
E-mail address: jdeleonluis@yahoo.es (J. De León-Luis).

http://dx.doi.org/10.1016/j.ejogrb.2017.04.023
0301-2115/© 2017 Elsevier B.V. All rights reserved.

in Madrid, between January 2004 and June 2015. Although gestational cancer is defined as malignancies diagnosed during pregnancy and up to one year postpartum, we excluded the latter because we could not evaluate the influence of the malignancy on the maternal and perinatal results. Two investigators of our centre (a Gynaecologic Oncology specialist and a Maternal-Foetal Medicine specialist) retrieved information concerning the maternal and perinatal variables as well as the evolution of pregnancy and postpartum from our hospital electronic database.

Systematic review

The PRISMA Statement (Preferred Reporting Items for Systematic Reviews and Meta-Analysis) was followed in this review [8]

Information sources and search strategy

We obtained all the articles related to our topic from the international electronic bibliographic databases PUBMED, ISI Web of Knowledge and Cochrane. The articles were identified using comprehensive search criteria and a combination of MeSH terms including the keywords "*pregnancy*" and "*melanoma*". We selected the articles published between January 1st 2004 and May 31st 2015, matching the period in which we collected data from our own patients (Fig. 1). The search was limited to studies reported in the English language. Finally, and once an article was considered relevant, the full text was retrieved. The references included in the selected articles were also reviewed for related citations.

Study selection and data retrieval Two independent researchers screened the titles and abstracts obtained to select the most relevant articles. If the title and abstract did not provide enough information, the full text was retrieved. Duplicates, letters to editors, editorials and review articles were excluded. We only included articles that followed our eligibility criteria. Both researchers selected the final studies to be included in the review after applying the eligibility criteria independently. Any conflict between researchers was resolved by mutual agreement.

Studies were considered eligible for review if they investigated obstetric outcomes in pregnant women with a diagnosis of PAM, with special reference to maternal, foetal or perinatal outcomes. We excluded those studies analysing data from pregnant women who had had melanoma, but were in complete remission during pregnancy, as well as those with melanoma diagnosed during the puerperium. The latter were excluded due to the impossibility of determining the influence of melanoma on the pregnancy outcomes.

Due to the small amount of studies including a large number of patients diagnosed with PAM, we also checked articles concerning single cases of melanoma where both maternal and foetal prognosis was reflected.

We collected the following data from the selected articles: authors, year of publication, type of study, geographic location, number of patients (N), median maternal age at diagnosis, median gestational age (weeks) at diagnosis, melanoma characteristics, American Joint Committee on Cancer (AJCC) stage, treatment during pregnancy (if stated) and data regarding perinatal variables such as: gestational age (weeks) at delivery, type of delivery, data regarding neonatal outcomes, birth weight and congenital anomalies.

Results

Population study

During the study period we attended 66,265 deliveries, and we collected two cases of PAM. The prevalence of PAM in our series is 3,1/100.000 deliveries.

The cases attended in our centre are described here below.

CASE 1

A 36 years old pregnant woman with two previous pregnancies was referred to our hospital during her 26th week of gestation due to clinical suspicion of chorioamnionitis. At hospital admission, she reported to have been experiencing low abdominal pain, asthenia, epistaxis and gingival bleeding for the last two weeks. Her blood pressure was 104/45 mmHg. The obstetrical examination and the ultrasound were normal. A cardiotocography showed regular contractions with normal foetal heart rate.

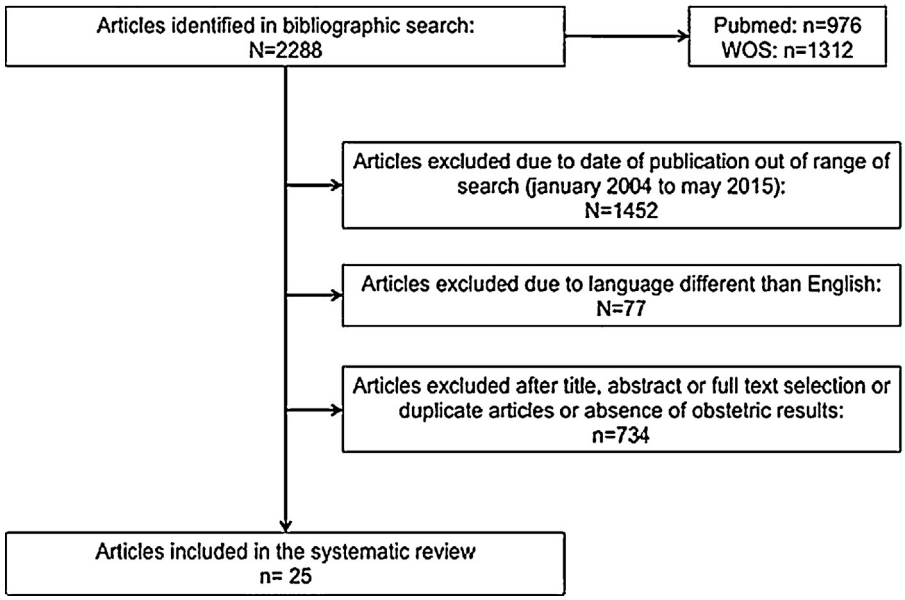

Fig. 1. Flow chart of studies retrieved and included in the systematic review.

The blood tests showed leukocytosis, thrombocytopenia, and increased liver enzymes and C-reactive protein. Urinalysis showed pyuria, bacteriuria and positive nitrites.

The differential diagnosis included urinary sepsis, chorioamnionitis, thrombotic thrombocytopenic purpura, acute fatty liver of pregnancy and HELLP syndrome.

Due to the suspicion of severe maternal illness, labour induction was deemed necessary. We administered corticosteroids for foetal pulmonary maturation, magnesium sulphate for foetal neuroprotection, and antibiotics. We attended a normal vaginal delivery. The newborn weighted 1000 grs. The Apgar score at minutes 1 and 5 was 6 and 8, with an arterial blood cord pH of 7.34. The neonate required orotracheal intubation and was admitted in the neonatal intensive care unit.

The patient presented a postpartum haemorrhage that required uterotonic drugs and a Bakri balloon placement.

The patient remained haemodynamically stable, but the analyses worsened. An abdominal sonography and a computerized tomography (CT) showed hepatosplenomegaly and ascitis. Peripheral blood smear revealed a severe leucoerythroblastic blood picture. Bone marrow biopsy showed metastases of a malignant solid tumour, suggesting melanoma metastases.

During the third day of puerperium, the patient had complained of an itchy cutaneous lesion on her left shoulder that had been growing during the last four months (Fig. 2). The lesion was dark, asymmetrical with uneven borders, suspicious of malignancy. A cutaneous biopsy confirmed the diagnosis of melanoma (Fig. 3). The hystopathological study of the placenta showed melanoma metastases (Fig. 4).

In the subsequent days, the patient presented a worsening in her biological parameters and neurological alterations. A thoracic CT revealed the presence of pulmonary metastases. The patient died due to multiple organ failure secondary to stage IV malignant melanoma.

The neonate developed hyaline membrane disease, pulmonary haemorrhage and necrotizing enterocolitis and died two weeks later. The hystopathological study did not find melanoma metastases in the neonate despite the placental invasion.

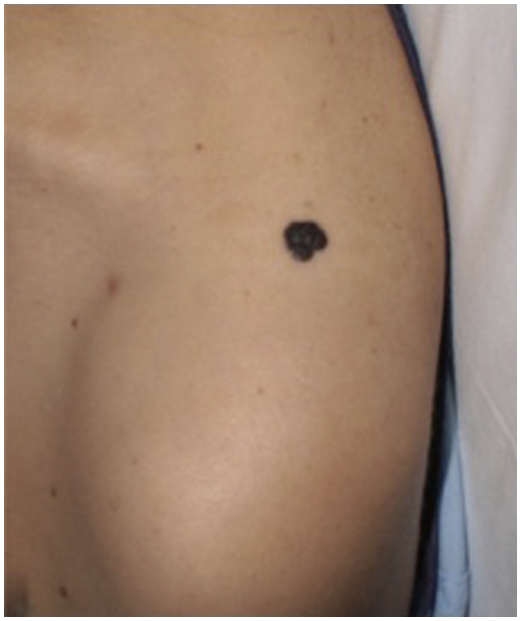

Fig. 2. Cutaneous pigmented lesion on left shoulder suspicious of malignancy.

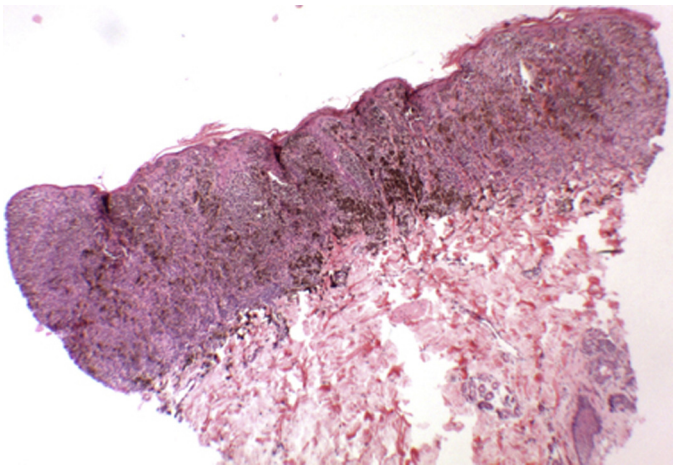

Fig. 3. Histopathological study of the cutaneous lesion confirming the diagnosis of melanoma (Haematoxylin-eosin stained section 4×).

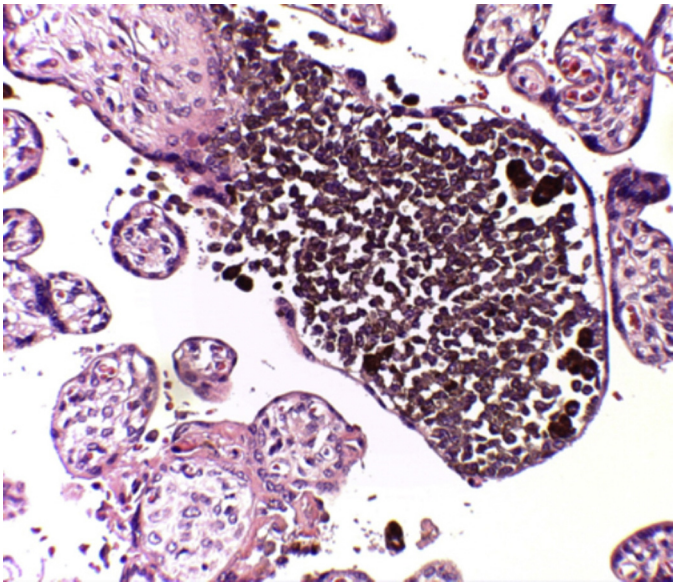

Fig. 4. Histopathological study of the placenta showing melanoma metastases (Haematoxylin-eosin stained section 40×).

CASE 2

A 28 years old nulliparous patient was diagnosed with malignant melanoma of the oral mucosa affecting the left maxilla, nasal cavity and the hard palate. She underwent a left hemimaxillectomy with cervical lymphadenectomy, adjuvant radiotherapy and interferon. One year later, she presented melanoma metastases on the dorsal and lumbar vertebrae. While assessing the adjuvant therapy to administer, she was found to be pregnant. The patient refused to receive any treatment for her melanoma and decided to continue with the pregnancy.

The pregnancy had a normal evolution despite the melanoma. A caesarean section (C-S) due to breech presentation was performed at 34 weeks of gestation due to severe maternal illness. The hystopathological analysis of the placenta and umbilical cord was normal. The neonate was healthy and weighted 2510 grs.

During the oncological follow-up in the postpartum, she presented a new metastatic lesion in the soft tissue and was included in a clinical trial with nivolumab. Four months after the C-S, she presented a progression of the vertebral metastases with medullar compression. Her treatment was changed to ipilimumab,

Table 1
Characteristics and clinical results of the case series studies included in the systematic review.

References	O'Meara et al. [9]	Langagergaard et al. [13]	Pages et al. [12]	Andtbacka et al. [11]	Bannister et al. [10]
Number of patients	149	88	22	15	195
Year of publication	2005	2007	2010	2012	2014
Country	E.E.U.U	Denmark	France	E.E.U.U	Australia
Study period	1991–1999	1970–2002	1993–2007	1997–2012	1994–2008
Study design	Retrospective population based study (comparing PAM and non-pregnant patients with melanoma)	Retrospective population-based study (comparing PAM and non-pregnant patients with melanoma)	Retrospective multicentre study describing PAM	Prospective hospital based study describing PAM	Retrospective regional population based study (comparing PAM and non-pregnant patients with melanoma)
Maternal age data (years)	<25: 9% 25–35: 62.9% >35: 27.9%	Mean 30.3 (±4.9) range 20–44. <25: 8(9.1%) 25–29: 35(39.8%) 30–34: 25(28.4%) >35: 20(22.7%)	Mean 32.04 (range 22–42)	Mean 28.5 (range 21.2–40.2)	15–24: 8.7%, 25–29: 22.2%, 30–34: 39%, 35–39: 21.5%, 40–55: 8.7%
Data related with gestational age at diagnosis	Similar number of patients diagnosed in the first, second or third trimester	19 in the first trimester 39 in the second 30 in the third	Mean 36 weeks (range 26–41)	Mean 20 weeks (5–33)	Mean 21 weeks
Stage of the disease	82% with localized disease	93% with localized disease	100% with advanced disease	78.94% with localized disease	92.8% with localized disease
Data related with oncological treatment in pregnancy	Surgery and lymphadenectomy depending on stages and locations	NR[a]	Absent 3 cases Surgery 14 cases Chemotherapy 4 cases (dacarbazina/ fotemustine) Cerebral radiotherapy 1 case	Surgery 14 + SLN with preoperative lymphoscintigraphy with 99mTc-labelled sulfur colloid, receiving a median of 443 lCi, 1 SLN with 1% isosulfan blue dye only. Adjuvant systemic therapy (interferon-a2b) was offered to all patients with metastatic disease, but all declined.	NR
Data related with the end of pregnancy and delivery	NR	NR	1 spontaneous miscarriage 3 TOP 9 C-S (4 urgent) 6 vaginal deliveries 3 NR	C-S 5 Vaginal deliveries 10	*Programmed delivery:* Spontaneous delivery 119 (61%) Induced labour 46 (23.6%) Elective C-S:30 15.4%) *Delivery:* Eutocic vaginal delivery 121 (62.1%) Instrumental vaginal delivery 20 (10.3%) C-S 54 (27.2%)
Gestational age at delivery (weeks)	92.3% > 37 weeks	Mean 39.9 weeks	Mean 36 weeks (range 26–41)	Mean 39 weeks (range 36–41)	94.4% >37 weeks
Data related with the foetal weight	95.2% AGA[b]	Mean 3604 (g)	Mean 2660 (g) (range 820–4360)	NR	SGA[c] 12 (6.2%) LGA[d] 37 (19%) AGA 146 (74.9%)
Data related with the newborn outcome	AW[e]	2 (2.3%) Congenital CHD	One case of SD[g] and one case of placental metastasis	AW	AW
Data related with abortion/ postpartum	TOP[f] non collected <20 weeks	TOP non collected <20 weeks	3 TOP and one spontaneous miscarriage	0% of stillbirth or TOP	TOP non-collected <20 weeks

[a] NR: not reported.
[b] AGA: appropriate for gestational age.
[c] SGA: small for gestational age.
[d] LGA: large for gestational age.
[e] AW: Alive and well.
[f] TOP: termination of pregnancy.
[g] SD: sudden death.

Table 2
Characteristics and clinical results of the single case.

References	Year	Country	Age (years)	GA[a] at diagnosis	Localization of the disease	Stage of the disease	Localization of metastasis	Treatment during pregnancy	Data related with the end of pregnancy	GA at delivery (weeks)	Data related with the foetal weight (grs)	Placental metastasis	Neonatal outcome	Maternal outcome
Alexander et al. [43]	2004	E.E.U.U	29	5	Vulvar	A[b] (Stage III)	Lung, chest	Surgery	VD[c]	37	2790	Yes	AW[d]	MD[e] 1 month after
Daly et al. [15]	2006	Australia	34	17	Scapular	A (Stage IV)	Axilla, chest	Radiotherapy	Induced and CS[f]	37	2735	No	AW/VSD[g]	AW 6 months after
Gojnic et al. [44]	2006	Serbia	NR[h]	36	Vagina	Localized	No	Surgery	Primary CS	38	3450	NR	AW	Postnatal Surgery + Radiotherapy, AW
Egberts et al. [45]	2006	Germany	36	11	Cheek	A[i] (Stage IV)	Neck	Chemotherapy	Induced and VD	36	NR	No	Twins AW	MD 12 months after
Sato et al. [46]	2008	Japan	35	19	Left foot	A (Stage IV)	Pelvis	Surgery	Primary CS	32	1887	No	AW	MD 6 months after
Shuhaila et al. [47]	2008	Singapore	40	29	Early metastatic disease	A (Stage IV)	Ovary, mesentery, placenta	No	Urgent CS	29	1045	Yes	IUGR[j]/AW	MD 1 week after
Jasaitiene et al. [48]	2009	Lithuania	34	NR	Buttock	A (Stage III)	Inguinal lymph nodes	Postnatal Surgery	Induced and VD	29	1529	No	AW	MD 5 months after
Yeung et al. [16]	2008	E.E.U.U	26	15	Arm	A (Stage IV)	CNS[i]	Palliative	Primary CS	27	820	Yes	ND (no autopsy)	MD 1 day after
Gottschalk [14]	2009	Germany	37	29	Groin	A(Stage IV)	Liver, bone	Chemotherapy	Primary Cs	28	735	No	IUGR[j]/AW	MD 10 weeks after
Mathew et al. [49]	2009	Oman	28	28	Groin	A (Stage IV)	Lung, Liver, Breast	No	Induced and VD	28	1310	No	Neonatal death	MD 4 month after
Ishida et al. [50]	2009	Japan	29	17	Thigh	A (Stage III)	Inguinal lymph nodes	Surgery	VD	35	2208	No	AW	AW 4 months after
Youn et al. [17]	2010	Korea	21	21	Back	Localized	No	TOP	TOP	NR	-	No	–	MD 21 month after
Ustaalioglu et al. [51]	2010	Turkey	27	27	NR	A(Stage IV)	NR	Chemotherapy	Primary Cs	36	NR	NR	AW	AW 12 months after
Valenzano Menada [18]	2010	Italy	28	31	Gluteus	A (Stage IV)	breast, liver, peritoneum and spleen	No	Urgent CS	31	2030	Yes	Neonatal metastasis, remission	MD 2 weeks after
Brandt et al. [52]	2012	E.E.U.U	41	14	CS scar	Localized	No	Surgery in CS	Primary Cs	34	NR	No	AW	MD 12 months after
Sioulas et al. [53]	2013	Greece	37	33	Ovary	A (Stage IV)	Lung and CNS	No	Primary Cs	33	1895	NR	AW	AW
Maleka et al. [54]	2013	Sweden	37	30	Left upper quadrant	A(Stage IV)	Liver, lung, brain	Chemotherapy	Primary Cs	28	1028	No	AW	AW
Dyduch et al. [55]	2013	Poland	34	24	vulvar	Localized	No	Surgery	Primary Cs	NR	NR	No	AW	AW
Pabuccu et al. [56]	2013	Turkey	39	20	Back	Localized	No	Surgery	Primary Cs	38	3300	No	AW	AW
Jeremic et al. [57]	2015	Serbia	40	26	Back	Localized	No	Surgery	VD	37	1950	No	Intestinal atresia	AW

[a] Gestational Age.
[b] A: Advanced.
[c] VD:Vaginal delivery.
[d] AW alive and well.
[e] MD: Maternal death.
[f] CS: Caesarean section.
[g] VSD: Ventricular septal defect.
[h] NR: Not related.
[i] CNS: Central nervous system.
[j] IUGR Intrauterine growth retardation.

Table 3
Summary results from PAM published studies.

Variables	Total	Case series	Case reports	Author cases
Articles included in the study	25	5	20	
Number of patients included	491	469	20	2
Years of publication of the articles	From 2005 to 2015			
Years of data collection	From 1970 to 2015			
Localized disease (stages I-II)	425	419 (89.3%)	6 (30%)	0
Avanced disease (stages III-IV)	66	50 (10.7%)	14 (70%)	2 (100%)
Chemotherapy during pregnancy	8	4 (0.8%)	4 (20%)	0
Radiotherapy during pregnancy	2	1 (0.2%)	1 (5%)	0
Placental metastases	6	1 (0.2%)	4 (20%)	1 (50%)
Neonatal metastases	1	0	1 (5%)	0
Neonatal death associated with prematurity	5	0	4 (20%)	1 (50%)

corticosteroids and radiotherapy. Eight months after starting radiotherapy she required decompressive laminectomy. Two months later, she presented a progression of the bone lesions, for which she received palliative pembrolizumab. Despite the treatment she presented lung and hepatic metastases and now requires palliative care.

Systematic review

We found 25 articles published between January 2004 and May 2015 analysing the obstetrical and/or perinatal results in patients diagnosed with PAM. Two tables were created representing the total number of studies included as well as the analyzed variables. Five of these articles, showing the results of more than one patient (four retrospective and one prospective), are shown in Table 1, whereas the remaining 20 articles describing a single case report are shown in Table 2. The whole review included 489 patients from 25 articles: 469 cases were retrieved from articles including more than one patient and 20 cases were retrieved from single case report articles. We analyzed them separately since the results are not equivalent (Table 3).

Review of the case series (Table 1)

It is noteworthy to mention that most of the patients included in Table 1 are from Australia, Denmark and the United States of America, and the data was obtained between 1970 and 2012.

The studies published by O Meara et al. [9] and Bannister et al. [10] including 149 and 195 patients respectively, represent 73.3% of the patients included in this systematic review. We only found one prospective study, published by Andtbacka et al. [11] with a very small sample size (15 patients).

In all studies, the mean maternal age was 30.27 years (range 20–44 years of age) and the mean gestational age at diagnosis was 25.67 weeks.

Regarding the stage of the melanoma at diagnosis, it is noteworthy that in the study published by Pages et al. [12] all the patients included (22) were diagnosed at advanced stages (stages III-IV) whereas in the rest of the studies, at least 78% of the patients were diagnosed with a localized disease. The articles by Langergaard et al. [13] and Bannister et al. [10] report that 93% and 92.8% of the patients respectively were diagnosed at initial stages.

As for the oncologic management, two of the articles did not specify the treatment(s) administered. The most frequent approach was tumour resection with or without lymphadenectomy. Andtbacka et al. [11] performed sentinel node biopsy with technetium 99 or isosulfan blue dye at the time of tumour resection.

The treatment of advanced stages varied from no treatment at all to metastases resection, cerebral radiotherapy or chemotherapy with dacarbazine and fotemustin. Andtbacka et al. [11] proposed a treatment with interferon alpha 2b that was rejected by the patients.

The information about the perinatal variables studied was scarce in the articles reviewed, and we only found all the variables described in the articles published by Pages et al. [12] and Bannister et al. [10].

Two hundred and twenty-five patients (225) carried on with their pregnancies. The labour started spontaneously in 133 cases (59.11%), was induced in 48 cases (21.33%), an elective C-S was performed in 40 cases (17.77%) and an urgent C-S was performed in 4 cases (1.77%). Two of the studies included did not give any information about the termination of pregnancy (TOP). The patients had a normal vaginal delivery in 137 cases (62.1%), operative vaginal delivery in 20 cases (10.3%) and C-S in 68 cases (27.2%). The rate of C-S was 60% if we only include the cases diagnosed at advanced stages.

The mean gestational age at delivery was beyond 37 weeks in all series except in the study by Pages et al. [10]. In this study the mean gestational age was 36 weeks (range 26–41 weeks); 56% of the patients delivered prematurely.

Neonates presented low birth weight for their gestational age in 1.1 to 4.8% of the cases.

The histopathological study showed one case of placental metastases not affecting the offspring.

There were two cases of foetal malformation (one cardiovascular, and one unspecified). One baby died at 5 months of age due to sudden infant death syndrome.

Data regarding the miscarriages and TOP was not included in the biggest series (no obstetrical data under 20 weeks of gestation were registered) and only Pages et al. [12] and Andtbaka et al. [11] gave details. In the former only one spontaneous miscarriage and 3 TOPs were reported while in the latter no miscarriages or TOPs were reported.

Review of the case reports (Table 2)

Table 2 shows the results of single case reports, including data from 20 patients, retrieved between 2004 and 2015. The mean maternal age was 33.3 years and the mean gestational age at diagnosis was 22.5 weeks. The primary lesion was a cutaneous melanoma in 14 cases (70%), a mucosal melanoma in 3 cases, an ovarian melanoma in one case and two cases of metastatic melanoma with an unspecified primary lesion. The disease was diagnosed at advanced stages in 75% of the cases ($n = 15$).

The pregnancy was terminated in 5 cases before starting the oncological treatment. Seven out of all the patients that continued with the pregnancy after the diagnosis, underwent a surgery for the removal of the primary lesion. Systemic treatment administered in cases of advanced disease were vemurafenib, dacarbazine; nimustine; vincristine, cisplatine or alpha-interferon. Two patients received radiotherapy during pregnancy (the first one for a

vertebral fracture associated to metastases [14]; the second one to treat metastases in the axillary region [15]).

Yeung et al. [16] described one case of central nervous system metastases at diagnosis with maternal cerebral death at 15 weeks of gestation who received haemodynamic and nutritional support until week 27 of gestation and underwent a C-S.

The mean gestational age at delivery was 33.3 weeks (range 27–38 weeks) and the mean neonatal weight was 1914 grs (range 735–3450 grs). A TOP was performed in one case at 21 weeks of gestation [17]. Out of the remaining 19 patients, 15.78% ($n = 3$) had a spontaneous delivery, 21.05% ($n = 4$) a labour induction, 52.63% ($n = 21$) underwent an elective C-S and 10.52% ($n = 2$) an urgent C-S. Three neonates died due to premature birth complications. There were two cases of foetal malformation: one with a duodenal atresia and another with perimembranous interventricular communication and lack of testicular descent.

The histopathological study confirmed the presence of placental melanoma metastases in 4 cases (20%). Menada et al. [18] described a case in which an urgent C-S was performed due to maternal peritoneal carcinomatosis. At 3 months of age, the neonate developed a melanoma in the mastoid region and multiple pulmonary metastases that showed a progression even though a chemotherapy treatment with ifosfamide and adriamycin was initiated. However, at 5 months, after the chemotherapy was ended, the infant showed a regression of the metastases with complete remission while receiving palliative treatment.

Eleven patients (55%) died between the first day after delivery and the 21st month (mean 5.8 months).

If we analyze together all the cases of advanced disease (stages III and IV), including the two cases in our centre ($n = 36$), 11.1% ($n = 4$) terminated their pregnancy before 20 weeks (3 terminations of pregnancies and 1 miscarriage), 62.5% ($n = 20$) delivered by C-S and 37.5% ($n = 12$) delivered vaginally. The mean gestational age at delivery was 32 weeks (range 26–41 weeks). The mean neonatal weight was 1.745 gr (range 820–4360 gr). There were 3 registered neonatal deaths related to prematurity.

Discussion

Melanoma is one of the five most frequent malignancies during gestation, representing between 8% and 25% [5,19–21] of all malignancies diagnosed during pregnancy. The prevalence of PAM in our centre (3.1/100.000) is consistent with the literature (2.8 to 5.0/100.000 pregnancies [6]).

We present two cases of special interest. The first one shows a challenging situation, since the differential diagnosis included a wide spectrum of illnesses in a patient without a previous diagnosis of melanoma, resulting in maternal and neonatal death. The second case presents a patient with metastatic melanoma diagnosed prior to pregnancy who received no treatment during pregnancy and delivered a healthy neonate after 34-weeks of gestation.

We also present a systematic review of the articles published in the last 10 years including maternal, perinatal and oncological outcomes in PAM.

The articles that had the largest amount of patients are from countries with a high prevalence of melanoma. Lee et al. [22] whose study was performed in Australia and Eibye et al. [23] from Denmark state that melanoma is the most common malignancy associated with pregnancy. The incidence of melanoma in Caucasian population is inversely related to the country's distance from the equator [24]. New Zealand and Australia have the highest incidence of worldwide [25]. In Europe, the highest incidence in women is found in Denmark, Iceland, Norway, and Switzerland [26].

It is noteworthy that even though the articles were published within the last ten years, the cases were registered between 1970 and 2015, which should be taken into account due to the advances in oncological and obstetrical treatments in the last 45 years. Nowadays, USA patients with melanoma have a 5-year survival rate of 91.5% when the disease is detected in the early stages.

To diagnose PAM is challenging since the changes that happen to a melanocytic lesion could be misdiagnosed as physiologic pregnancy-related changes (hyperpigmentation or enlargement of the melanocytic lesions due to weight increase) and this contributes to a delayed diagnosis [10].

Melanoma treatment should include tumour resection, sentinel node biopsy and lymphadenectomy if necessary, following the standard procedures outside pregnancy [27]. Technetium-99 instead of Blue dye is recommended during pregnancy because, although rare, there is a 1:10,000 risk of anaphylactic reaction associated with isosulfan blue, which could threaten the life of both mother and foetus. The alternative, methylene blue dye, is known to be teratogenic and contraindicated in pregnancy [28]. The literature review shows high heterogeneity in the treatment of advanced melanoma. Unfortunately, the two studies with the largest number of cases [10,13] do not give details of the oncological treatment(s) administered. Indeed, it varies with gestational age, presence of metastases, local legislation, hospital protocols and maternal preferences. Melanoma management may include no pharmacological treatment, TOP, preterm labour induction or the administration of chemotherapy, radiotherapy or immunotherapy.

It has long been believed that hormonal and immunological changes associated with pregnancy worsen the prognosis and accelerate melanoma progression [29–33]. Pigmentation changes that occur during pregnancy, contraceptive treatment or hormone replacement therapy [34], along with the detection of oestrogen receptors in melanoma cells [35,36], generate doubts about the possible influence of pregnancy on the evolution of the disease. However, many authors defend a similar prognosis of melanoma in pregnant and non-pregnant women at a similar stage of disease [37–41].

On the other side, very few recent articles analyze the influence of melanoma on obstetrical and perinatal results. With the exception of the article published by Pages et al. [12] (which analyses pregnant women with advanced melanoma), most of the articles included in our review did not find differences in obstetrical and perinatal outcomes in PAM when compared with the general population. This can be related to the fact that most of these articles analyze patients with early stages of melanoma. In our review, patients with advanced stages have more premature deliveries with lower neonatal weight, higher C-S rate and more miscarriages, consistent with the data presented by Lee et al. [22,42]. In fact, they found that women with cancer have higher probabilities to deliver in a tertiary centre, higher amount of prenatal hospitalizations, induced deliveries, preterm births, elective C-S and low birth weight compared with women without cancer.

Transplacentary metastatic dissemination is rare, but melanoma is the malignancy that metastasizes more frequently to the placenta [42]. In our results, placental metastases were present in 6 patients with advanced disease. This represents 1.22% of all the patients included in this review, and 16.66% of the patients with metastatic disease. One case [18] presented neonatal metastases (2.77%). The foetal risk of melanoma metastases with placental involvement is 16.7%, similar to that described by Alexander et al. [42] who stated a risk of foetal and placental involvement of 22%. However, they found a 83% of neonatal mortality and, in our review, the only case with neonatal melanoma metastases had a subsequent tumour remission while on palliative treatment.

To conduct our systematic review, we selected the articles that analyzed the obstetrical and materno-foetal results of patients

with PAM. We only included patients with active melanoma during pregnancy, excluding those diagnosed during the first or second year after delivery. However, some authors also include this period since they consider that the disease was probably already present during pregnancy [9,10,13].

We also excluded 620 patients from the Langergaard study [13] who had melanoma diagnosed before pregnancy, even though some of these patients had complete remission before pregnancy.

The analysis of the variables studied was also limited by the heterogeneity of the articles, since some authors did not describe the variables we included in our review, and when included, they were not always similarly reported.

Furthermore, the three articles that include most of the patients [9,10,13] (92.11% of the cases presented in Table 1), do not describe the pregnancies terminated before the twentieth week of gestation. This could create a selection bias as we do not know the amount of miscarriages, foetal malformations or TOPs that could be related to the melanoma, which could underestimate the adverse obstetrical results. In fact, Eibye et al. [23] published that 19.9% of the patients with PAM suffered a miscarriage during pregnancy, of which 12.5% were TOP.

Despite these limitations, our study presents the first systematic review of the literature analysing the effect of melanoma on obstetrical and neonatal outcomes, by gathering data from 489 patients.

Conclusion

Melanoma is one of the most common malignancies diagnosed during gestation. Diagnosis is usually made at early stages and patients with PAM should be controlled in a tertiary centre with a multidisciplinary approach. Surgical treatment should not be altered by the pregnancy, but the treatment of the metastatic disease should be individualized. Prognosis of melanoma does not seem to be altered by pregnancy. However, obstetrical and materno-perinatal outcomes seem to vary depending on the stage of the disease. Advanced melanoma is associated with a risk of prematurity, low birth weight and higher rates of C-S and neonatal morbidity and mortality.

Transplacental transmission of malignant melanoma to the foetus is very rare and has been described in women with distant metastases.

With the growing incidence malignancies during pregnancy, it would be interesting to create an international database in order to minimize differences in the recorded data, to compare the treatments used and to evaluate globally the evolution of the malignancies and the obstetric and materno-perinatal outcomes.

Disclosure of interests

We have read and understood the BMJ policy on declaration of interests and declare the following: none

Ethical approval

Consent to publish has been provided for the two cases represented in the paper.

Contribution to Authorship

EM and JDL conceived and designed the study, extracted data, performed the systematic review and wrote the paper, NR, LJ, PP, PR, VO and SL analyzed the data and contributed analysis tools.

Funding

This study received no specific funding or grant.

Appendix A. Supplementary data

Supplementary data associated with this article can be found, in the online version, at http://dx.doi.org/10.1016/j.ejogrb.2017.04.023

References

[1] Bataille V, de Vries E. Melanoma–Part 1: epidemiology, risk factors, and prevention. BMJ 2008;337:a2249.
[2] Pavlidis NA. Coexistence of pregnancy and malignancy. Oncologist 2002;7(4):279–87.
[3] Oduncu FS, Kimmig R, Hepp H, Emmerich B. Cancer in pregnancy: maternal-fetal conflict. J Cancer Res Clin Oncol 2003;129(3):133–46.
[4] Parente JT, Amsel M, Lerner R, Chinea F. Breast cancer associated with pregnancy. Obstet Gynecol 1988;71(6 Pt 1):861–4.
[5] Slingluff CL, Seigler HF. Malignant melanoma and pregnancy. Ann Plast Surg 1992;28(1):95–9.
[6] Dillman RO, Vandermolen LA, Barth NM, Bransford KJ. Malignant melanoma and pregnancy ten questions. West J Med 1996 Feb;164(2):156–61.
[7] Schwartz JL, Mozurkewich EL, Johnson TM. Current management of patients with melanoma who are pregnant, want to get pregnant, or do not want to get pregnant. Cancer 2003;97(9):2130–3.
[8] Liberati A, Altman DG, Tetzlaff J, Mulrow C, Gøtzsche PC, Ioannidis JP, et al. The PRISMA statement for reporting systematic reviews and meta-analyses of studies that evaluate healthcare interventions: explanation and elaboration. BMJ 2009;339:b2700.
[9] O'Meara AT, Cress R, Xing G, Danielsen B, Smith LH. Malignant melanoma in pregnancy. A population-based evaluation. Cancer. 2005;103(6):1217–26.
[10] Bannister-Tyrrell M, Roberts CL, Hasovits C, Nippita T, Ford JB. Incidence and outcomes of pregnancy-associated melanoma in New South Wales 1994-2008. Aust N Z J Obstet Gynaecol 2015;55(2):116–22.
[11] Andtbacka RH, Donaldson MR, Bowles TL, Bowen GM, Grossmann K, Khong H, et al. Sentinel lymph node biopsy for melanoma in pregnant women. Ann Surg Oncol 2013;20(2):689–96.
[12] Pagès C, Robert C, Thomas L, Maubec E, Sassolas B, Granel-Brocard F, et al. Management and outcome of metastatic melanoma during pregnancy. Br J Dermatol 2010;162(2):274–81.
[13] Langagergaard V, Puho EH, Lash TL, Nørgård B, Sørensen HT. Birth outcome in Danish women with cutaneous malignant melanoma. Melanoma Res 2007;17(1):31–6.
[14] Gottschalk N, Jacobs VR, Hein R, Fischer T, Schneider KT, Pildner von Steinburg S. Advanced metastatic melanoma during pregnancy: a multidisciplinary challenge. Onkologie 2009;32(12):748–51.
[15] Daly TA, Burmeister BH, Smithers BM, Doody J, Kane A. Radiotherapy for metastatic melanoma presenting in pregnancy. Australasian Radiol 2006;50(6):598–603.
[16] Yeung P, McManus C, Tchabo JG. Extended somatic support for a pregnant woman with brain death from metastatic malignant melanoma: a case report. J Matern Fetal Neonatal Med 2008;21(7):509–11.
[17] Youn SH, Lee YW, Seung NR, Park EJ, Cho HJ, Kim KH, et al. Rapidly progressing malignant melanoma influenced by pregnancy. Int J Dermatol 2010;49(11):1318–20.
[18] Valenzano Menada M, Moioli M, Garaventa A, Nozza P, Foppiano M, Trimarchi N, et al. Spontaneous regression of transplacental metastases from maternal melanoma in a newborn: case report and review of the literature. Melanoma Res 2010;20(6):443–9.
[19] Lishner M. Cancer in pregnancy. Ann Oncol 2003;14(Suppl 3):iii31–6.
[20] Miller E, Barnea Y, Gur E, Leshem D, Karin E, Weiss J, et al. Malignant melanoma and pregnancy: second thoughts. J Plast Reconstr Aesthet Surg 2010;63(7):1163–8.
[21] Lens M, Bataille V. Melanoma in relation to reproductive and hormonal factors in women: current review on controversial issues. Cancer Causes Control 2008;19(5):437–42.
[22] Lee YY, Roberts CL, Dobbins T, Stavrou E, Black K, Morris J, et al. Incidence and outcomes of pregnancy-associated cancer in Australia, 1994-2008: a population-based linkage study. BJOG 2012;119(13):1572–82.
[23] Eibye S, Kjær SK, Mellemkjær L. Incidence of pregnancy-associated cancer in Denmark, 1977-2006. Obstet Gynecol 2013;122(3):608–17.
[24] Armstrong BK. Epidemiology of malignant melanoma: intermittent or total accumulated exposure to the sun? J Dermatol Surg Oncol 1988;14(8):835–49.
[25] Sneyd MJ, Cox B. A comparison of trends in melanoma mortality in New Zealand and Australia: the two countries with the highest melanoma incidence and mortality in the world. BMC Cancer 2013;13:372.
[26] Karim-Kos HE, de Vries E, Soerjomataram I, Lemmens V, Siesling S, Coebergh JW. Recent trends of cancer in Europe: a combined approach of incidence, survival and mortality for 17 cancer sites since the 1990s. Eur J Cancer 2008;44(10):1345–89.

[27] Peccatori FA, Azim Jr. HA, Orecchia R, Hoekstra HJ, Pavlidis N, Kesic V, et al. Cancer, pregnancy and fertility: ESMO Clinical Practice Guidelines for diagnosis, treatment and follow-up. Ann Oncol 2013;24(Suppl 6):vi160–70.
[28] Dunki-Jacobs EM, Callender GG, McMasters KM. Current management of melanoma. Curr Probl Surg 2013;50(8):351–82.
[29] Pack GT, Scharnagel IM. The prognosis for malignant melanoma in the pregnant woman. Cancer 1951;4(2):324–34.
[30] Byrd BF, Mcganity WJ. The effect of pregnancy on the clinical course of malignant melanoma. South Med J 1954;47(3):196–200.
[31] Byrom L, Olsen C, Knight L, Khosrotehrani K, Green AC. Increased mortality for pregnancy-associated melanoma: systematic review and meta-analysis. J Eur Acad Dermatol Venereol 2015;29(8):1457–66.
[32] Driscoll MS, Grant-Kels JM. Nevi and melanoma in pregnancy. Dermatol Clin 2006;24(2)199–204 vi.
[33] Sutherland CM, Loutfi A, Mather FJ, Carter RD, Krementz ET. Effect of pregnancy upon malignant melanoma. Surg Gynecol Obstet 1983;157(5):443–6.
[34] Driscoll MS, Grant-Kels JM. Hormones, nevi, and melanoma: an approach to the patient. J Am Acad Dermatol 2007;57(6)919–31 quiz 32-6.
[35] Driscoll MS, Grant-Kels JM. Estrogen receptor expression in cutaneous melanoma. Arch Dermatol 2009;145(1):73–5.
[36] Ohata C, Tadokoro T, Itami S. Expression of estrogen receptor beta in normal skin, melanocytic nevi and malignant melanomas. J Dermatol 2008;35(4):215–21.
[37] Daryanani D, Plukker JT, De Hullu JA, Kuiper H, Nap RE, Hoekstra HJ. Pregnancy and early-stage melanoma. Cancer 2003;97(9):2248–53.
[38] Lens MB, Rosdahl I, Ahlbom A, Farahmand BY, Synnerstad I, Boeryd B, et al. Effect of pregnancy on survival in women with cutaneous malignant melanoma. J Clin Oncol 2004;22(21):4369–75.
[39] Ariel IM. Theories regarding the cause of malignant melanoma. Surg Gynecol Obstet 1980;150(6):907–17.
[40] Byrom L, Olsen CM, Knight L, Khosrotehrani K, Green AC. Does pregnancy after a diagnosis of melanoma affect prognosis? Systematic review and meta-analysis. Dermatol Surg 2015;41(8):875–82.
[41] MacKie RM, Bufalino R, Morabito A, Sutherland C, Cascinelli N. Lack of effect of pregnancy on outcome of melanoma. For The World Health Organisation Melanoma Programme. Lancet 1991;337(8742):653–5.
[42] Alexander A, Samlowski WE, Grossman D, Bruggers CS, Harris RM, Zone JJ, et al. Metastatic melanoma in pregnancy: risk of transplacental metastases in the infant. J Clin Oncol 2003;21(11):2179–86.
[43] Alexander A, Harris RM, Grossman D, Bruggers CS, Leachman SA. Vulvar melanoma: diffuse melanosis and metastasis to the placenta. J Am Acad Dermatol 2004;50(2):293–8.
[44] Gojnic M, Dugalic V, Milicevic S, Arsenijevic L, Popovic N, Stefanovic A. Vaginal malignant melanoma in a healthy pregnancy–a case report. Eur J Gynaecol Oncol 2006;27(2):201–3.
[45] Egberts F, Lischner S, Russo P, Kampen WU, Hauschild A. Diagnostic and therapeutic procedures for management of melanoma during pregnancy: risks for the fetus? J Dtsch Dermatol Ges 2006;4(9):717–20.
[46] Sato T, Ishiko A, Saito M, Tanaka M, Ishimoto H, Amagai M. Rapid growth of malignant melanoma in pregnancy. J Dtsch Dermatol Ges 2008;6(2):126–9.
[47] Shuhaila A, Rohaizak M, Phang KS, Mahdy ZA. Maternal melanoma with placental metastasis. Singapore Med J 2008;49(3):e71–2.
[48] Jasaitiene D, Valiukeviciene S, Makstiene J, Juodzbaliene EB. Metastatic amelanotic nodular melanoma during pregnancy. Medicina (Kaunas) 2008;44(6):467–71.
[49] Mathew M, Sheik S, Rao K, Burney IA, Sawhney S, Al-Hamdani A. Metastatic malignant melanoma during pregnancy: case report and a review of the literature. Sultan Qaboos Univ Med J 2009;9(1):79–83.
[50] Ishida I, Yamaguchi Y, Tanemura A, Hosokawa K, Itami S, Morita A, et al. Stage III melanoma treated with chemotherapy after surgery during the second trimester of pregnancy. Archiv Dermatol 2009;145(3):346–8.
[51] Ustaalioglu BBO, Gumus M, Unal A, Cayir K, Sever O, Bilici A, et al. Malignancies diagnosed during pregnancy and treated with chemotherapy or other modalities (review of 27 cases) multicenter experiences. Int J Gynecol Cancer 2010;20(5):698–703.
[52] Brandt JS, Fishman S, Magro CM. Cutaneous melanoma arising from a cesarean delivery skin scar. J Perinatol 2012;32(10):807–9.
[53] Sioulas VD, Panayiotides IG, Chrelias C, Grammatikakis I, Vaggopoulos V, Kefala M, et al. Ovarian melanoma complicating pregnancy achieved by in-vitro fertilisation. J Obstetr Gynaecol 2013;33(1):95–U147.
[54] Maleka A, Enblad G, Sjörs G, Lindqvist A, Ullenhag GJ. Treatment of metastatic malignant melanoma with vemurafenib during pregnancy. J Clin Oncol 2013;31(11):e192–3.
[55] Dyduch G, Jach R, Huras H, Radoń-Pokracka M, Szpor J, Pityński K, et al. Recurrent vulvar melanoma in 35-year-old pregnant women. J Low Genit Tract Dis 2013;17(2):223–5.
[56] Pabuccu R, Kiseli M, Kahyaoğlu I, Cağlar GS, Yılmaz MB. Malignant melanoma arising in an in vitro fertilisation pregnancy: a case report. J Turk Ger Gynecol Assoc 2013;14(3):186–7.
[57] Jeremić J, Jeremić K, Stefanović A, Gojnić M, Stojnić J, Nikolić Z. Pregnancy associated with melanoma and fetal anomalies: a case report and review of literature. Clin Exp Obstet Gynecol 2015;42(3):386–7.