SPECIAL TOPIC

Optimizing Postsurgical Scars: A Systematic Review on Best Practices in Preventative Scar Management

Justin L. Perez, M.D.
Rod J. Rohrich, M.D.

Dallas, Texas

Background: Scar management is critical for every plastic surgeon's practice and, ultimately, the patient's satisfaction with his or her aesthetic result. Despite the critical nature of this component of routine postoperative care, there has yet to be a comprehensive analysis of the available literature over the past decade to assess the best algorithmic approach to scar care. To this end, a systematic review of best practices in preventative scar management was conducted to elucidate the highest level of evidence available on this subject to date.
Methods: A computerized MEDLINE search was performed for clinical studies addressing scar management. The resulting publications were screened randomized clinical trials that met the authors' specified inclusion/exclusion criteria.
Results: This systematic review was performed in May of 2016. The initial search for the Medical Subject Headings term "cicatrix" and modifiers "therapy, radiotherapy, surgery, drug therapy, prevention, and control" yielded 13,101 initial articles. Applying the authors' inclusion/exclusion criteria resulted in 12 relevant articles. All included articles are randomized, controlled, clinical trials.
Conclusions: Optimal scar care requires taking into account factors such as incisional tension, anatomical location, and Fitzpatrick skin type. The authors present a streamlined algorithm for scar prophylaxis based on contemporary level I and II evidence to guide clinical practice. (*Plast. Reconstr. Surg.* 140: 782e, 2017.)

Plastic surgeons are judged by the scars—or lack thereof—that they produce, and patients seeking purely cosmetic procedures hold high standards with regard to postoperative scar aesthetics. Furthermore, unsightly scars may cause patients serious psychosocial distress in the perioperative period.[1–3] Several therapies exist to treat various scar types, including gels, creams, chemotherapeutic injectables, laser, and pressure therapy.[4–8] However, systematic review of the best evidence in preventative scar management is seriously lacking, mainly because of the scarcity of clinical trial data with adequate controls. The following is a systematic review of current literature to critically evaluate scar care modalities based on the highest level of clinical trial data available to date.

PATIENTS AND METHODS

Our population includes patients with surgical incisions with no known history of pathologic wound healing. The outcome of interest is aesthetically acceptable scar healing (e.g., native skin match, minimal erythema, no hypertrophy). For the purpose of focusing this review, outcomes of therapeutic modalities for preexisting pathologic scarring (i.e., keloids) were excluded.

A systematic review was conducted by means of computer-based MEDLINE search and Medical Subject Headings terms "cicatrix" AND "therapy, radiotherapy, surgery, drug therapy, prevention, and control." Abstracts and reference lists of the resultant articles were reviewed for inclusion and exclusion criteria as outlined (Table 1).

From the Department of Plastic Surgery, University of Texas Southwestern Medical Center; and the Dallas Plastic Surgery Institute.
Received for publication September 19, 2016; accepted April 3, 2017.
Presented at the Cosmetic Bootcamp Meeting, in Aspen, Colorado, July 7 through 10, 2016.
Copyright © 2017 by the American Society of Plastic Surgeons
DOI: 10.1097/PRS.0000000000003894

Disclosure: *Dr. Rohrich receives instrument royalties from Eriem Surgical, Inc., and book royalties from Thieme Medical Publishing. Neither author has any financial interest in any of the products or devices mentioned herein. Dr. Perez has no financial information to disclose. No funding was received for this article.*

Copyright © 2017 American Society of Plastic Surgeons. Unauthorized reproduction of this article is prohibited.

Table 1. Study Inclusion and Exclusion Criteria

Inclusion criteria
Published within the past 10 yr
Follow-up time ≥3 mo
Human subjects only
Postsurgical scars
Clinical trials
Full-text available
Exclusion criteria
Experimental modalities with preliminary data
Follow up time <3 mo
Articles not in the English language
Case reports, review articles, letters
Articles that address unique scar populations (e.g., pediatrics, burns, keloids, acne)
Experimental modalities with preliminary data

RESULTS

PubMed Search

The computer-based MEDLINE search was conducted in May of 2016. Initial PubMed search [Medical Subject Headings (a vocabulary controlled by the National Library of Medicine to uniformly index biomedical literature) terms "cicatrix" AND "therapy, radiotherapy, surgery, drug therapy, prevention and control" modifiers] yielded 13,101 articles (Fig. 1). When filtered for clinical trials, 865 articles resulted. When "published within last 10 years," "human," "English," and "full text article" filters were applied, 438 articles resulted. After abstract screening for inclusion/exclusion criteria, our MEDLINE search produced 18 articles of interest. Of these, six were excluded for experimental modalities with preliminary data.

Study Characteristics

Given our goal of critically analyzing the highest level of therapeutic data, all included articles are randomized controlled trials. All studies address postsurgical scars within 1 year of surgery. Study endpoints are predicated on standardized, validated scar assessment tools (i.e., Vancouver Scar Assessment Scale, Patient and Observer Scar Assessment Scale, Manchester Scar Scale, or graded tiers of scar appearance) (Figs. 2 and 3).[9–14]

Study Comparison

The heterogeneous nature of outcome measures in the selected studies precluded a meaningful numerical meta-analysis. Scar assessment tools, although an attempt to objectify scar appearance and morphology, are inherently descriptive.[9–14] Thus, a narrative review of the available evidence was conducted (Tables 2 through 5).[15–26] Selected clinical trials were divided into subgroups based on modality: topical therapy (keratin, silicone gel/sheets), laser therapeutics (pulsed dye laser, neodymium:yttrium-aluminum-garnet laser, 1550-nm nonablative laser, potassium-titanyl-phosphate laser), or compressive measures (mechanomodulation).

Topical Scar Management Studies

Three studies scrutinized silicone gel as topical means to optimize linear postsurgical scars.[15,18,19] The first, by de Giorgi et al., compared use of silicone gel against zinc oxide cream controls.[15] Outcome measures were resultant scar type (categorized as physiologic versus pathologic) and wound healing symptoms (i.e., paresthesia, pulling sensation, erythema). Pathologic scarring (i.e., widened, atrophic, or hypertrophic) was lower in the treatment group (27 percent) compared with the zinc oxide group (55 percent). No keloids formed in the treatment group, versus 11 percent keloid formation in controls. Hypertrophic scarring was decreased in the treatment group (9 percent) compared with controls (22 percent). In sum, there was a 28 percent absolute reduction rate (51 percent relative reduction) in pathologic scarring, with a number needed-to-treat of 3.6 patients to prevent one "pathologic" scar. Silicone gel with sunscreen additive resulted in less scar hyperpigmentation than zinc oxide alone.

Scuderi et al. and Signorini and Clementoni compared silicone gel (Dermatix) to either cyanoacrylate (Wipescar) or no treatment, respectively.[18,19] In the former, profilometry showed equal scar elevation in both cohorts at 1 month (range, 0.176 to 0.177 mm) with equal scar flattening at 1 year (range, 0.122 to 0.125 mm). Dermatix scars were 75 percent wider (1.4 mm) versus Wipescar (0.8 mm; $p < 0.0001$). A trend toward increased Vancouver Scar Assessment Scale scores was noted in both cohorts. Patients preferred applying cyanoacrylate every 3 to 5 days compared with twice-daily silicone gel application. No pathologic scarring occurred.[18] Signorini and Clementoni reported higher normal scar maturation in the treatment group (67 percent) compared with nontreated controls (28 percent). Furthermore, patients without scar care had higher rates of scar hypertrophy at 55 percent (versus treatment group, 23 percent). Patients who developed hypertrophy were transitioned to triamcinolone injection.[19]

Jina et al. compared keratin gel to aqueous cream and reported worse scarring in their control (Manchester Scar Scale score, 14.2) versus treatment cohort (Manchester Scar Scale score,

Copyright © 2017 American Society of Plastic Surgeons. Unauthorized reproduction of this article is prohibited.

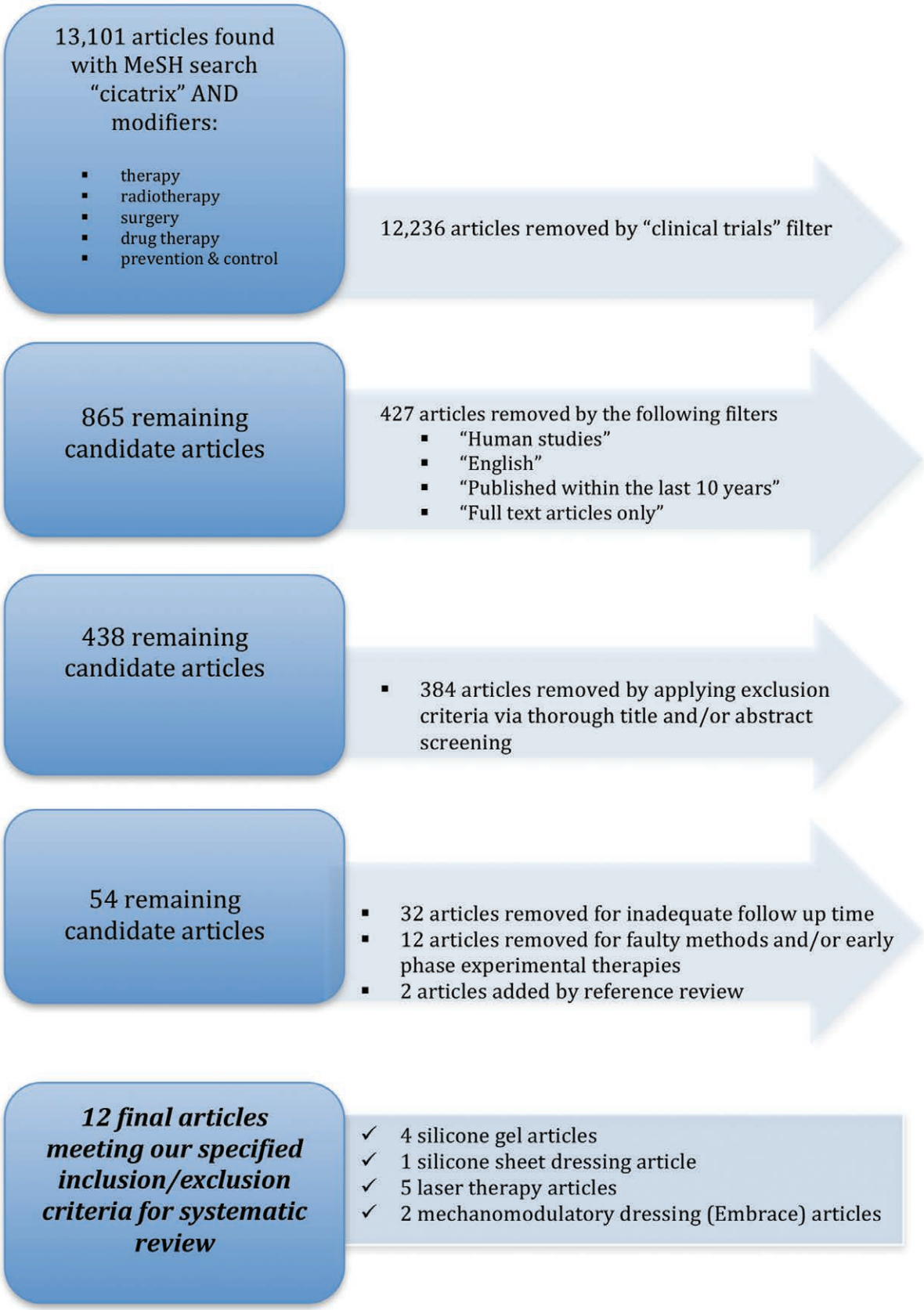

Fig. 1. Schematic of computerized MEDLINE search. *MeSH*, Medical Subject Headings.

Copyright © 2017 American Society of Plastic Surgeons. Unauthorized reproduction of this article is prohibited.

Vancouver Scar Assessment Scale

Pigmentation	Vascularity	Pliability	Height
0: Normal – closely resembles color of rest of body	0: Normal	0: Normal	0: Normal (flat)
1: Hypopigmentation	1: Pink	1: Supple – flexible with minimal resistance	1: <2 mm
2: Hyperpigmentation	2: Pink to red	2: Yielding - giving way to pressure	2: 2-5 mm
	3: Red	3: Firm – inflexible, not easily moved, resistant to manual pressure	3: >5 mm
	4: Red to purple	4: Banding – rope-like tissue that blanches with extension of scar	
	5: Purple	5: Contracture – permanent shortening of scar producing deformity or distortion	

Manchester Scar Scale

Color	Matte vs. Shiny	Contour	Distortion	Texture
1: Perfect	1: Matte	1: Flush with surrounding skin	1: None	1: Normal
2: Slight mismatch	2: Shiny	2: Slightly proud/Indented	2: Mild	2: Just palpable
3: Obvious mismatch		3: Hypertrophic	3: Moderate	3: Firm
4: Gross mismatch		4: Keloid	4: Severe	4: Hard

Fig. 2. The Vancouver Scar Assessment Scale and the Manchester Scar Scale, two commonly used standardized assessment tools to objectively quantify the degree of scar cosmetic improvement.

12.2).[16] Higher Manchester Scar Scale score correlates with more color mismatch, shinier appearance, elevation, and firm texture. The authors do not further quantify scar topography.[27]

Maher et al. examined use of silicone sheets (continuous wear, 6 months) on linear postsurgical scars versus no treatment (bisected scar).[17] Observers consistently rated improved scar pliability and pigmentation. However, patients noted similar improvement in scar thickness, relief, surface, width, and vascularity in both treated and untreated scars. Furthermore, there was no difference in pain or pruritus. Adverse effects were limited to minor skin irritation (20 percent).

Data Summarized

- Use of silicone gel improves scar maturation with regard to color and texture, and decreases pathologic scarring rate compared with zinc oxide cream or no scar treatment at all.
- Cyanoacrylate may be more efficacious than silicone gel in preventing scar widening.
- Keratin gel may soften and flatten poststernotomy scars; data in cosmetic cohorts are lacking.
- According to recent trials, silicone sheets do not alter scar appearance from the perspective of patients with a history of normal wound healing.

Light and Laser Therapy

Of three trials that address laser therapy for scar prophylaxis in mixed patient populations, two compare nonablative fractional laser to either no therapy or pulsed dye laser.[21,22] Verhaeghe et al. report significantly improved scar profiles by Physician Global Assessment Scales at 1 ($p < 0.001$) and 3 months ($p < 0.001$) postoperatively.[21] Incisions and full-thickness skin grafts treated with nonablative fractional laser scored significantly closer to native skin in thickness ($p = 0.001$), relief ($p = 0.001$), and pliability ($p = 0.002$) as assessed by

Copyright © 2017 American Society of Plastic Surgeons. Unauthorized reproduction of this article is prohibited.

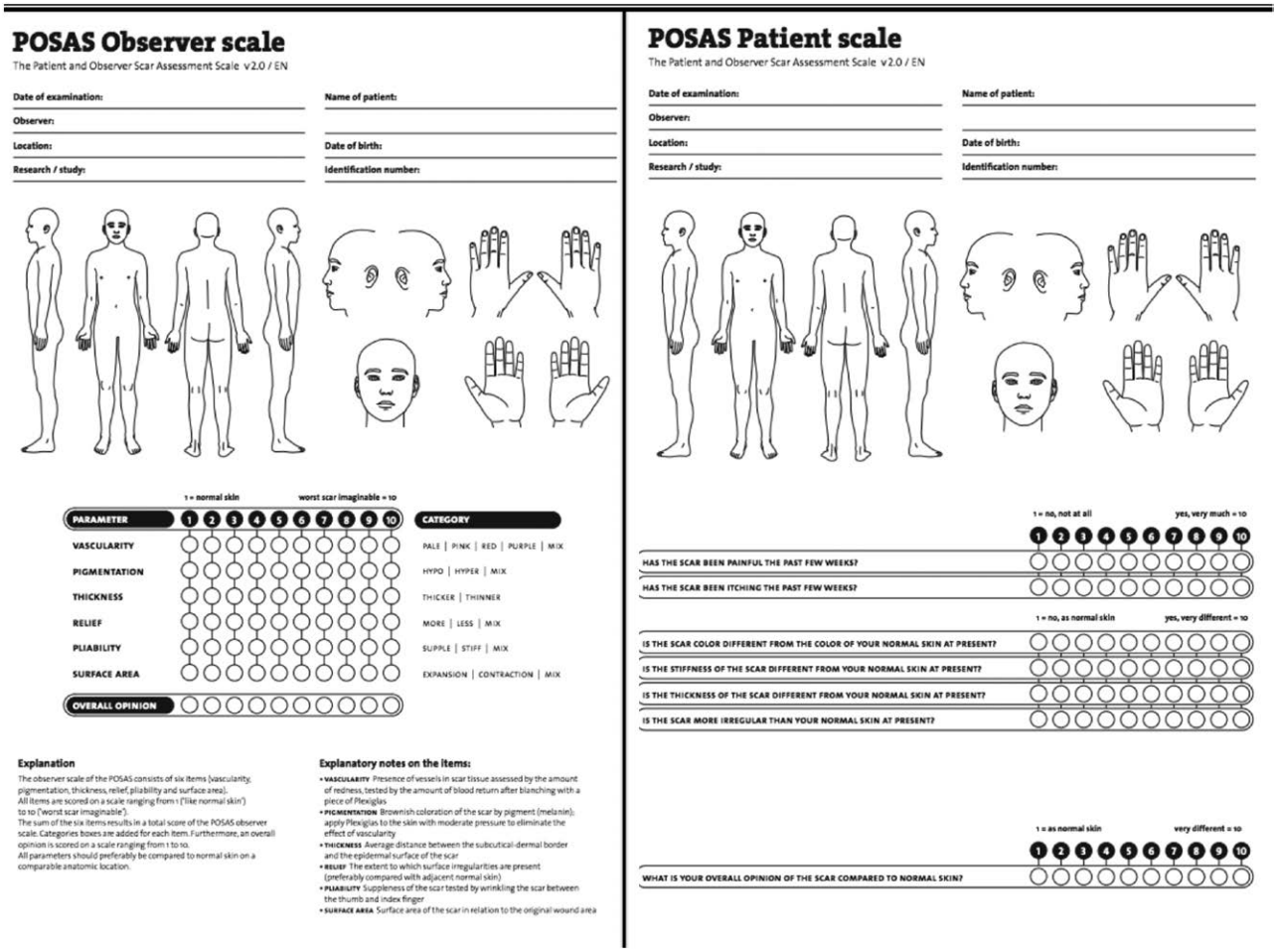

Fig. 3. Composite of Patient and Observer Scar Assessment Scale, another commonly used standardized assessment tool to objectively quantify the degree of scar cosmetic improvement.

blinded physicians. There was no long-term difference in skin reflectance. Adverse events included erythema (67 percent) and rare but serious events such as vesicle or ulcer formation (4 percent). No long-term adverse events occurred.

Tierney et al. compared 595-nm pulsed dye laser against 1550-nm nonablative fractional laser for scar prophylaxis using an institutionally created five-point assessment scale (i.e., surveying dyspigmentation, hypopigmentation, thickness, texture, overall cosmesis).[22] The authors noted improvement in all five aesthetic parameters—pigmentary variation (64.2 percent improvement with nonablative fractional laser versus 45.8 percent with pulsed dye laser; $p < 0.001$), hypopigmentation (65 percent improvement versus 0 percent; $p < 0.001$), thickness (86.6 percent improvement versus 45.8 percent; $p < 0.001$), texture (73.3 percent versus 52.5 percent; $p < 0.001$), and overall aesthetic appearance (75 percent versus 53 percent; $p < 0.001$). Eighty-three percent of patients globally preferred nonablative fractional laser. Nonablative fractional laser was associated with more postprocedural pain, but this did not dissuade patients from continuing therapy. Transient side effects included mild pain, erythema, and edema. No blistering occurred.

Vas et al. compared pulsed dye laser/neodymium:yttrium-aluminum-garnet laser against no treatment and found unanimously improved scar parameters by Vancouver Scar Assessment Scale (i.e., pigmentation, vascularity, pliability, and scar height; $p < 0.05$).[20] The group provides dermoscopic evidence (e.g., skin surface microscopy) for improved scar architecture—namely, narrower, flatter scars with decreased vascularity. No significant complications were reported.

Two studies addressed preventative laser therapy in patients with Fitzpatrick skin type IV or higher.[23,24] Choe et al. reported a statistically significant decrease in Vancouver Scar Assessment Scale on bisectionalized scars treated with 1550-nm fractional

Copyright © 2017 American Society of Plastic Surgeons. Unauthorized reproduction of this article is prohibited.

Table 2. Summary of Study Characteristics

Reference	Modality	Comparative Modality	Study Size (*n*)	Single vs. Multi-Institutional
de Giorgi et al., 2009[15]	Silicone gel (with sunscreen contained, brand not specified)	Zinc oxide cream	110	Single
Jina et al., 2015[16]	Keratin gel (KeragelT)	Aqueous cream	20	Single
Maher et al., 2012[17]	Silicone sheet (brand not specified)	Nothing/untreated	10	Single
Scuderi et al., 2011[18]	Silicone gel (Dermatix; Valeant Pharmaceuticals International, Aliso Viejo, Calif.)	Cyanoacrylate (Wipescar, FaselS.r.l., Bologna, Italy)	85	Multi
Signorini and Clementoni, 2007[19]	Silicone gel (Dermatix)	Nothing/untreated	160	Single
Vas et al., 2014[20]	Sequential 585-nm PDL/Nd:YAG Laser (Cynergy, Cynosure)	Nothing/untreated	25	Single
Verhaeghe et al., 2012[21]	1540-nm NAFL	Nothing/untreated	24	Single
Tierney et al., 2009[22]	595-nm PDL (Candela Corp Inc., Wayland, Mass.)	1550-nm NAFL (erbium doped fiber laser (Fraxel RS, Reliant Technologies, Mountain View, Calif.)	12	Single
Yun et al., 2010[23]	532-nm KTP Laser (plus silicone sheeting)	Silicone sheeting	28	Single
Choe et al., 2009[24]	1550-nm fractional erbium-glass laser (MOSAIC, Lutronic Co., Seoul, Republic of Korea)	Nothing/untreated	27	Single
Longaker et al., 2014[25]	Embrace advanced scar therapy device (Neodyne)	Nothing	36	Multi
Lim et al., 2014[26]	Embrace	Nothing [Steri-Strips (3M, St. Paul, Minn.) alone or no treatment]	12	Single

PDL, pulsed dye laser; Nd:YAG, neodymium:yttrium-aluminum-garnet; NAFL, nonablative fractional laser; KTP, potassium-titanyl-phosphate.

Table 3. Summary of Study Characteristics

Reference	Age Range (yr)	Mean Age (yr)	Sex	Fitzpatrick Skin Type Included
de Giorgi et al., 2009[15]	23–81	52	M, F	I, II, III, IV
Jina et al., 2015[16]	≥18	60.6	M predominant	NS
Maher et al., 2012[17]	17–33	25.5	M, F	NS
Scuderi et al., 2011[18]	18–52	32	F	NS
Signorini and Clementoni, 2007[19]	5–82	53	M, F	NS
Vas et al., 2014[20]	17–50	27.4	M, F	I, II, III, IV
Verhaeghe et al., 2012[21]	53–66	64	M, F	I, II, III, IV
Tierney et al., 2009[22]	NS	NS	M, F	NS
Yun et al., 2010[23]	20–72	48.6	M, F	IV, V
Choe et al., 2009[24]	21–64	46.9	M, F	IV, V
Longaker et al., 2014[25]	24–65	42.6	F predominant	I, II, III, IV, V
Lim et al., 2014[26]	29–51	38.6	M, F	NS

M, male; F, female; NS, not specified.

erbium-glass laser versus no treatment.[24] Erbium-glass laser–treated scars scored better in vascularity, pigmentation, pliability, and height (Vancouver Scar Assessment Scale score, 1.52 versus 3.00; $p = 0.03$) by blinded dermatologists. No adverse events (i.e., herpes labialis or postinflammatory hyperpigmentation) were noted. Lee et al. reported improved scar appearance after potassium titanyl phosphate laser versus no treatment (Vancouver Scar Assessment Scale score, 2.2 versus 5.75; $p < 0.001$), improved global assessment scores (3.1 versus 1.8; $p < 0.01$), and higher cosmetic patient satisfaction scores (3.1 versus 1.6; $p < 0.001$).[23] Blistering was reported in one patient, who opted to continue treatment.

Data Summarized

- Nonablative fractional laser improves texture and pliability of incisions and full-thickness grafts on the face and neck when compared to no treatment, albeit with a considerable short-term side-effect profile.
- Nonablative fractional laser improves scar pigmentary variation, hypopigmentation, thickness, and texture to a greater extent when compared head-to-head against pulsed dye laser therapy, although skin type of most benefit was not specified.

Copyright © 2017 American Society of Plastic Surgeons. Unauthorized reproduction of this article is prohibited.

- Combined pulsed dye laser/neodymium:yttrium-aluminum-garnet laser therapy starting on the day of suture removal is safe and effective in improving the quality and cosmetic appearance of surgical scars in patients with skin types I through IV with an apparently safe side-effect profile.
- Both 532-nm potassium-titanyl-phosphate laser and 1550-nm erbium laser are effective in improving scar appearance in high-risk ethnic groups (Fitzpatrick skin type ≥IV).

Compressive Therapy

Two randomized controlled trials investigated the potential benefit of the Embrace device (a silicone elastomeric dressing) in postoperative scar management.[25,26] Longaker et al. reported a statistically significant improvement in pigmentation ($p < 0.001$), pliability ($p < 0.001$), relief/roughness ($p = 0.006$), and vascularity ($p = 0.004$) according to the Observer Scar Assessment Scale on Embrace-treated abdominoplasty scars at 12-month follow-up.[25] Enrolled subjects rated Embrace-treated scars as significantly better than their nontreated side [e.g., irregularity ($p = 0.03$), thickness ($p = 0.01$), stiffness ($p = 0.002$), and overall aesthetic appearance ($p = 0.02$) according to the Patient Scar Assessment Scale). Photographs were reviewed by blinded board-certified plastic surgeons, and Vancouver Scar Assessment Scale scores were significantly improved for treated (2.9) compared with control scars (3.29; $p = 0.02$). No preferential benefit was noted by age, race, body mass index, or Fitzpatrick skin type after multivariate analysis.

Lim et al. also studied the prophylactic role of mechanomodulation and reported significantly improved Vancouver Scar Assessment Scale scores on treated scars (3.78) compared with controls (5.58; $p < 0.05$) when assessing vascularity, thickness, pliability, and pigmentation.[26] On patient satisfaction surveys, 100 percent were satisfied/very satisfied with overall improved scar cosmesis; 90 percent would recommend treatment to others; and 90 percent would want the Embrace (Gurtner and Longaker developed the Embrace device) device to optimize scarring if they underwent another procedure in the future.

Data Summarized

- Mechanomodulation therapy with the Embrace device compared to standard or no postoperative dressing improves scar vascularity, thickness, pliability, and pigmentation, with high patient satisfaction rates.

Table 4. Summary of Study Characteristics

Reference	Time of Therapy Initiation	Modality Compatible with Makeup?	Study Design (Level of Evidence)	Study Period
de Giorgi et al., 2009[15]	At suture removal	Yes	Single-blind (observer), prospective, randomized, controlled (I)	May–July of 2005
Jina et al., 2015[16]	7 days postoperatively	Yes	Single-blind, randomized, controlled (I)	NS
Maher et al., 2012[17]	<1 yr postoperatively	No	Prospective, randomized, controlled (IIb)	NS
Scuderi et al., 2011[18]	At suture removal	Yes	Prospective, randomized, controlled (I)	April of 2007–May of 2009
Signorini and Clementoni, 2007[19]	10 days–3 wk postoperatively	Yes	Prospective, randomized, controlled (IIb)	September of 2003–September of 2004
Vas et al., 2014[20]	At suture removal	NS	Prospective, randomized, controlled (I)	NS
Verhaeghe et al., 2012[21]	3–13 mo	Ns	Prospective, randomized, controlled (I)	January of 2010–January of 2011
Tierney et al., 2009[22]	Within 2 mo of Mohs	NS	Prospective, double-blind, randomized, controlled (IIb)	NS
Yun et al., 2010[23]	2–3 wk	Yes	Prospective, randomized, controlled (IIb)	September of 2008–February of 2009
Choe et al., 2009[24]	2–3 wk	Yes	Prospective single-blind (observer), randomized, controlled (IIb)	June of 2007–March of 2008
Longaker et al., 2014[25]	4–8 days	No	Prospective, single-blind, randomized, clinical trial, controlled (I)	June of 2011–May of 2012
Lim et al., 2014[26]	1–4 days	No	Prospective, open-label, randomized, controlled (IIb)	September of 2011–May of 2012

Copyright © 2017 American Society of Plastic Surgeons. Unauthorized reproduction of this article is prohibited.

Table 5. Summary of Study Characteristics

Reference	Scar Type	Location of Control	Total Follow-Up Time (mo)	Outcome Measure/ Scar Assessment Tool	Adverse Effects
de Giorgi et al., 2009[15]	Linear surgical	Different scar (?) on same patient	8	Resultant scar type (pathologic vs. nonpathologic), wound healing symptoms	None
Jina et al., 2015[16]	Sternotomy	Second half of sternotomy incision	6	MSS score, POSAS	None
Maher et al., 2012[17]	Linear	Second half of surgical incision	6	POSAS, VAS	Minor skin irritation (20%)
Scuderi et al., 2011[18]	After breast augmentation, BBR	Contralateral breast	12	VAS (clinician and patient); scar elevation, scar width by means of profilometry	Local intolerance (1.1%)
Signorini and Clementoni, 2007[19]	Linear, surgical (lesion excision)	Control with anatomically matched lesion	6	1–4 graded scar categories graded by clinicians (grade 1 normal, 2+ hyperemic vs. keloid)	None
Vas et al., 2014[20]	Linear, surgical (nevus removal)	Second half of surgical incision	7	VSS	None reported
Verhaeghe et al., 2012[21]	Mohs primary closure, STSG, FTSG	Second half of surgical incision	3	PhGA, PGA, POSAS, skin reflectance measurements	Erythema (67%), edema (31%), crusting (22%), burning (14%), purpura (9%), vesicles (4%), none long-term
Tierney et al., 2009[22]	Mohs primary closure	Second half of surgical incision	3	Institutionally created 5-point grading scale (pigmentation, thickness, texture, overall cosmesis)	PDL: transient erythema, purpura; NAFL: mild to moderate pain, erythema, edema. No dyspigmentation, blisters, or ulcers
Yun et al., 2010[23]	Linear surgical (thyroidectomy)	Fitzpatrick-matched controls	6	VSS	blisters ($n = 1$), opted to continue therapy with no further events
Choe et al., 2009[24]	Linear surgical (thyroidectomy)	Fitzpatrick-matched controls	6	VSS	None
Longaker et al., 2014[25]	Linear, surgical (abdominoplasty)	Second half of surgical incision	12	VAS, POSAS	Local skin irritation. Otherwise, none
Lim et al., 2014[26]	Linear, surgical (various)	Second half of surgical incision	6	VAS	None

MSS, Manchester Scar Scale; POSAS, Patient and Observer Scar Assessment Scale; VAS, Vancouver Scar Assessment Scale; BBR, bilateral breast reduction ; STSG, split-thickness skin graft; FTSG, full-thickness skin graft; PhGA, Physician Global Assessment Scales; PGA, Patient Global Assessment; PDL, pulsed dye laser; NAFL, nonablative fractional laser.

DISCUSSION

There Is Insufficient Evidence for Routine Silicone Sheeting in Patients with Normal Wound Healing

Although there is a wide array of research focusing on silicone sheets to treat hypertrophic scarring, the utility of silicone sheeting in patients with apparently normal wound healing is mixed.[28–32] Contemporary data contained herein corroborate these mixed results.[17] That is, observer scales demonstrated some benefit in scar softness and pigmentation, but patients themselves saw little aesthetic improvement. The mechanistic benefit of silicone products is occlusion, which is hypothesized to normalize keratinocyte hydration and regulate extracellular matrix production.[33] A potential confounder of consistent clinical results in the studies presented may be poor patient adherence to regular wear, potentially influenced by the need for prolonged wear, continued maintenance, or obtrusive appearance of sheeting.[34,35] Furthermore, several well-marketed silicone sheets cater to lighter skin tones, and thus appear unnatural and unattractive on darker skin. As our assessment of the current data stands, silicone sheets may have a place among the techniques used to address pathologic scarring, but its routine, blanketed use in scar prophylaxis may be overzealous and costly.

Copyright © 2017 American Society of Plastic Surgeons. Unauthorized reproduction of this article is prohibited.

There Is Evidence for Preventative Use of Silicone Gel in Mixed Cohorts

The ideal first-line therapy for scar prophylaxis should be effective, inconspicuous, and easily applicable by patients themselves. As such, silicone gel is an appealing option, and the presented data confirm that its use is compatible with other topical agents such as sunscreen, which have proven aesthetic benefits in postsurgical scar care to reduce hyperpigmentation.[15,36–39] Although the clinical trials included did not stratify by Fitzpatrick skin type,[15,18,19] the ubiquitous benefit obtained with regard to scar relief and vascularity suggests that silicone gel has universal appeal and should be considered in patients of all skin types regardless of whether or not they have a history of pathologic scarring.

There Is Evidence for Use of Cyanoacrylates for Extended Postoperative Scar Management in Cosmetic Cohorts

Cyanoacrylates are commonly used in lieu of Steri-Strips or occlusive dressings on breast and abdominal incisions. Many surgeons consider this agent merely a convenient, temporary means to dress their surgical wounds. However, the clinical trial data presented assert an aesthetic benefit with prolonged application to decrease scar widening.[18] Mechanisms to account for this benefit may include resistance to traction and occlusion and antimicrobial properties.[40–43] We propose that routine prolonged application of cyanoacrylates be considered in high-tension trunk or extremity wounds, with regular application every 2 to 3 days for up to 2 to 3 weeks, which has been shown to be well-tolerated in patients undergoing aesthetic procedures.[18] Caution should be taken with repeated application of cyanoacrylates above the clavicle, as the polymerized product is poorly compatible with makeup and thus gives a "caked-on" appearance in cosmetically sensitive areas.

There Is Insufficient Evidence for the Routine Use of Keratin Gel in Cosmetic Patients

The only clinical trial level evidence for use of keratin gel is in median sternotomy cohorts undergoing cardiothoracic surgery.[16] Although a plastic surgeon may be involved in sternal wound coverage in complicated cases such as sternal wound breakdown or osteomyelitis, the reconstructive priorities in these cases would be stable closure and eradication of infection; thus, cosmetic scar appearance becomes a secondary or tertiary goal at best. Also, one should consider that keratin gel is much less widely available in over-the-counter formulation than silicone gel, making silicone gel an arguably more preferred option. Until further clinical trial level evidence to support routine use of keratin gel in cosmetic cohorts is available, it should be considered a safe second-line alternative if silicone gel is either poorly tolerated or unavailable. Of note, the evidence for prophylactic topical antioxidants (i.e., vitamin E) to improve the cosmetic outcome of surgical scars is weak; its use should be discouraged.[44–46]

There Are No Clinical Trials to Support Routine Use of Steri-Strips in Addition to Suture Closure to Improve Cosmetic Appearance of Scars

Although there are few clinical trials that have studied Steri-Strip closure devices versus subcuticular closure,[47,48] no clinical trial data exist to demonstrate an added cosmetic benefit of using Steri-Strips as a wound dressing in addition to suture closure.

There Is Evidence for Preventative Laser Therapy in Patients with High-Risk Fitzpatrick Skin Types

Patients with a Fitzpatrick skin type greater than or equal to 4 are at higher than average risk for pathologic scarring considering the genetic predisposition for keloid and hypertrophic scarring in darker skinned ethnic groups.[49,50] However, many surgeons are reluctant to use laser in ethnic patients, given the risk of postinflammatory hyperpigmentation, which may worsen cosmetic outcome of scars.[51–53] Few clinical trials have specifically addressed these high-risk groups and explored the potential aesthetic benefits of prophylactic laser therapy. The trials presented herein demonstrate with the highest level of evidence available that prophylactic laser therapy is not only cosmetically beneficial for head and neck scarring, but also safe (at least in Korean subjects).[23,24] Further studies are needed to assess whether high-level cosmetic results and a low risk of postinflammatory hyperpigmentation can be recapitulated in other ethnic cohorts (e.g., Hispanics, African Americans).

There Is Limited Evidence That Nonablative Fractional Laser Is Superior for Scar Prophylaxis Compared with Pulsed Dye Laser, Although Several Laser Types Are Effective

Prior work has shown that pulsed dye laser, a commonly used nonablative laser, improves the appearance of raised postsurgical scars. However,

Copyright © 2017 American Society of Plastic Surgeons. Unauthorized reproduction of this article is prohibited.

recent data included in this review suggest that fractional laser resurfacing outperforms pulsed dye laser, particularly in repigmenting hypopigmented scars.[22] These results are not altogether surprising considering that fractional lasers have greater penetration depth and induce focal microthermal zones of injury in papillary and reticular dermis to stimulate collagen remodeling.[54–56] It is also hypothesized that nonablative fractional laser repigments hypopigmented scars by stimulating the migration of normal melanocytes into resurfaced tissues.[57] Overall, there are numerous laser types that have demonstrated efficacy at improving scar dyspigmentation, thickness, texture,[58] and overall cosmetic appearance and should be strongly considered by any plastic surgeon for scar prophylaxis, particularly on high-profile areas such as the neck and face.

There Is Strong Evidence for Use of Mechanomodulatory Therapy on High-Tension Wounds

In the largest, multi-institutional clinical trial contained in this systematic review, the Embrace

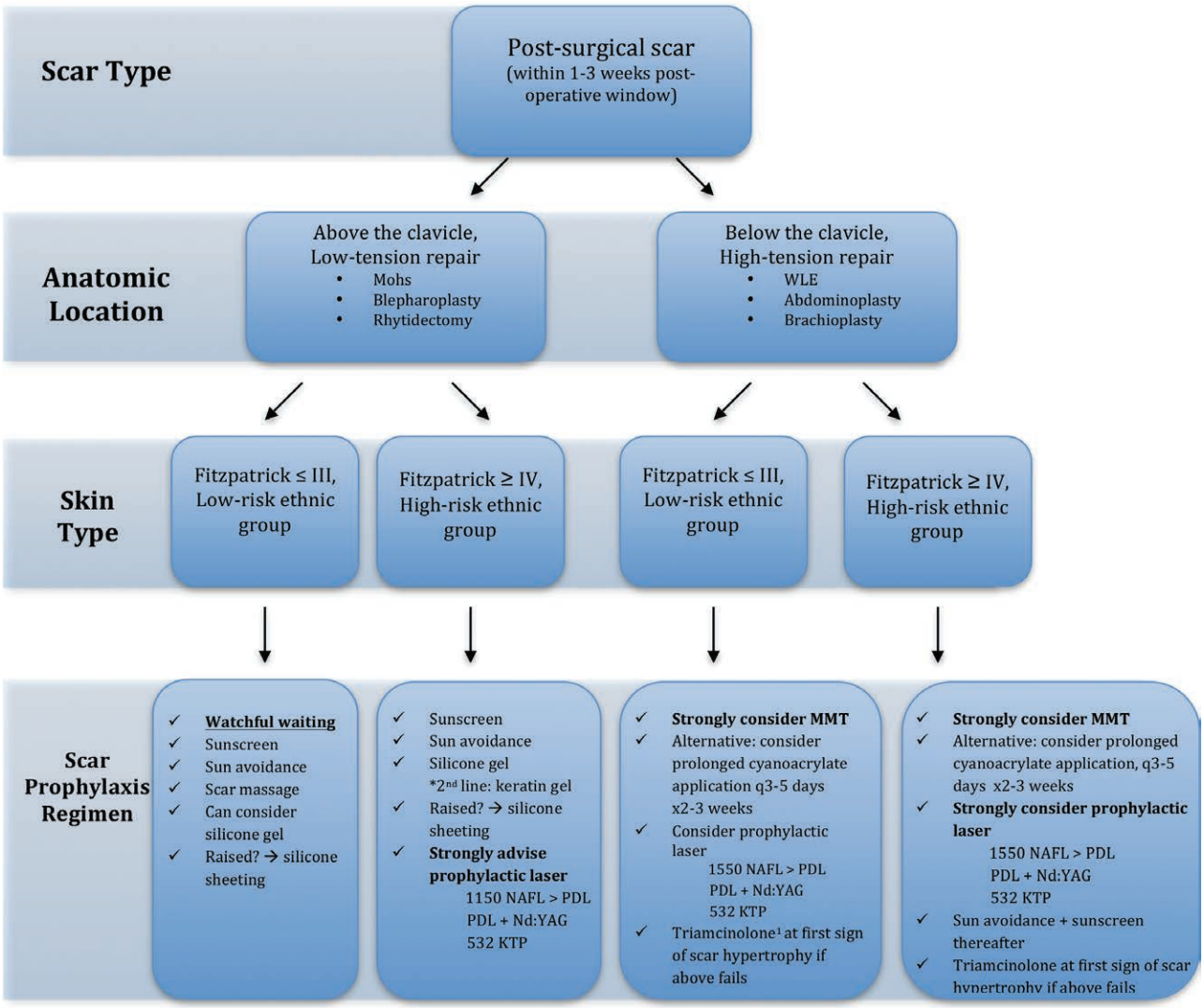

Fig. 4. A preventative postsurgical scar management algorithm. Recommended injection regimen is as follows: triamcinolone acetonide 10 mg/ml with equal parts of 1% lidocaine with epinephrine 1:100,000 at a dose of 1 ml/cm^3 of the lesion. It is imperative that these injections are made only within the lesion and not into adjacent normal tissue to minimize atrophy. Injections occur at 6-week intervals. In our hands, scar atrophy and scar widening risk may be lessened by limiting the dose of triamcinolone to 40 mg per session and by limiting the number of serial injections to three maximum. *WLE*, wide local excision; *NAFL*, nonablative fractional laser; *PDL*, pulsed dye laser; *Nd:YAG*, neodymium:yttrium-aluminum-garnet; *KTP*, potassium-titanyl-phosphate; *MMT*, mechanomodulatory therapy.

Copyright © 2017 American Society of Plastic Surgeons. Unauthorized reproduction of this article is prohibited.

device was shown to improve aesthetic scar quality after abdominoplasty at 1 year.[25] The design of the device aims to offload tension, one of the most significant contributors to unattractive scar widening or hypertrophy.[25,26] Given that abdominoplasty closures are arguably the highest tension closures cosmetic surgeons face, the Embrace device is therefore well-suited for scar prophylaxis on trunk and extremity incisions and should be highly considered in these cases. Furthermore, the device is widely available and well tolerated by wearers.

An Algorithmic Approach

Optimal scar care requires carefully approaching each patient individually, taking into account factors such as incisional tension, anatomical location, and Fitzpatrick skin type. A one-size-fits-all approach to postoperative incision care may be costly; yield suboptimal results; and predispose to scar widening, hypertrophy, or atrophy. We propose a streamlined algorithm to guide surgeons toward evidence-based modalities for scar minimization (Fig. 4).

Study Limitations

The main limitation of this study is a scarcity of randomized, controlled, clinical trials with regard to preventative scar therapy. Although there is a large volume of observational, case series, and case report data addressing postoperative scar optimization, the quality of clinical trials available for review is limited by short follow-up (<1 year), small cohorts, and heterogeneous patient populations (e.g., acne cohorts plus burn cohorts with no distinction between the two). Importantly, all studies included in this study were published within the past 10 years, thus emphasizing the need to stay current in scar care. This review valued quality over quantity, with the goal of isolating the highest level of contemporary evidence with the strictest of inclusion and exclusion criteria of any scar care systematic review performed within the past 10 years. Still, more high-quality randomized controlled trials in scar prophylaxis are needed to further substantiate our claims.

CONCLUSIONS

The synthesized results of this narrative systematic review strongly support with level I and II evidence the use of topical therapies for aesthetic optimization of postoperative scar appearance, whether silicone gel, silicone sheet, or mechanomodulatory dressings with good patient tolerability and safe side-effect profiles. Our proposed scar management algorithm provides plastic surgeons with an evidence-based approach to scar care rooted in data rather than sweeping subjective opinion.

Rod J. Rohrich, M.D.
9101 N Central Expressway, Suite 600
Dallas, Texas 75231
rod.rohrich@dpsi.org
@DrRodRohrich

REFERENCES

1. Bayat A, McGrouther DA, Ferguson MW. Skin scarring. *BMJ* 2003;326:88–92.
2. Sobanko JF, Sarwer DB, Zvargulis Z, Miller CJ. Importance of physical appearance in patients with skin cancer. *Dermatol Surg.* 2015;41:183–188.
3. Sarwer DC, Crerand CE. Psychological issues in patient outcomes. *Facial Plast Surg.* 2002;18:125–134.
4. Mustoe TA, Cooter RD, Gold MH, et al.; International Advisory Panel on Scar Management. International clinical recommendations on scar management. *Plast Reconstr Surg.* 2002;110:560–571.
5. Block L, Gosain A, King TW. Emerging therapies for scar prevention. *Adv Wound Care (New Rochelle)* 2015;4:607–614.
6. Visscher MO, Bailey JK, Hom DB. Scar treatment variations by skin type. *Facial Plast Surg Clin North Am.* 2014;22:453–462.
7. Narurkar VA. Nonablative fractional laser resurfacing. *Dermatol Clin.* 2009;27:473–478, vi.
8. Chen M, Davidson T. Scar management: Prevention and treatment strategies. *Curr Opin Otolaryngol Head Neck Surg.* 2005;13:242–247.
9. Poetschke J, Schwaiger H, Gauglitz G. Current and emerging options for documenting scars and evaluating therapeutic progress. *Dermatol Surg.* 2017:43(Suppl 1):S25–S36.
10. Brusselaers N, Pirayesh A, Hoeksema H, et al. Burn scar assessment: A systematic review of different scar scales. *J Surg Res.* 2010;164:e115–e123.
11. Brusselaers N, Pirayesh A, Hoeksema H, Verbelen J, Blot S, Monstrey S. Burn scar assessment: A systematic review of different scar scales. *J Surg Res.* 2010;164:e115–e123.
12. Draaijers LJ, Tempelman FR, Botman YA, et al. The patient and observer scar assessment scale: A reliable and feasible tool for scar evaluation. *Plast Reconstr Surg.* 2004;113:1960–1965; discussion 1966–1967.
13. van der Wal MB, Verhaegen PD, Middelkoop E, van Zuijlen PP. A clinimetric overview of scar assessment scales. *J Burn Care Res.* 2012;33:e79–e87.
14. Vercelli S, Ferriero G, Sartorio F, Cisari C, Bravini E. Clinimetric properties and clinical utility in rehabilitation of postsurgical scar rating scales: A systematic review. *Int J Rehabil Res.* 2015;38:279–286.
15. de Giorgi V, Sestini S, Mannone F, et al. The use of silicone gel in the treatment of fresh surgical scars: A randomized study. *Clin Exp Dermatol.* 2009;34:688–693.
16. Jina NH, Marsh C, Than M, Singh H, Cassidy S, Simcock J. Keratin gel improves poor scarring following median sternotomy. *ANZ J Surg.* 2015;85:378–380.
17. Maher SF, Dorko L, Saliga S. Linear scar reduction using silicone gel sheets in individuals with normal healing. *J Wound Care* 2012;21:602, 604–606, 608.
18. Scuderi N, Dessy LA, Buccheri EM, et al. Phase 2 cross-over multicenter trial on the efficacy and safety of topical cyanoacrylates compared with topical silicone gel in the prevention of pathologic scars. *Aesthetic Plast Surg.* 2011;35:373–381.

Copyright © 2017 American Society of Plastic Surgeons. Unauthorized reproduction of this article is prohibited.

19. Signorini M, Clementoni MT. Clinical evaluation of a new self-drying silicone gel in the treatment of scars: A preliminary report. *Aesthetic Plast Surg.* 2007;31:183–187.
20. Vas K, Gaál M, Varga E, et al. Effects of the combined PDL/Nd:YAG laser on surgical scars: Vascularity and collagen changes evaluated by in vivo confocal microscopy. *Biomed Res Int.* 2014;2014:204532.
21. Verhaeghe E, Ongenae K, Dierckxsens L, Bostoen J, Lambert J. Nonablative fractional laser resurfacing for the treatment of scars and grafts after Mohs micrographic surgery: A randomized controlled trial. *J Eur Acad Dermatol Venereol.* 2013;27:997–1002.
22. Tierney E, Mahmoud BH, Srivastava D, Ozog D, Kouba DJ. Treatment of surgical scars with nonablative fractional laser versus pulsed dye laser: A randomized controlled trial. *Dermatol Surg.* 2009;35:1172–1180.
23. Yun JS, Choi YJ, Kim WS, Lee GY. Prevention of thyroidectomy scars in Asian adults using a 532-nm potassium titanyl phosphate laser. *Dermatol Surg.* 2011;37:1747–1753.
24. Choe JH, Park YL, Kim BJ, et al. Prevention of thyroidectomy scar using a new 1,550-nm fractional erbium-glass laser. *Dermatol Surg.* 2009;35:1199–1205.
25. Longaker MT, Rohrich RJ, Greenberg L, et al. A randomized controlled trial of the embrace advanced scar therapy device to reduce incisional scar formation. *Plast Reconstr Surg.* 2014;134:536–546.
26. Lim AF, Weintraub J, Kaplan EN, et al. The embrace device significantly decreases scarring following scar revision surgery in a randomized controlled trial. *Plast Reconstr Surg.* 2014;133:398–405.
27. Fearmonti R, Bond J, Erdmann D, Levinson H. A review of scar scales and scar measuring devices. *Eplasty* 2010;10:e43.
28. O'Brien L, Jones D. Silicone gel sheeting for preventing and treating hypertrophic and keloid scars. *Cochrane Database Syst Rev.* 2013;9:CD003826.
29. Li-Tsang CW, Zheng YP, Lau JC. A randomized clinical trial to study the effect of silicone gel dressing and pressure therapy on posttraumatic hypertrophic scars. *J Burn Care Res.* 2010;31:448–457.
30. Tandara A, Mustoe T. The role of the epidermis in the control of scarring: Evidence for mechanism of action for silicone gel. *J Plast Reconstr Aesthet Surg.* 2008;61:1219–1225.
31. Gold MH, Foster TD, Adair MA, Burlison K, Lewis T. Prevention of hypertrophic scars and keloids by the prophylactic use of topical silicone gel sheets following a surgical procedure in an office setting. *Dermatol Surg.* 2001;27:641–644.
32. Berman B, Perez OA, Konda S, et al. A review of the biologic effects, clinical efficacy, and safety of silicone elastomer sheeting for hypertrophic and keloid scar treatment and management. *Dermatol Surg.* 2007;33:1291–1302; discussion 1302–1303.
33. Mustoe TA. Evolution of silicone therapy and mechanism of action in scar management. *Aesthetic Plast Surg.* 2008;32:82–92.
34. Nikkonen MM, Pitkanen JM, Al-Qattan MM. Problems associated with the use of silicone gel sheeting for hypertrophic scars in the hot climate of Saudi Arabia. *Burns* 2001;27:498–501.
35. Puri N, Talwar A. The efficacy of silicone gel for the treatment of hypertrophic scars and keloids. *J Cutane Aesthet Surg.* 2009;2:104–106.
36. Mancebo SE, Hu JY, Wang SQ. Sunscreens: A review of health benefits, regulations, and controversies. *Dermatol Clin.* 2014;32:427–438, x.
37. Clark A, Hessler J. Skin care. *Facial Plast Surg Clin North Am.* 2015;23:285–295.
38. Cohen L, Grant R. Sun protection: Current management strategies addressing UV exposure. *Clin Plast Surg.* 2016;43:605–610.
39. Scarfade. How to use topical silicone scar treatment gels. 2012. Available at: http://www.scarfade.com/blog/how-to-use-topical-silicone-scar-treatment-gels/. Accessed September 1, 2016.
40. Narang U, Mainwaring L, Spath G, Barefoot J. In-vitro analysis for microbial barrier properties of 2-octyl cyanoacrylate-derived wound treatment films. *J Cutan Med Surg.* 2003;7:13–19.
41. Mertz PM, Davis SC, Cazzaniga AL, Drosou A, Eaglstein WH. Barrier and antibacterial properties of 2-octyl cyanoacrylate-derived wound treatment films. *J Cutan Med Surg.* 2003;7:1–6.
42. Souza E, Fitaroni R, Januzelli D, Macruz H, Camacho J, Souza M. Use of 2-octyl cyanoacrylate for skin closure of sternal incisions in cardiac surgery: Observations of microbial barrier effects. *Curr Med Res Opin.* 2007;24:151–155.
43. Bhende S, Rothenburger S, Spangler DJ, Dito M. In vitro assessment of microbial barrier properties of Dermabond topical skin adhesive. *Surg Infect (Larchmt.)* 2002;3:251–257.
44. Baumann LS, Spencer J. The effects of topical vitamin E on the cosmetic appearance of scars. *Dermatol Surg.* 1999;25:311–315.
45. Jenkins M, Alexander JW, MacMillan BG, Waymack JP, Kopcha R. Failure of topical steroids and vitamin E to reduce postoperative scar formation following reconstructive surgery. *J Burn Care Rehabil.* 1986;7:309–312.
46. Curran JN, Crealey M, Sadadcharam G, Fitzpatrick G, O'Donnell M. Vitamin E: Patterns of understanding, use, and prescription by health professionals and students at a university teaching hospital. *Plast Reconstr Surg.* 2006;118:248–252.
47. Kerrigan C, Homa K. Evaluation of a new wound closure device for linear surgical incisions: 3M Steri-Strip S surgical skin closure versus subcuticular closure. *Plast Reconstr Surg.* 2010;125:186–194.
48. Lazar HL, McCann J, Fitzgerald CA, Cabral HJ. Adhesive strips versus subcuticular suture for median sternotomy wound closure. *J Card Surg.* 2011;26:344–347.
49. Wolfram D, Tzankov A, Pülzl P, Piza-Katzer H. Hypertrophic scars and keloids: A review of their pathophysiology, risk factors, and therapeutic management. *Dermatol Surg.* 2009;35:171–181.
50. Robles D, Berg D. Abnormal wound healing: Keloids. *Clin Dermatol.* 2007;25:26–32.
51. Been MG, Mangat DS. Laser and face peel procedures in non-Caucasians. *Facial Plast Surg Clin North Am.* 2014;22:447–452.
52. Alexis A. Lasers and light-based therapies in ethnic skin: Treatment options and recommendations for Fitzpatrick skin types V and VI. *Br J Dermatol.* 2013;169:91–97.
53. Chan HH. Special considerations for darker-skinned patients. *Curr Probl Dermatol.* 2011;42:153–159.
54. Wanner M, Tanzi EL, Alster TS. Fractional photothermolysis: Treatment of facial and nonfacial cutaneous photodamage with a 1,550-nm erbium-doped fiber laser. *Dermatol Surg.* 2007;33:23–28.
55. Behroozan DS, Goldberg LH, Dai T, Geronemus RG, Friedman PM. Fractional photothermolysis for the treatment of surgical scars: A case report. *J Cosmet Laser Ther.* 2006;8:35–38.
56. Graber E, Tanzi E, Alster T. Side effects and complications of fractional laser photothermolysis. *Dermatol Surg.* 2008;34:301–307.
57. Glaich AS, Rahman Z, Goldberg LH, Friedman PM. Fractional resurfacing for the treatment of hypopigmented scars: A pilot study. *Dermatol Surg.* 2007;33:289–294; discussion 293–294.
58. Preissig J, Hamilton K, Markus R. Current laser resurfacing technologies: A review that delves beneath the surface. *Semin Plast Surg.* 2012;26:109–116.

Copyright © 2017 American Society of Plastic Surgeons. Unauthorized reproduction of this article is prohibited.