Detection of High-Risk Histologic Features and Tumor Upstaging of Nonmelanoma Skin Cancers on Debulk Analysis: A Quantitative Systematic Review

Babu Singh, MD,* Adriana Dorelles, ScD, MS,† Nellie Konnikov, MD,‡ and Bichchau M. Nguyen, MD, MPH‡§

BACKGROUND Histologic analysis of tumor debulks from Mohs micrographic surgery (MMS) or wide local excision may lead to the detection of adverse features missed on initial biopsy.

OBJECTIVE Determine the incidence of (1) high-risk features on debulk analysis compared with initial biopsy and (2) upstaging of tumors on debulk analysis according to the American Joint Committee of Cancer-7th Edition (AJCC-7) and the Brigham and Women's Alternative (BWH) staging criteria.

MATERIALS AND METHODS A comprehensive search strategy using PubMed/MEDLINE, Web of Science, and EMBASE was conducted to identify articles published from 1960 to present that detail histology of initial biopsy and debulked tumor.

RESULTS Fourteen studies, encompassing 2,565 cases of basal cell carcinoma (BCC) and squamous cell carcinoma (SCC) were included in the data extraction process. BCCs (30.9%) were reclassified from a low-risk histologic subtype to a high-risk subtype on debulk analysis ($p < .001$). Cases with perineural invasion (89.4%) were detected on debulk analysis. SCC tumors (9.1% and 11.1%) were upstaged according to the AJCC-7 and BWH Alternative criteria, respectively. Ninety percent of high-risk BWH T2b SCCs were inaccurately staged lower on initial biopsy.

CONCLUSION Tumor debulk analysis in MMS may aid in the identification of additional high-risk features, thereby improving staging accuracy, treatment decisions and patient outcomes.

The authors have indicated no significant interest with commercial supporters.

Adverse histologic features (i.e., aggressive histologic subtype, invasion into fat or muscle, perineural invasion [PNI], lymphovascular invasion [LVI]) directly affect staging, treatment, and outcomes for patients with nonmelanoma skin cancers (NMSCs). Under the current American Joint Committee of Cancer-7th edition (AJCC-7) staging system for basal cell carcinoma (BCC) and squamous cell carcinoma (SCC), aggressive histologic subtype, invasion to fat or deeper, and PNI can upstage a tumor from T1 to T2.[1] Tumors with adverse features may require aggressive surgical treatment including Mohs micrographic surgery (MMS) and potentially, imaging studies and adjuvant radiation, to reduce risk.[2,3] Even with appropriate treatment, tumors with one or more adverse histologic features have an increased risk of local recurrence, metastasis and disease-specific death.[4]

Initial biopsy of a NMSC may fail to identify all adverse histologic features because of sampling error. Multiple studies have reported detection of aggressive histologic subtype and PNI in specimens from wide local excision (WLE) and MMS tumor debulk.[5–18] Clinical management based solely on findings from biopsy may lead to the under treatment of high-risk tumors and subsequent poor outcomes.

Department of Dermatology, Boston University Medical Center, Boston, Massachusetts; †Department of Economics, Arizona State University, Tempe, Arizona; ‡Department of Dermatology, VA Boston Healthcare System, Jamaica Plains Campus, Boston, Massachusetts; §Department of Dermatology, Tufts Medical Center, Boston, Massachusetts

© 2017 by the American Society for Dermatologic Surgery, Inc. Published by Wolters Kluwer Health, Inc. All rights reserved.
ISSN: 1076-0512 • Dermatol Surg 2017;0:1–9 • DOI: 10.1097/DSS.0000000000001146

© 2017 by the American Society for Dermatologic Surgery, Inc. Published by Wolters Kluwer Health, Inc. Unauthorized reproduction of this article is prohibited.

With WLE, the residual tumor and marginal tissue are examined en-bloc, allowing for the detection of additional adverse features in the residual tumor. However, with MMS, the central tumor is often discarded or curetted to define the clinical border before clearance of margins. Therefore, only the marginal surface is examined with MMS. Thus, there is a theoretical risk of under-staging because of incomplete histologic evaluation of the central tumor.

Methods

Search Strategy

A comprehensive search of PubMed/MEDLINE, Web of Science, and EMBASE with terms for SCC, BCC, MMS, WLE, biopsy, and all available synonyms was performed to identify all relevant studies in the English language published from 1960 to date.

Study and Case Inclusion Criteria

Select articles, including their references, were assessed in full for inclusion in the quantitative analysis. Articles that provided histologic data on both initial biopsy and subsequent tumor debulk from WLE or MMS of BCC, SCC in situ, and SCC tumors were included. Studies with less than 2 cases of NMSCs were excluded.

Case Inclusion Criteria

Case were included only when both histologic features of the initial biopsy and debulk specimen were available, even those with actinic keratosis or no residual tumor on the debulk analysis. Cases were excluded when incidental nonkeratinocytic tumors, for example, Dermatofibrosarcoma Protuberans or Microcystic Adnexal Carcinoma, were identified or those that were designated as "miscellaneous."

Data Extraction

Extracted variables from the selected studies included lead author, year published, study design, number of cases, consecutive nature of cases (i.e., if consecutive referrals for MMS surgery were included, or if cases were at random), definitive treatment modality (MMS or WLE) and major findings. Tumor characteristics extracted included tumor type, location, size (longest reported diameter), primary or recurrent histologic subtype of the initial biopsy and debulk specimen, presence of PNI or LVI, Clark level, and depth of invasion (in millimeters). If more than one subtype was reported, the more aggressive subtype was recorded. If a single patient had more than one NMSC, each tumor was included as a separate case in the quantitative analysis. The designation SCC or BCC not otherwise specified (NOS) indicates that a specific histologic subtype was not reported, but the authors of the article designated it as low-risk. Likewise, Aggressive BCC or SCC designation indicates that the tumor was not specified but of a high-risk histologic subtype.

Tumor Staging

Squamous cell carcinoma tumor (T) stage based on AJCC-7 and Brigham and Women's Alternative (BWH) Alternative staging criteria was determined using histologic features of the initial biopsy and debulked tumor. If the T stage on the debulk analysis was lower than that of the initial biopsy, then the T stage of the debulk specimen was designated the same as the initial biopsy. High-risk features according to the AJCC-7 include depth/invasion (>2-mm thickness, Clark level greater than or equal to IV, or PNI), anatomic location (ear or non–hair-bearing lip), and differentiation (poorly differentiated or undifferentiated).[1] AJCC T1 tumors are less than or equal to 2 cm in greatest dimension with less than 2 high-risk features and T2 tumors are greater than or equal to 2 cm or any size with greater than or equal to 2 high-risk features. Stage AJCC T3 and T4 tumors are those that invade bone or deeper structures. High-risk features according to the BWH Alternative system include tumor diameter greater than or equal to 2 cm, poorly differentiated histology, PNI greater than or equal to 0.1 mm, or tumor invasion beyond fat.[19] BWH stage T1, T2a, T2b, T3 have 0, 1, 2 to 3, or greater than or equal to 4 high-risk factors, respectively. Tumor invading bone automatically upgrades tumors to BWH stage T2.

Statistical Analysis

Summary statistics were presented as mean, interquartile range, or frequency count with percentage.

© 2017 by the American Society for Dermatologic Surgery, Inc. Published by Wolters Kluwer Health, Inc. Unauthorized reproduction of this article is prohibited.

Associations in histologic findings between initial biopsy and subsequent debulk specimen were accessed using Pearson chi-squared test or Fisher exact test. Fisher exact test was used to compute statistical significance differences between tumor stage of SSC on initial biopsy and tumor stage after debulk analysis. Results with p values < .05 were considered statistically significant. Statistical analysis was performed using STATA/IC (v.14, College Station, TX).

Results

Study Characteristics

Figure 1 outlines the systematic search and data extraction algorithm used. Initial search identified 2,953 articles of which 23 were selected for full-text examination including articles found in references. Fourteen were selected to be included in the data extraction process. Majority of the studies were retrospective with 51 to 523 cases per study (Table 1). Six (42.9%) studies analyzed debulk tumor from MMS and 8 (57.1%) from WLE.

Patient and Tumor Demographics

Table 2 summarizes patient and tumor characteristics. The mean reported age at diagnosis was 68.7 years (range, 32–91). Of total patients, 29.7% were women, 18.4% were men, with the remaining cases having no reported sex. Tumors were primary (94.9%) and 45.1% were located in the head and neck region. A total of 2,565 cases of BCC (2,079, 81%) and SCC (486, 19%) were collated. Although 73.7% had no reported size, 9.2% of the tumors had a diameter of greater than or equal to 2 cm.

Initial Biopsy Results

Initial diagnosis was made by punch biopsy in 52% of cases, shave biopsy in 12%, and an unspecified biopsy technique in 36% of cases. Majority of the BCC tumors were reported as nodular on initial biopsy (40.3%). Five hundred-nine (24.5%) cases of BCC were classified as high-risk (aggressive BCC NOS, basosquamous, infiltrative, micronodular, and morpheaform), and 1,570 (75.5%) were classified as low-risk (superficial, nodular, and NOS). Of 486 cases of SCC, 4 (0.8%) were classified as high-risk (poorly differentiated and aggressive SCC NOS) and 482 (99.2%) were classified as low-risk (in situ, well-differentiated, moderately differentiated, and NOS).

Correlation Between Initial Biopsy and Debulk Analysis

Table 3 reports the correlation between histologic findings on initial biopsy and subsequent debulk analysis. Of 2,079 cases of BCC, 643 (30.9%) were reclassified from a low-risk histologic subtype to high-risk subtype based on debulk analysis (p < .001). On

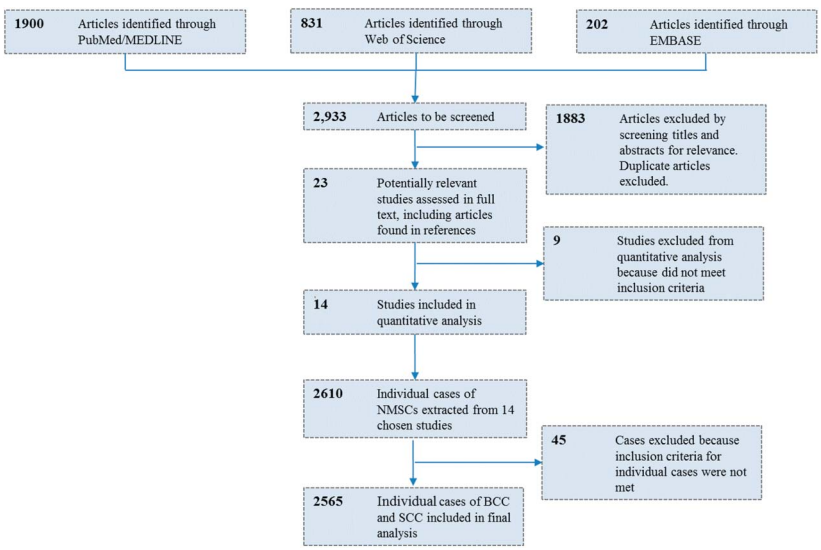

Figure 1. Systematic review and data extraction algorithm.

© 2017 by the American Society for Dermatologic Surgery, Inc. Published by Wolters Kluwer Health, Inc. Unauthorized reproduction of this article is prohibited.

TABLE 1. Summary of Studies

Study	Study Design	Number of Cases Included in Analysis/Total Number (Number Excluded)	Consecutive, Nonconsecutive Cases	NMSC	Primary, Recurrent	Biopsy Technique	MMS, WLE	Major Findings
Westers-Attema and colleagues[17]	Retrospective	105/105 (0)	Nonconsecutive	SCC	Primary	Punch	WLE	On punch biopsy, infiltration depth >4 mm is not identified in 83.3% (30/36), perineural invasion in 90.9% (10/11) and poor differentiation in 85.7% (6/7) of cases. TNM stage was underestimated on punch biopsy in 15.4% (16/104) of cases.
Knackstedt and colleagues[11]	Retrospective	48/51 (3)	Consecutive	SCCis	Primary	Shave, Punch	MMS	9.8% of cases of SCCis were found to harbor invasive SCC on Mohs debulk.
Wolberink and colleagues[18]	Retrospective	500/500 (0)	Consecutive	BCC	Primary	Punch	WLE	11% of cases, a more aggressive subtype was found on excision compared with initial biopsy.
Roozeboom and colleagues[14]	Retrospective	243/243 (0)	Consecutive	BCC	Primary	Punch	WLE	15.6% of initial punch biopsies did not predict an aggressive subtype found of excision.
Ebede and colleagues[7]	Retrospective	223/258 (35)	Nonconsecutive	BCC, SCC	Primary, Recurrent	Not reported	MMS	29% of cases changed from low or intermediate to high-risk histologic subtype on MMS paraffin sections compared with initial biopsy diagnosis.
Chuang and colleagues[5]	Prospective	29/29 (0)	Nonconsecutive	SCC	Primary	Shave, Punch	MMS	Up to 31% of biopsy-proven SCCis lesions may harbor invasive SCC.
Haws and colleagues[8]	Retrospective	232/232 (0)	Nonconsecutive	BCC	Primary	Shave, Punch	WLE	13% of cases were found to have an undetected aggressive histologic component on excision compared with initial biopsy.
Kamyab-Hesari and colleagues[10]	Retrospective	333/333 (0)	Nonconsecutive	BCC	Primary	Punch	WLE	14.1% of punch biopsies failed to detect aggressive subtypes of tumors.
Kwon and colleagues[12]	Prospective	28/28 (0)	Nonconsecutive	BCC, SCC	Not reported	Not reported	MMS	Complete sectioning through the tissue block of Mohs sections revealed no residual tumor in 93% of samples.
Mosterd and colleagues[13] 2011	Retrospective	73/73 (0)	Nonconsecutive	BCC	Recurrent	Punch	WLE	19% of excised BCCs with aggressive histologic subtypes were missed on initial biopsy.

© 2017 by the American Society for Dermatologic Surgery, Inc. Published by Wolters Kluwer Health, Inc. Unauthorized reproduction of this article is prohibited.

TABLE 1. (Continued)

Study	Study Design	Number of Cases Included in Analysis/Total Number (Number Excluded)	Consecutive, Nonconsecutive Cases	NMSC	Primary, Recurrent	Biopsy Technique	MMS, WLE	Major Findings
Welsch and colleagues[16]	Retrospective	100/100 (0)	Nonconsecutive	BCC	Primary	Not reported	WLE	Of lesions classified as superficial or nodular on the initial biopsy specimen, 26% were reclassified as micronodular or infiltrative type on review of excision specimens.
Izikson and colleagues[9]	Retrospective	516/523 (7)	Consecutive	BCC, SCC	Primary	Not reported	MMS	In 21.1% of cases, an aggressive subtype was identified that was not evidence on initial biopsy.
Cohen and colleagues[6]	Prospective	49/49 (0)	Consecutive	BCC	Primary, Recurrent	Not reported	MMS	BCC with mixed histology was observed in 43% of Mohs samples. Initial biopsy detected mixed histology in 10% of these samples.
Russell and colleagues[15]	Retrospective	86/86 (0)	Nonconsecutive	BCC	Primary	Shave, Punch	WLE	Shave biopsy misidentified infiltrating BCC in 50% of samples, whereas punch biopsy was incorrect in 21.4% of samples.

BCC, basal cell carcinoma; MMS, Mohs micrographic surgery; NMSC, nonmelanoma skin cancer; SCC, squamous cell carcinoma; SCCis, squamous cell carcinoma in situ; WLE, wide local excision.

© 2017 by the American Society for Dermatologic Surgery, Inc. Published by Wolters Kluwer Health, Inc. Unauthorized reproduction of this article is prohibited.

TABLE 2. Patient, Tumor, and Initial Biopsy Characteristics

Patient Characteristics	
Sex (N, %)	
Male	472 (18.4)
Female	762 (29.7)
Not reported	1,331 (51.9)
Age	
Mean	68.68
Range	32.2–90.8
Tumor characteristics	
Primary or recurrent	
Primary	2,433 (94.9)
Recurrent	104 (4.1)
Not reported	28 (1.0)
Location (N, %)	
Ears and lips	55 (2.1)
Head and neck	1,103 (43.0)
Trunk	348 (13.6)
Extremities	226 (8.8)
Not reported	833 (32.5)
Size (%), cm*	
Less than 2 cm	439 (17.1)
Greater than or equal to 2 cm	236 (9.2)
Not Reported	1,890 (73.7)
Initial biopsy characteristics	
Biopsy technique	
Shave	305 (11.9)
Punch	1,344 (52.4)
Not reported	916 (35.7)
Basal cell carcinoma (N)	2,079
Subtype (n, % of N)	
Superficial	315 (15.2)
Nodular	838 (40.3)
NOS	417 (20.0)
Aggressive BCC NOS	179 (8.6)
Basosquamous	2 (0.1)
Infiltrative	176 (8.5)
Micronodular	122 (5.9)
Morpheaform	30 (1.4)
High-risk subtype†	509 (24.5)
Low-risk subtype‡	1,570 (75.5)
Squamous cell carcinoma (N)	486
Subtype (n, % of N)	
In situ	143 (29.4)
Well-differentiated	17 (3.5)
Moderately differentiated	96 (19.8)
NOS	226 (46.5)
Poorly differentiated	2 (0.4)
Aggressive SCC NOS	2 (0.4)
High-risk subtype§	4 (0.8)
Low-risk subtype‖	482 (99.2)

*Longest reported dimension of initial lesion.

†BCCs that were considered high-risk include Aggressive BCC NOS, Basosquamous, infiltrative, micronodular and morpheaform.

‡BCCs that were considered low-risk include Superficial, Nodular and NOS.

§SCCs that were considered high-risk include Aggressive SCC NOS and poorly differentiated SCCs.

‖SCCs that were considered low-risk include in situ, well-differentiated, moderately differentiated and NOS.

BCC, basal cell carcinoma; NOS, not otherwise specified; SCC, squamous cell carcinoma.

debulk analysis, 22.4% of SCC in situ tumors were found to have an invasive SCC component. Eleven (2.3%) cases of invasive SCC were reclassified from low-risk to high-risk poorly differentiated subtype on

TABLE 3. Correlation in Histologic Findings Between Initial Biopsy and Subsequent Debulk Specimen

BCC Subtype (N, %)	N = 2,079
Low-risk to low-risk	927 (44.6)
Low-risk to high-risk	643 (30.9)
High-risk to high-risk	509 (24.5)
	$p < .001$*
SCC Subtype (N, %)	N = 486
In situ to invasive SCC	32/143 (22.4)
Low-risk to low-risk	471 (96.9)
Low-risk to high-risk	11 (2.3)
High-risk to high-risk	4 (0.8)
	$p < .001$†
Perineural Invasion (N,%)	N = 47‡
Biopsy specimen only	3 (6.4)
Biopsy specimen AND debulk specimen	2 (4.2)
Debulk specimen only	42 (89.4)
Lymphovascular invasion	N = 1§
Biopsy specimen only	0
Biopsy specimen AND debulk specimen	0
Debulk specimen only	1

*p-value calculated using Chi-square test.

†p-value calculated using Fischer's exact test.

‡Out of 137 cases evaluated for perineural invasion, 47 had histologic evidence of perineural invasion.

§Out of 105 cases evaluate for lymphovascular invasion, 1 had histologic evidence of lymphovascular invasion.

BCC, basal cell carcinoma; SCC, squamous cell carcinoma.

© 2017 by the American Society for Dermatologic Surgery, Inc. Published by Wolters Kluwer Health, Inc. Unauthorized reproduction of this article is prohibited.

TABLE 4. Tumor (T) Stage of SCC on Initial Biopsy and After Debulk Analysis

*American Joint Committee on Cancer Seventh Edition, Staging Criteria for Cutaneous SCC**

(N, %)		Debulk Analysis Specimen				
Initial Biopsy	*Tumor (T) Stage*	*Tis*	*T1*	*T2*	*T3*	*T4*
	Tis	111 (22.8)	32 (6.6)†	0	0	0
	T1	0	284 (58.4)	12 (2.5)†	0	0
	T2	0	0	47 (9.7)	0	0
	T3	0	0	0	0	0
	T4	0	0	0	0	0

Brigham and Women's Alternative Staging Criteria for Cutaneous SCC‡

(N, %)		Debulk Analysis Specimen				
Initial Biopsy	*Tumor Stage (T)*	*Tis*	*T1*	*T2a*	*T2b*	*T3*
	Tis	111 (22.8)	31 (6.4)†	1 (0.2)	0	0
	T1	0	271 (55.8)	4 (0.8)†	1 (0.2)	0
	T2a	0	0	48 (9.9)	17 (3.5)§	0
	T2b	0	0	0	2 (0.4)	0
	T3	0	0	0	0	0

Light-shaded cells indicate cases in which there was no change in tumor stage on debulk analysis compared to initial biopsy. Dark-shaded cells indicate cases where there was an upstage (or increase in tumor stage) on debulk analysis compared to initial biopsy.

*AJCC high-risk features include >2 mm thickness, Clark level ≥4, perineural invasion, primary site ear, primary site non–hair-bearing lip, or poorly differentiated histology.

†Indicates a statistically significant *p* value <.01.

‡BWH high-risk features include tumor diameter ≥2 cm, poorly differentiated histology, perineural invasion >0.1 mm, or tumor invasion beyond fat (excluding bone invasion which automatically upgrades tumor to BWH stage 3).

§Indicated a *p*-value = .774.

AJCC, American Joint Committee on Cancer; SCC, squamous cell carcinoma; T, tumor.

debulk analysis ($p < .001$). Of 47 cases with PNI, only 3 (6.4%) were detected on initial biopsy and 42 (89.4%) were detected in the debulk specimen. There was only one case of LVI, and it was detected in the debulk specimen.

Tumor Upstaging on Debulk Analysis

Table 4 displays the tumor (T) stage of 486 cases of SCC on initial biopsy and subsequent debulk analysis according to the AJCC-7 and BWH Alternative staging criteria. Incidence of upstaging to a higher T stage on debulk analysis was 9.1% per AJCC-7 criteria: 6.6% of cases were upstaged from AJCC Tis to T1 ($p < .01$); and 2.5% from AJCC T1 to T2 ($p < .01$). As per BWH Alternative criteria, 11.1% of SCCs were upstaged: 6.4% to T1 ($p < .01$), 1% to T2a ($p < .01$) and 3.7% to T2b ($p = .07$).

Discussion

The authors' study is the only quantitative systematic review to date that evaluates the incidence of adverse histologic features and tumor upstaging on debulk analysis compared with initial biopsy specimens. Analysis of over 2,000 BCCs revealed a 30% incidence of reclassification from low-risk to high-risk histologic subtype for example, infiltrative, basosquamous, micronodular, and morpheaform. High-risk BCCs should be excised with wider margins (4–6 mm) or with MMS.[2,3] Treatment of these aggressive tumors as low-risk BCCs with curettage, cryotherapy, or narrow margin excision will likely result in higher rates of local recurrence.[20–22] Basal cell carcinomas account for nearly 80% of all skin cancers diagnosed in the United States, that is 2 million cases occur annually per year.[23] Misclassification of high-risk BCCs as low-risk in

© 2017 by the American Society for Dermatologic Surgery, Inc. Published by Wolters Kluwer Health, Inc. Unauthorized reproduction of this article is prohibited.

30% of cases will result in a substantial number of inappropriately treated BCCs.

Tumor upstaging for SCC based on debulk analysis compared with initial biopsy was 9.1% per AJCC-7 and 11.1% per BWH Alternative staging criteria. Importantly, 90% (18/20) of BWH high-risk T2b SCCs were inaccurately staged as lower T stages. In their study proposing the BWH alternative staging criteria, Jambusaria-Pahlajani and colleagues[19] showed that BWH T2b SCCs have 43% risk of local recurrence, 72% nodal metastasis, and 83% SCC-related deaths. Although no guidelines currently exist, there is a suggested role of sentinel lymph node biopsy and adjuvant radiation therapy for BWH T2b SCCs. Furthermore, biopsy specimens failed to detect 89% of cases of PNI. The National Comprehensive Cancer Network (NCCN) guidelines for localized, high-risk cutaneous SCC recommend adjuvant radiation therapy for cases with extensive PNI or large-nerve invasion.[3] Debulk analysis can thus help identify high-risk tumors that may require closer surveillance, nodal workup, and multidisciplinary care.

The results of the authors' study depended on completeness and accuracy of the articles included in the quantitative systematic review. More than 70% of cases had missing tumor size. Diameter of nerves affected by PNI was not reported. Squamous cell carcinomas with missing data are thus likely under-staged based on both AJCC and BWH criteria which use tumor size and diameter of nerve invasion as staging criteria. Six out of 14 studies had nonconsecutive cases, where the surgeons selected the tumors to be sent for debulk analysis. These studies may have a higher incidence of adverse features because of selection bias as surgeons are presumably more likely to send clinically high-risk tumors for further analysis. Despite these limitations, the data from the authors' study still demonstrate statistically significant reclassification from low-risk to high-risk for 30% of BCCs, and upstaging to higher tumor T stage for approximately 10% of SCCs. The authors' reported incidence of SCC upstaging on debulk analysis is similar to that observed with melanoma tumors. Studies have reported an 8% to 10% incidence of melanoma upstaging after histologic analysis of residual tumor from WLE.[24,25]

The authors' study highlights the pitfalls of relying solely on biopsy pathology results to dictate treatment for NMSCs. Thorough physical examination is crucial to determine extent of soft tissue spread, potential nerve invasion signified by pain, numbness or muscle paralysis, and lymphatic spread. This is especially true for lesions undergoing treatment with MMS. The decision to send tumor debulk for further analysis remains at the discretion of the Mohs surgeon, as there is no applicable guidelines or consensus available. Further studies are needed to identify patient and tumor risk factors that correlate with an increased incidence of high-risk histologic features observed on debulk analysis. Once these patient and tumor risk factors are established, guidelines may be formed for the appropriate use of debulk analysis in MMS for the treatment of NMSCs.

Conclusion

Histologic analysis of debulked tumor improves the detection of high-risk features and accuracy of tumor (T) staging compared with initial biopsy. Debulk analysis may therefore help to optimize management for high-risk skin cancers and improve patient outcomes.

References

1. Edge SB, Byrd DR, Compton CC, Fritz AG, et al. *AJCC Cancer Staging Manual* (7th ed). New York, NY: Springer; 2010.
2. Connolly SM, Baker DR, Coldiron BM, Fazio MJ, et al. AAD/ACMS/ASDSA/ASMS 2012 appropriate use criteria for Mohs micrographic surgery: a report of the American Academy of Dermatology, American College of Mohs surgery, American Society for Dermatologic surgery Association, and the American Society for Mohs Surgery. J Am Acad Dermatol 2012;67:531–50.
3. National Comprehensive Cancer Network. *Squamous Cell Skin Cancer (Version 1.2016). NCCN Guidelines*. 2016. Available at: https://www.nccn.org/professionals/physician_gls/pdf/nmsc.pdf. Accessed June 7, 2017.
4. Karia PS, Jambusaria-Pahlajani A, Harrington DP, Murphy GF, et al. Evaluation of American Joint Committee on cancer, International union against cancer, and Brigham and women's hospital tumor staging for cutaneous squamous cell carcinoma. J Clin Oncol 2014; 32:327–34.
5. Chuang GS, Lu LK, Cummins DL, Wu H, et al. Incidence of invasive squamous cell carcinomas in biopsy-proven squamous cell carcinomas in situ sent for Mohs micrographic surgery. Dermatol Surg 2012;38: 1456–60.
6. Cohen PR, Schulze KE, Nelson BR. Basal cell carcinoma with mixed histology: a possible pathogenesis for recurrent skin cancer. Dermatol Surg 2006;32:542–51.
7. Ebede TL, Lee EH, Dusza SW, Busam KJ, et al. Clinical value of paraffin sections in association with Mohs micrographic surgery for nonmelanoma skin cancers. Dermatol Surg 2012;38:1631–8.

© 2017 by the American Society for Dermatologic Surgery, Inc. Published by Wolters Kluwer Health, Inc. Unauthorized reproduction of this article is prohibited.

8. Haws AL, Rojano R, Tahan SR, Phung TL, et al. Accuracy of biopsy sampling for subtyping basal cell carcinoma. J Am Acad Dermatol 2012;66:106–11.

9. Izikson L, Seyler M, Zeitouni NC. Prevalence of underdiagnosed aggressive non-melanoma skin cancers treated with Mohs micrographic surgery: analysis of 513 cases. Dermatol Surg 2010; 36:1769–72.

10. Kamyab-Hesari K, Seirafi H, Naraghi ZS, Shahshahani MM, et al. Diagnostic accuracy of punch biopsy in subtyping basal cell carcinoma. J Eur Acad Dermatol Venereol 2014;28:250–3.

11. Knackstedt TJ, Brennick JB, Perry AE, Zhongze L, et al. Frequency of squamous cell carcinoma (SCC) invasion in transected SCC in situ referred for Mohs surgery: the Dartmouth-Hitchcock experience. Int J Dermatol 2015;54:830–3.

12. Kwon S, Godsey HTT, Gloster HM. Evaluation of residual tumor from Mohs micrographic specimens of clinically resolved preoperative biopsy sites. Dermatol Surg 2013;39:487–9.

13. Mosterd K, Thissen MRTM, van Marion AMW, Nelemans PJ, et al. Correlation between histologic findings on punch biopsy specimens and subsequent excision specimens in recurrent basal cell carcinoma. J Am Acad Dermatol 2011;64:323–37.

14. Roozeboom MH, Mosterd K, Winnepenninckx VJL, Nelemans PJ, et al. Agreement between histological subtype on punch biopsy and surgical excision in primary basal cell carcinoma. J Eur Acad Dermatol Venereol 2013;27:894–8.

15. Russell EB, Carrington PR, Smoller BR. Basal cell carcinoma: a comparison of shave biopsy versus punch biopsy techniques in subtype diagnosis. J Am Acad Dermatol 1999;41:69–71.

16. Welsch MJ, Troiani BM, Hale L, DelTondo J, et al. Basal cell carcinoma characteristics as predictors of depth of invasion. J Am Acad Dermatol 2012;67:47–53.

17. Westers-attema A, Joosten WMHJ, Roozeboom MH, Nelemans PJ, et al. Correlation between histological findings on punch biopsy specimens and subsequent excision specimens in cutaneous squamous cell carcinoma. Acta Derm Venereol 2015;95:181–5.

18. Wolberink EAW, Pasch MC, Zeiler M, van Erp PEJ, et al. High discordance between punch biopsy and excision in establishing basal cell carcinoma subtype: analysis of 500 cases. J Eur Acad Dermatol Venereol 2013;27:985–9.

19. Jambusaria-Pahlajani A, Kanetsky PA, Karia PS, Hwang WT, et al. Evaluation of AJCC tumor staging for cutaneous squamous cell carcinoma and a proposed alternative tumor staging system. JAMA Dermatol 2013;149:402–10.

20. Sloane JP. The value of typing basal cell carcinomas in predicting recurrence after surgical excision. Br J Dermatol 1997;96:127–32.

21. Lang PG, Maize JC. Histologic evolution of recurrent basal cell carcinoma and treatment implications. J Am Acad Dermatol 1986;14:186–96.

22. Cohen PR, Schulze KE, Nelson BR. Cutaneous carcinoma with mixed Histology: a potential etiology for skin cancer recurrence and an indication for Mohs microscopically controlled surgical excision. South Med J 2005;98:740–7.

23. Asgari MM, Moffet HH, Ray TG, Quesenberry CP. Trends in basal cell carcinoma incidence and identification of high-risk Subgroups. JAMA Dermatol 2015;151:976–61.

24. Egnatios GL, Dueck AC, Macdonald JB, Laman SD, et al. The impact of biopsy technique on upstaging, residual disease, and outcome in cutaneous melanoma. Am J Surg 2011;202:771–8.

25. Hieken TJ, Hernandez-Irizarry R, Boll JM, Coleman JEJ. Accuracy of diagnostic biopsy for cutaneous melanoma: implications for surgical oncologists. Int J Surg Oncol 2013:1–6.

Address correspondence and reprint requests to: Bichchau M. Nguyen, MD, MPH, Department of Dermatology, Tufts Medical Center, 800 Washington Street, Box 114, Boston, MA 02111, or e-mail: BNguyen2@tuftsmedicalcenter.org

© 2017 by the American Society for Dermatologic Surgery, Inc. Published by Wolters Kluwer Health, Inc. Unauthorized reproduction of this article is prohibited.