J Stomatol Oral Maxillofac Surg xxx (2017) xxx–xxx

Available online at
ScienceDirect
www.sciencedirect.com

Elsevier Masson France
EM|consulte
www.em-consulte.com/en

Review

Injections of platelet-rich plasma for androgenic alopecia: A systematic review

Q1 F. Picard *, B. Hersant, J. Niddam, J.-P. Meningaud

Department of Plastic & Reconstructive Surgery and Maxillo-Facial Surgery, Henri-Mondor Hospital, 51 avenue du Maréchal-de-Lattre-de-Tassigny, Créteil 94010, France

ARTICLE INFO

Article history:
Received 2 April 2017
Accepted 20 June 2017

Keywords:
Platelet-rich plasma
Alopecia
Androgenic alopecia
Review

ABSTRACT

The aim of this literature review was to evaluate the effects of PRP injections into the scalp of patients with androgenic alopecia. A literature review was conducted using the Pubmed and Google Scholar databases with the search terms "platelet-rich plasma" or "platelet-rich fibrin" and "hair" or "alopecia" or "androgenic alopecia". The publications included had to clinically assess the efficacy of PRP injections in patients with androgenic alopecia. Out of the 32 publications retrieved, 14 publications were included, of which 3 randomized, 4 prospective controlled, 4 prospective uncontrolled and 3 retrospective studies. Seven out of 9 studies reported a significant increase of hair density ranging between 12.3 and 45.9 hairs/cm^2, (i.e. 19–31% hairs/cm^2). Four studies assessed hair loss with the traction test and found a negative result after treatment in more than 95% of patients. Regarding hair thickness, 1 study reported an increase in hair diameter of 46.4% and 1 reported an increase of 106.4% of the "Hair mass index". Overall, the use of PRP injections in patients with androgenic alopecia seems effective with respect to promoting lost hair regrowth, decreasing hair loss and increasing hair thickness. The effects appear to be progressive from the first injection session, to peak after 3 to 5 sessions and to be attenuated in the absence of further injections. No major adverse effect was reported in the 14 clinical studies.

© 2017 Elsevier Masson SAS. All rights reserved.

1. Introduction

Androgenic alopecia, which is explained by abnormally elevated activity of the enzyme 5α-reductase type 2 at the level of the hair follicles in the temporal, frontal and vertex areas [1], induces an esthetic prejudice. Injections of platelet-rich plasma (PRP) into the scalp are one of the new therapies used to slow down the onset of androgenic alopecia and to treat it. PRP is an increasingly widely used biomaterial prepared by recovering, separating and concentrating patient platelets from a blood draw [2]. The preparation methods are increasingly well mastered and abundantly described in the literature, including methods employing commercial kits [3]. Platelets are cells of interest with respect to cell proliferation and differentiation since they can release numerous growth factors and cytokines [4], which attract and stimulate endothelial and stem cells [5].

Hair growth, known as the anagen phase, consists of the proliferation and maturation of progenitor cells derived from the bulge stem cells [6,7]. The cells giving rise to hair growth are of at least 3 types [8]: slow-multiplying stem cells present in the hair follicle bulge, fast-multiplying progenitor cells which derive from stem cells and mesenchymal cells which are present in the dermal papilla.

Certain growth factors, of which EGF, FGF and TGF, contribute to hair growth regulation and control as shown in several studies [7,9–11]. Those growth factors are present in PRP [4] and thus available, from a blood sample, in an autologous manner, i.e. they are derived from the patient himself.

PRP injections may stimulate the growth of hair affected by locally increased activity of the enzyme 5α-reductase. Currently, the reference treatment is hair transplantation, which is an onerous surgical procedure requiring a donor site. This makes PRP injections attractive if they are effective.

The aim of this literature review was to evaluate the efficacy of PRP injections into the scalp of patients with androgenic alopecia, to determine the methods of use and to identify any adverse effects.

2. Material and methods

A literature review was conducted in February 2017 after searching the Pubmed and the Google Scholar databases with the

* Corresponding author.
E-mail address: dr.picard.frederic@gmail.com (F. Picard).

http://dx.doi.org/10.1016/j.jormas.2017.06.011
2468-7855/© 2017 Elsevier Masson SAS. All rights reserved.

UNCORRECTED PROOF

Please cite this article in press as: Picard F, et al. Injections of platelet-rich plasma for androgenic alopecia: A systematic review. J Stomatol Oral Maxillofac Surg (2017), http://dx.doi.org/10.1016/j.jormas.2017.06.011

search terms "platelet-rich plasma" or "platelet-rich fibrin" and "hair" or "alopecia" or "androgenic alopecia".

In order to be included, the publication had to clinically assess the efficacy of PRP injections in patients with androgenic alopecia. There was no publication date deadline. The publications could be written in English, French, Spanish, Italian or German.

The exclusion criteria consisted of the following: case reports, letters or reviews without any clinical trial, studies assessing PRP injections in association with another procedure or treatment, studies in patients with alopecia of a non-androgenic etiology, and in vitro and animal in vivo studies.

The primary endpoint was the hair regrowth as assessed by hair density, i.e. the number of hairs/unit area. The validated methods of measurement of hair density are phototrichograms [12], phototrichoscans [13] (which is a modified computerized Phototrichogram), and validated scores like the "Hair density Index" [14], which is the product of hair density and hair thickness assessed at the same time.

The secondary endpoint was hair loss, which can be assessed by the traction test [12]. This validated and well described method is the number of extracted hairs when a clinician grasps between his thumb, index and middle finger a bundle of approximately 50–60 hairs and tug them away firmly.

The others endpoints were hair thickness, which can be assessed by the hair diameter, the injections protocol and the side effects.

3. Results

The search retrieved 32 publications of which 18 were excluded for the following reasons: 5 publications consisted of letters without any clinical trial [15–19]; 2 publication were literature reviews which did not focus on the use of PRP for androgenic alopecia [20,21]; 1 publication was only an abstract [22]; 1 publication was a case report [23]; 2 publications evaluated PRP injections as adjunctive therapy with polydeoxyribonucleotide injections [24], or with deltaparine and protamine micro particles [25]; 1 publication evaluated hair transplants soaked with PRP before transplantation [26]; 3 publications evaluated PRP injections in patients with alopecia areata [27–29] and 3 publications were in vitro or animal in vivo studies [30–32].

The flowchart is presented in Fig. 1. The results are presented in Table 1.

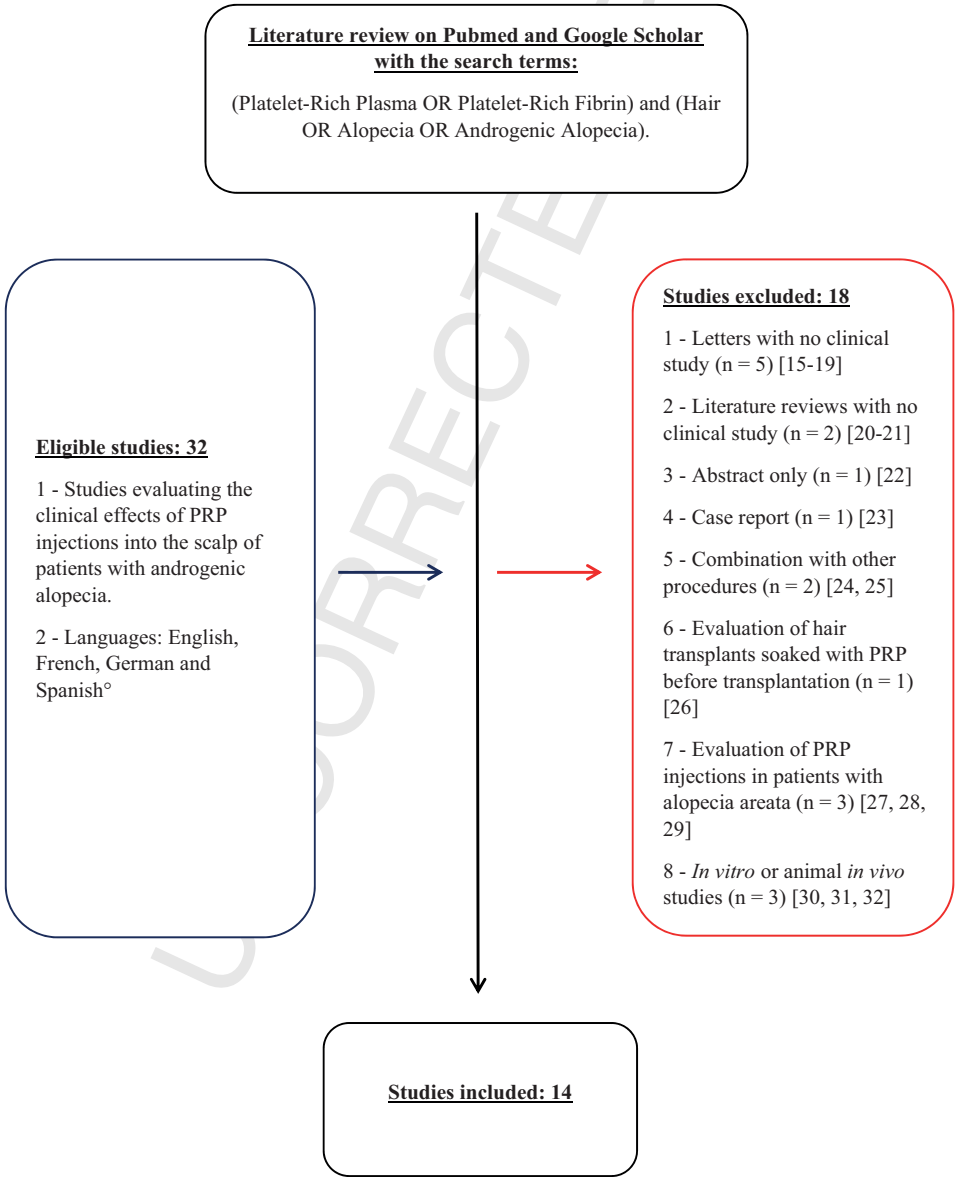

Fig. 1. Flowchart.

UNCORRECTED PROOF

Please cite this article in press as: Picard F, et al. Injections of platelet-rich plasma for androgenic alopecia: A systematic review. J Stomatol Oral Maxillofac Surg (2017), http://dx.doi.org/10.1016/j.jormas.2017.06.011

Table 1
Results.

Name, year	Design, number of patients	Injection protocol Protocol duration	Results for hair density, traction test, hair thickness, subjective assessment and satisfaction	Adverse effects
Gentile et al. 2015 [33]	Randomized, 20 patients	3 sessions of injections of PRP at intervals of 1 month Control areas: 3 sessions of normal saline injections	Mean increase in the number of hairs of 45.9 hairs/cm^2 for the treated areas vs. mean decrease of 5.6 hairs/cm^2 for the control areas ($P < 0.05$) Histological analysis: increase in the number of follicles, increase in the Ki67 cell division index of the bulb bulge stem cells, increase in the thickness of the epidermis	No adverse effect
Alves et al. 2016 [34]	Randomized, double-blind, 25 patients	3 sessions of injections of PRP at intervals of 1 month Control areas: 3 sessions of normal saline injections	Mean increase in the number of hairs of 12.8 hairs/cm^2 for the treated areas vs. mean decrease of 2.1 hairs/cm^2 for the control areas ($P < 0.05$)	Not described
Mapar et al. 2016 [35]	Randomized, single-blind, 17 patients	2 sessions of injections of PRP at intervals of 1 month Control areas: 2 sessions of normal saline injections	Mean decrease in the number of hairs of 2.2 hairs/cm^2 for the treated areas vs. mean decrease of 0.2 hairs/cm^2 for the control areas ($P > 0.05$)	Not described
Puig et al. 2016 [37]	Prospective, double-blind, controlled, 26 patients	1 session of injections of PRP Control areas: 1 session of normal saline injections	No improvement in hair count No improvement in hair mass index 13.3% of patients of the PRP group (vs. 0%) claimed to have experienced improvement in hair loss and hair thickness 26.7% of patients of the PRP group (vs. 18.2%) reported that their hair felt coarser or heavier	No adverse effect
Singhal et al. 2015 [38]	Prospective, controlled, 20 patients	Treated group: 4 sessions of injections of PRP at intervals of 2 weeks Control group: Minoxidil© treatment	Negative result of the traction test for all the treated patients Subjective improvement in hair growth in the treated group but not in the control group	Headache resolving on paracetamol
Cervelli et al. 2014 [39]	Prospective, controlled, 10 patients	Treated areas: 3 sessions of injections of PRP at intervals of 1 month Control areas: 3 sessions of normal saline injections	Mean increase in the number of hairs of 27.1 hairs/cm^2 for the treated areas vs. mean decrease of 2.1 hairs/cm^2 for the control areas ($P < 0.05$) Histological analysis: increase in the Ki67 cell division index of the bulb bulge stem cells, increase in the number of follicles, increase in follicle vascularization and increase in epidermal thickness vs. the untreated areas	No adverse effect
Kang et al. 2012 [40]	Prospective, controlled, 26 patients	Treatment group: 2 sessions of injections of PRP at an interval of 3 months Control group: placental extract injections once per week for 6 months	Mean increase in the number of hairs: 29.2% at 6 months, i.e. 12.3 hairs/cm^2 Mean increase in hair thickness of 46.4% at 6 months Significant difference for the PRP group with regard to increase in thickness but not for the number of hairs	Edema and erythema after the injections
Schiavone et al. 2014 [41]	Prospective, uncontrolled, 64 patients	2 sessions of injections of PRP at an interval of 3 months	Subjective improvement on the Jaeschke's evaluation scale [49] in 62 out of 64 patients for 1 observer and 64 out of 64 patients for the second observer Mean Jaeschke's scale score of 3.2 for the first observer and 3.9 for the second observer	No adverse effect
Gkini et al. 2014 [42]	Prospective, uncontrolled, 20 patients	3 sessions of injections of PRP at intervals of 3 weeks and 1 session 6 months after the 3rd session	Negative traction test result for all patients after the first 3 sessions Increase in hair density from 143.1 to 170.7 hairs/cm^2 after the first 3 sessions, i.e. an increase of 19.9% Subjective improvement in hair growth on photographs Mean patient satisfaction rate: 7.1/10	Pain and tenderness after the injections

UNCORRECTED PROOF

Please cite this article in press as: Picard F, et al. Injections of platelet-rich plasma for androgenic alopecia: A systematic review. J Stomatol Oral Maxillofac Surg (2017), http://dx.doi.org/10.1016/j.jormas.2017.06.011

Table 1 (*Continued*)

Name, year	Design, number of patients	Injection protocol Protocol duration	Results for hair density, traction test, hair thickness, subjective assessment and satisfaction	Adverse effects
Khatu et al. 2014 [43]	Prospective, uncontrolled, 11 patients	4 sessions of injections of PRP at intervals of 2 weeks	Negative result of the traction test for 9 out of 11 patients Mean increase in the number of hairs from 71 to 93 hairs/cm^2, i.e. 22 hairs/cm^2 Mean patient satisfaction rate: 7.0/10	Pain and redness
Sclafani, 2014 [44]	Prospective, uncontrolled, 15 patients	3 sessions of injections of platelet-rich fibrin at intervals of 1 month	Increase in the hair density index of 25.2% at 1 month, 47.4% at 2 months, 106.4% at 3 months and 75.1% at 6 months Patient satisfaction was greater in the patients presenting with limited alopecia vs. those with Norwood stage 5 or 6	No adverse effect
Navarro et al. 2016 [45]	Retrospective, controlled, 379 patients	2 sessions of injections of PRP at intervals of 1 month Control group: application of a minoxidil solution 6 nights a week for 4 months	Mean increase of the anagen follicles proportion of 6.9% vs. a mean increase of the anagen follicles proportion of 4.6% for the minoxidil group ($P < 0.05$) Mean decrease of the telogen follicles proportion of 5.7% vs. a mean decrease of the telogen follicles proportion of 2.6% for the minoxidil group ($P < 0.05$) Overall improvement in hair volume and quality on photographs	No adverse effect
Betsi et al. 2013 [46]	Retrospective, uncontrolled, 42 patients	5 sessions of injections of PRP at intervals of 2 weeks	Decrease in the positive traction test result from 90.5 to 0% after 3 sessions Overall improvement in hair volume and quality on photographs Superior results for the patients suffering from androgenic alopecia for less than 2 years	Tender and numb scalp after the injections
Navarro et al. 2015 [47]	Retrospective, uncontrolled, 100 patients	2 sessions of injections of PRP at intervals of 1 month	Mean increase of the anagen follicles proportion of 6.9% and mean decrease of the telogen follicles proportion of 5.7% Overall improvement in hair volume and quality on photographs All the patients were satisfied	No adverse effect

Overall, 14 clinical trials assessed PRP injections alone in patients with androgenic alopecia and were included in the review, of which 3 randomized study [33–35] (level of evidence 2 [36]), 4 prospective controlled studies [37–40] (level of evidence 2 [36]), 4 prospective uncontrolled studies [41–44] (level of evidence 4 [36]), and 3 retrospective studies [45–47] (level of evidence 4 [36]).

3.1. Hair density

Among the 14 studies included, 9 studies assessed hair density and 7 found an increase of hair density: 2 randomized controlled studies [33,34], 2 prospective controlled studies [39,40] and 3 prospective uncontrolled studies [42–44].

The study of Gentile et al. [33] was a randomized double-blinded trial on 23 patients treated with 3 sessions of injections of PRP on a monthly basis or 3 sessions of injections of physiological solutions. Hair density was assessed with Trichoscans and the results showed a mean increase of 45.9 hair/cm^2 in the treated group versus a mean decrease of 5.6 hair/cm^2 in the control group ($P < 0.05$).

The study of Alves et al. [34] was a randomized double-blinded trial on 25 patients treated with 3 sessions of injections of PRP on a monthly basis or 3 sessions of injections of physiological solutions. Hair density was assessed with Trichoscans and the results showed a mean increase of 12.8 hair/cm^2 in the treated group versus a mean decrease of 2.1 hair/cm^2 in the control group ($P < 0.05$).

The study of Cervelli et al. [39] was a prospective controlled study on 10 patients treated with 3 sessions of injections of PRP in one half of the alopecic scalp and 3 sessions of physiological solutions in the other half. Hair density was assessed with Trichoscans and the results showed a mean increase of 27.1 hair/cm^2 in the treated areas and a mean decrease of 2.1 hair/cm^2 in the control areas ($P < 0.05$).

The study of Kang et al. [40] was a prospective controlled study on 26 patients treated with 2 sessions of injections of PRP at an interval of 3 months or with weekly injections of placental extract. Hair density was assessed with phototrichograms and the results showed a mean increase of 29.2% of the hair density in the PRP group ($P < 0.0001$).

The study of Gkini et al. [42] was a prospective uncontrolled study on 20 patients treated with 3 sessions of injections of PRP at an interval of 3 weeks. Hair density was assessed with phototrichograms and the results showed a mean increase of the hair density from 143.1 hair/cm^2 to 170.7 hair/cm^2 ($P < 0.05$).

The study of Khatu et al. [43] was a prospective uncontrolled study on 11 patients treated with 4 sessions of injections of PRP every 2 weeks. Hair density was assessed with phototrichograms and the results showed a mean increase of the hair density from 71 to 93.1 hair/cm^2 (no statistical analysis).

The study of Sclafani [44] was a prospective uncontrolled study on 15 patients treated with 3 sessions of injections of PRP on a monthly basis. The primary endpoint was the "Hair density index"

UNCORRECTED PROOF

Please cite this article in press as: Picard F, et al. Injections of platelet-rich plasma for androgenic alopecia: A systematic review. J Stomatol Oral Maxillofac Surg (2017), http://dx.doi.org/10.1016/j.jormas.2017.06.011

[14], taking into account both the number of hairs and the thickness of hairs, assessed with a specific device (Hair Check, Divi international Co. ©). The results showed a gradual increase in the hair density index up to a mean increase of 106.4% ($P < 0.05$) 1 month after the third injections session. The index decreased to 75.1% 4 months after the last injection session.

Two studies did not find an increase of hair density. The study of Mapar et al. [35] was a randomized single-blinded trial on 17 patients treated with 2 sessions of injections of PRP on a monthly basis or 2 sessions of injections of physiological solutions. The results showed a mean decrease of 2.2 hair/cm^2 in the treated group and a mean decrease of 0.2 hair/cm^2 in the control group ($P > 0.05$). The study of Puig et al. [37] was a prospective double-blinded controlled study on 26 patients treated with 1 session of injections of PRP or 1 session of injections of physiological solutions. Hair density was assessed with phototrichograms and the results showed no improvement in hair count or hair mass index.

3.2. Hair thickness

Hair thickness has been objectively measured in 2 studies. In the study of Kang et al. [40], hair diameter increased on average of 31.3% ($P < 0.0001$) 3 months after the first injection session and 46.4% ($P < 0.0001$) 3 months after the second injection session.

In the study of Sclafani [44], the "Hair density index" [14] (was composed of the hair density and the hair thickness). A part of the increase of this index up to 106.4% was due to the increase of the hair diameter, as it was shown on pre- and post-treatment pictures.

Hair volume has been subjectively assessed in 4 studies. In the study of Betsi et al. [46], which was a retrospective uncontrolled study on 42 patients treated with 5 sessions of PRP at an interval of 2 weeks, in the 2 studies of Navarro et al. [45,47] which were retrospective studies on patients treated with 2 sessions of injections of PRP at an interval of 1 month and in the study of Puig et al. [37], in which 33.3% of patients in the treated group versus 27.2% in the minoxidil group ($P > 0.05$) found an improvement of their hair thickness.

3.3. Hair loss

Hair loss has been assessed in 4 studies by the traction test which became negative in over 95% of patients.

The study of Singhal et al. [38] was a prospective controlled study on 20 patients treated with 4 sessions of injections of PRP at an interval of 2 weeks. The traction test result was negative for all patients after having received 4 PRP injections sessions.

The study of Gkini et al. [42] was a prospective uncontrolled study on 20 patients treated with 3 sessions of injections of PRP at an interval of 3 weeks and a last session 6 months after. The traction test result was negative in all patients after the first of 3 injections sessions and became positive again 3 months after the last PRP injection session. The effect appeared to be transient.

In the study of Kathu et al. [43], the traction test result was negative in 9 out of 11 patients (82%) after 4 sessions of PRP injections at an interval of 2 weeks.

The study of Betsi et al. [46] was a retrospective uncontrolled study on 42 patients treated with 5 sessions of PRP at an interval of 2 weeks. The traction test result was negative for all the patients after the third injections session.

In the study of Puig et al. [37] (1 session of PRP injection), 26.6% of patients in the treated group vs. 27.3% of patients in the control group ($P > 0.05$) found an improvement of hair loss. The high score of subjective improvement of hair loss in the control group can only be due to the placebo effect since physiological solution was injected instead of PRP.

3.4. Patient satisfaction

In the prospective uncontrolled studies of Gkini et al. [42] and Khatu et al. [43], the mean patient satisfaction rate were respectively 7.1 and 7.0/10. In the retrospective uncontrolled study of Navarro et al. [47] on 100 patients treated with 2 sessions of PRP injections, "all the patients were satisfied" at the end of the follow-up, i.e. 3 months after the last injection.

3.5. Side effects

No major adverse effect was reported in the 14 studies. No iatrogenic alopecia, infection or abscess was reported. PRP injections seemed to be very safe.

Five studies [38,40,42,43,46] reported a few episodes of local pain, erythema and swelling post-injections but there was no infection. In the study of Singhal et al. [38], some patients experienced headache post-injections, which regressed on paracetamol.

3.6. Histological results

The histological analysis of the PRP-treated areas in the studies of Cervelli et al. [39] and Gentile et al. [33] showed a significant increase in the number of hair follicles, an increase in the thickness of the scalp epidermis, an increase in vascularization between the follicles and an increase in the Ki67 proliferation index [48] of bulge stem cells and of the cells of the basal layer of the epidermis.

In the retrospectives studies of Navarro et al. [45,47], the proportion of the anagen follicles increases of 6.9% in the PRP group versus 4.6% in the minoxidil group ($P < 0.05\%$) whereas the proportion of telogen follicles decreased of 5.7% in the PRP group versus 2.6% in the minoxidil group ($P < 0.05$).

3.7. Methods of injections

The total amount of PRP injected per treatment was between 1.5 mL and 12 mL: 6 studies [34,35,40,43,45,47] injected less than 4 mL and 7 studies [33,37–39,41,44,46] injected 8 to 12 mL. The volume per injection was described in 7 studies [33,34,39–42,44], and was between 0.05 and 0.15 mL/cm^2 in 6 studies [33,34,39,40,42,44]. The number of injections per session of injections was described in 7 studies [33,34,39–42,44], about 20 injections were made in the study of Alves et al. [34], about 50 injections were made in 3 studies [40–42] and about 100 injections in 3 other studies [33,39,44]. The depth of injections was described in 5 studies [35,37,41,42,44], 3 studies [35,42,44] did intradermal injections, 1 study [37] did subcutaneous injections and 1 study [41] injected in the "superficial scalp". The localisation of the injections was described in 8 studies [33,34,39,40,42–45] and was always the zones of androgenic alopecia, i.e. the frontal, parietal and vertex areas. Regarding the number of sessions of injections, 1 study [37] assessed 1 session, 5 studies [35,40,41,45,47] assessed 2 sessions, 5 studies [33,34,39,42,44] assessed 3 sessions, 2 studies [38,43] assessed 4 sessions and 1 study [46] assessed 5 sessions. The intervals between each session of treatment were 2 weeks in 3 studies [38,43,46], 3 weeks in 1 study [42], 1 month in 7 studies [33–35,39,44,45,47] and 3 months in 2 studies [40,41].

3.8. Methods of preparation of PRP

In 12 studies of this review [33–35,37,39–42,44–47], the PRP was made with commercial kits like Selphyl© [33,39,44], Regenlab© [42,46], Proteal© [34], Tubex© [35], Angel© [37], Smartprep© [40], Biomet© [41], and BTI© [45,47]. The PRP was

UNCORRECTED PROOF

Please cite this article in press as: Picard F, et al. Injections of platelet-rich plasma for androgenic alopecia: A systematic review. J Stomatol Oral Maxillofac Surg (2017), http://dx.doi.org/10.1016/j.jormas.2017.06.011

mixed with calcium before the injections in order to be activated in 11 studies [33–35,38,39,42–47]. Five studies [35,37,40–42] assessed the platelet concentration of the PRP used and found that it was increased between 2.75 [37] and 5.9 [40] times compared to the baseline.

4. Discussion

Fourteen clinical studies specifically assessing PRP injections in patients with androgenic alopecia were included in this literature review. However, these studies did not have the same protocol for the frequency and the amount of injections. Regarding the methods of evaluation, they used the most common objective non-invasive methods, which are phototrichograms [12], phototrichoscans [13], the "Hair density index" [14] and the measure of the hair diameter. To be accurate, these methods need to assess the exact same location on the scalp, which is not easily feasible in practice. Others studies used global pictures [12] and traction tests [12], which are much more subjective, but these methods are reproducible and do not need to assess the exact same location of the scalp.

Regarding hair regrowth, 7 studies (2 randomized trials [33,34], 2 prospective controlled [39,40] and 3 prospective uncontrolled studies [42–44]) showed a significant increase in the number of hairs ranging between 12.3 and 45.9 hairs/cm^2 (i.e. 19% to 31%), whereas 2 studies did not (1 randomized trial [35] and 1 prospective controlled study [37]).

Regarding hair loss, all the results were concordant and clinically interesting. The traction test was assessed in 4 studies and was negative for more than 95% [38,42,43,46] of the patients treated with PRP injections. Furthermore, histological studies by Navarro et al. [45,47] found an increase of the anagen follicles proportion and a decrease of the telogen follicles proportion after 2 PRP injections, which can explain the improvement of the traction test and hair loss.

Regarding hair thickness and hair volume, 2 studies found very promising results since one showed an increase of the hair diameter of almost 50% [40] and the other found an increase of the "Hair mass index" of more than 100% [44].

Furthermore, 8 studies [37,38,41,42,44–47] found subjective improvements whether it was for hair loss, hair volume, hair quality or scalp coverage.

With regard to histology, 2 studies [33,39] showed similar results that may underlie the clinical efficacy of PRP injections: an increase in the Ki67 index of cells at bulge level, and an increase in local vascularization which may improve hair growth.

In vitro and animal in vivo studies have also shown the effects of PRP at the cell level. The in vivo studies by Li et al. [30] and Rastegard et al. [32] generated similar results showing that PRP increased the proliferation of the cells of the dermal papilla and the activity of the signaling pathways involved in hair growth. Moreover, the study of Miao et al. [31] evidenced that the adjunction of PRP with epidermal stem cells and cells of the dermal papilla increased the formation of new follicles and the growth rate of murine fur.

Therefore, despite the lack of high level of evidence data, PRP injections into the scalp of patients with androgenic alopecia seemed to have 3 different ways of efficiency: hair regrowth, decrease of hair loss and increase of hair thickness.

Only minor side effects, like local pain, erythema and swelling were reported in the 14 studies included. There was no infection, no abscess and no iatrogenic alopecia reported. Thus, injections of PRP for androgenic alopecia seemed to be a very safe procedure.

The analysis of the injections methods showed that most of the studies [33,34,39,40,42,44] realized injections of about 0.1 mL/cm^2, and injected the PRP in or just below the dermis [35,37,41,42,44].

The analysis of the protocols did not enable the determination of a number of sessions or a between-session interval that was more effective since the studies were not sufficiently numerous, the number of injection sessions ranged from 1 to 5, and the between-session intervals ranged from 2 weeks to 3 months. However, 2 studies suggested that the effects were transient. The study of Sclafani et al. [44] showed that the "Hair density index" decreased 4 months after the last session and the study of Gkini et al. [42] generated similar results with an increase of the traction test and a decrease of the hair density 4 months after the last injections session.

The PRP used were prepared with commercial kits in 12 studies [33–35,37,39–42,44–47] and were activated with calcium in 11 studies [33–35,38,39,42–47]. Even though the control of the platelet concentration seems to be crucial, only 5 studies [35,37,40–42] controlled their PRP, which did not enable the determination of a more effective platelet concentration for androgenic alopecia.

Maintenance treatment seems therefore indispensable in order to delay the long-term progression of androgenic alopecia. An appropriate protocol for use of PRP may be an initial treatment with 3 injections sessions at an interval of 1 month and a maintenance treatment every 3 months.

5. Conclusion

Overall, the use of PRP injections in patients with androgenic alopecia seems effective in promoting lost hair regrowth, in decreasing hair loss and in increasing hair thickness. The effects appeared to be gradual, to peak after on average 4 sessions, and to decrease when the injections stopped, hence the need of a maintenance treatment. No major side effects were reported.

Disclosure of interest

The authors declare that they have no competing interest.

References

[1] Kaufman KD. Androgen metabolism as it affects hair growth in androgenetic alopecia. Dermatol Clin 1996;14(4):697–711.
[2] Dohan Ehrenfest DM, Bielecki T, Mishra A, Borzini P, Inchingolo F, Sammartino G, et al. In search of a consensus terminology in the field of platelet concentrates for surgical use: platelet-rich plasma (PRP), platelet-rich fibrin (PRF), fibrin gel polymerization and leukocytes. Curr Pharm Biotechnol 2012;13(7):1131–7.
[3] Magalon J, Bausset O, Serratrice N, Giraudo L, Aboudou H, Veran J, et al. Characterization and comparison of 5 platelet-rich plasma preparations in a single-donor model. Arthroscopy 2014;30(5):629–38.
[4] Park H-B, Yang J-H, Chung K-H. Characterization of the cytokine profile of platelet rich plasma (PRP) and PRP-induced cell proliferation and migration: upregulation of matrix metalloproteinase-1 and -9 in HaCaT cells. Korean J Hematol 2011;46(4):265–73.
[5] Kushida S, Kakudo N, Suzuki K, Kusumoto K. Effects of platelet-rich plasma on proliferation and myofibroblastic differentiation in human dermal fibroblasts. Ann Plast Surg 2013;71(2):219–24.
[6] Greco V. A two-step mechanism for stem cell activation during hair regeneration. Cell Stem Cell 2009;4(2):155–69.
[7] Cotsarelis G, Sun TT, Lavker RM. Label-retaining cells reside in the bulge area of pilosebaceous unit: implications for follicular stem cells, hair cycle, and skin carcinogenesis. Cell 1990;61(7):1329–37.
[8] Rompolas P, Deschene ER, Zito G, Gonzalez DG, Saotome I, Haberman AM, et al. Live imaging of stem cell and progeny behaviour in physiological hair-follicle regeneration. Nature 2012;487(7408):496–9.
[9] Watt FM, Jensen KB. Epidermal stem cell diversity and quiescence. EMBO Mol Med 2009;1(5):260–7.
[10] Shin HJ, Lee D-J, Kwon K, Seo H-S, Jeong H-S, Lee J-Y, et al. The success of thread-embedding therapy in generating hair re-growth in mice points to its possibly having a similar effect in humans. J Pharmacopuncture 2015;18(4):20–5.

UNCORRECTED PROOF

Please cite this article in press as: Picard F, et al. Injections of platelet-rich plasma for androgenic alopecia: A systematic review. J Stomatol Oral Maxillofac Surg (2017), http://dx.doi.org/10.1016/j.jormas.2017.06.011

[11] Oshima H, Rochat A, Kedzia C, Kobayashi K, Barrandon Y. Morphogenesis and renewal of hair follicles from adult multipotent stem cells. Cell 2001;104(2):233–45.
[12] Dhurat R, Saraogi P. Hair evaluation methods: merits and demerits. Int J Trichol 2009;1(2):108.
[13] Hoffmann R. Trichoscan: what is new? Dermatology 2005;211(1):54–62.
[14] Cohen B. The cross-section trichometer: a new device for measuring hair quantity, hair loss, and hair growth. Dermatol Surg 2008;34(7):900–11.
[15] Bagherani N. Is platelet-rich plasma effective in the treatment of alopecia areata? Dermatol Ther 2015 [Epub ahead of print].
[16] Rogers N. Commentary on autologous platelet-rich plasma: a potential therapeutic tool for promoting hair growth. Dermatol Surg 2012;38(7 Pt 1):1047–8.
[17] Godse K. Platelet rich plasma in androgenic alopecia: where do we stand? J Cutan Aesthet Surg 2014;7(2):110–1.
[18] Chaudhari ND, Sharma YK, Dash K, Deshmukh P. Role of platelet-rich plasma in the management of androgenetic alopecia. Int J Trichol 2012;4(4):291–2.
Q2 [19] Ferneini EM, Beauvais D, Castiglione C, Ferneini MV. Platelet-rich plasma in androgenic alopecia: indications, technique, and potential benefits. J Oral Maxillofac Surg 2016.
[20] Maria-Angeliki G, Alexandros-Efstratios K, Dimitris R, Konstantinos K. Platelet-rich plasma as a potential treatment for noncicatricial alopecias. Int J Trichol 2015;7(2):54–63.
[21] Gupta AK, Carviel JL. Meta-analysis of efficacy of platelet-rich plasma therapy for androgenetic alopecia. J Dermatol Treat 2017;28(1):55–8.
[22] Lopez V, Amparo Vaya, Bautista D, Ricart JM. Autologous platelet-rich plasma as a potential therapeutic tool in androgenetic alopecia. JAAD 2013;68(4):103.
[23] Park KY, Kim HK, Kim BJ, Kim MN. Letter: platelet-rich plasma for treating male pattern baldness. Dermatol Surg 2012;38(12):2042–4.
[24] Lee S-H, Zheng Z, Kang J-S, Kim D-Y, Oh SH, Cho SB. Therapeutic efficacy of autologous platelet-rich plasma and polydeoxyribonucleotide on female pattern hair loss. Wound Repair Regen 2015;23(1):30–6.
[25] Takikawa M, Nakamura S, Nakamura S, Ishirara M, Kishimoto S, Sasaki K, et al. Enhanced effect of platelet-rich plasma containing a new carrier on hair growth. Dermatol Surg 2011;37(12):1721–9.
[26] Uebel CO, da Silva JB, Cantarelli D, Martins P. The role of platelet plasma growth factors in male pattern baldness surgery. Plast Reconstr Surg 2006;118(6):1458–66.
[27] Singh S. Role of platelet-rich plasma in chronic alopecia areata: our centre experience. Indian J Plast Surg 2015;48(1):57–9.
[28] Trink A, Sorbellini E, Bezzola P, Rodella L, Rezzani R, Ramot Y, et al. A randomized, double-blind, placebo- and active-controlled, half-head study to evaluate the effects of platelet-rich plasma on alopecia areata. Br J Dermatol 2013;169(3):690–4.
[29] El Taieb MA, Ibrahim H, Nada EA, Seif Al-Din M. Platelets rich plasma versus minoxidil 5% in treatment of alopecia areata: a trichoscopic evaluation. Dermatol Ther 2017;30(1).
[30] Li ZJ, Choi H-I, Choi D-K, Sohn K-C, Im M, Seo Y-J, et al. Autologous platelet-rich plasma: a potential therapeutic tool for promoting hair growth. Dermatol Surg 2012;38(7 Pt 1):1040–6.
[31] Miao Y, Sun Y-B, Sun X-J, Du B-J, Jiang J-D, Hu Z-Q. Promotional effect of platelet-rich plasma on hair follicle reconstitution in vivo. Dermatol Surg 2013;39(12):1868–76.
[32] Rastegar H, Ahmadi Ashtiani H, Aghaei M, Ehsani A, Barikbin B. Combination of herbal extracts and platelet-rich plasma induced dermal papilla cell proliferation: involvement of ERK and Akt pathways. J Cosmet Dermatol 2013;12(2):116–22.
[33] Gentile P, Garcovich S, Bielli A, Scioli MG, Orlandi A, Cervelli V. The effect of platelet-rich plasma in hair regrowth: a randomized placebo-controlled trial. Stem Cells Transl Med 2015;4(11):1317–23.
[34] Alves R, Grimalt R. Randomized placebo-controlled, double-blind, half-head study to assess the efficacy of platelet-rich plasma on the treatment of androgenetic alopecia. Dermatol Surg 2016;42(4):491–7.
[35] Mapar MA, Shahriari S, Haghighizadeh MH. Efficacy of platelet-rich plasma in the treatment of androgenetic (male-patterned) alopecia: a pilot randomized controlled trial. J Cosmet Laser Ther 2016;18(8):452–5.
[36] Burns PB, Rohrich RJ, Chung KC. The levels of evidence and their role in evidence-based medicine. Plast Reconstr Surg 2011;128(1):305–10.
[37] Puig CJ, Reese R, Peters M. Double-blind, placebo-controlled pilot study on the use of platelet-rich plasma in women with female androgenetic alopecia. Dermatol Surg 2016;42(11):1243–7.
[38] Singhal P, Agarwal S, Dhot PS, Sayal SK. Efficacy of platelet-rich plasma in treatment of androgenic alopecia. Asian J Transfus Sci 2015;9(2):159–62.
[39] Cervelli V, Garcovich S, Bielli A, Cervelli G, Curcio BC, Scioli MG, et al. The effect of autologous activated platelet rich plasma (AA-PRP) injection on pattern hair loss: clinical and histomorphometric evaluation. Biomed Res Int 2014;2014(760709):9.
[40] Kang J-S, Zheng Z, Choi MJ, Lee S-H, Kim D-Y, Cho SB. The effect of CD34+ cell-containing autologous platelet-rich plasma injection on pattern hair loss: a preliminary study. J Eur Acad Dermatol Venereol 2014;28(1):72–9.
[41] Schiavone G, Raskovic D, Greco J, Abeni D. Platelet-rich plasma for androgenetic alopecia: a pilot study. Dermatol Surg 2014;40(9):1009–10.
[42] Gkini M-A, Kouskoukis A-E, Tripsianis G, Rigopoulos D, Kouskoukis K. Study of platelet-rich plasma injections in the treatment of androgenetic alopecia through an one-year period. J Cutan Aesthet Surg 2014;7(4):213–9.
[43] Khatu SS, More YE, Gokhale NR, Chavhan DC, Bendsure N. Platelet-rich plasma in androgenic alopecia: myth or an effective tool. J Cutan Aesthet Surg 2014;7(2):107–10.
[44] Sclafani AP. Platelet-rich fibrin matrix (PRFM) for androgenetic alopecia. Facial Plast Surg 2014;30(2):219–24.
[45] Navarro MR, Asín M, Martínez MA, Martínez AM, Molina C, Moscoso L, et al. Management of androgenetic alopecia: a comparative clinical study between plasma rich in growth factors and topical minoxidil. Eur J Plast Surg 2016;39(3):173–80.
[46] Betsi EE, Germain E, Kalbermatten DF, Tremp M, Emmenegger V. Platelet-rich plasma injection is effective and safe for the treatment of alopecia. Eur J of Plast Surg 2013;36(7):407–12.
[47] Navarro MR, Asín M, Martínez AM, Molina C, Navarro V, Pino A, et al. Plasma rich in growth factors (PRGF) for the treatment of androgenetic alopecia. Eur J Plast Surg 2015;38(6):437–42.
[48] Denkert C, Budczies J, Von Minckwitz G, Wienert S, Loibl S, Klauschen F. Strategies for developing Ki67 as a useful biomarker in breast cancer. Breast 2015;24(Suppl. 2):67–72.
[49] Jaeschke R, Singer J, Guyatt GH. Measurement of health status. Ascertaining the minimal clinically important difference. Control Clin Trials 1989;10(4):407–15.

UNCORRECTED PROOF

Please cite this article in press as: Picard F, et al. Injections of platelet-rich plasma for androgenic alopecia: A systematic review. J Stomatol Oral Maxillofac Surg (2017), http://dx.doi.org/10.1016/j.jormas.2017.06.011