Am J Clin Dermatol
DOI 10.1007/s40257-017-0278-9

SYSTEMATIC REVIEW

Primary Localized Cutaneous Amyloidosis: A Systematic Treatment Review

Till Weidner[1] · Tanja Illing[1] · Peter Elsner[1]

© Springer International Publishing Switzerland 2017

Abstract

Background Primary localized cutaneous amyloidosis (PLCA) is characterized by extracellular deposition of heterogenic amyloid proteins in the skin without systemic involvement. Lichen amyloidosis, macular amyloidosis, and (primary localized cutaneous) nodular amyloidosis are different subtypes of PLCA.

Objective The aim of this study was to review the current reported treatment options for PLCA.

Methods This systematic review was based on a search in the PubMed database for English and German articles from 1985 to 2016.

Results Reports on the treatment of PLCA were limited predominantly to case reports or small case series. There were a few clinical trials but these lacked control groups. A variety of treatment options for PLCA were reported including retinoids, corticosteroids, cyclophosphamide, cyclosporine, amitriptyline, colchicine, cepharanthin, tacrolimus, dimethyl sulfoxide, vitamin D_3 analogs, capsaicin, menthol, hydrocolloid dressings, surgical modalities, laser treatment, and phototherapy.

Conclusion No definitive recommendation of preferable treatment procedures can be made based on the analyzed literature. Randomized controlled trials are needed to offer patients an evidence-based therapy with high-quality standardized treatment regimens for PLCA.

✉ Till Weidner
till.weidner@med.uni-jena.de

[1] Department of Dermatology, University Hospital Jena, Erfurter Straße 35, Jena 07743, Germany

Key Points

- Therapy of primary localized cutaneous amyloidosis is a challenge for dermatologists.
- Many treatment options exist and no gold standard has been established.
- For lichen amyloidosis and macular amyloidosis, the most important issue is the resolution of any underlying disorder that may lead to chronic excoriation of the skin.

1 Introduction

Primary localized cutaneous amyloidosis (PLCA) is characterized by extracellular deposition of heterogenic amyloid proteins in the skin without systemic involvement. There are different subtypes of PLCA, namely: lichen amyloidosis (LA), macular amyloidosis (MA), and (primary localized cutaneous) nodular amyloidosis (NA) [1]. Additionally, the combined appearance of LA and MA is described as mixed (biphasic) amyloidosis (BA) [2].

Lichen amyloidosis, the most common form of PLCA, presents with multiple localized or rarely generalized, hyper-pigmented grouped papules with a predilection for the shins, calves, ankles, and dorsa of the feet and thighs (Fig. 1). It is mostly associated with severe pruritus, and it is, together with MA, a keratin-derived amyloidosis, in which cytokeratins serve as amyloid precursors, affecting only the dermis [3, 4]. Histological findings are grouped colloid bodies, which correspond to apoptotic basal keratinocytes [5]. Macular amyloidosis is characterized by

Published online: 24 March 2017

Fig. 1 Lichen amyloidosis on the lower legs

moderately pruritic macules of dark brown pigmentation with a rippled surface [6]. Pruritus does not occur in every patient and can be missing in up to 20% of LA cases [7]. Nodular amyloidosis is typically indicated by solitary or multiple tumors. In this condition, the amyloid originates from immunoglobulin light chains and is associated with dermal plasma cell infiltration, which has the potential to infiltrate the subcutaneous tissue and blood vessels and may progress to systemic disease, estimated to occur in at least 7% of cases [8, 9]. It has been observed that PLCA is relatively common among Southern Chinese and South American populations [10–12]. The etiopathology has yet to be clarified. It has been proposed that signaling abnormalities via the oncostatin M-type II receptor and/or the interleukin (IL)-31 receptor leads to keratinocyte apoptosis with subsequent amyloid deposition, a reduced number of cutaneous nerves, and pruritus [13, 14]. Moreover, a point mutation in the IL-31 receptor A gene in a family with hereditary PLCA was found by Lin et al. [15].

A wide array of medical conditions have been reported coincidentally with PLCA. Repeated skin friction may be associated with LA and MA [16–19]; to date, the causal factors are still unknown [20]. Multiple endocrine neoplasia type 2A is frequently associated with PLCA (especially LA), typically presenting in the interscapular region, and thus leading to the supposition that the amyloid deposition is a secondary phenomenon when a genetic disposition could not be observed [21].

A systemic involvement of amyloidosis should be excluded by a laboratory work-up. While many topical, systemic, and surgical treatment modalities for PLCA have been described, only a few minor clinical trials have been performed to date. The lack of treatment standards for PLCA and the unsuccessful therapies are underlined by the absence of European and national guidelines. The central aim of this review is to outline and summarize the reported treatment options for PLCA.

2 Materials and Methods

According to the Preferred Reporting Items for Systematic Reviews guidelines, we performed a systematic review using the MEDLINE (PubMed) database with the following research criteria: a: [‘cutaneous (localized OR localised) AND amyloidosis AND (treatment OR therapy)’]. Our search was limited to human-subject reports published between 1 January, 1985 and 24 July, 2016. A total of 62 articles was identified from this search, and a further 34 articles from a manual review of reference lists were included. Six of these were excluded because they were reviews and 20 publications were ruled out because of absent or imprecisely described treatment modalities or clinical outcomes. Seventy articles were deemed appropriate for inclusion in this review (Fig. 2). For each publication included, we recorded the author, study year, study design, localization, number of treated patients, therapies, and outcomes (Table 1).

3 Results

Throughout the medical specialist literature, reports on PLCA treatment are limited to case reports, retrospective case series, and minor studies of patients treated without a control group. A wide range of treatment options are reported, encompassing topical and systemic agents, phototherapy, laser therapy, and surgical interventions.

3.1 Topical and Systemic Retinoids

Retinoids have been used for disorders of keratinization because of their advantageous effects on epidermal proliferation, desquamation, and inflammation of the skin. They are known to induce apoptosis and to stimulate macrophages, resulting in the removal of redundant extracellular material [22]. Retinoids can be applied as topical and systemic agents. Systemic retinoid treatment was reported for LA and BA only, and it has been used in ten case series and case reports. In LA, positive clinical results have been demonstrated, referring to decreased pruritus and flattening of the papules [23–30], except in a single case report on the use of etretinate [31]. The authors described typical side effects of retinoids, namely dry lips and eyes, generalized xerosis, burning sensations, and elevated serum cholesterol. Additionally, etretinate elevated liver enzymes. Treatment with oral acitretin led to satisfactory results, but to residual hyperpigmentation in

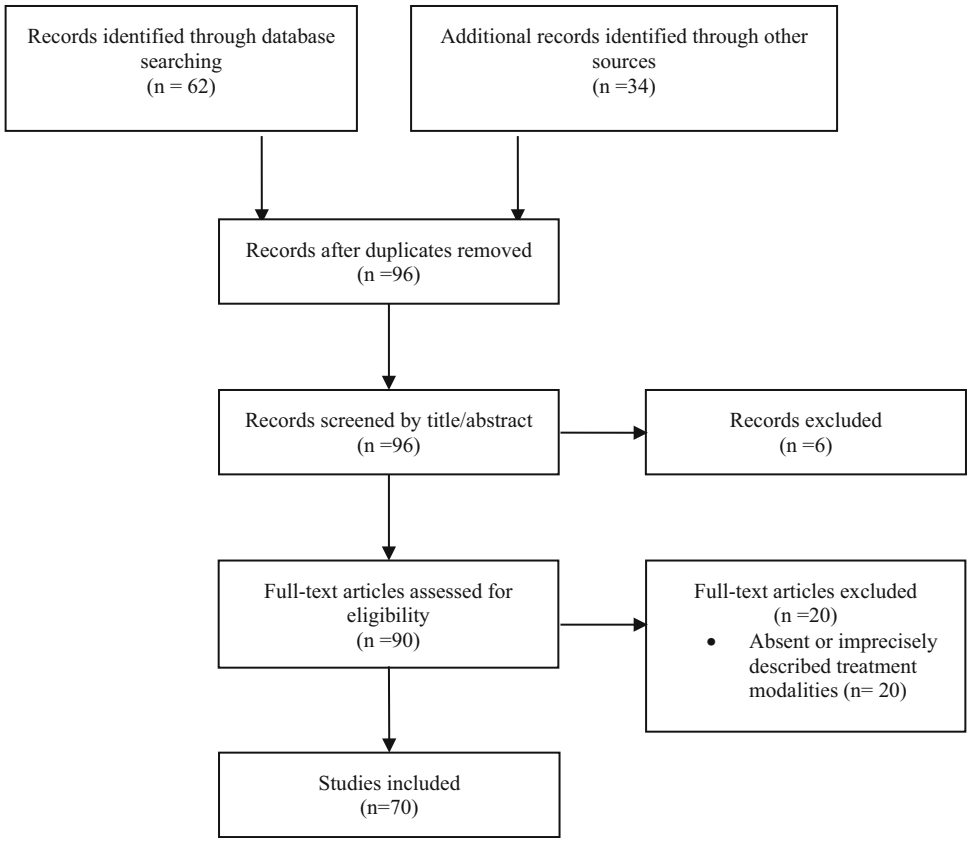

Fig. 2 Identified articles and study selection process

BA [32]. Topical application of tretinoin tocoferil, a synthetic esterified compound of tocopherol and retinoic acid, was reported to result in mixed outcomes varying between 'very good and no response' in a prospective clinical trial including ten patients with LA and MA [33]. Tazarotene in a single case report of MA was without positive clinical effects [34]; in a case report on the use of tretinoin, little relief of pruritus occurred [35].

3.2 Topical Vitamin D_3 Analogs

Vitamin D_3 analogs are known to modulate keratinocyte differentiation and proliferation as well as inflammation [36]. A single double-blind, right–left comparison study on 16 patients with LA showed beneficial effects of topical calcipotriol, but there was no significant difference to betamethasone 17-valerate. Three patients reported a mild degree of redness and scaling while treated with calcipotriol [37].

3.3 Immunosuppressive Agents

3.3.1 Cyclophosphamide

An excellent outcome has been found with oral application of the immunosuppressive alkylating drug cyclophosphamide in pulse treatment combined with systemic corticosteroids in LA [38] and NA [39]. A clinical trial with 36 patients using cyclophosphamide showed a good response to itching, the size of lesions, and hyperpigmentation in PLCA [40]. Observed side effects were diffuse alopecia in 11% of patients.

3.3.2 Corticosteroids

Topical corticosteroids are the gold standard treatment for many inflammatory skin diseases owing to their anti-inflammatory effect via interaction with the intracellular glucocorticoid receptor and the induction of specific genes encoding signaling proteins with an immunosuppressive and anti-proliferative efficacy spectrum. Corticosteroids were used as a regimen with no benefit in MA [17] and in comparison studies with contrary results, as mentioned in Sects. 3.2 [37] and 3.12 [41].

3.3.3 Cyclosporine and Tacrolimus

As a result of the inhibition of calcineurin phosphatase and the subsequently reduced IL-2 production, cyclosporine and tacrolimus might work in PLCA. Cyclosporine has been successfully used in three case reports [42–44] and in a combined regimen with narrow-band ultraviolet B (UVB) treatment in patients with LA with atopic dermatitis

Table 1 Study characteristics

References	Study type	Type of amyloidosis	Localization	No. of subjects	Treatment	Outcome (follow-up time)
Topical and systemic retinoids						
Atacan et al. [23]	Case report	LA	Upper extremities, abdomen, back	1	Oral isotretinoin 30 mg/day for 3 months	Lesions and dyspigmentation almost totally cleared
Carlesimo et al. [24]	Case report	LA	–	1	Oral acitretin	Good improvement of lesions. Complete resolution of pruritus (8 months)
Choi et al. [25]	Case series	LA	Generalized	1	Oral acitretin 10–25 mg/day for 2 months	Relief from pruritus. Flattening of hyperkeratotic papules. Establishing symptom control
David et al. [26]	Case report	LA	Limbs	1	Oral etretinate 60 mg/day for 9 months	Almost complete remission
Helander et al. [27]	Case series	LA	–	4	Oral etretinate 40–60 mg/day up to 20 weeks	Relief of itching. Lesions completely cleared. No amyloid material in repeated biopsies. No immediate relapses after discontinuation
Marschalkó et al. [28]	Case series	LA	–	2	Oral etretinate	Relief of pruritus. Lesions flattened
Reider et al. [29]	Case report	LA	Thighs, forearms, lumbosacral area	1	Oral acitretin 30 mg/day for 3 months	Lesions almost completely cleared. Repeated biopsy: normal skin (6 months). No relapse (3 years)
Tietze et al. [30]	Case report	LA	Generalized	1	Oral alitretinoin 30 mg/day for 6 months	Improvement of pruritus and lesions
Aram [31]	Case report	LA	Lower trunk, legs	1	Oral etretinate 50 mg/day for 1 month	Lack of effect
Hernandez-Nunez [32]	Case report	BA	Limbs	1	Oral acitretin 35 mg/day for 6 months	Disappearance of pruritus. Lesions progressively disappeared almost completely. Papules became flattened
Terao et al. [33]	Prospective clinical trial	LA MA	–	10	Topical tocoretinate 2/day for 10 weeks	3/10 very good response 2/10 good response 3/10 moderate responses 2/10 no responses. 4/10 recurrence after discontinuation
Rados et al. [34]	Case report	MA	Scapular region	1	Topical tazarotene for 3 months	Lesion looked unchanged. Alleviation of pruritus (3 months)
De Argilla et al. [35]	Case report	MA	Back	1	Medium- and high-potency topical corticosteroids for 6 months, then topical 0.5% tretinoin for 3 months	Small relief of pruritus
					Topical 0.025% capsaicin cream 2/day for 6 weeks	No relief of pruritus
Topical vitamin D_3 analogs						
Khoo et al. [37]	Double-blind, right–left comparison pilot study	LA	–	16	Topical calcipotriol 50 µg/g 2/day for 12 weeks	Significant reduction in roughness. Significantly reduced hyperpigmentation. Reduced pruritus
					Topical betamethasone 17-valerate 0.1% 2/day for 12 weeks	Significantly reduced hyperpigmentation. Reduced pruritus

Table 1 continued

References	Study type	Type of amyloidosis	Localization	No. of subjects	Treatment	Outcome (follow-up time)
Cyclosporine						
Behr et al. [42]	Case report	LA	Generalized	1	Oral cyclosporine 300 mg/day for 7 months, then 100 mg/day	Decrease in pruritus. Complete clinical remission (12 months)
Cho et al. [43]	Case report	LA	Generalized	1	Oral cyclosporine 300 mg/day for 1 month	Itching and lesions improved. No recurrence
Teraki [44]	Case report	LA	Legs	1	Oral cyclosporine 5 mg/kg	Pruritic papules gradually resolved
Kang et al. [45]	Case report	LA	Extremities and back	1	Oral cyclosporine 100 mg/day for 5.5 months, then 50 mg/day for 1 month and narrow-band UVB	Nearly complete resolution of lesions and pruritus
Cyclophosphamide						
Gupta et al. [38]	Case report	LA	Legs, arms	1	IV dexamethasone 100 mg for 3 days. Oral cyclophosphamide 500 mg	Completely free from itching with almost no papules. No recurrence (30 months)
Tong et al. [39]	Case report	NA	Feet and calves	1	Cyclophosphamide	Ulcers had healed with no further blistering and stabilization of existing nodules
Das et al. [40]	Prospective clinical trial	MA, LA, BA	–	36	Oral cyclophosphamide 50 mg/day for 6 months	Reduction in itching. Reduction in pigmentation. Size of lesions reduced
Corticosteroids						
Macsween et al. [17]	Case report	MA	Back	1	Topical hydrocortisone butyrate 2/day	Persistence
Topical tacrolimus						
Castanedo-Cazares et al. [47]	Case report	LA	Shin, elbows	1	Topical tacrolimus 0.1% 2/day for 2 months	Resolution of pruritus. Marked improvement in thickness of plaques
Oral colchicine						
Chakravarty [48]	Controlled clinical trial	MA	–	8	Oral colchicine 1 mg/day in 2 divided doses for 90 days	Pruritus disappeared in almost all MA patients Pigmentation almost disappeared
		LA		7		30–60% diminution of pruritus. Pigmentation diminished. 80–90% of papules disappeared
Oral cepharanthine						
Yoshida et al. (2009) [19]	Case report	LA	Upper back	1	Oral cepharanthine 2 mg/day and topical betamethasone valerate ointment for 6 months	Papular lesions became flattened (6 months)
Topical DMSO						
Monfrecola et al. [51]	Case report	LA	–	1	Topical DMSO	Itching improved. Flattening of papules. Repeated biopsy: partial disappearance of amyloid deposits
Pravata et al. [52]	Case report	LA	–	1	Topical DMSO	Lesions improved. Histological examination still showed amyloid deposits
Kobayashi et al. [53]	Case report	LA	Trunk	1	Topical DMSO	No response. Amyloid deposits persisted in histological specimen

Table 1 continued

References	Study type	Type of amyloidosis	Localization	No. of subjects	Treatment	Outcome (follow-up time)
Ozkaya-Bayazit et al. [54]	Prospective controlled clinical trial	LA MA BA	–	2 5 6	Topical DMSO	Disappearance of pruritus. >70% flattening of papules. 50% remission in pigmentation
Pandhi et al. [55]	Prospective clinical trial	MA, LA, BA	–	25	Topical DMSO	Pruritus decreased in 17/25. Lightening of hyperpigmentation in 6/25. No changes in amyloid deposits in post-treatment biopsies. Relapse rate 100%
Topical capsaicin						
Zeidler et al. [57]	Case series	LA	Lower limbs	2	Capsaicin 8% patch for 60 min	Reduction in pruritus. Lesions improved clinically and histologically (12 weeks)
Topical menthol						
Frolich et al. [59]	Case report	LA	Upper back	1	Topical menthol 2% cream 2/day in a combination preparation with 10% urea for 1 year	Lesions improved significantly. Free of pruritus
Hydrocolloid dressings						
Hallel-Halevy [60]	Case report	LA	Limbs	1	Hydrocolloid dressings changed every 2–3 weeks	Improvement of pruritus and cosmetic appearance
Oral amitriptyline						
Yew et al. [63]	Case series	LA	Shins Shins, arms	2	Oral amitriptyline 10 mg/day for 6 weeks	Resolution of itch No difference in lesions Marked reduction in itching No difference in lesions
Laser treatments						
Norisugi et al. [66]	Case series	LA	Shins, arms Legs	2	CO_2 laser 2/month for 6 months	Papules had flattened. Improvement of severe itching
Esmat et al. [67]	Randomized comparative single-blind clinical trial	MA LA	–	16 9	Fractional CO_2 laser, 4 sessions	Significant reduction in pigmentation, thickness, itching, and amyloid deposits
Truhan et al. [68]	Case report	NA	Scalp	1	CO_2 laser	Cosmetically acceptable result with atrophic epidermis. Repeat biopsy: presence of amyloid. New lesion occurred (9 months)
Lesiak et al. [69]	Case report	NA	Trunk and extremities	1	CO_2 laser	Clinical improvement of all treated areas with presence of atrophic scars
Kakani [70]	Case report	NA	Nose	1	Surgical excision followed by dermabrasion and CO_2 laser	Excellent result. No recurrence (10 months)
Ritchie et al. [71]	Case report	NA	Feet	1	Curettage and CO_2 laser	Effective and prevented recurrence of lesions
Panchaprateep et al. [72]	Prospective controlled clinical trial	LA	–	10	Ytterbium/erbium laser, 3 sessions	Itching symptom significantly improved. Repeated biopsy: decreased epidermal thickness and shrinkage of amyloid deposition. Partial recurrence in 2/10

Table 1 continued

References	Study type	Type of amyloidosis	Localization	No. of subjects	Treatment	Outcome (follow-up time)
Barsky et al. [73]	Case report	MA	Upper back	1	Pulsed dye laser, 3 sessions	Improvement with the lightening of the brown macules
Sawamura et al. [74]	Case report	LA	Shins, arms	1	Pulsed dye laser, 2 sessions	Itching drastically decreased. Papules became smaller and flatter (15 months)
Alster et al. [75]	Case report	NA	Chin and submental space	1	Pulsed dye laser 6- to 8-week time intervals for 6 months	Improvement in lesional color, size, and pliability (6 months)
Anitha et al. [76]	Case report	LA	Legs	1	Erbium:YAG laser, 6 sessions	95% clearance of lesions (6 months)
Ostovari et al. [77]	Prospective controlled clinical trial	MA	–	20	Q-switched Nd:YAG laser 532 nm, 2 sessions Q-switched Nd:YAG laser 1064 nm, 1 session	Effective in reducing degree of pigmentation (532 nm more effective)
Liu et al. [78]	Case report	LA	Limbs	1	Nd:YAG laser, 2–3 sessions	Very good results. No complete clearance
Phototherapy						
Alonso-González et al. [79]	Case report	LA	Generalized	1	Narrow-band UVB	Complete resolution of lesions (4 months)
Oiso et al. [80]	Case report	LA	Generalized	1	Narrow-band UVB Topical corticosteroids. Oral olopatadine hydrochloride 10 mg/day	Complete resolution of lesions (4 weeks)
Parsi et al. [81]	Case report	LA	Generalized	1	Narrow-band UVB	Marked improvement of pruritus. Clearing of amyloid deposits
Kalkan [82]	Case report	BA	Generalized	1	Topical tacrolimus ointment and narrow-band UVB	Remission of pruritus and flattening of papules Hyperpigmentation decreased
Hudson [83]	Case report	MA	–	1	UVB	Successful management of pruritus
Grimmer et al. [84]	Case series	LA	Generalized	1	Bath psoralen plus UVA. Oral acitretin	Itching decreased dramatically. Papules gradually resolved
			Lower legs	1		Resolution of skin papules. Impressive relief of pruritus
Tran et al. [85]	Retrospective study	LA	–	3	Bath psoralen plus UVA	Poor response
Jin et al. [41]	Prospective left–right comparative study	LA	–	9	UVB	Advantage over psoralen plus UVA for reducing skin roughness
				5	Topical psoralen plus UVA	More improvement in itching with psoralen plus UVA compared with UVB
				11	Topical corticosteroids	More improvement on phototherapy-treated sides in itching and roughness
Soler-Carrillo et al. [86]	Case report	LA	Generalized	1	Psoralen plus UVA. Discontinuation of intake of dietary supplements	Itching stopped. Clearance of lichenification. Reduced hyperpigmentation
Transcutaneous electrical nerve stimulation						
Yuksek et al. [88]	Prospective clinical trial	MA	–	8	Transcutaneous electrical nerve stimulation	Relief of pruritus (4 weeks)

Table 1 continued

References	Study type	Type of amyloidosis	Localization	No. of subjects	Treatment	Outcome (follow-up time)
Surgical interventions						
Schucht et al. [101]	Case report	NA	Temple region	1	Curettage	Complete clearance
Haverkamp et al. [102]	Case report	NA	Head	1	Curettage	Complete clearance (1 year)
Yong et al. [89]	Case report	NA	Oral commissure	1	Curettage and cautery	Complete clearance (1 year)
Fujisawa et al. [90]	Case report	NA	Left cheek	1	Surgical excision	No recurrence
Lien et al. [91]	Case report	NA	Chin	1	Shave excision followed by dermabrasion	No recurrence. Atrophic scar remained (26 months)
Okazaki et al. [92]	Case report	NA	Upper lip	1	Surgical excision	No recurrence (1 year)
Ueno et al. [93]	Case report	NA	Chin	1	Surgical excision covered by full-thickness skin graft	No recurrence
Vestey et al. [94]	Case report	NA	Nose	1	Cryotherapy	Unhelpful, minor hemorrhage
					Curettage followed by cautery	Satisfactory result
Aoki et al. [95]	Case report	LA	Ear	1	Electrodessication	Lesions were completely cleared (6 months)
Haharap et al. [96]	Case series	LA	–	9	Surgical scraping with scalpel	All patients were free of itching. 4/9 good results. 5/9 acceptable results (1 year)
Savant [97]	Case report	LA	Shins	1	Dermabrasion	Pruritus stopped. No recurrence (1.5 years)
Mun et al. [98]	Case report	PLCA	Eyelid	1	Surgical excision	Lesion recurred 6 months later
Santos-Briz et al. [99]	Case report	Primary, cutaneous localized amyloid elastosis	Axilla	1	Surgical excision. Local radiotherapy	No recurrence (1 year)
Sangen et al. [100]	Case report	LA (and thyroid papillary carcinoma)	Neck, upper back	1	Thyroidectomy of the right lobe	Skin lesions markedly improved

BA biphasic amyloidosis, CO_2 carbon dioxide, *DMSO* dimethyl sulfoxide, *IV* intravenous, *LA* lichen amyloidosis, *MA* macular amyloidosis, *NA* nodular amyloidosis, *Nd:YAG* neodymium-doped yttrium aluminum garnet, *PLCA* primary localized cutaneous amyloidosis, *UVA* ultraviolet A, UVB ultraviolet B

coincidentally [45]. It is postulated that reduced itching, owing to the inhibition of the production of proinflammatory cytokines (e.g., IL-2), may have a positive influence on LA. Increased blood pressure as a side effect has been reported [42].

The mechanism of tacrolimus inhibiting calcineurin interrupts the gene expression of cytokines and as a result decreases T-cell activity and inflammation [46]. One case report observed a significant improvement of skin lesions and reduced pruritus in LA after application of topical tacrolimus [47]. A supportive use of tacrolimus in UVB therapy is mentioned in Sect. 3.12.

3.4 Colchicine

Colchicine was applied to 15 patients (MA and LA) in a clinical trial for 90 days. The author describes a beneficial effect on itching, hyperpigmentation, and flattening of the papules. A mild hyperpigmentation of the lesions remained [48]. No further publication of PLCA and colchicine intake has been published to date. Colchicine binds to microtubules, interferes with the chemotaxis of leukocytes, and stimulates prostaglandin E2 release, which inhibits leukocyte function [49].

3.5 Cepharanthine

Cepharanthine has anti-inflammatory effects as a result of the reduction in radical oxygen species. One case report shows a beneficial outcome in combined use with topical betamethasone in LA [19].

3.6 Dimethyl Sulfoxide

Dimethyl sulfoxide (DMSO) has penetration-enhancing properties and acts as an anti-inflammatory pharmaceutical agent [50]. Beneficial topical application has been described in two case reports of LA. A histological disappearance of amyloid deposition could not be shown [51, 52]. No response to topical DMSO has been observed in a further case report of extensive LA [53]. One trial reported on topical DMSO in patients with LA, MA, and BA ($n = 13$) with positive outcomes, referring to the disappearance of pruritus, flattening of papules, and remission of hyperpigmentation in 50% of the patients [54]. A major study compared 50 and 100% solution of DMSO (topical) with unsatisfactory clinical results for each concentration with a relapse and no changes in amyloid deposits in all patients [55]. The side effects were contact urticaria, desquamation of the skin, and a burning sensation.

3.7 Capsaicin

Capsaicin binds to the transient receptor, potential ion channel vanilloid-1 on cutaneous histamine-sensitive and mechanosensitive C and Aδ fibers. Antiprurigenic effects are achieved by overstimulation of these fibers and a refractory mode setting [56]. In a case series of two patients with LA, impressive results (reduction of the pruritus and improved clinically and histologically skin lesions) were demonstrated by applying a high dose of capsaicin (8% patch) with the suspicion of destroying those special fibers [57]. The authors describe an initial burning sensation and a self-limited erythema as side effects. One patient with MA is mentioned, who received capsaicin cream (0.025%) without achieving a beneficial outcome [35].

3.8 Menthol

Menthol triggers the cold-sensitive, transient receptor, potential cation channel subfamily M member 8 in the skin, leading to cooling sensations. Moreover, there are reasonable grounds for suspecting that menthol reduces pruritus by the selective activation of κ-opioid receptors [58]. An excellent outcome (flattening of papules and almost complete absence of pruritus) could be seen in one case report using topical menthol in LA [59].

3.9 Hydrocolloid Dressings

A case report using hydrocolloid dressings (HDs) in a patient with LA described an improvement in pruritus and 'cosmetic appearance'. The mechanism may be explained as followed: first, HDs may act through a mechanical prevention of scratching [60]. Second, the amyloid deposits in LA originate from the epidermis layer [61]. Moreover, HD application in patients with psoriasis could positively affect the normalization of the epidermis [62]. The authors of this case report recommend HDs as first-line therapy in LA.

3.10 Amitriptyline

A case series of two patients with familial LA using oral amitriptyline showed an impressive reduction in pruritus without any changes of the skin lesions [63]. Amitriptyline is a tricyclic antidepressant, indicated for neuropathic itching [64]. A small-fiber neuropathy plays a major role in the pathogenesis of itching in PLCA, thus amitriptyline may be an effective treatment option for familial LA [13].

3.11 Laser Treatments

Laser therapy has been an efficient treatment modality in many medical publications of PLCA. Side effects included burning sensations, transient erythema, and edema. There was one review by Al Yahya [65] of laser treatments for PLCA.

3.11.1 Carbon Dioxide Laser

The carbon dioxide laser was the most frequently used laser treatment for PLCA. There was one case report showing good clinical outcomes on the flattening of the papules and an improvement in itching in LA [66]. A randomized single-blind clinical trial, which included 16 patients with MA and nine patients with LA, revealed a significant reduction in pigmentation, thickness of the lesions, itching, and amyloid deposits in repeated biopsies after treatment with the carbon dioxide laser [67].

The carbon dioxide laser induced clinical improvement of all treated areas in NA as reported in one case report; and cosmetically acceptable results with the recurrence of skin lesions after 9 months in another reported case of NA. [68] The authors report problems with hemostasis that correlated with amyloid infiltration of the dermis and blood vessels. Atrophic scars occurred post-treatment [69].

The supportive use of surgical excision followed by dermabrasion and carbon dioxide laser [70], and curettage followed by carbon dioxide laser [71] has been described in two case reports of NA, resulting in effective results and no recurrence of lesions.

3.11.2 Ytterbium/Erbium Laser

Ten patients with LA underwent ytterbium/erbium laser treatment in one prospective clinical trial. They revealed an improvement in itching and demonstrated a shrinkage of amyloid deposition in repeated biopsies [72]. The authors also mentioned a burning sensation.

3.11.3 Pulsed Dye Laser

The application of a pulsed dye laser has been recognized as a beneficial treatment regimen in all variants of PLCA. In MA, improvement and lightening of the brown macules could be observed in one single case report [73]. Reduced itching and a flattening of the LA papules was shown in another case report 15 months post-treatment [74]. Lesion color, size, and pliability was improved in one patient with NA [75].

3.11.4 Erbium:Yttrium Aluminum Garnet Laser

A single case report of LA revealed 95% clearance of the lesions after a 6-month follow-up [76].

3.11.5 Neodymium-doped:Yttrium Aluminum Garnet Laser

An effective reduction in the degree of pigmentation was observed using the Q-switch neodymium-doped:yttrium aluminum garnet laser in 20 patients with MA. The authors determined that treatment with 532 nm was more efficient than 1064 nm [77]. Very good results without clearance of LA skin lesions have been described in another case report. A cellulitis occurred in one patient after laser therapy [78].

3.12 Phototherapy

Different phototherapeutic modalities, especially for chronic inflammatory skin diseases, are available and offer a safe and controlled treatment option but require a continuous therapy over a long period. Narrow-band UVB irradiation led to complete resolution of LA lesions in one case report [79]; complete resolution of a generalized LA lesion in another patient treated with topical corticosteroids and oral olopatadine [80]; a marked improvement of itching and clearing of the amyloid deposits in a repeated biopsy in a patient with generalized LA [81]; remission of pruritus, decreased hyperpigmentation, and flattening of the papules in patient with BA who received topical tacrolimus additively [82]; and successful management of pruritus in a patient with MA receiving UVB therapy [83].

In patients with PLCA, topical psoralen with ultraviolet A (PUVA) was used in all documented cases. The additional intake of acitretin in one case series of two patients with LA treated with bath PUVA, revealed an efficient reduction in pruritus and an impressive resolution of the papules [84]. A disappointing clinical outcome was described in a case series of three patients with LA who applied bath PUVA. The authors report modest effects and a persistence of the skin lesions in more than 50% [85]. There is a small, prospective left–right comparative study of LA, which included nine patients treated with UVB, five treated with PUVA, and 11 treated with topical corticosteroids. Ultraviolet B treatment was more advantageous with regard to decreased skin roughness compared with UVB irradiation. However, PUVA therapy showed a better improvement in itching compared with PUVA treatment. Topical corticosteroids were inferior to the phototherapeutic treatments, which were applied inversely. Reported side effects include hyperpigmentation after PUVA therapy and increased itching in one patient after UVB irradiation [41]. Clearance of lichenification, resolution of itching, and reduced hyperpigmentation were described using PUVA therapy and discontinuing several dietary supplements in generalized LA [86].

3.13 Transcutaneous Nerve Stimulation

The exact mode of antipruritic action of transcutaneous nerve stimulation is not fully understood. One putative

mechanism is a peripheral nociceptive influence of an electrical current on itching and pain fibers [87]. Relief of pruritus in eight patients with MA receiving transcutaneous nerve stimulation therapy was described in one single published trial [88].

3.14 Surgical Interventions

Surgical excision was performed in several case reports in NA [89–94], leading to complete clearance without recurrence of skin lesions. An atrophic scar remained in one report [91]. Surgical interventions in LA were reported as electrodesiccation [95], a special technique 'scraping with the scalpel' [96], and dermabrasion [97]. Both case reports lead to complete clearance of LA lesions without recurrence [95, 97]. The patient treated with dermabrasion experienced delayed wound healing, superficial scarring, hypopigmentation, and a transient edema. A case series of nine patients with LA developed a new technique: 'scraping with the scalpel', resulting in a disappearance of pruritus and heterogeneous effects on clinical presentation (44.5% with 'good results', 55.5% with 'acceptable results'). Persistent pigment changes were side effects of this approach.

One case report of PLCA of the eyelid treated by surgery exists. The tumor could not be further classified and recurred 6 months post-treatment [98]. A case of primary localized cutaneous amyloid elastosis healed by surgical excision and local radiotherapy subsequently showed no recurrence after a 1-year follow-up [99]. In a single reported case of LA associated with thyroid papillary carcinoma, skin lesions improved markedly after the underlying tumor was removed [100]. Curettage led to complete healing in two cases of NA [101, 102].

As mentioned above (Sect. 3.11.1), the supportive use of surgical excision followed by dermabrasion and carbon dioxide laser [70] and curettage followed by carbon dioxide laser [71] has been described in two case reports of NA, resulting in effective results and preventing the recurrence of lesions.

3.15 Cryotherapy

One approach using cryotherapy in NA was described as 'unhelpful' and was complicated by a minor hemorrhage [94].

4 Discussion

Treatment of PLCA represents a complex challenge for physicians, as no guidelines exist regarding an evidence-based therapy regimen. Based on this current review, we conclude there are a large variety of therapies available for PLCA subtypes.

4.1 Lichen Amyloidosis, Macular Amyloidosis, and Mixed Amyloidosis

The treatment of LA, MA, and BA should refer to the striking symptoms and the patient's needs. For LA and MA, the most important issue is the resolution of any underlying disorder that may lead to chronic excoriation of the skin. We determined there were different modalities acting on pruritus and other treatment regimens affecting skin roughness, hyperpigmentation, and itching. Minor trials revealed beneficial outcomes for all symptoms using topical calcipotriol, phototherapy, oral cyclophosphamide, and laser treatments. Topical DMSO was used in many patients but led to several side effects. Neodymium-doped:yttrium aluminum garnet laser treatment resulted in hyperpigmentation responses in a clinical trial of MA [76]. All other treatment regimens are based on case reports and small case series. Physicians must compare side effects, opportunities, and patient's psychological strain to determine an appropriate therapy from the listed options. Furthermore, the size and localization of the skin lesions should influence the choice of treatment.

4.2 Primary Localized Cutaneous Nodular Amyloidosis

Nodular amyloidosis, the rarest form of PCLA, was predominantly excised by surgical interventions following carbon dioxide laser application in most cases. There is one single published case by Tong et al. with underlying CREST and Sjögren syndrome treated successfully with systemically cyclophosphamide, which is used in the treatment of systemic amyloidosis [103]. Surgical removal should be the goal because of the potential infiltration in subcutaneous tissue and blood vessels and progress to systemic disease [8, 9]. This is underlined by Vestey et al., who reported a hemorrhage after cryotherapy of a NA lesion. Therefore, physicians have to consider bleeding complications and use preventative techniques such as cauterization or a carbon dioxide laser, and also consider the putative persistence of amyloids in the dermis that can lead to recurrences.

5 Conclusions

No definitive recommendation on preferable treatment procedures for PLCA can be based on the present literature. Patients should be well informed that offered treatment modalities are not based on clinical studies, but on case reports and expert judgment. Randomized controlled trials

are needed to offer patients an evidence-based therapy with high-quality standardized treatment regimens for PLCA. Because of the rarity of the condition, this will probably require multicenter and possibly even internationally coordinated studies. Interleukin-31 antibodies, as a novel antipruritic medication, may offer a new approach in the treatment of PCLA in the future.

Compliance with Ethical Standards

Funding No sources of funding were received for the preparation of this article.

Conflict of interest T Weidner, T. Illing, and P. Elsner have no conflicts of interest directly relevant to the content of this article.

References

1. Fernandez-Flores A. Cutaneous amyloidosis: a concept review. Am J Dermatopathol. 2012;34(1):1–14 **(quiz 5–7)**. doi:10.1097/DAD.0b013e31823465c7.
2. Brownstein MH, Hashimoto K, Greenwald G. Biphasic amyloidosis: link between macular and lichenoid forms. Arch Dermatol. 1972;106(3):419.
3. Ollague W. Primary cutaneous amyloidosis. Int J Dermatol. 1987;26(2):135.
4. Breathnach SM. Amyloid and amyloidosis. J Am Acad Dermatol. 1988;18(1 Pt 1):1–16.
5. Huilgol SC, Ramnarain N, Carrington P, et al. Cytokeratins in primary cutaneous amyloidosis. Australas J Dermatol. 1998;39(2):81–5.
6. Brownstein MH, Hashimoto K. Macular amyloidosis. Arch Dermatol. 1972;106(1):50–7.
7. Ramirez-Santos A, Labandeira J, Monteagudo B, Toribio J. Lichen amyloidosus without itching indicates that it is not secondary to chronic scratching. Acta Derm Venereol. 2006;86(6):561–2. doi:10.2340/00015555-0155.
8. Schreml S, Szeimies RM, Vogt T, et al. Cutaneous amyloidoses and systemic amyloidoses with cutaneous involvement. Eur J Dermatol. 2010;20(2):152–60. doi:10.1684/ejd.2010.0842.
9. Woollons A, Black MM. Nodular localized primary cutaneous amyloidosis: a long-term follow-up study. Br J Dermatol. 2001;145(1):105–9.
10. Ollague W, Ollague J, Ferretti H. Epidemiology of primary cutaneous amyloidoses in South America. Clin Dermatol. 1990;8(2):25–9.
11. McDonald RR, Georgouras KE. Skin disorders in Indo-Chinese immigrants. Med J Aust. 1992;157(4):288.
12. Tan T. Epidemiology of primary cutaneous amyloidoses in southeast Asia. Clin Dermatol. 1990;8(2):20–4.
13. Tanaka A, Arita K, Lai-Cheong JE, et al. New insight into mechanisms of pruritus from molecular studies on familial primary localized cutaneous amyloidosis. Br J Dermatol. 2009;161(6):1217–24. doi:10.1111/j.1365-2133.2009.09311.x.
14. Tey HL, Yosipovitch G. Itch in ethnic populations. Acta Derm Venereol. 2010;90(3):227–34. doi:10.2340/00015555-0867.
15. Lin MW, Lee DD, Liu TT, et al. Novel IL31RA gene mutation and ancestral OSMR mutant allele in familial primary cutaneous amyloidosis. Eur J Hum Genet. 2010;18(1):26–32. doi:10.1038/ejhg.2009.135.
16. Hashimoto K, Ito K, Kumakiri M, Headington J. Nylon brush macular amyloidosis. Arch Dermatol. 1987;123(5):633–7.
17. Macsween RM, Saihan EM. Nylon cloth macular amyloidosis. Clin Exp Dermatol. 1997;22(1):28–9.
18. Somani VK, Hari S, Sita VN, Razvi F. Nylon friction dermatitis: a distinct subset of macular amyloidosis. Indian J Dermatol Venereol Leprol. 1995;61(3):145–7.
19. Yoshida A, Takahashi K, Tagami H, Akasaka T. Lichen amyloidosis induced on the upper back by long-term friction with a nylon towel. J Dermatol. 2009;36(1):56–9. doi:10.1111/j.1346-8138.2008.00586.x.
20. Venkataram MN, Bhushnurmath SR, Muirhead DE, Al-Suwaid AR. Frictional amyloidosis: a study of 10 cases. Australas J Dermatol. 2001;42(3):176–9.
21. Verga U, Fugazzola L, Cambiaghi S, et al. Frequent association between MEN 2A and cutaneous lichen amyloidosis. Clin Endocrinol. 2003;59(2):156–61.
22. Fritsch PO. Retinoids in psoriasis and disorders of keratinization. J Am Acad Dermatol. 1992;27(6 Pt 2):S8–14.
23. Atacan D, Ergin C, Celik G, et al. Oral isotretinoin: a new treatment alternative for generalized lichen amyloidosis. Australas J Dermatol. 2016;57(3):246–7. doi:10.1111/ajd.12316.
24. Carlesimo M, Narcisi A, Orsini D, et al. A case of lichen amyloidosus treated with acitretin. Clin Ter. 2011;162(2):e59–61.
25. Choi JY, Sippe J, Lee S. Acitretin for lichen amyloidosus. Australas J Dermatol. 2008;49(2):109–13. doi:10.1111/j.1440-0960.2008.00434.x.
26. David M, Ingber A, Ben-Chetrit A, et al. Effect of etretinate on lichen amyloidosus. Dermatologica. 1987;175(6):302–3.
27. Helander I, Hopsu-Havu VK. Treatment of lichen amyloidosus by etretinate. Clin Exp Dermatol. 1986;11(6):574–8.
28. Marschalko M, Daroczy J, Soos G. Etretinate for the treatment of lichen amyloidosis. Arch Dermatol. 1988;124(5):657–9.
29. Reider N, Sepp N, Fritsch P. Remission of lichen amyloidosus after treatment with acitretin. Dermatology. 1997;194(3):309–11.
30. Tietze JK, Heppt MV, Flaig MJ, Thomas P. Successful treatment of lichen amyloidosus with oral alitretinoin. J Eur Acad Dermatol Venereol. 2016;30(5):884–5. doi:10.1111/jdv.13048.
31. Aram H. Failure of etretinate (RO 10-9359) in lichen amyloidosus. Int J Dermatol. 1986;25(3):206.
32. Hernandez-Nunez A, Dauden E, Moreno de Vega MJ, et al. Widespread biphasic amyloidosis: response to acitretin. Clin Exp Dermatol. 2001;26(3):256–9.
33. Terao M, Nishida K, Murota H, Katayama I. Clinical effect of tocoretinate on lichen and macular amyloidosis. J Dermatol. 2011;38(2):179–84. doi:10.1111/j.1346-8138.2010.00962.x.
34. Rados J, Marinovic Kulisic S, Lipozencic J, et al. Macular amyloidosis: a case report. Acta Dermatovenerol Croat. 2008;16(3):138–41.
35. de Argila D, Ortiz-Romero PL, Ortiz-Frutos J, et al. Cutaneous macular amyloidosis associated with multiple endocrine neoplasia 2A. Clin Exp Dermatol. 1996;21(4):313–4.
36. Parish JL. Topical vitamin D3 analogues: unapproved uses, dosages, or indications. Clin Dermatol. 2002;20(5):558–62.
37. Khoo BP, Tay YK, Goh CL. Calcipotriol ointment vs. betamethasone 17-valerate ointment in the treatment of lichen amyloidosis. Int J Dermatol. 1999;38(7):539–41.
38. Gupta R, Gupta S. Dexamethasone cyclophosphamide pulse therapy in lichen amyloidosus: a case report. J Dermatol Treat. 2007;18(4):249–51. doi:10.1080/09546630701271799.
39. Tong PL, Walker WA, Glancy RJ, et al. Primary localized cutaneous nodular amyloidosis successfully treated with cyclophosphamide. Australas J Dermatol. 2013;54(1):e12–5. doi:10.1111/j.1440-0960.2011.00770.x.
40. Das J, Gogoi RK. Treatment of primary localised cutaneous amyloidosis with cyclophosphamide. Indian J Dermatol Venereol Leprol. 2003;69(2):163–4.

41. Jin AG, Por A, Wee LK, et al. Comparative study of phototherapy (UVB) vs. photochemotherapy (PUVA) vs. topical steroids in the treatment of primary cutaneous lichen amyloidosis. Photodermatol Photoimmunol Photomed. 2001;17(1):42–3.
42. Behr FD, Levine N, Bangert J. Lichen amyloidosis associated with atopic dermatitis: clinical resolution with cyclosporine. Arch Dermatol. 2001;137(5):553–5.
43. Cho TH, Lee MH. A case of lichen amyloidosus accompanied by vesicles and dyschromia. Clin Exp Dermatol. 2008;33(3):291–3. doi:10.1111/j.1365-2230.2007.02653.x.
44. Teraki Y, Katsuta M, Shiohara T. Lichen amyloidosus associated with Kimura's disease: successful treatment with cyclosporine. Dermatology. 2002;204(2):133–5. doi:10.1159/000051831.
45. Kang MJ, Kim HS, Kim HO, Park YM. A case of atopic dermatitis-associated lichen amyloidosis successfully treated with oral cyclosporine and narrow band UVB therapy in succession. J Dermatol Treat. 2009;20(6):368–70. doi:10.3109/09546630802691325.
46. Simpson D, Noble S. Tacrolimus ointment: a review of its use in atopic dermatitis and its clinical potential in other inflammatory skin conditions. Drugs. 2005;65(6):827–58.
47. Castanedo-Cazares JP, Lepe V, Moncada B. Lichen amyloidosis improved by 0.1% topical tacrolimus. Dermatology. 2002;205(4):420–1. doi:10.1159/000066426.
48. Chakravarty K, Chanda M. Role of colchicine in primary localised cutaneous amyloidosis. Indian J Dermatol Venereol Leprol. 1995;61(5):268–9.
49. Schattner A. Colchicine: expanding horizons. Postgrad Med J. 1991;67(785):223–6.
50. Capriotti K, Capriotti JA. Dimethyl sulfoxide: history, chemistry, and clinical utility in dermatology. J Clin Aesthet Dermatol. 2012;5(9):24–6.
51. Monfrecola G, Iandoli R, Bruno G, Martellotta D. Lichen amyloidosus: a new therapeutic approach. Acta Derm Venereol. 1985;65(5):453–5.
52. Pravata G, Pinto G, Bosco M, et al. Unusual localization of lichen amyloidosus: topical treatment with dimethylsulfoxide. Acta Derm Venereol. 1989;69(3):259–60.
53. Kobayashi T, Yamasaki Y, Watanabe T, Onoda N. Extensive lichen amyloidosus refractory to DMSO. J Dermatol. 1995;22(10):755–8.
54. Ozkaya-Bayazit E, Kavak A, Gungor H, Ozarmagan G. Intermittent use of topical dimethyl sulfoxide in macular and papular amyloidosis. Int J Dermatol. 1998;37(12):949–54.
55. Pandhi R, Kaur I, Kumar B. Lack of effect of dimethylsulphoxide in cutaneous amyloidosis. J Dermatol Treat. 2002;13(1):11–4. doi:10.1080/09546630252775180.
56. Bautista DM, Wilson SR, Hoon MA. Why we scratch an itch: the molecules, cells and circuits of itch. Nat Neurosci. 2014;17(2):175–82. doi:10.1038/nn.3619.
57. Zeidler C, Metze D, Stander S. Successful treatment of lichen amyloidosis using capsaicin 8% patch. J Eur Acad Dermatol Venereol. 2016;30(7):1236–8. doi:10.1111/jdv.13165.
58. Galeotti N, Di Cesare Mannelli L, Mazzanti G, et al. Menthol: a natural analgesic compound. Neurosci Lett. 2002;322(3):145–8.
59. Frolich M, Enk A, Diepgen TL, Weisshaar E. Successful treatment of therapy-resistant pruritus in lichen amyloidosis with menthol. Acta Derm Venereol. 2009;89(5):524–6. doi:10.2340/00015555-0725.
60. Hallel-Halevy D, Finkelstein E, Grunwald MH, Halevy S. Lichen amyloidosus treated by hydrocolloid dressings. J Eur Acad Dermatol Venereol. 2004;18(6):691–2. doi:10.1111/j.1468-3083.2004.00940.x.
61. Weyers W, Weyers I, Bonczkowitz M, et al. Lichen amyloidosus: a consequence of scratching. J Am Acad Dermatol. 1997;37(6):923–8.
62. David M, Lowe NJ. Psoriasis therapy: comparative studies with a hydrocolloid dressing, plastic film occlusion, and triamcinolone acetonide cream. J Am Acad Dermatol. 1989;21(3 Pt 1):511–4.
63. Yew YW, Tey HL. Itch in familial lichen amyloidosis: effective treatment with amitriptyline in two cases. Dermatol Ther. 2014;27(1):12–5. doi:10.1111/dth.12023.
64. Gupta MA, Gupta AK. Antidepressant drugs in dermatology. Skin Ther Lett. 2001;6(8):3–5.
65. Al Yahya RS. Treatment of primary cutaneous amyloidosis with laser: a review of the literature. Lasers Med Sci. 2016;31(5):1027–35. doi:10.1007/s10103-016-1917-8.
66. Norisugi O, Yamakoshi T, Shimizu T. Successful treatment of lichen amyloidosis using a CO2 surgical laser. Dermatol Ther. 2014;27(2):71–3. doi:10.1111/dth.12057.
67. Esmat SM, Fawzi MM, Gawdat HI, et al. Efficacy of different modes of fractional CO2 laser in the treatment of primary cutaneous amyloidosis: a randomized clinical trial. Lasers Surg Med. 2015;47(5):388–95. doi:10.1002/lsm.22361.
68. Truhan AP, Garden JM, Roenigk HH Jr. Nodular primary localized cutaneous amyloidosis: immunohistochemical evaluation and treatment with the carbon dioxide laser. J Am Acad Dermatol. 1986;14(6):1058–62.
69. Lesiak A, Rakowski A, Brzezinska A, et al. Effective treatment of nodular amyloidosis with carbon dioxide laser. J Cutan Med Surg. 2012;16(5):372–4.
70. Kakani RS, Goldstein AE, Meisher I, Hoffman C. Nodular amyloidosis: case report and literature review. J Cutan Med Surg. 2001;5(2):101–4. doi:10.1007/s102270000014.
71. Ritchie SA, Beachkofsky T, Schreml S, et al. Primary localized cutaneous nodular amyloidosis of the feet: a case report and review of the literature. Cutis. 2014;93(2):89–94.
72. Panchaprateep R, Tusgate S, Munavalli GS, Noppakun N. Fractional 1,550 nm ytterbium/erbium fiber laser in the treatment of lichen amyloidosis: clinical and histological study. Lasers Surg Med. 2015;47(3):222–30. doi:10.1002/lsm.22338.
73. Barsky M, Buka RL. Pulsed dye laser for the treatment of macular amyloidosis: a case report. Cutis. 2014;93(4):189–92.
74. Sawamura D, Sato-Matsumura KC, Shibaki A, et al. A case of lichen amyloidosis treated with pulsed dye laser. J Eur Acad Dermatol Venereol. 2005;19(2):262–3. doi:10.1111/j.1468-3083.2005.01038.x.
75. Alster TS, Manaloto RM. Nodular amyloidosis treated with a pulsed dye laser. Dermatol Surg. 1999;25(2):133–5.
76. Anitha B, Mysore V. Lichen amyloidosis: novel treatment with fractional ablative 2,940 nm erbium:YAG laser treatment. J Cutan Aesthet Surg. 2012;5(2):141–3. doi:10.4103/0974-2077.99459.
77. Ostovari N, Mohtasham N, Oadras MS, Malekzad F. 532-nm and 1064-nm Q-switched Nd:YAG laser therapy for reduction of pigmentation in macular amyloidosis patches. J Eur Acad Dermatol Venereol. 2008;22(4):442–6. doi:10.1111/j.1468-3083.2007.02473.x.
78. Liu HT. Treatment of lichen amyloidosis (LA) and disseminated superficial porokeratosis (DSP) with frequency-doubled Q-switched Nd:YAG laser. Dermatol Surg. 2000;26(10):958–62.
79. Alonso-Gonzalez J, Rodriguez-Granados MT, Toribio J. Satisfactory response to narrowband UV-B therapy in generalized lichen amyloidosis. Actas Dermsifiliogr. 2013;104(6):527–9. doi:10.1016/j.ad.2012.07.014.
80. Oiso N, Yudate T, Kawara S, Kawada A. Successful treatment of lichen amyloidosus associated with atopic dermatitis using a combination of narrowband ultraviolet B phototherapy, topical corticosteroids and an antihistamine. Clin Exp Dermatol. 2009;34(8):e833–6. doi:10.1111/j.1365-2230.2009.03574.x.
81. Parsi K, Kossard S. Thermosensitive lichen amyloidosis. Int J Dermatol. 2004;43(12):925–8. doi:10.1111/j.1365-4632.2004.02273.x.

82. Kalkan G, Markoc F, Bas Y. An alternative treatment model: the combination therapy of narrow band ultraviolet B phototherapy and tacrolimus ointment 0.1% in biphasic amyloidosis. J Pak Med Assoc. 2014;64(5):579–82.
83. Hudson LD. Macular amyloidosis: treatment with ultraviolet B. Cutis. 1986;38(1):61–2.
84. Grimmer J, Weiss T, Weber L, et al. Successful treatment of lichen amyloidosis with combined bath PUVA photochemotherapy and oral acitretin. Clin Exp Dermatol. 2007;32(1):39–42. doi:10.1111/j.1365-2230.2006.02244.x.
85. Tran D, Kwok YK, Goh CL. A retrospective review of PUVA therapy at the National Skin Centre of Singapore. Photodermatol Photoimmunol Photomed. 2001;17(4):164–7.
86. Soler-Carrillo J, Alsina-Gibert MM, Mascaro JM. Lichen amyloidosus universalis associated with long-term drug intake. Dermatology. 1997;195(3):286–8.
87. Engin B, Tufekci O, Yazici A, Ozdemir M. The effect of transcutaneous electrical nerve stimulation in the treatment of lichen simplex: a prospective study. Clin Exp Dermatol. 2009;34(3):324–8. doi:10.1111/j.1365-2230.2008.03086.x.
88. Yuksek J, Sezer E, Aksu M, Erkokmaz U. Transcutaneous electrical nerve stimulation for reduction of pruritus in macular amyloidosis and lichen simplex. J Dermatol. 2011;38(6):546–52. doi:10.1111/j.1346-8138.2010.01081.x.
89. Yong AS, Murphy JG, Shah N. Nodular localized cutaneous amyloidosis in an immunosuppressed patient. Int J Dermatol. 2015;54(6):708–9. doi:10.1111/ijd.12140.
90. Fujisawa T, Shu E, Ikeda T, Seishima M. Primary localized cutaneous nodular amyloidosis that appeared in a patient with severe atopic dermatitis. J Dermatol. 2012;39(3):312–3. doi:10.1111/j.1346-8138.2011.01247.x.
91. Lien MH, Railan D, Nelson BR. The efficacy of dermabrasion in the treatment of nodular amyloidosis. J Am Acad Dermatol. 1997;36(2 Pt 2):315–6.
92. Okazaki M, Hisatomi T, Sarukawa S. Aesthetic upper lip reconstruction with vermilion submucosal-pedicle cross-lip flap. J Craniofacial Surg. 2006;17(6):1259–62. doi:10.1097/01.scs.0000246737.99718.87.
93. Ueno M, Yamamoto T, Yamanaka M, Matsunaga T. Nodular amyloidosis in a patient with liver cirrhosis. Dermatol Online J. 2011;17(7):10.
94. Vestey JP, Tidman MJ, McLaren KM. Primary nodular cutaneous amyloidosis: long-term follow-up and treatment. Clin Exp Dermatol. 1994;19(2):159–62.
95. Aoki M, Kawana S. Lichen amyloidosis of the auricular concha: successful treatment with electrodesiccation. J Dermatol. 2009;36(2):116–7. doi:10.1111/j.1346-8138.2009.00603.x.
96. Harahap M, Marwali MR. The treatment of lichen amyloidosis: a review and a new technique. Dermatol Surg. 1998;24(2):251–4.
97. Savant SS. Therapeutic regional dermabrasion in papular lichen amyloidosis of shins. Indian J Dermatol Venereol Leprol. 1995;61(4):196–201.
98. Mun KS, Pailoor J, Reddy SC. Primary localised deep cutaneous amyloidosis of the eyelid. Malays J Pathol. 2005;27(2):113–5.
99. Santos-Briz A, Canueto J, Antunez P, et al. Primary cutaneous localized amyloid elastosis. Am J Dermatopathol. 2010;32(1):86–90. doi:10.1097/DAD.0b013e3181b1c62f.
100. Sangen Y, Kawada A, Maeda A, et al. Primary localized cutaneous amyloidosis in association with papillary thyroid carcinoma. J Cutan Med Surg. 2002;6(4):332–4. doi:10.1007/s10227-001-0052-7.
101. Schucht K, Schroder J, Siegmund H, et al. Nodular cutaneous amyloidosis at the temple. Case Rep Dermatol. 2016;8(2):193–6. doi:10.1159/000447234.
102. Haverkampf S, Evert K, Schroder J, Schreml S. Nodular cutaneous amyloidosis resembling a giant tumor. Case Rep Dermatol. 2016;8(1):22–5. doi:10.1159/000443950.
103. Wechalekar AD, Goodman HJ, Lachmann HJ, et al. Safety and efficacy of risk-adapted cyclophosphamide, thalidomide, and dexamethasone in systemic AL amyloidosis. Blood. 2007;109(2):457–64. doi:10.1182/blood-2006-07-035352.