Received: 20 July 2017 | Revised: 28 September 2017 | Accepted: 2 October 2017

DOI: 10.1111/dth.12568

REVIEW ARTICLE

WILEY DERMATOLOGIC THERAPY

Effectiveness and safety of polidocanol for the treatment of hemangiomas and vascular malformations: A meta-analysis

Zhi Gao | Yi Zhang | Wei Li | Chen Shi

Pharmacy Department, Plastic Surgery Hospital (Institute), Chinese Academy of Medical Sciences and Peking Union Medical College, Shijingshan District, Beijing 100144, China

Correspondence
Yi Zhang, Pharmacy Department, Plastic Surgery Hospital (Institute), Chinese Academy of Medical Sciences and Peking Union Medical College, No. 33 Badachu Rd, Shijingshan District, Beijing 100144, China.
Email: gao-zhi0000@163.com

Abstract

A meta-analysis was conducted to investigate the efficacy and safety of polidocanol versus other conventional therapies in treating hemangiomas (HMs) and vascular malformations (VMs). Literature search was conducted in the Cochrane, Embase, PubMed, Web of Science, CNKI, CBM, VIP, and WanFang databases until March 5, 2017. A meta-analysis was conducted using Revman 5.3 software. A total of 19 randomized controlled trials (RCTs) involving 1,514 participants met the inclusion criteria. Regarding the effectiveness, statistically significant differences were observed between polidocanol and all the independent treatments ($p = .006$), but not between polidocanol and pingyangmycin ($p = .16$). Combination therapy of polidocanol with any other conventional treatments ($p = .0001$), pingyangmycin ($p = .005$) or hemoclip ($p = .008$) elicited a better response compared to treatment with these treatments independently. A meta-analysis on the risk of adverse events (AEs) showed a lower risk for polidocanol versus other treatments, for example, all the conventional treatments used independently ($p < .00001$) and pingyangmycin ($p < .00001$). Combination therapy of polidocanol with pingyangmycin also yielded a significantly lower risk of AEs ($p < .00001$). Polidocanol is at least as effective as other conventional therapies on HMs and VMs (especially venous malformations). The former is much safer. Combining its use with other treatments may produce excellent results. Our study provides strong evidence supporting the use of polidocanol for HMs and VMs.

KEYWORDS

hemangiomas, polidocanol, vascular malformations

1 | INTRODUCTION

Hemangiomas (HMs) are vascular neoplasms or vascular anomalies due to the proliferation of blood vessels, and vascular malformations (VMs) are the result of the arrested development of the venous system during embryogenesis (Correa et al., 2007; Lee et al., 2015). The lesions commonly involve the head and neck region followed by the trunk and extremities (Zheng et al., 2013). Most HMs disappear without treatment, leaving minimal or no visible marks. However, when HMs interfere with vision or breathing or carry the threat of significant cosmetic injury (facial lesions and, in particular, nose and lip lesions), they are usually treated. Until recently, the mainstay of treatments include the systematic use of corticosteroids (Nieuwenhuis, de Laat, Janmohamed, Madern, & Oranje, 2013) and beta-blockers (Petrovic et al., 2017), the intralesional injection of corticosteroid (Chantharatanapiboon, 2008; Prasetyono & Djoenaedi, 2011) and antitumor drugs (Hou, Wang, Tang, Wang, & Huang, 2011; Wang et al., 2009), the topical use of beta-blockers (Mashiah et al., 2017; Schneider, Reimer, Cremer, & Ruef, 2014; Wang et al., 2017) and 5% imiquimod (Ho, Lansang, & Pope, 2007; Ma et al., 2011; Welsh, Olazarán, Gómez, Salas, & Berman, 2004), and lasers (Li, Hu, Li, & Deng, 2016; Ying et al., 2017). Surgical removal is sometimes indicated, particularly if there has been delay in commencing treatment and if structural changes have become irreversible (Essawy & Galal, 2013). It has been reported that sclerotherapy with ethanol (Muto, Kinehara, Takahara, & Sato, 1990; Szejnfeld et al., 2015), sodium tetradecyl sulfate (Damodaran, McAuliffe, Wong, McCloskey, & Lee, 2012), and polidocanol (lauromacrogol 400; Winter, Dräger, & Sterry, 2000) is an easy, safe, and effective modality for localized lesions. The combination use of sclerosants with other treatments has also been reported (Grover, Arora, Kedar, Pal, & Lal, 2010); these treatments aim to reduce the duration and cumulative dose of both agents and aim to use their respective salient beneficial effects to our maximum benefit.

 © 2017 Wiley Periodicals, Inc.

According to the modified Hamburg Classification of congenital VMs, VMs can be classified into arterial malformations, venous malformations, arterio-venous malformations, lymphatic malformations, capillary malformations, and combined VMs (Lee et al., 2015), in which venous malformations are most common. Venous malformations in the head and neck can often result in surface malformations and organ translocation. Some lesions in the limbs and trunk may lead to the formation of thrombus, pain, and dysfunction because of the slow bloodstream. Thus, painful lesions and those on the surface should be treated as early as possible. In the treatment of venous malformations, the standard of care is a multidisciplinary approach including the use of traditional surgical therapy, if applicable, and endovascular treatments (Lee, Laredo, Kim, & Neville, 2007). Endovascular techniques include embolization therapy, for instance, with coils but also sclerotherapy with liquid or foamed sclerosants. Foam sclerotherapy is recommended over liquid therapy for the treatment of venous malformations (Rabe et al., 2014). Polidocanol is widely reported to be a therapy for venous malformations (Blaise et al., 2011; Yamaki et al., 2008).

Both HMs and VMs are congenital anomalies of the vascular system and have similar clinical manifestations. Therefore, their clinical cases are often misdiagnosed. Sclerosants can be used in both cases. Polidocanol offers several advantages, such as having a local anesthetic effect, hence causing less pain during intralesional injection (Winter et al., 2000). However, few studies have systematically reviewed the advantages of polidocanol in effectiveness and safety compared to other conventional therapies in treating the above lesions. In the present study, we performed a meta-analysis of the existing randomized controlled trials (RCTs) to better elucidate the efficacy and safety of polidocanol in the treatment of HMs and VMs.

2 | MATERIAL AND METHODS

2.1 | Literature search strategy

Computer-based retrieval technology was applied to the electronic databases. We searched the Cochrane, Embase, PubMed, Web of Science, China National Knowledge Infrastructure (CNKI), Chinese Biomedical Literature (CBM), VIP, and Wan Fang databases for all literature from the database's date of launch up to March 5, 2017. The retrieval of subject terms and free text was used. For PubMed, the following search terms were used: "(polidocanol [supplementary concept] OR lauromacrogol OR polidocanol OR 'polyoxyethylene laurel ether' OR aethoxysklerol) AND (Hemangioma[mh] OR 'vascular malformation'[mh] OR Hemangiom* OR angiom* OR malformatio*)."

2.2 | Inclusion criteria

We included only RCTs involving patients with HMs or VMs. Trials were eligible if they evaluated polidocanol as the intervention of interest in adults or children and compared it to other conventional therapies. The language was restricted to English and Chinese. In addition, only published studies were taken into consideration.

2.3 | Study selection and data extraction

Two investigators (Zhi Gao and Yi Zhang) independently screened the search results, extracted the data using predefined forms and evaluated the risk of bias; all disputes were resolved by consensus. Study selection was based on the title and abstract, and, if necessary, full-text articles. The following data were extracted from studies that met the inclusion criteria: characteristics of participants, intervention and regimen details, clinical endpoints, and follow-up period. For the analysis of efficacy, data on the reduced scale of the lesions were extracted. The safety evaluation included the presence of any adverse events (AEs). The methodological quality was assessed using the Cochrane Collaboration tool for the evaluation of risk of bias, which covers sequence generation, allocation concealment, blinding, incomplete data, selective reporting, and other biases. In assessing the risk of bias, "+" denotes cases of low risk of bias, "–" indicates a high risk of bias, whereas "?" indicates an unclear risk of bias.

2.4 | Data synthesis and analysis

Revman 5.3 software was used to perform the meta-analysis. For these dichotomous outcomes, odds ratios (ORs) and 95% confidence intervals were estimated. In the present meta-analysis, either a random-effects model or a fixed-effects model (Mantel-Haenszel method) was used for analysis. Heterogeneity among the studies was evaluated using I^2 statistics. I^2 values of above 50% were defined as high heterogeneity. Funnel plot asymmetry was measured to assess publication bias. Probability values of $< .05$ were considered as statistically significant.

3 | RESULTS

3.1 | Literature search, description, and quality of the included studies

A total of 1,717 potentially relevant studies were identified in the literature search, and 474 of them were duplicates. Then, 1,146 studies were excluded after screening the titles and abstracts, and 78 studies were excluded after screening the full-text. The remaining 19 RCTs were considered in the meta-analysis. The quality of the included trials was relatively low. All trials were described as RCTs, but only three studies reported a specific method of randomized allocation. The others only mentioned randomization. Furthermore, none of the articles mentioned allocation concealment and blinding. Participant losses were reported in two trials: two participants in one trial were lost to follow-up and other unclear reasons, and four participants in the other trial were lost because of unclear reasons. These six patients were excluded from the analysis.

3.2 | Characteristics of the included studies

Included trials were published between 2011 and 2017. These trials randomized a total of 1,514 participants and possessed a sample size ranging from 46 to 120 subjects. All of the trials were from China and

TABLE 1 Characteristics of the RCTs included in the meta-analysis

Study	Sample size (age)	Location	Intervention	Dose of PL (liquid or foam)	Duration (week)	Follow-up (month)	No. of efficacy (E/C)	No. ofAE (E/C)	Criteria for effectiveness (the reduced scale of the lesion area)
1 (Bao, Zhao, Chen, Li, & Jiang, 2015)	33/34 (44.7 ± 9.7 y)	Liver HMs	PL vs. PY	30 mg/time (F)	8–18	6	22/24	8/21	> 75% (If the criterion is > 50%, the effective rate becomes 28/33:30/34)
2 (Deng, 2015)	34/34 (11.3 ± 3.6 y)	Oromaxillo-facial HMs	PL vs. PY	NR (F)	8	4	32/30	5/21	No criteria related to reduced scale
3 (Han et al., 2016)	32/27 (9.8 ± 11.6 m)	Parotid HMs	PL vs. PY	5 mg/cm^2 (L)	≥2	NR	32/27	10/16	> 2/3
4 (Sun, 2016)	31/31 (0–18 y)	Liver HMs	PL vs. PY	60–100 mg/time (L)	8–12	6	27/26	7/16	> 50%
5 (Tang, 2017)	37 (28.9 ± 6.5 y)/37 (28.1 ± 7.1 y)	Head, neck and extremity VMs	PL vs. PY	NR (F)	8	NR	35/27	7/17	> 25% (If the criterion is > 50%, the effective rate becomes 29/37:21/37)
6 (Xu et al., 2015)	54/52 (2 lost) (3 d–10 y)	Oromaxillo-facial HMs	PL vs. PY	10 mg/cm^2 (L)	1–5	3–12	54/45	26/37	> 2/3
7 (Zhang, H. M., 2013)	60/60 (6 m–46y)	Intraoral VMs	PL vs. PY	5–10 mg/time (L)	4–8	6–24	51/55	5/8	> 50%
8 (Zhang, Y. H., 2016)	29 (4.12 ± 1.38 y)/ 29 (4.78 ± 1.29 y)	VMs (unclear location)	PL vs. PY	NR (F)	NR	6	25/26	3/7	> 70%
9 (Zhu, Y., 2014)	30/30 (12.5 ± 7.9 y)	Face, limb, chest and abdomen VMs	PL vs. PY	<5 mg/time (F)	8	3	29/28	4/18	No criteria related to reduced scale
10 (Zou, Zhu, & Zhang, 2015)	24 (1 lost)/22 (3 lost) (4.3 ± 0.6 m)	Oromaxillo-facial HMs	PL vs. PY	10 mg/cm^3 (L)	8	3	22/21	7/20	> 50%
11 (Feng, 2013)	56/56 (52.6 ± 2.0 y)	Oromaxillo-facial HMs	PL vs. PR	<10 mg/cm^3 (L)	31	NR	54/41	N	> 50%
12 (Kong, 2016)	32/32 (50.6 ± 7.1 y)	Liver HMs	PL vs. AT	100–200 mg/site (L)	1–2	NR	32/32	24/43	> 50%
13 (Wang, 2016)	30/30 (43.4 ± 5.2 y)	Liver HMs	PL vs. AT	50–100 mg/site (L)	1–3	2–4	30/29	3/12	> 50%
14 (Liu, Liu, Zhao, Cai, & Zhong, 2016)	60/60 (16–52 y)	Oromaxillo-facial and extremities VMs	PL+PY vs. PY	80–100 mg/site (L)	8	NR	58/52	109/58	> 50%
15 (Meng, 2016)	53/50 (11.7 ± 8.2 y)	Maxillo-facial HMs	PL+PY vs. PY	<1 mg/cm^3(L)	8	3	51/46	4/19	> 50%

(Continues)

TABLE 1 (Continued)

Study	Sample size (age)	Location	Intervention	Dose of PL (liquid or foam)	Duration (week)	Follow-up (month)	No. of efficacy (E/C)	No. ofAE (E/C)	Criteria for effectiveness (the reduced scale of the lesion area)
16 (Zhang, H. T., 2013)	60/58 (12.5 ± 7.9 y)	Oromaxillo-facial HMs	PL+PY vs. PY	NR (L)	8	3	58/54	5/23	> 50%
17 (Zhao, 2015)	49/49 (13.1 ± 10.1 y)	Oromaxillo-facial HMs	PL+PY vs. PY	<10 mg/cm^3 (L)	4	NR	48/43	3/13	> 50%
18 (Cui et al., 2011)	30/31 (54 y)	Digestive tract VMs	PL+HC vs. HC	5 mg/site	One injection	12	29/24	N	No criteria related to reduced scale
19 (Zhu, S. J., 2014)	26 (50.1 ± 10.8 y)/ 26 (51.9 ± 11.8 y)	Digestive tract VMs	PL+HC vs. HC	5–10 mg/site (L)	NR	NR	25/20	N	No criteria related to reduced scale

Abbreviations: AE = adverse events; AT = ethanol; E/C = experimental group/control group; HC = hemoclip; HMs = hemangiomas; NR = not reported; PL = polidocanol; PR = prednisone; PY = pingyangmycin; VMs = venous malformations.

were single-center studies. The basic characteristics of the studies are shown in Table 1. Of these included trials, 10 trials compared the efficacy of polidocanol with intralesional pingyangmycin, two compared the efficacy of polidocanol with intralesional ethanol, one trial compared the efficacy of polidocanol with oral prednisone, four trials compared the efficacy of a combination of intralesional polidocanol and pingyangmycin with pingyangmycin used independently, and two compared the efficacy of a combination of polidocanol and hemoclip with hemoclip used independently. Patients in 15 trials suffered from superficial HMs or VMs, such as those on the face, limbs, and abdomen, and patients in four trials suffered from deep sites, such as the digestive tract or liver. Among these included trials, 12 trials included HM cases, seven included VM cases in which five were venous malformations, and the remaining two were not described in detail. Three trials did not include statistical information regarding AEs.

3.3 | Efficacy rate

The efficacy rate was reported in all of the included studies. In addition, in most of the references, efficacy was defined as a reduced scale of >50%. There was low heterogeneity in all the statistical analyses ($I^2 < 50\%$), and therefore, a fixed-effect model was used to evaluate the data. As shown in Figure 1, two trials showed the same number of effective events in the experimental and control groups, and thus, the ORs were not estimable. Statistically significant differences were observed between polidocanol and all of the drugs when used independently ($p = .006$) but not between polidocanol and pingyangmycin ($p = .16$). Combination therapy of polidocanol with any other conventional treatments ($p = .0001$), pingyangmycin ($p = .005$), or hemoclip ($p = .008$) elicited a better response compared to treatment with these drugs independently (Figure 1).

3.4 | Adverse events

Adverse reactions were reported in 16 articles, including ulceration, swelling, pain, infection, necrosis of skin, gastrointestinal reaction, liver damage, fever, dizziness, and amyotrophy, in either the experimental group or the control group. The top three AEs are fever, swelling, and ulceration in the experimental group and fever, swelling, and gastrointestinal reaction in the control group. Three trials did not include statistical information regarding AEs and were excluded. There was low heterogeneity in all the statistical analyses ($I^2 < 50\%$), and thus, a fixed-effect model was utilized. As shown in Figure 2, the AEs were counted by the number of occurrences in two trials, causing the number of AEs to be larger than that of total patients, and thus, the ORs were not estimable. A meta-analysis on the risk of AEs related to the treatments showed a significantly lower risk for polidocanol versus other treatments, for example, all treatments used independently ($p < .00001$) and pingyangmycin ($p < .00001$). Combination therapy of polidocanol with pingyangmycin also yielded a significantly lower risk of AEs ($p < .00001$; Figure 2).

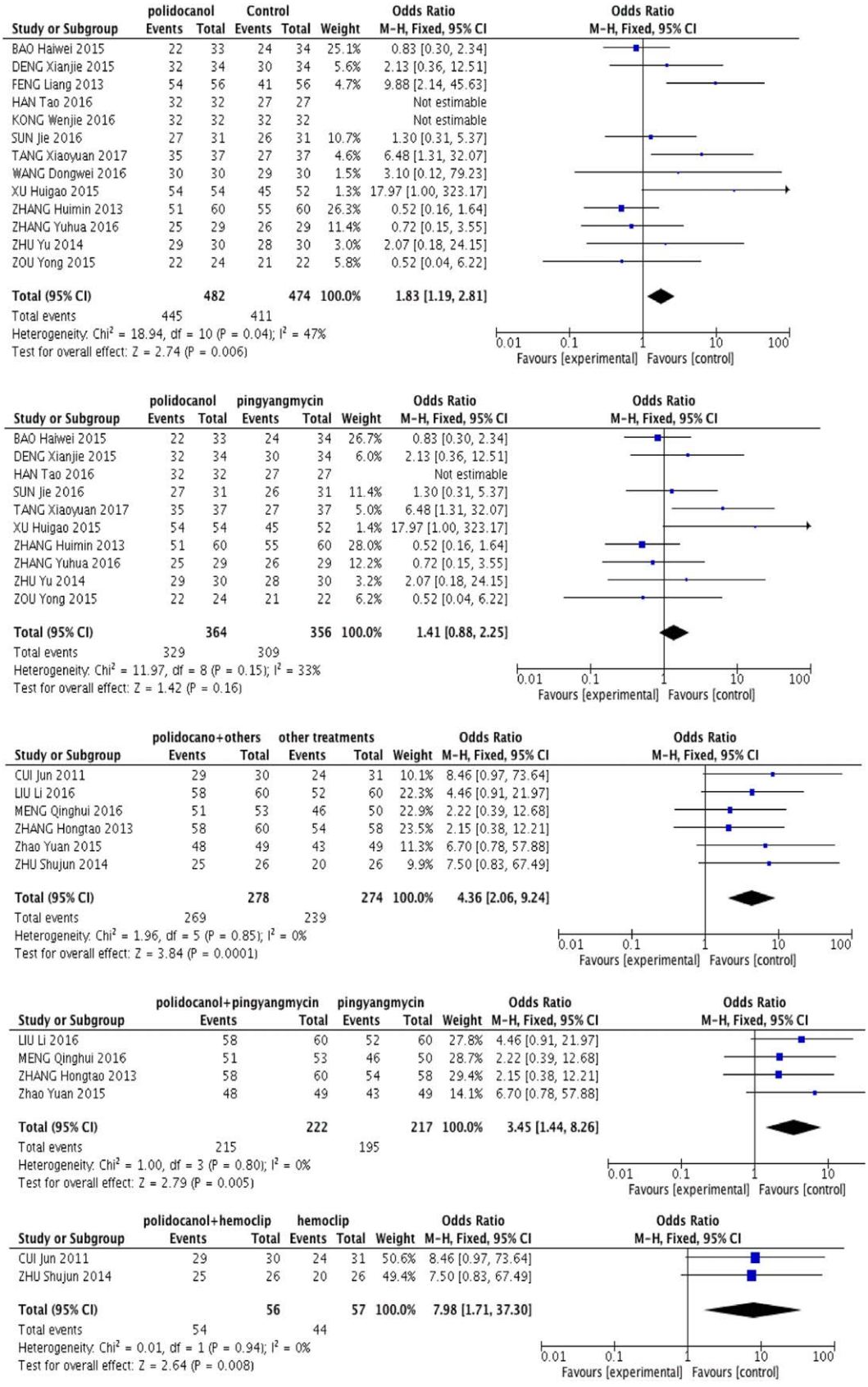

FIGURE 1 Comparison of the efficacy of polidocanol with that of other conventional therapies in the treatment of hemangiomas and vascular malformations

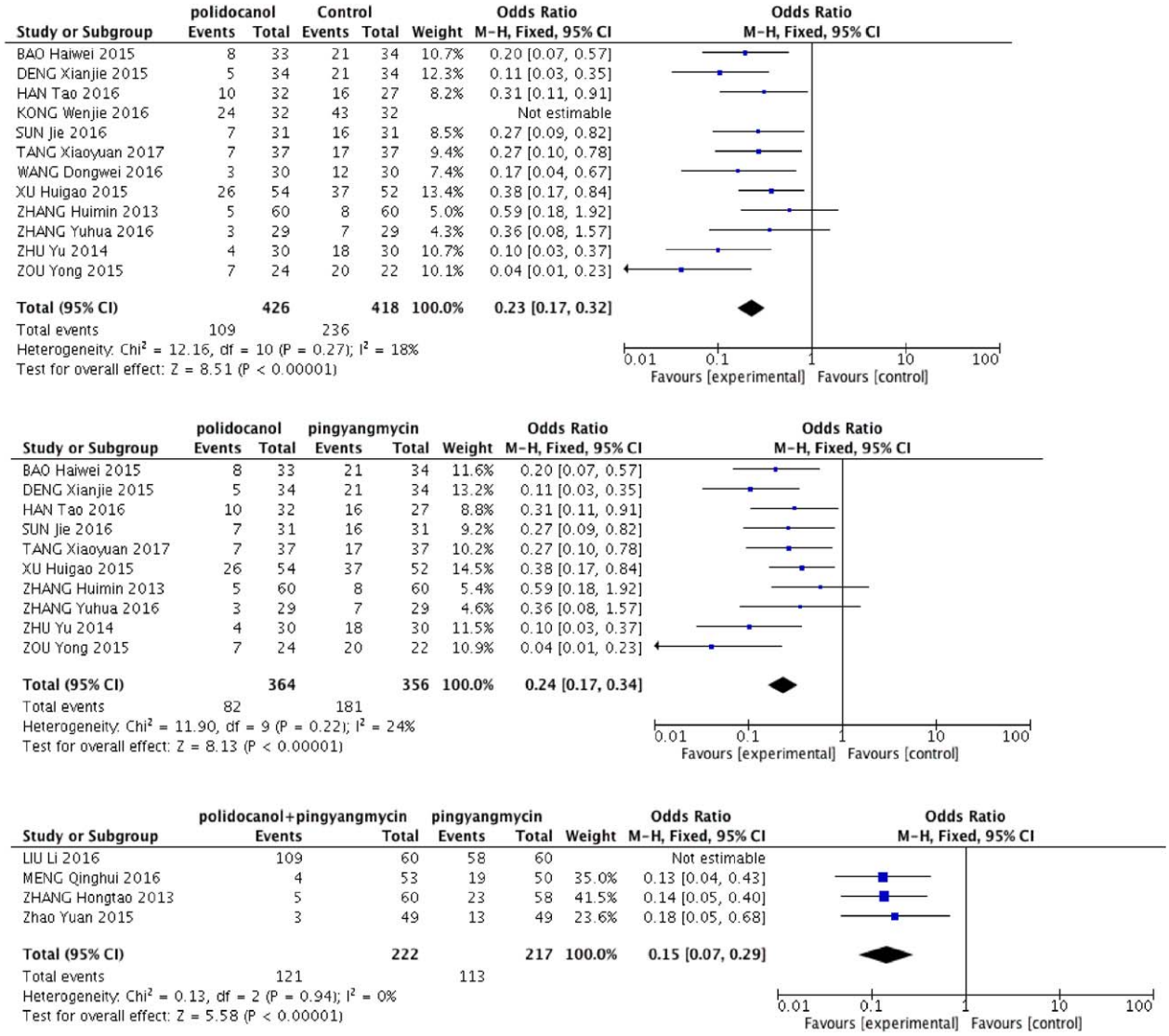

FIGURE 2 Comparison of the risk of adverse events from polidocanol use with that from the use of other conventional therapies in the treatment of hemangiomas and vascular malformations

3.5 | Publication bias

The funnel plot generated from the studies reporting efficacy and AEs was asymmetric. This might be a result of the smaller sample sizes producing a smaller effect size.

4 | DISCUSSION

Our analysis of the 19 studies demonstrated that polidocanol was at least as effective as other conventional therapies on HMs and VMs (especially venous malformations). In addition, the use of polidocanol was much safer. The combination of polidocanol with other therapies was also more effective and safer than treatment with those therapies independently.

Sclerosants cause irreversible damage to the vascular endothelium by disrupting cell membranes, resulting in sustained vasospasm and the denudation of the venous monolayer (Bergan, 2008). Sclerotherapy for HMs and VMs has been reported. Polidocanol, a sclerosant, offers several advantages, such as the local anesthetic effect, hence causing less pain during the injection (Winter et al., 2000). Despite the growing acceptance of polidocanol as a leading treatment modality in HMs and VMs, few studies have systematically reviewed the advantages of polidocanol compared to other common treatments. In the present study, we performed a meta-analysis of the existing RCTs to better elucidate the efficacy and safety of polidocanol in the treatment of HMs and VMs. The strengths of this meta-analysis are that it compared the use of polidocanol with the use of other therapies and also simultaneously analyzed the superior efficacy of a combination treatment.

However, there are several limitations that should be addressed. First, the quality of the included trials was relatively low. All trials were described as RCTs, but only three studies reported a specific method of randomized allocation, the others only mentioned randomization. Furthermore, none of the articles mentioned allocation concealment and blinding. Participant losses were reported in two trials: two

participants in one trial were lost to follow-up and other unclear reasons, and four participants in the other trial were lost because of unclear reasons. Unreasonable losses may influence outcome. The analysis of additional high-quality studies will be required. Second, of these 19 articles, 18 were published in Chinese, and 1 was in English. All of the participants were from China, resulting in geographical limitations. Third, the outcome measurement varied across the studies, which weakened the strength of the identified associations. Several studies used different percentages to determine the reduced scale of the lesions, whereas others used objective methods such as doppler ultrasonography to evaluate the responses. This discrepancy may lead to inevitable bias. Fourth, different forms of polidocanol were used, which may influence the efficacy. Many studies have shown that foam polidocanol has the advantage of better and longer lasting contact of the sclerosing agent with the vessel wall, which leads to a more effective treatment and a reduction of the necessary drug concentration (Rabe & Pannier, 2013).

Based on the findings of the present analysis, a few questions remain to be answered. First, if necessary and if there are enough data, the heterogeneity in the age of the patients as well as the type and the location of the lesions should be taken into account. Second, due to the lack of dose-response studies, the optimal dose of polidocanol remains unknown. To answer these questions, additional well-designed RCT studies need to be conducted.

In conclusion, polidocanol is an effective and safe therapy for HMs and VMs (especially venous malformations). In addition, combination therapy of polidocanol with other treatments will produce excellent responses, with minimal AEs. The present meta-analysis provides strong evidence supporting the use of polidocanol for the treatment of HMs and VMs.

CONFLICTS OF INTEREST

The authors declare that they have no competing interests.

ORCID

Zhi Gao http://orcid.org/0000-0002-3817-8037

REFERENCES

Bao, H. W., Zhao, Q.-Y., Chen, F., Li, C.-X., & Jiang, T.-A. (2015). Clinical efficacy of lauromacrogol percutaneous intratumor injection for treatment of liver hemangioma. *Chinese Journal of Interventional Imaging and Therapy*, *12*, 39–42.

Bergan, J. (2008). Sclerotherapy: A truly minimally invasive technique. *Perspectives in Vascular Surgery and Endovascular Therapy*, *20*, 70–72.

Blaise, S., Charavin-Cocuzza, M., Riom, H., Brix, M., Seinturier, C., Diamand, J. M., . . . Carpentier, P. H. (2011). Treatment of low-flow vascular malformations by ultrasound-guided sclerotherapy with polidocanol foam: 24 cases and literature review. *European Journal of Vascular and Endovascular Surgery*, *41*, 412–417.

Chantharatanapiboon, W. (2008). Intralesional corticosteroid therapy in hemangiomas: Clinical outcome in 160 cases. *Journal of the Medical Association of Thailand*, *91*(Suppl. 3), 90–96.

Correa, P. H., Nunes, L. C., Johann, A. C., Aguiar, M. C., Gomez, R. S., & Mesquita, R. A. (2007). Prevalence of oral hemangioma, vascular malformation and varix in a Brazilian population. *Brazilian Oral Research*, *21*, 40–45.

Cui, J., Huang, L. Y., Liu, Y. X., Song, B., Yi, L. Z., Xu, N., . . . Wu, C. R. (2011). Efficacy of endoscopic therapy for gastrointestinal bleeding from Dieulafoy's lesion. *World Journal of Gastroenterology*, *17*, 1368–1372.

Damodaran, O., McAuliffe, W., Wong, G., McCloskey, E., & Lee, G. (2012). Preoperative sclerotherapy using sodium tetradecyl sulphate (fibro-vein) can assist in the management of vertebral hemangiomas. *Global Spine Journal*, *2*, 169–174.

Deng, X. J. (2015). Clinical efficacy and safety of lauromacrogol injection in the treatment of hemangioma. *Journal of Medical Informatics*, *28*, 244.

Essawy, R. E., & Galal, R. E. (2013). Parenteral corticosteroids followed by early surgical resection of large amblyogenic eyelid hemangiomas in infants. *Clinical Ophthalmology*, *7*, 955–958.

Feng, L. (2013). Efficacy of lauromacrogol injection in the treatment of oral and maxillofacial vascular lesions. *Chinese Journal of Practical Medicine*, *40*, 128

Grover, C., Arora, P., Kedar, A., Pal, P., & Lal, B. (2010). Combination of oral corticosteroids and polidocanol sclerotherapy in the management of infantile hemangiomas. *Dermatologic Surgery*, *36*, 2030–2036.

Han, T., Chen, H., Zou, J., Ji, Y., Chen, J., Shen, W., & Cui, J. (2016). Clinical study of radiofrequency ablation combined with lauromacrogol for the treatment of parotidgland hemangioma in infants. *Chinese Journal of Plastic Surgery*, *32*, 254–258.

Ho, N. T., Lansang, P., & Pope, E. (2007). Topical imiquimod in the treatment of infantile hemangiomas: A retrospective study. *Journal of the American Academy of Dermatology*, *56*, 63–68.

Hou, J., Wang, M., Tang, H., Wang, Y., & Huang, H. (2011). Pingyangmycin sclerotherapy for infantile hemangiomas in oral and maxillofacial regions: An evaluation of 66 consecutive patients. *International Journal of Oral and Maxillofacial Surgery*, *40*, 1246–1251.

Kong, W. J. (2016). Efficacy of 2 sclerosing agents under ultrasound guided percutaneous injection for treatment of hepatic hemangioma. *Journal of Hebei Medical University*, *37*, 706–709.

Lee, B. B., Baumgartner, I., Berlien, P., Bianchini, G., Burrows, P., Gloviczki, P., . . . Zamboni, P.; International Union of Phlebology. (2015). Diagnosis and Treatment of Venous Malformations. Consensus Document of the International Union of Phlebology (IUP): Updated 2013. *International Angiology*, *34*, 97–149.

Lee, B. B., Laredo, J., Kim, Y. W., & Neville, R. (2007). Congenital vascular malformations: General treatment principles. *Phlebology*, *22*, 258–263.

Li, Y., Hu, Y., Li, H., & Deng, L. (2016). Successful treatment of ulcerated hemangiomas with a dual-wavelength 595- and 1064-nm laser system. *Journal of Dermatological Treatment*, *27*, 562–567.

Liu, L., Liu, D. X., Zhao, J. H., Cai, Y., & Zhong, H. Y. (2016). Clinical efficacy of lauromacrogol combined with pingyangmycin in the treatment of venous malformation: Clinical analysis of 120 consecutive cases. *Shanghai Kou Qiang Yi Xue*, *25*, 588–592.

Ma, G., Lin, X. X., Jiang, C. H., Chen, H., Li, W., Hu, X. J., . . . Ye, X. X. (2011). Clinical application of imiquimod for the treatment of infantile hemangiomas. *Zhonghua Zheng Xing Wai Ke Za Zhi*, *27*, 411–414.

Mashiah, J., Kutz, A., Rabia, S. H., Ilan, E. B., Goldberg, I., Sprecher, E., & Harel, A. (2017). Assessment of the effectiveness of topical propranolol 4% gel for infantile hemangiomas. *International Journal of Dermatology*, *56*, 148–153.

Meng, Q. H. (2016). Evaluation of the clinical efficacy of Pingyang combined with lauromacrogol in the treatment of oral facial hemangioma. *Guide of China Medicine*, *14*, 173–174.

Muto, T., Kinehara, M., Takahara, M., & Sato, K. (1990). Therapeutic embolization of oral hemangiomas with absolute ethanol. *Journal of Oral and Maxillofacial Surgery*, *48*, 85–88.

Nieuwenhuis, K., de Laat, P. C., Janmohamed, S. R., Madern, G. C., & Oranje, A. P. (2013). Infantile hemangioma: Treatment with short course systemic corticosteroid therapy as an alternative for propranolol. *Pediatric Dermatology*, *30*, 64–70.

Petrovic, J., Trifunovic, B., Vukomanovic, G., Topalovic, M., Trajkovic, G., & Parezanović, V. (2017). Oral propranolol for infantile hemangiomas: A prospective study on the role of 48-hour Holter monitoring in additional safety assessment. *Journal of Dermatological Treatment*, *28*, 554–558.

Prasetyono, T. O., & Djoenaedi, I. (2011). Efficacy of intralesional steroid injection in head and neck hemangioma: A systematic review. *Annals of Plastic Surgery*, *66*, 98–106.

Rabe, E., & Pannier, F. (2013). Sclerotherapy in venous malformation. *Phlebology*, *28(Suppl. 1)*, 188–191.

Rabe, E., Breu, F. X., Cavezzi, A., Coleridge Smith, P., Frullini, A., Gillet, J. L., . . . Pannier, F.; Guideline Group. (2014). European guidelines for sclerotherapy in chronic venous disorders. *Phlebology*, *29*, 338–354.

Schneider, M., Reimer, A., Cremer, H., & Ruef, P. (2014). Topical treatment with propranolol gel as a supplement to the existing treatment of hemangiomas. *World Journal of Pediatrics*, *10*, 313–317.

Sun, J. (2016). *Ultrasonographic evaluation of the efficacy of lauromacrogol injection in the treatment of hepatic hemangioma*. Paper presented at the Clinical Academic Conference of Emergency Medicine.

Szejnfeld, D., Nunes, T. F., Fornazari, V. A. V., de Matos, C. A. L., Gonzalez, A. M., D'Ippolito, G., . . . Goldman, S. M. (2015). Transcatheter arterial embolization for unresectable symptomatic giant hepatic hemangiomas: Single-center experience using a lipiodol-ethanol mixture. *Radiologia Brasileira*, *48*, 154–157.

Tang, X. Y. (2017). Effect of ultrasound guided coagulation of foam lauromacrogol on venous malformation. *Chinese Journal of Rural Medicine*, *24*, 24–25.

Wang, L. L., Gao, Q.-H., Liu, K., Wang, X.-Y., Wang, C.-M., & Wen, Y.-M. (2009). Intralesional Pingyangmycin therapy for 51 infantile patients with parotid gland hemangiomas. *Shanghai Kou Qiang Yi Xue*, *18*, 142–146.

Wang, D. W. (2016). Investigate the clinical effect of ultrasound-guided percutaneous injection of lauromacrogol on hepatic hemangioma. *World Latest Medicine Information*, *16*, 124.

Wang, Y., Zhang, X., Yang, Y., Zhang, J., Yang, Y., & Lu, Y. (2017). Efficacy and safety of 2% topical propranolol cream for the treatment of proliferating infantile strawberry hemangiomas. *Indian Journal of Pediatrics*, *84*, 425–429.

Welsh, O., Olazarán, Z., Gómez, M., Salas, J., & Berman, B. (2004). Treatment of infantile hemangiomas with short-term application of imiquimod 5% cream. *Journal of the American Academy of Dermatology*, *51*, 639–642.

Winter, H., Dräger, E., & Sterry, W. (2000). Sclerotherapy for treatment of hemangiomas. *Dermatologic Surgery*, *26*, 105–108.

Xu, H. G., Lv, Z., Wang, P., Yang, J., Xu, Z., Geng, Q., & Wang, S. (2015). Clinical comparative research of clinical efficacy and complications of lauromacrogol and pingyangmycin in the treatment of maxillofacial hemangioma. *Medical Innovation of China*, *12*, 17–20.

Yamaki, T., Nozaki, M., Sakurai, H., Takeuchi, M., Soejima, K., & Kono, T. (2008). Prospective randomized efficacy of ultrasound-guided foam sclerotherapy compared with ultrasound-guided liquid sclerotherapy in the treatment of symptomatic venous malformations. *Journal of Vascular Surgery*, *47*, 578–584.

Ying, H., Zou, Y., Yu, W., Qiu, Y., Ma, G., Chang, L., . . . Lin, X. (2017). Prospective, open-label, rater-blinded and self-controlled pilot study of the treatment of proliferating superficial infantile hemangiomas with 0.5% topical timolol cream versus 595-nm pulsed dye laser. *Journal of Dermatology*, *44*, 660–665.

Zhang, H. M. (2013). Clinical observation of 120 cases of maxillofacial vein malformation treated with Pingyang and lauromacrogol. *Journal of Oral Science Research*, *29*, 870–871.

Zhang, H. T., & Ye, T. (2013). Analysis of the therapeutic effects of pingyangmycin combined with lauromacrogol for oral and maxillofacial hemangioma. *Journal of Clinical Medicine in Practice*, *17*, 95–97.

Zhang, Y. H. (2016). Interventional treatment of venous malformation in children. *Chinese and Foreign Medical Journals*, *35*, 59–60.

Zhao, Y. (2015). Clinical observation of injection of lauromacrogol in patients with hemangioma of oral and maxillofacial region. *China Practical Medicine*, *10*, 164–165.

Zheng, J. W., Zhang, L., Zhou, Q., Mai, H. M., Wang, Y. A., Fan, X. D., . . . Zhao, Y. F. (2013). A practical guide to treatment of infantile hemangiomas of the head and neck. *International Journal of Clinical and Experimental Medicine*, *6*, 851–860.

Zhu, S. J., Deng, S., Deng, G., Wang, G., & Qin, R. (2014). Hemostasis efficacy of hardener joint titanium clips in the treatment of gastrointestinal bleeding caused by vascular malformations. *Heilongjiang Medical Journal*, *38*, 501.

Zhu, Y., Li, D.-L., Chen, Z.-Y., & Tan, Q. (2014). Comparative study on the effect of pingyangmycin and lauromacrogol on curing venous malformation. *Chinese Journal of Aesthetic Medicine*, *23*, 1181–1183.

Zou, Y., Zhu, Q., & Zhang, G.-Y. (2015). Clinical analysis of therapeutic effects of lauromacrogol injected locally for infant oral and maxillofacial hemangioma. *Lingnan Journal of Emergency Medicine*, *20*, 398–399.

How to cite this article: Gao Z, Zhang Y, Li W, Shi C. Effectiveness and safety of polidocanol for the treatment of hemangiomas and vascular malformations: A meta-analysis. *Dermatologic Therapy*. 2017;e12568. https://doi.org/10.1111/dth.12568