REVIEW ARTICLE

Treatment of necrobiotic xanthogranuloma – a systematic review

D. Miguel,* J. Lukacs, T. Illing, P. Elsner

Department of Dermatology, University Hospital, Jena, Germany
*Correspondence: D. Miguel. E-mail: diana.miguel@med.uni-jena.de

Abstract

Necrobiotic xanthogranuloma (NXG) is an uncommon non-Langerhans cell histiocytosis involving skin and extracutaneous tissues. The lesions are usually asymptomatic and commonly appear in the periorbital area. Paraproteinemia is closely associated with NXG and its pathogenesis remains unclear. NXG prognosis is poor with several treatments showing variable results. Treatment of monoclonal gammopathy with alkylating agents does not necessarily influence the activity of the skin disease and vice versa. The aim of this systematic review is to summarize all reported treatments of necrobiotic xanthogranuloma of the skin, with or without underlying malignant condition and based on articles from the PubMed database using the query 'necrobiotic xanthogranuloma treatment', both in English and German, about 'human' subjects and published between 1980 and 2014, documenting adequate treatment for NXG. Mainly individual case reports, small case series and retrospective studies were found. Treatment options include topical and systemic corticosteroids, thalidomide, high-dose intravenous immunoglobulin (IVIG), chlorambucil, cyclophosphamide, fludarabine, rituximab, melphalan, infliximab, interferon alpha, cladribine, hydroxychloroquine, azathioprine, methotrexate, laser therapy, radiotherapy, surgery, PUVA, plasmapheresis and extracorporeal photopheresis. Randomized controlled trials and studies on long-term outcomes after treatment were not found and are necessary to focus on in the future.
Received: 9 September 2015; Accepted: 2 May 2016

Conflicts of interest

None declared.

Funding Sources

None.

Introduction

With only approximately 100 cases reported in the literature, necrobiotic xanthogranuloma (NXG) is a rarely reported disorder first described in 1980.[1] This unusual, progressive and chronic, non-Langerhans cell histiocytosis is characterized by multiple indurated asymptomatic yellowish to reddish brown papules and nodules that slowly develop into large plaques involving the dermis and subcutaneous tissue. Ulceration, telangiectasia, atrophy and pruritus may also be present, and it commonly appears in the periorbital region (>80%). It is frequently associated with haematologic alterations, with the most common being monoclonal gammopathy of the immunoglobulin G-kappa type (65%), followed by IgG lambda (35%). Other reported associations comprise non-Hodgkin lymphoma, Waldenström's macroglobulinemia, amyloidosis and myelodysplastic syndrome. Some patients are diseased by NXG without the presence of paraproteinemia. Nevertheless, all patients should be examined for haematological and lymphoproliferative disorders, as the manifestation may come after the onset of skin manifestations. Laboratory findings may reveal hypocomplementemia, leucopenia, cryoglobulinemia and hyperlipidemia. NXG has no gender propensity and first symptoms of the disease occur frequently in the fifth or sixth decade of life.[2–7] NXG involves most commonly, the periorbital region (Fig. 1) manifesting in the skin or in the anterior orbit, leading to proptosis, blepharoptosis and limitation of ocular motility. Vision changes, diplopia, episcleritis, keratitis, iritis, conjunctivitis, corneal perforation, involvement of the extraocular muscles and fat and enlargement of the lacrimal glands may also be present. Lesions of NXG can appear anywhere and after initially involving the periorbital area, most commonly, trunk and extremities are affected. In over 90% of the patients, NXG involves more than one body site. Giant-cell myocarditis should also be excluded.[2,7–13]

The pathogenesis of NXG has not yet been fully cleared up, and there are some reports on the occurrence of NXG within a

 © 2016 European Academy of Dermatology and Venereology

Figure 1 Necrobiotic xanthogranuloma involving the left upper eyelid.

scar, after trauma or radiation.[14–16] A research group who detected spirochetal microorganisms in NXG, postulated an infectious aetiology.[17] Another study disclosed that NXG with monoclonal gammopathy is featured by an impaired HDL phenotype, associated with a single inflammatory pattern, the prevalence of a specific monocyte subset and an abnormal macrophage lipid homoeostasis, perhaps due to interactions between monoclonal immunoglobulin and lipoproteins. However, the answer to the reason why lipid-loaded macrophage cells usually deposit in the skin without a significant vascular tropism remains unsettled.[18]

The histopathologic diagnosis of NXG can be challenging due to its occasionally uncharacteristic features and similarities with necrobiosis lipoidica diabeticorum. An atrophic or normal epidermis may be present and granulomatous inflammation can affect dermis and subcutaneous tissue. Granulomas are normally band-like and consist of foamy histiocytes, lymphocytes, foreign body-type multinucleated giant cells, Touton giant cells with peripheral cytoplasmatic xanthomatous change and areas of necrobiosis. Granulomas can be associated with nodular lymphoid aggregates. Presence of extracellular lipid as cholesterol clefts can be found within the necrobiosis areas and is helpful to exclude other inflammatory granulomatous conditions.[4,7,13]

Management of NXG may be difficult with several treatment regimens including physical modalities, immunomodulatory drugs, immunosuppressive agents, high-dose corticosteroids, alkylating agents, plasmapheresis and local radiotherapy showing variable dermatological responses.[10]

This review wants to summarize the treatment of necrobiotic xanthogranuloma of the skin, helping other physicians in the choice of adequate treatment according to each patient's condition.

Materials and methods

We performed a systematic review based on PubMed, Medline and Web of Science databases using the query 'necrobiotic xanthogranuloma treatment'. Eligibility of the studies was assessed by two independent reviewers and divergences were arbitrated and resolved by a third experienced reviewer. Our search was limited to 'English' and 'German' language, 'human' subjects and publications from 1 January 1980 to 31 December 2014, documenting adequate treatment for NXG. Furthermore, we manually searched the references of the retrieved articles for any additional studies. We reviewed the reference lists of the full-length articles to identify additional articles meeting the predefined inclusion criteria. A total of 90 articles were identified from the initial search in Pubmed, and 28 additional articles were found through the manual review. After searching in Medline and Web of Science databases, one more article was added to our initial search. After reviewing all full-text articles and excluding reviews, papers about other diseases and articles without reporting on treatment, a total sum of 70 studies, 57 from the initial search and 13 from additional papers, were analysed. For each study included, a summary of author/study year, country, study design, number of patients, therapies, results and haematological or internal malignancies is given in Table 1. The case series from Kossard *et al.*[1] were excluded, since we suspected that some of the patients are included in the retrospective study from Finan and Winkelmann.[19] For the same reason, we decided to not include the review of Mehregan and Winkelmann *et al.* from 1992[8] and the case series from 1998[20] because the patient population may be the same as in Ugurlu *et al.* In the retrospective study from Wood *et al.*,[6] one patient case was already published and may have been repeatedly reported. In the study from Ugurlu *et al.*[9] five patients were excluded, but we suspected that some of them may be already included in the studies from Wood *et al.* or Finan and Winkelmann.

Results

Our results are mainly based on individual case reports, small case series and retrospective studies. Treatment options include topical, physical, surgery, systemic treatments and phototherapy. Treatments were often reported to have been unsuccessful. The disease course after treatment tends to be progressive with occurrence of new lesions. Medical literature also shows that treatment of monoclonal gammopathy with alkylating agents does not necessarily influence the activity of skin disease.

Topical and intralesional agents

Topical and intralesional corticosteroids Intralesional use of corticosteroids in treatment of NXG remains inconsistent. Elner *et al.* suggested the lack of studies with information about type, dose, depth and site of injections as responsible for its poor outcome. On the other hand, positive results from the use of injected triamcinolone on a regular basis until satisfactory response was achieved have been reported. Minimal isolated skin manifestations should be initially treated with topical corticosteroids, avoiding thereby the use of systemic corticosteroids and cytotoxic agents.[21] A total of 26 patients were treated with topical or intralesional corticosteroids with two patients showing marked improvement of skin lesions after topical therapy and

 © 2016 European Academy of Dermatology and Venereology

14683083, 2017, 2, Downloaded from https://onlinelibrary.wiley.com/doi/10.1111/jdv.13786 by University Of Toronto Libraries, Wiley Online Library on [15/06/2023]. See the Terms and Conditions (https://onlinelibrary.wiley.com/terms-and-conditions) on Wiley Online Library for rules of use; OA articles are governed by the applicable Creative Commons License

Table 1 Study characteristics

Author (Year)	Country	Study type	No. of patients	Topical and intralesional agents	Systemic agents	Physical modalities	Results	Haematological or internal malignancies
Hamilton *et al.* (2014)[50]	USA	Case report	1			Q-Switched 650-nm Laser	The patient's facial hyperpigmentation diminished almost entirely	IgG λ monoclonal gammopathy
Liszewski *et al.* (2014)[49]	USA	Case series	1		Chlorambucil, methotrexate, acitretin, infliximab, IVIG	ECP	Improvement after Infliximab, ECP and IVIG	No evidence of plasmacytosis
			1		Methotrexate, acitretin, cyclophosphamide, lenalidomide, decadron, IVIG		Improvement after IVIG infusion	MGUS
Ghani *et al.* (2013)[13]	USA	Case report	1		Thalidomide 100 mg/day Dexamethasone 20 mg/day for 4 days every 2 weeks		Dramatic dermatologic response	Monoclonal gammopathy of unknown significance (MGUS).
Rubinstein *et al.* (2013)[35]	USA	Case report	1		High-dose intravenous immunoglobulin (IVIG)		Successfully treatment	Smoldering multiple myeloma
Sutton *et al.* (2013)[46]	USA	Case report	1		2-Chlorodeoxyadenosine		Some success; treatment discontinued due to pancytopenia	No haematologic or internal malignancy
Rose *et al.* (2012)[4]	USA	Case report	1		Low-dose prednisone		Improvement of the lesions	Monoclonal gammopathy of unknown significance (MGUS).
Ghiasi *et al.* (2012)[61]	Canada	Case report	1		Prednisone, Doxycycline 100 mg 2x/day		Minimal or temporary improvment	No haematologic or internal malignancy
Ryan *et al.* (2012)[37]	Australia	Case report	1		8 cycles chlorambucil 10 mg/day for 14 days with a 14-day break		Significantly improvement, 2y later remains in remission with no recurrences	Chronic lymphocytic leukaemia (CLL)
Ziemer *et al.* (2012)[36]	Germany	Case report	1		0.5 g IVIG/kg bodyweight at 4 consecutive days at a 4-week interval		Remission	Monoclonal gammopathy IgG-lambda of undetermined significance
Hashemi *et al.* (2012)[3]	USA	Case report	1		Oral cyclophosphamide and oral dexamethasone		Worsening of skin lesions	Gammopathy of undetermined significance
Naghashpour *et al.* (2011)[62]	USA	Case report	1		6 cycles of fludarabine, cyclophosphamide and rituximab (FCR)		Complete resolution after 2 cycles	Immunoglobulin G paraproteinemia and small lymphocytic lymphoma

© 2016 European Academy of Dermatology and Venereology

14683083, 2017, 2, Downloaded from https://onlinelibrary.wiley.com/doi/10.1111/jdv.13786 by University Of Toronto Libraries, Wiley Online Library on [15/06/2023]. See the Terms and Conditions (https://onlinelibrary.wiley.com/terms-and-conditions) on Wiley Online Library for rules of use; OA articles are governed by the applicable Creative Commons License

Table 1 *Continued*

Author (Year)	Country	Study type	No. of patients	Topical and intralesional agents	Systemic agents	Physical modalities	Results	Haematological or internal malignancies
Szalat *et al.* (2011)[63]	France	Retrospective study	1 1 1 2 1 1 1		Thalidomide Steroids/immunosuppressive therapy Thalidomide/bortezomib Steroids/chlorambucil Chlorambucil/rituximab/ fludarabine/cyclophosphamide Chlorambucil/rituximab/ fludarabine/cyclophosphamide/ thalidomide/dexamethasone Melphalan/prednisone/interferon-α		No improvement No improvement Partial response Partial response Very good partial response Very good partial response Very good partial response	Stage I multiple myeloma Stage I multiple myeloma Monoclonal gammopathy of unknown significance (MGUS)/myelodysplasia Monoclonal gammopathy of unknown significance (MGUS). Lymphoma Monoclonal gammopathy of unknown significance (MGUS) Overt multiple myeloma
Kawakami and Yamamoto (2011)[32]	Japan	Case report	1		Oral prednisolone 20 mg daily (0.5 mg/kg) 4 weeks		Resolution of the skin lesions, no recurrence after 6 months	M-peak with IgG λ paraproteinemia
Efebera *et al.* (2011)[34]	USA	Case report	1		Thalidomide and dexamethasone		Complete resolution of the skin lesions	Monoclonal gammopathy IgG-kappa
Balagula *et al.* (2011)[22]	USA	Case report	1	Topical clobetasol 0,05% cream			No info	Waldenström macroglobulinemia
Oestreicher *et al.* (2010)[64]	Canada	Case report	1			Radiotherapy, surgery	Patient died 2 days after treatment due to a pulmonary embolus	No info
Reddy *et al.* (2010)[47]	USA	Case report	1	Antibiotic	Lenalidomide, dexamethasone, cladribine, systemic antibiotic	Hyperbaric oxygen, surgery	Significant improvement and control of the disease	Multiple myeloma
Hallermann *et al.* (2010)[11]	Germany	Case report	1		10. Cycles IVIg, 0.5 g/kg/day, for 4 consecutive days at 4-week intervals		Almost complete resolution of infiltrates	Multiple myeloma
Dilnawaz (2010)[23]	UK	Case report	1	Clobetasol 17-propionate and emollients			No info	Monoclonal gammopathy of unknown significance (MGUS).
Silapunt and Chon (2010)[65]	USA	Case report	1		Lenalidomide		Resolution of paraproteinemia was associated with resolution of NXG	MGUS

© 2016 European Academy of Dermatology and Venereology

14683083, 2017, 2, Downloaded from https://onlinelibrary.wiley.com/doi/10.1111/jdv.13786 by University Of Toronto Libraries, Wiley Online Library on [15/06/2023]. See the Terms and Conditions (https://onlinelibrary.wiley.com/terms-and-conditions) on Wiley Online Library for rules of use; OA articles are governed by the applicable Creative Commons License

Table 1 *Continued*

Author (Year)	Country	Study type	No. of patients	Topical and intralesional agents	Systemic agents	Physical modalities	Results	Haematological or internal malignancies
Al-Niaimi *et al.* (2010)[24]	UK	Case report	1	Very potent topical steroids (initial)		Oral PUVA treatment	Gradual improvement with very satisfactory results after beginning PUVA treatment.	No haematologic or internal malignancy
Gacto *et al.* (2009)[53]	Spain	Case series	2		Cyclophosphamid and prednisone	Surgery	Partial response with the systemic agents, complete after surgery	one Patient with MGUS
Khan *et al.* (2009)[66]	UK	Case report	1		Oral dexamethasone and oral cyclophosphamide		Lesions improved dramatically to almost complete resolution, no recurrence	Monoclonal paraproteinemia IgG- λ
Wood *et al.* (2009)[6]	USA	Retrospective study	2 4 1 1 1 2 2	Intralesional corticosteroids and topical immunomodulators	Chemotherapy Chlorambucil and Prednisone Melphalan and prednisone Pulse dexamethasone treatment cycles for 1 year Thalidomide und Prednisone	Radiotherapy (15-24 Gy)	Improvement of the lesions 2 achieved an excellent response, 2 showed no improvement Partial response Marked improvement in skin lesions Remission of skin lesions for 2 years Partial improvement in one patient and complete clearence of lesions in the other patient No response	Twelve patients (71%) had a serum monoclonal gammopathy (kappa gammopathy in 8 [47%] and gamma gammopathy in 4 [24%]), and 3 (18%) had multiple myeloma
Rayner *et al.* (2008)[67]	UK	Case report	1		Melphalan and prednisolone		The lesions had regressed	Monoclonal gammopathy IgG-kappa
Saeki *et al.* (2007)[58]	Japan	Case report	1		Melphalan and prednisolone	Skin graft	Improvement of the lesions and remission	Immunoglobulin Gκ paraproteinemia
Goede *et al.* (2007)[68]	Switzerland	Case report	1		High-dose chemotherapy	Autologous stem cell transplantation	Cosmetic and functional recovery was achieved	Immunoglobulin Gκ paraproteinemia

© 2016 European Academy of Dermatology and Venereology

14683083, 2017, 2, Downloaded from https://onlinelibrary.wiley.com/doi/10.1111/jdv.13786 by University Of Toronto Libraries, Wiley Online Library on [15/06/2023]. See the Terms and Conditions (https://onlinelibrary.wiley.com/terms-and-conditions) on Wiley Online Library for rules of use; OA articles are governed by the applicable Creative Commons License

Table 1 *Continued*

Author (Year)	Country	Study type	No. of patients	Topical and intralesional agents	Systemic agents	Physical modalities	Results	Haematological or internal malignancies
Elner *et al.* (2006)[21]	USA	Case series	1 1 1 1	Intralesional injection of triamcinolone acetonide Intralesional injection of triamcinolone acetonide Intralesional injection of triamcinolone acetonide			Improvement Improvement Improvement Stable	None NHL MGUS CLL, MDS
Torabian *et al.* (2006)[69]	USA	Case report	1		Chlorambucil		Flattening and complete resolution of his skin lesions	Monoclonal gammopathy of the IgG-lambda type
Smith *et al.* (2006)[55]	USA	Case report	1			Surgical removal of the lesion	After 24 months of follow-up, the patient has remained symptom free	Slightly elevated IgG-κ and IgG-λ paraproteins
Oumeish *et al.* (2006)[25]	Jordan	Case report	1	Topical corticosteroids	Cyclophosphamid, prednisolone, chlorambucil, melphalan, cyclosporin		Unsatisfactory	Chronic lymphocytic leukaemia
Flann *et al.* (2006)[2]	UK	Case series	1 1 1 1	 Topical corticosteroids Topical therapy (not specified)	Cyclophosphamide Chlorambucil Cyclophosphamide, chlorambucil		No clinical or haematological response Moderate improvement Almost complete resolution of all skin lesions No improvement	IgG-kappa paraproteinaemia Slight diffuse increase in gamma globulins IgG-kappa paraproteinaemia IgG-kappa paraproteinaemia
Wee and Shupack (2005)[26]	USA	Case report	1	Topical glucocorticoids		Nd-YAG laser, and local surgical excision	Persistence of skin lesions	Elevated gamma-globulin
Ziemer *et al.* (2005)[42]	Germany	Case report	1		Clofazimine, prednisolone, dapsone, minocycline, melphalan	Bath-PUVA	No effect, rapid progression under treatment with melphalan	IgG-kappa paraproteinemia

© 2016 European Academy of Dermatology and Venereology

14683083, 2017, 2, Downloaded from https://onlinelibrary.wiley.com/doi/10.1111/jdv.13786 by University Of Toronto Libraries, Wiley Online Library on [15/06/2023]. See the Terms and Conditions (https://onlinelibrary.wiley.com/terms-and-conditions) on Wiley Online Library for rules of use; OA articles are governed by the applicable Creative Commons License

Table 1 *Continued*

Author (Year)	Country	Study type	No. of patients	Topical and intralesional agents	Systemic agents	Physical modalities	Results	Haematological or internal malignancies
Vieira *et al.* (2005)[51]	Spain	Case report	1	Mupirocine		Dioxid carbon laser 5W/cm² over 4 weeks	Great improvement of cutaneous lesions and no relapse after a 12-month follow-up	Lymphoplasmacytic lymphoma associated with IgG monoclonal gammopathy
Kraft *et al.* (2004)[48]	Canada	Case report	1		Infliximab		Patient was responding and continues to improve	Discrete gammopathy/ paraproteinemia
Amer *et al.* (2005)[27]	Israel	Case report	1	Topical corticosteroids			Good response	Paraproteinemia of IgG-kappa
Meyer *et al.* (2005)[41]	Germany	Case report	1		Cyclophosphamide –dexamethasone		Significant decrease in size and an almost complete resolution of their inflammatory aspect	Monoclonal paraproteinemia type IgG-kappa
Wells *et al.* (2004)[70]	Australia	Case report	1		Chlorambucil		Supressed the disease to some extent	Monoclonal gammopathy of unknown significance (MGUS)
Schaudig and Al-Samir (2004)[59]	Germany	Case report	1			Surgical removal and reconstruction	The transplanted area remained free of disease	A monoclonal IgG (Kappa) paraproteinemia
Shah *et al.* (2004)[38]	India	Case report	1		Chlorambucil	Surgery	Lesions regressed by 80–90%	No haematologic or internal malignancy
Martínez Fernández *et al.* (2004)[56]	Spain	Case report	1		Melphalan	Surgery	Nineteen months after the surgery, there was no evident relapse of the xanthogranuloma	Multiple myeloma
Chang *et al.* (2003)[71]	South Korea	Case report	1		Oral steroid (0.5–0.6 mg/kg) and NSAIDS for 1 month		Partial improvement of pain and the lesion ceased to enlarge	No haematologic or internal malignancy
Criado *et al.* (2002)[72]	Brazil	Case report	1		Melphalan 0.15 mg/kg per day per os and prednisone 20 mg/day per os		Great improvement of cutaneous lesions and paraproteinemia remission.	Lambda paraproteinemia
Spraul *et al.* (2002)[73]	Germany	Case report	1		Melphalan 0,25 mg/kg KG and 2 mg/kg KG		Partly improvement of the lesions	Monoclonal gammopathy of unknown significance (MGUS)
Chandra *et al.* (2002)[54]	Australia	Case report	1			Surgery	1 year after the surgery, the patient has had no recurrence of NXG	No haematologic or internal malignancy
Machado *et al.* (2001)[74]	Portugal	Case report	1		Chlorambucil 2 mg/day for 7 months		Disappearance of all skin lesions	Monoclonal gammopathy of the IgGλ type

© 2016 European Academy of Dermatology and Venereology

14683083, 2017, 2, Downloaded from https://onlinelibrary.wiley.com/doi/10.1111/jdv.13786 by University Of Toronto Libraries, Wiley Online Library on [15/06/2023]. See the Terms and Conditions (https://onlinelibrary.wiley.com/terms-and-conditions) on Wiley Online Library for rules of use; OA articles are governed by the applicable Creative Commons License

Table 1 *Continued*

Author (Year)	Country	Study type	No. of patients	Topical and intralesional agents	Systemic agents	Physical modalities	Results	Haematological or internal malignancies
Westermann *et al.* (2001)[75]	Germany	Case report	1		Chlorambucil, prednisolone, interferon alpha-2a		Some improvement	Elevated monoclonal IgG-lambda protein
Chave *et al.* (2001)[33]	UK	Case report	1		High-dose dexamethasone and maintenance with prednisolone		Improvement of the cutaneous lesions, and a fall in the IgG k paraprotein levels	IgG-kappa paraproteinemia
Kossard *et al.* (2000)[76]	USA	Case report	1		Cyclophosphamid and prednisone		The skin lesions markedly resolved	A monoclonal IgG (Kappa) paraproteinemia
Stork *et al.* (2000)[57]	Czech Republic	Case report	1			Surgery	After 4 years no signs of paraproteinemia, malignancy, or new skin lesions	No haematologic or internal malignancy
Ugurlu *et al.* (2000)[9]	USA	Retrospective study	17 3 2		Chemotherapy Chemotherapy	 Local radiation of 1500 to 2400 cGy Radiation	Improvement of the lesions in 10 patients Improvement of the lesions in one patient Improvement of the lesions in two patients	Of the 26 patients, 20 had an IgG monoclonal serum paraprotein
Georgiou *et al.* (1999)[30]	Greece	Case report	1	Recombinant interferon- α, 3x/week over a period of 4 months			Complete remission and after 2 years, no recurrence	No haematologic or internal malignancy
Nestle *et al.* (1999)[77]	Switzerland	Case report	1		Low-dose melphalan		Clinical response with decrease in the inflammatory and infiltrative component	Monoclonal gammopathy of the IgGλ type
Barzilai *et al.* (1996)[28]	Israel	Case report	1	Wet dressings, topical steroids, and antibiotics			No info	A monoclonal IgG (Kappa) paraproteinemia
Criton *et al.* (1996)[43]	India	Case report	1		Prednisolone, cyclophosphamide and vincristine		Patient responded very well	Serum protein electrophoresis showed myeloma band
Venencie *et al.* (1995)[31]	Germany	Case report	1	sc recombinant interferon alpha-2b 6 million IU 3x/week	Oral prednisone 30 mg/day		All the lesions flattened with residual pigmentation and the monoclonal spike decreased	A monoclonal IgG (Kappa) paraproteinemia

© 2016 European Academy of Dermatology and Venereology

14683083, 2017, 2, Downloaded from https://onlinelibrary.wiley.com/doi/10.1111/jdv.13786 by University Of Toronto Libraries, Wiley Online Library on [15/06/2023]. See the Terms and Conditions (https://onlinelibrary.wiley.com/terms-and-conditions) on Wiley Online Library for rules of use; OA articles are governed by the applicable Creative Commons License

Table 1 *Continued*

Author (Year)	Country	Study type	No. of patients	Topical and intralesional agents	Systemic agents	Physical modalities	Results	Haematological or internal malignancies
Hauser *et al.* (1991)[78]	Switzerland	Case report	1		Melphalan, cyclophosphamid, plasmapheresis, fresh-frozen plasma, thalidomide, etretinate		Lesions improvement after melphalan	A monoclonal IgG (Kappa) paraproteinemia
Reeder *et al.* (1991)[79]	USA	Case report	1		Chemotherapy (nitrogen mustard, vincristine sulphate, prednisone, procarbazine hydrochloride, doxorubicin hydrochloride, and bleomycin sulphate)		Clinical remission	Hodgkin's disease
Plotnick *et al.* (1991)[80]	USA	Case report	1		Melphalan, pulsed high-dose oral dexamethasone		Healing of the lesions	Stage I multiple myeloma
Valentine *et al.* (1990)[81]	USA	Case report	1		Alkeran and prednisone		Complete resolution	IgA multiple myeloma
Luck *et al.* (1992)[82]	UK	Case report	1		Low-dose Chlorambucil 4 mg/day		6 weeks later, subjective improvement	IgG monoclonal paraproteinaemia
Finelli and Ratz (1987)[60]	USA	Case report	1	10% benzoyl peroxide dressings	Hydroxychloroquine	Plasmapheresis	Ulcers showed nearly complete healing	A monoclonal IgG (Kappa) paraproteinemia
Venencie *et al.* (1987)[44]	France	Case report	1		Vincristine, melphalan, cyclophosphamide, prednisone		Cutaneous lesions had flattened	A monoclonal IgG (Kappa) paraproteinemia
Char *et al.* (1987)[52]	USA	Case report	1			Local radiation of 22,5 Gy	Abnormalities disappeared within 2 weeks after irradiation	Gamma spike on protein electrophoresis
Holden and Winkelmann (1986)[83]	UK	Case series	1		Prednisolone, chlorambucil, ccyclophosphamid		Maintenance under prednisolone, worsening with chlorambucil and cyclophosphamid	Faint IgG monoclonal band with reduction of total globulins
			2		Prednisolone		Partial response	Dysproteinemia
Bullock *et al.* (1986)[84]	USA	Case report	1		Melphalan and prednisone		Lesions have persisted without changed	Multiple myeloma

© 2016 European Academy of Dermatology and Venereology

14683083, 2017, 2, Downloaded from https://onlinelibrary.wiley.com/doi/10.1111/jdv.13786 by University Of Toronto Libraries, Wiley Online Library on [15/06/2023]. See the Terms and Conditions (https://onlinelibrary.wiley.com/terms-and-conditions) on Wiley Online Library for rules of use; OA articles are governed by the applicable Creative Commons License

Table 1 *Continued*

Author (Year)	Country	Study type	No. of patients	Topical and intralesional agents	Systemic agents	Physical modalities	Results	Haematological or internal malignancies
Finan and Winkelmann (1986)[19]	USA	Retrospective study (total of 22 patients)	6		Chlorambucil		Improvement in three patients	20 of the 22 patients had 1 or more serum protein abnormalities
			3		Melphalan		Partial remission in one patient	
			2		Melphalan and prednisone		Partial remission in two patients	
			1		Chlorambucil and prednisone		Partial remission in one patient	
			2		Cyclophosphamid		No info	
			2		Azathioprine		Partial remission in one patient	
			1		Nitrogen mustard		No info	
			1		Methotrexate		No info	
			12		Corticosteroids alone		Improvement in four patients	
			6			Surgery	Improvement in one patient	
			7	Intralesional steroids			Improvement in two patients	
			5				No improvement	
			2	Topical steroids		Radiotherapy	Improvement in one patient	
Macfarlane and Verbov (1985)[85]	UK	Case report	1		Melphalan (0,15 mg/kg/day)		Definitive improvement in 5 weeks	A monoclonal IgG (Kappa) paraproteinemia
Codère *et al.* (1983)[29]	Canada	Case series	1	Intralesional triamcinolone		Surgery	Improvement of skin lesions	A monoclonal IgG (Kappa) paraproteinemia
			1		Prednisone (40 mg/day, oral)		Improvement of skin lesions and appearance of new ones	A monoclonal IgG (Kappa) paraproteinemia

ECP, Extracorporeal photopheresis; IVIG, intravenous immunoglobulin; NXG, Necrobiotic xanthogranuloma.

© 2016 European Academy of Dermatology and Venereology

14683083, 2017, 2, Downloaded from https://onlinelibrary.wiley.com/doi/10.1111/jdv.13786 by University Of Toronto Libraries, Wiley Online Library on [15/06/2023]. See the Terms and Conditions (https://onlinelibrary.wiley.com/terms-and-conditions) on Wiley Online Library for rules of use; OA articles are governed by the applicable Creative Commons License

five patients after intralesional application. Eight patients represented a worsening of skin affection after topical or intralesional steroid local therapy. In nine patients, no information about treatment outcome was provided. In one patient, skin affection remained stable after intralesional injection of triamcinolone acetonide.[2,6,19,21–29]

Interferon-α Interferon alpha has profound modulatory effects on proliferation, differentiation and immune potential of different tissues. Two patients responded positively to treatment with subcutaneous injections of human recombinant interferon alpha-2a. One of them, only treated with interferon-α, remained without relapsing into NXG 22 months after end of therapy.[30,31]

Systemic agents

Systemic corticosteroids Systemic steroids are not enthusiastically recommended as monotherapy, rather combined, i.e. with alkylating agents, as there is a high relapse rate after treatment discontinuation. Despite this, systemic corticosteroid monotherapy should be considered when other modalities are unsuccessful, contraindicated or if an underlying haematological condition does not exist.[32] Chave *et al.* reported a patient responding to a high-dose pulsed oral dexamethasone therapy with maintenance with oral prednisolone.[33]

Immunomodulatory drugs These novel agents used in the treatment of haematologic diseases are potentially promising in NXG, perhaps due to their wide spectrum effects on the immune system. Thalidomide and lenalidomide have been used separately or combined with dexamethasone showing satisfactory results. The length of systemic treatment is not defined and further reports are needed.[13,18,34]

High-dose intravenous immunoglobulin Known for having diverse immunoregulatory effects including decreasing the activation of autoreactive T cells, intravenous immunoglobulin (IVIG) showed rapid therapeutic efficacy with almost complete remission in three patients suffering from NXG with underlying haematologic disease (multiple myeloma, MGUS).[11,35,36] High-dose IVIG treatment should be considered when other treatment modalities have failed.

Alkylating agents (Chlorambucil, cyclophosphamide, melphalan, nitrogen mustards) About 50 patients with NXG underwent treatment with alkylating agents either alone or combined, with the most popular combination being Chlorambucil, cyclophosphamide or melphalan with corticosteroids (Table 2). Alkylating agents are currently the most common treatment for NXG. Chlorambucil is usually used in low-doses (2–4 g/day) and in NXG with paraproteinemia. However, cases without associated haematologic disease treated with Chlorambucil have also been reported.[7,37,38] The disadvantages of this treatment are the multiple complications of an increased risk of secondary malignancy and bone marrow suppression. Ryan *et al.* suggested the use of Chlorambucil as first-line therapy in selected patients with NXG.[37] Cyclophosphamide is a potent immunosuppressive agent, which affects cells in all phases of the cell cycle and causes as main side-effects, nausea, vomiting, alopecia, leucopenia and urotoxicity with haemorrhagic cystitis. Emesis prophylaxis and bladder protection with mesna should be provided.[39–41] Cyclophosphamide treatment must be reserved for patients with recalcitrant disease. Responses to treatment with melphalan are variable and although the larger part is satisfactory, there are some cases with disease progress.[42] Vincristine has also been used in combination with alkylating agents showing a good response rate.[43,44]

Cladribine This cytotoxic agent also called 2-Chlorodeoxyadenosine is a purine nucleoside analogue with high activity in lymphoid and myeloid malignancies and some autoimmune disorders. Several studies have demonstrated a good efficacy and acceptable toxicity when combined with other cytotoxic drugs.[45] A recent report showed some success when used alone in treatment of isolated NXG, but it was discontinued due to pancytopenia.[46] Another report showed significant improvement of cutaneous disease, when used as adjuvant therapy with hyperbaric oxygen and surgery, in a patient with NXG and underlying multiple myeloma resistant to lenalidomide and dexamethasone treatment.[47]

Table 2 Patients' response to treatment with alkylating agents

	Chlorambucil	Chlorambucil with corticosteroid	Melphalan	Melphalan with corticosteroid	Cyclophosphamide	Cyclophosphamide with corticosteroid	Combined therapy/Other
Very good response	6	2	3	3		3	7
Partial response	4	3	4	5	1	2	2
No effect		2		1	1		1
Worsening or recurrence			1	1		1	3

© 2016 European Academy of Dermatology and Venereology

14683083, 2017, 2, Downloaded from https://onlinelibrary.wiley.com/doi/10.1111/jdv.13786 by University Of Toronto Libraries, Wiley Online Library on [15/06/2023]. See the Terms and Conditions (https://onlinelibrary.wiley.com/terms-and-conditions) on Wiley Online Library for rules of use; OA articles are governed by the applicable Creative Commons License

Antimetabolites (azathioprine, methotrexate) A retrospective study from Finan and Winkelmann reports partial remission in a patient treated with azathioprine alone, and no information about response to methotrexate in another patient.[19] The clinical course of a patient receiving methotrexate and azathioprine resulted in new skin lesions.[1] The use of antimetabolites as azathioprine and methotrexate refers to reports from 1980 to 1986; recent studies do not include this treatment.

Infliximab Kraft *et al.* reported a case of a patient undergoing anti-TNF- α therapy resulting in improvement of the lesions after resistance to other therapies. Due to the important role of macrophages in NXG and the favourable results of infliximab, addressing necrobiosis lipoidica diabeticorum, physicians should be alert to this potential therapy option.[48] Another patient showed significant improvement of skin lesions but treatment was discontinued due to repeated infections.[49]

Other therapies Isolated cases using different treatment schemas including rituximab, cyclosporine, fludarabine, bortezomib, vincristine, etretinate, clofazimine and dapsone among others have been reported.

Physical modalities

Laser therapy The use of Q-switched 650-nm wavelength laser in atypical facial hyperpigmentation associated with NXG resulted in whitening of the skin and no recurrence after a 5-month follow-up.[50] Persistence of skin lesions occurred in one patient despite treatment with Ng-YAG laser[26] and great improvement was described in a patient with buttock and periorbital disease after treatment with dioxide carbon laser.[51]

Radiotherapy Up to now, nine patients were reported to have been treated with radiotherapy with variable results; one died 2 days after treatment due to a pulmonary embolus. In five patients with periocular involvement, one had partial improvement after radiation and two ameliorated after radiation combined with chemotherapy.[9] In relation to two other patients, skin lesions partially improved after radiation recurring after a while in one, and the other patient, previously treated unsuccessfully with chlorambucil and prednisone, had complete clearance of lesions on the parotid gland and left lung after radiation.[6] Char *et al.*, reported a patient successfully treated after 22, 5 Gy irradiation of the left orbit, remaining in remission after 2.5 years.[52] Radiotherapy may be used preferably in patients with periorbital affection not carrying a haematologic condition.

Surgery Due to its high recurrence rate (42%) within 6–12 months, surgical removal of NXG lesions is not recommended outside the diagnostic biopsy. Besides that, in majority of the cases, the recurrent skin manifestations are larger than the former ones.[9] Local management of ulcers and secondary infections is encouraged.[2] Five different studies reported successful treatment showing no relapse 1 year after surgery in three patients, 2 years after intervention in one patient, 19 months after procedure in one patient and 4 years after in another patient.[53–57] Other authors propose cycles of melphalan and prednisone after surgery to maintain remission.[58] Mechanisms of recurrence are unclear and relapse of skin disease after surgery mainly occurs during phases of high disease activity.[59] Thus, we recommend surgery approach in NXG of the eyelid or limited skin affection in patients with controlled haematological condition.

PUVA therapy Due to the successful use of PUVA treatment in many necrobiotic conditions, such as granuloma annulare and necrobiosis lipoidica, its use in NXG was proposed. A recent report discloses very satisfactory results after 47 treatments of PUVA using 8-methoxypsoralen in a patient with isolated NXG.[24] Another group reported no therapeutic effect after bath-PUVA in a patient with disseminated NXG associated with IgG-kappa paraproteinemia.[42] More studies covering this topic are needed since this could be a good alternative compared to other systemic agents.

Plasmapheresis Paraproteinemia has been successfully managed with plasmapheresis, leading to its rational use in treatment of NXG. Finelli and Ratz reported a case of NXG associated with an IgG paraproteinemia treated with plasmapheresis, 10% benzoyl peroxide and hydroxychloroquine resulting in an almost complete healing of skin lesions and improvement of paraproteinemia. We should not assign the results only to plasmapheresis; more cases about this medical procedure in NXG are required.[60]

Extracorporeal photopheresis In Extracorporeal photopheresis (ECP), about 10–20% of the body's leucocytes are isolated from the patient's blood, then extracorporally exposed to photoactivated 8-methoxypsoralen and reinfused back to the patient. While the exact mechanism of ECP is still not completely understood, it seems that exposure of the immune system to physically modified T-cell clones may lead to a specific inhibition of T-cell-mediated autoimmunity in diseases where T cells play a major role. A recent report showed regression of the skin lesions in a patient with NXG without paraproteinemia during the 2 years of receiving ECP. Photopheresis should be considered in patients with recalcitrant NXG, not responding to other therapies or with other diseases due to its good tolerability and safety when combined with other modalities.[46,49]

Discussion

NXG is a chronic, progressive and destructive granulomatous disease of the skin and extracutaneous tissues. Multiple organs may be affected, and it is usually associated with monoclonal

 © 2016 European Academy of Dermatology and Venereology

14683083, 2017, 2, Downloaded from https://onlinelibrary.wiley.com/doi/10.1111/jdv.13786 by University Of Toronto Libraries, Wiley Online Library on [15/06/2023]. See the Terms and Conditions (https://onlinelibrary.wiley.com/terms-and-conditions) on Wiley Online Library for rules of use; OA articles are governed by the applicable Creative Commons License

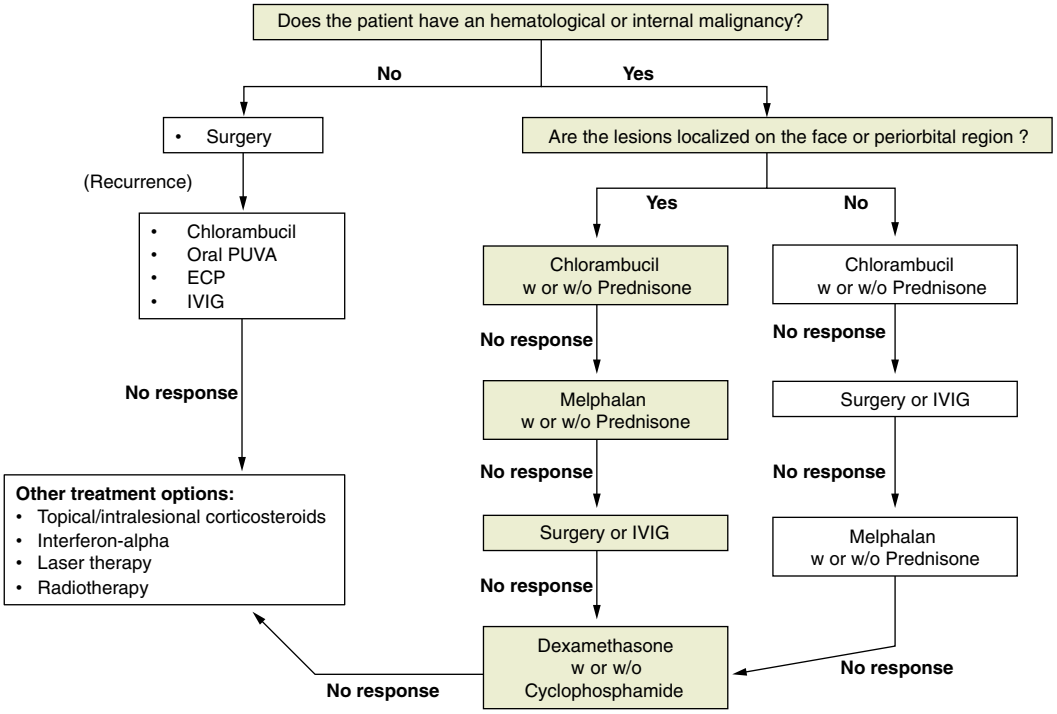

Figure 2 Algorithm developed by the authors suggesting an approach to Necrobiotic xanthogranuloma (NXG) therapy based on the current systematic review.

gammopathies. Clinical response is difficult to classify as a standard grading scale for severity of NXG does not exist. In our systematic review, clinical response or 'results' is mainly based on the individual report of each author. This makes comparison between studies more difficult and limits the reliability of our findings. Therapy of NXG is frequently unsuccessful, although many different modalities have been used. Low successful rates in treatment of NXG may likely be a reason for the small number of cases published in literature. We encourage authors to report their cases, whether treatment objectives are accomplished or not, in order to provide information about which options should be preferred/excluded. Evaluation of therapeutic outcomes is difficult and information about remission durability is scarce. Studies about long-term outcomes after treatment are needed. Another point of relevance in our work is that patient's response rates may be overestimated, as most authors prefer to publish reports for which some treatment response was accomplished. Thereby, and since NXG is rare and treatment is difficult, important data may remain concealed. Due to rarity of the condition, randomized controlled trials are difficult to perform and up to now no first-line therapy has been recommended. We hereby suggest an approach to NXG therapy based on the current review(Fig. 2).

Treatment decision should be made according to disease extent, underlying haematologic conditions, related diseases, size and location of skin lesions, and side-effects. Physicians should advise patients that some of the proposed treatment modalities currently available, are off label use, and that most of their decisions concerning this issue are made based on current case reports and actualized reviews. Randomized clinical trials or N-of-1 trials (CENT) are required in order to define treatment of choice.

References

1 Kossard S, Winkelmann RK. Necrobiotic xanthogranuloma with paraproteinemia. *J Am Acad Dermatol* 1980; **3**: 257–270.
2 Flann S, Wain EM, Halpern S, Andrews V, Whittaker S. Necrobiotic xanthogranuloma with paraproteinaemia. *Clin Exp Dermatol* 2006; **31**: 248–251.
3 Hashemi P, Rashidi A, Chapas AM, Balfour EM. Necrobiotic xanthogranuloma of the extremities with paraproteinemia and without periorbital involvement at presentation. *Cutis* 2012; **89**: 41–44.
4 Rose A, Robinson M, Kamino H, Latkowski JA. Necrobiotic xanthogranuloma. *Dermatol Online J* 2012; **18**: 30.
5 Inthasotti S, Wanitphakdeedecha R, Manonukul J. A 7-Year history of necrobiotic xanthogranuloma following asymptomatic multiple myeloma: a case report. *Dermatol Res Pract* 2011; **2011**: 927852.
6 Wood AJ, Wagner MV, Abbott JJ, Gibson LE. Necrobiotic xanthogranuloma: a review of 17 cases with emphasis on clinical and pathologic correlation. *Arch Dermatol* 2009; **145**: 279–284.
7 Spicknall KE, Mehregan DA. Necrobiotic xanthogranuloma. *Int J Dermatol* 2009; **48**: 1–10.
8 Mehregan DA, Winkelmann RK. Necrobiotic xanthogranuloma. *Arch Dermatol* 1992; **128**: 94–100.

© 2016 European Academy of Dermatology and Venereology

14683083, 2017, 2, Downloaded from https://onlinelibrary.wiley.com/doi/10.1111/jdv.13786 by University Of Toronto Libraries, Wiley Online Library on [15/06/2023]. See the Terms and Conditions (https://onlinelibrary.wiley.com/terms-and-conditions) on Wiley Online Library for rules of use; OA articles are governed by the applicable Creative Commons License

9 Ugurlu S, Bartley GB, Gibson LE. Necrobiotic xanthogranuloma: long-term outcome of ocular and systemic involvement. *Am J Ophthalmol* 2000; **129**: 651–657.
10 Bhari N, Chiramel MJ, Vedi KK *et al.* Necrobiotic xanthogranuloma with multiple myeloma. *Clin Exp Dermatol* 2015; **40**: 811–814.
11 Hallermann C, Tittelbach J, Norgauer J, Ziemer M. Successful treatment of necrobiotic xanthogranuloma with intravenous immunoglobulin. *Arch Dermatol* 2010; **146**: 957–960.
12 Fortson JS, Schroeter AL. Necrobiotic xanthogranuloma with IgA paraproteinemia and extracutaneous involvement. *Am J Dermatopathol* 1990; **12**: 579–584.
13 Ghani S, Al Ustwani O, Khalid B *et al.* Periorbital necrobiotic xanthogranuloma treated successfully with novel multiple myeloma therapy. *Clin Adv Hematol Oncol* 2013; **11**: 678–680.
14 Gun D, Demircay Z, Demirkesen C. Necrobiotic xanthogranuloma in a burn scar. *Int J Dermatol* 2004; **43**: 293–295.
15 Sabet LM, Wexler D, Salama S, Gan BS. An unusual cause of refractive chronic bilateral leg ulceration. *J Cutane Med Surg* 2004; **8**: 432–437.
16 Bara C, Barbarot S, Hamidou M *et al.* Systemic necrobiotic xanthogranuloma with initial pericardial and pulmonary involvement. *Ann Dermatol Venereol* 2003; **130**: 341–344.
17 Zelger B, Eisendle K, Mensing C, Zelger B. Detection of spirochetal micro-organisms by focus-floating microscopy in necrobiotic xanthogranuloma. *J Am Acad Dermatol* 2007; **57**: 1026–1030.
18 Szalat R, Pirault J, Fermand JP *et al.* Physiopathology of necrobiotic xanthogranuloma with monoclonal gammopathy. *J Intern Med* 2014; **276**: 269–284.
19 Finan MC, Winkelmann RK. Necrobiotic xanthogranuloma with paraproteinemia. a review of 22 cases. *Medicine*. 1986; **65**: 376–388.
20 Winkelmann RK, Dahl PR, Perniciaro C. Asteroid bodies and other cytoplasmic inclusions in necrobiotic xanthogranuloma with paraproteinemia. *J Am Acad Dermatol* 1998; **38**: 967–970.
21 Elner VM, Mintz R, Demirci H, Hassan AS. Local corticosteroid treatment of eyelid and orbital xanthogranuloma. *Ophthalmic Plast Reconstr Surg* 2006; **22**: 36–40.
22 Balagula Y, Straus DJ, Pulitzer MP, Lacouture ME. Necrobiotic xanthogranuloma associated with immunoglobulin m paraproteinemia in a patient with Waldenstrom macroglobulinemia. *J Clin Oncol* 2011; **29**: e305–e307.
23 Dilnawaz M. An unusual skin presentation of necrobiotic xanthogranuloma. *J Coll Physicians Surg Pak* 2010; **20**: 274–275.
24 Al-Niaimi FA, Dawn G, Cox NH. Necrobiotic xanthogranuloma without paraproteinaemia: marked improvement with psoralen ultraviolet a treatment. *Clin Exp Dermatol* 2010; **35**: 275–277.
25 Oumeish OY, Oumeish I, Tarawneh M, Salman T, Sharaiha A. Necrobiotic xanthogranuloma associated with paraproteinemia and non-Hodgkin's lymphoma developing into chronic lymphocytic leukemia: the first case reported in the literature and review of the literature. *Int J Dermatol* 2006; **45**: 306–310.
26 Wee SA, Shupack JL. Necrobiotic xanthogranuloma. *Dermatol Online J* 2005; **11**: 24.
27 Amer R, Pe'er J, Pappo O, Dotan S. Necrobiotic xanthogranuloma associated with choroidal infiltration and syncytial giant cell hepatitis. *J Neuroophthalmol* 2005; **25**: 189–192.
28 Barzilai A, Trau H, Shpiro D, Yorav S. Necrobiotic xanthogranuloma with paraproteinemia. *Cutis* 1996; **57**: 320–322.
29 Codere F, Lee RD, Anderson RL. Necrobiotic xanthogranuloma of the eyelid. *Arch Ophthalmol* 1983; **101**: 60–63.
30 Georgiou S, Monastirli A, Kapranos N, Pasmatzi E, Sakkis T, Tsambaos D. Interferon alpha-2a monotherapy for necrobiotic xanthogranuloma. *Acta Derm Venereol* 1999; **79**: 484–485.
31 Venencie PY, Le Bras P, Toan ND, Tchernia G, Delfraissy JF. Recombinant interferon alfa-2b treatment of necrobiotic xanthogranuloma with paraproteinemia. *J Am Acad Dermatol* 1995; **32**: 666–667.
32 Kawakami Y, Yamamoto T. Letter: necrobiotic xanthogranuloma of extremities in an elderly patient successfully treated with low-dose prednisolone. *Dermatol Online J* 2011; **17**: 13.
33 Chave TA, Chowdhury MM, Holt PJ. Recalcitrant necrobiotic xanthogranuloma responding to pulsed high-dose oral dexamethasone plus maintenance therapy with oral prednisolone. *Br J Dermatol* 2001; **144**: 158–161.
34 Efebera Y, Blanchard E, Allam C, Han A, Lee S, Munshi N. Complete response to thalidomide and dexamethasone in a patient with necrobiotic xanthogranuloma associated with monoclonal gammopathy: a case report and review of the literature. *Clin Lymphoma Myeloma Leuk* 2011; **11**: 298–302.
35 Rubinstein A, Wolf DJ, Granstein RD. Successful treatment of necrobiotic xanthogranuloma with intravenous immunoglobulin. *J Cutan Med Surg* 2013; **17**: 347–350.
36 Ziemer M, Norgauer J, Simon JC, Koehler MJ. An unusual histologic variant of necrobiotic xanthogranuloma. *Am J Dermatopathol* 2012; **34**: e22–e26.
37 Ryan E, Warren LJ, Szabo F. Necrobiotic xanthogranuloma: response to chlorambucil. *Australas J Dermatol* 2012; **53**: e23–e25.
38 Shah KC, Poonnoose SI, George R, Jacob M, Rajshekhar V. Necrobiotic xanthogranuloma with cutaneous and cerebral manifestations. Case report and review of the literature. *J Neurosurg* 2004; **100**: 1111–1114.
39 Chu CY, Chiu HC. Chemotherapy-induced recall dermatitis on a previously scalded wound in a patient with acute myeloid leukaemia. *Acta Derm Venereol* 2003; **83**: 382–383.
40 Smith KJ, Germain M, Skelton H. Histopathologic features seen with radiation recall or enhancement eruptions. *J Cutan Med Surg* 2002; **6**: 535–540.
41 Meyer S, Szeimies RM, Landthaler M, Hohenleutner S. Cyclophosphamide-dexamethasone pulsed therapy for treatment of recalcitrant necrobiotic xanthogranuloma with paraproteinemia and ocular involvement. *Br J Dermatol* 2005; **153**: 443–445.
42 Ziemer M, Wedding U, Sander CS, Elsner P. Necrobiotic xanthogranuloma-rapid progression under treatment with melphalan. *Eur J Dermatol* 2005; **15**: 363–365.
43 Criton S, Asokan PU, Pailey S, Kuttappan SS. Remani, Rodriguez FP. Necrobiotic xanthogranuloma with paraproteinaemia. *Indian J Dermatol Venereol Leprol* 1996; **62**: 383–385.
44 Venencie PY, Puissant A, Verola O *et al.* Necrobiotic xanthogranuloma with myeloma A case report. *Cancer* 1987; **59**: 588–592.
45 Robak T, Wierzbowska A, Robak E. Recent clinical trials of cladribine in hematological malignancies and autoimmune disorders. *Rev Recent Clin Trials* 2006; **1**: 15–34.
46 Sutton L, Sutton S, Sutton M. Treatment of necrobiotic xanthogranuloma with 2-chlorodeoxyadenosine. *Skinmed* 2013; **11**: 121–123.
47 Reddy VC, Salomao DR, Garrity JA, Baratz KH, Patel SV. Periorbital and ocular necrobiotic xanthogranuloma leading to perforation. *Arch Ophthalmol* 2010; **128**: 1493–1494.
48 Kraft J, Lynde C, Lynde C. Recalcitrant necrobiotic xanthogranuloma responding to infliximab. *J Am Acad Dermatol* 2004; **52**: 59.
49 Liszewski W, Wisniewski JD, Safah H, Boh EE. Treatment of refractory necrobiotic xanthogranulomas with extracorporeal photopheresis and intravenous immunoglobulin. *Dermatol Ther* 2014; **27**: 268–271.
50 Hamilton HK, Dover JS, Arndt KA. Successful treatment of disfiguring hemosiderin-containing hyperpigmentation with the Q-switched 650-nm wavelength laser. *JAMA Dermatol* 2014; **150**: 1221–1222.
51 Vieira V, Del Pozo J, Martinez W, Veiga-Barreiro JA, Fonseca E. Necrobiotic xanthogranuloma associated with lymphoplasmacytic lymphoma. Palliative treatment with carbon dioxide laser. *Eur J Dermatol* 2005; **15**: 182–185.
52 Char DH, LeBoit PE, Ljung BM, Wara W. Radiation therapy for ocular necrobiotic xanthogranuloma. *Arch Ophthalmol* 1987; **105**: 174–175.

 © 2016 European Academy of Dermatology and Venereology

14683083, 2017, 2, Downloaded from https://onlinelibrary.wiley.com/doi/10.1111/jdv.13786 by University Of Toronto Libraries, Wiley Online Library on [15/06/2023]. See the Terms and Conditions (https://onlinelibrary.wiley.com/terms-and-conditions) on Wiley Online Library for rules of use; OA articles are governed by the applicable Creative Commons License

53 Gacto P, Barrera F, Pereyra JJ, Fernandez-Ortega P. Necrobiotic xanthogranuloma: efficacy of surgery in 2 patients. *Actas Dermosifiliogr* 2009; **100**: 499–502.
54 Chandra S, Finklestein E, Gill D. Necrobiotic xanthogranuloma occurring within linear morphoea. *Australas J Dermatol* 2002; **43**: 52–54.
55 Smith HG, Sargent LA, Lundgrin DB. Necrobiotic xanthogranuloma of the chest wall. *Dermatol Online J* 2006; **12**: 12.
56 Martinez Fernandez M, Rodriguez Prieto MA, Ruiz Gonzalez I, Sanchez Sambucety P, Delgado Vicente S. Necrobiotic xanthogranuloma associated with myeloma. *Journal of the European Academy of Dermatology and Venereology : JEADV* 2004; **18**: 328–331.
57 Stork J, Kodetova D, Vosmik F, Krejca M. Necrobiotic xanthogranuloma presenting as a solitary tumor. *Am J Dermatopathol* 2000; **22**: 453–456.
58 Saeki H, Tomita M, Kai H *et al.* Necrobiotic xanthogranuloma with paraproteinemia successfully treated with melphalan, prednisolone and skin graft. *J Dermatol* 2007; **34**: 795–797.
59 Schaudig U, Al-Samir K. Upper and lower eyelid reconstruction for severe disfiguring necrobiotic xanthogranuloma. *Orbit* 2004; **23**: 65–76.
60 Finelli LG, Ratz JL. Plasmapheresis, a treatment modality for necrobiotic xanthogranuloma. *J Am Acad Dermatol* 1987; **17**: 351–354.
61 Ghiasi N, Alavi A, Coutts PM, Ghazarian D, Sibbald RG. Necrobiotic xanthogranuloma as an unusual cause of refractive chronic bilateral leg ulceration. *Int J Low Extrem Wounds* 2012; **11**: 293–295.
62 Naghashpour M, Setoodeh R, Moscinski L *et al.* Nonnecrobiotic necrobiotic xanthogranuloma as an initial manifestation of paraproteinemia and small lymphocytic lymphoma in a patient with Sjogren syndrome. *Am J Dermatopathol* 2011; **33**: 855–857.
63 Szalat R, Arnulf B, Karlin L *et al.* Pathogenesis and treatment of xanthomatosis associated with monoclonal gammopathy. *Blood* 2011; **118**: 3777–3784.
64 Oestreicher J, Dookeran R, Nijhawan N, Kolin A. Necrobiotic xanthogranuloma with predominant periorbital involvement. *Ophthalmic Plast Reconstr Surg* 2010; **26**: 473–475.
65 Silapunt S, Chon SY. Generalized necrobiotic xanthogranuloma successfully treated with lenalidomide. *J Drugs Dermatol* 2010; **9**: 273–276.
66 Khan IJ, Azam NA, Sullivan SC, Habboush HW, Christian A. Necrobiotic xanthogranuloma successfully treated with a combination of dexamethasone and oral cyclophosphamide. *Can J Ophthalmol* 2009; **44**: 335–336.
67 Rayner SA, Duncombe AS, Keefe M, Theaker J, Manners RM. Necrobiotic xanthogranuloma occurring in an eyelid scar. *Orbit* 2008; **27**: 191–194.
68 Goede JS, Misselwitz B, Taverna C *et al.* Necrobiotic xanthogranuloma successfully treated with autologous stem cell transplantation. *Ann Hematol* 2007; **86**: 303–306.
69 Torabian SZ, Fazel N, Knuttle R. Necrobiotic xanthogranuloma treated with chlorambucil. *Dermatol Online J* 2006; **12**: 11.
70 Wells J, Gillespie R, Zardawi I. Case of recalcitrant necrobiotic xanthogranuloma. *Australas J Dermatol* 2004; **45**: 213–215.
71 Chang SE, Lee WS, Lee MW *et al.* A case of necrobiotic xanthogranuloma without paraproteinemia presenting as a solitary tumor on the thigh. *Int J Dermatol* 2003; **42**: 470–472.
72 Criado PR, Vasconcellos C, Pegas JR *et al.* Necrobiotic xanthogranuloma with lambda paraproteinemia: case report of successful treatment with melphalan and prednisone. *J Dermatolog Treat* 2002; **13**: 87–89.
73 Spraul CW, Wagner P, Lang GK. Bilateral necrobiotic xanthogranuloma of the eyelids with associated paraproteinemia: case report and review of literature. *Klin Monatsbl Augenheilkd* 2002; **219**: 55–58.
74 Machado S, Alves R, Lima M, Leal I, Massa A. Cutaneous necrobiotic xanthogranuloma (NXG)–successfully treated with low dose chlorambucil. *Eur J Dermatol* 2001; **11**: 458–462.
75 Westermann G, August C, Bonsmann G, Rahn KH, Kisters K. Necrobiotic xanthogranuloma with skin and liver amyloidosis. *Med Klin* 2001; **96**: 50–54.
76 Kossard S, Chow E, Wilkinson B, Killingsworth M. Lipid and giant cell poor necrobiotic xanthogranuloma. *J Cutan Pathol* 2000; **27**: 374–378.
77 Nestle FO, Hofbauer G, Burg G. Necrobiotic xanthogranuloma with monoclonal gammopathy of the IgG lambda type. *Dermatology* 1999; **198**: 434–435.
78 Hauser C, Schifferli J, Saurat JH. Complement consumption in a patient with necrobiotic xanthogranuloma and paraproteinemia. *J Am Acad Dermatol* 1991; **24**: 908–911.
79 Reeder CB, Connolly SM, Winkelmann RK. The evolution of Hodgkin's disease and necrobiotic xanthogranuloma syndrome. *Mayo Clin Proc* 1991; **66**: 1222–1224.
80 Plotnick H, Taniguchi Y, Hashimoto K, Negendank W, Tranchida L. Periorbital necrobiotic xanthogranuloma and stage I multiple myeloma. Ultrastructure and response to pulsed dexamethasone documented by magnetic resonance imaging. *J Am Acad Dermatol* 1991; **25**: 373–377.
81 Valentine EA, Friedman HD, Zamkoff KW, Streeten BW. Necrobiotic xanthogranuloma with IgA multiple myeloma: a case report and literature review. *Am J Hematol* 1990; **35**: 283–285.
82 Luck J, Layton A, Noble BA. Necrobiotic xanthogranuloma with orbital involvement. *J R Soc Med* 1992; **85**: 357–358.
83 Holden CA, Winkelmann RK. Wilson Jones E. Necrobiotic xanthogranuloma: a report of four cases. *Br J Dermatol* 1986; **114**: 241–250.
84 Bullock JD, Bartley GB, Campbell RJ, Yanes B, Connelly PJ, Funkhouser JW. Necrobiotic xanthogranuloma with paraproteinemia. case report and a pathogenetic theory. *Ophthalmology* 1986; **93**: 1233–1236.
85 Macfarlane AW, Verbov JL. Necrobiotic xanthogranuloma with paraproteinaemia. *Br J Dermatol* 1985; **113**: 339–343.

© 2016 European Academy of Dermatology and Venereology

14683083, 2017, 2, Downloaded from https://onlinelibrary.wiley.com/doi/10.1111/jdv.13786 by University Of Toronto Libraries, Wiley Online Library on [15/06/2023]. See the Terms and Conditions (https://onlinelibrary.wiley.com/terms-and-conditions) on Wiley Online Library for rules of use; OA articles are governed by the applicable Creative Commons License